



Multiple occurrence of premature polyarticular osteoarthritis in an early medieval Bohemian cemetery (Prague, Czech Republic)

Sylva Drtikolová Kaupová, Petr Velemínský, Jan Cvrček, Valér Džupa, Vítězslav Kuželka, Marek Laboš, Alena Němečková, Kateřina Tomková, Eliška Zazvonilová, Sacha Kacki

► To cite this version:

Sylva Drtikolová Kaupová, Petr Velemínský, Jan Cvrček, Valér Džupa, Vítězslav Kuželka, et al.. Multiple occurrence of premature polyarticular osteoarthritis in an early medieval Bohemian cemetery (Prague, Czech Republic). *International Journal of Paleopathology*, 2020, 30, pp.35-46. 10.1016/j.ijpp.2020.04.004 . hal-02921712

HAL Id: hal-02921712

<https://hal.science/hal-02921712>

Submitted on 11 Nov 2020

HAL is a multi-disciplinary open access archive for the deposit and dissemination of scientific research documents, whether they are published or not. The documents may come from teaching and research institutions in France or abroad, or from public or private research centers.

L'archive ouverte pluridisciplinaire **HAL**, est destinée au dépôt et à la diffusion de documents scientifiques de niveau recherche, publiés ou non, émanant des établissements d'enseignement et de recherche français ou étrangers, des laboratoires publics ou privés.

Multiple occurrence of premature polyarticular osteoarthritis in an early medieval Bohemian cemetery (Prague, Czech Republic)

Sylva Drtikolová Kaupová^{1*}, Petr Velemínský¹, Jan Cvrček^{1,2}, Valér Džupa³,
Vítězslav Kuželka¹, Marek Laboš⁴, Alena Němečková⁵, Kateřina Tomková⁶,
Eliška Zazvonilová^{2,6}, Sacha Kacki^{7,8}

¹ Department of Anthropology, National Museum, Václavské náměstí 68, 11579 Praha 1, Czech Republic

² Department of Anthropology and Human Genetics, Faculty of Science, Charles University, Viničná 7, 128 43, Praha 2, Czech Republic

³ Department of Orthopaedics and Traumatology, Third Faculty of Medicine, Charles University, and University Hospital Kralovské Vinohrady, Srobarova 50, 100 34, Praha 10, Czech Republic

⁴ Department of Radiodiagnostics, Third Faculty of Medicine, Charles University, and University Hospital Kralovské Vinohrady, Srobarova 50, 100 34, Praha 10, Czech Republic

⁵ Department of Histology and Embryology, Medical Faculty in Pilsen, Charles University, Karlovarská 48, 301 00, Pilsen, Czech Republic

⁶ Institute of Archaeology of the Czech Academy of Sciences, Prague, v.v.i., Letenská 4, 118 01 Praha 1, Czech Republic

⁷ CNRS, UMR 5199 PACEA, Université de Bordeaux, Bât. B8, Allée Geoffroy St Hilaire, CS 50023, 33615 Pessac cedex, France

⁸ Department of Archaeology, Durham University, South Road, Durham, DH1 3LE, United Kingdom

* Corresponding author.

E-mail addresses: sylv.kaupova@nm.cz (S. Drtikolová Kaupová), petr.veleminsky@nm.cz (P. Velemínský), jan.cvrcek@nm.cz (J. Cvrček), valer.dzupa@fnkv.cz (V. Džupa), vitezslav_kuzelka@nm.cz (V. Kuželka), mareklabos@seznam.cz (M. Laboš), alena.nemeckova@lfp.cuni.cz (A. Němečková), tomkova@arup.cas.cz (K. Tomková), zazvonilova@arup.cas.cz (E. Zazvonilová), sach.kacki@u-bordeaux.fr (S. Kacki).

Abstract

Objectives: To highlight conditions that may cause early-onset degenerative joint disease, and to assess the possible impact of such diseases upon everyday life.

Material: Four adults aged under 50 years from a medieval skeletal collection of Prague (Czechia).

Methods: Visual, osteometric, X-ray, and histological examinations, stable isotope analysis of bone collagen.

Results: All four individuals showed multiple symmetrical degenerative changes, affecting the majority of joints of the postcranial skeleton. Associated dysplastic deformities were observed in all individuals, including bilateral hip dysplasia (n=1), flattening of the femoral condyles (n=3), and substantial deformation of the elbows (n=3). The diet of the affected individuals differed from the contemporary population sample.

Conclusions: We propose the diagnosis of a mild form of skeletal dysplasia in these four individuals, with multiple epiphyseal dysplasia or type-II collagenopathy linked to premature osteoarthritis as the most probable causes.

Significance: Combining the skeletal findings with information from the medical literature, this paper defines several characteristic traits which may assist with the diagnosis of skeletal dysplasia in the archaeological record.

Limitations: As no genetic analysis was performed to confirm the possible kinship of the individuals, it is not possible to definitively assess whether the individuals suffered from the same hereditary condition or from different forms of skeletal dysplasia.

Suggestions for Further Research: Further studies on premature osteoarthritis in archaeological skeletal series are needed to correct the underrepresentation of these mild forms of dysplasia in past populations.

Keywords: skeletal dysplasia; multiple epiphyseal dysplasia; type II collagenopathies; hip dysplasia; Middle Ages

1. Introduction

Osteoarthritis (OA) is the most common joint pathology in human populations across time and space. It is characterized by marginal proliferation of new bone (marginal osteophytosis or “lipping”), porosity, eburnation and formation of new bone on the joint surface. Radiologically, subchondral sclerosis and cystic degeneration of subchondral bone are observed (Buikstra and Ubelaker, 1994; Ortner, 2003; Waldron, 2009).

According to a number of studies from both clinical and bio-archaeological spheres, age-related factors are the drivers of most of the changes associated with OA (e.g. Calce et al., 2018; Plomp et al. 2015; Sovers, 2001). However, the aetiology of OA is complex, with a number of factors including sex, hormones, nutrition, genetics, anatomy, muscle weakness, obesity, and physical activity affecting both disease onset and progression (Burt et al., 2013; Busija et al., 2010; Calce et al., 2018; Domett et al., 2017; Plomp et al., 2015; Sowers, 2001; Waldron, 2009; Weiss and Jurmain, 2007). The prevalence of moderate or severe OA associated with bone changes at large appendicular joints is, however, low before the 5th decade of life (Jordan et al., 2009; Ortner, 2003).

Severe OA occurring earlier in life is thus usually linked with pre-existing abnormalities in affected joints. Premature (secondary) OA may occur locally (monoarticular or pauciarticular OA) in joints affected by factors such as fractures, osteomyelitis, Paget’s disease or Legg-Calvé-Perthes (LCP) disease (Ortner, 2003; Waldron, 2009), or as a result of abnormal mechanical stress caused by repetitive activities (Busija et al., 2010; Weiss and Jurmain, 2007). The polyarticular form of premature OA is a rarer occurrence. It is most commonly observed as a secondary feature of systemic conditions affecting a higher number of joints such as erosive arthropathies or metabolic disorders (Ortner, 2003; Solomon, 2001; Waldron, 2009). In addition, gene mutations reducing the functional levels of either collagen fibers or collagen matrix protein, or altering key interactions in their assembly and function, can compromise the biomechanics of joint cartilage and thus lead to development of generalized early-onset OA (Briggs and Chapman, 2002; Hildebrand, 2015; Chapman et al., 2003; Jurgens et al., 2015; Kannu et al., 2010). There are examples of polyarticular hereditary premature OA affecting whole families (Kannu et al., 2010; Mier et al., 2001), but also large portions of geographically- or culturally-isolated populations representing genetically-inbred groups of people are known from clinical practice (Solomon, 2001).

Although Ortner (2003) stressed the significance of hereditary early-onset OA in bioarchaeological studies, cases of polyarticular premature OA are extremely rare in the

paleopathological literature. To the best of our knowledge, all reports published so far concern isolated cases, where OA is often linked to other more prominent skeletal pathologies (Domett et al., 2017; Kozieradzka-Ogunmakin, 2011). Typically, generalized OA (regardless of the age of the individual) is uncommon in skeletal assemblages (Waldron 2009).

In the early medieval skeletal series from the burial site of Milady Horákové Street in Prague, severe osteoarthritic changes non-accordant with age-at-death were observed in multiple joints of four adults, whose skeletal ages ranged from 18–24 to 30–49 years. Through the use of differential diagnosis for these four cases, we aim to address rare systemic conditions that may cause polyarticular premature OA, and call attention to skeletal traits that are linked to these conditions. We additionally discuss the possible consequences of these severe disabling conditions by reconstructing diet of the affected individuals, thus uncovering one of the most important indicators of the quality of everyday life.

2. The Milady Horákové site and the skeletal material

Between 2011 and 2013, an early medieval burial site was uncovered in Prague - Milady Horákové Street, a site close to Prague castle. The area of the burial site was almost fully excavated, revealing 84 graves, organized in regular rows, and containing the remains of 89 individuals (Figure 1). According to characteristics of the jewelry and ceramics, the burial site was in use from the end of the 9th until the first half of the 10th centuries (Tomková, 2013). Anthropological examination revealed some specific features of the population (see Methods below). First, the majority of remains were those of subadult individuals (n=47). Within the adults, six were estimated to be males, while 25 were classified as females (in seven cases, sex could not be estimated). A high prevalence of pathological conditions and dental anomalies was found in this population (Stránská, 2012a). This demographic and palaeopathological profile suggests that most of the males of productive age and in good physical condition were buried elsewhere. This might result from some specific function of adult males in relation the nearby Prague castle, while only those who were too young, ill, or weak remained to be buried at Milady Horákové (Kaupová et al., 2019). An analogous situation has been observed at other early medieval burial sites in Bohemia, but rarely so marked as in this case (Frolík, 2013; Stránská, 2012b).

The graves of the four individuals reported in this paper were scattered across the whole burial site (Figure 1) and did not show any deviation from the usual burial rite. They all showed a west-east orientation. With the exception of G.29, who was buried in a plain pit of relatively

straight dimensions, the other three graves probably had internal construction of wood and/or stones. Only G.74 contained simple grave goods represented by a knife and a ceramic pot (Tomková, 2013). Three of the skeletons were found intact, while in the case of G.29, later terrain modification had resulted in the loss of bones of both legs and feet. With this exception, skeletal material was satisfactorily preserved (Figure 2). However, substantial fragmentation affected the facial parts of skulls, vertebrae, and ribs, which limited the collection of osteometric data.

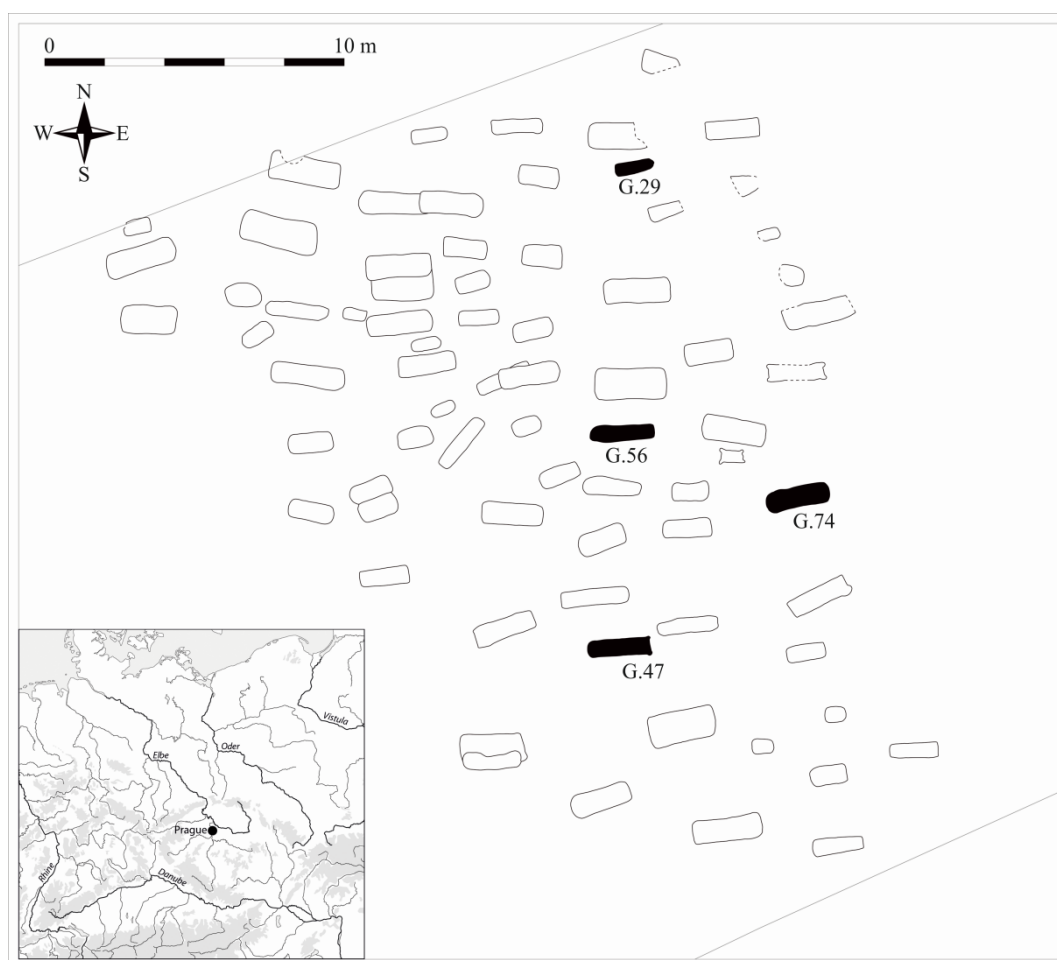

Figure 1. The geographical location of Prague in the area of Central Europe and the position of the graves of affected individuals within the cemetery area.

3. Methods

Sex was estimated on the basis of morphologic and morphometric evaluation of the innominate (Brůžek, 2002; Brůžek et al., 2017). Age-at-death estimation was based on assessment of skeletal maturation (Belcastro et al., 2019; Ferembach et al., 1980; Scheuer and

Black, 2000), as well as morphological changes of the pubic symphysis and auricular surface (Schmitt, 2005, 2008). However, as there is a substantial lack of systematic research on the potential effect of skeletal pathologies on osseous age-at-death indicators, these methods should be employed with caution in palaeopathological research (Bertrand et al. 2016). For this reason, the TCA (Tooth Cementum Annulation) method, based on the counting of annual increments of acellular cementum on the roots of monoradicular teeth (Colard et al., 2018; Wittwer-Backofen et al., 2004), was applied as an independent tool for age estimation. The first upper incisor was used in G.29 and G.74, while an upper canine was sampled in G.47 and G.56. An error range of ± 5 years was assumed for the final age estimation when using the TCA method (Rebay-Salisbury et al., 2018).

Skeletons were subject to a detailed macroscopic observation for pathological lesions with the help of a magnifying glass. The location of each bone change was recorded using skeletal diagrams, and its morphology was described, relying on standard paleopathological terminology.

X-ray examination was performed using computed radiography (CR) at the Department of Anthropology, National Museum, Prague. Limb bones were captured in anteroposterior and lateral views, while vertebrae were additionally captured in axial view. Bones were placed directly on the CR cassette, so the geometric magnification of the resulting images is negligible. The standard distance between focal point and CR cassette was 1.5 m, with tube voltages ranging between 48–55 kw and beam intensity between 8–20mAs.

Histological sections were prepared from two bones per individual (left capitate and left patella for G.29, right capitate and left patella for G.47, right lunate and left patella for G.56, and right capitate and right patella for G.74). Three samples were taken from each bone, with 10–12 slices per sample. Histological preparation and analysis were carried out at the Department of Histology and Embryology, Medical Faculty in Pilsen, Charles University. The collected tissue samples were fixed, then embedded in Epon blocks. The semithin sections were cut on an ultramicrotome using glass knives. Sections cut at 2–3 μm were floated in water and transferred to a drop of water on a clean microscope slide, and the slide with floating sections was then placed on a hot-plate pre-warmed to 60°C to adhere to the slide. The dried sections were then stained by dropping filtered toluidine blue onto the sections. After staining, slides were carefully rinsed with distilled water, dried and mounted in solacrylate. The semi-thin sections were examined under an Olympus BX 51 light microscope (Olympus, Tokyo, Japan).

Postcranial measurements were taken to estimate stature and body proportion. We used standard measurements as defined by Martin and Saller (1957) and Bräuer (1988). Maximal

lengths of humerus (H1), radius (R1), ulna (U1) femur (F1) and tibia (T1a) were taken and their ratios (F1/H1, T1a/R1, R1/H1 and T1a/F1) were calculated to describe potential disproportionality of the limbs and their parts. Next, F9, F10, T8a and T9a were measured, and the platymeric (F10/F9) and platycnemic (T9a/T8a) indexes were calculated. For the spine, metrical analysis of vertebral shape was performed to uncover potential platyspondyly (online appendix; Schiess and Haeusler, 2013).

Non-pathological individuals from the Milady Horákové burial site, as well as from other early medieval Prague (Střešovice, Lumbe Garden, Motol) and Czech burial sites (Žalov – Na Panenské, Libice, Lahovice), were measured to evaluate stature and body proportions of the four cases in the context of the contemporary population (N=119). For each individual, percentile rank of each measurement within the whole dataset was calculated. Stature was estimated using the length of the femur according to the formula proposed by Sjøvold (1990).

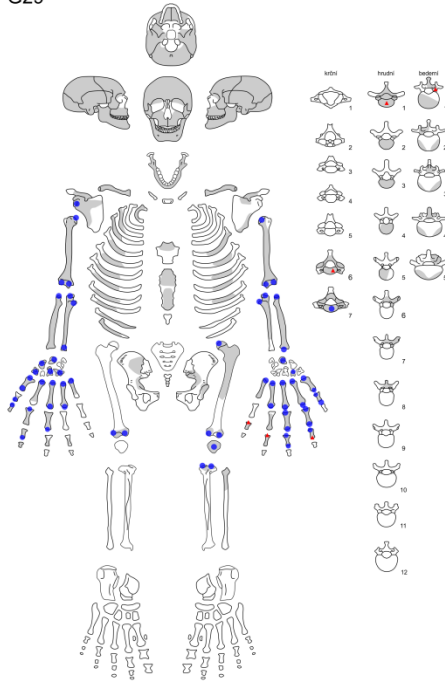
The diet of the affected individuals was reconstructed with the help of stable isotope analysis of carbon and nitrogen as a part of a wider study focused on the dietary behavior of the population of early medieval Bohemia. For technical details on the stable isotope analysis see Kaupová et al. (2019).

4. Results

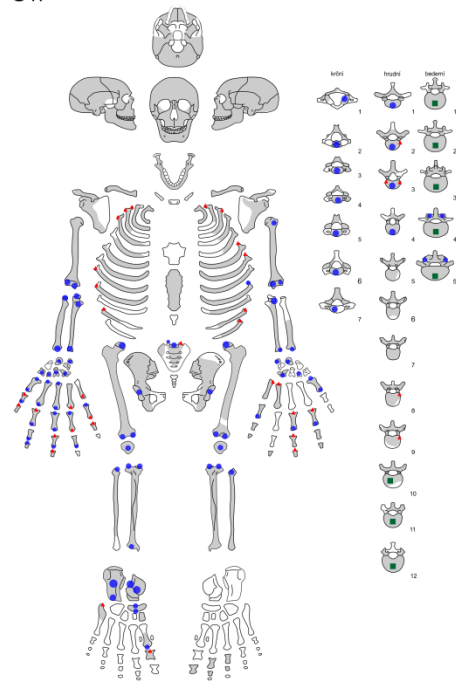
4.1. Macroscopic evaluation

Upon visual examination, all four individuals shared several common features. Notably, multiple severe degenerative lesions of the postcranial skeletons were observed, affecting the spine (zygapophyseal OA, marginal lipping of the vertebral bodies and endplate irregularities), large limb joints as well as small joints of the hand and foot, with the appendicular lesions being symmetrically distributed (Figure 2). In contrast, the temporomandibular joints (TMJs) were free of lesions, and the costae and clavicles were either not affected or showed only slight remodeling. None of the cranial and postcranial bones exhibited gross abnormalities in shape and/or proportions, and no abnormal scoliotic curvature of the spine was observed.

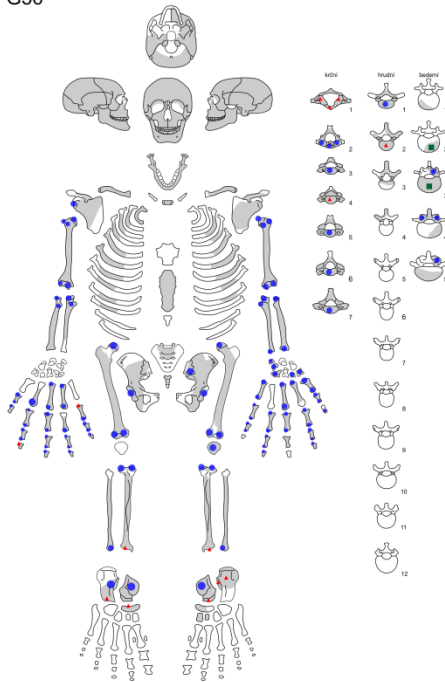
G29



G47



G56



G74

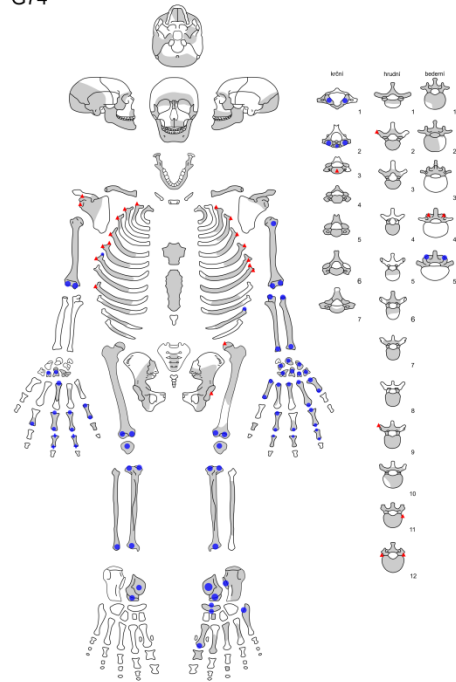


Figure 2. Skeletal distribution of severe (blue circles) and moderate (red triangles) degenerative lesions; at vertebrae, endplate irregularities are marked with green squares; preserved bones of each individual are marked in grey.

The individual uncovered in the grave 29 was assessed to be male, based at the morphology of the surviving parts of both innominates (Figure 2). He was aged 30–39 years at death, based on the complete maturation of the skeleton and state of the pubic symphysis, while the TCA method provided an age-at-death estimation of 41.8 ± 5 years (Table 1). The most severe osteoarthritic changes affected both shoulders, which in the other individuals were either non-pathological or only mildly affected. The distal humeral epiphyses appear deformed, and the articular surfaces are irregular (Figures 3 and 4). The medial condyle of the right femur shows slight but apparent flattening (Figure 5).

The male (according to the metrics of both innominates) buried in grave 47 was aged 30–49 years at death based on the maturation score of both pubic symphysis and auricular surface. The recently-fused sternal end of the clavicle with a still-visible epiphyseal line was noted as supplementary evidence of relatively young age (Belcastro et al. 2019), which is also supported by the TCA method (42.5 ± 5 years). This individual is visually the one for whom the pathological process appeared to be the most advanced among the four concerned individuals. Apart from diffuse osteoarthritic changes, deformities were observed in several joints: both elbows were severely deformed (Figures 3 and 4), the morphology of both hip joints corresponded with bilateral hip dysplasia (Figure 6), and the lateral femoral condyles were flattened bilaterally (Figure 5). Additional bone changes observed on the skeleton include a small lytic lesion on the major tubercle of the right humerus (Figure 7), endplate irregularities in some of the thoracic and all the lumbar vertebrae (Figure 8), *spondylolysis* at L5, and defects suggesting the presence of *osteochondritis dissecans* at the inferior articular surfaces of both tibiae and at the corresponding tali.

individual	tooth	TCA counts in 5 sections	SD	average tooth eruption	estimated TCA age in years	SD
G.29	first upper incisor	34.5	4.0	7.3	41.8	5.0
G.47	upper canine	31.2	3.1	11.3	42.5	5.0
G.56	upper canine	17.8	1.3	11.3	29.1	5.0
G.74	first upper incisor	24.0	1.9	7.3	31.3	5.0

Table 1. Age-at-death estimations of the four individuals from the Milady Horákové site, applying Tooth Cementum Annulation (TCA) technique; average age of tooth eruption according AlQhatani et al. (2010) for combined sexes was used.

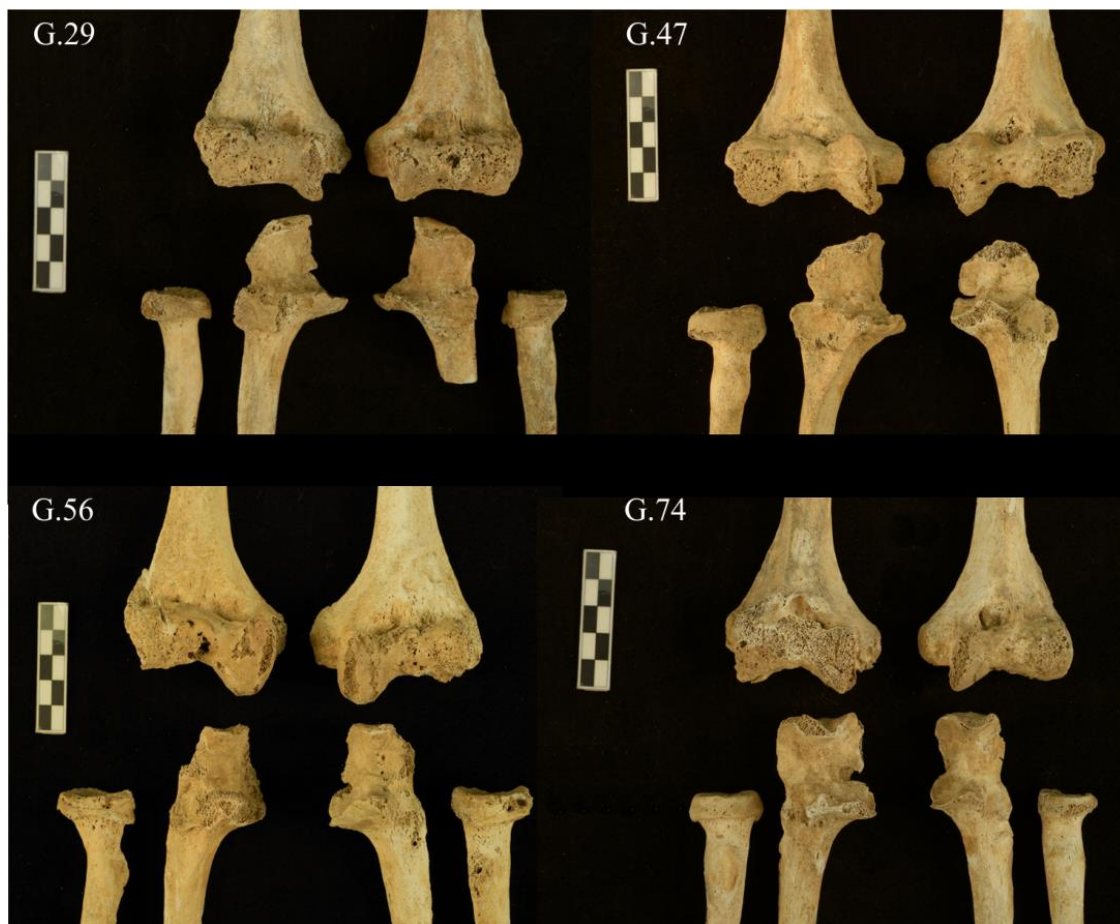


Figure 3. Anterior view of the elbows of all four individuals; Scale: 5 cm; Photo: M. Jantač.

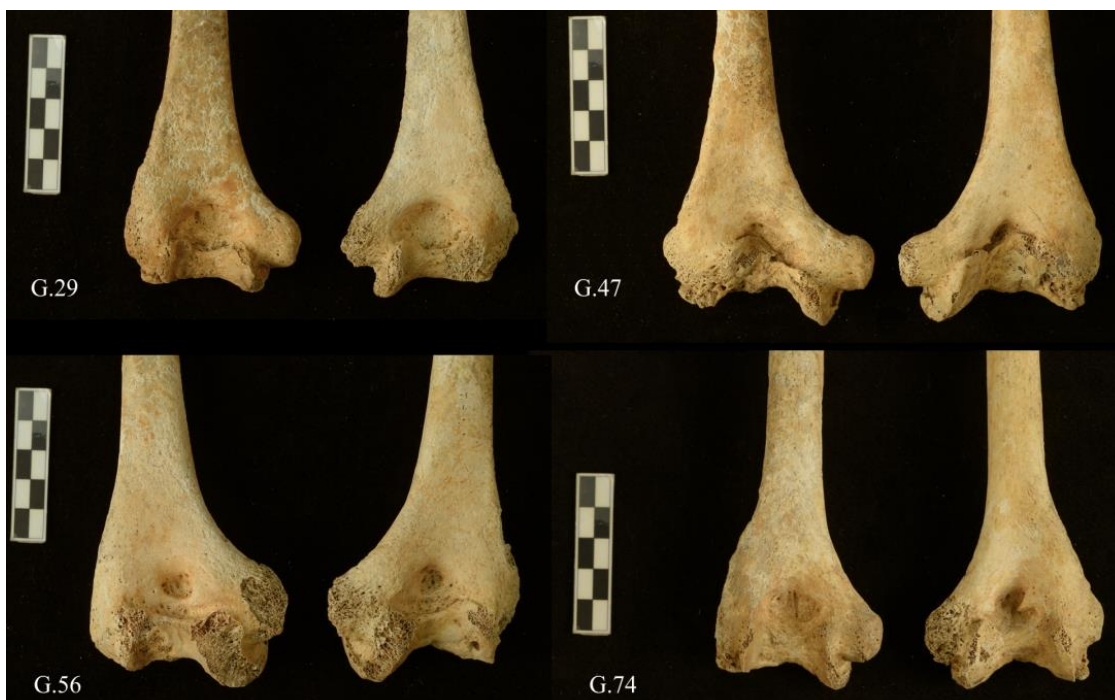


Figure 4. Posterior view of the humeri of all four individuals; note the substantial joint deformation; Scale: 5 cm; Photo: M. Jantač.

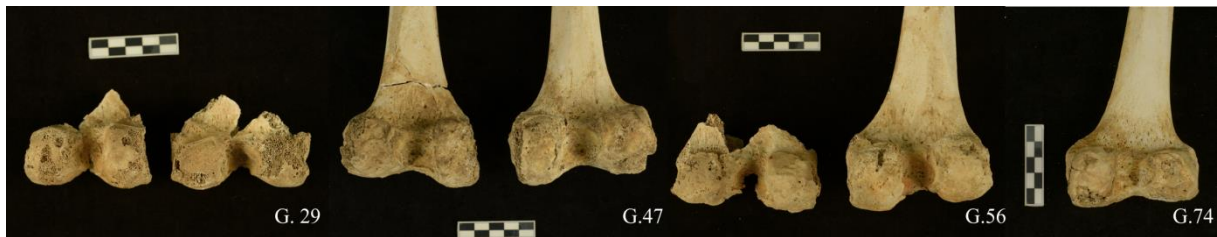

Figure 5. Posterior view of the preserved distal femoral epiphyses of all four individuals; note the flattening of the femoral condyles in G.29, G.47 and G.74 and the irregular articular surface of G.56; Scale: 5 cm; Photo: M. Jantač.

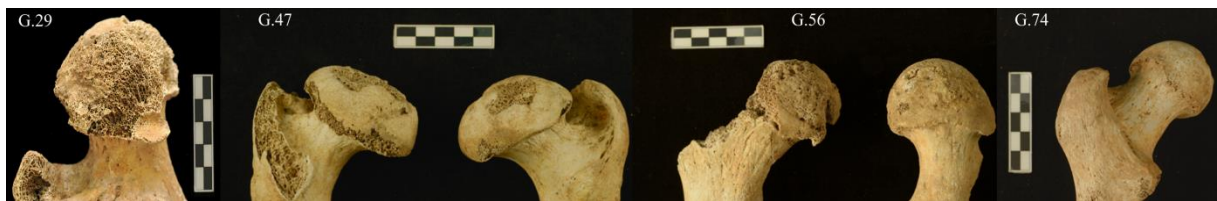

Figure 6. Views of the preserved femoral heads of all four individuals, highlighting the severe femoral head deformation in G.47; left femoral head of G.29 shows severe postmortem damage; Scale: 5cm; Photo: M. Jantač.



Figure 7. Views of the preserved humeral heads of G.47, G.56 and G.74; lytic lesions on the humeral tubercles marked with arrows; Scale: 5 cm; Photo: M. Jantač.

The individual buried in grave 56 was assessed to be male according to the metric evaluation of both innominates. He was the youngest of all the individuals, with an estimated age at death of 18–24 years based on the degree of skeletal maturation (unfused sternal end of the clavicle and iliac crests, and only partially fused humeral heads). The TCA method provided a slightly higher estimation of 29.1 ± 5 years, but both intervals are close to each other. As was the case for the above-described individual, both elbows were severely deformed (Figures 3 and 4). Additional pathological changes include *spondyloschisis* on the vertebral arch of the sixth cervical vertebra, endplate irregularities in two lumbar vertebrae (Figure 8), osteolytic lesions on both humeral tubercles (Figure 7), and *osteochondritis dissecans* at the inferior articular

surface of the right tibia. G.56 was the only one of the concerned individuals to exhibit a small (approx. 1×1 cm) erosive lesion of the auricular surface of the left ilium, but no other signs suggestive of sacroiliitis were present.

The last individual, buried in grave 74, was a female according to the morphology of the surviving parts of both innominates and the metric analysis of the better-preserved left-side bone. She was estimated to be 30–39 years old at death based on the complete maturation of the skeleton and the state of the auricular surface and pubic symphysis. The TCA method provided an estimate at the lower end of this interval (31.3 ± 5 years). In general, in this individual, osteoarthritic changes were less advanced than in the others. Both elbows showed substantial deformation (Figures 3 and 4) and the femoral condyles were visibly flattened (Figure 5). Additional bone changes include *spina bifida occulta*, enthesal changes at the lesser tubercle of the left humerus (Figure 7), and *osteocondritis dissecans* at the inferior articular surface of the left tibia.

From the description above, it is evident that all four individuals suffered from polyarticular OA non-accordant with their relatively young age. Elbows (Figures 3 and 4), knees (Figures 5 and 9), and the small joints of the hand were affected in all cases. A flattening of the epiphyses of the knee (Figure 5), severe deformation in the elbows (Figures 3 and 4), lytic lesions on the humeral tubercles (Figure 7) and aplastic defects of the neural arch were repeatedly observed.

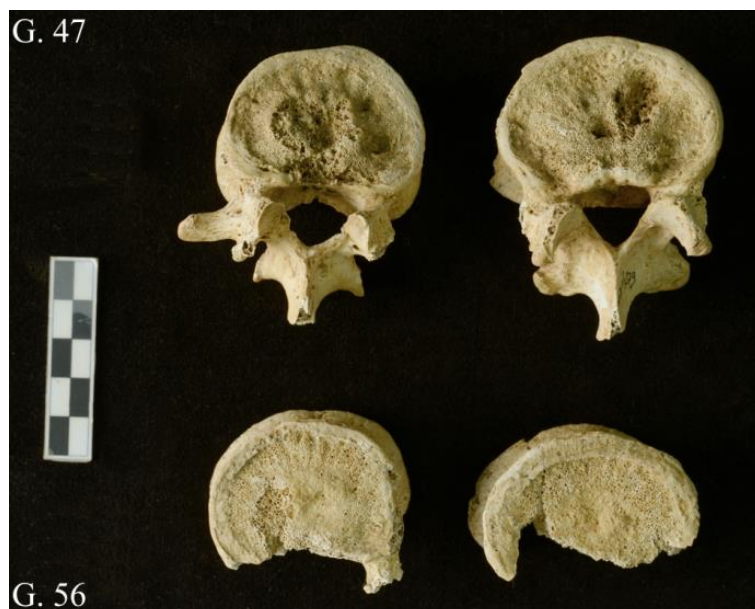

Figure 8. Example of the vertebral endplate irregularities of G.47 (Th12 and L1) and G.56 (L2 and L3); Scale: 5 cm; Photo: M. Jantač.



Figure 9. Superior view of the tibiae of G.47, G.56 and G.74; only small fragments of the left tibia were preserved in G.29; Scale: 5 cm; Photo: M. Jantač.

4.2. Radiographic and histological appearance

X-ray images showed a typical picture of degenerative changes with some subchondral cysts (Figure S1). Osteopenia was not observed. Histological images showed changes in subchondral bone, with lacunae of the cells that eroded the surface of the spongy trabeculae being apparent in the thin sections. The bone trabeculae underlying the traumatized eburnated surface showed cystic degeneration (Figure S2). In the patella of individual G.29, intra-trabecular resorption cavities filled with vascular connective tissue and with the appearance of granulation tissue (Figure S2) were found. The granulation tissue was originally composed of fibroblasts, vessels and round cell infiltration (Stevens et al., 2002).

4.3. Osteometric features

The stature of three of the four individuals appeared to be below average when compared to other early medieval Czech individuals of the same sex (Table 2). In G.29, maximum lengths of all the measurable long bones were the lowest among the entire dataset. The stature

calculation produced the value of 154 cm. The difference in the lowest measurement value compared to non-pathologic individuals varied between 10 (H1, U1) and 19 (F1) mm, which gives an approximately 5 cm difference in stature estimates (based on F1). In G.47, all the long bone lengths except T1 were the second lowest in the dataset (stature estimate = 156 cm). G.29 and G.47 also showed the shortest stature compared with the slightly younger dataset of 88 males from 11th to 14th-century Bohemia (Kaupová et al. 2013). In female G.74, stature was not as reduced, with all the maximum lengths (again with the exception of T1—percentile 44) varying between percentiles 10 and 20 (stature estimate = 159 cm). In contrast, G.56 showed above average stature, with all the measurable long bone lengths varying at or above the 80th percentile and a stature estimate of 176 cm.

The ratios that could be computed suggest that the affected individuals had relatively short femurs and long tibiae. Their values were, however, within or close to the normal population variability and in G.47, it could be at least partially affected by the dysplastic femoral heads. This also suggests that the above-mentioned statures may be slightly underestimated.

Interestingly, platymeric and platycnemic indexes of the affected individuals showed an unusual flattening of femurs in the antero-posterior axis and of tibiae in the medio-lateral axis.

Analysis of the shape of the vertebral bodies was limited due to the substantial fragmentation of vertebrae of the concerned individuals, as well as of the comparative dataset. However, the measurable dimensions of the four individuals did not suggest the presence of platyspondyly. For a detailed description of the vertebral metrics, see the online appendix.

4.4. Diet reconstruction

Isotopic analysis of the four individuals revealed a diet characterized by a low intake of animal products. This component of the diet differed in comparison with the majority of the Milady Horákové individuals (exact Mann-Whitney test; $p=0.007$ for nitrogen isotopic values), as well as with the rest of the population of early medieval Bohemia (Kaupová et al., 2019; Figure 10).

Measurement	Males									Females				
	n	Median	Range	G.29		G.47		G.56		n	Median	Range	G.74	
				Measurement	%ile	Measurement	%ile	Measurement	%ile				Measurement	%ile
H1	38	330	290-369	290	0	305	5	360	95	36	302.1	275-340	292	20
R1	34	247.5	219-275	219	0	225	3	262.5	79	36	228	199-260	212	14
U1	16	270	240-297	240	0	250	7	284	80	22	246.6	221-275	230.5	10
F1	52	457.5	400-517	400	0	405	2	482	84	62	418.5	370-465	403	16
F9	56	34	29-40	33	29	30	2	38	91	67	31	26-36	32	65
F10	56	26.5	19-32	22	2	19	0	23	7	67	23	19-29	21.2	18
T1	36	372	335-425			350	14			46	345	298-397	342	44
T8a	52	34.5	27-42			29	2	30.5	6	63	31	26-37	27.5	13
T9a	51	24	21-28			23	24	22.5	22	63	22	18-25	24	89
F1/H1	34	0.71	0.68-0.75	0.73	67	0.75	97	0.75	91	32	0.72	0.70-0.78	0.72	68
T1/R1	23	0.66	0.62-0.69			0.64	9			26	0.65	0.62-0.70	0.62	0
R1/H1	28	0.75	0.72-0.81	0.76	56	0.74	19	0.73	7	31	0.75	0.70-0.78	0.73	23
T1/F1	34	0.81	0.76-0.86			0.86	100			41	0.82	0.77-0.89	0.85	82.5
Platymeric index	55	0.77	0.61-0.97	0.67	11	0.63	3	0.61	0	67	0.74	0.66-0.93	0.66	2
Platycnemic index	51	0.69	0.56-0.84			0.79	92	0.73	78	62	0.71	0.57-0.87	0.87	100

Table 2. Comparison of postcranial metric data of the four documented cases with those of other individuals of the same sex from early medieval Bohemia; n = number of individuals; %ile = percentile; percentiles under 10 and above 90 in bold font; n, median and range are calculated including the affected individuals; preferentially, left-side bones were measured, when absent or fragmented, measurement was taken from the right side.

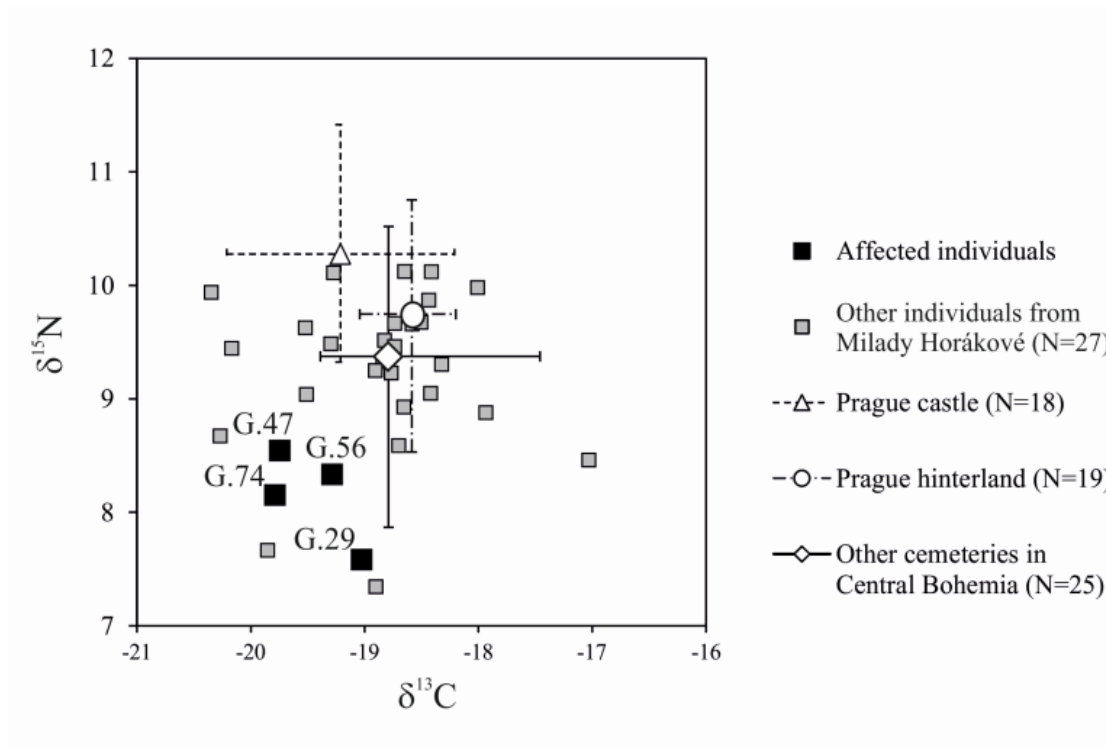


Figure 10. Carbon and nitrogen isotopic values of the four affected individuals compared to the Milady Horákové population and other early medieval burial sites from Central Bohemia (mean, percentile 2.5 and 97.5); higher nitrogen isotopic value indicates higher consumption of animal products, higher carbon isotopic value indicates higher consumption of millet; modified according to Kaupová et al. (2019).

5. Differential diagnosis

Differential diagnosis focused on two main groups of skeletal disorders: inflammatory arthropathies and skeletal dysplasias resulting in premature OA (Table 3). Metabolic causes of premature OA such as gout, alkaptonuria, mucopolysaccharidoses or Paget's disease can be ruled out due to the absence of characteristic skeletal symptoms of these conditions (e.g. *humerus varus* deformity, *dysostosis multiplex*, scooped-out defects, fusion of vertebral bodies), normal X-ray images, as well as age-at-death of the affected individuals (Kacki et al., 2013; Ortner, 2003; Waldron, 2009; White, 2011).

Amongst inflammatory polyarthropathies, rheumatoid arthritis (RA) can be readily dismissed based on the presence of significant bone proliferation in all the affected individuals, location of erosive lesions in central parts of the joint surfaces, and significant involvement of the spine including thoracic and lumbar vertebrae (Ortner, 2003; Waldron, 2009).

	G.29	G.47	G.56	G.74	DJD	RA	JIA	SpAs	SED	MED	Type II collagenopathies
Sex/Sex predilection	Male	Male	Male	Female	None	Females	Females	None	None (exc. X-linked form)	None	None
Stature	Moderately reduced	Moderately reduced	Above-average	Below-average	Normal	Normal	Normal	Normal	Short-trunk dwarfism	Normal or moderately reduced	Normal
Lesions symmetry	(+)	(+)	(+)	(+)	(-)	(+)	(+)	(-)	(+)	(+)	(+)
Bone proliferation	(+)	(+)	(+)	(+)	(+)	(-)	(-)	(+)	(+)	(+)	(+)
Bone erosion	(+)	(+)	(+)	(+)	(-)	(+) mainly marginal	(+) mainly marginal	(+)	(+)	(+)	(+)
Joint ankylosis	(-)	(-)	(-)	(-)	(-)	(+/-)	(+)	(+)	(-)	(-)	(-)
Osteopenia	(-)	(-)	(-)	(-)	(-)	(+)	(+)	(-)	(-)	(-)	(-)
Enteseal changes (erosive lesions)	(-)	(+)	(+)	(+)	(+); rotator cuff disease	(+/-)	(+/-)	(+)	(?)	(?)	(?)
TMJ involvement	(-)	(-)	(-)	(-)	(-)	(+/-)	(+)	(+)	(-)	(-)	(-)
Spine involvement	(+)	(+)	(+)	(+)	(+)	(+/-; cervical spine)	(+; cervical spine)	(+)	(+)	(+)	(+)
Vertebral endplate irregularities	Non-evaluable	(+)	(+)	(-)	(+)	(-)	(-)	(-)	(+)	(+)	(+)
Sacroiliitis	(-)	(-)	(-)	(-)	(-)	(+/-) may be found but uncommon	(-)	(+)	(?)	(?)	(?)
Distal humerus dysplasia	(-/+)	(+)	(+)	(+)	(-)	(-)	(-)	(-)	(+)	(+)	(+)

Flattened epiphyses of the knee	(+)	(+)	(-)	(+)	(-)	(-)	(-)	(-)	(+)	(+)	(+)
Hip dysplasia	(-)	(+)	(-)	(-)	(-)	(+/-) may be found but uncommon	(-)	(-)	(+)	(+)	(+)
Fibrovascular granulation tissue in the histological image	(+)	(-)	(-)	(-)	(-)	(-)	(-)	(-)	(?)	(+)	(?)

Table 3 . Distinctive features of degenerative joint disease (DJD), rheumatoid arthritis (RA), spondyloarthropathies (SpAs), spondylo-epiphyseal dysplasia (SED), multiple epiphyseal dysplasia (MED) and type II collagenopathies, and their presence in the skeletons under study; (+) presence; (+/-) possible but not common presence; (-) absence; (?) not described in the medical literature

Juvenile chronic arthritis (juvenile idiopathic arthritis; JIA) could also be considered, as at least one-third of the patients exhibited ongoing active disease into their adult years and others show sequelae of previous inflammation (Foster et al., 2003). However, diagnosis of JIA is improbable in the current cases, as JIA resembles the clinical picture of adult type RA, and characteristic features of JIA were absent, including bony ankyloses of carpals and tarsals and diarthrodial joints of the spine, involvement of the TMJ, and general underdevelopment of the mandible (Burt et al., 2013; Ortner, 2003; Twilt et al., 2004; Weiss and Ilowite, 2007).

From the group of spondyloarthropathies (SpAs), psoriatic arthritis, inflammatory bowel disease-related arthritis and undifferentiated SpAs could be considered due to their polyarticular involvement including that of the large appendicular joints. As with RA, juvenile forms of SpAs have been described (Rothschild et al., 1997), so the young age of the individuals (especially G.56) does not preclude this diagnosis. Enthesal changes at fibrocartilaginous attachments, which are typical for SpAs (Benjamin and McGonagle, 2001; Villotte and Kacki, 2009), were observed in three individuals (G.47, G.56 and G.74) at the insertion of *m. supraspinatus*, *m. infraspinatus* and *m. subscapularis*. However, osteolytic lesions at the rotator cuff are also relatively common in individuals without SpA (Villotte and Kacki, 2009), thus such observations could not be used as exclusive criteria for SpA. Moreover, sacroiliitis, which is typical of SpA, was not present. Further, asymmetry of lesions is an important diagnostic criterion for SpAs. From other characteristic traits of SpAs, the TMJ was spared, neither ankyloses of the spine nor the typical cup-and-pencil morphology of interphalangeal joints was observed, and distal interphalangeal joints did not show greater severity of lesions than other joints (Ortner, 2003; Samsel et al., 2014; Waldron, 2009).

Certain conditions from the wide spectrum of skeletal dysplasias must be considered as potential causes of bone changes observed in the four individuals. In both spondylo-epiphyseal dysplasia (SED) and multiple epiphyseal dysplasia (MED), a number of genes may be involved causing, for example, defects of type II or IX collagen fibers, collagen matrix protein (COMP), proteins involved in intracellular transport, or defects of growth factors controlling expression of collagen (e.g. Garcia Segarra et al., 2012; Chapman et al., 2003; Terhal et al., 2015). These mutations result in defects in cartilage formation and maintenance, leading to premature OA.

For SED, major involvement of the spine is typical, resulting in disproportion between the trunk and limbs. The more severe congenital forms (SEDC) may be excluded, as typical clinical findings include severely reduced stature (with a height below -7 SD, in general below 150 cm), with marked platyspondyly and a posterior wedging of the vertebrae. In adults, the anteroposterior diameter of the vertebrae is severely reduced. Furthermore, odontoid

hypoplasia, coxa vara with flattened femoral heads, flattened femoral condyles, genua vara/valga, cleft palate or clubfoot, and broad thorax are commonly found in SEDC patients (Amirfeyz et al., 2005; Terhal et al., 2015). With the exception of flattened distal femurs and dysplastic femoral heads, none of these traits was found in any of the studied individuals.

The other forms of SED, which manifest in later childhood (SED-tarda; SEDT) and thus show milder degrees of dysplasia with less affected stature and body proportions, may be considered for some individuals. They can be excluded, however, for the female individual G.74, due to their X-linked recessive inheritance (Amirfeyz et al., 2005; Bannerman et al., 1971; Garcia Segarra et al., 2012). Some of the characteristic features of SEDT were present in the other individuals, namely vertebral endplate irregularities, dysplastic hips, *osteochondritis dissecans* and other changes related to premature OA. On the other hand, platyspondyly, anterior wedging of the vertebrae, brachydactyly, or pelvic deformities with small ilia compensated by long ischia and pubis (Schantz et al., 1988) were not observed, making this diagnosis unlikely. A specific type of SEDT with progressive arthropathy (SEDT-PA) is also improbable due to the absence of characteristic traits such as platyspondyly, brachydactyly with enlarged metaphyses and epiphyses of MCP and phalanges, hypoplastic or fused carpals and/or tarsals, osteopenia and periarticular calcifications (Garcia Segarra et al., 2012; Kocyigit et al., 2000; Wynne-Davis, 1982; Yoleri et al., 2011).

Considering the absence of platyspondyly and short-trunk stature, MED seems to be a more probable diagnosis. The condition, which has in most cases an autosomal-dominant inheritance, is characterized by predominant involvement of the epiphyses, where an irregular epiphyseal growth affects a pair or many joints symmetrically, forming flattened and dysplastic articular surfaces. Stature of the affected individuals is normal or moderately short (about 150 cm in adults), but cases with above-average height have also been described (Ballhausen et al., 2003; Chapman et al., 2003; Jakkula et al., 2004; Unger et al., 2008; Wynne-Davies and Gormley, 1985). In addition, body proportions are usually normal, or in some cases mild shortening of the limbs may occur (Haga et al., 1998). The hips and knees are prominently affected in MED patients but the involvement of hands, feet, ankles and shoulders have been noted (Jakkula et al., 2004). For the spine, endplate irregularities are typical, but mild platyspondyly may also occur, as well as genu varum or valgum. Hip dysplasia (observed in G.47) is typical. In clinical practice, when cases of bilateral hip dysplasia (and LCP disease) are diagnosed, further testing for MED is strongly advised (Unger et al., 2008). Importantly, the histological finding of granulation tissue observed in several histological sections of G.29 is typical of MED (Stevens et al., 2002), further supporting this diagnosis.

Much less common autosomal recessive forms of MED are improbable, as several characteristic traits (prominent thumbs, brachydactyly, accelerated ossification of carpals resulting in reduced carpal width, club foot or so called “double-layered patella”) were not present in any of the studied individuals (Ballhausen et al., 2003; Huber et al., 2001; Mäkitie et al., 2003; Unger et al., 2008).

A final differential diagnosis, at the mildest end of the spectrum of skeletal dysplasias, is the group of type II collagenopathies. Premature OA is a leading symptom of these autosomal inherited disorders. Symmetrical lesions of virtually all large and small joints of the postcranial skeleton, without substantial changes in stature and/or body proportions, are typical. The onset of disease is relatively late in comparison to other skeletal dysplasias and varies widely between late childhood and early adulthood (Ala-Kokko et al., 1990; Hildebrand, 2015; Hoornaert et al., 2006; Hoornaert et al., 2007; Husar-Memmer et al., 2013; Jurgens et al., 2015; Kannu et al., 2010). Vertebral endplate irregularities are common, while scoliosis and mild platyspondyly may occur but without substantial impact on stature or body proportions (Ala-Kokko et al., 1990). *Osteochondritis dissecans*, flattened epiphyses of the knee joint and hip dysplasia imitating LCP disease are also common (Hoornaert et al., 2006; Husar-Memmer et al., 2013; Kannu et al., 2010).

6. Discussion

6.1. A picture of mild skeletal dysplasia

All four individuals from the Milady Horákové site show skeletal changes consistent with the diagnosis of skeletal dysplasia as described in the medical literature, including symmetrical osteoarthritic lesions of the postcranial skeleton, dysplasia of the joints (i.e. dysplastic hips imitating LCP disease, severe deformation of the distal humerus, and visibly flattened femoral condyles), endplate irregularities of the vertebrae, and *osteochondritis dissecans*. The absence of severe stature reduction (moderate stature reduction was observed in G.29 and G.47) and the absence of substantial changes in body proportion suggest that the causative condition(s) is/are from the mild end of the dysplasia spectrum, with a moderate form of MED or a type II collagenopathy being the most probable diagnoses. A definitive diagnosis cannot be made, however, as there is a considerable variation in the clinical manifestations of these conditions, making it impossible to distinguish between the conditions on the basis of skeletal lesions alone.

Even in clinical practice, genetic testing is needed to determine the exact type of dysplasia (Jurgens et al., 2015; Terhal et al., 2015).

Since the prevalence of skeletal dysplasia is extremely low (Ikegawa, 2006), the co-occurrence of four cases within the Milady Horákové cemetery, which was used for a brief duration, suggests that all four individuals may have suffered from the same skeletal dysplasia. This would be well in accord with the autosomal dominant inheritance of both MED and type II collagenopathy. However, in the absence of genetic analysis of the skeletons, it is not possible to assess the kinship of the individuals and to confirm this hypothesis. The four individuals may alternatively have suffered from different forms of skeletal dysplasia, co-occurring in the same population. It is noteworthy, however, that the slightly different distribution of skeletal lesions among the four individuals cannot be viewed as evidence for differing diagnoses, as a huge range of variation in clinical manifestation can be observed within one family (Kannu et al., 2010).

The involvement of the elbows in all of the individuals would perhaps make a type II collagenopathy a more probable diagnosis, as severe involvement of the elbows is not described in MED patients. However, it should be mentioned that OA of the elbow is much more common in archaeological populations than in modern populations (Domett et al., 2017; Ortner, 2003). The reasons for this are not understood, but differing workloads is considered a likely cause (Felson, 1994).

6.2. Skeletal features unreported in the medical literature

Alongside classic bone changes linked to skeletal dysplasia caused by MED and type II collagenopathy, the four skeletons from the Milady Horákové cemetery exhibit bone changes that are not described in the medical literature. First, the involvement of entheses is not described as a feature of either MED or type II collagenopathies. However, tendons and entheses include, to a great extent, the same components as cartilage (e.g. collagen types II and IX, cartilage oligomeric matrix protein). Defects of genes encoding these proteins are among the most common causes of MED or premature OA (Briggs and Chapman, 2002; Hildebrand, 2015; Chapman et al., 2003; Jurgens et al., 2015; Kannu et al., 2010). Experimentally, dramatic changes in the biomechanical properties of tendons have been found in individuals with COMP mutation related to MED (Piróg et al., 2010). Thus, the involvement of muscular insertions of the rotator cuff observed in G.47, G.56 and G.74 (Figure 7) may hypothetically be caused by MED and type II collagenopathy. Moreover, the rotator cuff region is a common site of

microtrauma resulting from excessive load (Benjamin and McGonagle, 2001). Both micro and macrotrauma might occur when locomotion in individuals is compromised by severely-affected hips and knees. Finally, pitting may be found at insertions of rotator cuff muscles together with osteoarthritic changes of the gleno-humeral and acromio-clavicular joints in a degenerative condition called rotator cuff disease (Hardy et al., 1986; Waldron, 2009).

Aplastic defects of the vertebral neural arch (observed in G.49, G.56 and G.74) are also not reported in association with MED and type II collagenopathy, but have been linked to other skeletal dysplasias (Schiess and Haeusler, 2013). Developing from improper endochondral ossification, isolated defects of the neural arch have been found to be caused by mutations in the same genes as cause MED (Cai et al., 2015). The absence of reports of these defects in clinical records may be due to their clinical unimportance. However, the co-occurrence of these defects in at least three of the four individuals (the spine of the fourth individual, G.29 fragmentary) clearly deserves our attention as a potential trait of mild skeletal dysplasia observable in the archaeological record, but should not be overinterpreted since *spina bifida occulta* (G. 74) is a relatively common condition (Ferembach, 1963). Similarly, spondylolysis (G.47) may result from trauma, especially in individuals with chronic overload (hyperextension) of the lumbar spine (in today's populations e.g. in gymnasts and basketball players) and occurs in hereditary disorders of connective tissues (Marfan syndrome, Ehlers-Danlos syndrome) and generalized inflammatory diseases (rheumatoid arthritis) (Hailer and Hailer, 2018; Horn et al., 2018; Selhorst et al., 2019). Alternatively, the co-occurrence of these developmental anomalies may also reflect kinship of the concerned individuals rather than their pathology (Barnes, 2012; Pietrusewsky and Douglas, 1992).

As the degree of platymery and platycnemy are traditionally linked to physical load (Ruff et al., 2006), the unusual shape of the shafts of the femur and tibia could also be caused by unusual loading in order to preserve mobility. Lastly, the effect of nutrition cannot be excluded (Angel, 1984), as well as a genetic component (Lovejoy et al., 2003), as the affected individuals were possibly biologically related.

6.3. Social effects of skeletal dysplasia

Although in the context of skeletal dysplasias, the presence of MED and type II collagenopathy are relatively mild, they would still have impacted the quality of life. Skeletal dysplasias are associated with pain and reduced mobility. In present-day populations, most

affected individuals undergo surgery during puberty or early adulthood. Skeletal dysplasias may also be associated with ocular and hearing problems, especially when the mutation of genes encoding type II collagen is involved (Terhal et al., 2015). All of these symptoms might lead to dependence of the affected individual on his or her family or wider society.

It is interesting that the diet of the four individuals differed from that of the majority of the Milady Horákové population, as well as from the rest of the population of early medieval Bohemia (Kaupová et al., 2019), showing a characteristically low dietary input of animal products. Digestive or metabolic problems, which could cause the observed isotopic pattern, have not been described in skeletal dysplasias. Other reasons for their somewhat unique diet, such as migration, cannot be excluded (note that the dietary pattern was not exclusive to the affected individuals). The present data suggest that the disability of these people may have limited their access to animal products. Also, we cannot exclude the possibility that the mild stature reduction observed in G.29 and G.47 resulted from improper diet during the period of growth, rather than from the skeletal dysplasia itself, or that both direct and indirect effects of the disease acted in synergy. However, it should be noted here that isotopic analysis of bone collagen reconstructs diet from the last decades of individual's life. To describe the childhood diet, a different sampling strategy using tooth dentine is needed (Balasse et al., 1999).

6. Conclusion

The four skeletons from the Milady Horákové site exhibit bone changes that are consistent with a set of milder forms of skeletal dysplasia, such as multiple epiphyseal dysplasia or type II collagenopathy. Only a few isolated cases of most severe forms of the conditions, showing notable change in stature and/or body proportion, have been described in the palaeopathological literature (Arcini and Frölund, 1996; Kozieradzka-Ogunmakin, 2011; Wakely, 2000), and these do not include isolated cases of premature OA (Domett et al., 2017). Although the prevalence of skeletal dysplasias causing premature OA is usually very low (Amirfeyz et al., 2005; Unger et al., 2008), it is possible that this condition might be under reported in skeletal series, as well.

Based on clinical literature, we recommend considering a diagnosis of MED and/or type II collagenopathy in cases of bilateral hip dysplasia. Our study calls attention to other skeletal lesions that may potentially be associated with mild skeletal dysplasia such as defects of the vertebral neural arch and erosive lesions at entheses. We advocate further study of the potential links between skeletal dysplasias and these less reported conditions. Also, further study focusing on premature OA in skeletal populations are needed to identify mild forms of dysplasia

in the archaeological record and to better assess their impact upon everyday life of affected individuals in past populations.

Acknowledgements: We would like to thank the following institutions for financial support: Czech Science Foundation (Grant number: 14-36938G), Ministry of Culture of the Czech Republic (Grant number: DKRVO 2019-2023/7.II.a, 00023272), National Museum. We thank International Science Editing for the English language editing and Marek Jantač for the photographic documentation. Finally, we appreciate the insightful editor and reviewer comments on a first version of this manuscript.

Declaration of competing interest: none.

Funding: This work was supported by the Czech Science Foundation (Grant number: 14-36938G) and the Ministry of Culture of the Czech Republic (Grant number: DKRVO 2019-2023/7.II.a, 00023272), National Museum; funding sources had no involvement in study design; in the collection, analysis and interpretation of data; in the writing of the report; and in the decision to submit the article for publication.

References

- Ala-Kokko, L., Baldwin, C.T., Moskowitz, R.W., Prockop, D.J., 1990. Single base mutation in the type II procollagen gene (COL2A1) as a cause of primary osteoarthritis associated with a mild chondrodysplasia. *Proceedings of the National Academy of Sciences* 87, 6565-6568.
- AlQahtani, S., Hector, M., Liversidge, H., 2010. Brief communication: The London atlas of human tooth development and eruption. *American Journal of Physical Anthropology* 142, 481-490.
- Amirfeyz, R., Clark, C., Gargan, M., 2005. Spondyloepiphyseal dysplasia. *Current Orthopaedics* 19, 309-313.
- Angel, J.L., 1984. Health as a crucial factor in the changes from hunting to developed farming in the eastern Mediterranean, in: Cohen, M.N., Armelagos, G.J. (Eds.), *Paleopathology at the Origins of Agriculture*. Academic Press, Orlando, pp. 51-73.
- Arcini, C., Frölund, P., 1996. Two dwarves from Sweden: A unique case. *International Journal of Osteoarchaeology* 6, 155-166.
- Ballhausen, D., Bonafé, L., Terhal, P., Unger, S.L., Bellus, G., Classen, M., Hamel, B.C., Spranger, J., Zabel, B., Cohn, D.H., Cole, W.G., Hecht, J.T., Superti-Furga, A., 2003. Recessive multiple epiphyseal dysplasia (rMED): phenotype delineation in eighteen homozygotes for *DTDST* mutation R279W. *Journal of Medical Genetics* 40, 65-71.
- Bannerman, R.M., Ingall, G.B., Mohn, J.F., 1971. X-linked spondyloepiphyseal dysplasia tarda: clinical and linkage data. *Journal of medical genetics* 8, 291-301.
- Barnes, E., 2012. *Atlas of developmental field anomalies of the human skeleton: a paleopathology perspective*. Wiley-Blackwell, Hoboken.

- Belcastro, M.G., Pietrobelli, A., Rastelli, E., Iannuzzi, V., Toselli, S., Mariotti, V., 2019. Variations in epiphyseal fusion and persistence of the epiphyseal line in the appendicular skeleton of two identified modern (19th–20th c.) adult Portuguese and Italian samples. *American Journal of Physical Anthropology* 169, 448–463.
- Benjamin, M., McGonagle, D., 2001. The anatomical basis for disease localisation in seronegative spondyloarthropathy at entheses and related sites. *Journal of Anatomy* 199, 503–526.
- Bertrand, B., Schug, G. R., Polet, C., Naji, S., Colard, T., 2016. Age-at-death estimation of pathological individuals: A complementary approach using teeth cementum annulations. *International Journal of Paleopathology* 15, 120–127.
- Bräuer, G., 1988. Osteometrie, in: Knussman, R. (Ed.), *Anthropologie. Handbuch der Vergleichenden Biologie des Menschen. Band I. Wesen und Methoden der Anthropologie*. Gustav Fischer Verlag, Stuttgart, pp. 160–231.
- Briggs, M.D., Chapman, K.L., 2002. Pseudoachondroplasia and multiple epiphyseal dysplasia: Mutation review, molecular interactions, and genotype to phenotype correlations. *Human Mutation* 19, 465–478.
- Brůžek, J., 2002. A method for visual determination of sex, using the human hip bone. *American Journal of Physical Anthropology* 117, 157–168.
- Brůžek, J., Santos, F., Dutailly, B., Murail, P., Cunha, E., 2017. Validation and reliability of the sex estimation of the human os coxae using freely available DSP2 software for bioarchaeology and forensic anthropology. *American Journal of Physical Anthropology* 164, 440–449.
- Buikstra, J., Ubelaker, D., 1994. Standards for data collection from human skeletal remains. *Arkansas Archaeological Survey, Fayetteville*.
- Burt, N.M., Semple, D., Waterhouse, K., Lovell, N.C., 2013. *Identification and Interpretation of Joint Disease in Paleopathology and Forensic Anthropology*. Charles C Thomas Publisher, Springfield.
- Busija, L., Bridgett, L., Williams, S.R.M., Osborne, R.H., Buchbinder, R., March, L., Fransen, M., 2010. Osteoarthritis. *Best Practice & Research Clinical Rheumatology* 24, 757–768.
- Cai, T., Yang, L., Cai, W., Guo, S., Yu, P., Li, J., Hu, X., Yan, M., Shao, Q., Jin, Y., Sun, Z.S., Luo, Z.-J., 2015. Dysplastic spondylolysis is caused by mutations in the diastrophic dysplasia sulfate transporter gene. *Proceedings of the National Academy of Sciences* 112, 8064–8069.
- Calce, S.E., Kurki, H.K., Weston, D.A., Gould, L., 2018. The relationship of age, activity, and body size on osteoarthritis in weight-bearing skeletal regions. *International Journal of Paleopathology* 22, 45–53.
- Colard, T., Bertrand, B., Naji, S., Delannoy, Y., Bécart, A., 2018. Toward the adoption of cementochronology in forensic context. *International Journal of Legal Medicine* 132, 1117–1124.
- Domett, K., Evans, C., Chang, N., Tayles, N., Newton, J., 2017. Interpreting osteoarthritis in bioarchaeology: Highlighting the importance of a clinical approach through case studies from prehistoric Thailand. *Journal of Archaeological Science: Reports* 11, 762–773.
- Felson, D.T., 1994. Do occupation-related physical factors contribute to arthritis? *Baillière's Clinical Rheumatology* 8, 63–77.
- Ferembach, D., 1963. Frequency of Spina Bifida Occulta in Prehistoric Human Skeletons. *Nature* 199, 100–101.
- Ferembach, D., Schwindezy, I., Stoukal, M., 1980. Recommendation for age and sex diagnoses of skeletons. *Journal of Human Evolution* 9, 517–549.

- Foster, H.E., Marshall, N., Myers, A., Dunkley, P., Griffiths, I.D., 2003. Outcome in adults with juvenile idiopathic arthritis: A quality of life study. *Arthritis & Rheumatism* 48, 767-775.
- Frolík, J., 2013. Das Gräberfeld im Lumbe-Garten auf der Prager Burg - eine Fallstudie zur Untersuchung der Sozialstruktur des 10. Jahrhunderts, in: Biermann, F., Kersting, T., Klammt, A. (Eds.), *Soziale Gruppen und Gesellschaftsstrukturen im westslawischen Raum, Beiträge zur Ur- und Frühgeschichte Mitteleuropas* 70, Langenweissbach, pp. 33-42.
- Garcia Segarra, N., Mittaz, L., Campos-Xavier, A.B., Bartels, C.F., Tuysuz, B., Alanay, Y., Cimaz, R., Cormier-Daire, V., Di Rocco, M., Duba, H.C., Elcioglu, N.H., Forzano, F., Hospach, T., Kilic, E., Kuemmerle-Deschner, J.B., Mortier, G., Mrusek, S., Nampoothiri, S., Obersztyn, E., Pauli, R.M., Selicorni, A., Tenconi, R., Unger, S., Utine, G.E., Wright, M., Zabel, B., Warman, M.L., Superti-Furga, A., Bonafe, L., 2012. The diagnostic challenge of progressive pseudorheumatoid dysplasia (PPRD): a review of clinical features, radiographic features, and WISP3 mutations in 63 affected individuals. *American Journal of Medical Genetics. Part C, Seminars in Medical Genetics* 160C, 217-229.
- Haga, N., Nakamura, K., Takikawa, K., Manabe, N., Ikegawa, S., Kimizuka, M., 1998. Stature and Severity in Multiple Epiphyseal Dysplasia. *Journal of Pediatric Orthopaedics* 18, 394-397.
- Hailer, Y.D., Hailer, N.P., 2018. Is Legg-Calvé-Perthes Disease a Local Manifestation of a Systemic Condition? *Clinical Orthopaedics and Related Research* 476, 1055-1064.
- Hardy, D.C., Vogler, J.B., White, R.H., 1986. The shoulder impingement syndrome: prevalence of radiographic findings and correlation with response to therapy. *American Journal of Roentgenology* 147, 557-561.
- Hildebrand, B., 2015. Mutation in the type II collagen gene (COL2A1) as a cause of early osteoarthritis and juvenile idiopathic arthritis—A pseudorheumatoid arthritis variant. *Seminars in Arthritis and Rheumatism* 44, e22.
- Hoornaert, K.P., Dewinter, C., Vereecke, I., Beemer, F.A., Courtens, W., Fryer, A., Fryssira, H., Lees, M., Müllner-Eidenböck, A., Rimoin, D.L., Siderius, L., Superti-Furga, A., Temple, K., Willems, P.J., Zankl, A., Zweier, C., De Paepe, A., Coucke, P., Mortier, G.R., 2006. The phenotypic spectrum in patients with arginine to cysteine mutations in the COL2A1 gene. *Journal of Medical Genetics* 43, 406-413.
- Hoornaert, K.P., Marik, I., Kozlowski, K., Cole, T., Le Merrer, M., Leroy, J.G., Coucke, P.J., Sillence, D., Mortier, G.R., 2007. Czech dysplasia metatarsal type: another type II collagen disorder. *European Journal Of Human Genetics* 15, 1269.
- Horn, S.R., Shepard, N., Poorman, G.W., Bortz, C.A., Segreto, F.A., Janjua, M.B., Diebo, B.G., Vira, S., Passias, P., 2018. National Trends in the Prevalence, Treatment, and Associated Spinal Diagnoses Among Pediatric Spondylolysis Patients. *Bulletin of the NYU Hospital for Joint Diseases* 76, 246-251.
- Huber, C., Odent, S., Rumeur, S., Padovani, P., Penet, C., Cormier-Daire, V., Munnich, A., Le Merrer, M., 2001. Sulphate transporter gene mutations in apparently isolated club foot. *Journal of Medical Genetics* 38, 191-193.
- Husar-Memmer, E., Ekici, A., Al Kaissi, A., Sticht, H., Manger, B., Schett, G., Zwerina, J., 2013. Premature osteoarthritis as presenting sign of type II collagenopathy: a case report and literature review, *Seminars in arthritis and rheumatism*. Elsevier, pp. 355-360.
- Chapman, K.L., Briggs, M.D., Mortier, G.R., 2003. Review: clinical variability and genetic heterogeneity in multiple epiphyseal dysplasia. *Pediatric Pathology & Molecular Medicine* 22, 53-75.
- Ikegawa, S. 2006. Genetic analysis of skeletal dysplasia: recent advances and perspectives in the post-genome-sequence era. *Journal of Human Genetics* 51, 581-586.

- Jakkula, E., Mäkitie, O., Czarny-Rataczak, M., Jackson, G.C., Damignani, R., Susic, M., Briggs, M.D., Cole, W.G., Ala-Kokko, L., 2004. Mutations in the known genes are not the major cause of MED; distinctive phenotypic entities among patients with no identified mutations. *European Journal of Human Genetics* 13, 292.
- Jordan, J.M., Helmick, C.G., Renner, J.B., Luta, G., Dragomir, A.D., Woodard, J., Fang, F., Schwartz, T.A., Nelson, A.E., Abbate, L.M., Callahan, L.F., Kalsbeek, W.D., Hochberg, M.C., 2009. Prevalence of Hip Symptoms and Radiographic and Symptomatic Hip Osteoarthritis in African Americans and Caucasians: The Johnston County Osteoarthritis Project. *The Journal of Rheumatology* 36, 809-815.
- Jurgens, J., Sobreira, N., Modaff, P., Reiser, C.A., Seo, S.H., Seong, M.-W., Park, S.S., Kim, O.H., Cho, T.-J., Pauli, R.M., 2015. Novel COL2A1 Variant (c.619G>A, p.Gly207Arg) Manifesting as a Phenotype Similar to Progressive Pseudorheumatoid Dysplasia and Spondyloepiphyseal Dysplasia, Stanescu Type. *Human Mutation* 36, 1004-1008.
- Kacki, S., Duneufjardin, P., Blanchard, P., Castex, D., 2013. Humerus Varus in a Subadult Skeleton from the Medieval Graveyard of La Madeleine (Orléans, France). *International Journal of Osteoarchaeology* 23, 119-126.
- Kannu, P., Bateman, J.F., Randle, S., Cowie, S., du Sart, D., McGrath, S., Edwards, M., Savarirayan, R., 2010. Premature arthritis is a distinct type II collagen phenotype. *Arthritis & Rheumatism* 62, 1421-1430.
- Kaupová, S., Brůžek, J., Velemínský, P., Černíková, A., 2013. Urban-rural differences in stature in the population of medieval Bohemia. *Anthropologischer Anzeiger* 70, 43-55.
- Kaupová, S., Velemínský, P., Stránská, P., Bravermanová, M., Frolíková, D., Tomková, K., Frolík, J., 2019. Dukes, elites, and commoners: dietary reconstruction of the early medieval population of Bohemia (9th–11th Century AD, Czech Republic). *Archaeological and Anthropological Sciences* 11, 1887-1909.
- Kocyigit, H., Arkun, R., Ozkinay, F., Cogulu, O., Hizli, N., Memis, A., 2000. Spondyloepiphyseal dysplasia tarda with progressive arthropathy. *Clinical Rheumatology* 19, 238-241.
- Kozieradzka-Ogunmakin, I., 2011. Multiple epiphyseal dysplasia in an Old Kingdom Egyptian skeleton: A case report. *Int J Paleopathol* 1, 200-206.
- Lovejoy, C.O., Meindl, R.S., Pryzbeck, T.R., Mensforth, R.P., 1985. Chronological metamorphosis of the auricular surface of the ilium: a new method for the determination of adult skeletal age at death. *American Journal of Physical Anthropology* 68, 15-28.
- Lovejoy, O.C., McCollum, M.A., Reno, P.L., Rosenman, B.A., 2003. Developmental biology and human evolution. *Annual Review of Anthropology* 32, 85-109.
- Mäkitie, O., Savarirayan, R., Bonafé, L., Robertson, S., Susic, M., Superti-Furga, A., Cole, W.G., 2003. Autosomal recessive multiple epiphyseal dysplasia with homozygosity for C653S in the *DTDST* gene: Double-layer patella as a reliable sign. *American Journal of Medical Genetics Part A* 122A, 187-192.
- Martin, R., Saller, K., 1957. *Lehrbuch der Anthropologie*. Fischer, Stuttgart.
- McKern, T.W., Stewart, T.D., 1957. Skeletal age changes in young American males analysed from the standpoint of age identification, in: Technical report EP 45. Quartermaster Research and Development Center, Environmental Protection Research Division. Natick, Massachusetts, pp 89-97.
- Mier, R.J., Holderbaum, D., Ferguson, R., Moskowitz, R., 2001. Osteoarthritis in Children Associated with a Mutation in the Type II Procollagen Gene (COL2A1). *Molecular Genetics and Metabolism* 74, 338-341.
- Ortner, D.J., 2003. Identification of pathological conditions in human skeletal remains. Academic Press.

- Perricone, C., Ceccarelli, F., Valesini, G., 2011. An overview on the genetic of rheumatoid arthritis: A never-ending story. *Autoimmunity Reviews* 10, 599-608.
- Pietrusewsky, M., Douglas, M. T., 1992. The skeletal biology of an historic Hawaiian cemetery: Familial relationships. *Homo* 43, 245-262.
- Piróg, K.A., Jaka, O., Katakura, Y., Meadows, R.S., Kadler, K.E., Boot-Handford, R.P., Briggs, M.D., 2010. A mouse model offers novel insights into the myopathy and tendinopathy often associated with pseudoachondroplasia and multiple epiphyseal dysplasia. *Human Molecular Genetics* 19, 52-64.
- Plomp, K.A., Roberts, C.A., Strand Viðarsdóttir, U., 2015. Morphological characteristics of healthy and osteoarthritic joint surfaces in archaeological skeletons. *International Journal of Osteoarchaeology* 25, 515-527.
- Rebay-Salisbury, K., Pany-Kucera, D., Spannagl-Steiner, M., Kanz, F., Galeta, P., Teschler-Nicola, M., Salisbury, R. B., 2018. Motherhood at Early Bronze Age Unterhautzenthal, Lower Austria. *Archaeologia Austriaca* 102, 71-134.
- Rothschild, B.M., HersHKovitz, I., Bedford, L., Latimer, B., Dutour, O., Rothschild, C., Jellema, L.M., 1997. Identification of childhood arthritis in archaeological material: juvenile rheumatoid arthritis versus juvenile spondyloarthropathy. *American Journal of Physical Anthropology* 102, 249-264.
- Ruff, C., Holt, B., Trinkaus, E., 2006. Who's afraid of the big bad Wolff?: "Wolff's law" and bone functional adaptation. *American Journal of Physical Anthropology* 129, 484-498.
- Samsel, M., Kacki, S., Villotte, S., 2014. Palaeopathological diagnosis of spondyloarthropathies: Insights from the biomedical literature. *International Journal of Paleopathology* 7, 70-75.
- Schantz, K., Andersen, P.E., Justesen, P., 1988. Spondyloepiphyseal dysplasia tarda: Report of a family with autosomal dominant transmission. *Acta Orthopaedica Scandinavica* 59, 716-719.
- Scheuer, L., Black, S., 2000. *Developmental juvenile osteology*. Academic Press, New York.
- Schiess, R., Haeusler, M., 2013. No skeletal dysplasia in the nariokotome boy KNM-WT 15000 (homo erectus)—A reassessment of congenital pathologies of the vertebral column. *American Journal of Physical Anthropology* 150, 365-374.
- Schmitt, A., 2005. Une nouvelle méthode pour estimer l'âge au décès des adultes à partir de la surface sacro-pelvienne iliaque. *Bulletins et Mémoires de la Société d'Anthropologie de Paris*, 89-101.
- Schmitt, A., 2008. Une nouvelle méthode pour discriminer les individus décédés avant ou après 40 ans à partir de la symphyse pubienne. *Journal de Médecine Légale Droit Médical* 51, 15-24.
- Selhorst, M., Fischer, A., MacDonald, J., 2019. Prevalence of Spondylolysis in Symptomatic Adolescent Athletes: An Assessment of Sport Risk in Nonelite Athletes. *Clinical Journal of Sport Medicine* 29, 421-425.
- Sjøvold, T., 1990. Estimation of stature from long bones utilizing the line of organic correlation. *Human Evolution* 5, 431-447.
- Solomon, L., 2001. Clinical features of osteoarthritis, in: Harris, E., Sledge, C. (Eds.), *Kelley's Textbook of Rheumatology*. Saunders, Philadelphia, pp. 1409-1418.
- Sowers, M., 2001. Epidemiology of risk factors for osteoarthritis: systemic factors. *Current Opinion in Rheumatology* 13, 447-451.
- Stevens, A., Lowe, J.S., Young, B., Wheeler, P.R., Burkitt, H.G., 2002. *Wheater's basic histopathology: a colour atlas and text*. Churchill Livingstone, London.
- Stránská, P., 2012a. Anthropological examination of the skeletal material from the Milady Horákové cemetery. *Archeologický ústav AV ČR Praha, v.v.i., Prague*.

- Stránská, P., 2012b. Pohřebiště na Levém Hradci a jeho předpolí z pohledu antropologie, in: Tomková, K. (Ed.), *Levý Hradec v zrcadle archeologických výzkumů I*. Archeologický ústav AV ČR Praha, v.v.i., Prague, pp. 354-380.
- Terhal, P.A., Nievelstein, R.J.A., Verver, E.J., Topsakal, V., van Dommelen, P., Hoornaert, K., Le Merrer, M., Zankl, A., Simon, M.E., Smithson, S.F., 2015. A study of the clinical and radiological features in a cohort of 93 patients with a COL2A1 mutation causing spondyloepiphyseal dysplasia congenita or a related phenotype. *American Journal of Medical Genetics Part A* 167, 461-475.
- Tomková, K., 2013. Urbs Praga und Levý Hradec - von Sklaven zu Fürsten. In: Biermann, F., Kersting, T., Klammt, A. (Eds.), *Soziale Gruppen und Gesellschaftsstrukturen im westslawischen Raum, Beiträge zur Ur- und Frühgeschichte Mitteleuropas* 70, Langenweissbach, pp 43-55.
- Twilt, M., Mober, S.M.L.M., Arends, L.R., ten Cate, R., van Suijlekom-Smit, L., 2004. Temporomandibular involvement in juvenile idiopathic arthritis. *The Journal of Rheumatology* 31, 1418-1422.
- Unger, S., Bonafé, L., Superti-Furga, A., 2008. Multiple epiphyseal dysplasia: clinical and radiographic features, differential diagnosis and molecular basis. *Best Practice & Research Clinical Rheumatology* 22, 19-32.
- Villotte, S., Kacki, S., 2009. Remodelages des entheses fibrocartilagineuses dans les spondylarthropathies inflammatoires l'exemple du cimetière du couvent des Sœurs Grises de Beauvais (Oise), XVe-XVIIIe siècles. *Bulletins et Mémoires de la Société d'Anthropologie de Paris* 21, 159-169.
- Wakely, J., 2000. Possible case of spondylo-epiphyseal dysplasia in a medieval skeleton. *Clinical Anatomy* 13, 11-16.
- Waldron, T., 2009. *Palaeopathology*. Cambridge University Press, Cambridge.
- Weiss, E., Jurmain, R., 2007. Osteoarthritis revisited: a contemporary review of aetiology. *International Journal of Osteoarchaeology* 17, 437-450.
- Weiss, J.E., Ilowite, N.T., 2007. Juvenile Idiopathic Arthritis. *Rheumatic Disease Clinics of North America* 33, 441-470.
- White, K.K., 2011. Orthopaedic aspects of mucopolysaccharidoses. *Rheumatology* 50, v26-v33.
- Wittwer-Backofen, U., Gampe, J., Vaupel, J. W., 2004. Tooth cementum annulation for age estimation: results from a large known-age validation study. *American Journal of Physical Anthropology* 123, 119-129.
- Wynne-Davies, R., Gormley, J., 1985. The prevalence of skeletal dysplasias. An estimate of their minimum frequency and the number of patients requiring orthopaedic care. *The Journal of Bone and Joint Surgery. British volume* 67-B, 133-137.
- Wynne-Davis, R., 1982. Spondyloepiphyseal dysplasia tarda with progressive arthropathy. *The Journal of Bone and Joint Surgery* 64, 442-445.
- Yoleri, O., Oz, B., Olmez, N., Memi, A., Gelal, F., 2011. Spondyloepiphyseal dysplasia tarda with progressive arthropathy complicated with paraplegia. *American Journal of Physical Medicine & Rehabilitation* 90, 490-494.