



HAL
open science

Severe COVID-19-related encephalitis can respond to immunotherapy

Albert Cao, Benjamin Rohaut, Loïc Le Guennec, Samir Saheb, Clémence Marois, Victor Altmayer, Vincent T Carpentier, Safaa Nemlaghi, Marie Soulie, Quentin Morlon, et al.

► **To cite this version:**

Albert Cao, Benjamin Rohaut, Loïc Le Guennec, Samir Saheb, Clémence Marois, et al.. Severe COVID-19-related encephalitis can respond to immunotherapy. *Brain - A Journal of Neurology*, 2020, <10.1093/brain/awaa337>. <hal-02918661v3>

HAL Id: hal-02918661

<https://hal.science/hal-02918661v3>

Submitted on 7 Sep 2020 (v3), last revised 3 Dec 2020 (v4)

HAL is a multi-disciplinary open access archive for the deposit and dissemination of scientific research documents, whether they are published or not. The documents may come from teaching and research institutions in France or abroad, or from public or private research centers.

L'archive ouverte pluridisciplinaire **HAL**, est destinée au dépôt et à la diffusion de documents scientifiques de niveau recherche, publiés ou non, émanant des établissements d'enseignement et de recherche français ou étrangers, des laboratoires publics ou privés.



HAL Authorization

Severe COVID-19-related encephalitis can respond to immunotherapy

Albert Cao, MD^{1,*}; Benjamin Rohaut, MD, PhD^{1,2,3,4,*,#}; Loic Le Guennec, MD, PhD^{1,2}; Samir Saheb⁵, MD¹; Clémence Marois, MD¹; Victor Altmayer, MA¹; Vincent T Carpentier, MSc¹; Safaa Nemlaghi, MD^{2,6}; Marie Soulie MD⁷, MD; Quentin Morlon, MD⁸; Bryan Berthet-Delteil, MD⁹; Alexandre Bleibtreu, MD, PhD¹⁰; Mathieu Raux, MD, PhD^{2, 11}; Nicolas Weiss, MD, PhD^{1,2,12}; Sophie Demeret MD¹

On the behalf of CoCo-Neurosciences study group.

* These authors contributed equally to this work

Corresponding author

¹ AP-HP, Groupe Hospitalier Universitaire APHP-Sorbonne Université, site Pitié-Salpêtrière, Department of Neurology, Neuro-ICU, Paris, France.

² Sorbonne Université, Paris, France

³ Brain institute - ICM, Sorbonne Université, Inserm U1127, CNRS UMR 7225, F-75013, Paris, France.

⁴ Department of Neurology, Columbia University, New York, NY, USA.

⁵ AP-HP, Groupe Hospitalier Universitaire APHP-Sorbonne Université, site Pitié-Salpêtrière, Department of Hemobiotherapy, Paris, France.

⁶ AP-HP, Groupe Hospitalier Universitaire APHP-Sorbonne Université, site Pitié-Salpêtrière, Service de Pneumologie, Médecine Intensive et Réanimation (Département R3S) and Sorbonne Université, INSERM, UMRS1158 Neurophysiologie Respiratoire Expérimentale et Clinique, F-75005 Paris, France.

⁷ AP-HP, Department of Critical Care, Hôpital Avicenne, AP-HP GHU-93. Bobigny, France.

⁸ AP-HP, Department of Critical Care, Hôpital Louis Mourier, AP-HP.Université de Paris. Colombes, France.

⁹ Medical and Surgical Intensive Care Unit, Groupe Hospitalier Paris Saint Joseph, Paris, France.

¹⁰ AP-HP, Groupe Hospitalier Universitaire APHP-Sorbonne Université, site Pitié-Salpêtrière, Department of Infectious and Tropical Diseases, AP-HP, Paris, France.

¹¹ AP-HP, Groupe Hospitalier Universitaire APHP-Sorbonne Université, site Pitié-Salpêtrière, Department of Anesthesiology & Critical Care, AP-HP, Paris, France.

¹² Sorbonne Université, Brain Liver Pitié-Salpêtrière Study group, INSERM UMR_S 938, Centre de Recherche Saint-Antoine & Institute of Cardiometabolism and Nutrition (ICAN), Paris, France

Correspondence:

Dr Benjamin Rohaut MD, PhD

Mail : benjamin.rohaut@sorbonne.universite.fr

Tel: +33 (0) 1 84 82 78 88

Postal Address:

Hôpital de la Pitié-Salpêtrière
Département de Neurologie
Unité de Reanimation Neurologique
47-83 Boulevard de l'Hôpital
PARIS 75013

ABSTRACT

Background: Neurological manifestations have been reported during coronavirus disease-2019 (COVID-19) but encephalitis has seldom been reported. The role immunotherapy is unclear.

Methods: We report five consecutive patients with severe COVID-19-related encephalitis treated with plasma exchange (PLEX) and corticosteroids in a 16-bed French Neuro-intensive care unit. Encephalitis was diagnosed after sedation withdrawal in patients initially admitted for a COVID-19 related acute respiratory distress syndrome. PLEX and corticosteroids were proposed for these brain-injured patients, as an immune-related mechanism was suspected.

Results: Patients (4 males, one female) were aged 37 to 77 years and presented with various central neurological manifestations including severe consciousness impairment, movement disorders, and brainstem dysfunction. In addition to brain involvement, one patient had a COVID-19 related acute inflammatory polyradiculoneuropathy. All patients had pathological brain magnetic resonance imaging findings, whereas cerebrospinal fluid (CSF) cytological and biochemical results were unremarkable. Reverse transcription-polymerase chain-reaction (RT-PCR) assay of the CSF was negative for SARS-CoV-2 for all patients. The interval between COVID-19 symptoms onset and diagnosis of neurological impairment ranged from 17 to 36 days. Three patients showed a rapid neurological improvement with consciousness recovery within 7 days after immunotherapy initiation.

Conclusions: Despite potentially severe clinical presentations, some COVID-19 related encephalitis patients can respond to immunotherapy (PLEX and corticosteroids) supporting the hypothesis of a host-immune response to SARS-CoV-2.

Keywords: *COVID-19, SARS-CoV-2, post-infectious encephalitis, plasma exchange, corticosteroids, immunotherapy*

INTRODUCTION

Since December 2019, an outbreak of infections due to severe acute respiratory syndrome-coronavirus 2 (SARS-CoV-2) has rapidly spread worldwide and various coronavirus disease-2019 (COVID-19)-related neurological symptoms have been reported (Filatov *et al.*, 2020, Helms *et al.*, 2020b; Mao *et al.*, 2020; Moriguchi *et al.*, 2020; Oxley *et al.*, 2020; Poyiadji *et al.*, 2020; Khoo *et al.*, 2020; Paterson *et al.*, 2020).

Although a neuro-invasive potential of SARS-CoV-2 is suspected – as for others coronaviruses –, there are few reports of COVID-19-associated encephalitis (Huang *et al.*, 2020; Le Guennec *et al.*, 2020; Moriguchi *et al.*, 2020; Paterson *et al.*, 2020). An immune-mediated mechanism has been proposed to explain coronaviruses associated encephalitis (Weyhern *et al.*, 2020), and immunotherapy has shown interesting results in a recent case series of COVID-19 mild meningoencephalitis (PLEX; Dogan *et al.*, 2020) and one out of two patients with encephalitis in a more recent series (immunoglobulins; Paterson *et al.*, 2020).

Herein, we report a case series of five patients treated by PLEX and corticosteroids for severe COVID-19 related encephalitis.

MATERIALS AND METHODS

We report a consecutive series of patients diagnosed with severe COVID-19-related encephalitis treated with plasma exchange (PLEX) and corticosteroids from an observational cohort (CoCo Neurosciences study - NCT04362930, see acknowledgement). SARS-CoV-2 was detected by reverse transcription-polymerase chain-reaction (RT-PCR) in nasopharyngeal swab or tracheal aspirate. In the absence of other causes of consciousness impairment (i.e. toxic or metabolic), COVID-19 related neurological disorder was suspected to be responsible for delayed awakening after sedation withdrawal. All patients had routine blood tests, cerebrospinal fluid (CSF) analysis, electroencephalogram (EEG), and brain magnetic resonance imaging (MRI). A comprehensive workup was performed in all patients

to rule out an alternative diagnosis, including PCR detection of *Herpesviridae* in CSF, and testing for neuronal antibodies in the blood and the CSF (see Supplementary material for details).

Because of the suspicion of post-infectious inflammatory or immune-mediated encephalitis, PLEX sessions (5 to 10 with albumin as a replacement solution; see Supplementary material for details) and corticosteroids infusions (methylprednisolone 1g/day – 5 to 10 days) were proposed as a therapeutic strategy. Consent was obtained from patient's legal surrogate in accordance with French regulations. The study received approval from the Sorbonne University Ethic Committee (CER-202028 on 24/04/2020).

RESULTS

Five patients aged between 37 and 77 years with suspected COVID-19 related encephalitis presenting with altered consciousness were treated by PLEX and corticosteroids. They all fulfilled diagnosis criteria for possible immune encephalitis according to Graus *et al.*, 2016. Three had a rapid and marked improvement (cases #1, #2 and #3) whereas two did not respond and eventually died (cases #4 and #5). The clinical presentation and the time course of the disease are summarized in Table 1, complementary explorations findings are summarized in Table 2 (a detailed history is available in for each patient in the Supplementary material). Patients had no prior history of neurological disease. They were intubated and mechanically ventilated for COVID-19 related ARDS. After sedation withdrawal (day 12 to 30 from initiation), they presented severe and persistent consciousness disorder (comatose state or unresponsive wakefulness syndrome), three had oculomotor disturbances (cases #1, #2 and #3) and one had peripheral symptoms attributed to Guillain-Barré syndrome (case #3). CSF examinations were unremarkable except in one patient with albuminocytologic dissociation (case #3),

Table 1: Clinical presentation and time course of the disease.

	Patient 1	Patient 2	Patient 3	Patient 4	Patient 5
Age (years) /sex	40-50 /M	50-60 /M	60-70 /M	30-40 /M	70-80 /F
Past medical history	Kidney transplant (rheumatoid purpura)	High blood pressure	Pulmonary sarcoidosis Heparin induced thrombocytopenia	Obesity	Obesity High blood pressure Asthma
Clinical features at admission in ICU					
COVID-19 symptoms	Fever, cough, shortness of breath	Fever, fatigue, shortness of breath	Fever, fatigue, shortness of breath, gait disturbances, doubt about a paresis of the right hand	Dry cough, odynophagia, headache	Fever, fatigue, cough, shortness of breath, headache, anosmia
Delay between COVID-19 onset and mechanical ventilation (days)	10	6	0	10	10
Duration of mechanical ventilation (days)	59	93	83 (still ongoing at time of writing)	60	65
SAPS II	38	58	65	50	41
Prone positioning sessions	Yes	Yes	No	Yes	Yes
Renal replacement therapy	Yes	Yes	Yes	Yes	No
Catecholamines*	Yes	Yes	Yes	Yes	Yes
Clinical features at sedation withdrawal and treatments					
Duration of sedation (days)	18	30	17	23	12
Neurological symptoms after sedation withdrawal	- Unresponsive wakefulness syndrome - Brainstem impairment - Movement disorders	- Coma - Brainstem impairment	- Unresponsive wakefulness syndrome - Brainstem impairment - Movement disorders - Dysautonomia	- Unresponsive wakefulness syndrome	- Unresponsive wakefulness syndrome
Corticosteroid injections (No.) / PLEX sessions (No.)	10 / 5	5 / 5	5 / 10	10 / 10	5 / 5
COVID-19 symptoms onset to intravenous corticosteroids /PLEX (days)	52 / 57	66 / 69	49 / 48	42 / 45	40 / 50
Sedation withdrawal to intravenous corticosteroids /PLEX (days)	24 / 29	30 / 33	32 / 31	9 / 12	18 / 28
First PLEX to neurological improvement (verbal commands following), (days)	6	2	7	No improvement	No improvement

Abbreviations: COVID-19, coronavirus disease 2019; ICU, intensive care unit; NP, not performed; PLEX, plasma exchange; SAPS 2, simplified acute physiology score 2; SARS-CoV-2, severe acute respiratory syndrome coronavirus

** epinephrine > 0.1 µg/kg/min OR norepinephrine > 0.1 µg/kg/min*

Table 2: Complementary explorations findings.

	Patient 1	Patient 2	Patient 3	Patient 4	Patient 5
Cerebrospinal fluid testing					
Cellularity, cells/mm ³	0	1	4	10	0
Protein levels, g/L	0.32	0.26	1.54	0.18	0.18
Oligoclonal bands	Absence	Absence	Absence	Absence	Absence
IL-6 levels in CSF, pg/mL (reference value <6.5pg/mL)	< 2.5	4	8	NP	< 2.5
SARS-CoV-2 RT-PCR	Negative	Negative	Negative	Negative	Negative
Neuronal antibodies	Negative	Negative	Negative	Negative	Negative
Other complementary explorations					
IL-6 levels in serum, pg/mL (reference value <6.5pg/mL)	59.7	6	181.3	71.7	33.6
Neuronal antibodies (serum)	Negative	Negative	Negative	Negative	Negative
EEG results	Nonspecific frontal and temporal slow activity	Nonspecific slow-wave activity, poorly reactive, without any epileptic patterns	Nonspecific slow-wave activity, reactive to auditory stimuli, without any epileptic patterns	Nonspecific diffuse slow-wave activity, unreactive, without any epileptic patterns	Nonspecific diffuse slow-wave activity, inconstantly reactive, without any epileptic patterns
Brain MRI results	- Deep hemispherical bilateral white matter lesions on T2/FLAIR with gadolinium enhancement on T1. - Left posterolateral lesions of the pons on T2/FLAIR	- Pontine tegmentum lesion on T2/FLAIR - Small hemorrhagic lesion of the left parietal lobe on SWAN - Multiple pontine microhemorrhages within the tegmentum on SWAN	- Bilateral diffuse lesions of the deep subcortical white matter on T2/FLAIR - Multiple microhemorrhages of the corpus callosum on SWAN	- Several confluent periventricular and deep supratentorial white matter lesions on T2/FLAIR - Gadolinium-enhanced symmetrical bilateral focal lesions of centrum semiovale, pallidum and periventricular white matter on T1	- Several confluent periventricular and deep supratentorial white matter lesions on FLAIR, mostly with necrotic centers and slight peripheral gadolinium enhancement on T1
Spinal cord MRI	Normal	Normal	NP	Normal	Normal
Somatosensory evoked potential	NP	Bilateral presence of N20	Bilateral presence of N20	Bilateral presence of N20	NP
Electroneuromyography	NP	Signs of critical illness polyneuropathy	Complete abolition of sensory and motor potential in four limbs	NP	NP

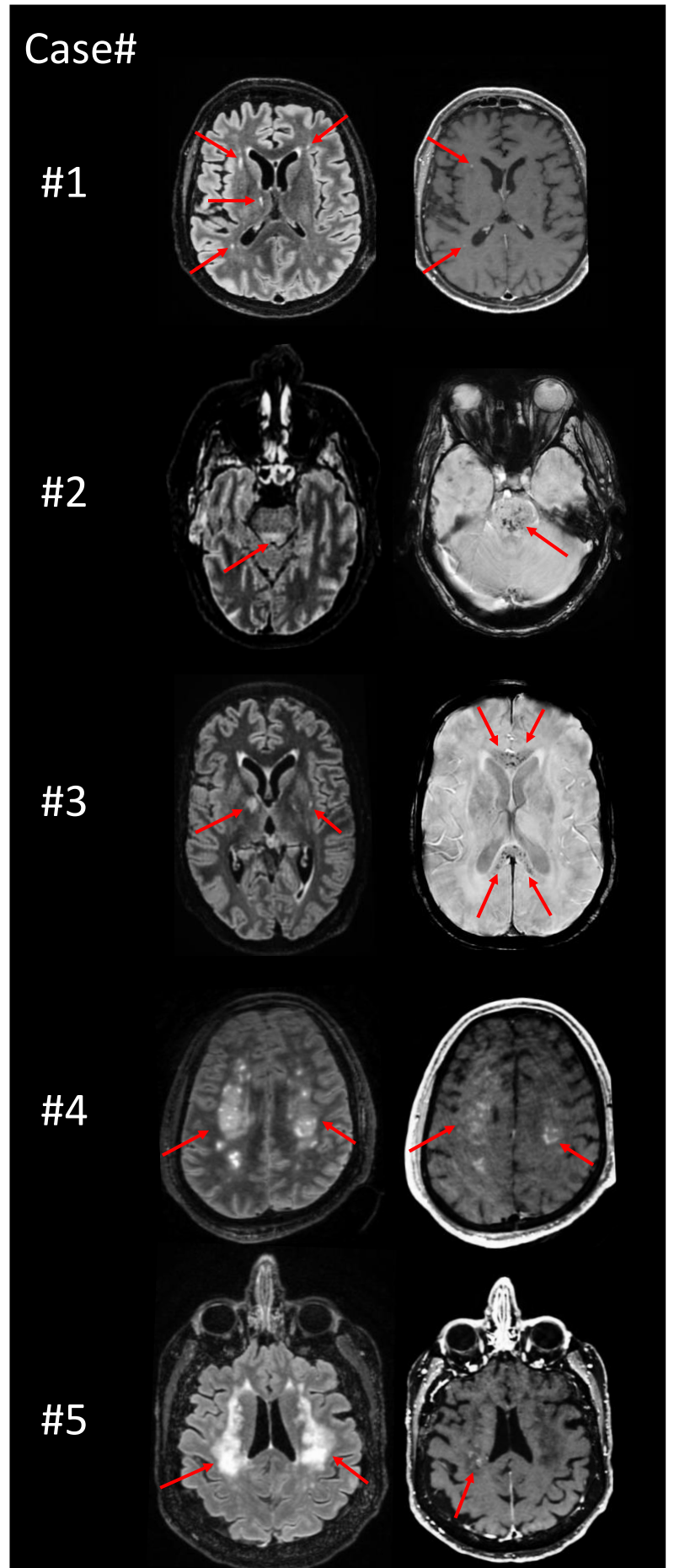
Abbreviations: COVID-19, coronavirus disease 2019; CSF, cerebrospinal fluid; EEG, electroencephalogram; IL-6, interleukin-6; MRI, magnetic resonance imaging; FLAIR, fluid-attenuated inversion recovery; SWAN, susceptibility weighted magnetic resonance sequences; NP, not performed; RT-PCR, Reverse transcription-polymerase chain-reaction; SARS-CoV-2, severe acute respiratory syndrome coronavirus 2

and one with mild pleocytosis (case #4). RT-PCR assays of the CSF were negative for SARS-CoV-2, as common viruses for all patients (see Supplementary material for details). Neuronal antibodies were negative in serum and CSF. None of the patients had signs of thrombotic microangiopathy (no hemolysis, normal levels of ADAMTS13 activity and antigen). EEGs showed unspecific slow-wave activity. Brain MRIs mostly showed bilateral hyperintense lesions in the deep and periventricular supratentorial white matter, either punctiform or slightly diffuse (cases #1, #2 and #3) or diffuse and confluent (cases #4 and #5), associated with lesions in the pons for 2 patients (cases #1 and #2; Figure 1) and gadolinium contrast enhancement for 3 patients (cases #1, #4 and #5).

All patients received immunotherapy combining corticosteroids infusions (IV methylprednisolone 1g/day for 5 to 10 days) and PLEX with albumin (5 to 10 sessions). It is worth noting that neurological impairment remained unchanged in for all patients with severe consciousness disorder despite cessation of sedation for 9-33 days. Three patients (cases #1, #2 and #3) showed neurological improvement few days after immunotherapy initiation (6, 2 and 7 days respectively), with consciousness recovery allowing ICU discharge and transfer to rehabilitation. Two patients (cases #4 and #5) showed no signs of consciousness improvement and died after discontinuation of life-sustaining therapies.

Figure 1

Significant MRI findings in **Case #1**: bilateral hyperintense lesions in fluid attenuated inversion recovery (T2/FLAIR) with gadolinium enhancement; **Case #2**: hyperintense lesions in T2/FLAIR with microhemorrhages; **Case#3**: multiple microhemorrhages in T2/FLAIR and diffusion sequences without gadolinium enhancement. **Case #4**: confluent hyperintense lesions in T2/FLAIR with gadolinium enhancement; **Case #5**: confluent hyperintense lesions in T2/FLAIR sequence with slight gadolinium enhancement.



DISCUSSION

We report the first case series of patients with severe COVID-19 related encephalitis including consciousness impairment treated by PLEX and corticosteroids with an excellent response in 3 out of 5 patients.

Relation Between Immunotherapy and Clinical Improvement

Reports on patients with positive SARS-CoV-2 RT-PCR assay in the CSF are scarce (Huang *et al.*, 2020; Moriguchi *et al.*, 2020) and, most patients had moderate acute cognitive impairment without pleocytosis (Helms *et al.*, 2020a) or, mildly elevated CSF cell counts (Bernard-Valnet *et al.*, 2020). Likewise, Guillain-Barré and Miller Fisher syndromes, acute necrotizing hemorrhagic encephalopathy, and acute disseminated encephalomyelitis have also been described in COVID-19 patients, suggesting a host-immune response mechanism rather than a direct neuro-invasion of the SARS-Cov-2 (Toscano *et al.*, 2020; Novi *et al.*, 2020; Gutiérrez-Ortiz *et al.*, 2020).

In the present cases, the secondary neurological involvement (no prior neurological initial symptoms), and the absence of SARS-CoV-2 in the CSFs point towards a post-infectious mechanism rather than a direct viral neuro-invasion as suggested by Weyhern *et al.*, although no oligoclonal bands and low Interleukine-6 were found in the CSFs.

The rapid clinical improvement (i.e 6, 2 and 7 days for cases #1, #2 and #3 respectively) after immunotherapy initiation was at striking contrast with the protracted neurological impairment (respectively 24, 30 and 31 days after sedation withdrawal) before treatment initiation. Such feature supports an inflammatory or immune process. In the instance of critical illness, delayed awakening and cognitive impairment such as delirium may result from many factors such as hypoxic encephalopathy, metabolic disturbances, side effects of sedation in the case of ICU patients (Mazeraud *et al.*, 2018). However, ICU related brain injuries had never been reported

to be responsive to immunotherapy. Although we cannot rule out a spontaneous recovery (Fischer *et al.*, 2020), the rapid improvement after immunotherapy initiation seems to point towards a therapeutic effect.

Differences Between Responders and Non-Responders

PLEX and corticosteroids' responders (cases #1, #2 and #3) and non-responders (cases #4 and #5) shared similar disease courses (severe COVID-19 related ARDS, mechanical ventilation and sedation for several weeks, severe consciousness impairment which persisted several weeks after sedation withdrawal, unremarkable CSF findings).

Differences in treatment response may be related to lesion severity observed on MRI between the 2 groups. The responders mainly had small deep white matter lesions while non-responders had more diffuse confluent lesions of the deep white matter. Time of treatment since diagnosis does not seem to be a relevant factor since non-responders had earlier immunotherapy compared to responders (40 and 42 days after COVID-19 symptoms onset for the non-responders, versus 48, 52 and 66 days for the responders). Another cause of treatment failure can also be related to the underlying mechanism: non-responders may have had irreversible necrotic lesions related to vasculopathy and coagulopathy as often seen after COVID-19 infection especially in the lungs (Helms *et al.*, 2020b).

CONCLUSION

Immunotherapy combining PLEX and corticosteroids can be effective in the treatment of severe COVID-19 related encephalitis. The exact pathophysiological mechanism underlying brain injury in these patients has yet to be clarified but a host-immune response to SARS-CoV-2 appears to be a plausible hypothesis. Further studies are necessary to confirm the therapeutic effect of combined PLEX and corticosteroids, and to determine the optimal treatment approach of these patients.

ACKNOWLEDGMENTS

We thank the Cohort COVID-19 Neurosciences (CoCo Neurosciences study group - NCT04362930, see member list below), study sponsored by AP-HP and funded by the generous support of the Fédération Internationale de l'Automobile (FIA) Foundation and donors of Paris Brain Institute – ICM, and the CoCo-Neurosciences study group for their participation to data collection. We thank Prof. Didier Dreyfus (Department of Critical Care, Hôpital Louis Mourier, AP-HP, Université de Paris, Colombes, France) for his thorough review of the manuscript. We finally thank the nurses, nurse assistants and residents of the Neuro-ICU (Jean-Baptiste Brunet de Courssou, Adam Celier, Grégoire Demoulin, Julia Devianne, Anceline Dong and Thomas Rambaud).

CoCo Neurosciences study group:

Steering Committee (Pitié-Salpêtrière Hospital, Paris): Cecile Delorme, Jean-Christophe Corvol, Jean-Yves Delattre, Stephanie Carvalho, Sandrine Sagnes. **Scientific Committee** (Pitié-Salpêtrière Hospital, Paris): Bruno Dubois, Vincent Navarro, Celine Louapre, Tanya Stojkovic, Ahmed Idbaih, Charlotte Rosso, David Grabli, Ana Zenovia Gales, Bruno Millet, Benjamin Rohaut, Eleonore Bayen, Sophie Dupont, Gaelle Bruneteau, Stephane Lehericy, Danielle Seilhean, Alexandra Durr, , Aurelie Kas, Foudil Lamari, Marion Houot, Vanessa Batista Brochard. **Principal investigators:** Pitié-Salpêtrière Hospital (Paris): Sophie Dupont, Catherine Lubetzki, Danielle Seilhean, Pascale Pradat-Diehl, Charlotte Rosso, Khe Hoang-Xuan, Bertrand Fontaine, Lionel Naccache, Philippe Fossati, Isabelle Arnulf, Alexandra Durr, Alexandre Carpentier, Stephane Lehericy, Yves Edel; Foch Hospital (Suresnes): Anna Luisa Di Stefano; Rothschild Hospital (Paris): Gilberte Robain, Philippe Thoumie; Avicenne Hospital (Bobigny): Bertrand Degos; Sainte-Anne Hospital (Paris): Tarek Sharshar; Saint-Antoine Hospital (Paris): Sonia Alamowitch, Emmanuelle Apartis-Bourdieu, Charles-Siegfried Peretti; Saint-Louis Hospital (Paris): Renata Ursu; Tenon Hospital (Paris): Nathalie Dzierzynski; Charles Foix Hospital (Ivry): Kiyoka Kinugawa Bourron, Joel Belmin, Bruno Oquendo, Eric Pautas, Marc Verny. **Co-investigators:** Pitié-Salpêtrière Hospital (Paris): Cecile Delorme, Jean-Christophe Corvol, Jean-Yves Delattre, Yves Samson, Sara Leder, Anne Leger, Sandrine Deltour, Flore Baronnet, Ana Zenovia Gales, Stephanie Bombois, Mehdi Touat, Ahmed Idbaih, Marc Sanson, Caroline Dehais, Caroline Houillier, Florence Laigle-Donadey, Dimitri Psimaras, Agusti Alenton, Nadia Younan, Nicolas Villain, David Grabli, Maria del Mar Amador, Gaelle Bruneteau, Celine Louapre, Louise-Laure Mariani, Nicolas

Mezouar, Graziella Mangone, Aurelie Meneret, Andreas Hartmann, Clement Tarrano, David Bendetowicz, Pierre-François Pradat, Michel Baulac, Sara Sambin, Phintip Pichit, Florence Chochon, Adele Hesters, Bastien Herlin, An Hung Nguyen, Valerie Procher, Alexandre Demoule, Elise Morawiec, Julien Mayaux, Morgan Faure, Claire Ewencyk, Giulia Coarelli, Anna Heinzmann, Tanya Stojkovic, Marion Masingue, Guillaume Bassez, Vincent Navarro, Isabelle An, Yulia Worbe, Virginie Lambrecq, Rabab Debs, Esteban Munoz Musat, Timothee Lenglet, Virginie Lambrecq, Aurelie Hanin, Lydia Chougar, Nathalia Shor, Nadya Pyatigorskaya, Damien Galanaud, Delphine Leclercq, Sophie Demeret, Benjamin Rohaut, Albert Cao, Clemence Marois, Nicolas Weiss, Salimata Gassama, Loic Le Guennec, Vincent Degos, Alice Jacquens, Thomas Similowski, Capucine Morelot-Panzini, Jean-Yves Rotge, Bertrand Saudreau, Bruno Millet, Victor Pitron, Nassim Sarni, Nathalie Girault, Redwan Maatoug, Ana Zenovia Gales, Smaranda Leu, Eleonore Bayen, Lionel Thivard, Karima Mokhtari, Isabelle Plu; Sainte-Anne Hospital (Paris): Bruno Gonçalves; Saint-Antoine Hospital (Paris): Laure Bottin, Marion Yger; Rothschild Hospital (Paris): Gaelle Ouvrard, Rebecca Haddad; Charles Foix Hospital (Ivry): Flora Ketz, Carmelo Lafuente, Christel Oasi. **Other Contributors: Associated centers** (Lariboisière Hospital, Paris): Bruno Megabarne, Dominique Herve; **Clinical Research Associates** (ICM, Pitié-Salpêtrière Hospital, Paris): Haysam Salman, Armelle Rametti-Lacroux, Alize Chalançon, Anais Herve, Hugo Royer, Florence Beauzor, Valentine Maheo, Christelle Laganot, Camille Minelli, Aurelie Fekete, Abel Grine, Marie Biet, Rania Hilab, Aurore Besnard, Meriem Bouguerra, Gwen Goudard, Saida Houairi, Saba Al-Youssef, Christine Pires, Anissa Oukhedouma, Katarzyna Siuda-Krzywicka, Tal Seidel Malkinson; (Saint-Louis Hospital, Paris): Hanane Agguini; (Foch Hospital, Suresnes): Hassen Douzane; **Data Manager** (ICM, Paris): Safia Said; **Statistician** (ICM, Paris): Marion Houot.

DECLARATIONS OF INTEREST

None of the authors report conflict of interest

DATA AVAILABILITY

Detailed data is available upon request to the corresponding author.

FUNDING

This research did not receive any specific grant from funding agencies in the public, commercial, or not-for-profit sectors.

REFERENCES

Bernard-Valnet R, Pizzarotti B, Anichini A, Demars Y, Russo E, Schmidhauser M, et al. Two patients with acute meningoencephalitis concomitant with SARS-CoV-2 infection [Internet]. *Eur J Neurol* 2020 Available from: <https://doi.org/10.1111/ene.14298>

Dogan L, Kaya D, Sarikaya T, Zengin R, Dincer A, Akinci IO, et al. Plasmapheresis treatment in COVID-19–related autoimmune meningoencephalitis: Case series [Internet]. *Brain, Behavior, and Immunity* 2020 [cited 2020 Jun 16] Available from: <http://www.sciencedirect.com/science/article/pii/S0889159120308035>

Filatov A, Sharma P, Hindi F, Espinosa PS. Neurological Complications of Coronavirus Disease (COVID-19): Encephalopathy. *Cureus* 2020; 12: e7352.

Fischer D, Threlkeld ZD, Bodien YG, Kirsch JE, Huang SY, Schaefer PW, et al. Intact Brain Network Function in an Unresponsive Patient with COVID-19 [Internet]. *Ann Neurol* 2020 Available from: <https://doi.org/10.1002/ana.25838>

Graus F, Titulaer MJ, Balu R, Benseler S, Bien CG, Cellucci T, et al. A clinical approach to diagnosis of autoimmune encephalitis. *The Lancet Neurology* 2016; 15: 391–404.

Gutiérrez-Ortiz C, Méndez A, Rodrigo-Rey S, San Pedro-Murillo E, Bermejo-Guerrero L, Gordo-Mañas R, et al. Miller Fisher Syndrome and polyneuritis cranialis in COVID-19 [Internet]. *Neurology* 2020 Available from: <https://doi.org/10.1212/WNL.0000000000009619>

Helms J, Kremer S, Merdji H, Clere-Jehl R, Schenck M, Kummerlen C, et al. Neurologic Features in Severe SARS-CoV-2 Infection. *N Engl J Med* 2020; 382: 2268–70.

Helms J, Kremer S, Merdji H, Clere-Jehl R, Schenck M, Kummerlen C, et al. Neurologic Features in Severe SARS-CoV-2 Infection. *N Engl J Med* 2020

Huang YH, Jiang D, Huang JT. SARS-CoV-2 Detected in Cerebrospinal Fluid by PCR in a Case of COVID-19 Encephalitis. *Brain Behav Immun* 2020; 87: 149.

Khoo A, McLoughlin B, Cheema S, Weil RS, Lambert C, Manji H, et al. Postinfectious brainstem encephalitis associated with SARS-CoV-2 [Internet]. *J Neurol Neurosurg Psychiatry* 2020 [cited 2020 Jul 8] Available from: <https://jnnp.bmj.com/content/early/2020/07/06/jnnp-2020-323816>

Le Guennec L, Devianne J, Jalin L, Cao A, Galanaud D, Navarro V, et al. Orbitofrontal involvement in a neuroCOVID-19 patient [Internet]. *Epilepsia* 2020; n/a [cited 2020 Jul 1] Available from: <https://onlinelibrary.wiley.com/doi/abs/10.1111/epi.16612>

Mao L, Wang M, Chen S, He Q, Chang J, Hong C, et al. Neurological Manifestations of Hospitalized Patients with COVID-19 in Wuhan, China: A Retrospective Case Series Study [Internet]. Rochester, NY: Social Science Research Network; 2020 [cited 2020 Mar 10] Available from: <https://papers.ssrn.com/abstract=3544840>

Mazeraud A, Bozza FA, Sharshar T. The Sepsis-associated Encephalopathy is Septic [Internet]. *Am J Respir Crit Care Med* 2018 [cited 2018 Jan 28] Available from: <https://www-atsjournals-org.gate2.inist.fr/doi/10.1164/rccm.201712-2593ED>

Moriguchi T, Harii N, Goto J, Harada D, Sugawara H, Takamino J, et al. A first Case of Meningitis/Encephalitis associated with SARS-Coronavirus-2. *Int J Infect Dis* 2020

Novi G, Rossi T, Pedemonte E, Saitta L, Rolla C, Roccatagliata L, et al. Acute disseminated encephalomyelitis after SARS-CoV-2 infection. *Neurol Neuroimmunol Neuroinflamm* 2020; 7

Oxley TJ, Mocco J, Majidi S, Kellner CP, Shoirah H, Singh IP, et al. Large-Vessel Stroke as a Presenting Feature of Covid-19 in the Young. *N Engl J Med* 2020; 382: e60.

Paterson RW, Brown RL, Benjamin L, Nortley R, Wiethoff S, Bharucha T, et al. The emerging spectrum of COVID-19 neurology: clinical, radiological and laboratory findings [Internet]. *Brain* 2020[cited 2020 Jul 8] Available from: <https://academic.oup.com/brain/article/doi/10.1093/brain/awaa240/5868408>

Poyiadji N, Shahin G, Noujaim D, Stone M, Patel S, Griffith B. COVID-19-associated Acute Hemorrhagic Necrotizing Encephalopathy: CT and MRI Features. *Radiology* 2020: 201187.

Toscano G, Palmerini F, Ravaglia S, Ruiz L, Invernizzi P, Cuzzoni MG, et al. Guillain-Barré Syndrome Associated with SARS-CoV-2. *N Engl J Med* 2020; 382: 2574–6.

Weyhern CH von, Kaufmann I, Neff F, Kremer M. Early evidence of pronounced brain involvement in fatal COVID-19 outcomes [Internet]. *The Lancet* 2020; 0[cited 2020 Jun 16] Available from: [https://www.thelancet.com/journals/lancet/article/PIIS0140-6736\(20\)31282-4/abstract](https://www.thelancet.com/journals/lancet/article/PIIS0140-6736(20)31282-4/abstract)

Supplementary material

DETAILED DESCRIPTION OF THE 5 CASES

Case #1 is a 40-50 year-old male hospitalized in ICU, intubated and mechanically ventilated for a severe ARDS 10 days after COVID-19 symptoms onset. He received no specific treatment for COVID-19. Sedatives were stopped at day 28 after symptoms onset, and neurological examination revealed an alteration of consciousness (spontaneous eye opening, no response to simple orders), oculomotor disturbances (skew deviation and internuclear ophthalmoplegia), a bilateral upper motor neuron syndrome (bilateral ankle clonus and diffuse brisk deep tendon reflexes) and axial and lower limbs myorhythmia. He was clinically in an unresponsive wakefulness syndrome. EEGs performed at days 34 and 41 showed a nonspecific bilateral frontotemporal slow activity. Brain MRI at day 43 was remarkable for several bilateral hyperintense lesions in fluid attenuated inversion recovery (T2/FLAIR) and diffusion sequences, without reduction in apparent diffusion coefficient (ADC) in deep hemispheric white matter lesions with gadolinium enhancement. Lumbar puncture (LP) at day 43 was unremarkable. Brain MRI at day 50 showed similar findings, with a new lesion within the posterolateral left part of the pons on T2/FLAIR in accordance with neurological symptoms. The patient was still unresponsive at day 51 (FOUR-score = 11 [E3 M3 B3 R1], 23 days after sedation withdrawal).

Corticosteroid infusions (1g/day IV methylprednisolone for 10 days) and PLEX (5 sessions) were respectively started at day 52 and day 57 with a rapid neurological improvement starting by a decrease in myoclonus and consciousness improvement allowing functional communication at day 63. Improvement of swallowing allowed withdrawal of mechanical ventilation at day 69, and a walking into the ward at day 70. Only a mild dysexecutive syndrome was observed at ICU discharge (on day 85).

Case #2 is a 50-60 year-old male hospitalized in the ICU, intubated and mechanically ventilated for severe ARDS 6 days after COVID-19 symptoms onset. He received no specific treatment for COVID-19. Sedatives were stopped at day 36 after symptoms onset, and neurological examination revealed a coma (no eye opening nor response to painful stimulation), and oculomotor disturbances (skew deviation and internuclear ophthalmoplegia). Brain MRI at day 41 showed a small hemorrhagic lesion of the left insula, a posterior hyperintensity of the pons, multiple microhemorrhages especially in the pontine tegmentum, and multiple left parieto-occipital punctiform T2 hyperintense lesions without gadolinium enhancement. CSF examination at day 43 showed 1 cell/mm³, with normal levels of protein and glucose. Brain MRI at day 55 showed a regression of the posterior hyperintensity of the pons, and a stability of the other lesions. Neurophysiological exploration at day 55 included somatosensory evoked potential showing bilateral presence of N20 but with an increased P14-N20 inter-latency and, brainstem auditory evoked potentials showing medulo-pontic involvement (low III and V wave amplitudes, increased I-V inter-latency) in relation with a brainstem dysfunction. EEGs at days 57 and 63 showed nonspecific slow-wave activity, poorly reactive, without any epileptic patterns. Electroneuromyography at day 65 showed signs of mild polyneuropathy compatible with critical illness polyneuropathy. The patient was still unresponsive at day 65 (FOUR-score = 7 [E2 M0 B4 R1], 29 days after sedation withdrawal). Corticosteroid infusions (1g day IV methylprednisolone for 5 days) and PLEX (5 sessions) were respectively started at day 66 and day 69, associated with a rapid consciousness improvement allowing functional communication at day 71, withdrawal of mechanical ventilation at day 88. and a transfer to rehabilitation center at 116 days. The patient was then fully conscious, with a mild dysexecutive syndrome.

Case #3 is a 60-70 year-old male hospitalized in the ICU, intubated and mechanically ventilated for severe ARDS the day of COVID-19 symptoms onset. He received no specific treatment for COVID-19. Sedatives were stopped at day 17, and neurological examination showed an alteration of consciousness (spontaneous eye opening, no response to simple orders), oculomotor disturbances (brisk horizontal oculocephalogyric reflex, ocular bobbing), myorhythmias of the tongue and flaccid quadriplegia with facial diplegia, areflexia and dysautonomia. He was clinically in an unresponsive wakefulness syndrome. EEG at day 25 showed nonspecific slow-wave activity, reactive to auditory stimuli, without any epileptic patterns. Brain MRI at day 30 was notable for multiple microhemorrhages within the corpus callosum and bilateral diffuse slightly hyperintense lesions of the deep subcortical white matter in T2/FLAIR and diffusion sequences. There were also two small ischemic lesions, of the right pallidum and the hypothalamus. CSF examination showed albuminocytologic dissociation with 4 cells/mm³, and high level of protein at 1.54g/L. Somatosensory evoked potential at day 45 showed slight bilateral N20 (inter – latencies were not reliable due to peripheral involvement). Brain MRI at day 48 showed new multiple microhemorrhages involving the corpus callosum, and a stability of the other lesions. Electroneuromyography at day 49 showed complete abolition of sensory and motor potential in four limbs, suggesting a COVID-19-related Guillain-Barré syndrome in addition to the encephalitis. The patient was still unresponsive at day 47 (FOUR-score = 8 [E3 M0 B4 R1], 30 days after sedation withdrawal). Corticosteroid infusions (1g day IV methylprednisolone for 5 days) and PLEX (10 sessions) were respectively started at day 49 and day 48, with a consciousness improvement and a regression of ocular bobbing, allowing functional communication (following verbal commands with eye tracking) at day 55, and a partial trapezius muscles strength recovery. Severe motor deficit of the 4 limbs with facial diplegia was still observed.

Case #4 is a 30-40 year-old male hospitalized in the ICU, intubated and mechanically ventilated for severe ARDS 10 days after COVID-19 symptoms onset. He initially received hydroxychloroquine plus spiramycin for 2 days (QT prolongation). Sedatives were stopped at day 33 after symptoms onset, and neurological examination revealed an alteration of consciousness (spontaneous non-goal directed movement, spontaneous eye opening, no eye fixation or following, no response to verbal commands). He was clinically in an unresponsive wakefulness syndrome. CSF examination at day 34 revealed a mild pleocytosis with 10 cells/mm³, with normal levels of protein and glucose. Brain MRI at day 39 was remarkable for several confluent hyperintense lesions in T2/FLAIR sequence, located within the periventricular and deep supratentorial white matter. There were also multiple symmetrical bilateral focal lesions of centrum semiovale, pallidum and periventricular white matter, hyperintense in T2/FLAIR and diffusion sequences with gadolinium enhancement. EEGs at days 34, 52, 58 and 65 showed nonspecific diffuse slow-wave activity, unreactive, without any epileptic patterns. Somatosensory evoked potential at day 60 showed bilateral presence of N20. The patient was still unresponsive at day 41 (FOUR-score = 8 [E3 M0 B4 R1], 8 days after sedation withdrawal).

Corticosteroid infusions (1g day IV methylprednisolone for 10 days) and PLEX (10 sessions) were respectively started at day 42 and day 45 without any consciousness improvement leading to withdrawal of care and death at day 81.

Case #5 is a 70-80 year-old female hospitalized in the ICU, intubated and mechanically ventilated for severe ARDS 10 days after COVID-19 symptoms onset. She received no specific treatment for COVID-19 but initial cefotaxime plus spiramycine for a suspected community-acquired pneumonia. Sedatives were stopped at day 22 after symptoms onset, and neurological

examination showed an alteration of consciousness (spontaneous eye opening, no response to simple orders). She was clinically in an unresponsive wakefulness syndrome. Brain MRI at day 35 was notable for several confluent hyperintense lesions in T2/FLAIR sequence, located within the periventricular and deep supratentorial white matter. They mostly had necrotic centers, with slight peripheral gadolinium enhancement. CSF examination at day 39 was normal. EEG at day 48 showed nonspecific diffuse slow-wave activity, inconstantly reactive, without any epileptic patterns. The patient was still unresponsive at day 39 (FOUR-score = 6 [E1 M0 B4 R1], 17 days after sedation withdrawal).

Corticosteroid infusions (1g day IV methylprednisolone for 5 days) and PLEX (5 sessions) were respectively started at day 40 and day 50 without consciousness improvement, leading to withdrawal of care and death at day 75.

ADDITIONAL EXPLORATIONS PERFORMED

For all patients, routine etiological workup included:

1/Blood:

- Serologic testing for human immunodeficiency virus
- Serologic testing for hepatitis b & c
- Antiphospholipid antibodies
- Autoantibodies to neutrophil cytoplasmic antigens
- Anti-ENA antibodies
- Anti-DNA antibodies
- Antinuclear antibodies
- Anti-aquaporin 4 antibodies

- Onconeural antibody testing including anti-NMDAr, -VGKC (LGI1, CASPR2), -AMPA1/2, -DPPX, -GABAb, -Hu, -Ri, -Yo, -Tr, -CV2, -GAD antibodies

2/Cerebrospinal fluid:

- Gram stain and culture
- Auramine O staining for mycobacteria
- PCR for Herpes Simplex Virus 1 & 2
- PCR for Varicella-zoster-virus
- PCR for Cytomegalovirus
- PCR for Epstein-Barr-Virus
- PCR for Enterovirus
- PCR for Adenovirus
- Interferon-alpha level (were all undetectable)
- PCR for Toxoplasma gondii
- PCR for Aspergillus fumigatus
- Detection of Mucorales DNA
- Oligoclonal bands research
- Onconeural antibody testing including anti-NMDAr, -VGKC (LGI1, CASPR2), -AMPA1/2, -DPPX, -GABAb, -Hu, -Ri, -Yo, -Tr, -CV2, -GAD antibodies
- Anti-aquaporin 4 antibodies

PLASMA EXCHANGE TECHNIQUE

Plasma exchanges were performed with a centrifuge-driven cell separator Spectra Optia (TerumoBCT®, Lakewood, CO, USA), with 5% albumin as the sole replacement solution

exchanging 1.2 plasma volumes with a blood flow of 60 (40–70) mL/min for a duration of 110 (93–120) minutes. Anticoagulation was achieved by regional citrate infusion. Vascular access was established by venous insertion of double-lumen hemodialysis catheter.