



HAL
open science

The conventional protocol versus a protocol including illumination with a fabric-based biophotonic device (the Phosistos protocol) in photodynamic therapy for actinic keratosis: a randomized, controlled, non-inferiority clinical study

Serge Mordon, A S Vignion-Dewalle, H Abi-Rached, E Thecua, F. Lecomte, C. Vicentini, P. Deleporte, H. Béhal, D. Kerob, T Hommel, et al.

► **To cite this version:**

Serge Mordon, A S Vignion-Dewalle, H Abi-Rached, E Thecua, F. Lecomte, et al.. The conventional protocol versus a protocol including illumination with a fabric-based biophotonic device (the Phosistos protocol) in photodynamic therapy for actinic keratosis: a randomized, controlled, non-inferiority clinical study. *British Journal of Dermatology*, 2020. hal-02908603

HAL Id: hal-02908603

<https://hal.science/hal-02908603>

Submitted on 29 Jul 2020

HAL is a multi-disciplinary open access archive for the deposit and dissemination of scientific research documents, whether they are published or not. The documents may come from teaching and research institutions in France or abroad, or from public or private research centers.

L'archive ouverte pluridisciplinaire **HAL**, est destinée au dépôt et à la diffusion de documents scientifiques de niveau recherche, publiés ou non, émanant des établissements d'enseignement et de recherche français ou étrangers, des laboratoires publics ou privés.

The conventional protocol versus a protocol including illumination with a fabric-based biophotonic device (the Phosistos protocol) in photodynamic therapy for actinic keratosis: a randomized, controlled, non-inferiority clinical study

Running head: A new protocol using a biophotonic device for MAL-PDT of AK.

*S. Mordon¹, AS. Vignion-Dewalle¹, H. Abi-Rached^{1, 2}, E. Thecu¹, F. Lecomte¹, C. Vicentini^{1, 2}, P. Deleporte¹, H. Béhal³, D. Kerob⁴, T. Hommel⁵, A. Duhamel³, RM. Szeimies^{5, *}, L. Mortier^{1, 2, *}*

¹Univ. Lille, INSERM, CHU Lille, U1189 – ONCO-THAI – Image Assisted Laser Therapy for Oncology, F-59000 Lille, France

²Department of Dermatology, CHU Lille, F-59000 Lille, France

³Univ. Lille, CHU Lille, EA 2694 – Santé Publique : épidémiologie et qualité des soins, Unité de Biostatistiques, F-59000 Lille, France

⁴Galderma International SAS, F-92927 La Défense, France

⁵Department of Dermatology and Allergology, Klinikum Vest GmbH, D-45657 Recklinghausen, Germany

* RM. Szeimies and L. Mortier contributed equally to this work.

Corresponding author: Anne-Sophie Vignion-Dewalle
INSERM U1189 ONCO-THAI,
1, avenue Oscar Lambret,
59037 LILLE Cedex,
France
anne-sophie.vignion@inserm.fr

Funding sources:

This work was supported by the European Commission under the Competitiveness and Innovation Framework Programme (CIP) (Project identifier: CIP-ICT-PSP-2013-7-621103). Metvixia cream (168 mg of MAL/g) was graciously supplied by Galderma R&D (France)

Conflicts of interest:

S. Mordon, AS. Vignion-Dewalle, H. Abi-Rached, E. Thecua, F. Lecomte, C. Vicentini, P. Deleporte, H. Béhal, D. Kerob, T. Hommel and A. Duhamel have none conflicts of interest to declare.

RM. Szeimies is vice president of EURO-PDT. He has been a member of advisory boards for Almirall, Biofrontera, Galderma, ISDIN, LEO Pharma, photonamic and Pierre-Fabre, and has received speakers' honoraria from the aforementioned companies.

L. Mortier has been a member of advisory boards for BMS, Roche, GSK, Novartis, LEO Pharma and MSD. He has received travel grants for attending congresses from BMS, Roche, GSK, Novartis and LEO Pharma. He has been the principal investigator of clinical trials performed for BMS, Roche, GSK, Novartis, LEO Pharma and MSD.

What's already known about this topic?

- Topical photodynamic therapy using methyl aminolevulinate is effective for treating actinic keratosis.
- In Europe, the conventional protocol involves illumination with a red-light lamp. Unfortunately, pain is often experienced by patients undergoing this protocol.
- An alternative protocol that uses daylight illumination has recently been shown to be as effective as the conventional protocol while being nearly painless. However, this alternative protocol can be conducted only in suitable weather conditions.

What does this study add?

- The Phosistos protocol is demonstrated to be as effective as the conventional protocol, as nearly painless as the daylight protocols and suitable year-round for treatment of actinic keratosis.

Abstract

Background: Topical photodynamic therapy (PDT) using methyl aminolevulinate is a non-invasive treatment option suitable to treat clinical and subclinical actinic keratosis (AK) over a large area (field cancerization). The most widely used, conventional protocol in Europe includes illumination with a red-light lamp. This illumination commonly causes pain, and patients often cannot complete the treatment.

Objectives: The aim of this paper is twofold. The first aim is to introduce a novel protocol, the Phosistos protocol (P-PDT), which includes illumination with a fabric-based biophotonic device. The second and major aim is to assess the non-inferiority, in terms of efficacy for PDT of AK, of P-PDT compared to the conventional protocol (C-PDT).

Methods: A randomized, controlled, multicentre, intra-individual clinical study was conducted. Forty-six patients with grade I-II AK of the forehead and scalp were treated with P-PDT on one area (n=285 AK lesions) and with C-PDT on the contralateral area (n=285 AK lesions). The primary endpoint was the lesion complete response (CR) rate at three months, with an absolute non-inferiority margin of -10%. Secondary endpoints included pain scores, incidence of adverse effects and cosmetic outcome.

Results: Three months following treatment, the lesion CR rate of P-PDT was non-inferior to that of C-PDT (79.3% vs. 80.7%, respectively; absolute difference, -1.6%; one-sided 95% confidence interval, -4.5% to infinity). The non-inferiority of P-PDT to C-PDT in terms of the lesion CR rate remained at the six-month follow-up visit (94.2% vs. 94.9%, respectively; absolute difference, -0.6%; one-sided 95% confidence interval, -2.7% to infinity). Moreover, the pain score at the end of illumination was significantly lower for P-PDT than for C-PDT (mean±standard deviation: 0.3±0.6 vs. 7.4±2.3; p<0.0001).

Conclusions: P-PDT is non-inferior to C-PDT in terms of efficacy for treating AK of the forehead and scalp and resulted in much lower pain scores and fewer adverse effects.

Trial registration: ID-RCB number: 2016-A00010-51, ClinicalTrials.gov Identifier: NCT03076892.

Introduction

Photodynamic therapy (PDT), which is an effective, approved treatment for thin and non-pigmented AK on the face and scalp, is increasingly used to treat field cancerization¹⁻³. However, the conventional approved PDT protocol in Europe (C-PDT), involving illumination with 37 J/cm² of red light after 3 hours of methyl 5-aminolevulinate (MAL) incubation⁴⁻⁶, is associated with high pain scores^{4,7,8}. Another protocol, consisting of MAL under occlusion for a maximum of 30 minutes followed by a 2-hour exposure to daylight, is also approved in Europe⁹. This protocol is as effective as C-PDT⁸ and is better tolerated by patients^{8,10,11}. Nonetheless, the 2-hour daylight exposure cannot be performed year-round in all weather conditions¹². Alternative protocols designed to be as effective as C-PDT, nearly painless, and usable irrespective of the weather and the time of the year are therefore emerging^{11,13-16}.

Among these alternative protocols is the Flexitheralight protocol (FLEXI-PDT) that we have recently published¹⁶. Consisting of an illumination with a light-emitting, fabric-based device for 2.5 hours beginning 30 minutes after applying MAL under occlusion, FLEXI-PDT has been shown to be non-inferior in efficacy to C-PDT while being nearly painless.

Following on from this successful result, we propose a new protocol heavily inspired by FLEXI-PDT. Referred to as the Phosistos protocol (P-PDT), this new protocol indeed applies illumination with a fabric-based biophotonic device. P-PDT differs significantly from FLEXI-PDT in the illumination parameters; the irradiance has been reduced from 12.3 mW/cm² to 1.3

mW/cm², and the light dose from 37 J/cm² to 12 J/cm². Furthermore, the device has been redesigned to be more ergonomic and compact.

The aim of this study was to assess the efficacy and tolerability of P-PDT compared to that of C-PDT in treating patients with AK of the forehead and scalp. The primary hypothesis was that P-PDT was non-inferior to C-PDT in terms of the lesion complete response (CR) rate at three months.

Patients, materials and methods

Study design

This was a randomized, controlled, multicentre, intra-individual, non-inferiority study comparing two protocols for PDT of AK. Two centres took part in the study: the department of dermatology at the Lille University Hospital in France and the Klinikum Vest in Germany.

Ethical considerations

This study was conducted in accordance with the ethical principles of the Declaration of Helsinki and the International Conference on Harmonization Guidelines for Good Clinical Practice.

The study design was reviewed and approved by the French Ethics Committee (CPP), the French National Agency for the Safety of Medicines and Health Products (ANSM), the Federal Institute for Drugs and Medical Devices (BfArM) and the Ethics committee of the University of Münster.

All patients provided written informed consent before entering the study.

Study registration

The study was registered at ANSM on January 4, 2016 (ID-RCB: 2016-A00010-51) and at ClinicalTrials.gov on March 9, 2017 (Identifier: NCT03076892).

Study population

Patients were recruited from the patient population of the two aforementioned centres from September 2016 to March 2017.

Patients over 18 years of age diagnosed with 10 to 14 non-pigmented, non-hyperkeratotic, grade I or II (according to the classification of Olsen et al.¹⁷), AK lesions on the forehead and scalp were enrolled in the study. These patients were required to have two treatment areas with a similar number and grade of AK lesions.

The main exclusion criteria consisted of any previous treatment of AK on the face or scalp within the last 30 days; porphyria; pregnancy; immunosuppression; use of topical corticosteroids within the last 2 weeks; contra-indication to PDT and participation in a clinical trial within the last 30 days.

The Phosistos protocol (P-PDT)

Developed within the Phosistos project funded by the European Commission (Project identifier: CIP-ICT-PSP-2013-7-621103) (<http://www.phosistos.com/>), P-PDT involves the application of MAL cream under a transparent occlusive dressing for 30 minutes followed by 2.5 hours of illumination with a fabric-based biophotonic device. The illumination is performed without removing the dressing. As illustrated in Figure 1, the device consists of a power control unit distributing 635 nm red light to a light-emitting fabric that lines the inside of a cap. Constructed from bent optical fibres, this fabric is biocompatible, flexible and provides homogeneous illumination at low irradiance (1.3 mW/cm^2) without heat generation¹⁸. Furthermore, an ergonomic helmet holds the cap in place during the treatment. The device, classified as an exempt risk group according to IEC 60601-2-57/2012, is configured to automatically start illumination 30 minutes after it is turned on and to stop 2.5 hours later such that a total dose of approximately 12 J/cm^2 is delivered. Due to the transparent occlusive dressing, the device is kept completely isolated from the patient's skin and therefore is reusable.

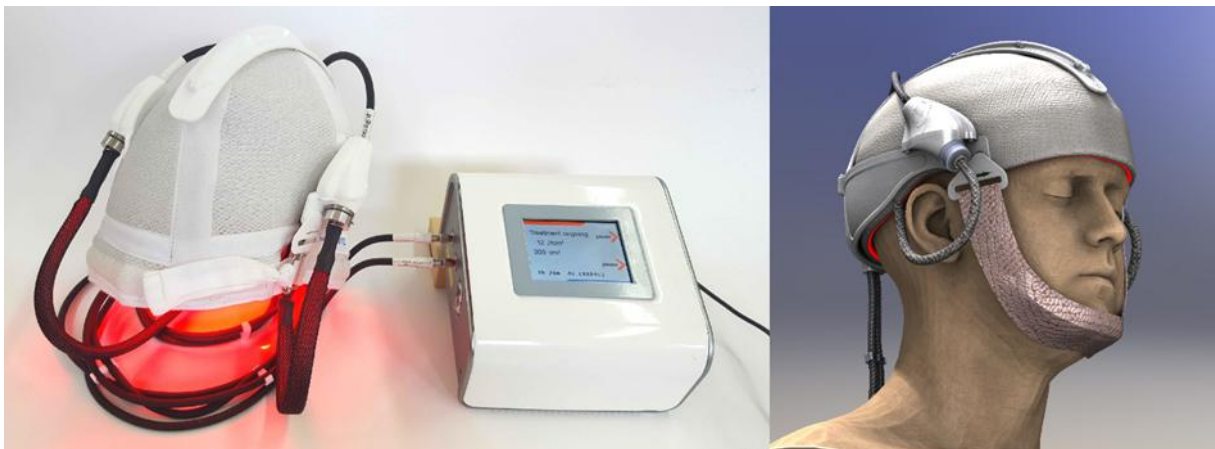

Figure 1: The fabric-based biophotonic device used for P-PDT: red light is emitted by an optical fibre-based fabric that lines the inside of a cap, which is held in place by an ergonomic helmet.

Treatment

The treatment regimen included one mandatory PDT session and a second PDT session, identical to the first, in the case of at least one remaining AK lesion among the included lesions at three months after the first PDT session. Follow-up visits were scheduled at 7 days, 3 months and 6 months after the first PDT session. If required, the second PDT session was performed within three weeks following the 3-month follow-up visit.

At the screening visit, the patient's information was recorded, and a physical examination was performed.

On the day of treatment, AK lesions were counted, graded and divided into two areas with a similar number and grade of lesions. For accurate AK localization and follow-up, AK lesions were traced on a transparent sheet. Randomization was performed. Both the areas were then prepared by removing crusts and gently scraping the lesion surface. Approximately 1 to 2 g of MAL cream (Metvixia, Galderma, France) was applied under a transparent occlusive dressing (Tegaderm, 3M, London Ontario, Canada) in a 1-mm-thick layer to the lesions and surrounding normal skin (5-10 mm margin) in each area. In the area randomized to receive C-PDT, aluminium foil was placed over the transparent occlusive dressing. The cap for P-PDT was then immediately set up and fixed by the helmet, and the power control unit was switched on so that the illumination required for P-PDT started thirty minutes later. After two and a half hours, P-PDT was completed. The cap, helmet, and all dressings were removed, and the MAL cream was washed off with saline solution. The area that received P-PDT was then protected with aluminium foil, while an Aktelite CL 128 lamp (Galderma SA, Lausanne, Switzerland) was placed 5 to 8 cm from the area that was randomized to receive C-PDT and programmed to deliver 37 J/cm² in seven to 10 minutes.

Randomization

The randomization sequence, stratified by centre, was generated by an independent statistician using the PROC PLAN procedure of SAS (SAS Institute Inc., Cary, North Carolina, USA). The allocation ratio was 1:1, and the block size was four. The allocation was concealed in sequentially numbered, opaque, sealed envelopes.

Endpoints

The primary endpoint was the lesion CR rate at three months.

The secondary endpoints included pain scores at the end of illumination, incidence of adverse effects at 7 days, lesion CR rate at 6 months, cosmetic outcome at 3 and 6 months and patient satisfaction throughout the study.

The lesion CR ("CR", "incomplete response") and skin appearance ("excellent", "good", "fair", or "poor"), from which the cosmetic outcome was derived, were clinically assessed by the investigator. The cosmetic outcome was defined as the change in skin appearance and ranged from -3 to +3 (e.g., +3 indicated an improvement from "poor" at the screening visit to "excellent" at the current visit).

Pain was assessed using a visual analogue scale ranging from 0 (no pain) to 10 (worst pain). Patient satisfaction was assessed with a standard questionnaire.

Data analysis

The study was designed to have a statistical power of 80% to demonstrate non-inferiority in the primary endpoint of P-PDT compared to C-PDT with a one-sided alpha level of 5%. A split-cluster design was adopted. The sample size was calculated assuming a design effect to account for the correlation between lesions within the same patient (intra-cluster correlation (ICC): 0.011) as well as the correlation between lesions within the same area (inter-period correlation (IPC): 0.0022). Assuming a primary endpoint of 75% in both areas, an absolute non-inferiority margin of -10% and a mean lesion number per patient per area of six (which, associated with the above-set ICC and IPC, yielded a design effect of 1.0528), 245 lesions per area were required. Considering a possible sample loss of 10%, this number was increased to 270 lesions per area (i.e., 45 patients).

Continuous variables are expressed as the means and standard deviations (SD), and categorical variables are expressed as frequencies and percentages. The normality of the distribution was assessed graphically and using the Shapiro-Wilk test.

Non-inferiority of P-PDT compared to C-PDT was assessed by estimating a one-sided 95% confidence interval (CI) of the absolute difference in lesion CR rates at three months between the two protocols. This estimation was performed using a generalized estimating equation (GEE) model with a binomial distribution and identity link function to account for repeated observations within patients. The treatment area was included as a covariate. If the lower limit of the one-sided 95% CI was higher than the pre-stated absolute margin of non-inferiority (i.e., -10%), P-PDT would be declared non-inferior to C-PDT, and a two-sided superiority test would be performed at an alpha level of 5%. A GEE model with a binomial distribution and log link function was also used to estimate the two-sided 95% CI of the relative risk of lesion CR. Furthermore, a subgroup analysis according to the severity of AK lesions (grade I vs. grade II) was performed and heterogeneity test was conducted.

The lesion CR data at six months were subject to the same statistical analysis as the lesion CR data at three months.

The differences in pain scores reported at the end of illumination between P-PDT and C-PDT were assessed using a linear mixed model with patients as random effects (the significance level was set at a two-sided alpha level of 0.05).

Finally, the cosmetic outcomes at 3 and 6 months of follow-up were compared between C-PDT and P-PDT using the Wilcoxon signed-rank test.

All statistical analyses were performed using SAS software version 9.4 (SAS Institute Inc., Cary, North Carolina, USA).

Results

Population study

Forty-seven patients were included in the study. One patient withdrew consent and did not receive treatment. Forty-six patients with a total of 560 AK lesions were treated in a split-face manner with C-PDT (280 AK lesions) and P-PDT (280 AK lesions) and were evaluated at 3 months of follow-up. Due to at least one remaining AK lesion, 19 patients were required to undergo a second PDT session. Of these, one patient dropped out for fear of pain as intense as that experienced with C-PDT during the first PDT session. As a result, 18 patients (for a total of 104 remaining AK lesions of the 220 initial AK lesions at the first treatment session) were retreated. Forty-five patients completed the study at 6 months. The study flow diagram is shown in Figure 2.

Baseline characteristics are presented in Table 1. All patients were men aged 49-89 years (mean age 72.2 years). Most patients had a Fitzpatrick skin type of II (63.0%). Of the 285 AK lesions, 45.6% and 44.9% were grade I and 54.4% and 55.1% were grade II, for those randomized to receive C-PDT and for those randomized to receive P-PDT, respectively.

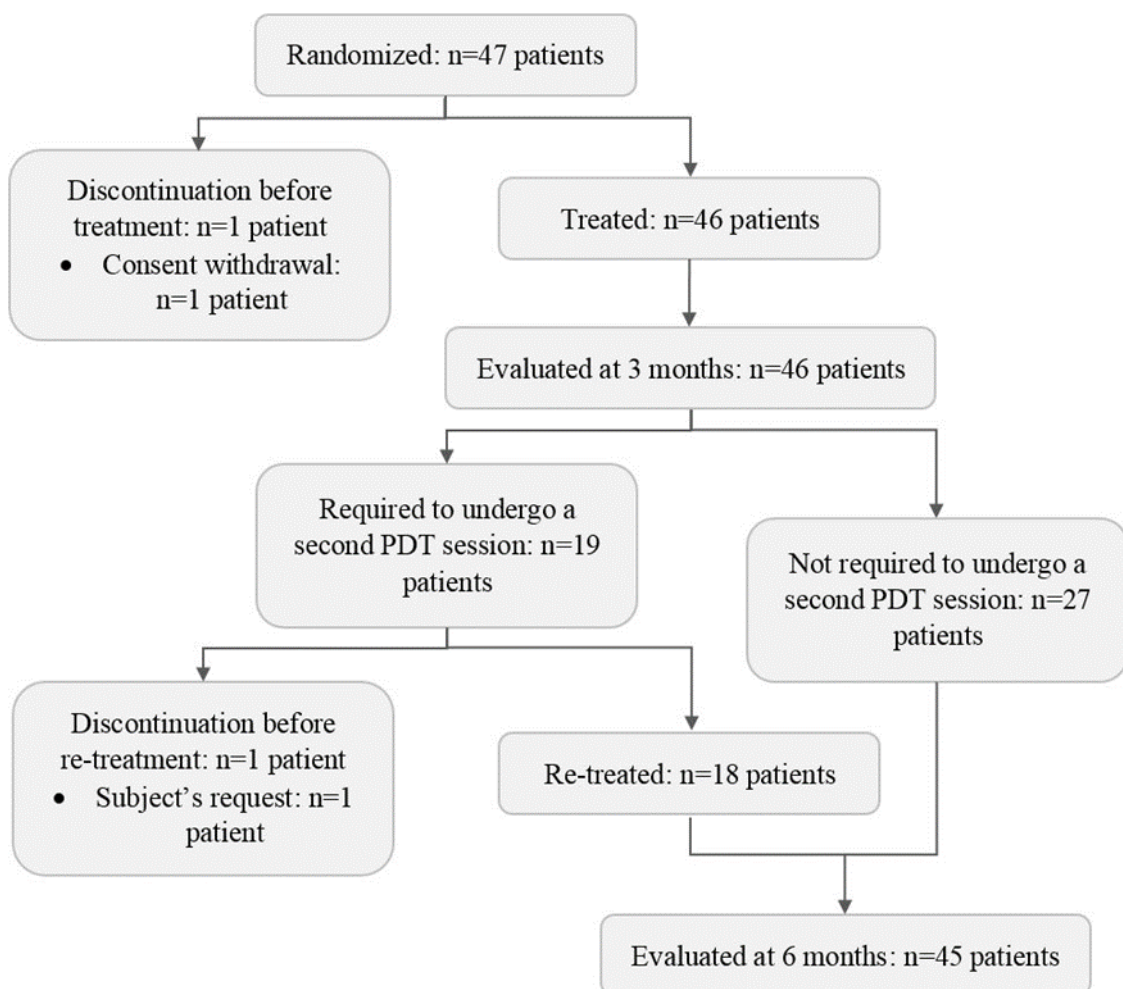


Figure 2: Study flow diagram

Table 1: Baseline demographics and clinical characteristics

Total (n=46)		
Age (years)		
Mean ± SD		72.2 ± 9.1
Range		49-89
Sex (%)		
Male		46 (100.0)
Female		0 (0.0)
Fitzpatrick skin phototype (%)		
I		8 (17.4)
II		29 (63.0)
III		8 (17.4)
IV		1 (2.2)
	C-PDT	P-PDT
Number of AK lesions	280	280
Severity of total treated lesions (%)		
Grade I	129 (46.1)	128 (44.7)
Grade II	151 (53.9)	152 (54.3)

Efficacy

Primary endpoint

The primary endpoint achieved by P-PDT was non-inferior to that obtained with C-PDT (79.3% vs. 80.7%, respectively; absolute difference, -1.6%; one-sided 95% CI, -4.5% to infinity), as evidenced by the lower limit of the one-sided 95% CI, which was much greater than the pre-stated absolute margin of non-inferiority (-10%) (Figure 3). The superiority of P-PDT over C-PDT in terms of the primary endpoint was, however, not demonstrated, with a relative risk of 0.98 (two-sided 95% CI, 0.94 to 1.02, p=0.32).

When the analysis was stratified according to the severity of AK lesions, the non-inferiority of P-PDT vs. C-PDT was established for grade I AK lesions and for grade II AK lesions without evidence of heterogeneity in treatment effect size across the two grade groups (See Table S1 in the Online Supporting Information for full details).

Lesion CR rate at six months

Six months following the first treatment session (after one PDT session for 27 patients and two PDT sessions for 18 patients), the one-sided 95% CI for the absolute difference in the lesion CR rate between P-PDT and C-PDT was -2.7% to infinity, demonstrating the non-inferiority of P-PDT vs. C-PDT, as shown in Figure 3. Nevertheless, P-PDT was not demonstrated to be superior to C-PDT (relative risk, 0.99; two-sided 95% CI, 0.97 to 1.02, p=0.66).

At 6 months, the non-inferiority of P-PDT vs. C-PDT for grade I AK lesions and the non-inferiority of P-PDT vs. C-PDT for grade II AK lesions both remained and no evidence of heterogeneity in treatment effect size across the two grade groups emerged (See Table S1 in the Online Supporting Information for full details).

AK in complete response (%)	C-PDT	P-PDT	P-PDT minus C-PDT (one-sided 95% CI)	P-PDT minus C-PDT (one-sided 95% CI)	p-value for superiority
At 3-month follow-up (after one PDT session)	226/280 (80.7)	222/280 (79.3)	-1.6 (-4.5 to ∞)		0.34
At 6-month follow-up (after one or two PDT sessions)	261/275 (94.9)	259/275 (94.2)	-0.6 (-2.7 to ∞)		0.66

Abbreviations: C-PDT, conventional photodynamic therapy; P-PDT, Phosistos photodynamic therapy; CI, confidence interval.

Figure 3: Non-inferiority evaluation of P-PDT vs. C-PDT for lesion complete response rate. Between-protocol absolute differences and their associated one-sided 95% CI were estimated from a GEE model accounting for repeated measures from individual patients and including treatment area as a covariate. Error bars indicate a one-sided 95% CI. The blue dashed line indicates the absolute non-inferiority margin, and the blue tinted region indicates the zone of inferiority.

Tolerability

Pain

With all pain scores ranging from 0 to 2.7, P-PDT was almost painless. Regarding the first PDT session, the pain at the end of illumination was significantly lower for P-PDT than for C-PDT (0.3 ± 0.6 vs. 7.4 ± 2.3 , $p < 0.0001$). The same advantage was also observed for the second PDT session (Figure 4) (0.2 ± 0.4 for P-PDT vs. 7.7 ± 1.8 for C-PDT, $p < 0.0001$).

One patient experienced such severe pain with C-PDT during the first PDT session that he dropped out of the study when a second PDT session was required.

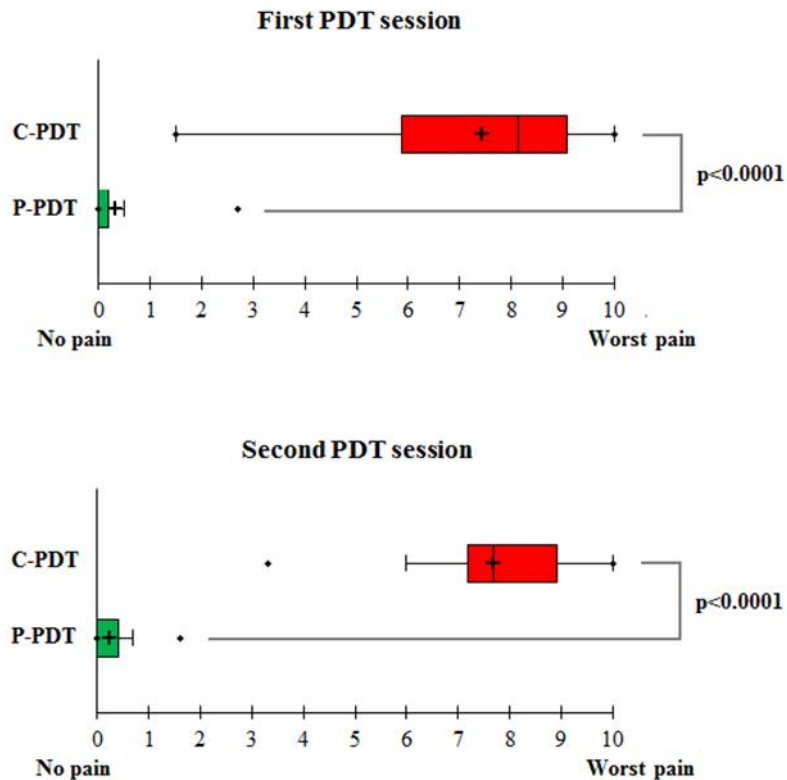


Figure 4: Box plot of pain scores. The black crosses correspond to the mean pain scores, and the central horizontal bars represent the median pain scores. The lower and upper limits of the boxes indicate the first and third quartiles, respectively. Points above or below the upper and lower bounds of the whiskers can be considered outliers. The ends of the whiskers represent the minimum and maximum pain scores when excluding outliers.

Adverse effects

As shown in Table 2, the number of patients reporting adverse effects at 7 days was lower for P-PDT than for C-PDT (34 vs. 40) and each adverse effect, particularly skin haemorrhage, was more likely to be reported for C-PDT than for P-PDT. No serious adverse effects occurred. Skin exfoliation was observed in a vast majority of patients and was the most common adverse effect for both P-PDT and C-PDT. Scab, skin haemorrhage and pruritus were also frequently experienced with the two protocols.

Patients (%)	C-PDT	P-PDT
All related adverse reactions	40 (85.1)	34 (72.3)
Related serious adverse reactions	0 (0)	0 (0)
Skin burning sensation	1 (2.2)	0 (0)
Scab	19 (41.3)	16 (34.8)
Erythema	5 (10.9)	4 (8.7)
Skin infection	0 (0)	0 (0)

Skin ulcer	0 (0)	0 (0)
Skin oedema	0 (0)	0 (0)
Skin swelling	0 (0)	0 (0)
Blister	0 (0)	0 (0)
Skin haemorrhage	12 (26.1)	6 (13.0)
Pruritus	8 (17.4)	6 (13.0)
Skin exfoliation	35 (76.1)	30 (65.2)
Paraesthesia	4 (8.7)	2 (4.3)
Headache	0 (0)	0 (0)
Other	0 (0)	0 (0)

Cosmetic outcome

According to Figure 5, the cosmetic outcome achieved with P-PDT and that obtained with C-PDT showed identical medians and distributions of data at three months (median: 1; interquartile: 1) and at 6 months (median: 1; interquartile: 2). From Figure 5, an improvement of the skin appearance was observed throughout the study.

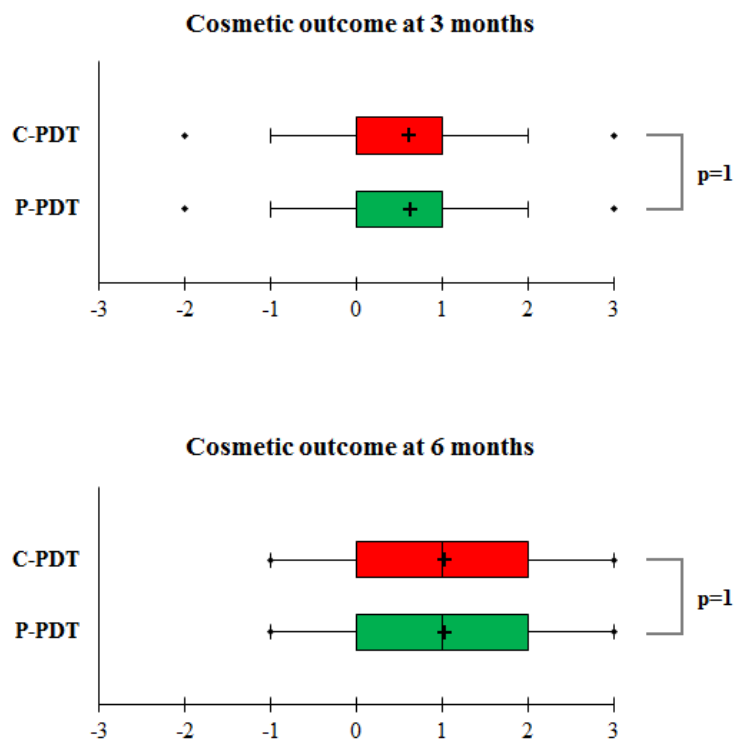


Figure 5: Box plot of cosmetic outcomes. The black crosses correspond to the mean cosmetic outcomes, and the central horizontal bars represent the median cosmetic outcomes. The lower and upper limits of the boxes indicate the first and third quartiles, respectively. Points above or below the upper and lower bounds of the whiskers can be considered outliers. The ends of the whiskers represent the minimum and maximum cosmetic outcomes when excluding outliers.

Patient satisfaction

As expected given the above-reported pain scores, C-PDT was mostly rated as very unpleasant by patients (71.7%), whereas P-PDT was perceived as either not (41.3%) or slightly unpleasant (47.8%). Probably due to pain experienced during illumination, more than 80% of patients were dissatisfied or very dissatisfied with C-PDT, compared to less than 7% with P-PDT. As a result, 93.5% of patients preferred P-PDT to C-PDT, while the remaining 6.5% expressed no preference. Regarding the illumination time, the 2.5 hours required for P-PDT were mainly described as slightly unpleasant (67.4% of patients), while the seven to 10 minutes required for C-CPT was described as very unpleasant (60.9% of patients).

Discussion

The present study demonstrates that P-PDT could be an effective, nearly painless, convenient alternative to C-PDT for treating AK of the forehead and scalp. The primary endpoint analysis showed that P-PDT was significantly non-inferior to C-PDT; the lesion CR rate at three months was 80.7% in the C-PDT area vs. 79.3% in the P-PDT area. Moreover, P-PDT showed better tolerability in terms of pain and adverse effects and a higher patient adherence than C-PDT. With a mean pain score less than 0.3, P-PDT was preferred by 93.5% of patients to C-PDT, as the mean pain score of the latter was higher than 7.

P-PDT is a revised version of FLEXI-PDT, which we have recently shown to be non-inferior to C-PDT for the lesion CR rate and superior for pain¹⁶. FLEXI-PDT, which consists of MAL under occlusion for 30 minutes followed by 2.5 hours of fractionated illumination with a light-emitting, fabric-based device emitting 635 nm red light at 12.3 mW/cm² irradiance, involves a 37 J/cm² light dose, similar to C-PDT. Based on a study that reported successful PDT treatment of AK with red traffic lamps and a light dose of 3.5 J/cm²¹⁹, we have reduced the light dose from 37 J/cm² for FLEXI-PDT to 12 J/cm² for P-PDT. We also reduced the irradiance (from 12.3 mW/cm² to 1.3 mW/cm²) and preferred continuous illumination to fractionated illumination. The reduction in irradiance was motivated by several studies that have demonstrated similar PDT efficacy between variable irradiances^{20,21}.

The homogeneous low irradiance of P-PDT and, perhaps more specifically, the short delay of 30 minutes between MAL application and illumination initiation allowed P-PDT to be significantly superior to C-PDT regarding pain. With 40 of 46 patients reporting a pain score lower than 1, P-PDT was nearly painless, whereas pain during illumination remained the major drawback of C-PDT (24 of 46 patients reported a pain score higher than 8). Unlike C-PDT²²⁻²⁵, P-PDT allows treatment to be conducted without the use of strategies to manage pain. These strategies are already not required for protocols involving illumination with daylight^{7-9,26-28}. However, compared to those protocols, P-PDT is also neither time of year- nor location-dependent. Indeed, the MAL manufacturers recommend using the daylight protocols only if the temperature and weather conditions are suitable to stay comfortably outdoors for two hours. Moreover, the daylight illumination requirements for an effective treatment have been demonstrated to be achieved only until mid-September in Iceland and Norway, until mid-

November in Italia, and until the end of October in Denmark and Germany¹². By contrast, P-PDT can be conducted year-round in all weather conditions and geographic locations. Moreover, P-PDT consistently delivers the same light dose.

The optimal conformability of the flexible light-emitting fabric used in P-PDT to the treatment area allows homogeneous illumination and an equal light dose of 12 J/cm² to be delivered anywhere in the treatment area. In contrast, heterogeneities in irradiance and light dose with the Aktelite CL 128 lamp used in C-PDT have been demonstrated in several studies^{29,30}. Vicentini et al. thus reported an irradiance ranging from 0.25 to 60 mW/cm² and a light dose ranging from 0.15 to 36 J/cm² when treating patients with AK of the forehead and scalp^{30,31}.

Similar results than those achieved with P-PDT, both in terms of efficacy and tolerability, could be obtained with low-irradiance illumination beginning 30 minutes after applying MAL provided that a homogeneous illumination over the treatment area is achieved. Unfortunately, this is not the case for most LED panels and in particular for the Aktelite CL 128 lamp as above discussed.

Our study has several limitations. The major limitation is that the study was unblinded, since the investigator, who assessed the lesion CR, and the patients were aware of which protocol was used. This limitation can lead to biased estimates of protocol performances. Further trials with blinded investigator assessment of photographs should be performed.

Due to its compact device and convenient use, P-PDT could be further considered for ambulatory use at home. Patients may leave the dermatological practice after MAL application and device installation by health professionals and receive their treatment while performing their daily tasks. This freedom would provide an additional advantage to P-PDT over C-PDT, which is time-consuming for both health professionals and patients and requires quite cumbersome equipment usually available only in hospitals. P-PDT could therefore become the treatment of choice for AK.

Acknowledgements

The authors thank all members and partners of the Phosistos consortium (www.phosistos.com) (<https://cordis.europa.eu/project/rcn/191777/factsheet/en>). The authors acknowledge the European Commission for funding the Phosistos project under the Competitiveness and Innovation Framework Programme. The authors also thank Galderma R&D (France) and Avène Dermatological Laboratories (France) for graciously supplying Metvixia cream and Cicalfate Repair cream, respectively.

References

- 1 Szeimies RM, Torezan L, Niwa A *et al.* Clinical, histopathological and immunohistochemical assessment of human skin field cancerization before and after photodynamic therapy. *Br J Dermatol* 2012; **167**: 150-9.
- 2 Braathen LR, Morton CA, Basset-Seguin N *et al.* Photodynamic therapy for skin field cancerization: an international consensus. International Society for Photodynamic Therapy in Dermatology. *J Eur Acad Dermatol Venereol* 2012; **26**: 1063-6.
- 3 Morton C, Szeimies RM, Sidoroff A *et al.* European Dermatology Forum Guidelines on topical photodynamic therapy. *Eur J Dermatol* 2015; **25**: 296-311.
- 4 Morton C, Campbell S, Gupta G *et al.* Intraindividual, right-left comparison of topical methyl aminolaevulinate-photodynamic therapy and cryotherapy in subjects with actinic keratoses: a multicentre, randomized controlled study. *Br J Dermatol* 2006; **155**: 1029-36.
- 5 Pariser D, Loss R, Jarratt M *et al.* Topical methyl-aminolevulinate photodynamic therapy using red light-emitting diode light for treatment of multiple actinic keratoses: A randomized, double-blind, placebo-controlled study. *J Am Acad Dermatol* 2008; **59**: 569-76.
- 6 Szeimies RM, Matheson RT, Davis SA *et al.* Topical methyl aminolevulinate photodynamic therapy using red light-emitting diode light for multiple actinic keratoses: a randomized study. *Dermatol Surg* 2009; **35**: 586-92.
- 7 Wiegell SR, Haedersdal M, Philipsen PA *et al.* Continuous activation of PpIX by daylight is as effective as and less painful than conventional photodynamic therapy for actinic keratoses; a randomized, controlled, single-blinded study. *Br J Dermatol* 2008; **158**: 740-6.
- 8 Rubel DM, Spelman L, Murrell DF *et al.* Daylight photodynamic therapy with methyl aminolevulinate cream as a convenient, similarly effective, nearly painless alternative to conventional photodynamic therapy in actinic keratosis treatment: a randomized controlled trial. *Br J Dermatol* 2014; **171**: 1164-71.
- 9 Wiegell SR, Wulf HC, Szeimies RM *et al.* Daylight photodynamic therapy for actinic keratosis: an international consensus: International Society for Photodynamic Therapy in Dermatology. *J Eur Acad Dermatol Venereol* 2012; **26**: 673-9.
- 10 Neittaanmaki-Perttu N, Karppinen TT, Gronroos M *et al.* Daylight photodynamic therapy for actinic keratoses: a randomized double-blinded nonsponsored prospective study comparing 5-aminolaevulinic acid nanoemulsion (BF-200) with methyl-5-aminolaevulinate. *Br J Dermatol* 2014; **171**: 1172-80.

- 11 O'Gorman SM, Clowry J, Manley M *et al.* Artificial White Light vs Daylight Photodynamic Therapy for Actinic Keratoses: A Randomized Clinical Trial. *JAMA Dermatol* 2016; **152**: 638-44.
- 12 Wiegell SR, Fabricius S, Heydenreich J *et al.* Weather conditions and daylight-mediated photodynamic therapy: protoporphyrin IX-weighted daylight doses measured in six geographical locations. *Br J Dermatol* 2013; **168**: 186-91.
- 13 Kellner C, Bauriedl S, Hollstein S *et al.* Simulated-daylight photodynamic therapy with BF-200 aminolaevulinic acid for actinic keratosis: assessment of the efficacy and tolerability in a retrospective study. *Br J Dermatol* 2015; **172**: 1146-8.
- 14 Kessels JP, Nelemans PJ, Mosterd K *et al.* Laser-mediated Photodynamic Therapy: An Alternative Treatment for Actinic Keratosis? *Acta Derm Venereol* 2016; **96**: 351-4.
- 15 Lerche CM, Heerfordt IM, Heydenreich J *et al.* Alternatives to Outdoor Daylight Illumination for Photodynamic Therapy--Use of Greenhouses and Artificial Light Sources. *Int J Mol Sci* 2016; **17**: 309.
- 16 Vicentini C, Vignion-Dewalle AS, Thecua E *et al.* Photodynamic therapy for actinic keratosis of the forehead and scalp: a randomized controlled clinical study evaluating the non-inferiority of a new protocol applying irradiation with a light-emitting, fabric-based device (the Flexitheralight protocol) compared to the conventional protocol using the Aktelite CL 128 lamp. *Br J Dermatol* 2018; **Accepted**.
- 17 Olsen EA, Abernethy ML, Kulp-Shorten C *et al.* A double-blind, vehicle-controlled study evaluating masoprocol cream in the treatment of actinic keratoses on the head and neck. *J Am Acad Dermatol* 1991; **24**: 738-43.
- 18 Mordon S, Cochrane C, Tylcz JB *et al.* Light emitting fabric technologies for photodynamic therapy. *Photodiagnosis Photodyn Ther* 2015; **12**: 1-8.
- 19 Enk CD, Levi A. Low-irradiance red LED traffic lamps as light source in PDT for actinic keratoses. *Photodermatol Photoimmunol Photomed* 2012; **28**: 332-4.
- 20 Langmack K, Mehta R, Twyman P *et al.* Topical photodynamic therapy at low fluence rates--theory and practice. *J Photochem Photobiol B* 2001; **60**: 37-43.
- 21 Apalla Z, Sotiriou E, Panagiotidou D *et al.* The impact of different fluence rates on pain and clinical outcome in patients with actinic keratoses treated with photodynamic therapy. *Photodermatol Photoimmunol Photomed* 2011; **27**: 181-5.
- 22 Jetter N, Chandan N, Wang S *et al.* Field Cancerization Therapies for Management of Actinic Keratosis: A Narrative Review. *Am J Clin Dermatol* 2018.
- 23 Serra-Guillen C, Hueso L, Nagore E *et al.* Comparative study between cold air analgesia and supraorbital and supratrochlear nerve block for the management of pain during

- photodynamic therapy for actinic keratoses of the frontotemporal zone. *Br J Dermatol* 2009; **161**: 353-6.
- 24 Halldin CB, Paoli J, Sandberg C *et al.* Nerve blocks enable adequate pain relief during topical photodynamic therapy of field cancerization on the forehead and scalp. *Br J Dermatol* 2009; **160**: 795-800.
 - 25 Stangeland KZ, Kroon S. Cold air analgesia as pain reduction during photodynamic therapy of actinic keratoses. *J Eur Acad Dermatol Venereol* 2012; **26**: 849-54.
 - 26 Wiegell SR, Fabricius S, Gniadecka M *et al.* Daylight-mediated photodynamic therapy of moderate to thick actinic keratoses of the face and scalp: a randomized multicentre study. *Br J Dermatol* 2012; **166**: 1327-32.
 - 27 Wiegell SR, Fabricius S, Stender IM *et al.* A randomized, multicentre study of directed daylight exposure times of 1(1/2) vs. 2(1/2) h in daylight-mediated photodynamic therapy with methyl aminolaevulinate in patients with multiple thin actinic keratoses of the face and scalp. *Br J Dermatol* 2011; **164**: 1083-90.
 - 28 Wiegell SR, Haedersdal M, Eriksen P *et al.* Photodynamic therapy of actinic keratoses with 8% and 16% methyl aminolaevulinate and home-based daylight exposure: a double-blinded randomized clinical trial. *Br J Dermatol* 2009; **160**: 1308-14.
 - 29 Moseley H. Light distribution and calibration of commercial PDT LED arrays. *Photochem Photobiol Sci* 2005; **4**: 911-4.
 - 30 Vicentini C, Vignion-Dewalle AS, Thecua E *et al.* Photodynamic therapy of actinic keratosis with the Aktelite CL128: irradiance distribution and impact of light dose on the treatment efficacy. *EuroPDT Nice* 2018.
 - 31 Vicentini C, Vignion-Dewalle AS, Thecua E *et al.* Photodynamic therapy for actinic keratosis of the forehead and scalp with the Aktelite CL 128: is there a cut-off value for PpIX-weighted irradiance for effective treatment? *Photodermatol Photoimmunol Photomed* 2019.