



HAL
open science

Operatively induced chronic reflux in rats: A suitable model for studying esophageal carcinogenesis?

Caroline Gronnier, Emilie Bruyère, Guillaume Piessen, Nicolas Briez, Jérôme Bot, David Buob, Emmanuelle Leteurre, Isabelle van Seuningen, Christophe Mariette

► To cite this version:

Caroline Gronnier, Emilie Bruyère, Guillaume Piessen, Nicolas Briez, Jérôme Bot, et al.. Operatively induced chronic reflux in rats: A suitable model for studying esophageal carcinogenesis?. *Surgery*, 2013, 10.1016/j.surg.2013.05.029 . hal-02905869

HAL Id: hal-02905869

<https://hal.science/hal-02905869>

Submitted on 30 Sep 2020


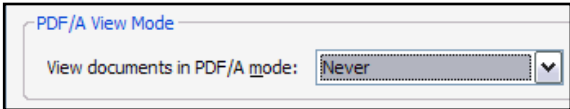
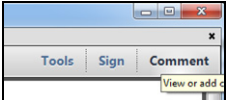
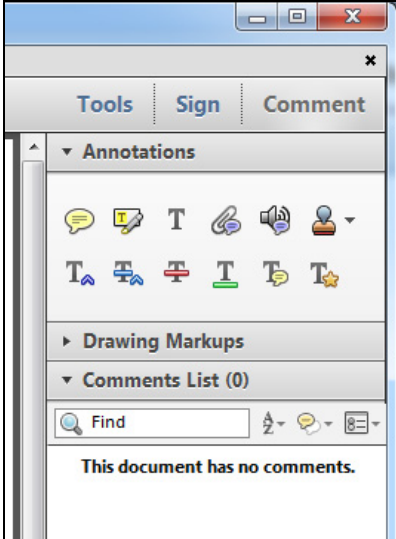
HAL is a multi-disciplinary open access archive for the deposit and dissemination of scientific research documents, whether they are published or not. The documents may come from teaching and research institutions in France or abroad, or from public or private research centers.

L'archive ouverte pluridisciplinaire **HAL**, est destinée au dépôt et à la diffusion de documents scientifiques de niveau recherche, publiés ou non, émanant des établissements d'enseignement et de recherche français ou étrangers, des laboratoires publics ou privés.






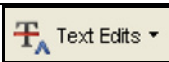





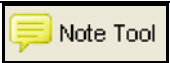

INSTRUCTIONS ON THE ANNOTATION OF PDF FILES

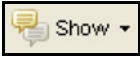
To view, print and annotate your article you will need Adobe Reader version 9 (or higher). This program is freely available for a whole series of platforms that include PC, Mac, and UNIX and can be downloaded from <http://get.adobe.com/reader/>. The exact system requirements are given at the Adobe site: <http://www.adobe.com/products/reader/tech-specs.html>.

Note: if you opt to annotate the file with software other than Adobe Reader then please also highlight the appropriate place in the PDF file.

PDF ANNOTATIONS	
Adobe Reader version 9	Adobe Reader version X and XI
<p>When you open the PDF file using Adobe Reader, the Commenting tool bar should be displayed automatically; if not, click on 'Tools', select 'Comment & Markup', then click on 'Show Comment & Markup tool bar' (or 'Show Commenting bar' on the Mac). If these options are not available in your Adobe Reader menus then it is possible that your Adobe Acrobat version is lower than 9 or the PDF has not been prepared properly.</p>  <p>(Mac)</p> <p>PDF ANNOTATIONS (Adobe Reader version 9)</p> <p>The default for the Commenting tool bar is set to 'off' in version 9. To change this setting select 'Edit Preferences', then 'Documents' (at left under 'Categories'), then select the option 'Never' for 'PDF/A View Mode'.</p>  <p>(Changing the default setting, Adobe version 9)</p>	<p>To make annotations in the PDF file, open the PDF file using Adobe Reader XI, click on 'Comment'.</p> <p>If this option is not available in your Adobe Reader menus then it is possible that your Adobe Acrobat version is lower than XI or the PDF has not been prepared properly.</p>  <p>This opens a task pane and, below that, a list of all Comments in the text. These comments initially show all the changes made by our copyeditor to your file.</p> 

HOW TO...

HOW TO...		
Action	Adobe Reader version 9	Adobe Reader version X and XI
Insert text	<p>Click the 'Text Edits' button  on the Commenting tool bar. Click to set the cursor location in the text and simply start typing. The text will appear in a commenting box. You may also cut-and-paste text from another file into the commenting box. Close the box by clicking on 'x' in the top right-hand corner.</p>	<p>Click the 'Insert Text' icon  on the Comment tool bar. Click to set the cursor location in the text and simply start typing. The text will appear in a commenting box. You may also cut-and-paste text from another file into the commenting box. Close the box by clicking on 'x'  in the top right-hand corner.</p>
Replace text	<p>Click the 'Text Edits' button  on the Commenting tool bar. To highlight the text to be replaced, click and drag the cursor over the text. Then simply type in the replacement text. The replacement text will appear in a commenting box. You may also cut-and-paste text from another file into this box. To replace formatted text (an equation for example) please Attach a file (see below).</p>	<p>Click the 'Replace (Ins)' icon  on the Comment tool bar. To highlight the text to be replaced, click and drag the cursor over the text. Then simply type in the replacement text. The replacement text will appear in a commenting box. You may also cut-and-paste text from another file into this box. To replace formatted text (an equation for example) please Attach a file (see below).</p>
Remove text	<p>Click the 'Text Edits' button  on the Commenting tool bar. Click and drag over the text to be deleted. Then press the delete button on your keyboard. The text to be deleted will then be struck through.</p>	<p>Click the 'Strikethrough (Del)' icon  on the Comment tool bar. Click and drag over the text to be deleted. Then press the delete button on your keyboard. The text to be deleted will then be struck through.</p>
Highlight text/ make a comment	<p>Click on the 'Highlight' button  on the Commenting tool bar. Click and drag over the text. To make a comment, double click on the highlighted text and simply start typing.</p>	<p>Click on the 'Highlight Text' icon  on the Comment tool bar. Click and drag over the text. To make a comment, double click on the highlighted text and simply start typing.</p>
Attach a file	<p>Click on the 'Attach a File' button  on the Commenting tool bar. Click on the figure, table or formatted text to be replaced. A window will automatically open allowing you to attach the file. To make a comment, go to 'General' in the 'Properties' window, and then 'Description'. A graphic will appear in the PDF file indicating the insertion of a file.</p>	<p>Click on the 'Attach File' icon  on the Comment tool bar. Click on the figure, table or formatted text to be replaced. A window will automatically open allowing you to attach the file. A graphic will appear indicating the insertion of a file.</p>
Leave a note/ comment	<p>Click on the 'Note Tool' button  on the Commenting tool bar. Click to set the location of the note on the document and simply start typing. <u>Do not use this feature to make text edits.</u></p>	<p>Click on the 'Add Sticky Note' icon  on the Comment tool bar. Click to set the location of the note on the document and simply start typing. <u>Do not use this feature to make text edits.</u></p>

HOW TO...		
Action	Adobe Reader version 9	Adobe Reader version X and XI
Review	To review your changes, click on the 'Show' button  on the Commenting tool bar. Choose 'Show Comments List'. Navigate by clicking on a correction in the list. Alternatively, double click on any mark-up to open the commenting box.	Your changes will appear automatically in a list below the Comment tool bar. Navigate by clicking on a correction in the list. Alternatively, double click on any mark-up to open the commenting box.
Undo/delete change	To undo any changes made, use the right click button on your mouse (for PCs, Ctrl-Click for the Mac). Alternatively click on 'Edit' in the main Adobe menu and then 'Undo'. You can also delete edits using the right click (Ctrl-click on the Mac) and selecting 'Delete'.	To undo any changes made, use the right click button on your mouse (for PCs, Ctrl-Click for the Mac). Alternatively click on 'Edit' in the main Adobe menu and then 'Undo'. You can also delete edits using the right click (Ctrl-click on the Mac) and selecting 'Delete'.

SEND YOUR ANNOTATED PDF FILE BACK TO ELSEVIER

Save the annotations to your file and return as instructed by Elsevier. Before returning, please ensure you have answered any questions raised on the Query Form and that you have inserted all corrections: later inclusion of any subsequent corrections cannot be guaranteed.

FURTHER POINTS

- Any (grey) halftones (photographs, micrographs, etc.) are best viewed on screen, for which they are optimized, and your local printer may not be able to output the greys correctly.
- If the PDF files contain colour images, and if you do have a local colour printer available, then it will be likely that you will not be able to correctly reproduce the colours on it, as local variations can occur.
- If you print the PDF file attached, and notice some 'non-standard' output, please check if the problem is also present on screen. If the correct printer driver for your printer is not installed on your PC, the printed output will be distorted.

Operatively induced chronic reflux in rats: A suitable model for studying esophageal carcinogenesis?

Q2 **Caroline Gronnier, MD,^{a,b,c} Emilie Bruyère, PhD,^{a,b,c} Guillaume Piessen, MD, PhD,^{a,b,c} Nicolas Briez, MD,^{a,b,c} Jérôme Bot, MD,^{a,b,c} David Buob, MD,^{b,d} Emmanuelle Leteurtre, MD, PhD,^{a,b,d} Isabelle Van Seuning, PhD,^{a,b} and Christophe Mariette, MD, PhD,^{a,b,c} Lille, France**

Background. The mechanisms of esophageal reflux leading to esophageal adenocarcinoma (EA) remain poorly understood. This study appraises critically an operatively induced chronic reflux rat model.

Methods. We randomized 108 Sprague-Dawley rats into 2 experimental groups; one was performing esophagoduodenal (ED) anastomosis with or without gastrectomy to induce duodeno-esophageal reflux (DER group; n = 63), and the other involved duodeno-gastro-esophageal reflux (DGER group; n = 45). Control groups included (i) Roux-en-Y esophagojejunal anastomosis, (ii) laparotomy alone, (iii) subtotal gastrectomy to induce duodenogastric reflux (DGR group), and (iv) the same procedure as in the DGER group plus proton pump inhibition (PPI group). The esophagus underwent histologic and molecular analyses.

Results. The prevalence of Barrett's esophagus (BE), dysplasia, and EA in the experimental groups was 41%, 7%, and 11%, respectively. Histologic and molecular analyses in groups DER, DGER, and DGR suggested that BE occurred through de novo intestinal metaplasia and proximal migration of duodenal cells. No distant metastases were identified. The molecular characteristics of both BE and EA were similar to humans. BE was more common, and dysplasia and EA less frequent in the DER group when compared with the DGER group (44% vs 24% [P = .038] and 7% vs 25% [P = .012], respectively). Compared with the DGER group, carcinogenic sequence occurred less frequently in the PPI-treated group (P = .019).

Conclusion. Despite pathophysiologic differences with humans, the rat model of esophagoduodenostomy reproduces accurately histologic and molecular lesions in the carcinogenic sequence of BE and allowed us to identify novel, tumor-associated proteins that may be potential biomarkers and new therapeutic targets in EA. (Surgery 2013;■:■-■.)

From Inserm, UMR837,^a Jean-Pierre Aubert Research Center, Team 5 "Mucins, epithelial differentiation and carcinogenesis," the Université Lille Nord de France,^b the Department of Digestive and Oncological Surgery,^c University Hospital Claude Huriez, Centre Hospitalier Régional et Universitaire de Lille, and the Centre de Biologie-Pathologie,^d Department of Pathology, Centre Hospitalier Régional et Universitaire de Lille, Lille, France

DESPITE ADVANCES IN MULTIMODAL THERAPY, the prognosis for invasive esophageal adenocarcinoma (EA) remains poor.¹ EA is thought to develop in Barrett's esophagus (BE), following the low- to high-grade dysplasia sequence and under the

influence of duodeno-gastric-esophageal reflux (DGER).² The cytotoxic mechanisms of reflux leading to initiation and progression of BE remain poorly understood. The hypothesis has been made that pH changes in DGER caused by PPI may induce cytotoxicity related to the bile acid refluxed and may play a role in the increase in incidence of EA incidence in Western countries.³

Because of the long delay in the progression of the carcinogenic sequence in humans, an efficient animal model of BE and EA better our understanding of the mechanisms involved. Various surgical models of BE/EA have been reported.⁴⁻¹⁰ None showed superiority. Discrepant results have been reported regarding the time of development

Accepted for publication May 16, 2013.

Reprint requests: Christophe Mariette, MD, PhD, Professor of Surgery, Department of Digestive and Oncological Surgery, University Hospital Claude Huriez, Centre Hospitalier régional et Universitaire, Place de Verdun F-59037, Lille, France. E-mail: christophe.mariette@chru-lille.fr.

0039-6060/\$ - see front matter

© 2013 Mosby, Inc. All rights reserved.

<http://dx.doi.org/10.1016/j.surg.2013.05.029>

of each step in the sequence of carcinogenesis.¹¹ Whether the metaplasia in these models is de novo, originating from the esophageal glands, is derived by entrapment of duodenal mucosa to the esophageal wall during the anastomosis, or occurs by creeping substitution (proximal migration of duodenal cells through the anastomosis) remains unclear.^{8,12,13} Doubt has been cast on whether these models reflect the development of BE and EA.⁸ Moreover, many investigators have also reported adenosquamous or pure squamous cell carcinoma, questioning the model's ability to elucidate mechanisms of tumorigenesis.^{9,13} Finally, the respective roles of duodenal and gastroduodenal reflux in the model remain unsolved.^{5,7} These questions raise the validity of the animal model as a reliable tool in understanding the human carcinogenic sequence.^{8,12,13}

The aims of our study were to evaluate at histologic and molecular levels the (i) value of the rat model, and (ii) respective roles of the duodenal and gastroduodenal reflux, in the BE/EA carcinogenic sequence.

Q1 MATERIAL AND METHODS

Six-week-old, male Sprague-Dawley rats (Charles River, L'Arbresle, France), were housed under standard laboratory conditions. Operations were performed under general anesthesia, using xylazine (12 mg/kg) and ketamine (80 mg/kg). Through a midline laparotomy, operative procedures were performed to induce esophageal reflux. The experimental protocol received approval from the Veterinary Ethics Committee (CREEA, authorization no.59-350177).

Experimental groups (Fig 1). *DGER group.* We [F1-4/C] performed an esophagoduodenal (ED) anastomosis without gastrectomy to study the impact of the combination of gastric and duodenal reflux on esophageal mucosa. The esophagus was transected proximal to the gastroesophageal junction, and anastomosed to the duodenum with mucosa-to-mucosa apposition with 8 interrupted sutures of 7.0 polypropylene.

Duodeno-esophageal reflux group. We performed an ED anastomosis with gastrectomy to evaluate the impact of the duodenal reflux on esophageal mucosa. A total gastrectomy was performed after ligation of left gastric and short gastric vessels, and the duodenum just distal to the pylorus. The distal esophagus was anastomosed as in DGER group.

Control groups. *Roux-en-Y esophagojejunal anastomosis group.* We performed an esophagojejunal (EJ) anastomosis with jejunal limb without reflux (internal control). The proximal jejunum was

transected 4 cm distal to the duodenojejunal junction and sectioned proximal to the ligature. The distal segment was anastomosed to the distal esophagus via a Roux-en-Y (RY) esophagojejunostomy and an entero-entero anastomosis ≥ 15 cm distal to the esophagojejunostomy using a 1-layer, running 7.0 polypropylene suture.

Laparotomy group. We performed laparotomy (LAP) only (external control).

Duodenogastric reflux group. We performed a partial gastrectomy respecting the gastroesophageal junction, with a proximal gastroduodenal anastomosis. This duodenogastric reflux (DGR) group, in which the esophagus was adjacent to but not part of the anastomosis, acted as a control for the duodeno-esophageal reflux (DER) group to evaluate if the origin of esophageal intestinal metaplasia was de novo, originating from the esophagus, or originating from the duodenum through entrapment of duodenal mucosa into the esophageal wall during the ED or creeping of duodenal cells across the anastomosis as a healing process. The stomach was anastomosed to the duodenum via a gastroduodenostomy with 10 interrupted sutures of 7.0 polypropylene.

Proton pump inhibitor group. Rats that underwent the same procedure as in the DGER group received Esomeprazole (Astra-Zeneca, Dunkerque, France), at a dose of 5 $\mu\text{mol/kg}$ via daily gavage from day 1 after the operative procedure. This group was used to evaluate the suppression of the acidic in the gastric reflux in operatively induced DGER rats to evaluate its role on reflux-induced lesions.

Tissue specimens. All animals were weighed weekly. Rats that became ill or lost $>15\%$ of their weight were killed. Rats that died before the scheduled date were autopsied.

Animals were killed under general anesthesia to recover tissue samples at 20 weeks for BE lesions, 30 weeks for dysplasia, and 50 weeks for EA.¹¹ As a consequence of the intermediate results obtained for the last 55 rats operated, the killing of these animals was delayed to 60, 70, and 80 weeks, to test the hypothesis that a longer duration of exposure to reflux could increase the incidence of each step of the carcinogenic sequence.¹ After injection of the euthanizing agent T61, the thoracic and abdominal cavities were inspected with an en bloc removal of the esophagus. After longitudinal opening, the esophagus was sectioned into slices of 2- to 3-mm thickness. In rats with visible esophageal tumor, the liver and the lungs were removed to perform a histologic analysis looking for micrometastases.

Histologic analysis. Histologic analyses were performed by 2 expert pathologists in a double-blinded manner (EL, DB). Tissues were fixed in 10% (w/v) buffered formaldehyde, embedded in paraffin, cut at 4 μm thickness, and applied on SuperFrost slides (Menzel-Glaser, Braunschweig, Germany). Slides were then stained with hematoxylin and eosin, Safran, and Astra blue. Lesions were defined as (i) BE, specialized columnar epithelium with cellular characteristics mimicking human BE (intestinal-like cells and Alcian blue-positive goblet cells); (ii) dysplasia, lesions with an increase of the nuclear-cytoplasmic ratio, nuclear atypia, partial loss of cell polarity, and increase in mitotic figures, and (iii) EA, predominant component or pure EA with invasion through the basement membrane to surrounding tissues, tumor stroma reaction, increase in nuclear atypia, and mitotic figures.

pH-metry. A measurement of intragastric pH was performed using a pH meter orion 2 star (Thermoscientific, Brebieres, France), in 10 randomly selected rats of the DGER, LAP, and PPI groups after aspiration through a gastrotomy to assess the persistence of acid secretion (DGER group) or its suppression (PPI group).

RNA extraction and purification. Total RNA was isolated and purified from tissues using the NucleoSpin RNA L kit (Macherey-Nagel, Düren, Germany) as described in the manufacturer's protocol. The RNA quantity was determined by measuring the optical density at 260 nm with a NanoDrop 1000 spectrophotometer (Thermo Scientific, Pittsburgh, Penn).

Quantitative reverse transcriptase-polymerase chain reaction. Total RNA (0.5 μg) was used to prepare cDNA using the RT² First Strand Kit (SABioscience, Valencia, Calif). Quantitative reverse transcriptase-polymerase chain reaction (qRT-PCR) was performed on cDNA (1 μL), using specific primers for TFF2 (PPR48691A), TFF3 (PPR52672A), Muc1 (PPR51463A), Muc4 (PPR47950A), Nfkb1 (PPR42746A), and Pik3cg (PPR56854A) synthesized by SABioscience and the RT² Fast SYBR Green Master Mixes/fluorescein qPCR Master Mixes. For each of those primers, the standard curve was made to determine the best concentration of cDNA to use. Amplification was made in triplicate for each sample, and the internal control used was the lactate dehydrogenase A (*Ldha*) gene (PPR56603B). Amplification was made using the CFX96 thermocycler (BioRad, Marnes-la-Coquette, France): 1 cycle of 10 minutes at 95°C, followed by 45 cycles of 15 seconds at 95°C and 1 minute at 60°C.

pH-metry. A measurement of intragastric pH was performed using a pH meter orion 2 star (Thermoscientific, Brebieres, France), in 10 randomly selected rats of the DGER, LAP, and PPI groups after aspiration through a gastrotomy to assess the persistence of acid secretion (DGER group) or its suppression (PPI group).

RNA extraction and purification. Total RNA was isolated and purified from tissues using the NucleoSpin RNA L kit (Macherey-Nagel, Düren, Germany) as described in the manufacturer's protocol. The RNA quantity was determined by measuring the optical density at 260 nm with a NanoDrop 1000 spectrophotometer (Thermo Scientific, Pittsburgh, Penn).

Quantitative reverse transcriptase-polymerase chain reaction. Total RNA (0.5 μg) was used to prepare cDNA using the RT² First Strand Kit (SABioscience, Valencia, Calif). Quantitative reverse transcriptase-polymerase chain reaction (qRT-PCR) was performed on cDNA (1 μL), using specific primers for TFF2 (PPR48691A), TFF3 (PPR52672A), Muc1 (PPR51463A), Muc4 (PPR47950A), Nfkb1 (PPR42746A), and Pik3cg (PPR56854A) synthesized by SABioscience and the RT² Fast SYBR Green Master Mixes/fluorescein qPCR Master Mixes. For each of those primers, the standard curve was made to determine the best concentration of cDNA to use. Amplification was made in triplicate for each sample, and the internal control used was the lactate dehydrogenase A (*Ldha*) gene (PPR56603B). Amplification was made using the CFX96 thermocycler (BioRad, Marnes-la-Coquette, France): 1 cycle of 10 minutes at 95°C, followed by 45 cycles of 15 seconds at 95°C and 1 minute at 60°C.

RT-PCR. Total RNA (1 μg) was used to prepare cDNA using oligod(T) (1 μL) and recombinant Retro-Transcriptase Moloney Murine Leukemia Virus (1 μL ; Promega, Charbonnieres, France). PCR was performed on cDNA (5 μL), using specific pairs of primers: β -actin (sense: ATATCGCTGC GCTCGTCGTCGACAA; anti-sense: AACACAGCC TGGATGGCTACGTACAT), cyclin D1 (sense: TGA CTGCCGAGAAGTTGTG; anti-sense: GAGGGTG GGTGGAAATG), ErbB1 (sense: AGTGGTC CTTGCAAACCTTGG; anti-sense: TTAACCTCAAGCT GCCTCGCC), cyclo-oxygenase-2 (sense: AGTAT CAGAACCGCATGCCC; anti-sense: TAAGGTTT CAGGGAGAAGCG), PI3K (sense: GAAGCCATT GAGAAGAAAGGA; anti-sense: GAGGTGTTTCAG TATTATCAGAGC), NF- κ B (sense: GAAGAAGCGA GACCTGGAG; anti-sense: TCCGGAACACAATG GCCAC), Smad4 (sense: CATTCTGTGGCTTC CACAA; anti-sense: GACTGATGGCTGGAGCTATT)

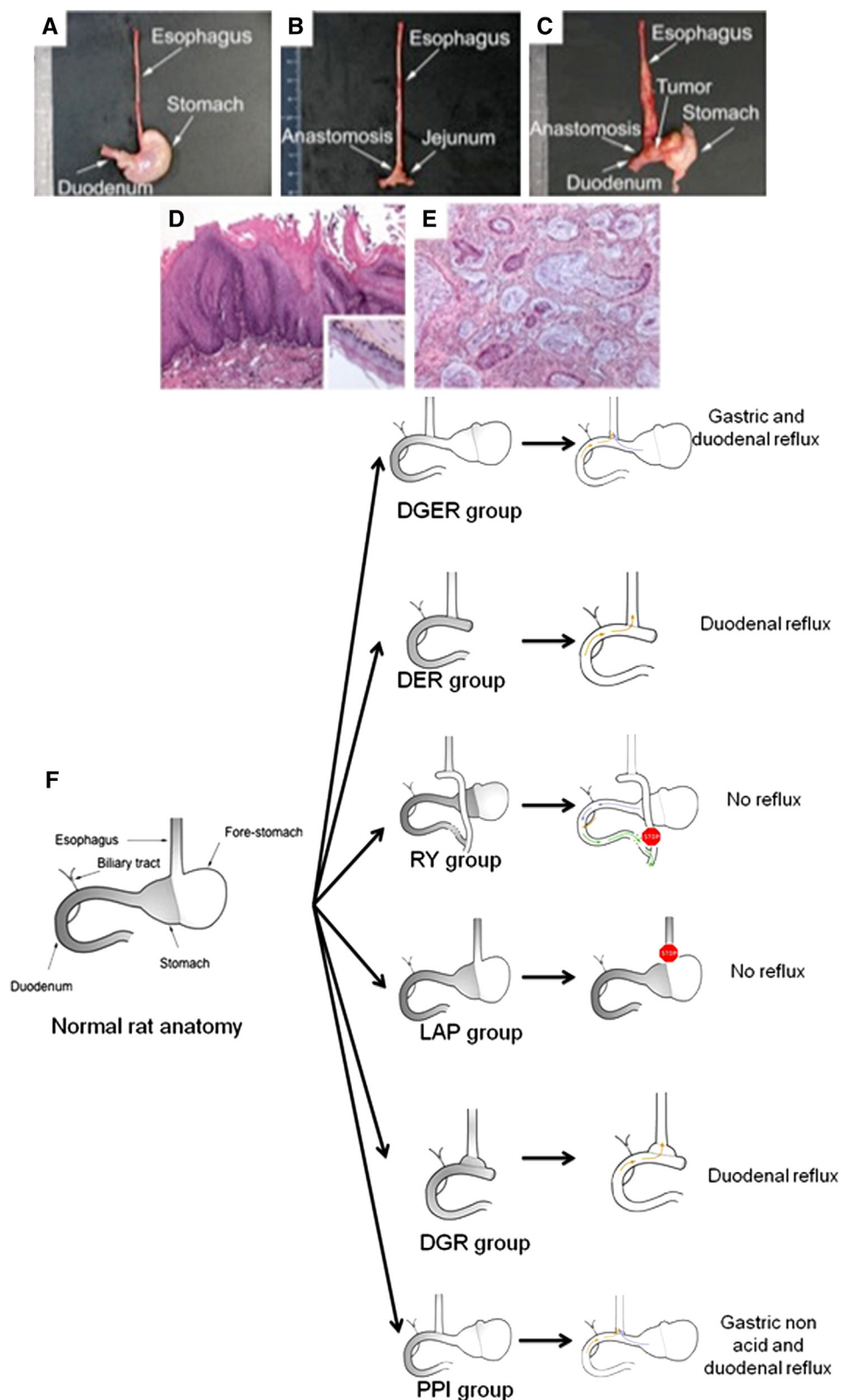


Fig 1. Macroscopic aspect of specimens classified according the operation group and histologic observation of the esophagus after operation using hematoxylin and eosin, Safran, and Astra blue stainings. The control groups with no reflux—(A) LAP and (B) RY groups—showed thin and noninflamed esophagus. (C) In the DGER group, the esophagi were dilated and inflamed, sometimes with the presence of a macroscopic tumor always localized in the distal

and vascular endothelial growth factor (sense: ACG AAA GCG CAA GAA ATC CC; anti-sense: TTA ACT CAA GCT GCC TCG CC; MWG-Biotech, Ebersberg, Germany). For each gene, analyses were made from ≥ 3 different rats. Rat β -actin was used as the internal control. PCR products (20 μ L) were separated on a 1.5% (w/v) agarose gel containing ethidium bromide run in 1X Tris Borate EDTA buffer. The gene of interest/ β -actin ratio was calculated after scanning DNA bands with GelAnalyst-GelSmart software (Clarivision, Verrieres Le Buisson, France).

Microarray analysis. Complementary RNA was synthesized from total RNA and purified using the TrueLabeling-AMP 2.0 Kit and the ArrayGrade cRNA Cleanup Kit respectively (SABioscience), together with biotin-UTP (Roche, Neuilly-sur-Seine, France) according to the manufacturer's instructions. Complementary RNA (2 μ g) was incubated with Oligo GEArrays (SABioscience)—Rat Cancer PathwayFinder, Rat Tumor Metastasis, Rat Cell Cycle, and Rat PI3K-AKT signaling pathway microarrays—all designed for profiling the expression of 113 genes. Expression level of each gene was detected by chemoluminescence using ECF substrate on a Storm 860 scanner (GE Healthcare Buckinghamshire, UK; IFR114/IMPRT, U. Lille 2). Signals were analyzed finally with the GEArray Expression Analysis Suite (SABioscience).

Immunohistochemistry. Protein expression was studied using either manual or automatic immunohistochemistry (IHC). Automatic IHC with an automated 8 immunostainer (ES, Ventana Medical System, Illkirch Graffenstaden, France). Antibodies were purchased from Cell Signaling (Danvers, Mass; cyclin D1 [2926 at 1/50e], Santa Cruz Biotechnology [Santa Cruz, Calif; MCM6 [sc-9845 at 1/100e], Mmp3 (sc-31074 at 1/100e), Mmp7 (sc-8832 at 1/50e), Mmp10 (sc-6842 at 1/200e), and Timp1 (sc-6834 at 1/100e)]. Positive controls were included by staining normal rat tissues known to express the protein of interest and negative controls were run with 1 \times D-PBS instead of primary antibodies.

Cell culture. The OE33 EA esophageal adenocarcinomatous cells were purchased from the

European Collection of Cell Culture and cultured as described in Mariette et al.¹⁴

Small interfering RNA assays. Parental OE33 cells were transfected with small interfering RNA (siRNA) from Dharmacon (Epsom, United Kingdom) following the protocol described by Piessen et al.¹⁵

Proliferation. Cell proliferation was analyzed by counting cells on a Malassez counting chamber. OE33 cells transfected with siRNA were plated on 24-well plates then counted during 3 days after transfection.

Migration. Cell migration was studied by a wound healing test. Cells were plated on 96-well plates until confluence; a "wound" was then performed using the 96-pin WoundMaker (Essen Bioscience, Ann Arbor, Mich). Plates were placed in an incubator with 5% of CO₂ at 37°C into the Incucyte device (Essen Bioscience). Every other hour, a picture of the wound was taken and the percentage of wound closure was then every 12 hours, from 0 to 48 hours.

Statistical analysis. The primary objective was the occurrence of ≥ 1 element of the carcinogenic sequence (either BE, dysplasia, or EA). Based on preliminary experiments and the literature, we hypothesized that with a power of 80% and an α value of 5%, ≥ 45 animals per experimental group (DGER and DER groups) were required to observe an incidence of 40% in 1 group versus 75% in the other group (bilateral comparison of 2 binomial proportions). Because intermediate analysis showed a mortality rate of $\leq 60\%$, the number of rats required per group was 120. Statistical analysis was performed using SPSS version 15.0 software (SPSS, Chicago, Ill). Data are shown as prevalence and mean values (standard deviation). Continuous data were compared by means of the Mann-Whitney *U* test and ordinal data by the Chi-square test or Fisher exact test as appropriate. All statistical tests were 2-sided.

RESULTS

Global evaluation. Among 285 rats operated, 120 were included in the DGER group and 120 in

portion of esophagus exposed to the reflux. The histologic observations showed (*D*) esophagitis (original magnification, $\times 200$). (*E*) Esophageal adenocarcinoma with the presence of mucus lakes stained in blue (black arrow; original magnification, $\times 200$) compared with (*D*, *insert*) normal esophagus (original magnification, $\times 200$). (*F*) Operative procedures and compositions of reflux for each group. DGER group, duodeno-gastro-esophageal reflux group allows the induction of a mixed gastric and duodenal reflux in the distal portion of the esophagus; DER group, duodeno-esophageal reflux only in the distal portion of the esophagus; RY group, internal control; LAP group, external control; DGR group, control for the DER group and PPI groups, which allows inhibition of acidic component of the gastric reflux.

Table I. Number of rats analyzed: Histologic analysis of resected esophagus of rats, analyzed according to the treatment group

Group	Experimental groups		Control groups			
	DGER group	DER group	DGR group	PPI group	RY group	LAP group
Reflux composition	Gastric duodenal	Duodenal	Duodenal	Gastric nonacid duodenal	No reflux	No reflux
No. of rats	63	45	6	10	7	10
Histologic results*						
Esophagitis	63 (100%)	45 (100%)	6 (100%)	10 (100%)	0 (0%)	0 (0%)
BE	23 (36%)	21 (47%)	1 (16%)	1 (10%)	0 (0%)	0 (0%)
Dysplasia	7 (11%)	0 (0%)	0 (0%)	0 (0%)	0 (0%)	0 (0%)
EA	8 (13%)	4 (9%)	1 (16%)	0 (0%)	0 (0%)	0 (0%)

*Some rats may exhibit concomitant steps of the carcinogenetic sequence.

BE, Barrett's esophagus; DER, duodeno-esophageal reflux; DGER, duodeno-gastro-esophageal reflux; DGR, duodeno-gastric reflux; EA, esophageal adenocarcinoma; LAP, laparotomy; PPI, proton pump inhibitor; RY, Roux-en-Y.

the DER group. The overall mortality rate was 53% and decreased during the study period from 68% to 37%; 55 rats died from respiratory failure owing to massive aspiration (none in the no-reflux groups). Other causes of death were malnutrition (loss of weight > 15%; n = 62), peritonitis (n = 9), intraoperative complications (n = 20), and unknown causes (n = 5). Number of survivors analyzed was 63 in the DGER group, 45 in DER the group, 6 in the DGR group, 10 in the PPI group, 7 in the RY group, and 3 in the LAP group.

Nutritional status. The body weight loss was $10 \pm 4\%$ and was maximal after 3 weeks. After an initial postoperative decrease, the curve of animal body weight joined progressively the one of the control group (data not shown), suggesting that nutritional status did not interfere with the results observed.

pH-metry. The mean values of the intragastric pH were 2.7 ± 0.4 , 2.8 ± 0.4 , and 5.1 ± 0.4 in the DGER, LAP, and PPI groups, respectively. This underlines the expected persistence of acid gastric secretion in the DGER group and a decrease in acid secretion after PPI administration ($P = .019$), which validates the models used to generate both duodenal and gastroduodenal refluxes.

Reflux lesions. In the LAP and RY groups (Fig 1, F), all rats had normal esophagus on macroscopic (Fig 1, A and B) and microscopic examination (Fig 1, D). In the DGER, DER, DGR, and PPI groups (Fig 1, F), the esophagus was dilated and markedly shortened in all rats, and microscopic analysis showed esophagitis (Fig 1, D). These results attest the efficacy of this chronic reflux model to induce esophagitis.

Steps of the carcinogenetic sequence. In the LAP and RY groups (Fig 1, A and B), no lesions of the carcinogenetic sequence were found. In the reflux groups,

32 animals exhibited visible tumor growth localized on the external surface of the esophagus (Fig 1, C).

Histologic analysis in the experimental groups showed at least 1 step of the carcinogenetic sequence in 50% of rats (Table I). Prevalence of BE, dysplasia, and cancer were 41% (n = 44), 8% (n = 9), and 11% (n = 12), respectively. Histologic lesions were always observed in the distal esophagus, which was the region with maximal exposure to reflux. Among 32 macroscopic tumors, only 12 were histologically proven carcinomas (Fig 1, E), the 20 remaining cases showing only a granulomatous inflammatory reaction. The positive predictive value of a macroscopic examination in predicting a cancerous lesion was only 38%. This finding suggests that exposure to chronic reflux promotes the development of elements of the carcinogenetic sequence in half of the animals.¹⁶

Histologic tumor characteristics. Among the proven carcinomas, 8 were well-differentiated, mucinous adenocarcinomas (malignant infiltrating glands associated with lakes of extracellular mucus; Fig 1, E). Five rats developed adenosquamous carcinomas combining components of squamous carcinoma and adenocarcinoma, but in all carcinomas, adenocarcinoma was the major component. Some of these cases exhibited vascular invasion, confirming their malignant nature. Neither lymph node nor distant metastases were identified macroscopically during necropsies. In rats with visible esophageal tumor growth, a systematic, histologic analysis of the liver and the lungs did not exhibit any micrometastatic dissemination. Even if features of local esophageal malignancy were present, these results challenge the ability of these tumors to metastasize.

Characterization of the intestinal lesions. The IHC analysis showed that intestine-specific markers

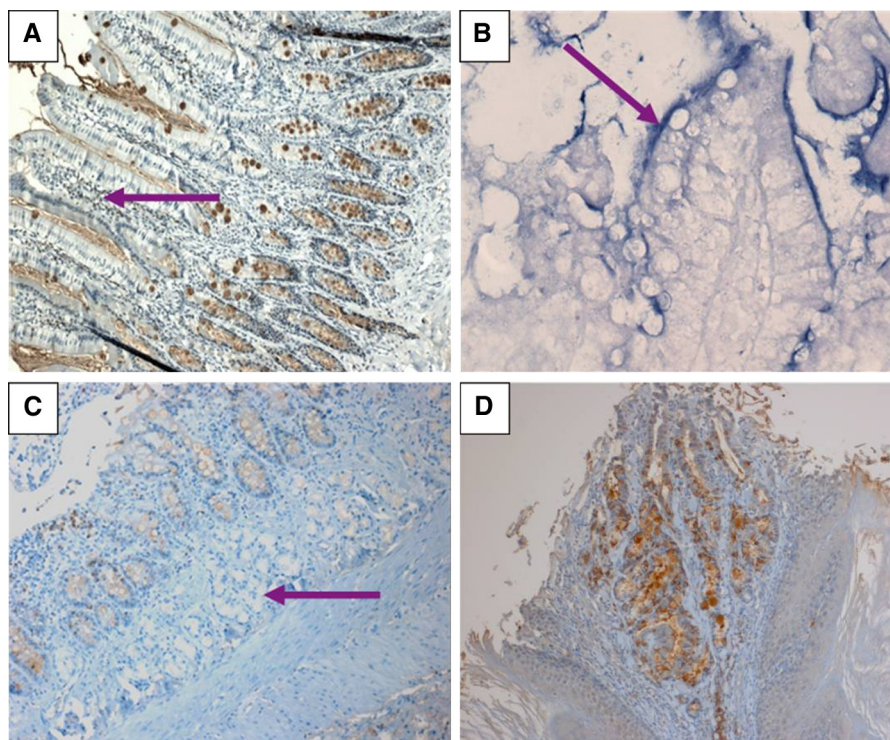


Fig 2. Histologic analyses showing the presence of intestinal tissue in the esophagus exposed to reflux. (A) Immunohistochemistry (IHC) using an anti-MUC2 antibody. (B) Lysozyme staining shows presence of villi (arrows). (C) IHC carried out with an anti-MUC4 antibody shows presence of Brunner's glands (arrow). (D) Typical aspects of entrapment characterized by a short segment of Barrett's esophagus surrounded by squamous mucosa. IHC staining was performed using an anti-MUC4 antibody. (A, original magnification, $\times 200$; B, original magnification, $\times 400$; C, D, original magnification, $\times 100$).

such as Villin, Cdx-2 (data not shown), and Muc2 [F2-4/C] (Fig 2, A), were expressed in BE, whereas they were never expressed in normal esophagus (data not shown). Expression of cytokeratins 4 (CK4) and 14 (CK14), known to participate in the cytoskeleton formation and usually found in normal esophageal epithelium, in the cytoplasm of the suprabasal cells for CK4 and of the basal cells for CK14, was also assessed. They were expressed in the histologically normal rat esophagus without expression in BE lesions (data not shown). These results confirm the differentiation of normal esophageal cells submitted to reflux into an intestinal-type phenotype mimicking human BE.

Origin of the intestinal mucosa. To investigate the origin of BE lesions observed in the reflux groups, we went expanded our histologic analysis. Villi and Brunner glands were present in the esophageal wall, 2 histologic characteristics of normal duodenum, usually not present in human BE (Fig 2, B and C). These results suggest that BE lesions in the ED rat model may not be true BE lesions originating de novo from the esophagus, but may be caused by mechanically induced

entrapment or creeping. To validate these, a histologic reassessment of rats with BE was performed. A short segment of BE surrounded by squamous mucosa corresponding to a typical aspect of entrapment was found in 1 rat (Fig 2, D). Second, another control group was constructed by performing a subtotal gastrectomy and gastroduodenal anastomosis (DGR group) in which the esophagus did not form part of the anastomosis. As presented in Table I, esophagitis was present in all these rats, confirming the presence of reflux. One rat developed a mucinous adenocarcinoma arising directly from the anastomotic site and located between the remaining stomach and lower esophagus with surrounding BE lesions. In the absence of histologic lesions in the esophagus, this group did not allow us to eliminate the hypothesis of creeping. Expression pattern of genes encoding trefoil factors (TFF) in BE had been shown previously to differ from that in normal jejunal mucosa in an EJ rat model,¹⁷ suggesting that BE lesions represented de novo BE and not creeping; therefore, we studied the expression of TFF-2 and TFF-3 mRNA

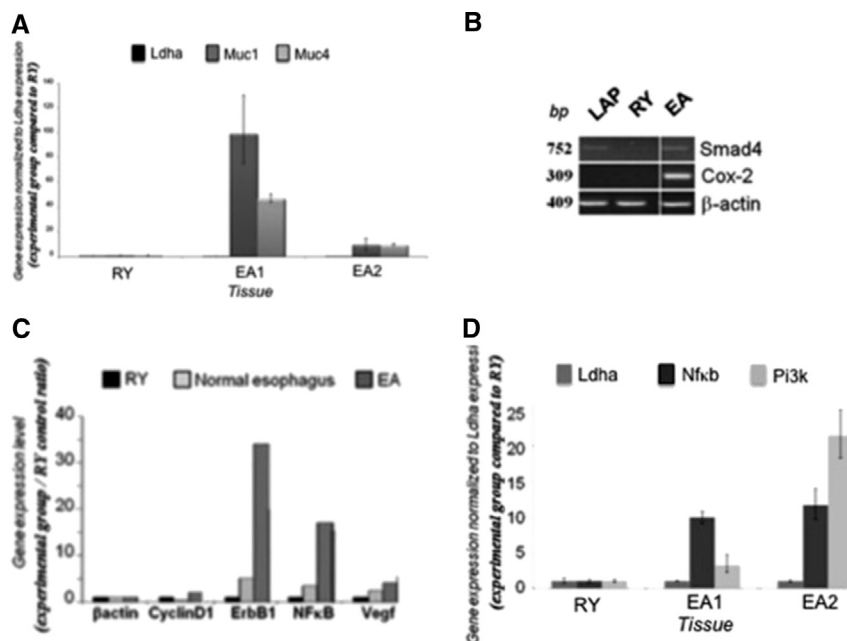


Fig 3. Gene expression in control squamous esophagus (Roux-en-Y [RY] and [LAP] groups) and in esophageal adenocarcinoma (EA). (A) Upregulation of *Muc1* and *Muc4* in EA compared with RY by quantitative reverse transcriptase-polymerase chain reaction (qRT-PCR). Expression levels are normalized to *Ldha* and compared with the RY group. (B) Neo-expression of *Smad4* and *Cox-2* in EA compared with RY and LAP groups by RT-PCR. (C) Upregulation of *cyclin D1*, *ErbB1*, *NF-κB*, and *Vegf* in EA compared with control groups using RT-PCR. The internal control used was β actin. (D) Activation of *Pi3k* and *NF-κB* associated with the tumor progression in esophagus subjected to reflux by qRT-PCR. Expression levels are normalized to *Ldha* and compared with the RY control. (E) Proliferation and (F) migration assays on OE33 cells transfected with *PI3K* or *NF-κB* small interfering RNA (siRNA). Controls are made by a transfection with a non-targeting (NT) siRNA or with the transfection agent alone (mock). * $P \leq .05$; ** $P \leq .005$.

by qRT-PCR in BE and normal duodenum. The expression of TFF-2 was more prominent in BE compared with duodenum (1,030-fold), whereas expression of TFF3 was more uniform in the tissues and was not discriminant (1.6 fold; data not shown). Altogether, these data suggest that, in this ED model, BE lesions may occur through various concomitant mechanisms, including de novo intestinal metaplasia and proximal migration of duodenum.

Characterization of the esophageal adenocarcinomatous lesions. We sought to evaluate the similarities of tumors found in humans and in this model. The expression of genes and proteins associated with EA tumorigenesis,^{18,19} and/or implicated in mediation of the effects of bile acid in EA²⁰ was compared in normal esophageal mucosa (no-reflux control groups) and in EA. Having previously shown that membrane-bound mucins MUC1 and MUC4 are overexpressed in human EA and that they are regulated by bile acids,^{15,20} we showed that genes encoding *Muc1* and *Muc4* mucins were overexpressed in EA (Fig 3, A), as

well as at the protein level (data not shown). We evaluated also expression of transcription factors associated with esophageal tumorigenesis²¹ or implicated in MUC1 or MUC4 regulation by bile acids,^{15,20} (Fig 3, B, C and D). A neo-expression of *Smad4* (transforming growth factor- β pathway) and cyclo-oxygenase-2 (inflammation) was observed in EA compared with RY controls (Fig 3, B). An increase of the cell-cycle factor cyclin D1 and the epidermal growth factor receptor *ErbB1* (cell proliferation), nuclear factor (NF)- κ B (inflammation), and vascular endothelial growth factor (angiogenesis) was also found (Fig 3, C). By qRT-PCR, we confirmed the activation of 2, central signaling pathways in EA tumor progression: *NF-κB* and *PI3K* (Fig 3, D). *Hnf-1α* and *Hnf-4α* transcription factors were not expressed in the esophagus of the RY and LAP groups, whereas nuclear expression was found in EA lesions. Nuclear expression of P63 protein was found in the esophageal epithelium of RY and LAP groups and was lost in EA (data not shown). Nuclear expression of Ki-67 (proliferation) was observed

[F3]

A

Gene	Description	GenBank	Fold expressed relative to control
Ccnd1	Cyclin D1	NM_171992	1.84
Mcm6	Mini chromosome maintenance deficient 6	U17565	1.59
Timp1	Tissue inhibitor of metalloproteinase 1	NM_053819	2.15
Mmp3	Matrix metalloproteinase 3	NM_133523	2.16
Mmp7	Matrix metalloproteinase 7	NM_012864	1.93
Mmp9	Matrix metalloproteinase 9	NM_031055	2.50
Mmp10	Matrix metalloproteinase 10	NM_133514	1.85
Mmp13	Matrix metalloproteinase 13	XM_343345	2.46
S100a4	S100 calcium binding protein A4	NM_012618	2.05
Htatip2	Similar to HIV-1 tat interactive protein 2, homolog	XM_214927	3.19
Tp53	Tumor protein p53	NM_030989	0.63
Tsg101	Tumor susceptibility gene 101	NM_181628	0.55
Pten	Phosphatase and tensin homolog	NM_031606	0.52
Chk2	Protein kinase Chk2	NM_053677	0.55
Casp9	Caspase 9	NM_031632	0.53
Wnt1	Wingless-type MMTV integration site family, member 1	XM_235639	0.68
Gsk3b	Glycogen synthase kinase 3 beta	NM_032080	0.95

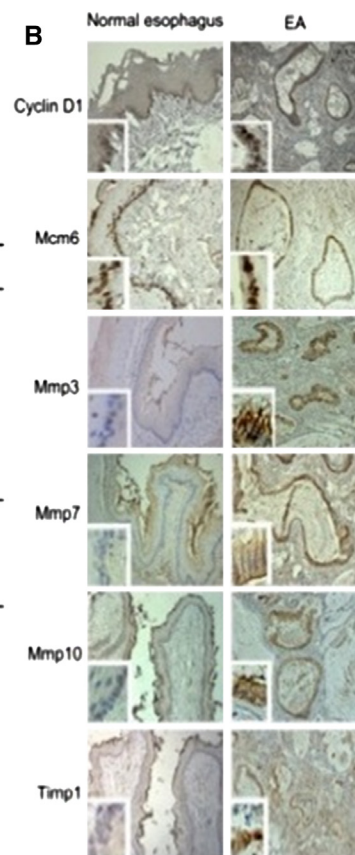


Fig 4. Expression of genes associated with tumorigenesis in esophagus subjected to reflux. (A) Expression of genes using microarrays. Average of 5 different rats showing esophageal adenocarcinoma lesions. (B) Expression of proteins (immunohistochemistry) for which genes were up-regulated in microarrays studies. Normal squamous esophagus (original magnification, $\times 100$); esophageal adenocarcinoma (original magnification, $\times 100$; insert, original magnification, $\times 200$).

in the basal layer of the normal esophageal epithelium in the RY and LAP groups and in EA lesions (data not shown). After studying genes known to participate in esophageal carcinogenesis, we then searched for new factors using a transcriptomic approach (Fig 4). As above, genes known to participate in proliferation (cyclin D1) and metastasis formation or invasion (Mmp3, -7, -9, -10, -13, the metalloproteinase-inhibitor Timp1) were up-regulated in EA. Conversely, tumor suppressor genes (Tp53, Tsg101, Pten) and genes participating in cell death (CHEK2, Caspase 9) were down-regulated (Fig 4, A). Alteration of gene expression was confirmed at the protein level by IHC for some of the markers (Fig 4, B). We then focused on 3 genes—CHEK2, TSG101, and MCM6—not yet known to participate in esophageal tumor progression, but known to play roles in epithelial tumorigenesis.²¹⁻²³ Using small interfering RNA approach, mRNA expression of CHECK, TSG101, and MCM6 was knocked down (KD) in OE33 cells

(Fig 5). Decreased proliferation was observed for the 3 KD cell lines as soon as day 2 for MCM6-KD cells (D2, $P = .0309$; D3, $P = .0019$) and as of day 3 for CHEK2-KD and TSG101-KD cells (D3, $P < .0056$ for both). No difference in cell migration was found in CHEK2-, TSG101-, or MCM6-KD cells compared with controls (Fig 5). These data indicate that tumor progression is induced by chronic reflux with activation of key signaling pathways and expression of tumor-associated proteins in a similar way in the DGER and DER groups. These results demonstrate that BE and EA present similar molecular characteristics in both experimental groups compared with humans.

Role of exposure time in esophageal carcinogenesis. The prevalence of histologic lesions did not differ between the different times of exposure to reflux (esophagitis, $P = .612$; BE, $P = .195$; dysplasia and EA, $P = .741$). No differences were found when comparing time of reflux exposure

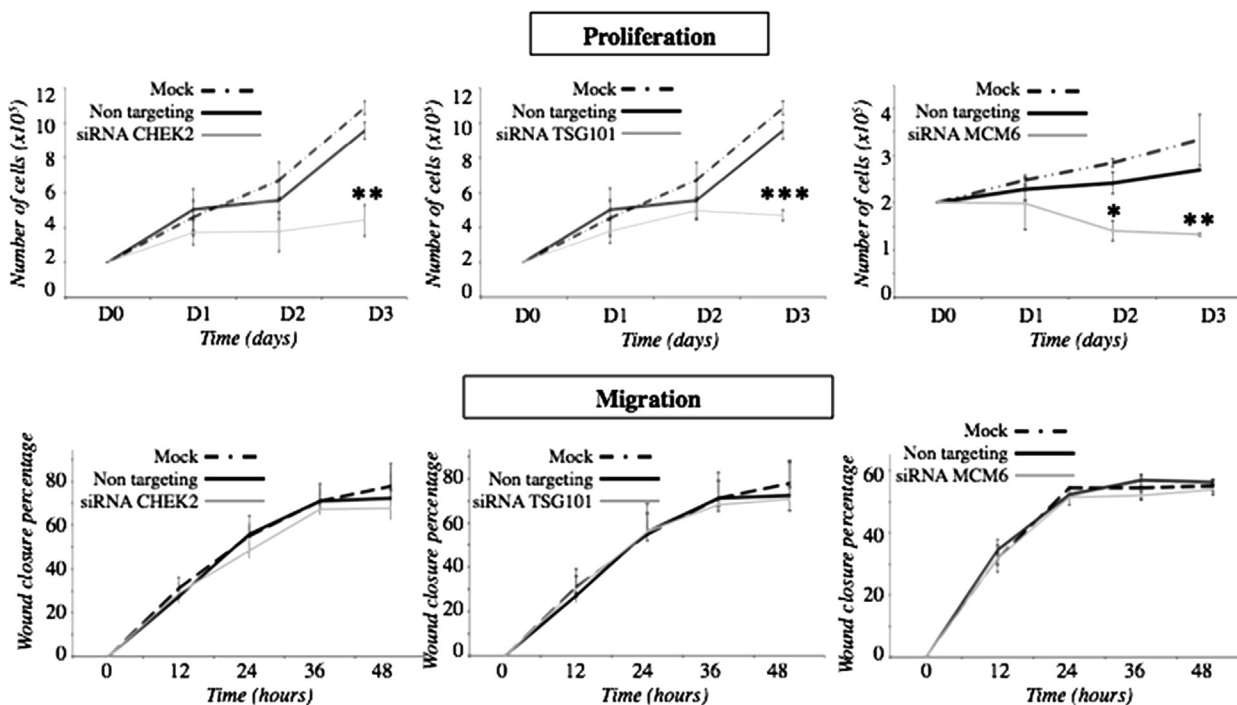


Fig 5. Proliferation and migration assays on OE33 cells transfected with MCM6, CHEK2, or TSG101 siRNA. Controls are made by a transfection with a non-targeting (NT) siRNA or with the transfection agent alone (mock). * $P \leq .05$; ** $P \leq .005$.

to promote ≥ 1 step of the carcinogenic sequence between the DGER and DER groups (median times, 50 [range, 22–68] vs 50 [22–83] weeks; $P = .789$; Table II). Subgroup analysis in the DGER and the DER groups showed similar results ($P = .741$). These findings suggest that esophageal carcinogenesis is not linked to exposure time to reflux and that delaying necropsy to >50 weeks is useless.

Role of the reflux composition on esophageal carcinogenesis. The proportion of rats who developed ≥ 1 step of the carcinogenic sequence did not differ between the 2 groups (49% vs 51%; $P = .841$). BE lesions were more frequent in the DER group compared with the DGER group (44 vs 24%; $P = .038$). Prevalence of dysplasia and/or EA lesions was less in the DER group (7%, vs 25%; $P = .012$). These results suggest that the duodenal component of the reflux may play an initiating role in the carcinogenic sequence, whereas duodenogastric juice may lead to progression of the carcinogenic sequence to EA.

Impact of acid component of gastric reflux. To determine the role of acid component in these findings, the control PPI group ($n = 10$) was constructed. Macroscopic and histologic results are presented in Table I. At 30 weeks, the esophageal macroscopic appearance was similar in the

PPI ($n = 10$) and in the DGER groups ($n = 19$), with esophagitis present in all rats. At least 1 step of the carcinogenic sequence was observed more frequently in the DGER group (58%) compared with the PPI group (10%; $P = .019$). These results suggest that the acidic reflux may favor progression of the carcinogenic sequence toward EA.

DISCUSSION

Our rat model using either ED or EJ anastomosis is considered the most promising model for reproducing histologic lesions mimicking the human EA carcinogenic sequence,³ but few groups have characterized the lesions that develop at both the histologic and molecular levels.^{8,13,24,25} This lack of in-depth characterization of this frequently used model led us to determine whether the rat model reliably and accurately reproduces the carcinogenic sequence as occurs in humans.^{8,12}

We demonstrated herein that the ED rat model of reflux allows the development of metaplasia-like lesions (BE) and its transformation into dysplasia and EA with similar histologic and molecular characteristics described in humans. We showed that the duodenal component of the reflux plays a crucial role in initiating the carcinogenic sequence, whereas duodenogastric juice may lead

Table II. Distribution of histologic lesions according to the duration of reflux exposure in rats

Reflux group	Time of exposure to reflux (in weeks)					
	21–30		30–50		50–83	
	DGER group	DER group	DGER group	DER group	DGER group	DER group
Histologic results						
Esophagitis only	6 (50%)	2 (25%)	11 (55%)	9 (64%)	15 (48%)	11 (48%)
BE only	3 (25%)	5 (62%)	4 (20%)	4 (28%)	8 (26%)	11 (48%)
Dysplasia or EA	3 (25%)	1 (13%)	5 (25%)	1 (8%)	8 (26%)	1 (4%)
Total	12 (100%)	8 (100%)	20 (100%)	14 (100%)	31 (100%)	23 (100%)

BE, Barrett's esophagus; EA, esophageal adenocarcinoma.

to its progression to EA. Many discrepancies, however, have been highlighted in the literature when comparing human observations with previous animal models,^{1,5-10} including the development of benign tumor and adenocarcinomas observed rarely in humans, a low rate of EA tumorigenesis despite deliberate esophageal exposure to extensive gastroesophageal reflux, and no apparent impact of duration of the exposure on the incidence of BE/EA. The absence of any tumoral dissemination to regional lymph nodes or distant organs also questions whether the induced malignancies behave in an aggressive manner. It has also been questioned whether creeping of the duodenal mucosa or entrapment of the jejunal mucosa may be the mechanisms to be involved in the development of BE rather than a de novo process. As reported by others,^{8,9} the high postoperative mortality despite the well-known expertise of the surgical team raised ethical concerns and questioned the reproducibility of such modeling.

In humans, BE metaplasia is thought to result from the abnormal differentiation of esophageal stem cells or from the transdifferentiation of 1 mature esophageal cell type into another type of mature cell.²⁶ The gene expression profile of TFF in a rodent model with EJ anastomosis suggests that BE occurs de novo and is not owing to proximal migration of jejunal mucosa.¹⁷ Brunner glands in the DRG group and observation of short segments of BE surrounded by squamous mucosa suggest that BE-like lesions in the rat model could arise also from duodenal mucosa through entrapment or creeping in accordance with previous studies.^{8,9} Only a formal lineage tracing would allow to solve this question definitively. Contrary to our results, some investigators^{7,9,11} have suggested that the time of exposure to reflux may determine the type and incidence of lesions that develop; however, the number of rats operated on in each of those studies was relatively small.^{6,8,11}

The incidence of EA in the present study was low (13%) with some adenocarcinomas occurring despite avoiding the use of nitrosamines, a co-carcinogen shown to be responsible for high rates of a squamous cell tumoral component.²⁷ A review has discussed the reproducibility of the rat model²⁸ with regard to (i) the variability of the operative procedures, with a greater rate of EA after EJ than after ED anastomosis,^{3,13} possibly because of a lesser volume of refluxate in the latter type of anastomosis,²⁹ (ii) the various durations of reflux, (iii) the use of a variety of rat species, and (iv) the suboptimal pathologic analysis of induced lesions.⁸

Analysis of the transcriptome allowed us to identify genes that had been shown to previously be important in human EA, corroborating the validity of this model.^{15,30,31} Moreover, this analysis allowed us to identify novel, potential biomarkers involved in esophageal carcinogenesis. First, the *S100a4* gene, whose protein is known to have many roles in cancer cell properties, was upregulated.³² We reported previously that altered properties of OE33 esophageal cancer cells deficient for MUC4 mucin correlated with that of the calcium-binding protein s100A4,² suggesting that regulation of S100A4 by the membrane-bound mucin MUC4 would lead to decreased proliferation and migration of esophageal cancer cells.

MCM6 and CHEK2, both involved in cell proliferation, were up regulated in our transcriptomic study, and activity on cell proliferation was confirmed in vitro. MCM6 has been shown previously to be involved in meningioma, and its expression was correlated with clinical outcomes and grade of the tumor.²¹ As for CHEK2, a gene mutation has been associated with an increased risk of breast cancer.²² Altogether, our results and those in the literature suggest strongly that MCM6 and CHEK2 may play an important roles in the properties of esophageal adenocarcinomatous cells as well as in esophageal carcinogenesis.

Tsg101 was shown previously to decrease proliferation in breast cancer.²³ Accordingly, our results in esophageal cancer cells deficient for Tsg101 showed decreased proliferation, suggesting that Tsg101 is a new and interesting marker for further study in that type of cancer.

The respective contributions of the duodenal and gastroduodenal reflux on the development of BE and EA remain controversial.^{5,7,9,12} We wanted to evaluate the impact of the gastric and the duodenal contents on the carcinogenic sequence. The pH of gastric juice has been shown previously to be neutralized when an EJ anastomosis is performed without gastrectomy³³; therefore, we chose to perform an ED anastomosis.^{6,28} We showed that absence of gastric juice (DER group) was associated with significantly earlier lesions of BE, whereas combined gastric and duodenal reflux (DGER group) was associated with more advanced lesions (dysplasia and EA). A control group of rats exposed to mixed reflux and receiving pharmacologic acid suppression (PPI group) confirmed this mechanism with a dramatic decrease in the number of early lesions. Confirming data reported previously using a cellular model of EA, these results suggest a distinct impact of the duodenal reflux according to pH environment,³⁴ which suggests that PPIs may prevent initiation of the carcinogenic sequence with a protective effect. These results are in accordance with a recently published study,³⁵ but contrary to another³⁶ in which a PPI was administered subcutaneously on alternative days without verification of acid suppression by pH measurements.

Gastric content may act as a catalyst for the carcinogenic process favoring tumor development. When comparing our data with published results from previous, similar rat studies comparing DGER and DER, 3 of 4 studies did not show any differences between groups regarding the occurrence BE or EA but with small number of animals enrolled and lesions not related to reflux.^{7,9,12} The fourth study suggested a protective effect of gastric juice against the development of EA.⁵

For ethical reasons, we chose to include a limited number of rats in the control groups. In the PPI group, we performed a preliminary analysis at 30 weeks. Because the results were significant, it did not seem ethically valid to continue the study.

In conclusion, despite pathophysiologic differences with humans, the rat ED model reproduces accurately histologic and molecular lesions of the BE carcinogenic sequence and allowed us

to identify potential tumor-associated proteins that may prove to be new biomarkers and new therapeutic targets in EA. This rat ED anastomosis model offers a unique opportunity to study the respective roles of the duodenal and gastroduodenal contents in the BE carcinogenic sequence.

C.G. and E.B. equally contributed to the work. I.V.S. and C.M. equally contributed to the work. Supported by La Fondation pour l'Avenir and La Fondation pour la Recherche Médicale (Equipe FRM 2009). Emilie Bruyère is the recipient of a PhD Fellowship from Le Centre Hospitalier Régional Universitaire de Lille and Région Nord-Pas de Calais. Isabelle Van Seuning is the recipient of a "Contrat Hospitalier de Recherche Translationnelle"/CHRT 2010, AVIESAN.

The authors thank Dr Jean-Noël Freund (Inserm U782, Strasbourg) for scientific discussions. We thank also Dr William B Robb for critical reading of this manuscript. This work was supported by grants from CHRU de Lille, Région Nord-Pas-de-Calais, La Fondation de l'Avenir and La Fondation pour la Recherche Médicale (EQUIPE FRM 2009) and AVIESAN (CHRT 2010, IVS).

REFERENCES

1. Mariette C, Piessen G, Briez N, Gronnier C, Triboulet JP. Oesophagogastric junction adenocarcinoma: which therapeutic approach? *Lancet Oncol* 2011;12:296-305.
2. Hamilton SR, Smith RR. The relationship between columnar epithelial dysplasia and invasive adenocarcinoma arising in Barrett's esophagus. *Am J Clin Pathol* 1987;87:301-12.
3. Moore KH, Barry P, Burn J, Falk G. Adenocarcinoma of the rat esophagus in the presence of a proton pump inhibitor: a pilot study. *Dis Esophagus* 2001;14:17-22.
4. Levrat M, Lambert R, Kirshbaum G. Esophagitis produced by reflux of duodenal contents in rats. *Am J Dig Dis* 1962;7:564-73.
5. Ireland AP, Peters JH, Smyrk TC, DeMeester TR, Clark GW, Mirvish SS, et al. Gastric juice protects against the development of esophageal adenocarcinoma in the rat. *Ann Surg* 1996;224:358-70.
6. Goldstein SR, Yang GY, Curtis SK, Reuhl KR, Liu BC, Mirvish SS, et al. Development of esophageal metaplasia and adenocarcinoma in a rat surgical model without the use of a carcinogen. *Carcinogenesis* 1997;18:2265-70.
7. Fein M, Peters JH, Chandrasoma P, Ireland AP, Oberg S, Ritter MP, et al. Duodeno-esophageal reflux induces esophageal adenocarcinoma without exogenous carcinogen. *J Gastrointest Surg* 1998;2:260-8.
8. Buskens CJ, Hulscher JB, van Gulik TM, Ten Kate FJ, van Lanschot JJ. Histopathologic evaluation of an animal model for Barrett's esophagus and adenocarcinoma of the distal esophagus. *J Surg Res* 2006;135:337-44.
9. Miwa K, Segawa M, Takano Y, Matsumoto H, Sahara H, Yagi M, et al. Induction of esophageal and forestomach carcinomas in rats by reflux of duodenal contents. *Br J Cancer* 1994;70:185-9.
10. Li H, Walsh TN, O'Dowd G, Gillen P, Byrne PJ, Hennessy TP. Mechanisms of columnar metaplasia and squamous

- 1483 regeneration in experimental Barrett's esophagus. *Surgery* 1994;115:176-81.
- 1484
- 1485 11. Pera M, Brito MJ, Poulson R, Riera E, Grande L, Hanby A, et al. Duodenal-content reflux esophagitis induces the development of glandular metaplasia and adenocarcinoma in rats. *Carcinogenesis* 2000;21:1587-91.
- 1486
- 1487
- 1488 12. Oberg S, Wenner J, Johansson J, Walther B, Willén R. Barrett esophagus: risk factors for progression to dysplasia and adenocarcinoma. *Ann Surg* 2005;242:49-54.
- 1489
- 1490
- 1491 13. Bonde P, Sui G, Dhara S, Wang J, Broor A, Kim IF, et al. Cytogenetic characterization and gene expression profiling in the rat reflux-induced esophageal tumor model. *J Thorac Cardiovasc Surg* 2007;133:763-9.
- 1492
- 1493
- 1494 14. Mariette C, Piessen G, Leteurtre E, Hémon B, Triboulet JP, Van Seuning I. Activation of MUC1 mucin expression by bile acids in human esophageal adenocarcinomatous cells and tissues is mediated by the phosphatidylinositol 3-kinase. *Surgery* 2008;143:58-71.
- 1495
- 1496 15. Piessen G, Jonckheere N, Vincent A, Hémon B, Ducourouble MP, Copin MC, et al. Regulation of the human mucin MUC4 by taurodeoxycholic and taurochenodeoxycholic bile acids in oesophageal cancer cells is mediated by hepatocyte nuclear factor 1alpha. *Biochem J* 2007;402:81-91.
- 1497
- 1498 16. Macke RA, Nason KS, Mukaisho K, Hattori T, Fujimura T, Sasaki S, et al. Barrett's esophagus and animal models. *Ann N Y Acad Sci* 2011;1232:392-400.
- 1499
- 1500 17. Oh DS, DeMeester SR, Dunst CM, Mori R, Lehman BJ, Kuramochi H, et al. Validation of a rodent model of Barrett's esophagus using quantitative gene expression profiling. *Surg Endosc* 2009;23:1346-52.
- 1501
- 1502 18. Fitzgerald RC. Molecular basis of Barrett's oesophagus and oesophageal adenocarcinoma. *Gut* 2006;55:1810-20.
- 1503
- 1504 19. Zagorowicz E, Jankowski J. Molecular changes in the progression of Barrett's oesophagus. *Postgrad Med J* 2007;83:529-35.
- 1505
- 1506 20. van der Sluis M, Melis MH, Jonckheere N, Ducourouble MP, Büller HA, Renes I, et al. The murine Muc2 mucin gene is transcriptionally regulated by the zinc-finger GATA-4 transcription factor in intestinal cells. *Biochem Biophys Res Commun* 2004;325:952-60.
- 1507
- 1508 21. Gauchotte G, Vigouroux C, Rech F, Battaglia-Hsu SF, Soudant M, Pinelli C, et al. Expression of minichromosome maintenance MCM6 protein in meningiomas is strongly correlated with histologic grade and clinical outcome. *Am J Surg Pathol* 2012;36:283-91.
- 1509
- 1510 22. Vahteristo P, Bartkova J, Eerola H, Syrjäkoski K, Ojala S, Kilpivaara O, et al. A CHEK2 genetic variant contributing to a substantial fraction of familial breast cancer. *Am J Hum Genet* 2002;71:432-8.
- 1511
- 1512 23. Zhang Y, Song M, Cui ZS, Li CY, Xue XX, Yu M, et al. Down-regulation of TSG101 by small interfering RNA inhibits the proliferation of breast cancer cells through the MAPK/ERK signal pathway. *Histol Histopathol* 2011;26:87-94.
- 1513
- 1514
- 1515 24. Bruyère E, Jonckheere N, Frénois F, Mariette C, Van Seuning I. The MUC4 membrane-bound mucin regulates esophageal cancer cell proliferation and migration properties: Implication for S100A4 protein. *Biochem Biophys Res Commun* 2011;413:325-9.
- 1516
- 1517 25. Su Y, Chen X, Klein M, Fang M, Wang S, Yang CS, et al. Phenotype of columnar-lined esophagus in rats with esophagoduodenal anastomosis: similarity to human Barrett's esophagus. *Lab Invest* 2004;84:753-65.
- 1518
- 1519 26. Eberhard D, Tosh D. Transdifferentiation and metaplasia as a paradigm for understanding development and disease. *Cell Mol Life Sci* 2008;65:33-40.
- 1520
- 1521 27. Mirvish SS. Studies on experimental animals involving surgical procedures and/or nitrosamine treatment related to the etiology of esophageal adenocarcinoma. *Cancer Lett* 1997;117:161-74.
- 1522
- 1523 28. Attwood SE, Harrison LA, Preston SL, Jankowski JA. Esophageal adenocarcinoma in "mice and men": back to basics!. *Am J Gastroenterol* 2008;103:2367-72.
- 1524
- 1525 29. Sato T, Miwa K, Sahara H, Segawa M, Hattori T. The sequential model of Barrett's esophagus and adenocarcinoma induced by duodeno-esophageal reflux without exogenous carcinogens. *Anticancer Res* 2002;22:39-44.
- 1526
- 1527 30. Song S, Guha S, Liu K, Buttar NS, Bresalier RS. COX-2 induction by unconjugated bile acids involves reactive oxygen species-mediated signalling pathways in Barrett's oesophagus and oesophageal adenocarcinoma. *Gut* 2007;56:1512-21.
- 1528
- 1529 31. Langer R, Von Rahden BH, Nahrig J, Von Weyhern C, Reiter R, Feith M, et al. Prognostic significance of expression patterns of c-erbB-2, p53, p16INK4A, p27KIP1, cyclin D1 and epidermal growth factor receptor in oesophageal adenocarcinoma: a tissue microarray study. *J Clin Pathol* 2006;59:631-4.
- 1530
- 1531 32. Sherbet GV, Lakshmi MS. S100A4 (MTS1) calcium binding protein in cancer growth, invasion and metastasis. *Anticancer Res* 1998;18:2415-21.
- 1532
- 1533 33. Fein M, Fuchs KH, DeMeester TR, Peters JH, Wittmann D, Weig M. Evaluation of the intestinal microflora in the rat model for esophageal adenocarcinoma. *Dis Esophagus* 2000;13:39-43.
- 1534
- 1535 34. Kaur BS, Ouatu-Lascar R, Omary MB, Fang M, Wang S, Yang CS, et al. Bile salts induce or blunt cell proliferation in Barrett's esophagus in an acid-dependent fashion. *Am J Physiol Gastrointest Liver Physiol* 2000;278:1000-9.
- 1536
- 1537 35. Miyashita T, Shah FA, Marti GP, Wang J, Bonde P, Gibson MK, et al. Rabeprazole impedes the development of reflux-induced esophageal cancer in a surgical model. *Dig Dis Sci* 2011;56:1309-14.
- 1538
- 1539 36. Nasr AO, Dillon MF, Conlon S, Downey P, Chen G, Ireland A, et al. Acid suppression increases rates of Barrett's esophagus and esophageal injury in the presence of duodenal reflux. *Surgery* 2012;15:382-90.
- 1540
- 1541
- 1542
- 1543
- 1544

AUTHOR QUERY FORM

 ELSEVIER	Journal: YMSY Article Number: 3448	
--	---	--

Dear Author,

Please check your proof carefully and mark all corrections at the appropriate place in the proof (e.g., by using on-screen annotation in the PDF file) or compile them in a separate list. Note: if you opt to annotate the file with software other than Adobe Reader then please also highlight the appropriate place in the PDF file. To ensure fast publication of your paper please return your corrections within 48 hours.

For correction or revision of any artwork, please consult <http://www.elsevier.com/artworkinstructions>.

Any queries or remarks that have arisen during the processing of your manuscript are listed below and highlighted by flags in the proof.

Location in article	Query / Remark: Click on the Q link to find the query's location in text Please insert your reply or correction at the corresponding line in the proof
Q1 Q2 Q3 EQ1	<p>If there are any drug dosages in your article, please verify them and indicate that you have done so by initialing this query</p> <p>Please check heading levels throughout to ensure that they are correct.</p> <p>Please confirm that given names and surnames have been identified correctly.</p> <p>For figure 3A/D, the resolution is too low to be used. Please provide better quality figure of 300 dpi.</p> <p>Figure 5: ‘***’ not defined at caption. Kindly check and provide.</p> <div data-bbox="304 1330 895 1508" style="border: 1px solid black; padding: 5px;"> <p style="color: red;">Please check this box or indicate your approval if you have no corrections to make to the PDF file</p> <div style="display: inline-block; border: 1px solid black; width: 30px; height: 30px; vertical-align: middle;"></div> </div>

Thank you for your assistance.