HAL open science

Hydrocephalus and Chiari malformation pathophysiology in FGFR2-related faciocraniosynostosis: A review

G. Coll, Youssef El Ouadih, F. Abed Rabbo, V. Jecko, L. Sakka, F. Di Rocco

To cite this version:

G. Coll, Youssef El Ouadih, F. Abed Rabbo, V. Jecko, L. Sakka, et al.. Hydrocephalus and Chiari malformation pathophysiology in FGFR2-related faciocraniosynostosis: A review. Neurochirurgie, 2019, 65 (5), pp.264-268. 10.1016/j.neuchi.2019.09.001 . hal-02903593

HAL Id: hal-02903593

https://hal.science/hal-02903593v1

Submitted on 21 Dec 2021

HAL is a multi-disciplinary open access archive for the deposit and dissemination of scientific research documents, whether they are published or not. The documents may come from teaching and research institutions in France or abroad, or from public or private research centers.

L'archive ouverte pluridisciplinaire **HAL**, est destinée au dépôt et à la diffusion de documents scientifiques de niveau recherche, publiés ou non, émanant des établissements d'enseignement et de recherche français ou étrangers, des laboratoires publics ou privés.

Distributed under a Creative Commons Attribution - NonCommercial 4.0 International License

Version of Record: https://www.sciencedirect.com/science/article/pii/S0028377019302115
Manuscript_9c1a4741aab031d85284cfa1b33897ea

Hydrocephalus and Chiari malformation pathophysiology in FGFR2-related faciocraniosynostosis: a review.

Guillaume Coll[1,2], Youssef El Ouadih[1], Francis Abed Rabbo[1], Vincent Gecko[3], Laurent Sakka[1,4], Federico Di Rocco[5,6]

1. *Service de Neurochirurgie, CHU Clermont-Ferrand, Clermont-Ferrand, F-63000, France*
2. *Clermont Auvergne University CNRS, SIGMA, Institut Pascal, Clermont-Ferrand, France.*
3. *Service de Neurochirurgie, CHU Bordeaux, Bordeaux, France*
4. *Laboratoire d'Anatomie et d'Organogenèse, Laboratoire de Biophysique Sensorielle, NeuroDol, Faculté de Médecine, Université Clermont Auvergne, F-63000 Clermont-Ferrand, France*
5. *Service de Neurochirurgie Pédiatrique, Hôpital Femme Mère Enfant, Lyon, France*
6. *Université Claude Bernard, INSERM 1033, Lyon, France*

Correspondence: Dr Guillaume Coll
Service de Neurochirurgie,
Hôpital Gabriel-Montpied,
B.P. 69,
58 Rue Montalembert
63003 Clermont-Ferrand, France.
Tel: +33.6.88.10.67.20
e-mail: gcoll@chu-clermontferrand.fr

Disclosure of funding: The authors have no personal financial or institutional interest in any of the drugs, materials, or devices described in this article.

© 2019 published by Elsevier. This manuscript is made available under the CC BY NC user license
https://creativecommons.org/licenses/by-nc/4.0/

ABSTRACT

Background: Patients with syndromic faciocraniosynostosis due to the mutation of the fibroblast growth factor receptor (FGFR) 2 gene present premature fusion of the coronal sutures and of the cranial base synchondrosis. Cerebrospinal fluid (CSF) circulation disorders and cerebellar tonsil prolapse are frequent findings in faciocraniosynostosis.

Objective: We reviewed the medical literature on the pathophysiological mechanisms of CSF disorders such as hydrocephalus and of cerebellar tonsil prolapse in FGFR2-related faciocraniosynostosis.

Discussion: Different pathophysiological theories have been proposed, but none elucidated all the symptoms present in Apert, Crouzon and Pfeiffer syndromes. The first theory that addressed CSF circulation disruption was the constrictive theory (cephalocranial disproportion): cerebellum and brain stem are constricted by the small volume of the posterior fossa. The second theory proposed venous hyperpressure due to jugular foramens stenosis. The most recent theory proposed a pressure differential between CSF in the posterior fossa and in the vertebral canal, due to foramen magnum stenosis.

Keywords: Complex craniosynostosis, Hydrocephalus, Chiari, Crouzon, Apert, Pfeiffer

INTRODUCTION

Craniostenosis refers to premature closure of the cranial suture. Incidence is estimated at between 1 per 2,100 and 1 per 2,500 births [1]. While the vast majority of craniostenoses involve only one of the cranial sutures [2], children with syndromic faciocraniostenosis, such as Apert, Crouzon-Pfeiffer, Muenke or Saethre Chotzen syndromes, usually have premature fusion of one or two coronal sutures but also of the sutures of the skull and synchondroses of the skull base [3,4]. Mutations in the gene coding for fibroblast growth factor receptor 2 (FGFR2) may be responsible for the various syndromes, according to the type of amino acid alterations, such as Crouzon, Apert or Pfeiffer syndromes but also McGillivray family scaphocephalia, lacrimotorino-dento-digital, Antley-Bixler, cutis gyrata-acanthosis nigricans-craniosynostosis, or Jackson-Weiss syndromes [2,5,6]. The association between CSF disorder, cerebellar tonsil prolapse and syndromic craniosynostosis is frequent and well-documented, especially for the Crouzon, Apert and Pfeiffer syndromes. For instance, 30% to 70% of children with Crouzon or Pfeiffer syndrome [7–10] and 40 to 90% of children with Apert syndrome show ventriculomegaly [10–12]. This increase in volume results in progressive ventriculomegaly, requiring neurosurgical treatment [13]. Hydrocephalus, defined as an increase in the volume occupied by the CSF with an increase in intracranial pressure, is also common [10]. 9% to 17% of patients with Crouzon syndrome, 28-64% of those with Pfeiffer syndrome and 4-7% of those with Apert syndrome have authentic hydrocephalus [7–9,11,12,14–16] . A previous article reported hydrocephalus in 29% of children with Crouzon syndrome and 33% with Pfeiffer syndrome [10]; all syndromes were FGFR-2 induced and genetically confirmed. No children with Apert syndrome had an active fluid disorder [10]. Discrepancies in percentages for Pfeiffer syndrome in most

series probably come from the difficulty of clinically differentiating between different forms of faciocraniostenosis, such as Crouzon, Jackson-Weiss and Pfeiffer syndrome, in the absence of genetic mutation analysis. This problem is absent in Apert syndrome thanks to its morphological characteristics (syndactyly); which explains the small percentage discrepancy between reports.

Despite new classifications for Chiari malformation [17], the present study focused on Chiari type-I malformation, which we prefer to call ectopia of the cerebellar tonsils (ECT). It is defined as >5 mm protrusion of the cerebellar tonsils under the basion-opisthion plane, and is found in 70% of Crouzon, 50% of Pfeiffer and 1.9% of Apert syndromes [18,19].

METHOD

Three literature searches were conducted on PubMed. The first used the following keywords: fibroblast growth factor type 2 receptor, craniosynostoses, hydrocephalus. The second used: fibroblast growth factor type 2 receptor, craniosynostoses, Chiari. The third used: fibroblast growth factor type 2 receptor, posterior fossa. Respectively 12, 9 and 7 articles were retrieved, and were all analyzed. The complete reference lists of all 28 articles were exhaustively analyzed.

PATHOPHYSIOLOGY OF FLUID DISORDER

Several theories have been developed in recent years to explain fluid disorders in syndromic craniosynostosis.

1.Constrictive theory

According to constrictive theory, a small posterior fossa results in a mechanical increase in resistance to the flow of cerebrospinal fluid (CSF). This postulate was based on the finding, in children with craniosynostosis and active CSF disorder, of an association between compressed subarachnoid spaces in the posterior fossa and a small "Chiari like" 4th ventricle anomaly [7,13,20–23]. This posterior fossa constriction was first referred to in 1976 by Hoffman and Tucker as “cephalocranial disproportion” [24]. Hydrocephalus would in that case be the consequence of progressive blocking of the subarachnoid spaces secondary to insufficient posterior fossa development compared to cerebellar growth [7,25]. It was hypothesized that, in reduced 4th ventricle volume, these posterior fossa modifications impacted Sylvius aqueduct permeability [8,9,13]; but MRI studies generally reported an open aqueduct for patients with Crouzon, Apert or Pfeiffer syndrome [7,13,20,22]. Reduced posterior fossa volume was demonstrated on isotopic cisternography [26] and several volumetric studies [27,28]. Sgouros et al. showed that the posterior fossa was smaller in the first 2 years of life in both girls and boys with craniosynostosis: the posterior fossa had a smaller anterior posterior diameter but greater width [27]. In 2015, we compared the volumes of the posterior fossa and the cerebellum (figure 1) between children suffering from FGFR2-induced craniosynostosis (14 Crouzon, 6 Pfeiffer and 11 Apert syndromes) and a population of healthy subjects, using millimetric computed tomography (CT) acquisitions [10]. Posterior fossa volume (figure 1) was measured by contouring the space between the cerebellar tent, occipital bone, clivus and temporal bone [10]. The anterolateral boundary was the ridge of the petrous part of the temporal bone and the anterior boundary was its connection with the posterior petroclinoid ligament [10]. No difference in either posterior fossa or cerebellum volume emerged between the healthy population and the syndromic patients [10].

2. Venous theory

Venous theory was developed by Sainte Rose et al. in 1984 [29]. The alleged pathophysiology consists in venous sinus hyperpressure, following observation of jugular foramen stenosis in hydrocephalic children with Crouzon syndrome [7,29]. The jugular foramen has a large lateral portion, the sigmoidal part, which receives drainage from the sigmoidal sinus, and a smaller medial part, the petrous part, which receives drainage from the lower petrous sinus [30]. This venous hyperpressure results in defective CSF resorption in venous sinuses [7,29]. Angiographic studies demonstrated the presence of a highly developed collateral venous network in a majority of children suffering from Crouzon syndrome and in fewer children with Apert syndrome [7]. A previous study compared jugular foramina diameter between FGFR2-mutant children (Crouzon, Apert and Pfeiffer syndromes) and a healthy population, using millimetric CT slices (figure 2) [10]. Only children with Apert syndrome showed truly reduced jugular foramina[10], corroborating the finding that children with Apert syndrome had tetra-ventriculomegaly with a wide open aqueduct while none showed active hydrocephalus[10]. These findings are similar to the physiopathology of ventriculomegaly in children suffering from achondroplasia, another FGFR-related pathology with reduced jugular foramen, showing large ventricles with widening of the subarachnoid spaces secondary to increased venous pressure but without any active CSF disorder [10,29,31,32]. The theory of venous hyperpressure, related to stenosis of the jugular foramen, may explain ventriculomegaly in Apert syndrome, but cannot explain hydrocephalus in Crouzon or Pfeiffer syndromes, where ventricular dilation is associated with reduced subarachnoid spaces [10]. All these differences reflect the fact that jugular foramen stenosis cannot

completely explain the pathophysiology of hydrocephalus in children with Crouzon or Pfeiffer syndrome.

3. Foramen magnum stenosis theory

Foramen magnum (FM) area was found to be reduced in children with Crouzon syndrome [3,4,33–37]. A previous study confirmed this in populations with FGFR2-induced Crouzon and Pfeiffer syndrome [10]. The reduction in area was significantly associated with CSF disorder [10]. The pathophysiology alleged to explain hydrocephalus in FM stenosis is a craniospinal pressure gradient: blockage of the subarachnoid spaces linked to the reduction in FM area increases pressure in the cranial compartment according to Bernouilly's theorem and the Ventury effect [38]. If fluid flow is constant and diameter decreases, flow-rate increases and pressure decreases downstream of the stenosis while the opposite occurs upstream. As previously demonstrated [10,33], and in agreement with the theory of Greitz [39,40] and Levine [38], reduced CSF flow between the intracranial subarachnoidal and spinal subarachnoidal spaces plays a key role in the development of hydrocephalus in syndromic craniosynostosis. Interruption of CSF flow, by generating fluctuations independent of fluid pressure on each side of the FM, induces a dissociation of craniospinal pressure, resulting in a decrease in subarachnoid craniospinal chamber compliance [10,38–40]. This reduced craniospinal compliance with higher pressure gradient at the cranial stage leads, according to Greitz's hydrodynamic theory [39,40] and Levine's theory [38], to abnormal pressure transmission to brain capillaries, with increases in ventricular pulse pressure and pulsatile CSF flow in the aqueduct, and finally global ventricular dilation [10,39]. In 2013, Preus et al. developed the pulsatile

vector theory, according to which arterial and venous blood flow are at the origin of three vector forces responsible for CSF pulsatility and circulation [41]. By altering arterio-venous flow following a decrease in craniospinal compliance, as in the Greitz model [39], craniospinal pressure dissociation increases the "interstitial fluid shockwave", as in Preuss's model [41], leading to an increase in ventricular CSF pulse wave and ultimately to ventricular dilation [10]. All these mechanisms explain the presence of communicating hydrocephalus in children with Crouzon or Pfeiffer syndrome, who show a reduced FM. The absence of active hydrocephalus in Apert syndrome, where FM is not reduced, supports this theory, as does the absence of subarachnoid effusion in Crouzon and Pfeiffer FGFR2-mutants in previous reports [10].

4. Clinical implications

The variable efficacy of endoscopic 3rd ventriculostomy (ETV) in some children with faciocraniosynostosis [42] is an additional argument in favor of craniospinal pressure dissociation [10]. The stoma increases the low compliance as a result of craniospinal dissociation, by creating an alternative CSF pathway to the subarachnoid space [10]. Pediatric craniofacial neurosurgeons usually perform craniospinal decompression surgeries, associated or not to posterior cranial vault expansion in children with FGFR2-induced craniosynostosis [43]. It is usually easier to perform ETV than posterior cranial vault expansion, and future statistical analysis may assess the efficiency of these techniques in controlling hydrocephalus.

PATHOPHYSIOLOGY OF ECTOPIA OF THE CEREBELLAR TONSILS

The pathophysiological explanation of ECT given by Cinalli et al. [19,20] consists in premature closure of lambdoidal sutures in Crouzon and Pfeiffer syndromes compared to Apert syndrome, resulting in smaller posterior fossa volume. The conflict between neural growth and reduced bone growth, especially during the first 2 years of life when cerebellar growth is greater than that of other posterior fossa neural structures, is believed to be the origin of cerebellar tonsil ectopia [19,20]. In Crouzon syndrome, the lambdoid sutures are usually closed at a younger age than in the general population [3]. Chronologically, the first sutures to close in Crouzon syndrome are the posterior intra-occipital sutures, then the lambdoid sutures at the age of 10 months [3]. It is generally impossible to assess sutures ossification for patients with Apert or Pfeiffer syndrome, because most are operated on before 2 years of age [3,10]. Moreover, any craniofacial surgery can bias analysis of these children [3]. An FGFR2-induced craniosynostosis series of children under 2 years of age found no growth differential between neural and posterior fossa structures to explain ECT [10] (figure3). While there was no statistically significant correlation between presence or absence of ECT and the anatomical measurements we performed, hydrocephalus and ECT were significantly associated. The literature data show that, for Crouzon's syndrome, all hydrocephalic patients have ECT and 53% of patients with ECT are hydrocephalic [20]. In an FGFR2-induced craniosynostosis series, 75% of Crouzon syndrome children with hydrocephalus had ECT whereas 60% of Crouzon syndrome children with ECT had hydrocephalus [10]. The same series also showed that 83% of hydrocephalic children with Crouzon or Pfeiffer syndrome had ECT whereas only 62.5% of Crouzon or Pfeiffer children with ECT were hydrocephalic [10]. Children with Apert syndrome did not have reduced FM, were not hydrocephalic and had no ECT [10]. The hypothesis of aggravation of FM

stenosis by ECT seems more coherent than a descent of the cerebellar tonsils secondary to hydrocephalus, although this has not been confirmed statistically.

CONCLUSION

Children with FGFR2-induced craniosynostosis can have hydrocephalus and ECT. Hydrocephalus and tonsillar prolapse are statistically associated [4,10,33]. A correlation between small foramen magnum area and hydrocephalus has been demonstrated in children with genetically confirmed Crouzon or Pfeiffer syndrome [4,10,33]. Children with Apert syndrome have ventriculomegaly without decreased foramen magnum area [10]. While the most likely mechanism for active fluid disorder in children with Crouzon or Pfeiffer syndrome appears to be craniospinal dissociation resulting from foramen magnum stenosis, ventriculomegaly in Apert syndrome appears to be secondary to vascular stenosis at the jugular foramen [10]. As the clinical phenotype varies greatly in FGFR2-related synostosis, the pathophysiological mechanisms underlying CSF disorders such as cerebellar tonsil prolapse may also differ according to the type of mutation.

FIGURE LEGENDS

Figure 1. 3D reconstruction, axial, sagittal and coronal millimetric CT slices showing, in blue on the left side, cerebellar volume calculation in a 19-month-old child (Crouzon) and, in purple on the right side, posterior fossa volume calculation in a 1-month-old child (control group). iPlan stereotaxy 3.0.2. Adapted from reference 10

Figure 2. Multiplanar CT reconstruction perpendicular to the major axis of the left jugular foramen in a 3-month-old child with Crouzon syndrome. Foramen magnum area is contoured and shown in white. Adapted from reference 10.

Figure 3. Posterior fossa volume and cerebellar volume plotted by age. Crouzon and Pfeiffer syndromes with and without ectopia of the cerebellar tonsils. Growth speeds are extrapolated with locally weighted scatterplot smoothing regression. Adapted from reference 10.

References

[1] Lajeunie E, Ma HW, Bonaventure J, Munnich A, Le Merrer M, Renier D. FGFR2 mutations in Pfeiffer syndrome. Nat Genet 1995;9:108. doi:10.1038/ng0295-108.

[2] Azoury SC, Reddy S, Shukla V, Deng C-X. Fibroblast Growth Factor Receptor 2 (FGFR2) Mutation Related Syndromic Craniosynostosis. Int J Biol Sci 2017;13:1479–88. doi:10.7150/ijbs.22373.

[3] Coll G, Sakka L, Botella C, Pham-Dang N, Collet C, Zerah M, et al. Pattern of Closure of Skull Base Synchondroses in Crouzon Syndrome. World Neurosurg 2018;109:e460–7. doi:10.1016/j.wneu.2017.09.208.

[4] Rijken BFM, Lequin MH, Van Veelen M-LC, de Rooi J, Mathijssen IMJ. The formation of the foramen magnum and its role in developing ventriculomegaly and Chiari I malformation in children with craniosynostosis syndromes. J Cranio-Maxillo-Fac Surg Off Publ Eur Assoc Cranio-Maxillo-Fac Surg 2015;43:1042–8. doi:10.1016/j.jcms.2015.04.025.

[5] Collet C, Alessandri J-L, Arnaud E, Balu M, Daire VC, Di Rocco F. Crouzon syndrome and Bent bone dysplasia associated with mutations at the same Tyr-381 residue in FGFR2 gene. Clin Genet 2014;85:598–9. doi:10.1111/cge.12213.

[6] Apra C, Collet C, Arnaud E, Di Rocco F. FGFR2 splice site mutations in Crouzon and Pfeiffer syndromes: two novel variants. Clin Genet 2016;89:746–8. doi:10.1111/cge.12705.

[7] Cinalli G, Sainte-Rose C, Kollar EM, Zerah M, Brunelle F, Chumas P, et al. Hydrocephalus and craniosynostosis. J Neurosurg 1998;88:209–14. doi:10.3171/jns.1998.88.2.0209.

[8] Proudman TW, Clark BE, Moore MH, Abbott AH, David DJ. Central nervous system imaging in Crouzon's syndrome. J Craniofac Surg 1995;6:401–5.

[9] Noetzel MJ, Marsh JL, Palkes H, Gado M. Hydrocephalus and mental retardation in craniosynostosis. J Pediatr 1985;107:885–92.

[10] Coll G, Arnaud E, Collet C, Brunelle F, Sainte-Rose C, Di Rocco F. Skull Base Morphology in Fibroblast Growth Factor Receptor Type 2-Related Faciocraniosynostosis: A Descriptive Analysis. Neurosurgery 2015;76:571–83. doi:10.1227/NEU.0000000000000676.

[11] Hanieh A, David DJ. Apert's syndrome. Childs Nerv Syst 1993;9:289–91.

[12] Renier D, Arnaud E, Cinalli G, Sebag G, Zerah M, Marchac D. Prognosis for mental function in Apert's syndrome. J Neurosurg 1996;85:66–72. doi:10.3171/jns.1996.85.1.0066.

[13] Collmann H, Sörensen N, Krauss J. Hydrocephalus in craniosynostosis: a review. Childs Nerv Syst 2005;21:902–12. doi:10.1007/s00381-004-1116-y.

[14] Moore MH, Hanieh A. Hydrocephalus in Pfeiffer syndrome. J Clin Neurosci Off J Neurosurg Soc Australas 1994;1:202–4.

[15] Murovic JA, Posnick JC, Drake JM, Humphreys RP, Hoffman HJ, Hendricks EB. Hydrocephalus in Apert syndrome: a retrospective review. Pediatr Neurosurg 1993;19:151–5.

[16] Collmann H, Sörensen N, Krauss J, Mühling J. Hydrocephalus in craniosynostosis. Childs Nerv Syst 1988;4:279–85.

[17] Azahraa Haddad F, Qaisi I, Joudeh N, Dajani H, Jumah F, Elmashala A, et al. The newer classifications of the chiari malformations with clarifications: An anatomical review. Clin Anat N Y N 2018;31:314–22. doi:10.1002/ca.23051.

[18] Friede RL, Roessmann U. Chronic tonsillar herniation: an attempt at classifying chronic herniations at the foramen magnum. Acta Neuropathol (Berl) 1976;34:219–35.

[19] Cinalli G, Spennato P, Sainte-Rose C, Arnaud E, Aliberti F, Brunelle F, et al. Chiari malformation in craniosynostosis. Childs Nerv Syst 2005;21:889–901. doi:10.1007/s00381-004-1115-z.

[20] Cinalli G, Renier D, Sebag G, Sainte-Rose C, Arnaud E, Pierre-Kahn A. Chronic tonsillar herniation in Crouzon's and Apert's syndromes: the role of premature synostosis of the lambdoid suture. J Neurosurg 1995;83:575–82. doi:10.3171/jns.1995.83.4.0575.

[21] Cinalli G, Chumas P, Arnaud E, Sainte-Rose C, Renier D. Occipital remodeling and suboccipital decompression in severe craniosynostosis associated with tonsillar herniation. Neurosurgery 1998;42:66–71; discussion 71-73.

[22] Thompson DN, Harkness W, Jones BM, Hayward RD. Aetiology of herniation of the hindbrain in craniosynostosis. An investigation incorporating intracranial pressure monitoring and magnetic resonance imaging. Pediatr Neurosurg 1997;26:288–95.

[23] Francis PM, Beals S, Rekate HL, Pittman HW, Manwaring K, Reiff J. Chronic tonsillar herniation and Crouzon's syndrome. Pediatr Neurosurg 1992;18:202–6.

[24] Hoffman HJ, Tucker WS. Cephalocranial disproportion. A complication of the treatment of hydrocephalus in children. Childs Brain 1976;2:167–76.

[25] Venes JL. Arnold-Chiari malformation in an infant with Kleeblattschadel: an acquired malformation? Neurosurgery 1988;23:360–2.

[26] Scarfò GB, Tomaccini D, Gambacorta D, Capaccioli L. Contribution to the study of craniostenosis: disturbance of the cerebrospinal fluid flow in oxycephaly. Helv Paediatr Acta 1979;34:235–43.

[27] Sgouros S, Natarajan K, Hockley AD, Goldin JH, Wake M. Skull base growth in craniosynostosis. Pediatr Neurosurg 1999;31:281–93.

[28] Wang TJ, Hung KS, Chen PKT, Chuang WL, Shih TY, Lai BJP, et al. Beare-Stevenson cutis gyrata syndrome with Chiari malformation. Acta Neurochir (Wien) 2002;144:743–5. doi:10.1007/s00701-002-0933-6.

[29] Sainte-Rose C, LaCombe J, Pierre-Kahn A, Renier D, Hirsch JF. Intracranial venous sinus hypertension: cause or consequence of hydrocephalus in infants? J Neurosurg 1984;60:727–36. doi:10.3171/jns.1984.60.4.0727.

[30] Rhoton AL Jr. Jugular foramen. Neurosurgery 2000;47:S267-285.

[31] Reina V, Baujat G, Fauroux B, Couloigner V, Boulanger E, Sainte-Rose C, et al. Craniovertebral junction anomalies in achondroplastic children. Adv Tech Stand Neurosurg 2014;40:295–312. doi:10.1007/978-3-319-01065-6_10.

[32] King JAJ, Vachhrajani S, Drake JM, Rutka JT. Neurosurgical implications of achondroplasia. J Neurosurg Pediatr 2009;4:297–306. doi:10.3171/2009.3.PEDS08344.

[33] Coll G, Arnaud E, Selek L, Brunelle F, Sainte-Rose C, Collet C, et al. The growth of the foramen magnum in Crouzon syndrome. Childs Nerv Syst 2012;28:1525–35. doi:10.1007/s00381-012-1805-x.

[34] Rijken BFM, Lequin MH, de Rooi JJ, van Veelen M-LC, Mathijssen IMJ. Foramen magnum size and involvement of its intraoccipital synchondroses in Crouzon syndrome. Plast Reconstr Surg 2013;132:993e-1000e. doi:10.1097/PRS.0b013e3182a8077e.

[35] Milhorat TH, Nishikawa M, Kula RW, Dlugacz YD. Mechanisms of cerebellar tonsil herniation in patients with Chiari malformations as guide to clinical management. Acta Neurochir (Wien) 2010;152:1117–27. doi:10.1007/s00701-010-0636-3.

[36] Goodrich JT. Skull base growth in craniosynostosis. Childs Nerv Syst 2005;21:871–9. doi:10.1007/s00381-004-1113-1.

[37] Assadsangabi R, Hajmomenian M, Bilaniuk LT, Vossough A. Morphology of the foramen magnum in syndromic and non-syndromic brachycephaly. Childs Nerv 2015. doi:10.1007/s00381-015-2639-0.

[38] Levine DN. The pathogenesis of syringomyelia associated with lesions at the foramen magnum: a critical review of existing theories and proposal of a new hypothesis. J Neurol Sci 2004;220:3–21. doi:10.1016/j.jns.2004.01.014.

[39] Greitz D. Radiological assessment of hydrocephalus: new theories and implications for therapy. Neurosurg Rev 2004;27:145–65; discussion 166-167. doi:10.1007/s10143-004-0326-9.

[40] Greitz D. Unraveling the riddle of syringomyelia. Neurosurg Rev 2006;29:251–63; discussion 264. doi:10.1007/s10143-006-0029-5.

[41] Preuss M, Hoffmann K-T, Reiss-Zimmermann M, Hirsch W, Merkenschlager A, Meixensberger J, et al. Updated physiology and pathophysiology of CSF circulation--the pulsatile vector theory. Childs Nerv Syst 2013;29:1811–25. doi:10.1007/s00381-013-2219-0.

[42] DiRocco F, Jucá CE, Arnaud E, Renier D, Sainte-Rose C. The role of endoscopic third ventriculostomy in the treatment of hydrocephalus associated with faciocraniosynostosis. J Neurosurg Pediatr 2010;6:17–22. doi:10.3171/2010.3.PEDS09484.

[43] Nowinski D, Di Rocco F, Renier D, SainteRose C, Leikola J, Arnaud E. Posterior cranial vault expansion in the treatment of craniosynostosis. Comparison of current techniques. Childs Nerv Syst 2012;28:1537–44. doi:10.1007/s00381-012-1809-6.

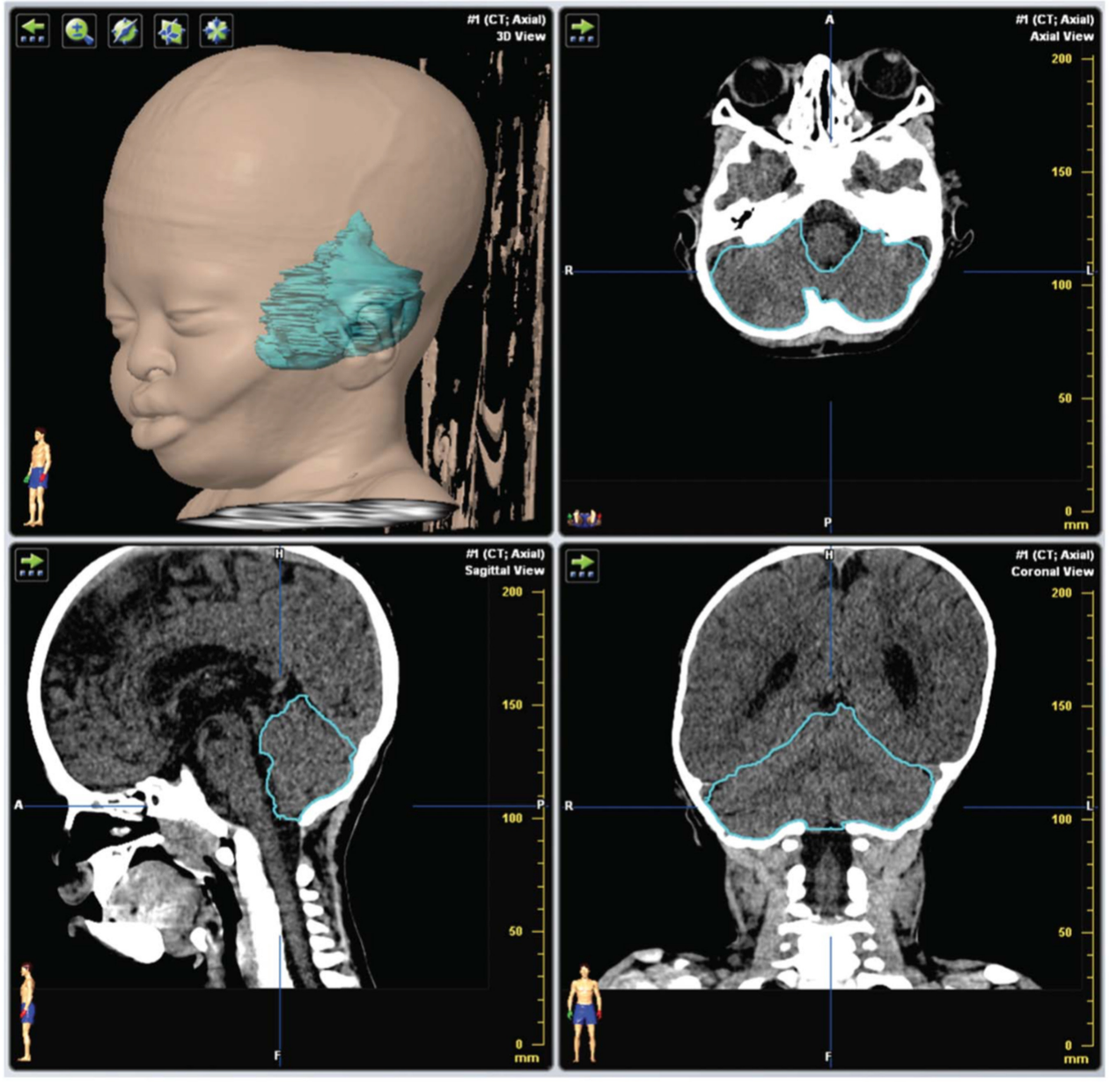
#1 (CT; Axial)
3D View
#1 (CT; Axial)
Axial View
#1 (CT; Axial)
Sagittal View
#1 (CT; Axial)
Coronal View
A
R
L
P
H
F
200
150
100
50
0
mm

#1 (CT; Axial)
3D View
#1 (CT; Axial)
Original 78/95
#1 (CT; Axial)
Sagittal View
#1 (CT; Axial)
Coronal View
A
R
L
P
H
F
150
100
50
0
mm

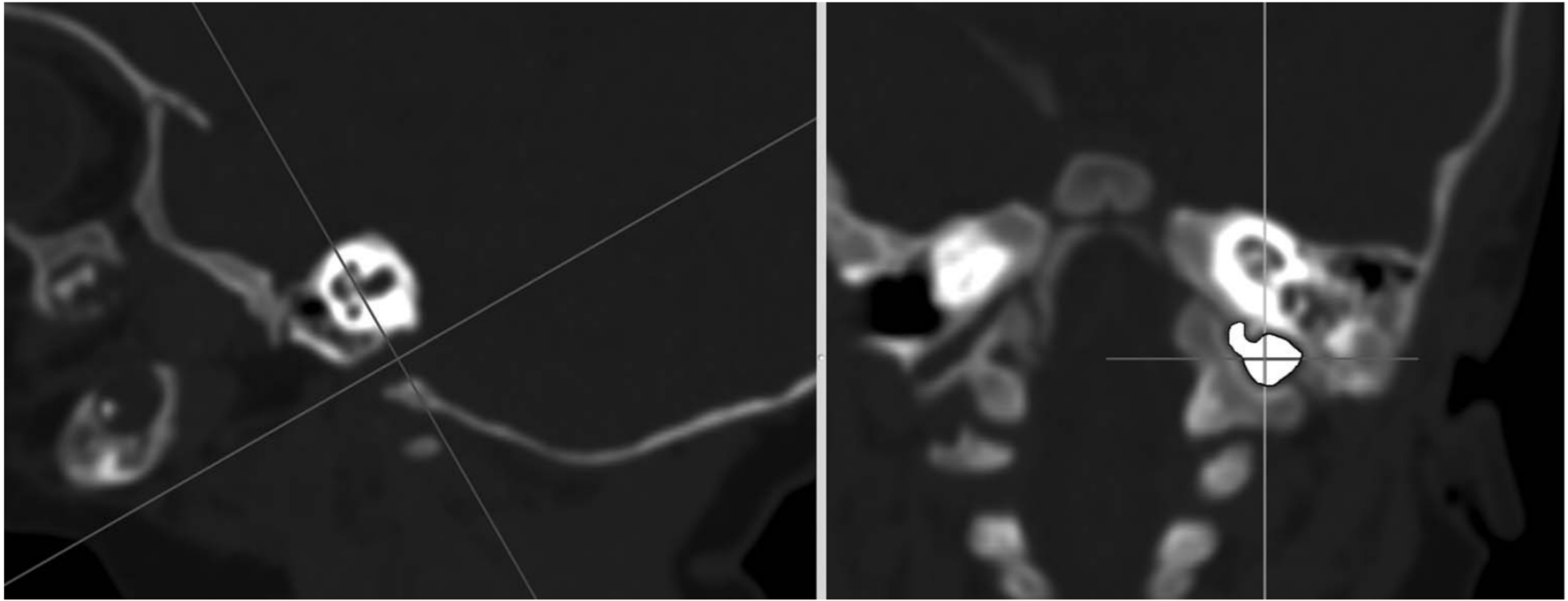

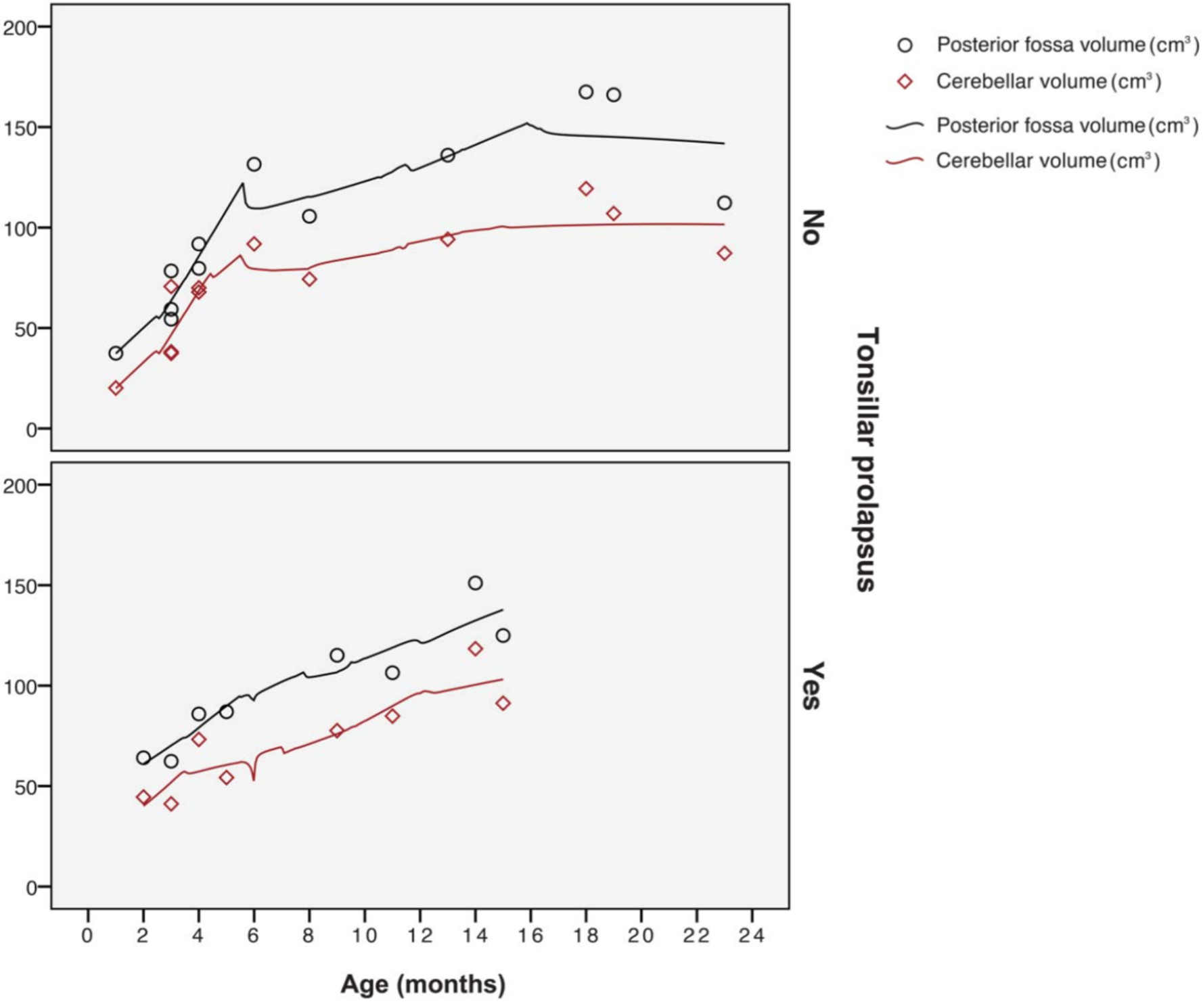
Posterior fossa volume (cm³)
Cerebellar volume (cm³)
Posterior fossa volume (cm³)
Cerebellar volume (cm³)
No
Yes
Tonsillar prolapsus
200
150
100
50
0
0
2
4
6
8
10
12
14
16
18
20
22
24
Age (months)