



HAL
open science

Ictal Blinking in Focal Seizures: insights from SEEG recordings

Stanislas Lagarde, Maya Dirani, Agnès Trébuchon, Anne Lépine, Nathalie Villeneuve, Didier Scavarda, Romain Carron, Aileen Mcgonigal, Fabrice Bartolomei

► **To cite this version:**

Stanislas Lagarde, Maya Dirani, Agnès Trébuchon, Anne Lépine, Nathalie Villeneuve, et al.. Ictal Blinking in Focal Seizures: insights from SEEG recordings. *Seizure - European Journal of Epilepsy*, 2020, 10.1016/j.seizure.2020.07.010 . hal-02901121v1

HAL Id: hal-02901121

<https://hal.science/hal-02901121v1>

Submitted on 16 Jul 2020 (v1), last revised 29 Jun 2021 (v2)

HAL is a multi-disciplinary open access archive for the deposit and dissemination of scientific research documents, whether they are published or not. The documents may come from teaching and research institutions in France or abroad, or from public or private research centers.

L'archive ouverte pluridisciplinaire **HAL**, est destinée au dépôt et à la diffusion de documents scientifiques de niveau recherche, publiés ou non, émanant des établissements d'enseignement et de recherche français ou étrangers, des laboratoires publics ou privés.

Journal Pre-proof

Ictal Blinking in Focal Seizures: insights from SEEG recordings

Stanislas Lagarde, Maya Dirani, Agnès Trebuchon, Anne Lepine, Nathalie Villeneuve, Didier Scavarda, Romain Carron, Aileen McGonigal, Fabrice Bartolomei



PII: S1059-1311(20)30206-5
DOI: <https://doi.org/10.1016/j.seizure.2020.07.010>
Reference: YSEIZ 3776

To appear in: *Seizure: European Journal of Epilepsy*

Received Date: 22 May 2020
Revised Date: 9 July 2020
Accepted Date: 10 July 2020

Please cite this article as: Lagarde S, Dirani M, Trebuchon A, Lepine A, Villeneuve N, Scavarda D, Carron R, McGonigal A, Bartolomei F, Ictal Blinking in Focal Seizures: insights from SEEG recordings, *Seizure: European Journal of Epilepsy* (2020), doi: <https://doi.org/10.1016/j.seizure.2020.07.010>

This is a PDF file of an article that has undergone enhancements after acceptance, such as the addition of a cover page and metadata, and formatting for readability, but it is not yet the definitive version of record. This version will undergo additional copyediting, typesetting and review before it is published in its final form, but we are providing this version to give early visibility of the article. Please note that, during the production process, errors may be discovered which could affect the content, and all legal disclaimers that apply to the journal pertain.

© 2020 Published by Elsevier.

Ictal Blinking in Focal Seizures: insights from SEEG recordings

Authors:

Stanislas LAGARDE (MD, MSc)^{1*}, Maya DIRANI (MD)^{2*}, Agnès TREBUCHON (MD, PhD)¹, Anne LEPINE (MD)³, Nathalie VILLENEUVE (MD)³, Didier SCAVARDA (MD, PhD)⁴, Romain CARRON (MD, PhD)⁵, Aileen McGONIGAL (MD, PhD)¹, Fabrice BARTOLOMEI (MD, PhD)¹

Affiliations:

1. Aix Marseille Univ, APHM, INSERM, INS, Inst Neurosci Syst, Timone Hospital, Epileptology Department, Marseille, France;
2. Department of Neurology, American University of Beirut Medical Center, Beirut, Lebanon
3. APHM, Timone Hospital, Pediatric Neurology Department, Marseille, France;
4. Aix Marseille Univ, APHM, INSERM, INS, Inst Neurosci Syst, Timone Hospital, Pediatric Neurosurgery Department, Marseille, France
5. Aix Marseille Univ, APHM, INSERM, INS, Inst Neurosci Syst, Timone Hospital, Functional and Stereotactic Neurosurgery Department, Marseille, France;

* Equal contribution

*Corresponding Author: Dr Stanislas LAGARDE (MD, MSc); stanislas.lagarde@ap-hm.fr; stanislas.lagarde@univ-amu.fr; Service d'Epileptologie et de Rythmologie Cérébrale, Hôpital de la Timone, 264 rue Saint Pierre, 13005 Marseille, France ; Tel : +33(0)4.91.38.49.90
<https://orcid.org/0000-0003-2916-1302>

HIGHLIGHTS

- Ictal blinking occurred in 8% of our patients explored by SEEG, mostly bilateral.
- Ictal blinking was statistically over-represented in occipital & occipito-temporal seizures.
- Ictal blinking could also be observed in temporal mesial, and insulo-opercular seizures.
- The speed of the blinking was fastest in insulo-opercular and slowest in temporal mesial seizures.
- The presence of nystagmus & tonic eye deviation were associated with occipital lobe involvement.

ABSTRACT

Purpose: Ictal blinking may be observed in various forms of epilepsies. In the context of presurgical assessment of drug-resistant focal epilepsies, its semiological value is poorly understood. Our aims were to determine the prevalence and localizing value of ictal blinking.

Methods: We reviewed our cohort of more than 300 patients explored by SEEG, searching for ictal blinking. We defined seizure onset zone (SOZ) using visual analysis complemented by a quantified method (epileptogenicity index). We analysed the features of ictal blinking and the associated signs. We tested for statistically significant associations with the underlying SOZ.

Results: We found that about 8% of our patients exhibited ictal blinking, mostly bilateral. Ictal blinking was seen mostly in four type of SOZ: occipital, occipito-temporal, temporal mesial, and insulo-opercular. It was significantly over-represented in occipito-temporal and occipital SOZ. Eye blinking was fastest in insulo-opercular SOZ and slowest in temporal mesial SOZ. Nystagmus and tonic eye deviation were associated with SOZ involving the occipital lobe.

Conclusion: Ictal blinking is not uncommon in the population of patients with drug-resistant focal epilepsies. It is mostly associated with four types of SOZ: occipital, occipito-temporal, temporal mesial, and insulo-opercular. Some features of ictal blinking, as well as the analysis of the associated signs, allow to orient clinical hypotheses toward some specific SOZ.

Keywords: drug-resistant epilepsy, focal epilepsy, epilepsy surgery, SEEG, blinking, semiology

MAIN TEXT

INTRODUCTION

Ictal blinking is an oculomotor sign occurring in various types of epilepsies [1]. A blink consists of tonic closure of upper and lower eyelid, co-occurring with downward movement of the eyes (contraction of *orbicularis oculi* and *levator palpebrae superioris* muscles) [2], distinct from eyelid *myoclonia* observed in generalized epilepsy (associated with upward movement of eyes and extension of the head) or eyelid *clonia* observed in facial motor focal seizures (associated with other facial muscles contraction). Physiological blinking can occur spontaneously, voluntarily or in response to a threat (reflex blinking). Blinks can also be a learned response, such as in eyeblink conditioning[2] or startle eye blinking[3]. The mechanisms underlying blinking are still not very well understood although several central nervous system (CNS) structures have been reported to be involved (cerebellum, brainstem, primary and supplementary motor cortex, thalamus) [2,4].

The prevalence of ictal blinking is not very well-known and few papers have estimated a frequency of unilateral blinking ranging from 0.8%–1.5% of children and adults with focal epilepsy [5,6]. Its pathophysiology is unknown and very little is known about its localizing value.

Ictal blinking has been reported to be a frequent early sign in occipital lobe seizures [7], but has been also observed in other forms of epilepsies as temporal, frontal lobe or insular seizures [8–12].

To our knowledge, no study has specifically investigated ictal blinking using intracerebral EEG recordings. In this study, we aimed to explore the semiological value of ictal blinking in patients with refractory focal epilepsy explored using stereotactic-EEG (SEEG).

METHODS

Patients

We retrospectively reviewed all consecutive patients who underwent SEEG in our department from 2000 to 2018, searching for all patients with ictal blinking recorded during SEEG. Ictal blinking was defined as repetitive eyelid closure and opening at a frequency higher than the patient's baseline (rate of spontaneous blink in adult is about 0.16-0.33 hertz [2]), occurring as a semiological finding during visible SEEG ictal discharge. Patients with 1) concomitant facial clonic jerks (contraction of other facial muscles than *orbicularis* muscle), or 2) blinking immediately before secondary tonic-clonic generalization (within the three seconds before generalization), or 3) seizures where both eyes cannot be optimally analysed, were classified as without ictal blinking. We analysed lateralisation of the blinking, speed (hertz), delay of appearance (second), association with head version, presence or absence of epileptic nystagmus,

and presence or absence of tonic eye deviation. Two patients had each two analysed seizures with similar semiological features (we used the mean for speed and delay of the two seizures).

All patients had detailed presurgical workup, including medical history, neurologic examination, cerebral magnetic resonance imaging (MRI), cerebral positron emission tomography, and scalp EEG recordings. In this study, all patients required SEEG as part of their usual clinical care [13]. The placement of electrodes was selected, in each patient, based on available non-invasive information providing hypotheses about the localization of the EZ. We excluded patients without spontaneous seizures and/or with sub-optimal ictal recording (*e.g.* deficient contact or electrode, absence of SEEG ictal discharge). The institutional review board of the French Institute of Health (IRB15226) approved this study and patients' written consent was obtained.

SEEG Recordings

Recordings were performed using intracerebral multiple contact electrodes (10- 15 contacts with length = 2 mm, diameter = 0.8 mm, 1.5 mm apart). Signals were recorded on a 128- or 256-channel Natus system, sampled at 256, 512, or 1024 Hz, depending on the period of recording, and recorded on a hard disk (16 bits/sample) using no digital filter. Two hardware filters were present in the acquisition procedure: a high- pass filter (cut-off frequency equal to 0.16 Hz at -3 dB) and an antialiasing low- pass filter (cut-off frequency equal to 97 Hz at 256 Hz, 170 Hz at 512 Hz, or 340 Hz at 1024 Hz).

We defined the seizure onset zone (SOZ) using visual analysis complemented when possible (ictal discharge above 12 Hz) by a quantitative method (epileptogenicity index, for detail see Bartolomei et al. [14]), using Anywave software[15]. Location of electrodes was defined by visual analysis of pre- SEEG MRI fused with the postoperative computed tomographic scan

performed after electrode implantation, using Gardel GUI[16]. According to our previous studies[14,17–22], we classified epilepsies into several sub-groups according to the localization/organization of their SOZ: temporal mesial, temporal lateral, temporal medial + lateral, temporal + frontal, temporal plus (*i.e.* temporal + insular or temporal + parietal), bitemporal, prefrontal, premotor, prefrontal + premotor, central, central + premotor, frontal plus (*i.e.* frontal + temporal, frontal + parietal, frontal + insula), bifrontal, occipital, occipital + parietal, occipital + temporal, parietal, parietal + frontal, insulo-opercular. For the SOZ involving several lobes, the first is defined based on the structure with the maximum of epileptogenicity and/or where was located the epileptogenic lesion.

Statistical testing

We performed two sets of analyses: 1) comparison of patients with blinking to all other patients without blinking explored by SEEG during the same period, 2) comparison of blinking features and associated signs according to the SOZ (limited to the four SOZ with more than 2 observations). For statistical analysis, we defined the aetiology of the epilepsy based on a combination of factors: MRI and histological findings. Mann-Whitney U test was performed to analyse numerical variables, and Fisher's two-tailed exact test was used to analyse nominal variables. In these analyses, $p \leq 0.05$ was considered to be statistically significant. Statistical tests were performed with the software SPSS Statistics for Mac, version 22 (IBM).

RESULTS

Prevalence of ictal blinking and characteristics of patients

From our database, we reviewed 301 patients recorded with SEEG in our centre from 2000 to 2018. We found 60 patients with ictal blinking described in medical reports. After careful review of SEEG data, we excluded 14 patients (lack of clear visible blinking or suboptimal video recording, blinking during secondary generalization) from our analyses. Of the 46 remaining analysed patients, 21 had co-occurrence of hemifacial clonus (therefore not classified as ictal blinking), and then 25 patients (13 women and 12 men) were considered as having ictal blinking. These patients represented 8.3% of the whole cohort of patients explored by SEEG during the studied period. Six of these patients had negative MRI (4%). Their median age of epilepsy onset was seven years (+/- 9), and their median age at SEEG was 25 years (+/- 4). The aetiology of the epilepsy was focal cortical dysplasia (FCD) in 11 patients (44%), undetermined in six (24%), neurodevelopmental tumour in two (8%), post-stroke in two (8%), heterotopia in two (8%), and hippocampal sclerosis in two (8%). There was no significant association between the presence of ictal blinking and these clinical features (Table 1).

SOZ underlying ictal blinking

Ictal blinking was observed with different prevalence according to the localization of SOZ (Table 1 and Figure 1). Ictal blinking was observed in nine patients with occipito-temporal seizure (33.3% of the patients with this SOZ, Figure 2a and b), four with occipital seizure (57.1% of patients with this SOZ, Figure 2c and d), four with temporal mesial seizure (7.5% of patients with this SOZ, Figure 3a and b), three with insulo-opercular seizure (17.6% of patients with this SOZ, Figure 3c and d), two with central + premotor seizure (20% of patients with this SOZ), two with temporal mesio-lateral seizure (11.1% of patients with this SOZ), two with temporal plus seizure (4.3% of patients with this SOZ) and two with parietal seizure (5.9% of

patients with this SOZ). We did not observe ictal blinking in frontal seizures apart of central + premotor SOZ, and in temporal lateral seizures. Thus, ictal blinking was significantly more prevalent in patients with occipital and occipito-temporal seizures ($p < 0.001$).

Ictal blinking features

Ictal blinking was mostly bilateral (92%) and more rarely ipsilateral (one patient with temporal mesio-lateral seizure) or contralateral (one patient with central + premotor seizure), 4 % for each. Notably some patients had asymmetric eye blinking but with bilateral blink and were then classified as bilateral. Ictal blinking was associated in 20% of the cases with head version (always ipsilateral). Nystagmus and tonic eye deviation (always contralateral) were associated with blinking in 12% of the cases each. The mean delay before the appearance of ictal blinking was 24.8 seconds (+/- 18.1). The mean frequency of ictal blinking was 2 hertz (+/- 1.2).

Ictal features according to SOZ localization

We focused our analyses only on occipital, occipito-temporal, insulo-opercular and temporal mesial seizures, since these SOZ had each more than 2 observations per group (> 10% of ictal blinking, for a total of 20 seizures). The features are detailed in Table 2. Speed of eye blinking was faster in insulo-opercular seizures (mean = 3.58 Hz), than in occipital, occipito-temporal and temporal mesial seizure (mean = 1.84, 1.76 and 1.55 Hz respectively, Figure 4). Blinking was always bilateral for these SOZ. Nystagmus was always associated with occipital (n=1/4) and occipito-temporal seizures (n=2/9). Head version was only observed in occipito-temporal (n=2/9) and temporal mesial seizures (n=1/4). Tonic eye deviation (always contralateral) was only observed in occipito-temporal seizures (n=2/9). Four patients had a combination of head version

and/or tonic eye deviation and/or nystagmus (n=3/9 in occipito-temporal seizures, n=1/2 in central + premotor seizures). There is a tendency for longer delay before appearance of ictal blinking in occipital seizures and shorter in occipito-temporal seizures. However, all statistical tests, searching for association between semiological features and SOZ, were not significant, probably because of the low number of observations.

DISCUSSION

In this study, we report a series of 25 patients with ictal blinking investigated with SEEG and with quantified definition of SOZ. The main findings are as follows: 1) ictal blinking occurred in 8.3% of the patients explored with SEEG in our centre; 2) ictal blinking is found in several types of SOZ, with a significant predominance in occipital and occipito-temporal seizures; 3) the majority of blinking features are shared by different types of focal epilepsies but speed of blinking, and association with nystagmus and tonic eye deviation may be indicative of the underlying SOZ.

The overall prevalence of ictal blinking in our cohort was 8.3%, with ictal blinking being mostly bilateral (92%) and more rarely unilateral (16%). The prevalence of bilateral ictal blinking in our population of SEEG-investigated patients was approximately 7% with an over-representation in occipital SOZ (prevalence of 57,1%) which is in accordance with existing literature on occipital epilepsy (prevalence ranging from 15 to 62,5%) [7,23–27]. The prevalence of unilateral ictal blinking in our cohort was approximately 1.3%, that is consistent with previous studies (0.7-

1,5%) [5,6,9] , except in a series focusing on patients with tuberous sclerosis complex (12%) [10]. Noteworthy, because we have excluded patients without optimal visualisation of both eyes, it is possible that we have a little underestimated the prevalence of ictal eye blinking in our cohort.

The lateralizing value of ictal blinking has previously been discussed. Wada originally reported unilateral blinking as being ipsilateral to ictal discharges in patients with temporal seizures recorded with sphenoidal electrodes [28]. Benbadis et al. showed that unilateral blinking could be a reliable lateralizing sign after he described 38 seizures in 14 patients, with unilateral blinking ipsilateral to the lesion in 10, which led to a positive predictive value for ipsilateral ictal EEG localization of 83% [5]. Ipsilateral blinking has been found to be a frequent sign in insular seizures [11,12]. Case reports have reported similar features using scalp EEG [8,9]. In contrast, Jadhav et al. described unilateral blinking in 11 children with tuberous sclerosis and noted that it was not a reliable lateralizing sign [10]. They noticed that when unilateral blinking occurred early in seizures, it was mostly contralateral to the ictal discharge [10]. In our cohort, when unilateral, blinking was contralateral to the SOZ in one patient with seizures involving motor systems and ipsilateral in one patient with temporal mesio-lateral seizure. Seizures including occipital lobes at onset were often characterized by bilateral blinking. We did not find significant association between ictal blinking and seizure lateralization, because we observed a large predominance of bilateral blinking. However, it is interesting to note that in our series, ipsilateral blinking was observed in a single patient involving temporal mesial zone. Mesial temporal seizures are rarer today in series using invasive EEG, which may be an explanation for the under-representation of unilateral ipsilateral blinking in the present series. Taken together with

the various previous data from the literature, this suggests that unilateral ictal blinking, beside facial clonic seizures, has only limited lateralizing value if interpreted separately.

The localizing value of ictal blinking has until now not been clearly demonstrated. Indeed, it has been reported in seizures arising from temporal, frontal, occipital and insular lobes [29]. The highest prevalence is observed in occipital epilepsies [7,23–27,30–34] with ictal blinking classically being bilateral. More recently, Marchi and al., using SEEG recordings, reported a high prevalence of ictal blinking in occipital and “occipital plus” epilepsies [19]. Unilateral ictal blinking could be observed in patients with temporal seizures [6,28,35]. Others authors suggested also a frontal origin mostly based on scalp EEG recordings [5,8,9]. Recent papers have also emphasize its frequency in insular epilepsies [11,12].

Our data have the advantage of allowing precise localization of the SOZ using quantified analysis of SEEG recordings and comparison with the SOZ of patients without blinking analysed using similar methodology. We demonstrated that blinking may occur in various forms of seizures, most commonly in occipital and occipito-temporal localizations. We also found ictal blinking to be relatively common in seizures involving the mesial part of the temporal lobe, and insulo-opercular regions. Blinking was rarer for other SOZ. Thus, ictal blinking may arise during seizures involving one of three main lobes: occipital, temporal (mesial), and insulo-opercular regions. It should be noted that we excluded several other patients with blinking associated with facial clonic seizures and thus with SOZ involving motor systems. Our results clarify previous divergent literature which probably focused more on temporal lobe epilepsies, with lower spatial accuracy (scalp EEG, absence of insulo-opercular sampling in earliest intracranial recordings). Moreover, the population currently explored with SEEG is probably different from those of some

previous studies, with numerous cases involving extra-temporal and more complex forms of epilepsies.

Ictal blinking can be an isolated ictal semiological sign [8,31] or more frequently can co-occur with other seizure signs (e.g. nystagmus, head version, tonic eye deviation). Some authors have reported bilateral blinking [7,23–27,30–34], and more rapid forced eye closure in case of occipital seizures [29] but clear features of ictal blinking orientating to a specific SOZ have not previously been described. We found that the speed of the blinking may suggest some SOZ: slowest blinking in temporal mesial SOZ and fastest in insulo-opercular SOZ. Moreover, the co-occurrence of nystagmus and tonic eye deviation was associated with involvement of occipital lobe (occipital and occipito-temporal SOZ) but did not reach statistical significance because of the small number of observations. It emphasises that the analysis of the whole ocular semiology is crucial in order to improve hypotheses about underlying SOZ during pre-surgical assessment.

The exact pathophysiology of ictal blinking remains unknown. At the peripheral nervous system level, several cranial nerves act as effectors for blinking, and trigeminal fibers as afferents for some reflex blinking [2]. Their stimulation elicits ipsilateral or bilateral blinking [36]. In the central nervous system, several structures are thought to be involved in the regulation and coordination of blinking, notably brainstem, cerebellum, and multiple sub-cortical and cortical structures. Ebert et al. stated that blinking is generated by the reticular formation and that its regulation is mediated by the *substantia nigra*, the superior colliculus and the occipital cortex [37]. The amygdala has also some projections toward the reticular formation as demonstrated by its influence on startle eye blinking[3]. Hypothalamus, caudate nucleus, thalamus and cerebellum also seem to be involved. However, the specific locations and projections of the involved regions have not been fully elucidated [2]. Notably, activation imaging studies have revealed that the

primary motor cortex, supplementary motor cortex, motor cingulate cortex and the central thalamus are activated during spontaneous and voluntary blinking [38,39]. Intracranial stimulations of occipital lobe [40] and temporo-basal regions [41] have induced ipsilateral blinking in humans. Therefore, it could be hypothesized that some types of seizures (occipital and/or temporal, insulo-opercular) may activate the sub-cortical blinking pathway (basal ganglia, brainstem) or the startle eye blinking pathway (amygdala and reticular formation); and some, rarer, others (SOZ involving motor systems) would directly activate the motor systems involved in blinking. Activation of the subcortical pathways may explain the bilateral or ipsilateral nature of some ictal blinking.

In conclusion, we observed that ictal blinking was predominantly associated with occipito-temporal and occipital SOZ, but is not uncommon in temporal mesial, and insulo-opercular SOZ. Some associated clinical features (speed, presence of nystagmus, tonic eye deviation) may suggest some specific SOZ.

ACKNOWLEDGMENTS

We thank Prof Patrick Chauvel, Prof Martine Gavaret, Prof Maxime Guye, Prof Mathieu Milh, Dr Francesca Bonini, Dr Sandrine Aubert, Dr Geraldine Daquin, Dr Lisa Vaugier (Marseille) for the clinical management of some included patients; Prof Henry Dufour, Prof Jean- Claude Peragut, and Prof Jean Régis (Marseille) for surgical or SEEG procedures in some of the selected patients. We thank all the paramedical team of the epileptology unit, who allow optimal recordings and clinical testing of the patients explored by SEEG.

DECLARATIONS

Fundings

This work was supported by the French National Research Agency (ANR) (FHU EPINEXT, A*MIDEX project (ANR- 11- IDEX- 0001- 02) funded by the Investissements d’Avenir, a French government program); and jointly by the ANR and Direction Générale de l’Offre de Santé (grant VIBRATIONS ANR- 13- PRTS- 0011- 01).

Declarations of interest: none

REFERENCES

- [1] Bajwa R, Jay WM, Asconapé J, Bajwa R. Neuro-Ophthalmologic Manifestations of Epilepsy. *Semin Ophthalmol* 2009;0538. <https://doi.org/10.1080/08820530601006742>.
- [2] Smit AE. *Blinking and the Brain: Pathways and Pathology*. Erasmus University Rotterdam, 2009.
- [3] Kettle JWL, Andrewes DG, Allen NB. Lateralization of the startle reflex circuit in humans: An examination with monaural probes following unilateral temporal lobe resection. *Behav Neurosci* 2006. <https://doi.org/10.1037/0735-7044.120.1.24>.
- [4] Sindou M, Fobe JL, Berthier E, Vial C. Facial motor responses evoked by direct electrical stimulation of the trigeminal root. Localizing value for radiofrequency thermorhizotomy. *Acta Neurochir (Wien)* 1994;128:57–67. <https://doi.org/10.1007/BF01400654>.
- [5] Benbadis SR, Kotagal P, Klem GH. Unilateral blinking: A lateralizing sign in partial seizures. *Neurology* 1996;46:45–8. <https://doi.org/10.1212/WNL.46.1.45>.
- [6] Henkel A, Winkler PA, Noachtar S. Ipsilateral blinking: a rare lateralizing seizure phenomenon in temporal lobe epilepsy. *Epileptic Disord* 1999.

- [7] Williamson PD, Thadani VM, Darcey TM, Spencer DD, Spencer SS, Mattson RH. Occipital lobe epilepsy: Clinical characteristics, seizure spread patterns, and results of surgery. *Ann Neurol* 1992;31:3–13. <https://doi.org/10.1002/ana.410310103>.
- [8] Pestana EM, Gupta A. Ipsilateral blinking seizures during left fronto-temporal ictal pattern on scalp EEG. *Epileptic Disord* 2007;9:449–52.
- [9] Kalss G, Leitinger M, Dobesberger J, Granbichler CA, Kuchukhidze G, Trinka E. Ictal unilateral eye blinking and contralateral blink inhibition - A video-EEG study and review of the literature. *Epilepsy Behav Case Reports* 2013;1:161–5. <https://doi.org/10.1016/j.ebcr.2013.10.001>.
- [10] Jadhav T, Bailey C, Maixner W, Harvey AS. Ictal unilateral blinking is an unreliable lateralizing sign in tuberous sclerosis complex. *Epilepsy Res* 2016;125:58–61. <https://doi.org/10.1016/j.eplepsyres.2016.06.006>.
- [11] Peltola ME, Trébuchon A, Lagarde S, Scavarda D, Carron R, Metsähonkala L, et al. Anatomoelectroclinical features of SEEG-confirmed pure insular-onset epilepsy. *Epilepsy Behav* 2020;105:106964. <https://doi.org/10.1016/j.yebeh.2020.106964>.
- [12] Wang H, McGonigal A, Zhang K, Guo Q, Zhang B, Wang X, et al. Semiologic subgroups of insulo-opercular seizures based on connectional architecture atlas. *Epilepsia* 2020:1–11. <https://doi.org/10.1111/epi.16501>.
- [13] Isnard J, Taussig D, Bartolomei F, Bourdillon P, Catenoix H, Chassoux F, et al. French guidelines on stereoelectroencephalography (SEEG). *Neurophysiol Clin* 2017. <https://doi.org/10.1016/j.neucli.2017.11.005>.
- [14] Bartolomei F, Chauvel P, Wendling F. Epileptogenicity of brain structures in human temporal lobe epilepsy: A quantified study from intracerebral EEG. *Brain* 2008;131:1818–30. <https://doi.org/10.1093/brain/awn111>.
- [15] Colombet B, Woodman M, Badier JM, Bénar CG. AnyWave: A cross-platform and modular software for visualizing and processing electrophysiological signals. *J Neurosci Methods* 2015;242:118–26. <https://doi.org/10.1016/j.jneumeth.2015.01.017>.
- [16] Medina Villalon S, Paz R, Roehri N, Lagarde S, Pizzo F, Colombet B, et al. EpiTools, A software suite for presurgical brain mapping in epilepsy: Intracerebral EEG. *J Neurosci Methods* 2018;303:7–15.

- <https://doi.org/10.1016/j.jneumeth.2018.03.018>.
- [17] Bartolomei F, Cosandier-Rimele D, McGonigal A, Aubert S, Régis J, Gavaret M, et al. From mesial temporal lobe to temporoparietal seizures: A quantified study of temporal lobe seizure networks. *Epilepsia* 2010;51:2147–58. <https://doi.org/10.1111/j.1528-1167.2010.02690.x>.
- [18] Lagarde S, Buzori S, Trebuchon A, Carron R, Scavarda D, Milh M, et al. The repertoire of seizure onset patterns in human focal epilepsies: Determinants and prognostic values. *Epilepsia* 2019;60:85–95. <https://doi.org/10.1111/epi.14604>.
- [19] Marchi A, Bonini F, Lagarde S, McGonigal A, Gavaret M, Scavarda D, et al. Occipital and occipital “plus” epilepsies: A study of involved epileptogenic networks through SEEG quantification. *Epilepsy Behav* 2016;62:104–14. <https://doi.org/10.1016/j.yebeh.2016.06.014>.
- [20] Bartolomei F, Gavaret M, Hewett R, Valton L, Aubert S, Régis J, et al. Neural networks underlying parietal lobe seizures: A quantified study from intracerebral recordings. *Epilepsy Res* 2011;93:164–76. <https://doi.org/10.1016/j.eplepsyres.2010.12.005>.
- [21] Bonini F, McGonigal A, Trebuchon A, Gavaret M, Bartolomei F, Giusiano B, et al. Frontal lobe seizures: From clinical semiology to localization. *Epilepsia* 2014;55:264–77. <https://doi.org/10.1111/epi.12490>.
- [22] Bonini F, McGonigal A, Wendling F, Régis J, Scavarda D, Carron R, et al. Epileptogenic networks in seizures arising from motor systems. *Epilepsy Res* 2013;106:92–102. <https://doi.org/10.1016/j.eplepsyres.2013.04.011>.
- [23] Munari C, Bonis A, Kochen S, Pestre M, Brunet P, Bancaud J, et al. Eye Movements and Occipital Seizures in Man. *Adv. Stereotact. Funct. Neurosurg.* 6, 1984. https://doi.org/10.1007/978-3-7091-8726-5_5.
- [24] Usui N, Mihara T, Baba K, Matsuda K, Tottori T, Umeoka S, et al. Versive seizures in occipital lobe epilepsy: Lateralizing value and pathophysiology. *Epilepsy Res* 2011;97:157–61. <https://doi.org/10.1016/j.eplepsyres.2011.08.004>.
- [25] Salanova V, Andermann F, Oliver A, Rasmussen T, Quesney LF. Occipital lobe epilepsy: Electroclinical manifestations, electrocorticography, cortical stimulation and outcome in 42 patients treated between 1930 and 1991: Surgery of occipital lobe epilepsy. *Brain* 1992;115:1655–80. <https://doi.org/10.1093/brain/115.6.1655>.

- [26] Aykut-Bingol C, Bronen RA, Kim JH, Spencer DD, Spencer SS. Surgical outcome in occipital lobe epilepsy: Implications for pathophysiology. *Ann Neurol* 1998;44:60–9. <https://doi.org/10.1002/ana.410440112>.
- [27] Sang KL, Seo YL, Kim DW, Dong SL, Chung CK. Occipital lobe epilepsy: Clinical characteristics, surgical outcome, and role of diagnostic modalities. *Epilepsia* 2005. <https://doi.org/10.1111/j.1528-1167.2005.56604.x>.
- [28] Wada JA. Unilateral blinking as a lateralizing sign of partial complex seizure of temporal lobe origin. *Adv Epileptol* 1980;10:533.
- [29] Kotagal P. Complex partial seizures. *Treat. Epilepsy, Princ. Pract.*, Lippincott Williams & Wilkins; 2001, p. 309–28.
- [30] Yang PF, Jia YZ, Lin Q, Mei Z, Chen ZQ, Zheng ZY, et al. Intractable occipital lobe epilepsy: clinical characteristics, surgical treatment, and a systematic review of the literature. *Acta Neurochir (Wien)* 2014;157:63–75. <https://doi.org/10.1007/s00701-014-2217-3>.
- [31] Falsaperla R, Perciavalle V, Pavone P, Praticò AD, Elia M, Ruggieri M, et al. Unilateral Eye Blinking Arising from the Ictal Ipsilateral Occipital Area. *Clin EEG Neurosci* 2016;47:243–6. <https://doi.org/10.1177/1550059414533111>.
- [32] Liava A, Mai R, Tassi L, Cossu M, Sartori I, Nobili L, et al. Paediatric epilepsy surgery in the posterior cortex: A study of 62 cases. *Epileptic Disord* 2014;16:141–73. <https://doi.org/10.1684/epd.2014.0648>.
- [33] Williamson PD, Spencer SS. Clinical and EEG Features of Complex Partial Seizures of Extratemporal Origin. *Epilepsia* 1986;27:S46–63. <https://doi.org/10.1111/j.1528-1157.1986.tb05740.x>.
- [34] Bancaud J. Les crises épileptiques d'origine occipitale (étude stéréo-électroencéphalographique). *Rev d'Oto-Neuro-Ophthalmologie* 1969.
- [35] Villanueva V, Serratosa JM. Temporal lobe epilepsy: Clinical semiology and age at onset. *Epileptic Disord* 2005;7:83–90.
- [36] Aramideh M, Ongerboer De Visser BW. Brainstem reflexes: Electrodiagnostic techniques, physiology, normative data, and clinical applications. *Muscle and Nerve* 2002. <https://doi.org/10.1002/mus.10120>.
- [37] Ebert D, Albert R, Hammon G, Strasser B, May A, Merz A. Eye-blink rates and depression. Is the antidepressant effect of sleep deprivation mediated by the dopamine system? *Neuropsychopharmacology*

1996. [https://doi.org/10.1016/0893-133X\(95\)00237-8](https://doi.org/10.1016/0893-133X(95)00237-8).
- [38] Evinger C, Perlmutter JS. Blind men and blinking elephants. *Neurology* 2003. <https://doi.org/10.1212/01.WNL.0000067493.91199.E8>.
- [39] Dimitrova A, Weber J, Maschke M, Elles HG, Kolb FP, Forsting M, et al. Eyeblick-related areas in human cerebellum as shown by fMRI. *Hum Brain Mapp* 2002. <https://doi.org/10.1002/hbm.10056>.
- [40] Bartholow R. Experimental Investigations into the Functions of the Human Brain. *Am J Med Sci* 1874:305.
- [41] Lesser RP, Lüders H, Klem G, Dinner DS, Morris HH, Hahn J. Ipsilateral trigeminal sensory responses to cortical stimulation by subdural electrodes. *Neurology* 1985. <https://doi.org/10.1212/wnl.35.12.1760>.
- [42] Ho J, Tumkaya T, Aryal S, Choi H, Claridge-Chang A. Moving beyond P values: data analysis with estimation graphics. *Nat Methods* 2019. <https://doi.org/10.1038/s41592-019-0470-3>.

FIGURES LEGENDS

Figure 1: Proportion of patients with ictal blinking according to the seizure onset zone.

*The seizure onset zone was classified according to previous papers [14,17–22], and sorted by order of increasing number of observation. * statistically significant*

Figure 2: Example of occipito-temporal and occipital seizure with ictal blinking. **Panel A:** SEEG traces of an occipito-temporal seizures (high epileptogenicity index values in hippocampus and occipital mesial contacts). **Panel B:** 3D representation on patient's MRI of the epileptogenicity values of the occipito-temporal seizure. **Panel C:** SEEG traces of an occipital seizures (high epileptogenicity index values in occipital mesial contacts). **Panel D:** 3D representation on patient's MRI of the epileptogenicity values of the occipital seizure.

Panels A and B: A'1-2 sampled the left amygdala, B'1-2 left hippocampus, OT'2-3: left posterior para-hippocampal gyrus, GL'1-2: left lingual gyrus, GL'6-7: left lateral inferior occipital cortex, FCA'3-4: left anterior cuneus, CU'1-2: left posterior cuneus, CU'5-6: left lateral superior occipital cortex, PI'1-2: left precuneus.

Panels C and D: OT'5-6 sampled the left lingual gyrus, GPH'1-2: left posterior para-hippocampal gyrus, C'4-5: left posterior hippocampus, GC1-2: right posterior cingulum, GC5-6: right parieto-occipital fissure, GL2-3: right posterior lingual gyrus, GL9-10: right lateral occipital cortex, OT1-2: right anterior lingual gyrus, OT7-8: right posterior temporal inferior gyrus

Figure 3: Example of temporal mesial and insulo-opercular seizure with ictal blinking. **Panel A:** SEEG traces of a temporal mesial seizures (high epileptogenicity index values in amygdala, hippocampus, entorhinal and temporal pole contacts). **Panel B:** 3D representation on patient's MRI of the epileptogenicity values of the temporal mesial seizure. **Panel C:** SEEG traces of an insulo-opercular seizures (high epileptogenicity index value in middle insula contacts). **Panel D:** 3D representation on patient's MRI of the epileptogenicity values of the insulo-opercular seizure.

Panels A and B: A2-3 sampled the right amygdala, B2-3: right hippocampus, TP: right temporal pole, TB: right entorhinal cortex, H11-12: right superior temporal gyrus (posterior part), GPH1-2: right posterior para-hippocampal gyrus, GPH11-13: right inferior temporal gyrus (posterior part), Im4-5: right insula (anterior), A'1-2: left amygdala, B'1-2: left hippocampus, TB'1-2: left entorhinal cortex.

Panels C and D: A'1-2 sampled the left amygdala, Im'3-4: left middle insula, Ip'3-4: left posterior insula, OP'1-2: left posterior-superior insula, OP'5-6: left parietal operculum, PI'1-2: left precuneus, PI'10-11: left inferior parietal lobule.

Figure 4: Speed of ictal blinking according to the SOZ

OI = operculo-insular, O = occipital, OT = occipito-temporal, TM = temporal mesial

Figure following the method from [42]

Fig 1

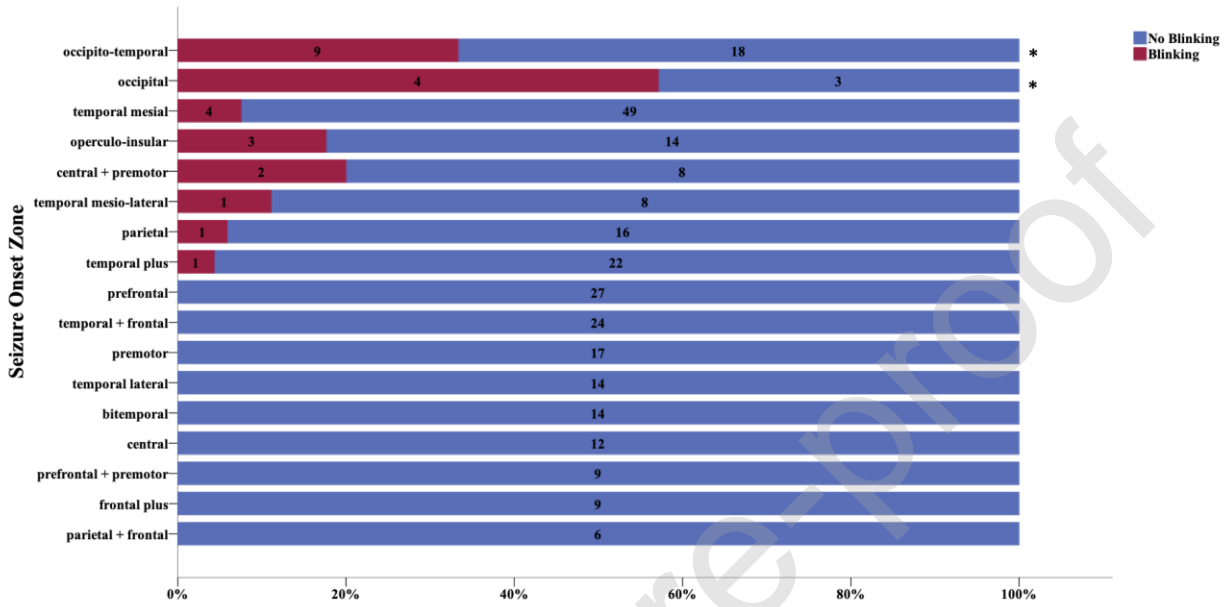


Fig 2

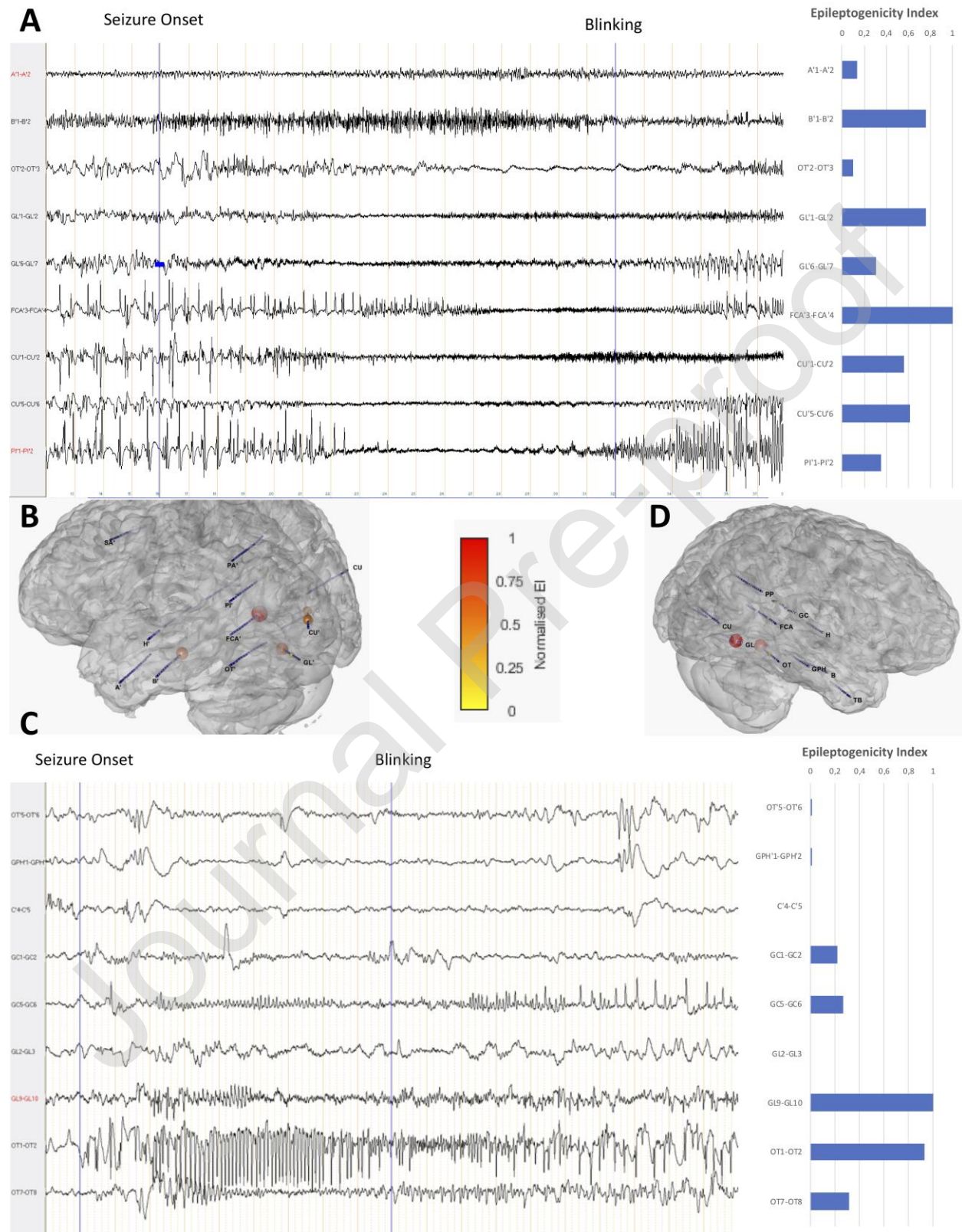


Fig 3

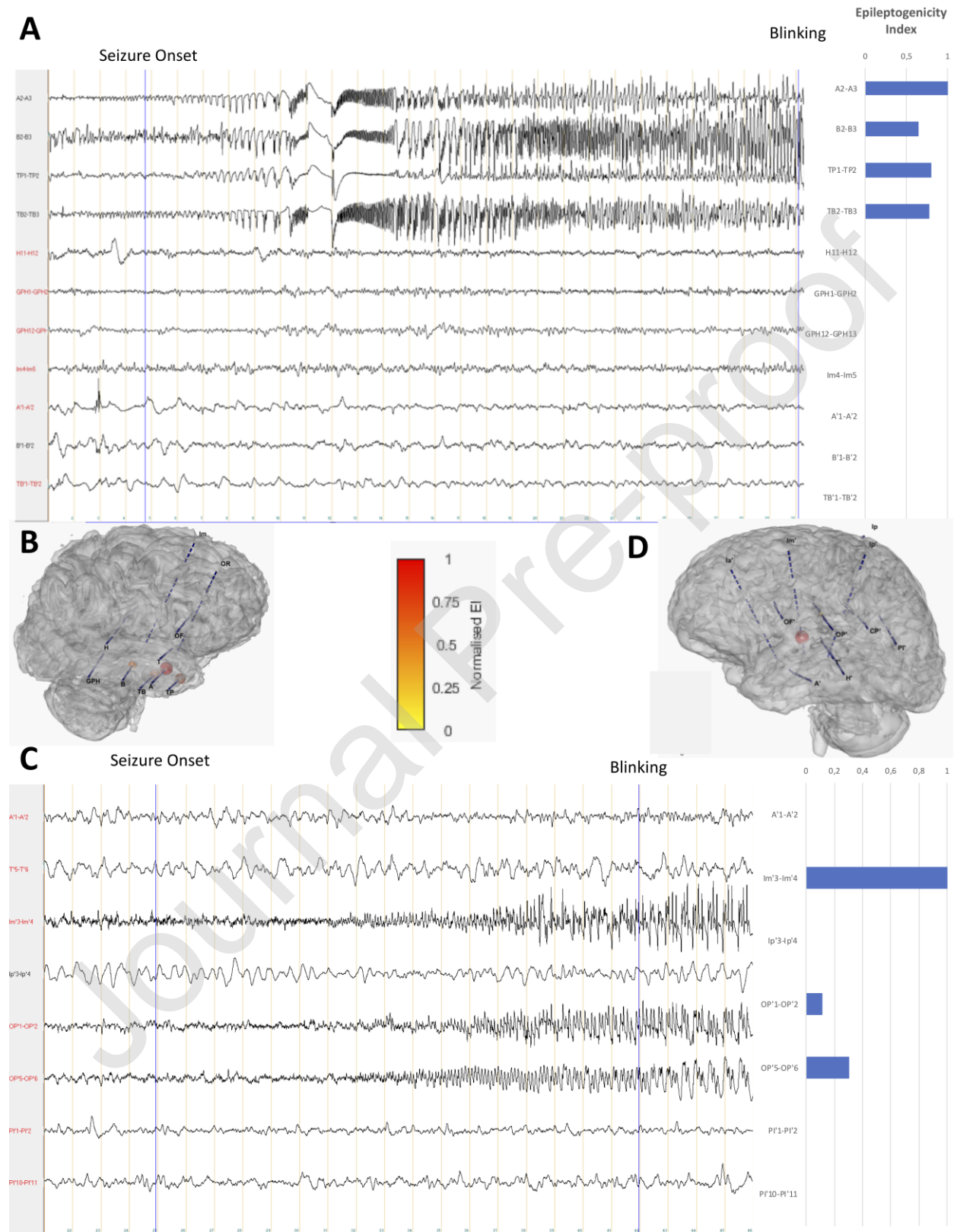
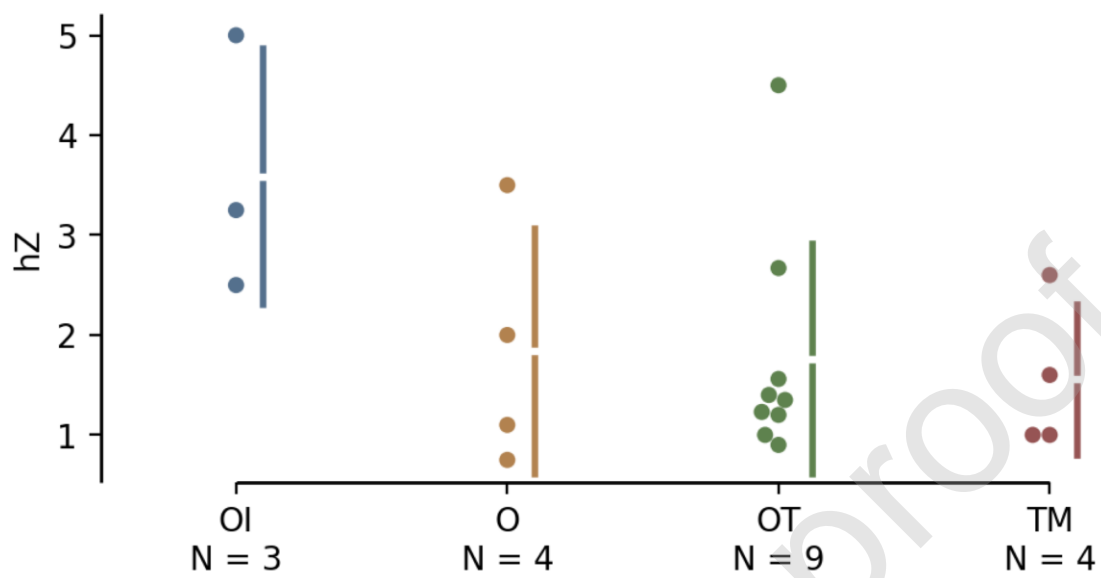


Fig 4



TABLE

Table 1: Comparison of clinical variables between patients with and without blinking

For aetiology and epilepsy type (SOZ), only categories with observed blinking is reported. The seizure onset zone (SOZ) was classified according to previous papers [14,17–22], * statistically significant association, FCD= focal cortical dysplasia, NDT = neurodevelopmental tumours, % = proportion within the populations of patients with and without.

CATEGORICAL VARIABLES				
Variables	Categories	Blinking	No Blinking	p-value (Fisher exact test)
		n (%)	n (%)	
Gender	Female	25 (8.3)	276 (91.7)	0.836
MRI	Positive	19 (76)	208 (75.4)	1
Aetiology	FCD	11 (44)	86 (31.2)	0.95
	Undetermined	6 (24)	72 (26.1)	
	Post-stroke	2 (8)	25 (9.1)	
	NDT	2 (8)	23 (8.3)	
	Hippocampal Sclerosis	2 (8)	19 (6.9)	
	Heterotopia	2 (8)	8 (2.9)	
Epilepsy Type (SOZ)	Temporal Mesial	4 (16)	49 (17.8)	<0.001*
	Occipital + Temporal *	9 (36)	18 (6.5)	
	Temporal plus	1 (4)	22 (8)	
	Insulo-Opercular	3 (12)	14 (5.1)	
	Parietal	1 (4)	16 (5.8)	
	Central + Premotor	2 (8)	8 (2.9)	
	Temporal Mesial +	1 (4)	8 (2.9)	
	Lateral	4 (16)	3 (1.1)	
	Occipital *			
NUMERICAL VARIABLES				
Variables		Blinking Median (SD)	No Blinking Median (SD)	P-value (Mann-Whitney U test)
Age at Seizure onset (years)		7 (9)	5 (8)	0.213
Age at SEEG (years)		25 (14)	25 (13)	0.601
Duration of epilepsy (years)		14 (10.75)	15 (11.8)	0.802

Table 2: Features of ictal blinking according to the seizure onset zones*Data from the four most frequent SOZ (total of 20 seizures)*

Variables	Categories	Seizure Onset Zones			
		Occipital (n=4)	Occipito-temporal (n=9)	Insulo-opercular (n=3)	Temporal mesial (n=4)
Lateralization	Bilateral	4	9	3	4
Version	No	4	7	3	3
	Yes (<i>ipsilateral</i>)	0	2	0	1
Nystagmus	No	3	7	3	4
	Yes	1	2	0	0
Tonic Eye Deviation	No	4	7	3	4
	Yes (<i>contralateral</i>)	0	2	0	0
Delay (mean, sec)		40	16	30	31
Speed (mean, Hz)		1.84	1.76	3.58	1.55