HAL open science

# Bilateral sagittal split osteotomy training on mandibular 3-dimensional printed models for maxillofacial surgical residents

H. Bertin, J.-F. Huon, M. Praud, F. Fauvel, J.-M. Salagnac, J.-P. Perrin, J.-M. Mercier, P. Corre

## To cite this version:

H. Bertin, J.-F. Huon, M. Praud, F. Fauvel, J.-M. Salagnac, et al.. Bilateral sagittal split osteotomy training on mandibular 3-dimensional printed models for maxillofacial surgical residents. British Journal of Oral and Maxillofacial Surgery, 2020, 10.1016/j.bjoms.2020.04.039 . hal-02892540

**HAL Id: hal-02892540**

**https://hal.science/hal-02892540v1**

Submitted on 21 Sep 2022

**HAL** is a multi-disciplinary open access archive for the deposit and dissemination of scientific research documents, whether they are published or not. The documents may come from teaching and research institutions in France or abroad, or from public or private research centers.

L'archive ouverte pluridisciplinaire **HAL**, est destinée au dépôt et à la diffusion de documents scientifiques de niveau recherche, publiés ou non, émanant des établissements d'enseignement et de recherche français ou étrangers, des laboratoires publics ou privés.

Distributed under a Creative Commons Attribution - NonCommercial 4.0 International License

Version of Record: https://www.sciencedirect.com/science/article/pii/S0266435620301935
Manuscript_6c046e8f1b24bab59fccd4710a221b9e

## TITLE

Bilateral sagittal split osteotomy training on mandibular three-dimensional-printed models for maxillofacial surgery residents

## AUTHOR NAMES AND AFFILIATIONS

Hélios Bertin[a,b]* (MD, PhD Student)
helios.bertin@chu-nantes.fr
Tel: +33 (0)2 40 08 36 79
Fax: +33 (0)2 40 08 36 68
* Corresponding author

Jean-François Huon[c] (Pharm D, PhD)
jeanfrancois.huon@chu-nantes.fr

Morgan Praud[a] (Mr)
morgan.praud@chu-nantes.fr

Fabien Fauvel[d] (MD)
fabien.fauvel@hotmail.fr

Jean-Michel Salagnac[a] (MD)
jeanmichel.salagnac@chu-nantes.fr

Jean-Philippe Perrin[a] (MD)
jeanphilippe.perrin@chu-nantes.fr

Jacques-Marie Mercier[a] (MD)
jacques.mercier@chu-nantes.fr

© 2020 published by Elsevier. This manuscript is made available under the CC BY NC user license
https://creativecommons.org/licenses/by-nc/4.0/

Pierre Corre[a,e] (MD, PhD)
pierre.corre@chu-nantes.fr

[a] Service de chirurgie Maxillo-faciale et stomatologie, CHU de Nantes, 1 place Alexis Ricordeau, 44093 Nantes Cedex 1, France.
[b] Laboratoire des sarcomes osseux et remodelage des tissus calcifiés (Phy.OS), UMR 1238, Faculté de médecine, 1 rue Gaston Veil, 44035 Nantes cedex, France.
[c] Service de pharmacie clinique, CHU de Nantes, 1 place Alexis Ricordeau, 44093 Nantes Cedex 1, France
[d] Service de chirurgie Maxillo-faciale et stomatologie, CH de Saint-Nazaire, 11 boulevard Georges Charpak, 44600 Saint-Nazaire, France
[e] Laboratoire d'Ingénierie Ostéo-Articulaire et Dentaire (LIOAD), Faculté de Chirurgie Dentaire, 1 Place Alexis Ricordeau, 44042Nantes, France

# Bilateral sagittal split osteotomy training on mandibular 3-dimensional printed models for maxillofacial surgical residents


## Abstract

Complications with bilateral sagittal split osteotomy (BSSO) can sometimes result from surgical inexperience. Our aim was to present a 3-dimensional printed mandibular model for BSSO training in a maxillofacial surgical education programme. A polymethacrylate mandibular model obtained from mandibular cone-beam computed tomographic (CT) images was designed and printed for use in training. Twenty-four residents were each asked to do a BSSO according to the Epker/Dal-Pont technique. The session was conducted as a simulation course with a final debriefing. A questionnaire before and after the test was filled in using a 10-point Likert scale to assess the participants' knowledge. The mandibular model provided a realistic way of handling the trabecular bone after cortical osteotomy, as well as in the splitting phase. Significant increases in knowledge and surgical skills were noted for all steps of the BSSO, particularly regarding the use of the piezoelectric device for osteotomy, and for management of wisdom teeth in the splitting zone (3.00 (2.16) to 6.95 (2.06) and 2.73 (1.91) to 5.75 (2.63), respectively; $p_1$=0.0002 and $p_2$=0.0003). We think that this is a valuable printed mandibular model for the development of surgical skills for BSSO in maxillofacial surgical residents.



**Keywords:** Orthognathic surgical procedure; education; models; 3D printing

## Introduction

Bilateral sagittal split osteotomy (BSSO) is the most common surgical procedure used to correct mandibular deformities .[1-3] Although it is a standard, safe procedure, it can lead to perioperative complications,[4,5] among which injury to the inferior alveolar nerve (IAN),[6,7] condylar resorption,[6] and bad splitting [8,9] are the most common, occurring in 0-80%, 1%-31%, and 3%-23%, respectively. Non-union, relapse, damage to teeth, infections, and bleeding complications are quite rare. [6,10]A lack of surgical experience and skills are known to be associated with a higher risk of such complications, particularly regarding recovery of the sensitivity of the IAN. [11,12]

In surgery "learning by doing" remains the best way for residents to acquire the skills required to manage and treat patients properly. [13] However, technical interventions require such skills to be acquired before the procedures are undertaken with actual patients. [1,11] Simulation has been well-described for anaesthesia, intensive care, and general surgery residents, [14,15] but there have been few reports of it in maxillofacial surgical training. [16] Nevertheless, simulation-based training has been shown to increase surgical skills without risk to the patient, while it also reduces operating time and the number of complications.[11,17,18]

The use of 3-dimensional printed models as educational tools has been mainly described for sinus surgery, dental extractions, bone grafting, and repair of clefts,[11,16,18] and such models are also commonly used for planning and training in mandibular reconstruction and difficult orthognathic procedures. [2,19]As far as we know no report has yet been published about the use of 3-dimensional models to teach BSSO.

The aim of this paper was to describe and evaluate a BSSO training programme for maxillofacial surgical residents using a 3D-printed manufactured mandibular model.

## Material and methods

*Conception and fabrication of the model*

*Requirement specification:* a custom-made mandibular model was designed using rapid prototyping techniques. To create a realistic model for BSSO, we used the following criteria: compliance with normal mandibular anatomy; identifiable anatomical structures - particularly the lingula, the external oblique ridge, and the mental foramen; and rigid cortical, and soft medullary, bones to allow for realistic splitting of the mandible.

*Phantom design:* the phantom was designed using high-resolution cone-beam computed tomographic (CT) data from two patients (field of view 120 x 120 mm, focused on the mandible, 110 kV, the tube current and exposure time were modulated according to the scout views). The cone-beam CT device used for acquisition of images was a wide-field model (NewTom VGI, QR). The selected mandibular specimen had a normal anatomy and came from two patients who had had BSSO to correct a Class II malocclusion; for one, the mandibular wisdom teeth were included in the mandibular ramus. Creation of the phantom started with the importing of the cone-beam CT image into 3-dimensional visualisation Anatomaker software (3D-Medlab). The lower jaw was segmented based on the voxel intensity using techniques incorporating global thresholding. The segmented mandible was then converted to a mesh model using Netfabb® software (Autodesk), then saved as a stereo lithography (STL) file and sent to a 3-dimensional printer software (Objet studio, Stratasys) to manage the 3-dimensional printing.

*Fabrication:* both the anatomical models were printed using PolyJet technology with a Connex 3260 3D printer (Stratasys). A mix of polymethacrylate resin was used to produce the models and to try to reproduce the mechanical characteristics of the natural mandible (such as the cortical and medullary bones, and the mandibular canal) (Support Soluble, FullCure 706

& VeroWhite Plus FullCure 835). The design time, including importing the CT images, segmentation, and export of the STL file took roughly two hours for both the inferior jaws. The 3-dimensional printing time for a mandible was around six to eight hours, depending on the model being studied. The cost of the fabrication was US$155 (ex-VAT). The models were tested and approved by three senior surgeons before they were used with maxillofacial surgical residents.

*Session:* a two-day national training programme for BSSO was scheduled at the maxillofacial surgery unit of Nantes University Hospital. Over two half-days, the residents were given several lectures and practical teaching about orthognathic mandibular surgery, cephalometric planning, and the manufacture of occlusal splints. For the simulation during one half-day, each resident had a 3-dimensional printed mandible, a high-speed surgical drilling system (NSK France SAS), or a piezoelectric device (NSK), and all the surgical materials necessary to do a BSSO (including a Bein dental elevator, periosteal elevators, straight osteotomes, a bone chisel, and Tessier expansion forceps) and fixation (Delphos Implants SA). They were asked to do a BSSO according to the Epker/Dal Pont technique with the standard steps: drawing of reference points; cutting (bud burr or piezoelectric) the cortical bone; additional "cut through" osteotomy of the medullary bone with an osteotome or bone chisel; splitting the mandible; and fixation with an osteosynthesis device. Assistance from a senior supervisor was available at each stage, and a final evaluation of the procedure was made for each participant.

*Evaluation*

Two separate questionnaires were filled in to check the validity of our models and our teaching course: one before the intervention to evaluate the theoretical knowledge of the participants, and one after the intervention for feedback. A 10-point Likert scale was used to

rate each question (Table 1). The significance of the differences was analysed by a Wilcoxon test for paired observations using GraphPad Prism (version 5.0).

## Results

*Epidemiological data*

Twenty-four residents from seven different medical centres participated in our training program. Seven students were in their third year of residency, five in their second year, and five in their fourth year, while three and four of them, respectively, were in their first or last year of residency. **AQ: the percentages have been omitted as the journal does not publish them unless n>100 (see item 5 on your email of provisional acceptance).**

The pretest survey was completed by 22 of the students, and results indicated that most of the residents were satisfied with their level of experience with the surgical instruments required for the BSSO procedure, and with the first steps of the technique (including identification of the lingula) irrespective of their level of experience, with mean self-assessment scores for these items of 5.68 (1.91), and 5.09 (2.09), respectively. The residents were less confident of their skills as far as the osteotomy was concerned, particularly regarding the use of a piezoelectric device. Similar findings were obtained for mandibular splitting, management of the wisdom tooth and the IAN, and the osteosynthesis (Table 2).

*Training on mandibular models*

The 3-dimensional printed models allowed BSSO to be done according to the Epker/Dal Pont technique, irrespective of the device (a bud burr or piezoelectric device) used for the osteotomy (Fig. 1). The model proved to be realistic in terms of handling the hard cortical bone and soft trabecular bone during the osteotomy. The splitting phase with a Bein elevator positioned at the mandibular basal border was equally lifelike in terms of handling and

sounding. A bad split occurred in approximately one-third of cases and could be explained by a poor cortical osteotomy, mainly in the lingula and the basal border. The presence of the wisdom tooth in the mandibular ramus was an additional difficulty, which could be overcome by an additional tooth section and splitting, as in real life. The hardness of the third molar was easy to recognise in the soft cancellous bone of the mandible. Mandibular fixation with miniplates was no problem and resembled real-life conditions (Fig. 2).

*Evaluation of the course*

The residents reported an improvement in their surgical skills for BSSO, as reflected by the significant increase in the self-assessment scores after completion of the training course (Table 2). Osteotomy with a piezoelectric device, and management of the wisdom tooth, were particularly improved by participation in the workshop (Fig. 3). The mean score increased from 4.33 to 6.59, which indicated an increase of roughly a third in knowledge and skills.

## Discussion

The importance of learning by having surgical training is underscored by the fact that a surgeon's error rate for a procedure declines as the number times that they do the procedure increases. [13] As well as classroom teaching and instruction by a senior faculty member in the operating room, various models can be used to acquire surgical skills. However, the use of cadaveric or animal models gives rise to availability, biosafety, and ethical considerations.[19] (19) Digital and mannequin simulations have, therefore, progressively become part of maxillofacial surgical educational programmes. [11,14,16,18]In a recent study, Maliha et al identified 22 simulators based on the use of a virtual reality haptic simulator, physical models, and web-based simulators. [16]The virtual reality and haptic-based simulators allow the trainees to gain experience doing an orthognathic procedure in a virtual patient, [20,21] but they

fail to reflect reality properly, particularly in terms of surgical instruments and clinical accuracy. [16] Web-based simulators are an interesting tool on which to learn the main stages of an orthognathic intervention, but they fail to reflect the surgeon's technical involvement and the operating environment adequately.

Phantom heads have been used for many years in dental training programmes.[17] In maxillofacial surgery, printed models have been described in educational programmes for sinus lifts and third molar extractions, [11] endoscopic sinus surgery, craniofacial reconstruction,[19] and cleft repair.[18] Most authors suggest that stereolithographic models should be used in residency training, but such models are mainly used in simulation and planning of complex orthognathic procedures [2] or mandibular reconstructions. [19,22]

Here we have described a mandibular 3- dimensional printed model and its use for a trainee simulation programme of BSSO, and to our knowledge this is the first published description of such a programme. Despite the absence of biomechanical studies, our model proved to be realistic in terms of the procedures involved in an Epker/Dal Pont osteotomy, from the bone-cutting stage to the osteosynthesis, as it accurately reflected real-life conditions and, despite an elaborate manufacturing process, the production cost was not excessive (US$ 155).

As described by Werz et al, printed models have led to the concept of "personalised medicine", whereby individual patients can be transformed in a training model.[11] In our specific case, we used the cone-beam CT data from two different patients who had BSSO to correct malocclusion. Despite the quality being lower than that of a CT scan in terms of virtual planning, we did not experience problems with the numerical segmentation step. In one case, the wisdom teeth were included in the mandibular ramus to introduce a degree of difficulty to the osteotomy, which helps the trainees tackle such clinical conditions, and our model allowed the residents to develop their surgical skills in the use of two different devices

for cutting the bone (a high-speed bud burr and piezoelectric technology), and how to manage the osteosynthesis. However, the model illustrates only the bony anatomy, irrespective of the attached soft tissues, which precludes the incision and the first steps of detachment of the muscle. The mandibular condyle was also not jointed to the base of the skull. Condylar positioning is an essential stage during BSSO to obtain functional results and to avoid postoperative temporomandibular dysfunction. [3]

The advantages and drawbacks of our model are listed in Table 3. Future printed models should be refined to expose a connection between the condyle and the glenoid fossa; these models should also have a coated gum and a coloured mandibular nerve structure in addition to being embedded in a phantom head, to better recapitulate the difficulty of an intra-oral approach. Such new models should be compared with normal mandibular bone in terms of mechanical properties (such as resistance and elasticity).

Simulation is based on three key steps: an upstream framework; the simulation session; and a debriefing period. [14,15] Our training programme met these three requirements as each trainee was provided with a systematic analysis of the reasons for success or failure of the osteotomy. The residents who participated in the session completed a questionnaire before and after the test, which showed that there was a significant increase in knowledge and surgical skills as a result of having practiced the BSSO technique. Based on the self-assessment questionnaires, most of the residents were confident of their skills with the first steps of the technique until the bone osteotomy, as they probably usually do these stages on patients. However, they were less sure when it came to the osteotomy, splitting, and fixation, which are probably usually done by a senior surgeon. This highlights the relevance of simulation of all the steps of BSSO in physical models. Unfortunately our questionnaire was not standardised to validate the relevance of our teaching and learning methods.

Most reports of maxillofacial surgical simulation programmes have been descriptive, and have lacked scientific evidence of their validity.[16] Further studies are needed to assess the efficacy of 3-dimensional printed models as educational tools for BSSO in maxillofacial surgery, and to compare them with other methods of learning.

## Conclusion

Our 3-dimensional printed mandibular model seems to be useful for maxillofacial surgical residents to obtain experience and skills for the management of bilateral sagittal split osteotomy.


## Acknowledgements

We thank Dr Jean-Yves Gagner and Stéphane Guerraud (Agence Régionale de Santé des Pays de la Loire), NSK, SANOFI, and Delphos Implants SA for their material and human support for this national training program. We thank Mr. Pierre-Emmanuel Menuet (3D-Medlab company). We also thank Mrs. Sophie Domingues for her careful reading and correction of the English version of this manuscript.

This training programme received funding from the Agence Régionale de Santé (ARS) des Pays de la Loire (French Ministry of Health). The sponsor had no role in the study design, collection, analysis, or interpretation of data, nor in the writing of the manuscript or in its submission for publication.


## Conflict of interest

None

**Ethics statement/confirmation of patient permission**

No ethics approval required. No patient consent needed.

**QUERIES TO AUTHOR**

**Throughout : the journal is published in British English so any American phraseology or spelling has been corrected.**

**Page 5 : the percentages have been omitted as the journal does not publish them unless n>100 (see item 5 on your email of provisional acceptance).**

**Legend to Fig. 3 : Please give exact p value.**

**References**


1. Arikatla VS, Tyagi M, Enquobahrie A, et al. High fidelity virtual reality orthognathic surgery simulator. *Proc SPIE Int Soc Opt Eng* 2018;10576.

2. Erkan M, Ulkur E, Karagoz H, et al. Orthognathic surgical planning on three-dimensional stereolithographic biomodel. *J Craniofac Surg* 2011;**22**:1336-41.

3. Savoldelli C, Chamorey E, Bettega G. Computer-assisted teaching of bilateral sagittal split osteotomy: Learning curve for condylar positioning. *PloS One* 2018;**13**:e0196136.

4. Sofronia RE, Knott T, Davidescu A, et al. Failure mode and effects analysis in designing a virtual reality-based training simulator for bilateral sagittal split osteotomy. *Int J Med Robot* 2013;**9**:e1-9.

5. Jędrzejewski M, Smektała T, Sporniak-Tutak K, et al. Preoperative, intraoperative, and postoperative complications in orthognathic surgery: a systematic review. *Clin Oral Investig* 2015;**19**:969-77.

6. Panula K, Finne K, Oikarinen K. Incidence of complications and problems related to orthognathic surgery: a review of 655 patients. *J Oral Maxillofac Surg* 2001;**59**:1128-37.

7. Ylikontiola L, Kinnunen J, Oikarinen K. Factors affecting neurosensory disturbance after mandibular bilateral sagittal split osteotomy. *J Oral Maxillofac Surg* 2000;**58**:1234-40.

8. Kriwalsky MS, Maurer P, Veras RB, et al. Risk factors for a bad split during sagittal split osteotomy. *Br J Oral Maxillofac Surg* 2008; **46**:177-9.

9. Teltzrow T, Kramer FJ, Schulze A, et al. Perioperative complications following sagittal split osteotomy of the mandible. *J Craniomaxillofac Surg* 2005;**33**:307-13.

10. Spaey YJ, Bettens RMA, Mommaerts MY, et al. A prospective study on infectious complications in orthognathic surgery. *J Craniomaxillofac Surg* 2005;**33**:24-9.

11. Werz SM, Zeichner SJ, Berg BI, et al. 3D Printed surgical simulation models as educational tool by maxillofacial surgeons. *Eur J Dent Educ* Aug 2018;**22**:e500-5.

12. Al-Nawas B, Kämmerer PW, Hoffmann C, et al. Influence of osteotomy procedure and surgical experience on early complications after orthognathic surgery in the mandible. *J Craniomaxillofac Surg* 2014;**42**:e284-8.

13. Fahmy MD. Teaching in oral and maxillofacial surgery training programs: a resident's perspective. *J Oral Maxillofac Surg* 2018;**76**:2461-2.

14. Coffey-Zern S, Calvi RMD, Vorrasi JS, et al. Incorporating simulation into oral and maxillofacial surgery residency education and training: Christiana Care's method. *J Oral Maxillofac Surg* 2015;**73**:1244-5.

15. Levraut J, Fournier JP. Never the first time on the patient. *Annales Francaises de Medecine d'Urgence* 2012;**2**:361-3 (paper in French).

16. Maliha SG, Diaz-Siso JR, Plana NM, et al. Haptic, physical, and web-based simulators: are they underused in maxillofacial surgery training? *J Oral Maxillofac Surg* 2018;**76**:2424.e1-2424.e11.

17. Ahmed N, McVicar IH, Mitchell DA. Simulation-based training in maxillofacial surgery: are we going to be left behind? *Br J Oral Maxillofac Surg* 2019;**57**:67-71.

18. Lioufas PA, Quayle MR, Leong JC, et al. 3D Printed models of cleft palate pathology for surgical education. *Plast Reconstr Surg Glob Open* 2016;**4**:e1029.

19. Chan HHL, Siewerdsen JH, Vescan A, et al. 3D Rapid prototyping for otolaryngology-head and neck surgery: applications in image-guidance, surgical simulation and patient-specific modeling. *PloS One* 2015;**10**:e0136370.

20. Sohmura T, Hojo H, Nakajima M, et al. Prototype of simulation of orthognathic surgery using a virtual reality haptic device. *Int J Oral Maxillofac Surg* 2004;**33**:740-50.

21. Pulijala Y, Ma M, Pears M, et al. An innovative virtual reality training tool for orthognathic surgery. *Int J Oral Maxillofac Surg* 2018;**47**:1199-205.

22. Dziegielewski PT, Zhu J, King B, et al. Three-dimensional biomodeling in complex mandibular reconstruction and surgical simulation: prospective trial. *J Otolaryngol Head Neck Surg* 2011;**40** (Suppl 1):S70-81.

**Legends to Figures**

**Figure 1.** Photograph of a cortical bone osteotomy done with the piezoelectric device on the right external oblique ridge.

**Figure 2.** Photograph of an osteosynthesis of the left mandibular sagittal split osteotomy using a four-hole, 1-mm miniplate.

**Figure 3.** The self-assessment questionnaire used to evaluate the surgical skills for bilateral sagittal split osteotomy on a 10-point Likert scale, before (dark grey) and after (light grey) participation in the training programme. All the differences are significant (Wilcoxon test, p = **0.0??). AQ: please give exact p value.**

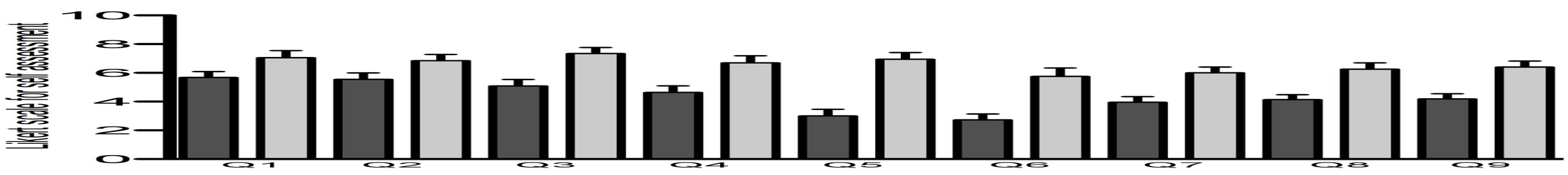
Likert scale for self assessment
10
8
6
4
2
0
Q1
Q2
Q3
Q4
Q5
Q6
Q7
Q8
Q9

Table 1
Questionnaire given before and after the test to the residents who took part in the training for bilateral sagittal split osteotomy (BSSO) on 3-dimensional printed models.

---

Rate your level of experience of bilateral sagittal split osteotomy in the following:

- Surgical instruments required
- Identification of the lingula
- Osteotomy with a bud burr
- Osteotomy with a piezoelectric device
- Management of the wisdom tooth in the splitting zone
- Surgical splitting of the mandible
- Management of the inferior alveolar nerve
- Mandibular fixation with miniplates

---

Table 2.

Results of the questionnaire given before and after the test to the residents who took part in the training for bilateral sagittal split osteotomy on 3-dimensional printed models.

| Question | Before | After | p Value |
|---|---|---|---|
| Surgical instrument required | 5.68 (1.91) | 7.05 (2.24) | 0.0032 |
| Identification of the lingula | 5.09 (2.09) | 7.35 (1.84) | 0.0003 |
| Osteotomy with a bud bur | 4.64 (2.17) | 6.70 (2.18) | 0.0003 |
| Osteotomy with a piezoelectric device | 3.00(2.16) | 6.95 (2.06) | 0.0002 |
| Management of the wisdom tooth | 2.73 (1.91) | 5.75 (2.63) | 0.0003 |
| Splitting of the mandible | 3.96 (1.84) | 6.00 (1.81) | 0.0001 |
| Management of the inferior alveolar nerve | 4.14 (1.61) | 6.25 (1.99) | 0.0002 |
| Mandibular fixation | 4.18 (1.68) | 6.40 (1.88) | 0.0002 |

Table 3.

Advantages and drawbacks of the mandibular printed model.

---

**Advantages** :

Personalised mandibular model from real patients

Easy to design and manufacture

Acceptable cost (US$ 155)

Realistic feel (hard cortical bone, soft trabecular bone, splitting phase

Evaluation by three senior surgeons and 22 residents

**Drawbacks** :

Created from cone-beam computed tomographic (CT) images (lower segmentation quality than CT scan)

No soft tissue and gum envelope

No connection between condyle and glenoid fossa

Mandibular nerve not tagged

No embedding of phantom head

No biomechanical comparison with normal mandible

---