



HAL
open science

Distal biceps tendon repair via new knotless endobutton fixation: A biomechanical study

Victor Rutka, Florent Weppe, Sonia Duprey, Laure-Lise Gras

► To cite this version:

Victor Rutka, Florent Weppe, Sonia Duprey, Laure-Lise Gras. Distal biceps tendon repair via new knotless endobutton fixation: A biomechanical study. *Shoulder & Elbow*, 2021, 13 (3), 23p. 10.1177/1758573219864303 . hal-02889002

HAL Id: hal-02889002

<https://hal.science/hal-02889002>

Submitted on 7 Jul 2020

HAL is a multi-disciplinary open access archive for the deposit and dissemination of scientific research documents, whether they are published or not. The documents may come from teaching and research institutions in France or abroad, or from public or private research centers.

L'archive ouverte pluridisciplinaire **HAL**, est destinée au dépôt et à la diffusion de documents scientifiques de niveau recherche, publiés ou non, émanant des établissements d'enseignement et de recherche français ou étrangers, des laboratoires publics ou privés.

Distal Biceps repair. A biomechanical study

1 **Distal biceps tendon repair via new knotless endobutton**
2 **fixation: a biomechanical study**

3

4 Victor Rutka¹, MD, Florent Weppe¹, MD, Sonia Duprey², PhD, Laure-Lise Gras², PhD

5

6 ¹ Lyon Ortho Clinic / Centre de la Main Sauvegarde 29B avenue des Sources 69009 LYON,

7 France

8 ² Univ Lyon, Université Claude Bernard Lyon 1, IFSTTAR, LBMC UMR T9406, F69622

9 Lyon, France

10

11 E-mail address for corresponding author: victor.rutka@gmail.com

12

13 **Keywords:** Distal Biceps repair; Elbow; Tendon injuries; tensile strength; biomechanics;

14 Cortical button.

15 **Abstract**

16 Background: Distal biceps tendon (DBT) repair using endobutton fixation has shown the
17 best biomechanical results in terms of pullout strength. Sethi's enhanced tension adjustable
18 endobutton technique known as the « tension slide technique » (TST) decreases the gap
19 between bone tunnel and graft. Here we compared the TST to a new knotless endobutton
20 fixation technique without a post-fixation screw. Our new approach is as effective as the TST
21 in terms of pullout strength and gapping after early mobilization.

22 Methods: A biomechanical cadaveric study with 8 specimens was performed (16 arms).
23 Right and left arms were paired and each arm was placed in either the knotless or the TST
24 group. With the radius held in place, the DBT was loaded at 100 N for 500 cycles and the load
25 was then increased until failure. Gapping after loading cycles and maximum load to failure
26 were recorded and compared.

27 Results: Median bone-tendon gapping was 5.77 mm [interquartile range (IQR) 4.84-9.11]
28 for TST and 4.72 mm [IQR 1.77-6.16] for the knotless fixation ($p = 0.047$). Median load to
29 failure was 257.87 N [IQR 222.07-325.35] in the TST group and 407.78 N [IQR 358.54-
30 485.20] in the knotless group ($p = 0.047$).

31 Discussion: The knotless endobutton is a reliable fixation technique for DBT repair. It
32 provides good pullout strength compared to the TST without the use of an interference screw,
33 allowing early mobilization in order to faster return to daily living activities.

Commentaire [DS1]: Higher?

34

35 Level of evidence: Basic science study.

36

37 **Introduction**

38

39 Distal biceps tendon ruptures mainly affect a population between 40 and 60 years old.
40 Representing 3% of biceps lesions, they generally occur during an eccentric load¹. If not
41 surgically repaired, these lesions lead to loss of strength and range of motion². A strong and
42 safe fixation is required to enable, after surgery, immediate and active mobilization and thus
43 better and faster functional outcomes^{3,4}.

44 The current literature is as yet unable to single out any fixation technique as preferable in
45 terms of clinical results⁵⁻⁸. However, several biomechanical studies have shown that
46 endobuttons perform better on pullout strength than other fixations⁹⁻¹². The original method
47 described by Bain (2000)¹³ was subsequently improved by Sethi (2008)¹⁴ using the so called
48 Tension Slide Technique (TST). Sethi's technique allows for the ability to tension and dock
49 the repair through an anterior incision. Hence there is no need to predetermine the length of
50 the suture between the button and the biceps, it eliminate the technical concern for the button
51 flipping and it reduce the gap between the bone tunnel and the distal graft extremity¹⁵.
52 However after docking the tendon into the bone one suture end have to be passed through the
53 tendon to secure it. Securing the knot can be challenging in muscular patients and knots have
54 to be tied in a shoulder arthroscopic fashion to ensure a good knot fastening. Sethi's also
55 inserted an interference screw to secure the tendon in high demand patients. The method
56 presented here uses Sethi's concept but involves a knotless endobutton with a looped suture,
57 without interference screw, making it easier to use. There is only one published study so far to
58 have used a similar device¹⁶.

Distal Biceps repair. A biomechanical study

59 Our hypothesis was that our original distal biceps tendon repair technique using knotless
60 fixation was at least equivalent to the TST in terms of pullout strength and gapping at
61 physiological tension.

62

63 **Materials and Methods**

64

65 Eight fresh cadavers (5 females, 3 males, 87.25 ± 3.79 yo) were selected according to
66 specimen availability (Table 1). The right and left elbow of the same specimen were paired to
67 avoid any inter-individual variability. Each specimen's arm was randomly assigned to the
68 TST or knotless group.

69

70 **Surgical technique**

71

72 Specimens were placed in a supine position with the forearm on a hand table. Using an
73 anterior approach, a 4 cm longitudinal incision centered on the radial tuberosity was made. A
74 C-arm was used to center the incision on the radial tuberosity. The biceps tendon was then cut
75 from its footprint and a 2 cm proximal incision was made to allow tendon preparation.
76 Tendon length was then measured.

77 Sethi's technique using the BicepsButton™(Arthrex™, Naples, FL, USA) and n°2
78 Fiberloop® (Arthrex™, Naples, FL, USA) device to prepare the tendon has already been
79 described in detail¹⁴. In our modified technique, the graft was prepared with a braided pre-
80 looped suture n°5 Niceloop® (Tornier™-Wright™, Memphis, TN, USA). The suture was
81 whipstitched through the tendon from proximal to distal, starting at 35mm from the distal free
82 end of the tendon. Four to five loops were made through the tendon before passing it through
83 the loop of the knotless endobutton (Ziploop®, Zimmer-Biomet™, Warsaw, IN, USA). The
84 device was then secured to the distal end of the graft by passing the suture through the tendon
85 in backward direction, from distal to proximal three times more. The needle was cut and the
86 two free ends of the suture were tied on the graft (Fig.1).

87 A perpendicular or slightly radio-humeral direction was chosen for the bone tunnel to
88 reduce posterior interosseous nerve lesions while drilling¹⁷. The tunnel was placed as ulnarly
89 as possible, to preserve the cam effect of the radial tuberosity¹⁸. A pin guide and then a 4.5
90 mm bicortical tunnel were performed with a cannulated drill. Next, a second drill with a
91 diameter corresponding to the tendon diameter was used to go through the first cortical. The
92 endobutton was then pulled through the second cortical and into the bone tunnel by
93 alternatively pulling on the 2 sutures. At this point, a scopic control was performed. Our self-
94 locking system was knotless and didn't require a post-fixation screw.

95 Immediately following the repair, the biceps was cut at its musculo-tendinous junction.
96 Finally, a radius osteotomy was performed 10cm distally to the radial head and the samples
97 were collected.

98 All dissections and tendon repairs were performed by the same surgeon.

99

100 Experimental protocol

101

102 Tensile tests were performed with a servo-hydraulic testing system (Instron 8803™,
103 Elancourt, France). The proximal side of the radius was embedded into a resin bloc and
104 secured with a clamp on the machine. The proximal tendon graft was secured on a custom-
105 made system of clamps connected to the testing device. Traction was kept perpendicular to
106 the radius axis. Similar cyclic load model have been used in prior biomechanical testing of
107 tendon constructs^{11,12,19}.

108 Traction force and total displacement was measured with a uni-axial strength sensor
109 (1000N, TME™, France) set on the Instron's actuator. A 10N-pre-tension load was applied to
110 the tendon and then 500 cycles at 100N were performed at a 1mm.s⁻¹ speed. In several

Distal Biceps repair. A biomechanical study

111 studies^{9,11,15,16}, the authors chose to load the tendon up to 50 N, which corresponds to the
112 strength developed by the elbow during elbow flexion against gravity^{10,20}. We chose a 100 N
113 load, which is roughly the strength developed during elbow flexion when lifting a 1kg-mass⁹.
114 Following these cycles, all failures were numbered: transplant ruptures of any kind (suture,
115 tendon, bone), all tendon elongations at the bone-tendon interface greater than 1cm (which
116 could seriously alter tendon-to-bone healing²¹).

117 Total graft elongation was measured by the Instron displacement sensor. Tendon
118 elongation at the bone-tendon interface, which represents tendon setback in the bone tunnel or
119 gapping, was measured by means of a markers network set on the graft (Fig.2) and measuring
120 the difference in distance between two points (on the bone at the tunnel extremity and another
121 on the graft just at the exit from the tunnel) before and after the loading cycles. Images were
122 recorded by cameras (Photron SA3™, The Barn, UK) facing the transplant and measurements
123 were analyzed with a video analysis software.

124 The tendon was then elongated to failure by applying an increasing displacement at 3.5
125 mm.s⁻¹.

126

127 [Statistical analysis](#)

128

129 A Shapiro-Wilk test was used to analyze statistical distributions because our sample was
130 small (n<30), not from a normal distribution, and could be considered as a paired sample
131 (JMP® software (SAS, Cary, NC, USA)). A non-parametric Wilcoxon test was used to
132 analyze maximum load to failure (MLF) and graft elongation(p<0.05)..

133

134 **Results**

135

136 Regarding graft characteristics, the difference between the median length and diameter of
137 the grafts in each group was not statistically significant (Table 1).

138 The median total graft elongation after loading cycles was 12.09 mm [interquartile range
139 (IQR): 9.12-14.61] in the TST group and 13.69 mm [IQR 12.39-16.410] in the knotless group
140 ($p=0.1$). For both groups, 90% of total graft elongation had already occurred at the 28th cycle
141 [IQR 22.75-79]. The median elongation at bone-tendon interface was 5.77 mm [IQR 4.84-
142 9.11] in the TST group and 4.72 mm [IQR 1.77-6.16] in the knotless group ($p = 0.047$)
143 (Figure 3). During the cycles, 2 specimens failed in the TST group, while none failed in the
144 knotless group (Table 2). Both failures occurred during the first loading cycles and involved a
145 pullout of the screw from the tunnel.

146 The median MLF was 257.87 N [IQR 222.07-325.35] in the TST group and 407.78 N
147 [IQR 358.54-485.20] in the knotless group ($p = 0.047$) (Figure 4). In the TST group there
148 were 5 ruptures by suture breakage that all occurred at the endobutton-suture junction. No
149 bone breaking occurred in this group. One failure by graft slippage occurred into the proximal
150 clamp. In the knotless group there were 3 posterior cortical breakages, 3 suture breakages and
151 2 graft slippages into the proximal clamp (Figure 5). In the posterior cortical breakage group
152 the median MLF was 364 N [IQR 360.36-432.145].

153

154

Discussion:

155

156 A new distal biceps tendon repair technique using knotless fixation was evaluated and
157 compared to the TST. In the knotless group, a median of 407.78N MLF was reached. This
158 result is similar to those reported in the literature, with MLF ranging from 259N to 584N⁹⁻
159^{12,15,16} for endobutton repair. Moreover, the study presenting the best results¹⁰ used a n°5
160 suture, as in the present study. A thicker suture may therefore significantly enhance tendon
161 repair performance regarding MLF.

162 The rupture mode, for 5 of the 6 specimens in the TST group was by suture breakage.
163 Contrastingly, in the knotless group, 3 of the 8 specimens broke their posterior cortical bone
164 during the ultimate load to failure. This difference in rupture mode between the two groups
165 may result from the larger diameter of the bone tunnel created by the knotless endobutton
166 ancillary than that created with the TST device (4.5mm vs 3.2mm). In the posterior cortical
167 breakage group the median MLF was 364N which is superior to the TST median MLF
168 257.87N and Idler et al. found a 221N to be the maximum pullout strength for a native
169 biceps¹⁹ so there shouldn't be any concern about potential in vivo risk of fracture using our
170 procedure. Furthermore in a recent study of 38 patients Alech-Tournier et al. did not report
171 cortical fracture using the same knotless device²².

172 Our elongations results are slightly higher than those published elsewhere. For classic
173 endobutton techniques, Mazzocca et al.⁹ found 3.42 mm, Spang et al.¹¹ 2.58 mm, Sethi et al.¹⁵
174 2.79mm and only 1.26mm when using the TST technique. On the other hand, Savin et al.¹⁶, in
175 the only previous biomechanical study reporting on the knotless device, found 2.5mm
176 elongation in the TST group but 10.4mm elongation in their knotless group with a standard
177 locking whipstitch. To avoid this gapping, they reinforced their suture with a suture tape to

178 obtain a similar result to the TST with no significant difference. In the present study, a 4.24
179 mm elongation was measured, this may be due to the n°5 looped suture which is stronger than
180 the suture used in Savin et al. study (n°2 Fiberwire®, Arthrex™, Naples, FL, USA) and to our
181 suture technique which may present less gapping than the one use in the former study.

182 During the loading cycles phase, two failures occurred in the TST group. Both failures
183 followed early pullout of the screw from the bone at the beginning of the loading cycles,
184 possibly because of cortical bone weakening during the screwing. However, this explanation
185 cannot be confirmed without BMD and thus could not be correlated with the pullout screw
186 occurrence here. In the light of this result and of Sethi et al.¹⁵ observations (the screw didn't
187 generate any pullout strength nor displacement differences),we would not advise using the
188 screw in addition to the endobutton, particularly with an elderly population.

189 We chose a 100 N load, which is roughly the strength developed during elbow flexion
190 when lifting a 1kg-mass⁹ because we consider this the load bearing required for an early
191 return to daily living and occupational activities. However, this heavier loading may also have
192 increased our median graft elongation, explaining differences from the literature data.

193 During the loading cycles, elongation was observed to occur in the first stages before
194 reaching a plateau: at the 28th cycle, 90% of the total elongation had already occurred. Taken
195 together with the present encouraging experimental results, this suggests that our technique
196 reliably affords early rehabilitation and that an early return to daily activities can be envisaged
197 with no restriction other than a 1kg-lifting limit, as it is suggested in the literature to be
198 associated with satisfactory clinical results and no re-rupture or transplant elongation^{3,23}. In
199 their recent study Alech-Tournier et al. using the same device allowed rehabilitation at one
200 week post-operatively with good clinical result and no re-rupture rate²².

201 In endobutton repair using an anterior approach, drilling direction is chosen to reduce the
202 risk of posterior interosseous nerve injury^{17,24}. As a consequence, the transplant insertion set

Distal Biceps repair. A biomechanical study

203 radially relative to the biceps footprint²⁵. Anterior drilling also impacts biceps tuberosity
204 height²⁶, and thus could affect supination strength by reducing the cam effect²⁷. Prud'homme-
205 Foster et al.²⁸ found that direct repair led to a loss of 15% supination strength in neutral
206 position and 40% at 45°-supination. Seeking to recreate the cam effect, Sethi et al.¹⁴ proposed
207 adding the interference screw radially positioned in the bone tunnel. To date, however, there
208 has been no biomechanical or clinical study attesting to its beneficial effect on supination
209 strength. Nor has any clinical publication used isometrical and isocinetical tests to show the
210 difference in supination strength between patients who have undergone direct repair by
211 endobutton and anatomical repair with a posterior approach.

212 The main limitation of this study is that, being cadaveric, the specimens used were old
213 (average of 87.25 yo). Even though BMD measurements were not performed before testing,
214 the specimens' BMD can be assumed to be lower than those of the active population affected
215 by biceps tendon ruptures and requiring biceps reinsertion. However, the pairing mode
216 between each arm of each specimen allowed us to overcome this limitation. This study also
217 assessed a limited population (8 specimens), for reasons of availability. Further experiments
218 on specimens from various age groups will be needed in order to draw more general
219 conclusions

220 Regarding our testing protocol, the fact that the measurements were performed on the
221 isolated radius via axial traction perpendicular to the radius axis, instead of using a poly-axial
222 mechanism measurement protocol^{3,9,10,15,16} closer to elbow physiological use and movement,
223 can be considered as another limitation. The biceps is principally a supinator muscle, and our
224 protocol did not account for the potentially interesting issue of prono-supination strength.
225 However, this procedure provided accurate measurement of the exact tendon displacement
226 and elongation per cycle, as well as providing better reproducibility of the boundary
227 conditions for each test.

Distal Biceps repair. A biomechanical study

228 The present technique performs better than the original TST in terms of elongation and
229 MLF. It is also more robust than the original technique as described by Sethi in 2010¹⁵. Thus,
230 our new approach appears as a simple and reliable technique for distal biceps tendon repair
231 allowing early rehabilitation. As a consequence it could be recommended for active patients
232 wishing to return quickly to their daily living and occupational activities.

233

234 Acknowledgments: We thank the Laboratory of Anatomy, UCLB Lyon 1, Tornier™-
235 Wright™, Memphis, TN, USA, Arthrex™, Naples, FL, USA, Zimmer-Biomet™, Warsaw,
236 IN, USA for providing samples free of charges.

237

238

239

References:

- 240 1. Kelly MP, Perkinson SG, Ablove RH, et al. Distal Biceps Tendon Ruptures: An
241 Epidemiological Analysis Using a Large Population Database. *Am J Sports Med* 2015;
242 43: 2012–2017.
- 243 2. Baker BE, Bierwagen D. Rupture of the distal tendon of the biceps brachii. Operative
244 versus non-operative treatment. *J Bone Joint Surg Am* 1985; 67: 414–417.
- 245 3. Rose DM, Archibald JD, Sutter EG, et al. Biomechanical analysis suggests early
246 rehabilitation is possible after single-incision EndoButton distal biceps repair with
247 FiberWire. *Knee Surgery, Sports Traumatology, Arthroscopy* 2011; 19: 1019–1022.
- 248 4. Cil A, Merten S, Steinmann SP. Immediate Active Range of Motion after Modified 2-
249 Incision Repair in Acute Distal Biceps Tendon Rupture. *The American Journal of Sports
250 Medicine* 2009; 37: 130–135.
- 251 5. Savin DD, Watson J, Youderian AR, et al. Surgical Management of Acute Distal Biceps
252 Tendon Ruptures: *The Journal of Bone and Joint Surgery* 2017; 99: 785–796.
- 253 6. Stoll LE, Huang JI. Surgical Treatment of Distal Biceps Ruptures. *Orthopedic Clinics of
254 North America* 2016; 47: 189–205.
- 255 7. Kodde IF, Baerveldt RC, Mulder PGH, et al. Refixation techniques and approaches for
256 distal biceps tendon ruptures: a systematic review of clinical studies. *Journal of Shoulder
257 and Elbow Surgery* 2016; 25: e29–e37.
- 258 8. Lang NW, Bukaty A, Sturz GD, et al. Treatment of primary total distal biceps tendon
259 rupture using cortical button, transosseus fixation and suture anchor: A single center
260 experience. *Orthopaedics & Traumatology: Surgery & Research* 2018; 104: 859–863.
- 261 9. Mazzocca AD, Burton KJ, Romeo AA, et al. Biomechanical Evaluation of 4 Techniques
262 of Distal Biceps Brachii Tendon Repair. *The American Journal of Sports Medicine* 2007;
263 35: 252–258.
- 264 10. Greenberg JA, Fernandez JJ, Wang T, et al. EndoButton-assisted repair of distal biceps
265 tendon ruptures. *Journal of Shoulder and Elbow Surgery* 2003; 12: 484–490.
- 266 11. Spang JT, Weinhold PS, Karas SG. A biomechanical comparison of EndoButton versus
267 suture anchor repair of distal biceps tendon injuries. *Journal of Shoulder and Elbow
268 Surgery* 2006; 15: 509–514.
- 269 12. Kettler M, Lunger J, Kuhn V, et al. Failure Strengths in Distal Biceps Tendon Repair.
270 *The American Journal of Sports Medicine* 2007; 35: 1544–1548.
- 271 13. Bain GI, Prem H, Heptinstall RJ, et al. Repair of distal biceps tendon rupture: A new
272 technique using the endobutton. *Journal of Shoulder and Elbow Surgery* 2000; 9: 120–
273 126.
- 274 14. Sethi PM, Tibone JE. Distal biceps repair using cortical button fixation. *Sports medicine
275 and arthroscopy review* 2008; 16: 130–135.

Distal Biceps repair. A biomechanical study

- 276 15. Sethi P, Obopilwe E, Rincon L, et al. Biomechanical evaluation of distal biceps
277 reconstruction with cortical button and interference screw fixation. *Journal of Shoulder*
278 *and Elbow Surgery* 2010; 19: 53–57.
- 279 16. Savin DD, Piponov H, Watson JN, et al. Biomechanical evaluation of distal biceps
280 tendon repair using tension slide technique and knotless fixation technique. *International*
281 *Orthopaedics* 2017; 41: 2565–2572.
- 282 17. Duncan D, Lancaster G, Marsh SG, et al. Anatomical Evaluation of a Cortical Button for
283 Distal Biceps Tendon Repairs. *HAND* 2013; 8: 201–204.
- 284 18. Schmidt CC, Brown BT, Williams BG, et al. The Importance of Preserving the Radial
285 Tuberosity During Distal Biceps Repair: *The Journal of Bone and Joint Surgery-*
286 *American Volume* 2015; 97: 2014–2023.
- 287 19. Rashid A, Copas D, Watts AC. Failure of distal biceps repair by gapping. *Shoulder &*
288 *Elbow* 2016; 8: 192–196.
- 289 20. Idler CS, Montgomery WH, Lindsey DP, et al. Distal Biceps Tendon Repair: A
290 Biomechanical Comparison of Intact Tendon and 2 Repair Techniques. *The American*
291 *Journal of Sports Medicine* 2006; 34: 968–974.
- 292 21. Alech-Tournier F, Elkholti K, Locquet V, et al. Outcomes of distal biceps tendon
293 reattachment using the ToggleLoc™ fixation device with ZipLoop™ technology with
294 single mini-open technique. *European Journal of Orthopaedic Surgery & Traumatology*.
295 Epub ahead of print 7 February 2019. DOI: 10.1007/s00590-019-02376-9.
- 296 22. An K-N, Hui FC, Morrey BF, et al. Muscles across the elbow joint: a biomechanical
297 analysis. *Journal of biomechanics* 1981; 14: 659663–661669.
- 298 23. Smith JRA, Amirfeyz R. Does immediate elbow mobilization after distal biceps tendon
299 repair carry the risk of wound breakdown, failure of repair, or patient dissatisfaction?
300 *Journal of Shoulder and Elbow Surgery* 2016; 25: 810–815.
- 301 24. Thumm N, Hutchinson D, Zhang C, et al. Proximity of the Posterior Interosseous Nerve
302 During Cortical Button Guidewire Placement for Distal Biceps Tendon Reattachment.
303 *The Journal of Hand Surgery* 2015; 40: 534–536.
- 304 25. Hasan SA, Cordell CL, Rauls RB, et al. Two-incision versus one-incision repair for
305 distal biceps tendon rupture: a cadaveric study. *Journal of Shoulder and Elbow Surgery*
306 2012; 21: 935–941.
- 307 26. Schmidt CC, Brown BT, Williams BG, et al. The Importance of Preserving the Radial
308 Tuberosity During Distal Biceps Repair: *The Journal of Bone and Joint Surgery-*
309 *American Volume* 2015; 97: 2014–2023.
- 310 27. Haugstvedt J-R, Berger RA, Berglund LJ. A mechanical study of the moment-forces of
311 the supinators and pronators of the forearm. *Acta Orthopaedica Scandinavica* 2001; 72:
312 629–634.

Distal Biceps repair. A biomechanical study

- 313 28. Prud'homme-Foster M, Louati H, Pollock JW, et al. Proper placement of the distal
314 biceps tendon during repair improves supination strength—a biomechanical analysis.
315 *Journal of Shoulder and Elbow Surgery* 2015; 24: 527–532.

316

317

318 **Figures and Tables:**

319

	Population
Sex ratio	5 women and 3 men
Specimen conservation type	5 fresh and 3 embalmed
Age \pm SD	87.25 ¹ \pm 3.79
Tendon length cm \pm SD	9.09 ¹ \pm 1.20
Tendon diameter cm \pm SD	6.65 ¹ \pm 0.53
Tendon prepared diameter cm \pm SD	7.38 ¹ \pm 0.53

320 **Table 1:** Population included characteristic. ¹, average. SD, standard deviation.

321

Group	TST		Knotless		P
	Average	SD	Average	SD	
Tendon length, cm	9.08	1.20	9.1	1.34	0.9
Tendon diameter, mm	6.7	0.57	6.6	0.55	0.7
Prepared tendon diameter, mm	7.08	0.49	7.67	0.41	0.05

322 **Table 2:** Graft and tendon anatomical characteristics. SD, standard deviation. IC 95 %, confidence interval 95 %.

323 P<0,05

324

Cycling achieved, n	TST		Knotless		P
	Median	IQR	Median	IQR	
	6/8		8/8		
Total elongation, mm	12.09	[9.12-14.61]	13.69	[12.39-16.41]	0.1
Bone-tendon interface elongation, mm	5.77	[4.84-9.11]	4.72	[1.77-6.16]	0.047
Load to failure, N	257.87	[222.07-325.35]	407.78	[358.54-485.20]	0.047
Failure mode	5 sutures 1 clamp-tendon slippage		3 sutures 3 posterior cortical ruptures 2 clamp-tendon slippages		

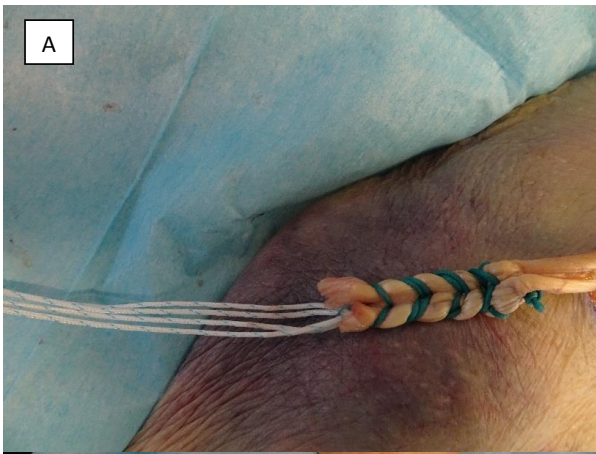325 **Tableau 3:** Main results in TST group vs knotless group. IQR, interquartile range.

326 P<0,05

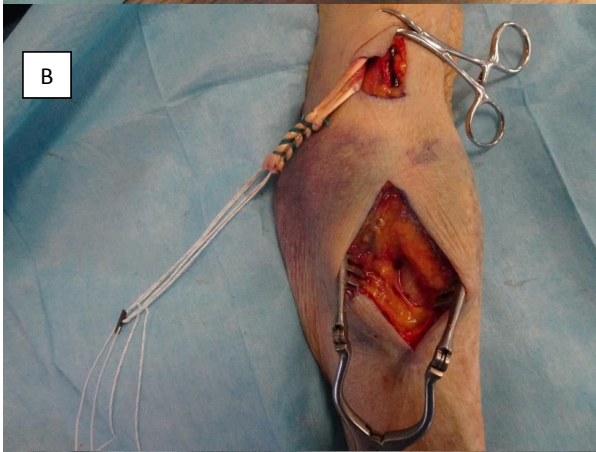327

Distal Biceps repair. A biomechanical study

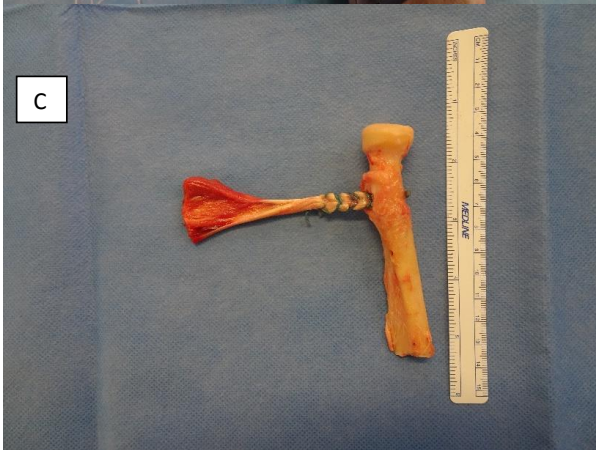
328



329



330



331


Figure 1: A: Preparation of the tendon with Knotless technique. B: Tendon prepared,

332

before passing it beside the skin for bone fixation. C: Harvested tendon.

333

334



335

336 **Figure 2:** Transplant before testing, bone embedded in resin, tendon maintained in
337 custom-made clamp and secured to the servo-hydraulic machine. Landmarks are drawn
338 directly on the tendon and the bone to measure displacement and distention. One point is
339 drawn at the bone tendon junction to measure tendon pullout.

340

Distal Biceps repair. A biomechanical study

341

342

343

344

345

346


347

348

349

350

351



352

353


Figure 5 : A : Slippage inside the proximal clamp during ultimate load to failure

354

355

356

357



358

359 **Figure 5 : B** : Suture breakage during ultimate load to failure

360

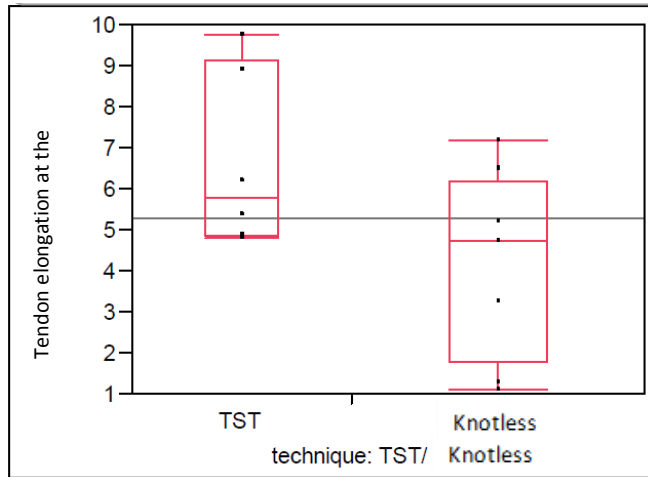
361



362

363 **Figure 5:** C: Cortical breakage during ultimate load to failure.

364



365

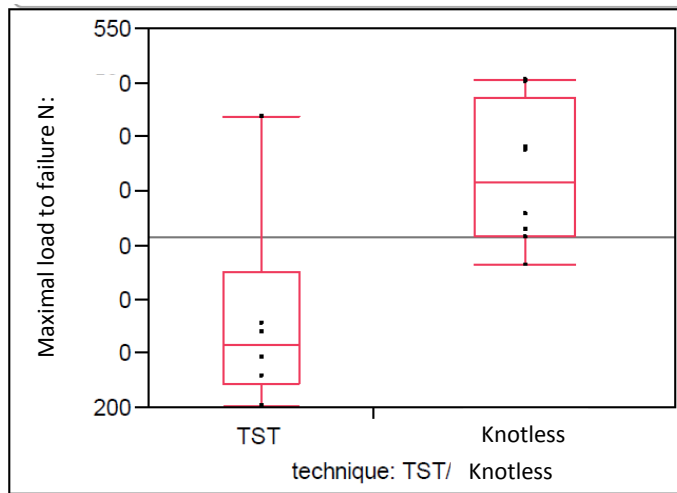
366 **Figure 3:** Maximal elongation at the bone-tendon junction. *Medians, IQR, minimum and*
367 *maximum values.*

368

369

370

371



372

373 **Figure 4:** Maximal load to failure. *Medians, IQR, minimum and maximum values.*

374