



The Importance of Characterizing the Hemoglobin Instability of New Variants: The Case of Hb Dompierre [$\beta 29(\text{B11})\text{Gly} \rightarrow \text{Arg}$, HBB : c.88G>C]

Etienne Mondesert, Muriel Giansily Blaizot, Olivier Tournilhac, Anne François Serre Sapin, Bernard Aubin, Jean-Luc Pellequer, Patricia Aguilar Martinez

► To cite this version:

Etienne Mondesert, Muriel Giansily Blaizot, Olivier Tournilhac, Anne François Serre Sapin, Bernard Aubin, et al.. The Importance of Characterizing the Hemoglobin Instability of New Variants: The Case of Hb Dompierre [$\beta 29(\text{B11})\text{Gly} \rightarrow \text{Arg}$, HBB : c.88G>C]. Hemoglobin, 2020, 44 (1), pp.13-16. 10.1080/03630269.2020.1721021 . hal-02884855

HAL Id: hal-02884855

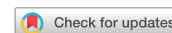<https://hal.science/hal-02884855>

Submitted on 13 Jan 2021

HAL is a multi-disciplinary open access archive for the deposit and dissemination of scientific research documents, whether they are published or not. The documents may come from teaching and research institutions in France or abroad, or from public or private research centers.

L'archive ouverte pluridisciplinaire **HAL**, est destinée au dépôt et à la diffusion de documents scientifiques de niveau recherche, publiés ou non, émanant des établissements d'enseignement et de recherche français ou étrangers, des laboratoires publics ou privés.

SHORT COMMUNICATION



The Importance of Characterizing the Hemoglobin Instability of New Variants: The Case of Hb Dompierre [$\beta 29(\text{B}11)\text{Gly} \rightarrow \text{Arg}$, *HBB*: c.88G>C]

Etienne Mondesert^a, Muriel Giansily Blaizot^a, Olivier Tournilhac^b, Anne François Serre Sapin^c, Bernard Aubin^d, Jean-Luc Pellequer^e and Patricia Aguilar Martinez^a

^aDepartment of Biological Hematology, CHU Montpellier, Montpellier, France; ^bDepartment of Clinical Hematology, CHU Clermont-Ferrand, Clermont-Ferrand, France; ^cDepartment of Biological Hematology, CHU Clermont-Ferrand, Clermont-Ferrand, France; ^dDepartment of Internal Medicine, CH Moulins Yzeure, Moulins, France; ^eInstitute of Structural Biology, University of Grenoble Alpes, CEA, CNRS, Grenoble, France

ABSTRACT

Hb Dompierre [$\beta 29(\text{B}11)\text{Gly} \rightarrow \text{Arg}$, *HBB*: c.88G>C] is a rare β -globin gene variant that was previously described in the heterozygous state in a 24-year-old female patient. It is defined in the HbVar database as being clinically and biologically asymptomatic. A few years after the first description, we had an opportunity of reassessing the index case because she presented with splenomegaly and clinical and biological manifestations of hemolysis. After ruling out the most common causes of hemolysis, further analyses on the variant hemoglobin (Hb) using brilliant cresyl blue staining, indicated that it showed mild instability, which may explain the clinical and biological manifestations. A structural bioinformatic analysis on the Hb variant suggested that the amino acid replacement may be deleterious to the integrity of the Hb. This report confirms the importance of completely characterizing all new Hb variants in order to guide the patients' clinical management and follow-up, as well as to provide the probands and their family members with appropriate genetic counseling.

ARTICLE HISTORY

Received 24 October 2019
Revised 8 January 2020
Accepted 16 January 2020

KEYWORDS

Heinz bodies; Hb Dompierre; unstable hemoglobin (Hb)

Hb Dompierre [$\beta 29(\text{B}11)\text{Gly} \rightarrow \text{Arg}$, *HBB*: c.88G>C] is a rare β -globin gene variant, which was first described in the heterozygous state in a 24-year-old female patient [1]. This variant was reported in the HbVar database [2] to have no pathological features (clinical presentation was normal and laboratory findings were normocytic and normochromic). As HbVar is used as a reference for hemoglobin (Hb) variants by most genetic laboratories specializing in globin gene analysis, being able to provide an accurate description of the clinical and biological characteristics of any new variant is of utmost importance. This database provides physicians with useful information about the clinical and biological manifestations as well as the prognosis of the disease whenever this variant is identified in a new patient. If the Hb variant shows no pathological features, the patient and any other carriers identified can be reassured and no follow-up will be required, but when specific Hb abnormalities, such as increased Hb affinity or instability are suspected, a biological and/or clinical follow-up is necessary, as well as appropriate genetic counseling. This could be critical in the case of young adults in order to evaluate the genetic risk to their offspring, when the spouse is also a carrier of another Hb abnormality. In addition, family screening should be recommended [3].

We recently had an opportunity of reexamining the index case carrying Hb Dompierre and some of her relatives. We establish here that this β -globin gene variant is in fact a

mildly unstable Hb accompanied by clinical and biological manifestations of hemolysis.

Case report

The patient consulted for the first time at the age of 22 for repeated episodes of acute abdominal pain. At that time, an ultrasound scan showed the presence of no hepatosplenomegaly or gallstones, and the complete blood count (CBC) was normal [Hb 15.0 g/dL and mean corpuscular volume (MCV) 85.0 fL]. Two years later, another episode of abdominal pain led to further investigations. The abdominal scan was still normal, but Hb studies revealed an abnormal Hb fraction. The variant was still undescribed and was called Hb Dompierre (*HBB*: c.88G>C) [2]. This finding was thought to be an incidental finding with no clinical consequences and no follow-up was undertaken. A few years after the initial diagnosis, the patient was referred to a hematological consultation for investigations because of another episode of abdominal pain. At the clinical examination, she had splenomegaly. Biological tests showed the presence of an increased white blood cell (WBC) count (13.0 G/L), increased plasma c-reactive protein (CRP) (19.4 mg/L), and decreased serum haptoglobin levels (0.26 g/L). Subsequent controls showed mild thrombocytopenia oscillating between 120.0 and 150.0 G/L. Ultrasound and a computed tomography (CT) scan showed the presence of splenomegaly

(154 × 140 × 86 mm), without any portal vein thrombosis or gallbladder gallstones.

As the Hb variant was assumed to be asymptomatic, further investigations were undertaken in order to rule out the most common causes of splenomegaly, including a myeloproliferative syndrome or Gaucher's disease. The patient's mother and maternal grandfather also had a clinical history of abdominal pain and her mother had undergone cholecystectomy at the age of 40. The patient was then referred to our Center for a biological investigation of hemolytic syndrome. Family screening included the patient's mother and two siblings.

A CBC-differential, iron status, and serum bilirubin, lactate dehydrogenase, CRP and haptoglobin measurements were performed. The Hb investigations included cation exchange high-performance liquid chromatography (HPLC) (VARIANT IITM; Bio-Rad Laboratories, Hercules, CA, USA), capillary electrophoresis (CE) (Minicap®; Sebia, Evry, France), polyacrylamide gel isoelectric focusing (IEF), and citrate agar electrophoresis (CAE). Hemoglobin stability was tested using the isopropanol precipitation test [4]. A search for Heinz bodies was conducted using 1.0% brilliant cresyl blue supravital stain in saline buffer, after 30 min., 1, 2, 4, and 24 hours of incubation at 37 °C. This prolonged incubation step is recommended when searching for unstable Hbs [5].

The pink test (PT) was performed to assess the patient's red cell membrane resistance, and FACs analysis was carried out using eosin-5'-maleimide (EMA) labeling of red blood cells (RBC) to rule out hereditary spherocytosis. DNA was extracted from whole blood and the *HBB*, *HBA1*, and *HBA2* genes were sequenced using the Sanger method. The patients gave their written consent to genetic testing in keeping with the national regulations. Structural analysis of the mutant was performed using the Missense3D modeling program [6] on the deoxy human Hb structure (PDB 1A3N) [7].

At the time of the laboratory reassessments, slight thrombocytopenia (117.0 G/L) was the only anomaly of the CBC and differential observed. No increase in the reticulocyte count (96.0 G/L) was noted. The blood film showed the presence of a few spherocytes (3.0%). Hemoglobin studies confirmed the presence of an abnormal Hb fraction (40.0% on CE), which coeluted with Hb A₂ on cation exchange HPLC, and migrated between Hb S (*HBB*: c.20A>T) and Hb F on IEF. This fraction was not separated from Hb A under acid pH electrophoresis. Hb A₂ was slightly elevated (3.5%) on CE, which was also the case in the initial report [2]. Genetic tests identified the *HBB*: c.88G>C mutation previously described in HbVar [2] in the heterozygous state, and further analyses (search for mutations and large rearrangements) on the *HBB*, *HBA1*, and *HBA2* genes were negative. No Hb precipitates were observed on the isopropanol test after 50 minutes of incubation and the test was, therefore, considered negative. However, an Hb precipitate was present after 24 hours in the patient's test tube, whereas the control tube was devoid of any precipitates. This never occurs in normal samples. In addition, the search for Heinz bodies turned out to be positive after 4 hours of incubation

at 37 °C, and became massively positive after 24 hours, with 98.0% of RBC showing multiple membrane inclusions [Figure 1(A–C)]. This behavior and pattern are typical of other known unstable Hbs previously diagnosed routinely at our laboratory.

Membrane stability tests and biochemical blood parameters were within the normal ranges, except for the low serum iron (5.6 μmol/L) and transferrin saturation levels (7.0%) and a slightly elevated plasma CRP (16.4 mg/L). Serum ferritin (sFt) levels were normal (146.0 μg/L), but this could be due to the possible interference of inflammation. The Hb variant was also identified in one of the patient's siblings during family screening. The mother was not affected. Structural analysis showed that in the Hb, Gly29 is entirely buried and its replacement with a large positively charged residue (Arg) was unfavorable [Figure 1(D)], which accounts for the conclusion of 'damaging' in the Missense3D summary report [6].

Here, we present new insights on a β-globin gene variant [Hb Dompierre: β29(B11)Gly→Arg], which was reported to be clinically silent in the original description in HbVar [2]. Its original classification was based on the presence of a normal CBC in the patient and by analogy with mutations located at the same or in a closely neighboring position. The authors reminded that Hb Lufkin [*HBB*: c.89G>A; β29(B11)Gly→Asp] and Hb Tizi-Ouzou [*HBB*: c.88G>A; β29(B11)Gly→Ser] had no clinical expression, despite mild *in vitro* instability. However, comparisons with the effects of various amino acid substitutions in an adjacent position [β28(B10)] have shown that the effects on the behavior of Hb and on the resulting clinical manifestations can be quite different, as some of them lead to highly unstable Hbs and others have no consequences [8].

Structural analysis of Hb Dompierre showed that Gly29 (Gly30 in the HGVS nomenclature) is entirely buried and that its replacement with a large positively charged residue (Arg) would be highly unfavorable. Glycine is a very special amino acid as it often occupies positions in the molecular structure that could rarely be occupied by any of the remaining 19 amino acids. It is likely that the unfavorable replacement of Gly29 by arginine may destabilize the local structure of the β chain, resulting in mild instability of the variant Hb [9]. The level of the Dompierre variant is not decreased as it occurs with many other mildly unstable Hbs. This may be attributable to the fact that the phi and psi angles of the wildtype Gly29 may suit any other amino acid residues and the modeling with Missense3D points to the possibility of solvent-exposed orientation of arginine [Figure 1(D)].

Hb Dompierre was originally identified using Hb studies (cation exchange HPLC and CE) and gene sequencing, but no stability tests were initially performed or mentioned. The reasons why Hb studies were initially conducted on this patient are not very clear. A few years after the initial report, further investigations were performed on the index case because of the occurrence of clinical signs of mild hemolysis (including splenomegaly and abdominal pain) and biological signs of hemolysis. The present results show that Hb

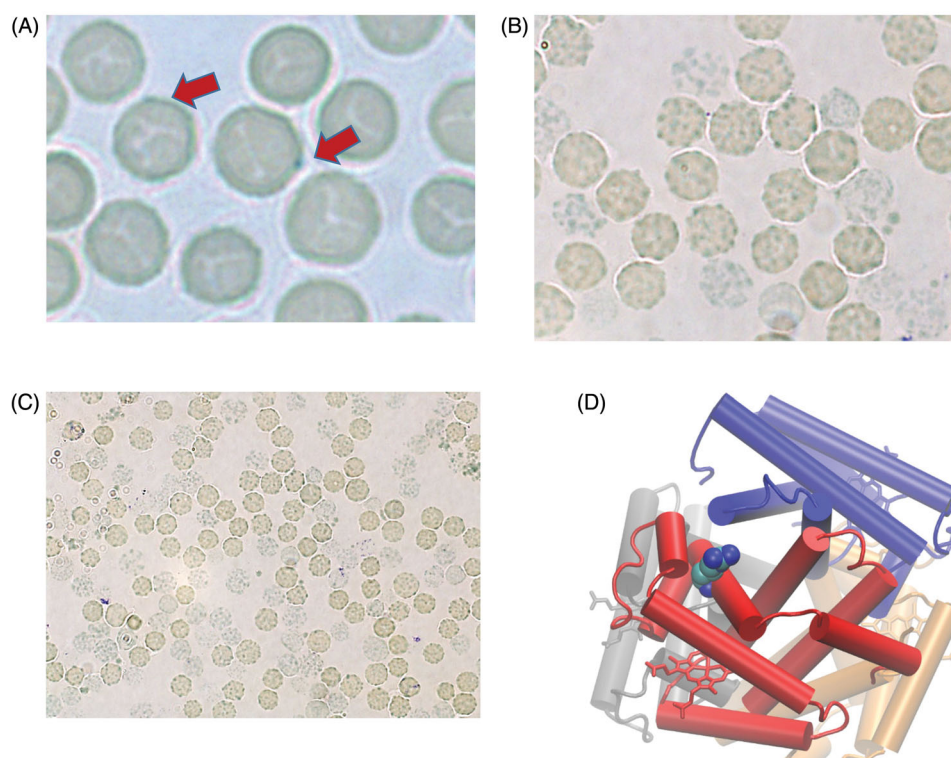


Figure 1. (A–C) Heinz body screening after 4 and 24 hours of incubation at 37 °C. A few red cells were found to contain some blue inclusions after being incubated with brilliant cresyl blue for 4 hours (A: 200× magnification), whereas after a 24 hours period of incubation (B: 100× and C: 50× magnification), nearly all the RBCs contained multiple Heinz body inclusions. This pattern is characteristic of the presence of an unstable Hb. The staining was checked twice on two different samples taken from the patients several months apart. (D) Structural analysis of Hb Dompierre. The mutated arginine residue is highlighted in the present CPK models. The heme groups are shown in the form of sticks in each of the Hb chains. Gly29 (Gly30 in the HGVS nomenclature) is entirely buried, and its replacement with a large positively charged residue (Arg) is highly unfavorable, which may explain the instability of the Hb.

Dompierre is an unstable Hb that precipitates in the form of Heinz bodies after 4–24 hours of incubation and also shows unusually late precipitation in isopropanol tests. The presence of a slightly increased Hb A₂ on CE may be due to small fractions originating from the abnormal Hb and comigrating with Hb A₂. An alternative explanation may be that the instability of Hb Dompierre may lead to larger numbers of free α chains able to bind to the δ -globin chains, resulting in higher Hb A₂ levels.

The instability of Hb Dompierre may explain the acute clinical manifestations observed in the present patient and the presence of some hemolytic biological features. Abdominal pain may be attributable to hemolytic crises, but is usually encountered in cases of massive intravascular hemolysis [10]. Despite the family history of abdominal pain on the maternal side, this does not seem to be associated with the Hb variant, which was not inherited from the mother. Other possible main causes of splenomegaly in this patient have been ruled out, leaving us with the hypothesis that it may have been caused by chronic hemolysis and triggered the fluctuating thrombocytopenia. Biological signs, such as the presence of spherocytes and the history of low haptoglobin, might indicate the presence of chronic hemolysis. Abnormal hemolytic parameters do not seem to be permanently present in this patient, as the measurements carried out at our laboratory, and again a few weeks after the clinical manifestations, were nearly normal. The presence of stigmata of inflammation (infection) might possibly

explain the acute manifestations, as infections and some drugs can trigger acute hemolytic crises in patients who are carriers of an unstable Hb.

This report highlights the importance of performing complete phenotypic assessments on patients diagnosed with an Hb variant, including the search for clinical and biological signs of hemolysis, as well as a full set of tests for Hb analysis. In this context, instability tests and searching for Heinz bodies after prolonged incubation times [5] are of utmost importance.

Disclosure statement

The authors report no conflicts of interest. The authors alone are responsible for the content and writing of this article.

References

- [1] Renoux C, Feray C, Joly P, *et al.* Description of three new α variants and four new β variants: Hb Montluel [α 110(G17)Ala→Val; HBA1: c.332C>T], Hb Cap d'Agde [α 131(H14)Ser→Cys; HBA2: c.395C>G] and Hb Corsica [α 100(G7)Leu→Pro; HBA1: 302T>C]; Hb Nîmes [β 104(G6)Arg→Gly; HBB: c.313A>G], Hb Saint Marcellin [β 112(G14)Cys→Gly; HBB: c.337T>G], Hb Saint Chamond [β 80(EF4)Asn→0; HBB: c.241_243delAAC] and Hb Dompierre [β 29(B11)Gly→Arg; HBB: c.88G>C]. *Hemoglobin*. 2015;39(3): 147–151.
- [2] Hardison RC, Chui DHK, Giardine B, *et al.* HbVar: a relational database of human hemoglobin variants and thalassemia

- mutations at the globin gene server. *Hum Mutat.* 2002;19(3): 225–233 (<http://globin.cse.psu.edu>).
- [3] Traeger-Synodinos J, Harteveld CL, Old JM, *et al.* EMQN Best Practice Guidelines for molecular and haematology methods for carrier identification and prenatal diagnosis of the haemoglobinopathies. *Eur J Hum Genet.* 2015;23(4):426–437.
 - [4] Carrel RW, Kay R. A simple method for the detection of unstable haemoglobins. *Br J Haematol.* 1972;23(5):615–619.
 - [5] Bain BJ, Bates I, Laffan MA. Investigation of variant haemoglobins and thalassaemias. *Dacie and Lewis Practical Haematology E-book-de.* 12th ed. London (UK): Elsevier Publishing Company; 2017. p. 309–310.
 - [6] Ittisoponpisan S, Islam SA, Khanna T, *et al.* Can predicted protein 3D structures provide reliable insights into whether missense variants are disease associated? *J Mol Biol.* 2019; 431(11):2197–2212.
 - [7] Tame JRH, Vallone B. The structures of deoxy human haemoglobin and the mutant Hb Tyr α 42His at 120 K. *Acta Crystallogr D Biol Crystallogr.* 2000;56(7):805–811.
 - [8] Thein SL, Best S, Sharpe J, *et al.* Hemoglobin Chesterfield (β 28 Leu–Arg) produces the phenotype of inclusion body β thalassemia. *Blood.* 1991;77(12):2791–2793.
 - [9] Chen SW, Pellequer JL. Identification of functionally important residues in proteins using comparative models. *Curr Med Chem.* 2004;11(5):595–605.
 - [10] Toniolo M, Ceschi A, Meli M, *et al.* Haemolytic anaemia and abdominal pain – a cause not to be missed. *Br J Clin Pharmacol.* 2011;72(1):168–169.