



HAL
open science

Patterns of Failure After Linear Accelerator Radiosurgery for Cerebral Arteriovenous Malformations

Youssef El Ouadih, Jean Jacques Lemaire, Bénédicte Vigier, Jean
Gabrillargues, Aurelien Mulliez, Véronique Dedieu, Guillaume Dupic, Pierre
Verrelle, Julian Biau, Toufic Khalil

► **To cite this version:**

Youssef El Ouadih, Jean Jacques Lemaire, Bénédicte Vigier, Jean Gabrillargues, Aurelien Mulliez, et al.. Patterns of Failure After Linear Accelerator Radiosurgery for Cerebral Arteriovenous Malformations. World Neurosurgery, 2020, 136, pp.e141-e148. 10.1016/j.wneu.2019.12.044 . hal-02882156

HAL Id: hal-02882156

<https://hal.science/hal-02882156>

Submitted on 22 Aug 2022

HAL is a multi-disciplinary open access archive for the deposit and dissemination of scientific research documents, whether they are published or not. The documents may come from teaching and research institutions in France or abroad, or from public or private research centers.

L'archive ouverte pluridisciplinaire **HAL**, est destinée au dépôt et à la diffusion de documents scientifiques de niveau recherche, publiés ou non, émanant des établissements d'enseignement et de recherche français ou étrangers, des laboratoires publics ou privés.



Distributed under a Creative Commons Attribution - NonCommercial 4.0 International License

Patterns of Failure after LINAC Radiosurgery for Cerebral Arteriovenous Malformations

Authors: EL OUADIH Youssef, MD, Msc (1,4), LEMAIRE Jean Jacques MD PhD (1,4), VIGIER Benedicte MD (2), GABRILLARGUES Jean MD (2), MULLIEZ Aurélien MD Msc (6), DEDIEU Véronique, Physicist, PhD (3), DUPIC Guillaume MD (3), VERELLE Pierre MD PhD (3,5), BIAU Julian MD, PhD (3,7), KHALIL Toufic MD Msc (1)

- (1) Service de Neurochirurgie, CHU Clermont Ferrand, F-63000, Clermont-Ferrand, France
- (2) Service de Radiologie, CHU Clermont Ferrand, F-63000, Clermont-Ferrand, France
- (3) Département de Radiothérapie, Centre Jean Perrin, Clermont Ferrand, F-63000, France
- (4) Université Clermont Auvergne, CNRS, SIGMA Clermont, F-63000, Clermont-Ferrand, France
- (5) Institut Curie, Département de radiothérapie, F-75248, Paris, France
- (6) Service de Biostatistiques, CHU Clermont Ferrand, F-63000, Clermont-Ferrand, France
- (7) Université Clermont Auvergne, INSERM, U1240 IMoST, F-63000 Clermont Ferrand, France

Short Title : AVM Radiosurgery : Pattern of Failures

Corresponding Author :

EL OUADIH Youssef

Address : 48, rue Victor Charretton, 63100 Clermont Ferrand, France

Email address : youssef.elouadih@gmail.com

Conflict of interest : None

Disclosure of Funding : None

Patterns of Failure after LINAC Radiosurgery for Cerebral Arteriovenous Malformations

Running title: AVM Radiosurgery: Patterns of Failures

Key Words: failure, patterns, radiosurgery, arteriovenous malformation, LINAC, radiosensitivity, radioresistance

Abstract word count: 259 words

Text word count: 2179 words

Number of references: 51

Number of figures: 1

Number of tables: 2

ABSTRACT

Background

Numerous studies have assessed the predictive factors of the arteriovenous malformation (AVM) response to stereotactic radiosurgery (SRS) but only a few have discussed the causes of failure. The aim of this study was to evaluate the patterns of failure in patients with AVM who had undergone LINAC SRS.

Methods

We performed a retrospective analysis of 288 patients treated by LINAC SRS in our institution from 1995 to 2011. Failure was defined on the basis of the control angiogram at 5 years and identified in 44 patients. The distribution of causes was estimated by a descriptive analysis of literature-based causes: minimal margin dose < 18 Gy, residual nidus outside the initial targeted volume, prior embolization, recanalization and size of the target volume. We also analyzed associations between causes.

Results

Incomplete nidus identification (41%) and prior embolization (77%) were the most frequently observed conditions in cases of failure. Previously embolized patients, in whom the cause of failure was always identified ($p=0.001$), were younger ($p=0.004$) and had larger nidus volumes (0.025). Recanalization was rare (5/34) and exclusively in females ($p=0.048$). Larger nidus volumes were less frequent ($2.18 \text{ cm}^3 \pm 2.2 / [0.13-10.8]$) and observed mainly in females when $> 2 \text{ cm}^3$ ($p=0.012$). Insufficient dose was observed in 9 patients and found in case of larger volume ($p=0.031$) leading to dosimetry constraints (3 cases) and vicinity of eloquent zones (6 cases). No known causes were found in 5 patients, 4 of whom had low Spetzler-Martin grades (I and II, $p=0.003$) suggestive of radioresistance.

Conclusion

Detailed analysis highlighted the distribution of causes and the potential role of radioresistance.

INTRODUCTION

Cerebral arteriovenous malformations (AVM) have a significant cumulative risk for hemorrhage¹. Several treatment options are possible: observation, microsurgical resection, stereotactic radiosurgery (SRS), embolization, and multimodal treatment². Open AVM resection is considered the gold standard treatment because of its ability to immediately relieve the risk of hemorrhage³. However, when the risk of microsurgery is too great, SRS has proven to be a favorable alternative. The rates of AVM obliteration after primary SRS varies from 43% to 92%⁴⁻¹⁰. Most SRS-treated AVMs are obliterated within 3 years¹¹. When the nidus is still present 5 years after SRS, treatment is considered to have failed. The diagnosis of failure is established by angiogram¹² or by angio-magnetic resonance imaging (MRI) in the event of contraindications or patient refusal¹³. Numerous studies^{14,15} have assessed the predictive factors of AVM response to SRS (clinical features, imaging and dosimetry) but only a few have investigated the specific patterns of failure^{16,17}. Our aim was to analyze the patterns of AVM treatment failure at 5 years after linear accelerator (LINAC) SRS.

MATERIAL AND METHODS

❖ Population and Radiosurgery

From September 1995 to December 2011, 288 patients were treated in our institution with LINAC SRS for cerebral AVM. SRS was performed on a Varian® Clinac 2100C (Varian Medical Systems, Palo Alto, CA). We used cylindrical collimators (diameters: 6 to 24 mm) from 1995 to 2000 (n=50) and micro-multileaf collimators with a conformal arc technique from 2000 to 2011 (n= 238), (Brainlab, Feldkirchen, Germany). A Leksell stereotactic head frame was placed under local anesthesia for all treatments. Delineation and treatment planning were performed with BrainScan software (Brainlab, Feldkirchen, Germany). The planning target volume (PTV) consisted of the AVM nidus without any additional margin, which was identified on a multimodal imaging approach including angio computed tomography (CT) scan (1.25-mm slice thickness), angio-MRI (1-mm slice thickness) and an angiogram. In case of prior embolization, the non-flowing embolized zones were excluded from the target volume. All AVM nidi were delineated by both a neurosurgeon and a neuroradiologist. The prescribed dose was 25 Gy at the isocenter with a marginal dose of 22 Gy. The marginal dose was reduced on a case-by-case basis according to the size of the target volume and the surrounding organs at risk (OAR). Each treatment plan was reviewed and approved by a radiation oncologist, neurosurgeon and physicist.

❖ Failures of Radiosurgery

Follow-up consisted in clinical examination and angio-MRI 6 months, 1 year and each year up to 5 years after SRS. At 5 years, a systematic angiogram was performed. Fourteen patients (4.9%) were lost to follow-up (cylindrical collimators n=2, micro-multileaf collimators n=12). At the 5-year control angiogram, 44 patients (15.3%) were considered to have experienced therapeutic failure if incomplete nidus obliteration with persistence of an early filling draining vein¹². The characteristics of the 44 patients are shown in **Table 1**.

Thirty-five patients (80%) had received treatment before SRS1, consisting in embolization in 94% of cases. The residual AVM nidus volume at the 5-year control angiogram was < 50% in 28 patients (64%), > 50% in 14 patients (31 %) and unchanged in 2 patients (5%).

Of the 44 patients, 22 (50%) (13 women, mean age 40.8 years) underwent a second SRS (SRS2) at the same facility with the same strategy. Of the 22 non re-irradiated patients, 1 underwent successful surgery, 6 were successfully re-embolized, 1 died (of causes unrelated to AVM), 3 refused a second radiosurgery treatment, 2 were treated in another center, 4 were lost to follow-up and 5 had no further treatment (maximum reasonable dose reached and no alternative therapy available). Failure was defined on the basis of the SRS2 5-year control arteriogram.

Of the 22 patients with SRS2, 20 underwent the 5-year control angiogram and were analyzed. The mean time between SRS1 and SRS2 was 6.7 years (range 5-16 years) and the mean follow-up after SR2 6.6 years (range 5-12 years). Seven patients were embolized between the two SRS (1 to 5 embolizations). The mean minimum marginal dose was 19.6 Gy \pm 3.9 (range 11.5-24). In 16 patients (80%) treatment was successful and in 4 (20%) a failure. In 13 of the 14 patients who had a > 50% reduction after SR1 treatment was successful (cure rate of 93%). In the 6 patients with >50% residual nidus (reduction <50 %) after SR1, treatment was successful in 3 and a failure in 3 (cure rate of 50%). (**Figure 1: Flow Chart**)

❖ Data analysis

After a case-by-case assessment, the distribution of patterns of AVM treatment failure at 5 years after SRS was estimated retrospectively by a descriptive analysis of literature-based causes: minimal margin dose < 18 Gy^{18,19}, residual nidus outside the initial target volume (i.e. insufficient nidus targeting)^{16,17,20}, the size of the targeted volume^{19,21-24}, prior embolization^{25,26} and recanalization^{27,28}. We elected to study the mean volume (cm³) of the

targeted volume, the Spetzler-Martin grading scale, and AVMs with a volume greater than 2 cm³ and greater than 4 cm³^{23,24}. We also recorded absence of cause of failure.

Data are shown as numbers with associated percentages for categorical data and as means with associated standard deviations (\pm SD) and range [minimum – maximum] for continuous data.

Associations between patterns of failure were analyzed by chi-squared test or Fisher's exact test when appropriate. Comparisons of means were performed by Student's t-test or Mann & Whitney's test if the distribution of data was not normal.

Statistics were computed with STATA (version 12, StataCorp, College Station, US). All tests were two-sided and a p-value < 5% was considered statistically significant.

The study received full ethical review and approval.

RESULTS

Insufficient nidus targeting was observed in 18 patients (41%). In 8 of the 18, the targeted volume was reduced (mean targeted volume = 0.9 cm³) because of the vicinity of eloquent areas: precentral region (n=2), brainstem (n=1), corpus callosum (n=2), deep gray nuclei (n=1) and optical tracts (n=2). In the remaining 10 patients, determination was insufficient because parts of the nidus were not identified: a draining vein (n=1), no clear boundaries of the nidus (n=3, no previous treatment), nidus partially masked by prior embolization (n=5) and a split nidus after prior embolization with one part being masked (n=1).

Prior embolization was performed in 34 patients (77%). Recanalization was visualized in 5 patients, which was systematically located in a previously embolized area not included in the targeted volume as it was not permeable at the time of SRS. These 5 patients were embolized 3, 3, 5, 7 and 9 times, respectively, with histoacryl before SRS. The mean time between the last embolization and radiosurgery was 6.8 months (range 4-12).

The mean size of the targeted volume in the failed treatment group (n=44) was 2.18 cm³ \pm 2.22 (SD), range 0.13-10.8. On the Spetzler-Martin scale, 2 patients (5%) had grade I AVMs, 13 (30%) grade II, 15 (34%) grade III and 14 (32%) grade IV. Sixteen patients had a volume greater than 2 cm³ (36%) and 9 a volume greater than 4 cm³ (20%).

For 9 patients (20%) the minimum marginal dose was insufficient (< 18 Gy, range [11.3 – 17.3]). Three patients had an insufficient dose because of large volume AVMs (10.8 cm³, 5.8

cm³ and 5.4 cm³). Six patients had lesions in the vicinity of eloquent areas: capsulo-thalamic (n=1), corpus callosum (n=2) and central region (n=3).

In 5 patients (11%) no cause of failure was identified. In these patients, the minimum marginal dose was sufficient (>18Gy), targeting was suitable and no prior embolization had been performed (i.e. no recanalization). Volume was lower than 2 cm³ with a mean volume of 0.57 cm³ ± 0.35 (SD), range [0.23-1.14].

Previously embolized patients were younger (p=0.004, Mann & Whitney), the volume of their nidus was larger (p=0.025, Mann & Whitney) and they all had an identified cause of failure (p=0.001, Fisher). Recanalization was exclusively observed in females (p=0.048, Fisher). Low Spetzler-Martin grades were predominantly observed in patients without an identified cause (p=0.003, Fisher). Volumes > 2 cm³ were preferentially observed in females (p=0.012, Chi2). Low doses (<18Gy) were preferentially observed for larger volumes (p=0.031; Mann & Whitney). When no cause was identified the volume was smaller (0.57 cm³ ± 0.35, range [0.23-1.14]; p=0.013, Mann & Whitney) with low Spetzler-Martin grades (p=0.003, Fischer). All associations of causes are given in **Table 2**.

DISCUSSION

The aim of this study was to analyze patterns of AVM treatment failure at 5 years after LINAC SRS. Incomplete nidus identification and prior embolization were the most frequently observed conditions, in 41% and 77%, respectively, of patients with failed treatment. Previously embolized patients were younger (p=0.004) and had larger volumes of nidus (0.025) and an identified cause of failure (p=0.001). Recanalization was rare (5 out of 34) and exclusively in females (p=0.048). Large volumes of nidus were less frequent (mean value = 2.18 ± 2.2 (SD) range [0.13-10.8]) and observed mainly in females when > 2 cm³ (p=0.012). Nine patients with larger volumes (3.66 cm³ ± 3.20 (SD) versus 1.80 cm³ ± 1.77 (SD); p=0.031) had received insufficient doses, which led to dosimetry constraints in 3 and vicinity of eloquent zones in 6. In 5 patients, 4 of whom had low Spetzler-Martin grades (I and II, p=0.003), no known causes were identified.

Incomplete nidus identification in AVM treatment has been documented elsewhere^{16,17,20}. It can be the consequence of a targeting mistake, as seen in 10 of 18 patients in our series, a ratio similar to that of Ellis et al¹⁶. It could have been avoided with better technical tools that provide a comprehensive overview of the nidus in 3D. Modern imaging and planning technologies we systematically used (2D angiogram, co-registered angio CT-Scan and angio

MRI) were however limited in our 10 patients. Historical series²⁷ using only angiograms recorded incorrect definitions of nidus in 33 of 45 cases. One imaging modality is known to be prone to errors in the identification of the nidus^{29,30}. The lack of full nidus identification could also be investigator-dependent³¹ or in some cases due to non-utilization of supra-selective arteriography^{32,33}. Prior embolization, which was very frequent in our series, can interfere with nidus definition^{18,25} and consequently affect failure²⁶. In our series, on this particular point, patients were younger, nidus were bigger and a cause of failure was always found. The incidence of prior embolization in the literature is variable but the procedure can be beneficial in carefully selected patients, in particular for large AVMs^{34,35}. Finally, the concentration of histoacryl could influence the obliteration rate³⁶ and chronic hypoxia due to embolization could be suspected to enhance cell resistance to radiation³⁷.

The incidence of recanalization is rather low^{26-28,38}. Lesions related to embolic agents^{26,38,39} and neoangiogenesis secondary to transient regional nidus hypoxia⁴⁰ can take part in the recanalization process. Hematoma resorption (21/44, Table I) could lead to recanalization, although rare, 9%²⁷. However in our series, we took care to wait for complete resorption before undertaking SRS, which on average was performed 6.8 months after embolization. Surprisingly, we observed recanalization in females only, which suggests a potential link with hormones⁴¹⁻⁴³.

In 9 of 44 patients, the mean minimum marginal dose was low (<18 Gy) and likely contributed to failure according to the demonstrated dose-dependent efficiency^{18,22,44,45}. Moreover, the mean volume of these 9 patients was larger (3.67 cm³) than for the rest of the SRS failures (2.39 cm³). There is inconclusive evidence in the literature on the predictive value of volume for treatment failure^{19,21-23}, which therefore is perhaps not an independent factor.

In 5 patients we found no definite causes of failure and their nidus volumes were small (Spetzler-Martin grades I and II). Radioresistance could have been a factor since it has been reported that a plateau of a maximum obliteration rate of 75%-88% is observed at 25Gy^{18,19}. Beyond that, endothelial cells could die without cellular proliferation and vessel occlusion. There is no study available of intrinsic endothelial cell sensitivity to single high dose radiation. Experimental data suggest that a 10 Gy single dose is a minimum threshold required for inducing massive endothelial cell apoptosis⁴⁶, which is due to radiation-induced activation of acidic sphingomyelinase and leads to the production of ceramide, a pro-

apoptotic sphingolipid⁴⁷. An increase in total plasma ceramide following stereotactic high dose radiation therapy for lung or liver metastases was recently reported as a promising biomarker of tumor response⁴⁸. These results and others suggest that vascular cell ability to synthesize ceramide in response to single high dose radiation could be a major determinant of vessel radiosensitivity and hence the efficacy of AVM SRS.

Repeat radiosurgery succeeded in decreasing SRS1 failures since we obtained an occlusion rate of 80%, which is consistent with that in the literature⁴⁹⁻⁵¹. Kano et al⁴⁹ reported, in line with our observations, that a decrease in the nidus of at least 50% after SRS1 could be a predictive occlusion factor for SRS2.

CONCLUSION

This study assessed the patterns of failure after LINAC SRS for the treatment of AVM. Despite our limited data, detailed analysis established the distribution of causes and identified the potential role of radioresistance and the future interest of individual radiosensitivity measurements. Further studies are required to elucidate the intricate mechanisms of failure.

REFERENCES

1. Ding D, Chen C-J, Starke RM, et al. Risk of Brain Arteriovenous Malformation Hemorrhage Before and After Stereotactic Radiosurgery. *Stroke*. 2019;50(6):1384-1391. doi:10.1161/STROKEAHA.118.024230
2. Tsuji A, Nozaki K. A Prospective and Retrospective Study of Cerebral AVM Treatment Strategies 1990-2014. *Acta Neurochir Suppl*. 2016;123:135-139. doi:10.1007/978-3-319-29887-0_19
3. Schramm J, Schaller K, Esche J, Boström A. Microsurgery for cerebral arteriovenous malformations: subgroup outcomes in a consecutive series of 288 cases. *J Neurosurg*. 2017;126(4):1056-1063. doi:10.3171/2016.4.JNS153017
4. Bitaraf MA, Katozpour R, Azar M, Nouri M, Mortazavi SA, Amirjamshidi A. Radiosurgery in treatment of cerebral arteriovenous malformation: Mid-term results of 388 cases from a single center. *Asian J Neurosurg*. 2017;12(2):159-166. doi:10.4103/1793-5482.145121
5. Pollock BE, Flickinger JC, Lunsford LD, Bissonette DJ, Kondziolka D. Factors that predict the bleeding risk of cerebral arteriovenous malformations. *Stroke*. 1996;27(1):1-6.
6. Kurita H, Kawamoto S, Sasaki T, et al. Results of radiosurgery for brain stem arteriovenous malformations. *J Neurol Neurosurg Psychiatry*. 2000;68(5):563-570.
7. Kiran NAS, Kale SS, Kasliwal MK, et al. Gamma knife radiosurgery for arteriovenous malformations of basal ganglia, thalamus and brainstem--a retrospective study comparing the

- results with that for AVMs at other intracranial locations. *Acta Neurochir (Wien)*. 2009;151(12):1575-1582. doi:10.1007/s00701-009-0335-0
8. Andrade-Souza YM, Zadeh G, Scora D, Tsao MN, Schwartz ML. Radiosurgery for basal ganglia, internal capsule, and thalamus arteriovenous malformation: clinical outcome. *Neurosurgery*. 2005;56(1):56-63; discussion 63-64.
 9. Massager N, Régis J, Kondziolka D, Njee T, Levivier M. Gamma knife radiosurgery for brainstem arteriovenous malformations: preliminary results. *J Neurosurg*. 2000;93 Suppl 3:102-103. doi:10.3171/jns.2000.93.supplement
 10. Nicolato A, Foroni R, Crocco A, et al. Gamma knife radiosurgery in the management of arteriovenous malformations of the Basal Ganglia region of the brain. *Minim Invasive Neurosurg*. 2002;45(4):211-223. doi:10.1055/s-2002-36200
 11. Blanchard N, Bernier V, Anxionnat R, et al. [Radiosurgery of cerebral arteriovenous malformations: a prescription algorithm]. *Cancer Radiother*. 2009;13(1):1-10. doi:10.1016/j.canrad.2008.11.004
 12. Lindquist C, Steiner L. Stereotactic Radiosurgical Treatment of Arteriovenous Malformations. In: *Modern Stereotactic Neurosurgery*. Topics in neurological surgery. Springer, Boston, MA; 1988:491-505. doi:10.1007/978-1-4613-1081-5_39
 13. Pollock BE, Kondziolka D, Flickinger JC, Patel AK, Bissonette DJ, Lunsford LD. Magnetic resonance imaging: an accurate method to evaluate arteriovenous malformations after stereotactic radiosurgery. *J Neurosurg*. 1996;85(6):1044-1049. doi:10.3171/jns.1996.85.6.1044
 14. Starke RM, Komotar RJ, Hwang BY, et al. A comprehensive review of radiosurgery for cerebral arteriovenous malformations: outcomes, predictive factors, and grading scales. *Stereotact Funct Neurosurg*. 2008;86(3):191-199. doi:10.1159/000126945
 15. Franzin A, Snider S, Boari N, et al. Evaluation of prognostic factors as predictor of AVMS obliteration after Gamma Knife radiosurgery. *Acta Neurochir (Wien)*. 2013;155(4):619-626. doi:10.1007/s00701-013-1631-2
 16. Ellis TL, Friedman WA, Bova FJ, Kubilis PS, Buatti JM. Analysis of treatment failure after radiosurgery for arteriovenous malformations. *J Neurosurg*. 1998;89(1):104-110. doi:10.3171/jns.1998.89.1.0104
 17. Gallina P, Nataf F, Merienne L, Schlienger M, Lefkopoulos D, Roux FX. [Retrospective analysis of failures in radiosurgery treatment of cerebral arteriovenous malformations]. *Neurochirurgie*. 2001;47(2-3 Pt 2):311-317.
 18. Flickinger JC, Kondziolka D, Maitz AH, Lunsford LD. An analysis of the dose-response for arteriovenous malformation radiosurgery and other factors affecting obliteration. *Radiother Oncol*. 2002;63(3):347-354.
 19. Touboul E, Al Halabi A, Buffat L, et al. Single-fraction stereotactic radiotherapy: a dose-response analysis of arteriovenous malformation obliteration. *Int J Radiat Oncol Biol Phys*. 1998;41(4):855-861.

20. Yamamoto Y, Coffey RJ, Nichols DA, Shaw EG. Interim report on the radiosurgical treatment of cerebral arteriovenous malformations. The influence of size, dose, time, and technical factors on obliteration rate. *J Neurosurg.* 1995;83(5):832-837. doi:10.3171/jns.1995.83.5.0832
21. Karlsson B, Lindquist C, Steiner L. Prediction of obliteration after gamma knife surgery for cerebral arteriovenous malformations. *Neurosurgery.* 1997;40(3):425-430; discussion 430-431.
22. Karlsson B, Lax I, Söderman M. Can the probability for obliteration after radiosurgery for arteriovenous malformations be accurately predicted? *Int J Radiat Oncol Biol Phys.* 1999;43(2):313-319.
23. Kondziolka D, Lunsford LD, Flickinger JC. Intraparenchymal brain stem radiosurgery. *Neurosurg Clin N Am.* 1993;4(3):469-479.
24. Kemeny AA, Dias PS, Forster DM. Results of stereotactic radiosurgery of arteriovenous malformations: an analysis of 52 cases. *J Neurol Neurosurg Psychiatry.* 1989;52(5):554-558.
25. Oermann EK, Ding D, Yen C-P, et al. Effect of Prior Embolization on Cerebral Arteriovenous Malformation Radiosurgery Outcomes: A Case-Control Study. *Neurosurgery.* 2015;77(3):406-417; discussion 417. doi:10.1227/NEU.0000000000000772
26. Gobin YP, Laurent A, Merienne L, et al. Treatment of brain arteriovenous malformations by embolization and radiosurgery. *J Neurosurg.* 1996;85(1):19-28. doi:10.3171/jns.1996.85.1.0019
27. Pollock BE, Kondziolka D, Lunsford LD, Bissonette D, Flickinger JC. Repeat stereotactic radiosurgery of arteriovenous malformations: factors associated with incomplete obliteration. *Neurosurgery.* 1996;38(2):318-324.
28. Natarajan SK, Born D, Ghodke B, Britz GW, Sekhar LN. Histopathological changes in brain arteriovenous malformations after embolization using Onyx or N-butyl cyanoacrylate. Laboratory investigation. *J Neurosurg.* 2009;111(1):105-113. doi:10.3171/2008.12.JNS08441
29. Phillips MH, Kessler M, Chuang FY, et al. Image correlation of MRI and CT in treatment planning for radiosurgery of intracranial vascular malformations. *Int J Radiat Oncol Biol Phys.* 1991;20(4):881-889.
30. Bova FJ, Friedman WA. Stereotactic angiography: an inadequate database for radiosurgery? *Int J Radiat Oncol Biol Phys.* 1991;20(4):891-895.
31. Gao X, Liang G, Li Z, et al. Transarterial coil-augmented Onyx embolization for brain arteriovenous malformation. Technique and experience in 22 consecutive patients. *Interv Neuroradiol.* 2014;20(1):83-90. doi:10.15274/INR-2014-10012
32. Willinsky R, TerBrugge K, Montanera W, Wallace C, Aggarwal S. Micro-arteriovenous malformations of the brain: superselective angiography in diagnosis and treatment. *AJNR Am J Neuroradiol.* 1992;13(1):325-330.
33. Potts MB, Zumofen DW, Raz E, Nelson PK, Riina HA. Curing arteriovenous malformations using embolization. *FOC.* 2014;37(3):E19. doi:10.3171/2014.6.FOCUS14228
34. Iyer A, D'souza M, Steinberg GK. Embolization before stereotactic radiosurgery for the treatment of brain arteriovenous malformations. *J Neurosurg Sci.* 2018;62(4):514-518. doi:10.23736/S0390-5616.18.04425-9

35. Marks MP, Marcellus ML, Santarelli J, et al. Embolization Followed by Radiosurgery for the Treatment of Brain Arteriovenous Malformations (AVMs). *World Neurosurg.* 2017;99:471-476. doi:10.1016/j.wneu.2016.12.059
36. Shtaya A, Millar J, Sparrow O. Multimodality management and outcomes of brain arteriovenous malformations (AVMs) in children: personal experience and review of the literature, with specific emphasis on age at first AVM bleed. *Childs Nerv Syst.* 2017;33(4):573-581. doi:10.1007/s00381-017-3383-4
37. Rockwell S, Dobrucki IT, Kim EY, Marrison ST, Vu VT. Hypoxia and radiation therapy: past history, ongoing research, and future promise. *Curr Mol Med.* 2009;9(4):442-458.
38. Fournier D, Terbrugge K, Rodesch G, Lasjaunias P. Revascularization of brain arteriovenous malformations after embolization with bucrylate. *Neuroradiology.* 1990;32(6):497-501.
39. Taylor C, Ashby WS, Gorassini DR, et al. Embolized cerebral arteriovenous malformations: a multivariate analysis of 101 excised specimens. *J Neurosurg.* March 2019:1-7. doi:10.3171/2018.12.JNS182244
40. Buell TJ, Ding D, Starke RM, Webster Crowley R, Liu KC. Embolization-induced angiogenesis in cerebral arteriovenous malformations. *J Clin Neurosci.* 2014;21(11):1866-1871. doi:10.1016/j.jocn.2014.04.010
41. Ventéjou S, Machet M-C, Herbreteau D, le Touze A, Lorette G, Maruani A. Hormonal receptors in cutaneous vascular malformations: 51 cases. *Virchows Arch.* 2019;474(6):755-761. doi:10.1007/s00428-019-02546-4
42. Desai M, Wali AR, Birk HS, Santiago-Dieppa DR, Khalessi AA. Role of pregnancy and female sex steroids on aneurysm formation, growth, and rupture: a systematic review of the literature. *Neurosurg Focus.* 2019;47(1):E8. doi:10.3171/2019.4.FOCUS19228
43. Duyka LJ, Fan CY, Coviello-Malle JM, Buckmiller L, Suen JY. Progesterone receptors identified in vascular malformations of the head and neck. *Otolaryngol Head Neck Surg.* 2009;141(4):491-495. doi:10.1016/j.otohns.2009.06.012
44. Miyawaki L, Dowd C, Wara W, et al. Five year results of LINAC radiosurgery for arteriovenous malformations: outcome for large AVMS. *Int J Radiat Oncol Biol Phys.* 1999;44(5):1089-1106.
45. Zipfel GJ, Bradshaw P, Bova FJ, Friedman WA. Do the morphological characteristics of arteriovenous malformations affect the results of radiosurgery? *J Neurosurg.* 2004;101(3):393-401. doi:10.3171/jns.2004.101.3.0393
46. Fuks Z, Kolesnick R. Engaging the vascular component of the tumor response. *Cancer Cell.* 2005;8(2):89-91. doi:10.1016/j.ccr.2005.07.014
47. Garcia-Barros M, Paris F, Cordon-Cardo C, et al. Tumor response to radiotherapy regulated by endothelial cell apoptosis. *Science.* 2003;300(5622):1155-1159. doi:10.1126/science.1082504
48. Dubois N, Rio E, Ripoche N, et al. Plasma ceramide, a real-time predictive marker of pulmonary and hepatic metastases response to stereotactic body radiation therapy combined with irinotecan. *Radiother Oncol.* 2016;119(2):229-235. doi:10.1016/j.radonc.2016.03.014

49. Kano H, Kondziolka D, Flickinger JC, et al. Stereotactic radiosurgery for arteriovenous malformations, Part 3: outcome predictors and risks after repeat radiosurgery. *J Neurosurg.* 2012;116(1):21-32. doi:10.3171/2011.9.JNS101741
50. Karlsson B, Kihlström L, Lindquist C, Steiner L. Gamma knife surgery for previously irradiated arteriovenous malformations. *Neurosurgery.* 1998;42(1):1-5; discussion 5-6.
51. Stahl JM, Chi Y-Y, Friedman WA. Repeat radiosurgery for intracranial arteriovenous malformations. *Neurosurgery.* 2012;70(1):150-154; discussion 154. doi:10.1227/NEU.0b013e31822c5740

Figure Legends

Figure 1 : Flow chart of the study population

Table 1 : Characteristics of the population of failure

Table 2 : Associations of causes of failure

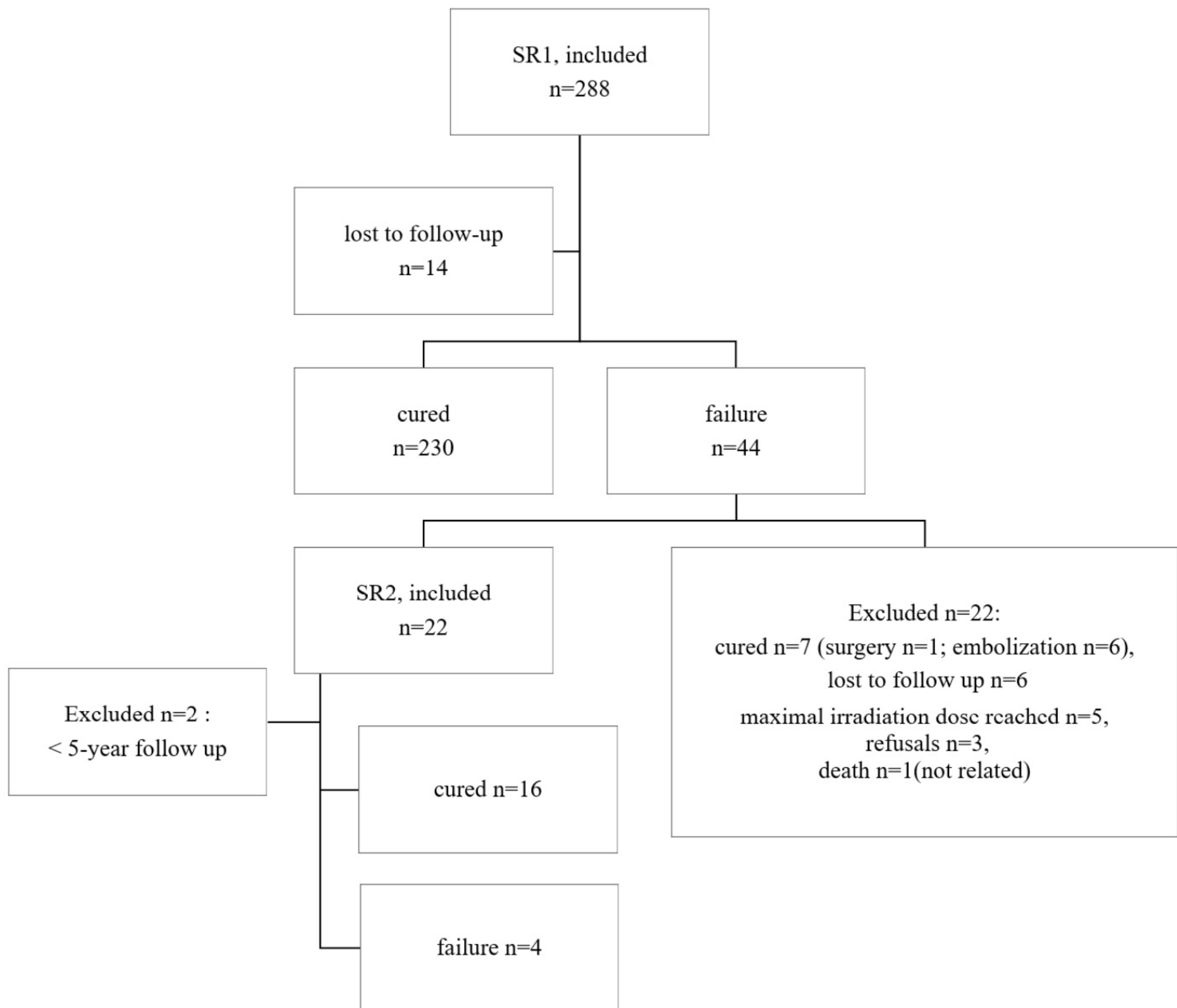


Table 1 : Characteristics of the population of failure

Population of Failure	
Age (years), mean \pmsd / [range]	36 \pm 14.7 / [13-61]
Gender, n (%)	
male	22 (0.50)
Female, n (%)	22 (0.50)
Clinical feature, n(%)	
hemorrhage	21 (0.48)
seizure	10 (0.23)
headache	9 (0.20)
progressive motor deficit	1 (0.02)
incidental finding	3 (0.07)
Previous Treatments, n (%)	
embolization	32 (0.73)
microsurgery	2 (0.05)
embolization + microsurgery	2 (0.05)
Location (eloquence), n (%)	
eloquent zone	32 (0.73)
non eloquent zone	12 (0.27)
Location, n (%)	
Frontal lobe	7 (0.16)
Parietal lobe	6 (0.14)
Temporal lobe	7 (0.16)
Occipital lobe	4 (0.09)
Cerebellum	1 (0.02)
Corpus callosum	2 (0.05)
Basal ganglia	3 (0.07)
brainstem	2 (0.05)
Spetzler & Martin, n (%)	
I	2 (0.05)
II	13 (0.30)
III	15 (0.34)
IV	14 (0.32)
Pollock score, mean \pmsd / [range]	1.17 \pm 0.417 / [0.324-2.220]
Dosimetrics Parameters, mean \pmsd / [range]	
Targeted Volume (cm ³)	2.18 \pm 2.2 / [0.13-10.8]

Table 1 : Characteristics of the population of failure

Minimal Marginal Dose (Gy)	20.72 \pm 3.6 / [11.3-25.7]
Maximal Marginal Dose (Gy)	28.56 \pm 6.8 / [20-63.7]
Reference Dose (Gy)	24.18 \pm 4.0 / [20-27]
ICRU (Gy)	26.36 \pm 1.1 / [22-27]

		female	age (years)	Patterns of failure											
				Insufficient nidus coverage	prior embolization	recanalization	Volume (cm ³)	Spetzler & Martin				Volume > 2 cm ³	Volume > 4 cm ³	Dose min < 18Gy	No cause
								I	II	III	IV				
		n (percentage)	SD; [range]	n (percentage)			(SD; range)	n (percentage)							
Insufficient nidus coverage	yes	7 (0.39)	33.83 +/- 12.73; [24-43]		15 (0.83)	0 (0)	1.52 +/- 1.49 [0.72-2.03]	0 (0)	6 (0.33)	5 (0.28)	7 (0.39)	5 (0.28)	1 (0.06)	2 (0.11)	0 (0)
	no	15 (0.58)	36.27 +/- 15.29; [22-45]		19 (0.73)	5 (0.19)	2.64 +/- 2.55 [0.61-4.23]	2 (0.08)	7 (0.27)	10 (0.38)	7 (0.27)	11 (0.42)	8 (0.31)	7 (0.27)	5 (0.19)
prior embolization	yes	18 (0.53)	31.28 +/- 11.90 [22-		15 (0.44)	5 (0.15)	2.50 +/- 2.33 [0.635-3.34]*	0 (0)	9 (0.26)	11 (0.32)	14 (0.41)	15 (0.44)	8 (0.24)	7 (0.21)	0 (0)*

			40] *												
	no	4 (0.40)	48 +/- 14. 51 [36- 60] *	3 (0.30)		0 (0)	1.10 +/- 1.40 [0.45-1.06]*	2 (0.20)	4 (0.40)	4 (0.4 0)	0 (0)	1 (0.1 0)	1 (0.1 0)	2 (0.20)	5 (0.50)*
recanalizat ion	yes	5 (1)*	35. 40 +/- 6.2 3 [34- 38]	0 (0)	5 (1)		2.18 +/- 2.22 [0.64-3.34]	0 (0)	1 (0.20)	3 (0.6 0)	1 (0.2 0)	3 (0.6 0)	2 (0.4 0)	2 (0.40)	0 (0)
	no	17 (0.44) *	35. 26 +/- 14. 97 [22- 45]	18 (0.46)	29 (0.74)		2.03 +/- 2.21 [0.61-2.47]	2 (0.05)	12 (0.31)	12 (0.3 1)	13 (0.3 3)	13 (0.3 3)	7 (0.1 8)	9 (0.23)	5 (0.13)
Spetzler & Martin	I	0 (0)	44. 50 +/- 31. 81 [22- 67]	0 (0)	0 (0)	0 (0)								0 (0)	2 (1)*

	II	6 (0.46)	39. 15 +/- 15. 37 [32- 52]	6 (0.46)	9 (0.69)	1 (0.08)								0 (0)	2 (0.15))*
	III	7 (0.47)	35. 00 +/- 14. 04 [26- 40]	5 (0.33)	11 (0.73)	3 (0.20)								5 (0.33)	1 (0.07))*
	IV	9 (0.64)	30. 64 +/- 10. 35 [22- 42]	7 (0.50)	14 (1)	1 (0.07)								4 (0.29)	0 (0)*
Volume > 2 cm³	yes	12 (0.75) *	35. 06 +/- 10. 93 [28- 41]	5 (0.31)	15 (0.94)	3 (0.19)								5 (0.31)	0 (0)
	no	10 (0.36) *	35. 39 +/- 15.	13 (0.46)	19 (0.68)	2 (0.07)								4 (0.14)	5 (0.18)

			95 [21. 5- 44. 5]												
volume > 4 cm³	yes	7 (0.78)	34. 89 +/- 15. 39 [22- 45]	1 (0.11)	8 (0.89)	2 (0.22)								4 (0.44)	0 (0)
	no	15 (0.43)	36. 78 +/- 8.5 4 [34- 40]	17 (0.49)	26 (0.74)	3 (0.09)								5 (0.14)	5 (0.14)
Dose min < 18Gy	yes	7 (0.78)	33. 56 +/- 11. 66 [30- 40]	2 (0.22)	7 (0.78)	0 (0)	3.66 +/- 3.20 [1.60-5]*	0 (0)	0 (0)	5 (0.5 6)	4 (0.4 4)	5 (0.5 6)	4 (0.4 4)		0 (0)
	no	15 (0.43)	35. 71 +/- 14. 90	16 (0.46)	27 (0.77)	5 (0.14)	1.80 +/- 1.77 [0.60-2.10]*	2 (0.06)	13 (0.37)	10 (0.2 9)	10 (0.2 9)	11 (0.3 1)	5 (0.1 4)		5 (0.14)

			[23-45]												
No cause of failure	yes	1 (0.20)	48. 40 +/- 18. 22 [38-60]	0 (0)	0 (0)*	0 (0)	0.57 +/- 0.35 [0.42-0.61]*	2 (0.40))*	2 (0.40))*	1 (0.20))*	0 (0)*	0 (0)	0 (0)	0 (0)	
	no	21 (0.54)	33. 59 +/- 12. 94 [23-43]	18 (0.46)	34 (0.87)*	5 (0.13)	2.38 +/- 2.28 [0.74-3.65]*	0 (0)*	11 (0.28))*	14 (0.36))*	14 (0.36))*	16 (0.41)	9 (0.23)	9 (0.23)	