

Folding dynamics of the Central Sulcus : a longitudinal study on preterms

Presented During: Poster Session

Tuesday, June 11, 2019: 12:45 PM - 02:45 PM

Poster No:

T505

Submission Type:

Abstract Submission

Authors:

Héloïse de Vareilles¹, Zhongyi Sun¹, Manon Benders², Clara Fischer¹, François Leroy³, Linda de Vries², Floris Groenendaal², Denis Rivière¹, Jessica Dubois³, Jean-Francois Mangin¹

Institutions:

¹NeuroSpin-CEA (Commissariat à l'Energie Atomique et aux Energies Alternatives), Gif-sur-Yvette, France,

²Wilhelmina Children's Hospital and Brain Center Rudolf Magnus, University Medical Center, Utrecht, Netherlands,

³Inserm, Gif-sur-Yvette, France

E-POSTER

Introduction:

Though unique among individuals, a global homogeneity within human cortical folding allows us to compare specific folds in a population. To study the development of cortical folds, which mainly occurs during the last trimester of pregnancy, we can take benefit of in vivo data acquired with MRI in preterm newborns [1], and map the folding process in a longitudinal way [2]. Within the sulcal pattern, the central sulcus stands out through its functional relevance, as the frontier between the motor and somatosensory cortices. Capturing the main variability traits of the developing central sulcus allows us to assess the way its typical features evolve before normal-term-birth.

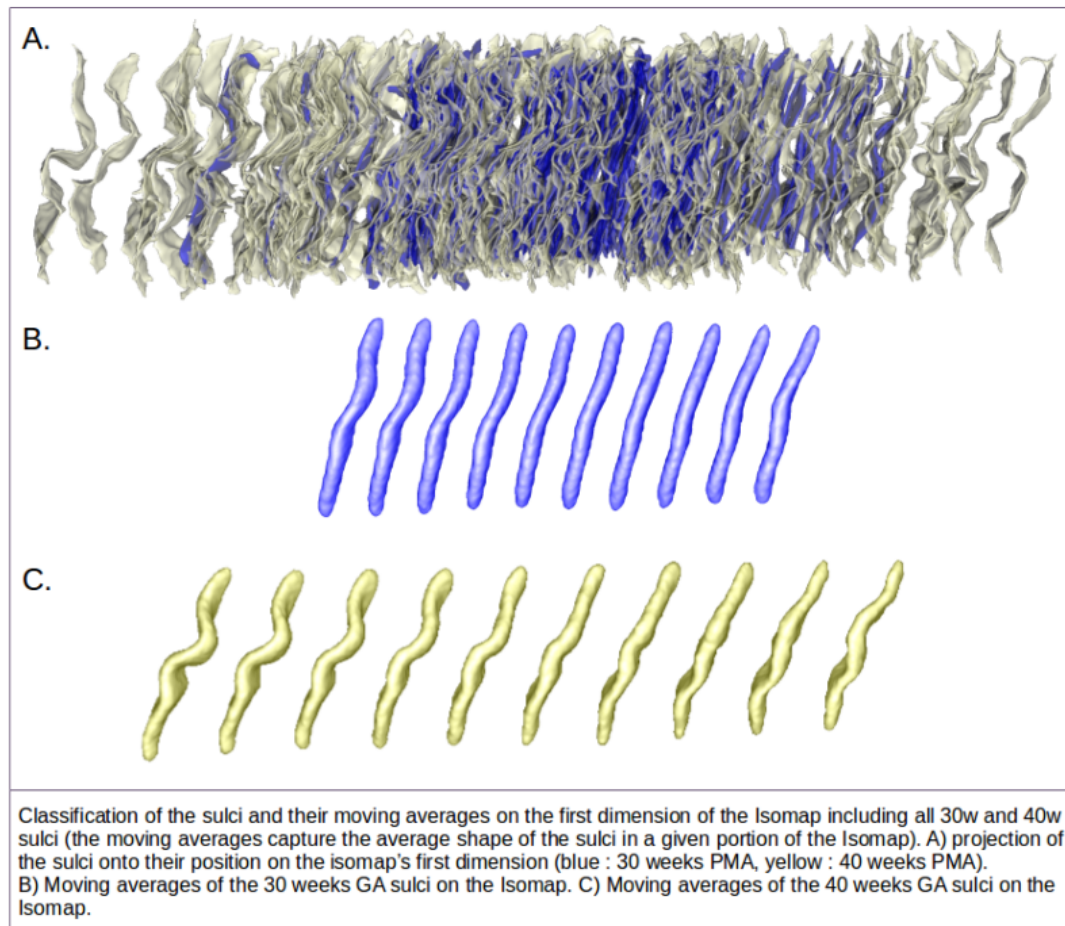
Methods:

This study relies on T2-weighted MRI images acquired using a 3T MR system (Achieva, Philips Medical Systems, Best, the Netherlands) from a cohort of 71 extremely preterm subjects (gestational age at birth : 26.5 ± 2.1 weeks) [2, 3]. Every subject was scanned twice, once at 30 weeks of post-menstrual age (PMA : 30.7 ± 0.8 weeks), and again at term-equivalent age (PMA : 41.1 ± 0.5 weeks). The central sulci were extracted using a dedicated BrainVisa toolbox which allows to segment T2-weighted MRI images of infants in a semi-automatic way [2]. 3D models of the brains were constructed, then normalised to the Talairach space [4]. Once extracted, the right sulci were flipped to match the

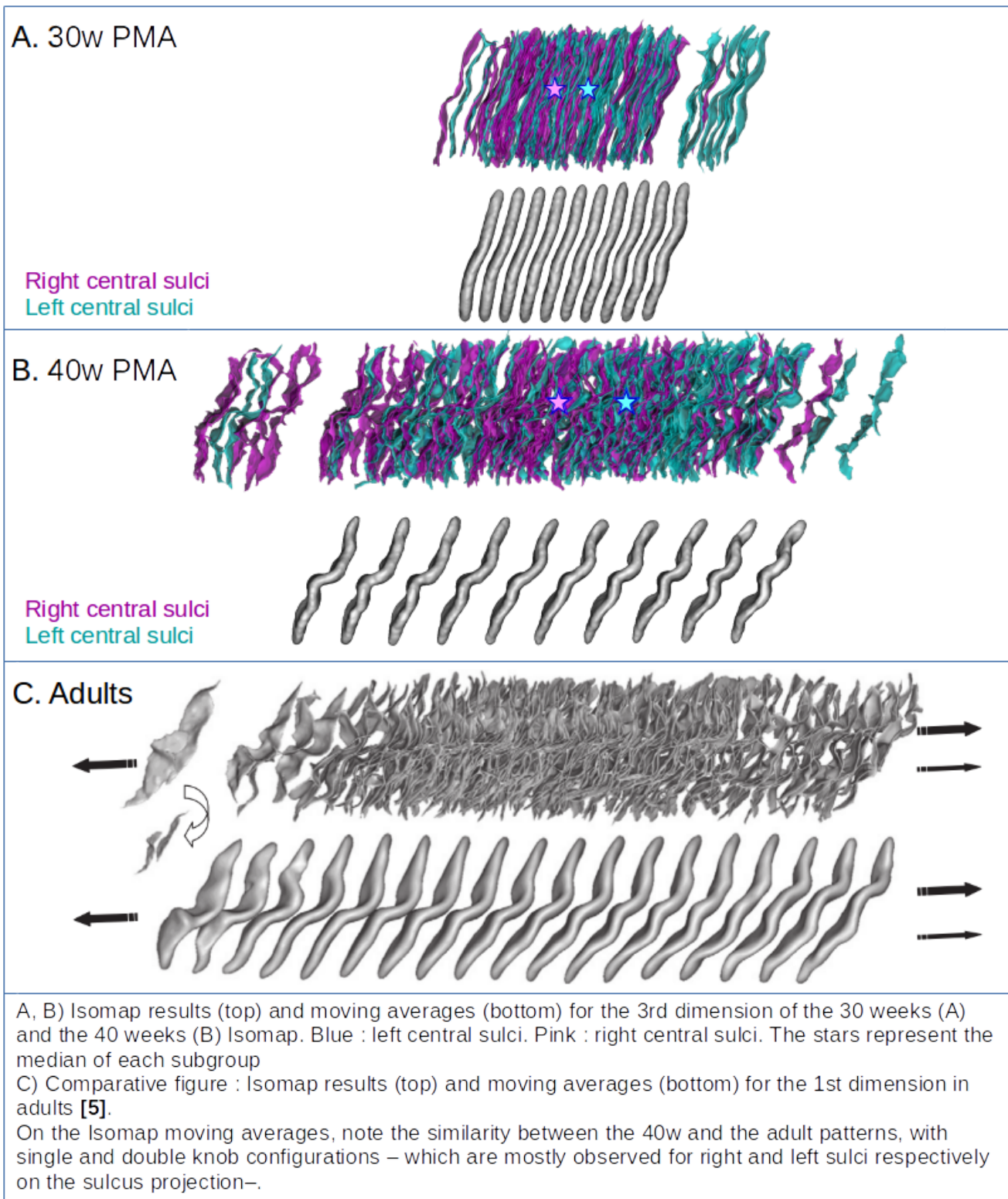
orientation of the left ones. The shape similarity between a group of sulci was captured using a pairwise quadratic distance matrix, computed after co-registration of each pair using the Iterative Closest Point algorithm [5]. The high-dimensional space spanned by the sulci was then projected on 3 axes using Isomap-based manifold learning [6]. Local average shapes were computed at regularly-spaced intervals [5] to visualise the classification along these axes (the position of a given sulcus on the Isomap axes is characteristic of its shape). On the Isomap axes generated using both acquisitions, we assessed the relationship between the positions of the 30 weeks sulci and the 40 weeks sulci with a Pearson correlation (r). On the age-specific datasets, we investigated the distribution of left central sulci versus right ones using Wilcoxon signed-rank tests.

Results:

For both 30 and 40 weeks sulci, the position on the age-specific Isomap and on the global Isomap were highly related (r between 0.78 and 0.95). On the global Isomap, we measured high correlation coefficients between the positions of the two groups on the three axes (dimension 1 : $r = 0.73$, dimension 2 : $r = 0.58$, dimension 3 : $r = 0.69$), suggesting that most of the shape features are already observed at 30w of PMA for the central sulcus. In adults, a previous study [5] shows a variability on the first axis ranging from a single knob to a double knob configuration, with an asymmetry in sulcal repartition depending on the hemisphere and the manual lateralization. Here we observed a similar shape variability in preterms: the third Isomap dimension showed an asymmetry as the left sulci tended towards a double knob configuration, while the right sulci tended towards a single knob configuration (Wilcoxon test's p-value at 30w: 0.002 | at 40w: 0.016).



•first Isomap dimension with moving averages



·third Isomap dimension with right/left differentiation

Conclusions:

This study revealed that the variance in the central sulcus shape is captured by the same features at 30w and 40w of age. In the cohort studied, the 3 main variability traits of the developing sulcus are already encoded during the third gestational trimester, and have a strong impact on the main sulcus features at term-equivalent age. Incidentally, the most important shape variation in adult central sulci, which correlates with handedness, seems to be already encoded in the preterm central sulci, but only as the third most important. This opens questions both about how and when this

feature gains importance relatively to those encoded by the first two axes, and about the degree of pre-birth handedness predetermination.

Acknowledgement to the HBP-SGA2 (785907) and FRM (DIC20161236445).

Imaging Methods:

Anatomical MRI

Lifespan Development:

Normal Brain Development: Fetus to Adolescence ¹

Modeling and Analysis Methods:

Classification and Predictive Modeling

Neuroanatomy:

Cortical Anatomy and Brain Mapping ²
Normal Development

Keywords:

Cortex
Development
PEDIATRIC
STRUCTURAL MRI
Other - Sulci

^{1|2}Indicates the priority used for review

My abstract is being submitted as a Software Demonstration.

No

Please indicate below if your study was a "resting state" or "task-activation" study.

Other

Healthy subjects only or patients (note that patient studies may also involve healthy subjects):

Patients

Was any human subjects research approved by the relevant Institutional Review Board or ethics panel? NOTE: Any human subjects studies without IRB approval will be automatically rejected.

Yes

Was any animal research approved by the relevant IACUC or other animal research panel? NOTE: Any animal studies without IACUC approval will be automatically rejected.

Not applicable

Please indicate which methods were used in your research:

Structural MRI

For human MRI, what field strength scanner do you use?

3.0T

Which processing packages did you use for your study?

Other, Please list - BrainVisa

Provide references using author date format

- [1] J. Dubois, M. Benders, A. Cachia, F. Lazeyras, R. Ha-Vinh Leuchter, S. V.Sizonenko, C. Borradori-Tolsa, J. F. Mangin, and P. S. Hüppi, « Mapping the early cortical folding process in the preterm newborn brain », *Cerebral Cortex*, vol. 18, no. 6, pp. 1444-1454, 2008.
- [2] K.J. Kersbergen, F. Leroy, I. Išgum, F. Groenendaal, L.S. de Vries, N.H. Claessens, I.C. van Haastert, P. Moeskops, C. Fischer, J.F. Mangin, M.A. Viergever, J. Dubois, M.J. Benders, « Relation between clinical risk factors, early cortical changes, and neurodevelopmental outcome in preterm infants » *Neuroimage*, 2016.
- [3] P. Moeskops, M. J. Benders, K. J. Kersbergen, F. Groenendaal, L. S. De Vries, M. A. Viergever, and I. Išgum, « Development of cortical morphology evaluated with longitudinal MR brain images of preterm infants » *PloS ONE*, vol. 10, no. 7, pp. 1-22, 2015.
- [4] J. Talairach and P. Tournoux, *Co-Planar Stereotaxis Atlas of the Human Brain*, 1988.
- [5] Z. Y. Sun, S. Klöppel, D. Rivière, M. Perrot, R. Frackowiak, H. Siebner, and J. F. Mangin, « The effect of handedness on the shape of the central sulcus », *NeuroImage*, 2012.
- [6] J. B. Tenenbaum, V. De Silva, and J. C. Langford, « A global geometric framework for nonlinear dimensionality reduction », *Science*, 2000.