



HAL
open science

Congenital unilateral upper limb absence flattens the contralateral hand knob

Zhong Yi Sun, Arnaud Cachia, Denis Rivière, Clara Fischer, Tamar Makin, Jean-François Mangin

► **To cite this version:**

Zhong Yi Sun, Arnaud Cachia, Denis Rivière, Clara Fischer, Tamar Makin, et al.. Congenital unilateral upper limb absence flattens the contralateral hand knob. 2017 Organization for Human Brain Mapping Meeting (OHBM 2017), Organization for Human Brain Mapping, Jun 2017, Vancouver, Canada. hal-02876124

HAL Id: hal-02876124

<https://hal.science/hal-02876124>

Submitted on 20 Jun 2020

HAL is a multi-disciplinary open access archive for the deposit and dissemination of scientific research documents, whether they are published or not. The documents may come from teaching and research institutions in France or abroad, or from public or private research centers.

L'archive ouverte pluridisciplinaire **HAL**, est destinée au dépôt et à la diffusion de documents scientifiques de niveau recherche, publiés ou non, émanant des établissements d'enseignement et de recherche français ou étrangers, des laboratoires publics ou privés.

Congenital unilateral upper limb absence flattens the contralateral hand knob

Poster Number:

3277

Submission Type:

Abstract Submission

Authors:

Zhong Yi Sun^{1,2}, Arnaud Cachia^{3,4}, Denis Rivière^{5,6}, Clara Fischer^{7,2}, Tamar Makin^{8,9}, Jean-François Mangin^{7,2}

Institutions:

¹UNATI, Neurospin, DRF, CEA, Paris Saclay University, Gif-sur-Yvette, France, ²CATI Multicenter Neuroimaging Platform, cati-neuroimaging.com, Gif-sur-Yvette, France, ³LaPsyDe, CNRS UMR 8240, Paris, France, ⁴INSERM-Paris Descartes University UMR 894, Imaging Biomarkers of Brain Development and Disorders, Ste Anne Hospital, Paris, France, ⁵UNATI, CEA DRF/I2BM NeuroSpin center; University Paris Saclay, Gif sur Yvette, France, ⁶CATI Multicenter Neuroimaging Platform, cati-neuroimaging.com, Gif-sur-yvette, France, ⁷UNATI, Neurospin, DRF, CEA, Paris Saclay University, Gif sur Yvette, France, ⁸FMRIB Centre, Nuffield Department of Clinical Neuroscience, University of Oxford, Oxford, United Kingdom, ⁹Institutes of Cognitive Neuroscience, University College London, London, United Kingdom

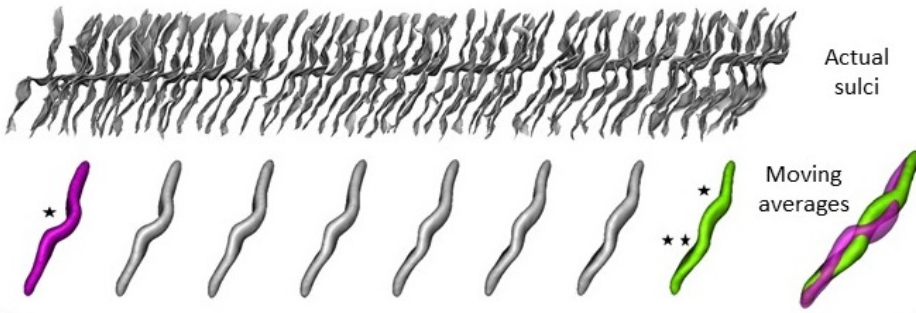
Introduction:

We are seven billion humans with unique fingerprints but also unique cortical folding patterns. The cortical folding process occurs essentially during the last trimester of pregnancy. The forces driving the folding dynamics are still unclear but several hypotheses assume interactions with the primal sketch of the cortical architecture [1]. Hence, the folding patterns could be a useful proxy of the variability of the cortical architecture and may embed the signature of abnormal developmental events associated for instance to cognitive efficacy [2] or psychiatric symptoms [3]. In this abstract, we explore this concept in the context of congenital unilateral upper limb absence [4], hereafter termed congenital one-handers. To test whether the folding pattern signatures can be specific to developmental events, we compare congenital one-handers with individuals with acquired unilateral upper limb amputation [5] and controls.

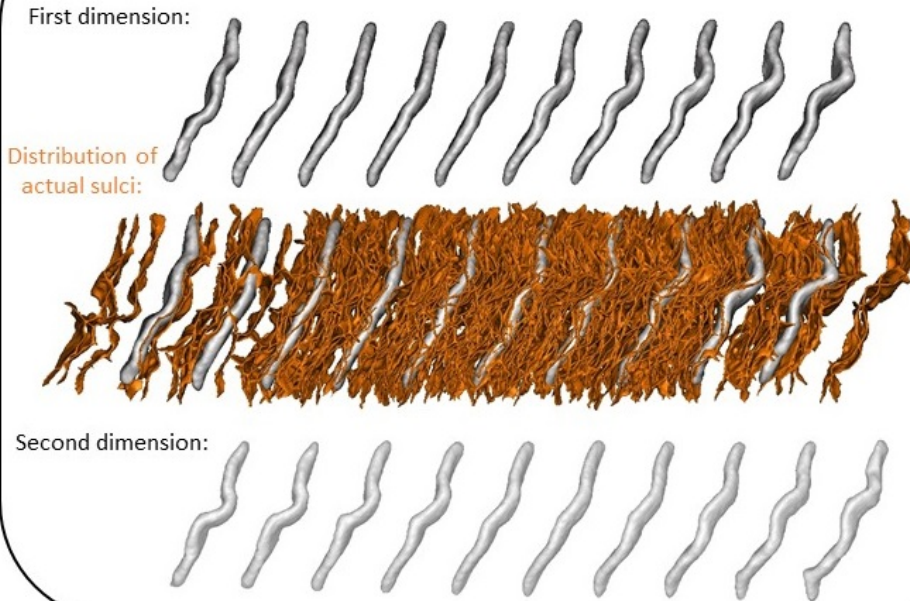
Methods:

This study relies on T1-weighted MPRAGE images collected using 3T Siemens scanners (Vario and Prisma) with 1mm isotropic resolution. 16 congenital one-handers (four with absent right hand), 16 amputees (four with absent right hand) and 24 two-handed controls were recruited. We focus on the shape of the central sulcus, using an approach developed previously to study morphological correlates of handedness [8]. First, the two central sulci were extracted automatically using the "Morphologist 2012" toolbox of BrainVisa [<http://brainvisa.info>] [9,10] and brought to Talairach space with an affine transform. Right sulci were flipped to become comparable with left sulci. Then, the shape similarity between two sulci was coded by the average quadratic distance between their 3D representations after pairwise rigid alignment. Finally, from the resulting similarity matrix, we used Isomap-based manifold learning to capture a bidimensional approximation of the high dimensional space spanned by each sulcus. For each Isomap dimension, we finally computed local average sulci at regularly spaced locations to clarify visually the shape variations encoded along the manifold. Hence, localization of a specific sulcus in the manifold provides a summary of its shape. We compared the localizations of the central sulci of the three groups using two-sided Wilcoxon tests.

A: First dimension of the Central Sulcus manifold in the general population



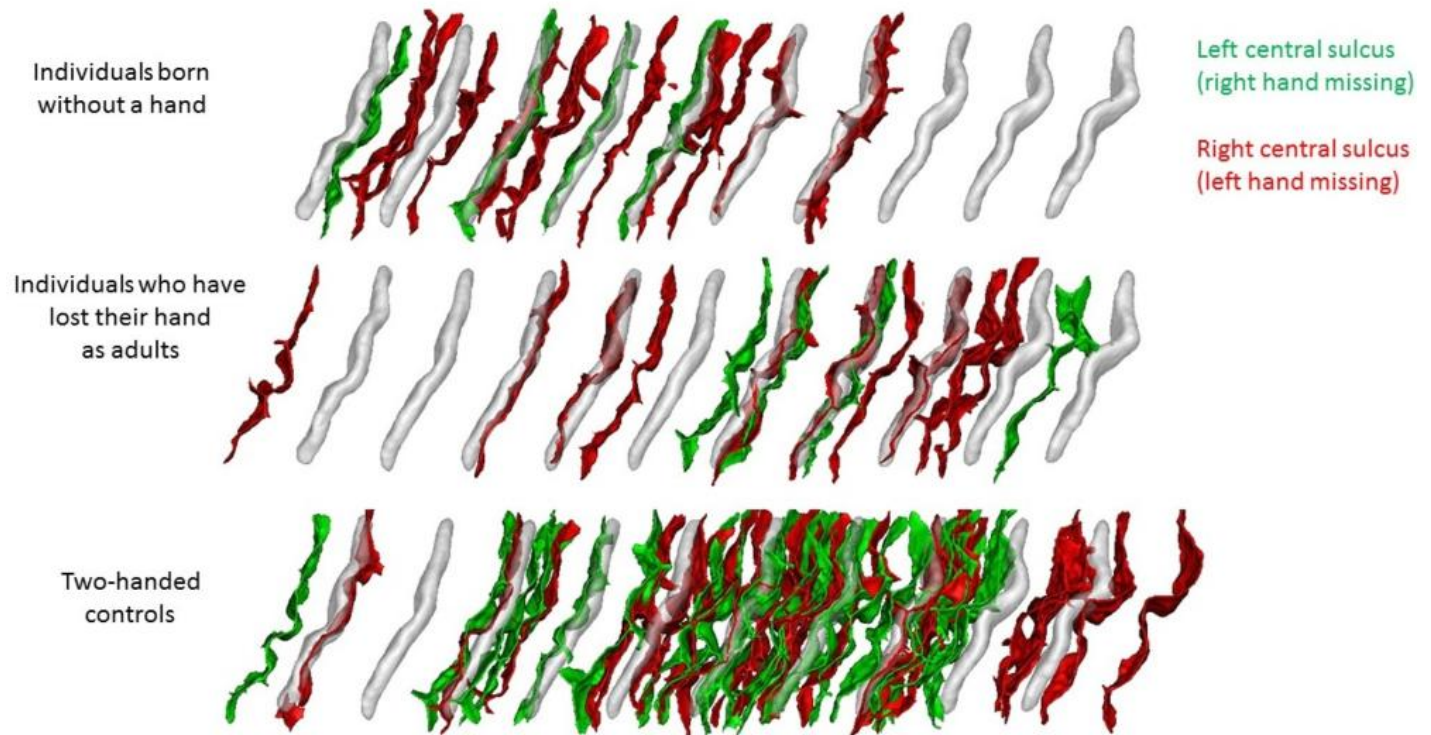
B: Central sulcus manifold in a population gathering one-handers and two-handed controls



Results:

In the past, we have been computing the shape-manifold of the central sulcus for over ten different databases. In each study, the first dimension of the manifold, namely the shape variations accounting for the largest amount of variance, did encode the transition from a single knob configuration toward a two knobs configuration [7,8] (see Fig 1.A). In contrast, in our study of one-handers, this specific shape variation is encoded by the second dimension of the Isomap only (see Fig 1.B). The first dimension encodes the transition from a flat sulcus toward a sulcus with a marked hand knob. This means that a large proportion of one-handers have at least one flat sulcus, which is an unusual configuration in the general population. For congenital one-handers, we found that the sulci contralateral to the missing hand are much more flattened than the two sulci of the controls ($p=0.0002$), which is not the case for their ipsilateral sulci ($p>0.5$) (Fig. 2). We did not find any difference between amputees and controls.

Shape of the Central Sulcus contralateral to the missing hand of one-handers



Conclusions:

Congenital hand deformities usually occur between the fourth and the eighth week after the embryo is formed [6]. Our study has shown that the aftermath regarding brain development prints a signature in the cortical folding morphology, a flattened hand knob. Furthermore, the absence of this signature after amputation (more than 10 years after for some amputees), shows that folding patterns are stable enough to encode developmental signatures resistant to adverse events occurring later in life. Future studies will tell us whether the extent of the remnant hand knob in the congenital one-handers depends on their usage of the handless arm in daily tasks.

Imaging Methods:

Anatomical MRI

Modeling and Analysis Methods:

Image Registration and Computational Anatomy ²

Neuroanatomy:

Cortical Anatomy and Brain Mapping ¹

Keywords:

Computational Neuroscience
Machine Learning
Morphometrics
Motor
Spatial Normalization
STRUCTURAL MRI

¹²Indicates the priority used for review

Would you accept an oral presentation if your abstract is selected for an oral session?

Yes

I would be willing to discuss my abstract with members of the press should my abstract be marked newsworthy:

Yes

Please indicate below if your study was a "resting state" or "task-activation" study.

Other

By submitting your proposal, you grant permission for the Organization for Human Brain Mapping (OHBM) to distribute the presentation in any format, including video, audio print and electronic text through OHBM OnDemand, social media channels or other electronic media and on the OHBM website.

I accept

Healthy subjects only or patients (note that patient studies may also involve healthy subjects):

Patients

Internal Review Board (IRB) or Animal Use and Care Committee (AUCC) Approval. Please indicate approval below. Please note: Failure to have IRB or AUCC approval, if applicable will lead to automatic rejection of abstract.

Yes, I have IRB or AUCC approval

Please indicate which methods were used in your research:

Structural MRI

For human MRI, what field strength scanner do you use?

3.0T

Provide references in author date format

1. Mangin JF. (2016), Spatial normalization of brain images and beyond, *Med Image Anal* 33:127-133
2. Cachia A. (2014), The shape of the ACC contributes to cognitive control efficiency in preschoolers, *J Cogn Neurosci* 26:96-106
3. Plaze M. (2015), Who is talking to me? — Self–other attribution of auditory hallucinations and sulcation of the right temporoparietal junction. *Schizophrenia Research* 169 (1), 95-100
4. Avital H. (2015), Normalisation of brain connectivity through compensatory behaviour, despite congenital hand absence, *Elife*, 4:e04605
5. Makin TR (2013). Phantom pain is associated with preserved structure and function in the former hand area. *Nature Communications* 4:1570.
6. Moore Keith L. (2008), Book Chapter: Highlights of fourth to eighth weeks. In: *The developing human: clinically oriented embryology*. 8th ed.
7. Sun Z. Y. (2016) 'Linking morphological and functional variability in hand movement and silent reading'. *Brain Structure and Function* 221(7):3361-71
8. Sun Z. Y. (2012), 'The Effect of Handedness on the Shape of the Central Sulcus', *Neuroimage*, 60(1):332-9
9. Perrot M. (2011), 'Cortical sulci recognition and spatial normalization'. *Medical Image Analysis*, 15(4):529-550
10. Fischer C. (2012). 'Morphologist 2012: the new morphological pipeline of BrainVISA'. In: *HBM*. Beijing.