



**HAL**  
open science

## Is the apical vertebra the most rotated vertebra in the scoliotic curve ?

Chris Labaki, Joeffroy Otayek, Abir Massaad, Ziad Bakouny, Mohammad Karam, Cyril Hanna, Anthony Kassab, Aren Joe Bizdikian, Georges Mjaess, Aya Karam, et al.

### ► To cite this version:

Chris Labaki, Joeffroy Otayek, Abir Massaad, Ziad Bakouny, Mohammad Karam, et al.. Is the apical vertebra the most rotated vertebra in the scoliotic curve ?. *Journal of Neurosurgery: Spine*, 2019, 31 (6), pp.775-921. <10.3171/2019.6.SPINE19203>. <hal-02794294>

**HAL Id: hal-02794294**

**<https://hal.science/hal-02794294v1>**

Submitted on 5 Jun 2020

**HAL** is a multi-disciplinary open access archive for the deposit and dissemination of scientific research documents, whether they are published or not. The documents may come from teaching and research institutions in France or abroad, or from public or private research centers.

L'archive ouverte pluridisciplinaire **HAL**, est destinée au dépôt et à la diffusion de documents scientifiques de niveau recherche, publiés ou non, émanant des établissements d'enseignement et de recherche français ou étrangers, des laboratoires publics ou privés.



HAL Authorization

# Is the apical vertebra the most rotated vertebra in the scoliotic curve?

Chris Labaki,<sup>1</sup> Joeffroy Otayek, MD, MSc,<sup>1</sup> Abir Massaad, PT, PhD,<sup>1</sup> Ziad Bakouny, MD, MSc,<sup>1</sup> Mohammad Karam, PT, MSc,<sup>1</sup> Cyril Hanna, MD,<sup>1</sup> Anthony Kassab, MD,<sup>1</sup> Aren Joe Bizdikian, MD, MSc,<sup>1</sup> Georges Mjaess,<sup>1</sup> Aya Karam,<sup>1</sup> Wafa Skalli, PhD,<sup>2</sup> Ismat Ghanem, MD, MSc,<sup>1</sup> and Ayman Assi, PhD<sup>1,2</sup>

<sup>1</sup>Faculty of Medicine, University of Saint-Joseph, Beirut, Lebanon; and <sup>2</sup>Institut de Biomécanique Humaine Georges Charpak, Arts et Métiers ParisTech, Paris, France

**OBJECTIVE** The aim of this study was to determine if the apical vertebra (AV) in patients with adolescent idiopathic scoliosis (AIS) is the most rotated vertebra in the scoliotic segment.

**METHODS** A total of 158 patients with AIS (Cobb angle range 20°–101°) underwent biplanar radiography with 3D reconstructions of the spine and calculation of vertebral axial rotations. The type of major curvature was recorded (thoracic, thoracolumbar, or lumbar), and both major and minor curvatures were included. The difference of levels (DL) between the level of maximal vertebral rotation (LMVR) and the AV was calculated as follows: DL = 0 if LMVR and AV were the same, DL = 1 if LMVR was directly above or below the AV, and DL = 2 if LMVR was separated by 1 vertebra or more from the AV. To investigate which factors explained the divergence of the LMVR from the AV, multinomial models were computed.

**RESULTS** The distribution of the DL was as follows: for major curvatures, 143 were DL = 0, 11 were DL = 1, and 4 were DL = 2; and for minor curvatures, 53 were DL = 0, 9 were DL = 1, and 31 were DL = 2. The determinants of a DL = 2 (compared with DL = 0) were lumbar curvature (compared with thoracic; adjusted OR 0.094,  $p = 0.001$ ), major curvature (compared with minor; adjusted OR 0.116,  $p = 0.001$ ), and curvatures with increasing apical vertebral rotation (adjusted OR 0.788,  $p < 0.001$ ).

**CONCLUSIONS** This study showed that the AV is the most rotated vertebra in the majority of major curvatures, while in minor curvatures, the most rotated vertebra appears to be the junctional vertebra between major and minor curvatures in a significant proportion of cases.

**KEYWORDS** spine; 3D biplanar x-rays; scoliosis; apical vertebra; vertebral rotation; deformity

**A**DOLESCENT idiopathic scoliosis (AIS) is a 3D deformity of the spine and is generally assessed on frontal radiographs by measuring the frontal Cobb angle of the scoliotic segment. A spine can have one or more curvatures: the one with the greatest Cobb angle is defined as major, and the one with the smaller Cobb angle as minor.<sup>15</sup> A scoliotic segment is defined by the upper- and lower-end vertebrae, and between them is the apical vertebra (AV).<sup>13</sup> A junctional vertebra is defined as being the link between two curvatures. The AV in a scoliotic

curvature is defined as the most translated vertebra in the global coordinate system on the frontal radiograph.<sup>3,21</sup> The AV is also the most laterally deviated vertebra from the center sacral vertical line.<sup>15</sup>

In order to achieve better surgical outcomes, correction of scoliosis must focus on all 3 planes (frontal, sagittal, and transverse). In the transverse plane, the main concern is to correct the vertebral axial rotations, especially the apical one.<sup>16</sup> In cases of thoracic and thoracolumbar scoliosis, vertebral axial rotation is responsible for the rib

hump, which accounts for one of the most important factors influencing quality of life in scoliosis patients, causing a major cosmetic deformity in affected patients and even severe respiratory complications in severe scoliosis.<sup>7</sup> A consensus is established that the AV is also the most rotated vertebra in the axial plane. To our knowledge, only a few studies have attempted to verify this claim, resulting in controversial conclusions.<sup>1,4</sup>

Several methods can be used to measure vertebral rotations.<sup>14</sup> Four methods are based on frontal standing radiographs (Cobb,<sup>5</sup> Nash-Moe,<sup>22</sup> Perdriolle,<sup>20</sup> and Stokes<sup>25</sup>), while 2 methods are based on CT scans (Aaro-Dahlborn<sup>24</sup> and Ho et al.<sup>19</sup>). The methods based on frontal radiographs are known to be inaccurate since they are based on the estimation of the transverse plane from a frontal view of the spine. The methods based on CT scans are known to expose patients to large amounts of radiation and make it difficult to determine the axial vertebral rotations due to compensation caused by the supine position.<sup>26</sup> Recently, full-body biplanar radiographs have been available in several centers worldwide, allowing for 3D reconstructions of the spine in the standing position.<sup>9</sup> This technique also allows calculation of the vertebral rotations in the 3 planes<sup>11,18</sup> with previously quantified precision and reproducibility.<sup>2,10</sup> The use of this technique could be practical in evaluating the axial rotation of the AV.

Thus, the aim of this study was to determine if maximal vertebral axial rotation occurs at the level of the apex of the scoliotic curve, using 3D reconstruction of the spine based on biplanar radiographs.

## Methods

This study was approved by our institutional review board. The population comprised 158 patients with AIS (mean age  $14.9 \pm 3.3$  years [ $\pm$  SD], 132 female patients, mean Cobb angle  $40^\circ$  [range  $20^\circ$ – $100^\circ$ ]) who presented to our center for evaluation or follow-up. Demographic characteristics of all patients were collected (age, sex, weight, height, and BMI).

Patients underwent low-dose biplanar radiography of the spine and pelvis in a standing position<sup>6</sup> using EOS (EOS Imaging). Spines were reconstructed in 3D using SterEOS (version 1.6.4.7977, EOS Imaging) by well-trained orthopedic residents (Fig. 1). The method of 3D reconstruction uses parametric models based on longitudinal and transverse inferences<sup>8</sup> that allow calculation of the vertebral body orientation in the coronal, sagittal, and axial planes. During the process of 3D reconstruction, curvature identification is made possible by determining the upper-end (cranial), apical, and lower-end (caudal) vertebrae of each curvature by the operators. The AV was determined as the most laterally deviated vertebra in the scoliotic curvature relative to the global coordinate system, while the cranial and caudal vertebrae were defined as the most tilted vertebrae in the scoliotic curvature.<sup>21</sup> Then, the following parameters were collected: 1) location of the curvature: thoracic (the AV is located above T12), thoracolumbar (the AV is either T12 or L1), or lumbar (the AV is located below L1);<sup>15</sup> 2) type of curvature: major (the highest frontal Cobb angle) or minor; and 3) spinopelvic parameters in 3D (Fig. 2): axial rotation

of all vertebrae in each scoliotic curvature, including the apical vertebral rotation (AVR), the level of maximal vertebral rotation (LMVR) in the scoliotic curvature, frontal Cobb angle of each curvature, L1–S1 lumbar lordosis (LL), and T1–T12 thoracic kyphosis (TK) as well as the pelvic incidence (PI), pelvic tilt (PT), and sacral slope (SS).

The difference of levels (DL) between the LMVR and the AV was calculated. The DL was coded as 0 if the LMVR was the AV or if the difference between the AVR and the maximal vertebral rotation in the scoliotic curvature was inferior to the uncertainty threshold of  $\pm 6^\circ$ .<sup>10</sup> The DL was coded as 1 if the LMVR was directly above or below the AV. The DL was coded as 2 if the LMVR was separated by 1 vertebra or more from the AV (Fig. 3).

In order to evaluate the uncertainty of the choice of the AV, 3 trained operators (orthopedic residents) had selected the AV on the radiographs, using the same technique described above, 3 times each, on a subset of 94 patients, for both major and minor curvatures. In total, the AV was selected on 188 curvatures.

## Statistical Analysis

The uncertainty on the choice of the AV was evaluated by calculating the reproducibility ( $S_R$ ) as defined by the ISO (International Organization for Standardization) of norm.<sup>12</sup> Then, the 95% confidence interval was calculated ( $2S_R$ ). The error on the estimate of the reproducibility was less than 5%.<sup>17</sup>

The DL between the LMVR and the AV was reported for both major and minor curvatures. Comparisons between the results for both curvature types were performed using a chi-square test. When the LMVR was different from the AV, the radiographs were checked to verify if the LMVR was a junctional vertebra or if the apex was an intervertebral disc or if there was any other noticeable reason.

In order to explore the relationship between the divergence of the LMVR from the AV, a univariate multinomial analysis was performed. The dependent variable was the DL, while the independent variables were demographics, location of the curvature, type of curvature, Cobb angle, TK, LL, and PI.

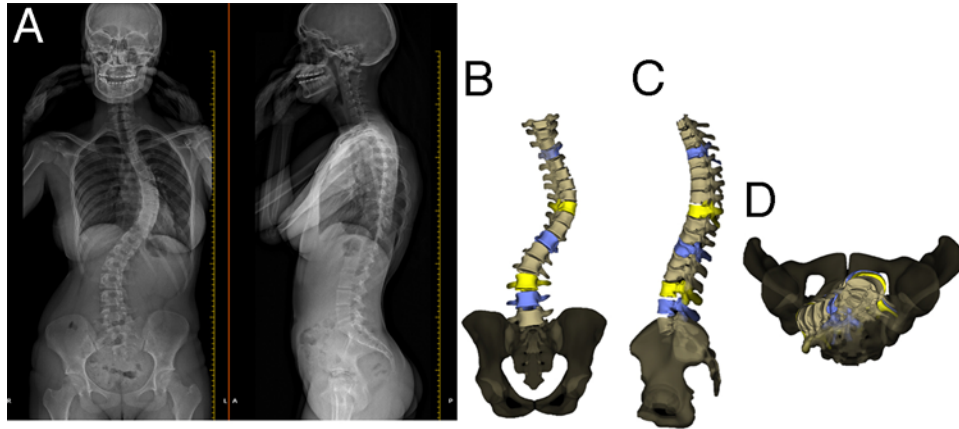
Then, to account for possible confounding factors, a stepwise multivariate multinomial analysis was performed. The dependent variable was the DL. The independent variables that were shown to be significant in the univariate analysis were included. Effect sizes are reported as odds ratios for univariate models and adjusted odds ratios (aORs) for multivariate models, along with their 95% confidence intervals. IBM SPSS (version 23.0, IBM Corp.) and Xlstat (version 2018.1, Addinsoft) were used for the statistical analysis, and the level of statistical significance was set at 0.05.

## Results

In total, 158 major and 93 minor curvatures were included, with mean Cobb angles of  $42.0^\circ \pm 17.7^\circ$  (range  $20^\circ$ – $101^\circ$ ) and  $36.3^\circ \pm 14.6^\circ$  (range  $20^\circ$ – $95^\circ$ ), respectively.

The reproducibility on the choice of AV was 0.26 and the 95% confidence interval was 0.52 (unit: vertebra).

The distribution of the DL of major curvatures was as



**FIG. 1.** Full-body low-dose biplanar radiographs (A) with 3D reconstruction of the spine (frontal [B], lateral [C], and horizontal [D] views). Figure is available in color online only.

follows: 143 major curvatures had a DL of 0, 11 had a DL of 1, and 4 had a DL of 2. The distribution of the DL of minor curvatures was as follows: 53 minor curvatures had a DL of 0, 9 had a DL of 1, and 31 had a DL of 2 (Fig. 4). This distribution was significantly different when compared between major and minor curvatures ( $p < 0.001$ ).

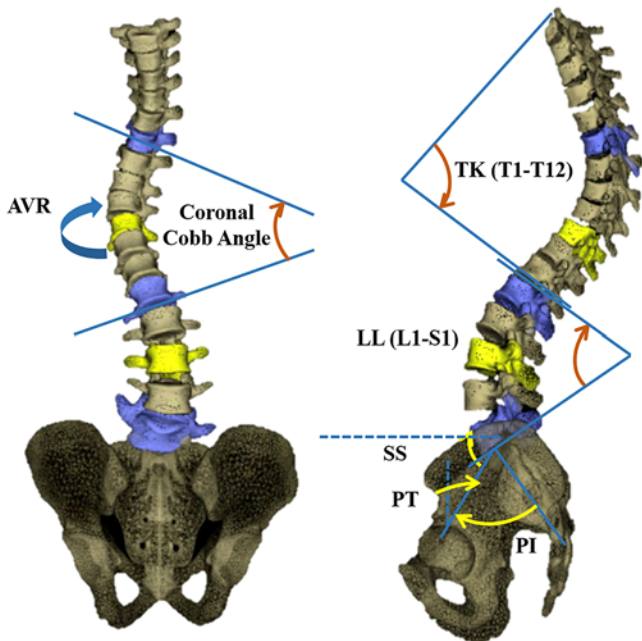
When verifying the spinal radiographs in cases in which the LMVR did not coincide with the AV, major curves largely showed either an LMVR at the junctional vertebra or the apex coinciding with an intervertebral disc; minor curves largely showed an LMVR at the junctional vertebra (Table 1).

The spinopelvic parameters calculated in 3D are shown in Fig. 5. Univariate analysis showed that thoracolumbar

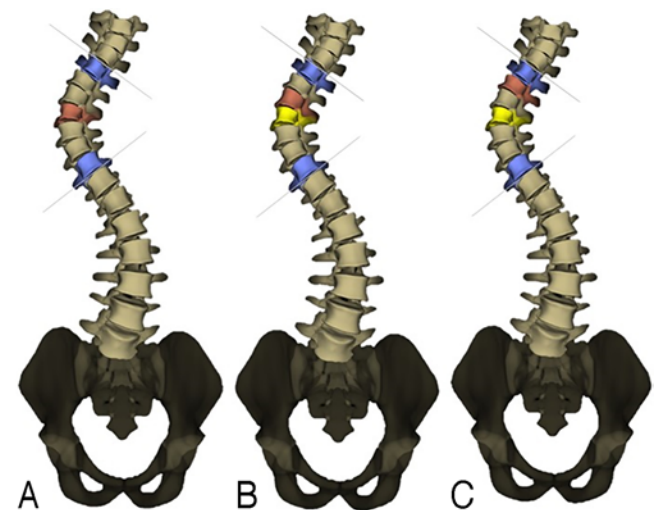
scoliosis (OR 0.064,  $R^2 = 0.14$ , 95% CI 0.008–0.483,  $p = 0.008$ ) and lumbar scoliosis (OR 0.194,  $R^2 = 0.14$ , 95% CI 0.065–0.577,  $p = 0.003$ ) were significantly less likely to have a DL of 2 (as opposed to a DL of 0) when compared with thoracic scoliosis.

Major curvatures (OR 0.058, 95% CI 0.021–0.157;  $R^2 = 0.23$ ,  $p < 0.001$ ), as well as curvatures with increasing Cobb angle (OR 0.973, 95% CI 0.948–0.999;  $R^2 = 0.03$ ,  $p = 0.044$ ) and increasing AV rotation (OR 0.732, 95% CI 0.659–0.814;  $R^2 = 0.34$ ,  $p < 0.001$ ) were also found to be significantly less likely to have a DL of 2 (as opposed to a DL of 0).

When multivariate analysis was conducted, the determinants of a DL of 2 (compared with a DL of 0) were found to be: lumbar curvature (compared with thoracic; adjusted OR [aOR] 0.094, 95% CI 0.023–0.383,  $p = 0.001$ ), major scoliotic curvature (compared with minor curvatures; aOR 0.116, 95% CI 0.032–0.418,  $p = 0.001$ ), and



**FIG. 2.** Frontal and sagittal spinopelvic parameters obtained from 3D reconstructions. PI = pelvic incidence; PT = pelvic tilt; SS = sacral slope. Figure is available in color online only.



**FIG. 3.** DL between the LMVR (red vertebrae) and the AV (yellow vertebrae). A: DL = 0. B: DL = 1. C: DL = 2. The blue vertebrae are upper and lower limits of the curvature. Figure is available in color online only.

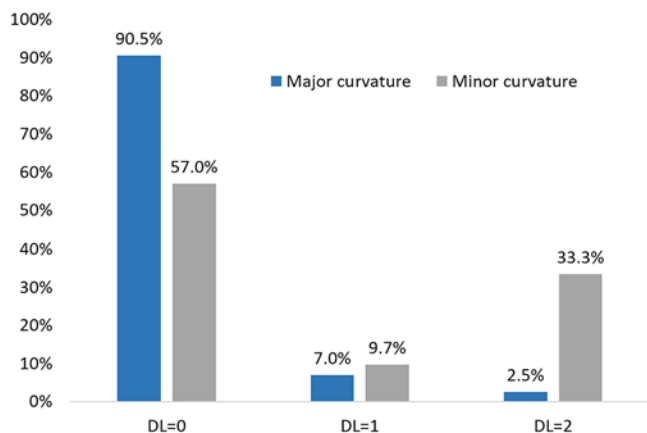


FIG. 4. Distribution of the DL in major and minor curvatures. Figure is available in color online only.

curvatures with increasing apical vertebral axial rotation (aOR 0.788, 95% CI 0.693–0.897,  $p < 0.001$ ).

In both the univariate and multivariate models, the occurrence of a DL of 1 compared with a DL of 0 was found to be independent of all demographic and curvature characteristics. Both univariate and multivariate analyses are detailed in Table 2.

## Discussion

Adolescent idiopathic scoliosis is a deformity of the spine that occurs in the 3 planes, and the AV is considered to be the most translated vertebra from the spinopelvic plumb line on frontal radiography. It was suggested that the AV might also be the most axially rotated vertebra in the horizontal plane, with no evidence considering this topic. Based on this hypothesis, the surgical correction of scoliosis in the transverse plane, which plays a considerable role in the correction of the 3D spinal deformity, especially the rib hump, in case of thoracic and thoracolumbar scoliosis, focused mainly on the correction of the AVR.<sup>16</sup>

Two previous studies evaluated the rotation of the AV in relation to surrounding vertebrae within the scoliotic curve. Birchall et al. found that the most rotated vertebra was always located at the apex of the scoliotic curvature in a total of 10 curvatures, while Acarogulu et al. found that only a minority of scoliotic curvatures have their apex corresponding to the level of maximal rotation.<sup>1,4</sup> However, these studies were conducted on a small number of patients (10 and 33 patients, respectively) and were based on the analysis of vertebral rotation utilizing MRI<sup>4</sup> and CT scans<sup>1</sup> as imaging techniques. These techniques, although considered the gold standard for spine imaging, are performed with the patient in a supine position. This position is known to alter the scoliotic curvature compared with standing radiographs.<sup>26</sup> As a result, in order to study the entire alignment of the spine and the magnitude of a deformity in the scoliotic segment in the 3 planes, standing radiographs are necessary.

The results of the current study showed that the AV was

TABLE 1. Description of cases in which the AV did not coincide with the most rotated vertebra in the scoliotic segment in a sample of 158 patients with AIS

Reason	Major Curvatures	Minor Curvatures
Most rotated vertebra is the junctional vertebra	7	38
Apical disc	6	1
End vertebra is the sacrum	1	1
Low Cobb angle (10°–20°)	1	0

the most axially rotated vertebra in 88% of major scoliotic curvatures and only in 55% of minor scoliotic curvatures.

In a large, significant proportion (45%) of minor curvatures, the AV does not coincide with the most axially rotated vertebra. In an attempt to understand this divergence and when analyzing each radiograph, it was evident that in minor curvatures, the LMVR was the junctional vertebra in 95% of cases. This reinforces the need to identify the limits of instrumentation through a detailed 3D assessment of each vertebral level.

Surprisingly, even in major curvatures, the assumed concept that the AV is the most axially rotated vertebra is not always applicable (12% of cases). However, when studying each radiograph to detect the reasons responsible for the aforementioned results, we found that in a large proportion (40%) of major curvatures having a DL different from 0, the apex of the curvature was in fact the intervertebral disc. When taking this result into consideration, the proportion of major curvatures having a DL equal to 0 increased from 88% to 94%. This means that only 6% of major curvatures had their AV not aligning with the most axially rotated vertebra, making the assumed concept of maximally rotated AV verified in the vast majority of cases of major curvatures. This finding should be taken into account while planning scoliosis correction using the vertebral derotation at each level.

Univariate and multivariate analyses were performed to assess which demographic or spinopelvic parameters most influenced the DL between the apex and the most axially rotated vertebra.

The result that major curvatures were less likely to have a DL of 2 as compared with minor curvatures could be probably explained by the fact that the minor curvature is usually influenced by the major curvature, thus influencing vertebral rotations as well. In fact, minor curvatures are usually compensatory curvatures that develop in order to address the tilting of the spine in the frontal plane secondary to the corresponding major curvatures.

In the univariate analysis, scoliotic curvatures with increasing Cobb angle or with an increasing AVR were less likely to have a DL of 2. In the multivariate analysis, only scoliotic curvatures with increasing AVR were less likely to have a DL of 2. This latter result could be explained by the fact that an increasing AVR is usually correlated to an increasing Cobb angle,<sup>23</sup> as the spinal deformity in scoliosis occurs in the 3 planes, thus the AVR becoming the only determinant.

**TABLE 2. Determinants of the difference of levels between the AV and the most rotated vertebra in the scoliotic segment in 158 patients with AIS**

DL Btwn AV & the Most Rotated Vertebra	p Value	OR	95% CI
Univariate analysis			
DL = 1*			
Qualitative			
Female sex†	0.12	5.01	0.65–38.47
Segment‡			
Thoracolumbar	0.094	0.17	0.02–1.35
Lumbar	0.75	1.16	0.46–2.93
Major curvature§	0.18	0.54	0.21–1.33
Quantitative			
Cobb angle	0.32	1.01	0.99–1.03
Rotation of the AV	<b>0.04</b>	0.94	0.89–1.01
Age	0.46	0.94	0.80–1.10
Weight	0.35	0.98	0.94–1.02
Height	0.92	0.78	0.01–84.35
L1–S1 (LL)	0.28	0.98	0.94–1.02
T1–12 (TK)	0.64	0.99	0.96–1.02
DL = 2*			
Qualitative			
Sex†	0.41	1.53	0.56–4.18
Segment‡			
Thoracolumbar	<b>0.01</b>	0.06	0.01–0.48
Lumbar	<b>0.01</b>	0.19	0.07–0.58
Major curvature§	<b>&lt;0.001</b>	0.06	0.02–0.16
Quantitative			
Cobb angle	<b>0.04</b>	0.97	0.95–0.99
Rotation of the AV	<b>&lt;0.001</b>	0.73	0.66–0.81
Age	0.28	1.05	0.96–1.15
Weight	0.54	1.01	0.98–1.04
Height	0.63	0.4	0.01–16.31
LL	0.31	1.01	0.99–1.05
TK	0.89	1	0.98–1.03
	p Value	aOR	95% CI
Multivariate analysis			
DL = 1*			
Qualitative			
Segment‡			
Thoracolumbar	0.15	0.21	0.26–1.72
Lumbar	0.98	0.98	0.35–2.78
Major curvature§	0.64	0.77	0.26–2.29
Quantitative			
Rotation of the AV	0.23	0.96	0.90–1.03

CONTINUED IN NEXT COLUMN »

» CONTINUED FROM PREVIOUS COLUMN

**TABLE 2. Determinants of the difference of levels between the AV and the most rotated vertebra in the scoliotic segment in 158 patients with AIS**

DL Btwn AV & the Most Rotated Vertebra	p Value	OR	95% CI
Multivariate analysis			
DL = 2*			
Qualitative			
Segment‡			
Thoracolumbar	0.09	0.13	0.13–1.38
Lumbar	<b>0.001</b>	0.09	0.02–0.38
Major curve§	<b>0.001</b>	0.12	0.03–0.42
Quantitative			
Rotation of the AV	<b>&lt;0.001</b>	0.79	0.69–0.90

\* DL = 0 as reference.

† Male sex as reference.

‡ Thoracic as reference.

§ Minor as reference.

Lumbar curvatures were less likely to have a DL of 2 than thoracic curvatures. This result cannot be explained by the 3D spinal deformity of the spine alone. The rib cage and the surrounding soft tissues could be influencing vertebral rotation. Musculoskeletal modeling, including mechanical properties of the spine and surrounding soft tissues, could help in explaining the difference between lumbar and thoracic curvatures in response to the deformity mechanisms.

## Conclusions

A majority (94%) of the major scoliotic curvatures (when accounting for the intervertebral disc as the apex of the curvature in selected cases) had the AV as the most rotated vertebra. Only 55% of the minor scoliotic curvatures had their AV as the most rotated vertebra. In lumbar curvatures, the AV was more likely to be the most axially rotated vertebra. With increasing severity of scoliosis, as illustrated by an increasing Cobb angle and an increasing AVR, the most rotated vertebra was more likely to be the AV. Even though the AV was the most rotated vertebra in most cases, special consideration should be given when correcting the rotational deformity in patients with a thoracic minor curve to avoid overcorrection at the level of the apex or undercorrection at the level of the junctional vertebra. The findings of this study are useful while planning surgical correction. For those surgeons who use the vertebral rotation technique, greater rotation correction should be undertaken at the apex of major curves. In cases in which selective thoracic fusion is planned, assessment of vertebral rotation at the junctional area is mandatory in order to include the most rotated vertebra in the fusion.

## Acknowledgments

This study was funded by the University of Saint-Joseph (grant no. FM288).

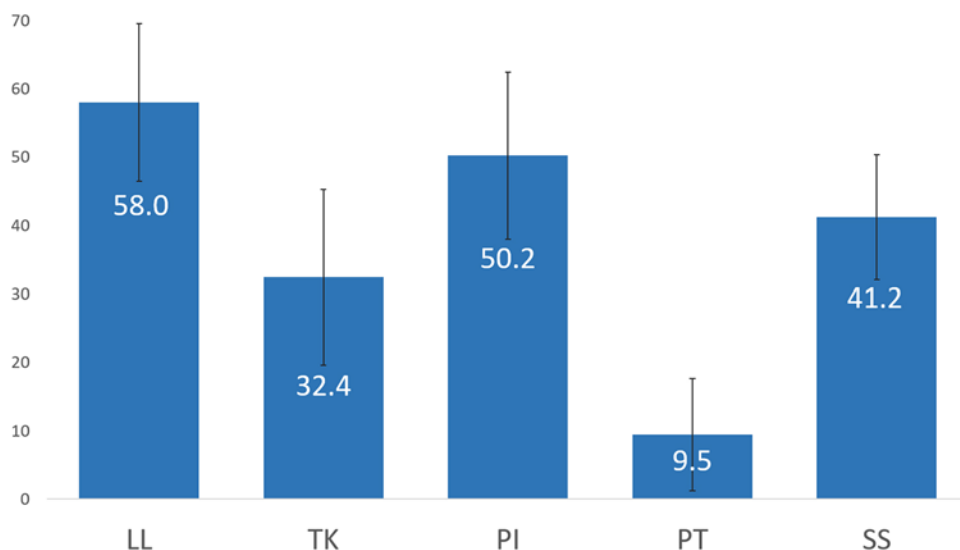


FIG. 5. Average values (degrees) of the spinopelvic parameters along with their standard deviations (error bars) in 158 patients with AIS. Figure is available in color online only.

## References

1. Acaroglu E, Yazici M, Deviren V, Alanay A, Cila A, Surat A: Does transverse apex coincide with coronal apex levels (regional or global) in adolescent idiopathic scoliosis? *Stud Health Technol Inform* **88**:136–139, 2002
2. Al-Aubaidi Z, Lebel D, Oudjhane K, Zeller R: Three-dimensional imaging of the spine using the EOS system: is it reliable? A comparative study using computed tomography imaging. *J Pediatr Orthop B* **22**:409–412, 2013
3. Anitha H, Prabhu GK: Identification of apical vertebra for grading of idiopathic scoliosis using image processing. *J Digit Imaging* **25**:155–161, 2012
4. Birchall D, Hughes DG, Hindle J, Robinson L, Williamson JB: Measurement of vertebral rotation in adolescent idiopathic scoliosis using three-dimensional magnetic resonance imaging. *Spine (Phila Pa 1976)* **22**:2403–2407, 1997
5. Drerup B: Principles of measurement of vertebral rotation from frontal projections of the pedicles. *J Biomech* **17**:923–935, 1984
6. Faro FD, Marks MC, Pawelek J, Newton PO: Evaluation of a functional position for lateral radiograph acquisition in adolescent idiopathic scoliosis. *Spine (Phila Pa 1976)* **29**:2284–2289, 2004
7. Hisam MA, Siti NS, Jou NP, Ghaneshinee S, Shaharuddin AR, Azmi B, et al: Does the quality of life in operated patients with adolescent idiopathic scoliosis correspond with the radiographic parameters? *Malays Orthop J* **9**:37–40, 2015
8. Humbert L, De Guise JA, Aubert B, Godbout B, Skalli W: 3D reconstruction of the spine from biplanar x-rays using parametric models based on transversal and longitudinal inferences. *Med Eng Phys* **31**:681–687, 2009
9. Humbert L, De Guise JA, Godbout B, Cresson T, Branchaud D, Chav R, et al: Fast 3D reconstruction of the spine from biplanar radiography: a diagnosis tool for routine scoliosis diagnosis and research in biomechanics. *Comput Methods Biomech Biomed Engin* **12**:151–152, 2009
10. Ilharreborde B, Steffen JS, Nectoux E, Vital JM, Mazda K, Skalli W, et al: Angle measurement reproducibility using EOS three-dimensional reconstructions in adolescent idiopathic scoliosis treated by posterior instrumentation. *Spine (Phila Pa 1976)* **36**:E1306–E1313, 2011
11. Illés T, Somoskeöy S: The EOS™ imaging system and its uses in daily orthopaedic practice. *Int Orthop* **36**:1325–1331, 2012
12. International Organization for Standardization: **ISO 5725-2: Accuracy (Trueness and Precision) of Measurement Methods and Results—Part 2: Basic Method for the Determination of Repeatability and Reproducibility of a Standard Measurement Method**. Geneva: International Organization for Standardization, 1994
13. Kotwicki T: Evaluation of scoliosis today: examination, x-rays and beyond. *Disabil Rehabil* **30**:742–751, 2008
14. Lam GC, Hill DL, Le LH, Raso JV, Lou EH: Vertebral rotation measurement: a summary and comparison of common radiographic and CT methods. *Scoliosis* **3**:16, 2008
15. Lenke LG, Betz RR, Harms J, Bridwell KH, Clements DH, Lowe TG, et al: Adolescent idiopathic scoliosis: a new classification to determine extent of spinal arthrodesis. *J Bone Joint Surg Am* **83**:1169–1181, 2001
16. Majdouline Y, Aubin CE, Robitaille M, Sarwark JF, Labelle H: Scoliosis correction objectives in adolescent idiopathic scoliosis. *J Pediatr Orthop* **27**:775–781, 2007
17. McAlinden C, Khadka J, Pesudovs K: Precision (repeatability and reproducibility) studies and sample-size calculation. *J Cataract Refract Surg* **41**:2598–2604, 2015
18. Melhem E, Assi A, El Rachkidi R, Ghanem I: EOS® biplanar x-ray imaging: concept, developments, benefits, and limitations. *J Child Orthop* **10**:1–14, 2016
19. Merolli A, Leali P, Aulisa L, Guidi P, Impagnatello M: A new method for clinical measurement of vertebral rotation, in Sevastik JS, Diab KM (eds): **Research Into Spinal Deformities 1. Studies in Health Technology and Informatics, Vol 37**. Amsterdam: IOS Press, 1997, pp 147–149
20. Perdriolle R, Vidal J: Thoracic idiopathic scoliosis curve evolution and prognosis. *Spine (Phila Pa 1976)* **10**:785–791, 1985
21. Stokes IA: Three-dimensional terminology of spinal deformity: a report presented to the Scoliosis Research Society by the Scoliosis Research Society Working Group on 3-D Terminology of Spinal Deformity. *Spine (Phila Pa 1976)* **19**:236–248, 1994
22. Stokes IA, Bigalow LC, Moreland MS: Measurement of axial rotation of vertebrae in scoliosis. *Spine (Phila Pa 1976)* **11**:213–218, 1986

23. Sullivan TB, Reighard FG, Osborn EJ, Parvaresh KC, Newton PO: Thoracic idiopathic scoliosis severity is highly correlated with 3D measures of thoracic kyphosis. **J Bone Joint Surg Am** **99**:e54, 2017
24. Thomets J, Liu X, Lyon R: Axial rotation in idiopathic scoliosis: a comparison of the Perdriolle, Scoliometer, Quantec Spinal Image System, in Stokes IAF (eds): **Research Into Spinal Deformities 2. Studies in Health Technology and Informatics, Vol 59**. Amsterdam: IOS Press, 1999, pp 329–331
25. Weiss H: Technical error of vertebral rotation measurements, in D'Amico M, Merolli A, Santambrogio GC (eds): **Three-Dimensional Analysis of Spinal Deformities. Studies in Health Technology and Informatics, Vol 15**. Amsterdam: IOS Press, 1995, pp 243–249
26. Yazici M, Acaroglu ER, Alanay A, Deviren V, Cila A, Surat A: Measurement of vertebral rotation in standing versus supine position in adolescent idiopathic scoliosis. **J Pediatr Orthop** **21**:252–256, 2001

---

## Disclosures

Dr. Skalli: coinventor of the EOS low-dose x-ray system.

## Author Contributions

Conception and design: Assi, Labaki, Massaad, Bakouny, M Karam. Acquisition of data: Assi, Labaki, Otayek, M Karam, Hanna, Kassab, Bizdikian, Mjaess, A Karam. Analysis and interpretation of data: Assi, Otayek. Drafting the article: Assi, Labaki, Otayek, M Karam. Critically revising the article: Assi, Massaad, Skalli, Ghanem. Reviewed submitted version of manuscript: Assi, Skalli, Ghanem. Approved the final version of the manuscript on behalf of all authors: Assi. Statistical analysis: Assi, Bakouny. Administrative/technical/material support: Assi. Study supervision: Assi.

## Correspondence

Ayman Assi: University of Saint-Joseph, Beirut, Lebanon. ayman.assi@gmail.com, ayman.assi@usj.edu.lb.