



HAL
open science

Clostridium ventriculi bacteremia following acute colonic pseudo-obstruction: A case report

Perrine Bortolotti, Eric Kipnis, Emmanuel Faure, Karine Faure, Agnès Wacrenier, Maud Fauquembergue, Sophian Messaadi, Laure Marceau, Rodrigue Dessenin, Rémi Le Guern

► To cite this version:

Perrine Bortolotti, Eric Kipnis, Emmanuel Faure, Karine Faure, Agnès Wacrenier, et al.. Clostridium ventriculi bacteremia following acute colonic pseudo-obstruction: A case report. *Anaerobe*, 2019, 59, pp.32-34. <10.1016/j.anaerobe.2019.05.005>. <hal-02566179>

HAL Id: hal-02566179

<https://hal.science/hal-02566179v1>

Submitted on 7 May 2020

HAL is a multi-disciplinary open access archive for the deposit and dissemination of scientific research documents, whether they are published or not. The documents may come from teaching and research institutions in France or abroad, or from public or private research centers.

L'archive ouverte pluridisciplinaire **HAL**, est destinée au dépôt et à la diffusion de documents scientifiques de niveau recherche, publiés ou non, émanant des établissements d'enseignement et de recherche français ou étrangers, des laboratoires publics ou privés.



HAL Authorization

1 ***Clostridium ventriculi* bacteremia following acute colonic pseudo-obstruction: a**
2 **case report.**

3 **Author's names & affiliations :**

4 **Perrine Bortolotti^{1,2}, Eric Kipnis^{1,2}, Emmanuel Faure^{1,3}, Karine Faure^{1,3}, Agnès**
5 **Wacrenier⁴, Maud Fauquembergue⁵, Malo Penven⁶, Laure Marceau⁶, Rodrigue**
6 **Dessein^{1,6}, Rémi Le Guern^{1,6}**

7 1 : Univ. Lille, EA 7366 - Recherche translationnelle: relations hôte pathogènes, F-59000
8 Lille, France

9 2 : CHU Lille, Service de Réanimation Chirurgicale, F-59000 Lille, France

10 3 : CHU Lille, Service de Maladies Infectieuses, F-59000 Lille France

11 4 : CHU Lille, Institut de Pathologie, F-59000 Lille France

12 5 : CHU Lille, Institut de Radiologie, F-59000 Lille France

13 6 : CHU Lille, Institut de Microbiologie, F-59000 Lille, France

14 **Corresponding Author:**

15 Dr. Rémi Le Guern, Univ. Lille, EA 7366 - Recherche translationnelle: relations hôte
16 pathogènes, F-59000 Lille, France; CHU Lille, Institut de Microbiologie, F-59000 Lille,
17 France; e-mail: remi.leguern@chru-lille.fr

18

19

20 **Abstract: (47 words)**

21 *Clostridium ventriculi* (formerly *Sarcina ventriculi*) is a Gram-positive, obligate anaerobic
22 coccus. Human infections due to this bacterium have rarely been reported, its
23 involvement in the development of gastric ulcers and perforation was suggested. We
24 present a case of bacteremia due to *C. ventriculi* following acute colonic pseudo-
25 obstruction.

26 **Keywords:**

27 *Clostridium ventriculi*, *Sarcina ventriculi*, bacteremia, Ogilvie syndrome

28

29 **Introduction**

30 Acute colonic pseudo-obstruction (Ogilvie syndrome) is characterized by massive
31 dilatation of the colon, without any mechanical obstruction. Cecal perforation is rare (1 –
32 3%), but leads to high mortality rates of 50% (1). Ogilvie syndrome often incurs after
33 trauma or surgical procedures, principally orthopedic procedures (2). Colonic or
34 intestinal obstruction can lead to bacterial translocation in mesenteric lymph nodes (3),
35 or in blood (4). Translocated bacteria often belongs to *Enterobacteriaceae* (5), but
36 anaerobes are also involved (6).

37 *Clostridium ventriculi* (formerly *Sarcina ventriculi*) is a Gram-positive, obligate anaerobic
38 coccus. *C. ventriculi* has been recovered from gastric biopsies, and may be linked to
39 gastric perforation, emphysematous gastritis and peritonitis (7). Bacteremia due *C.*
40 *ventriculi* was exceptionally reported (8).

41 We present a case of bacteremia caused by *C. ventriculi* in a patient with acute colonic
42 pseudo-obstruction following orthopedic surgery.

43 **Case report**

44 In February 2019, a 65-year-old man was admitted to the hospital after being hit
45 by a car on the public road. He had a past medical history of cardiac failure secondary to
46 atrial flutter in 2016 that required a dual chamber pacemaker implantation, bicuspid
47 aortic valve, non-insulin-dependent diabetes mellitus, supplemented hypothyroidism,
48 obstructive sleep apnea with no home ventilation therapy and spastic diplegia (Little's
49 disease) with preserved walking ability. Clinical and radiological examinations including
50 a whole-body CT scan with contrast, revealed multiple bone fractures involving left
51 ankle, right patella, right eye orbit, frontal and maxillary sinuses, right transverse process
52 of C1, and left posterior arches from C5 to C7 without any neurological deficit. Of note,
53 there was no clinical or radiological sign of thoracic or abdominal visceral injury. Cervical
54 fractures were orthopedically treated by immobilization with a rigid cervical collar.
55 Because the patient's medications included the anticoagulant agent rivaroxaban,
56 surgical treatment of the inferior limbs was postponed and an orthopedic immobilization
57 of the two legs was performed, involving strict bed rest. Finally, the patient was
58 transferred from the emergency department to a conventional surgery department.

59 Six days after hospitalization, the patient presented an acute widespread
60 abdominal pain, massive abdominal distention and intestinal obstruction symptoms
61 associated with fever. The abdomen and pelvis CT scan with contrast revealed a
62 severe, diffuse colonic distention with a cecal dilatation of 10cm. There was no evidence
63 of mechanical obstruction or underlying gastrointestinal pathology, suggesting the
64 diagnosis of acute colonic pseudo-obstruction. There was no radiological sign of
65 pneumoperitonitis, but the existence of a pericecal infiltration of the mesenteric fat

66 suggested the onset of an intestinal wall injury with a high risk of cecal rupture (Figure
67 1). Thus, the patient underwent abdominal surgery consisting of a laparotomic ileocecal
68 resection, abundant washing of the abdominal cavity and creation of a double-barreled
69 ileocolostomy. During the surgery, the patient developed hemodynamic instability
70 requiring fluid expansion, red blood cells transfusion and increasing dose of
71 norepinephrine that suggested an early sepsis. Two pairs of aerobic and anaerobic
72 blood cultures were drawn, and the patient received piperacillin-tazobactam and
73 gentamicin. He was then admitted to surgical ICU for postoperative care.

74 Fourteen hours after surgery, the patient developed fever associated with
75 persistent hemodynamic instability. Two pairs of aerobic and anaerobic blood cultures
76 were repeated during the temperature peaks, reaching 39.2°C. Biological markers of
77 infection were increased with a CRP 411mg/l, PCT 18µg/l, leukocytes 25000/mm³
78 including 23000/mm³ neutrophils. Antifungal therapy with parenteral fluconazole was
79 added.

80 After 45h of incubation in the BacT/ALERT Virtuo automated system (bioMérieux,
81 Marcy l'Etoile, France), one anaerobic blood culture sampled during the initial fever peak
82 was flagged as positive. Gram staining on the blood culture fluid exhibited large Gram-
83 positive cocci in tetrads (Figure 2). Positive blood culture bottle was plated onto blood
84 agar under aerobic conditions, and onto Meat-Yeast agar under anaerobic conditions.
85 Growth was only observed under anaerobic conditions after 48h of incubation.
86 Identification by matrix-assisted laser desorption ionization time of flight mass
87 spectrometry (MALDI-TOF MS; Bruker Daltonics, Wissembourg, France) was
88 unsuccessful, despite addition of formic acid. The closest match was *Staphylococcus*

89 *vitulinus*, with a low score of 1.22. Identification by 16S rDNA sequencing was
90 performed. A 464-bp DNA fragment was amplified using universal primers 341F and
91 785R (9). DNA sequence was analyzed with leBIBI SSU-rDNA-16S-TS-stringent
92 database (9) and with the NCBI database. There was 100% identity for 417-bp with *C.*
93 *ventriculi* (GenBank accession n° AF110272) (10).

94 *In vitro* antimicrobial susceptibility was determined as recommended by the CA-SFM
95 2019 (Comité de l'Antibiogramme de la Société Française de Microbiologie;
96 <http://www.sfm-microbiologie.org/>) guidelines. Our isolate of *C. ventriculi* was
97 susceptible to penicillin (MIC = 0.25 mg/L), amoxicillin (MIC = 0.50 mg/L), amoxicillin-
98 clavulanic acid, piperacillin-tazobactam, imipenem, clindamycin, levofloxacin, rifampicin,
99 vancomycin, metronidazole and linezolid. The positive blood culture with Gram-positive
100 cocci led the physicians to treat the patient with intravenous vancomycin, given the
101 clinical concern of a possible bacteremia with piperacillin-tazobactam-resistant bacteria
102 in the context of sepsis. This treatment was maintained for 5 days, until identification of
103 the bacteria was obtained.

104 The clinical evolution has been marked by a persistent fever for seven days without any
105 other positive microbial samples despite daily blood cultures. The patient presented a
106 persistent functional small bowel obstruction confirmed at CT scan imaging 3 days after
107 admission in the ICU. This intestinal obstruction was managed with prokinetic
108 medications and stomach aspiration through nasogastric tube, allowing the recovery of a
109 normal intestinal function after 7 days. Concomitantly, hemodynamic status
110 progressively improved with a complete weaning of the norepinephrine achieved 7 days
111 after surgery. He was weaned from mechanical ventilation 2 days after admission in ICU

112 without any oxygen requirement and no evidence for ventilator-associated pneumonia.
113 There was no other clinically identified source of infection. Anatomopathology of the
114 ileocecal specimen previously resected revealed large ulcerations of the cecal mucosa
115 filled with fibrin and leukocytes aggregates, compatible with infectious colitis.
116 Piperacillin-Tazobactam and fluconazole were administrated for a total of 10 days.
117 Biological parameters progressively decreased during ICU stay with CRP 89mg/l, PCT
118 1.2µg/l and PMN 4500/mm³ at discharge. The patient was finally discharged from the
119 ICU 8 days after admission to the abdominal surgery department.

120 Discussion

121 *C. ventriculi* was first identified by Goodsir in 1842 from a patient with abdominal pain
122 and suspicion of stomach ulcer (10). At the time, this microorganism was named *Sarcina*
123 *ventriculi*. In 1994, 16S rRNA gene sequences phylogenetic analyses showed that *S.*
124 *ventriculi* actually belongs to the genus *Clostridium* (11). Genus transfer from *S.*
125 *ventriculi* to *C. ventriculi* was finally proposed in 2016 (12). *C. ventriculi* are large
126 anaerobic Gram-positive cocci in clusters of tetrads (1.8 to 3 µm individual size) (8),
127 even bigger than other large anaerobic cocci like *Fingoldia magna* (0.8 to 1.6 µm) (13).

128 *C. ventriculi* has been recovered from gastric samples of patients suffering from
129 gastroparesis, gastric perforation, emphysematous gastritis and peritonitis (7). Despite
130 sharing the same gastric niche, co-isolation of *C. ventriculi* and *Helicobacter pylori* in the
131 same patient was only reported once (14). *C. ventriculi* can also colonize the human gut,
132 as it could be isolated from feces of healthy adults. *C. ventriculi* has been recovered
133 more frequently from adults on vegetarian diets (70.8%) than from adults on diets
134 containing animal products (1.6%) (15).

135 Bacteremia caused by *C. ventriculi* is exceptional, with two verified case reported in the
136 literature (8, 16). This first case described bacteremia due to *C. ventriculi* in a 48-year-
137 old female diagnosed with congenital chloride diarrhea, presenting a sudden onset of
138 vomiting and extensive watery diarrhea (8). The patient improved after 5 days of oral
139 amoxicillin. The second case concerned a 33-year-old woman with structural kidney
140 abnormalities presenting pyelonephritis and bacteremia caused by *Escherichia coli* and
141 *C. ventriculi* (16). The authors suggested that the source of the *C. ventriculi* bacteremia

142 could be either urogenital or gastrointestinal because the patient also presented
143 vomiting. The patient improved after 14 days of levofloxacin. It should be noted that *C.*
144 *ventriculi* bacteremia was also reported in 1872, but the significance of this report is
145 dubious: blood cultures were incubated for 2 months and *C. ventriculi* could easily be
146 mistaken with *Micrococcus*, which can contaminate blood cultures.

147 We described a case of bacteremia caused by *C. ventriculi* in a patient with acute
148 colonic pseudo-obstruction. *C. ventriculi* is an increasingly common anaerobic bacteria
149 isolated from patients with gastrointestinal symptoms. *C. ventriculi* typical morphological
150 features on Gram stain helps to the identification, but this should be confirmed by
151 molecular methods. In our particular case, only one blood sample was positive for *C.*
152 *ventriculi*. However, the recent medical history of pre-perforated colonic pseudo-
153 obstruction together with the anatomopathological findings suggest an intestinal origin
154 for the sepsis that probably involves *C. ventriculi*, classically found in the gastrointestinal
155 tract, without any other bacterial agent identified. Our patient showed multiple risk
156 factors for Ogilvie syndrome, including recent trauma, bed confinement, and opioid-
157 based analgesia with tramadol, that could have favored the onset of the infectious
158 colitis. However, the exact role of *C. ventriculi* in the pathophysiology of the disease
159 remains unknown.

160 **Conflict of Interest**

161 No conflict of interest

162 **Funding Statement**

163 Univ. Lille, CHU Lille.

164 **Acknowledgments**

165 We thank Antonino Bongiovanni of the BICeL Facility for access to systems and
166 technical advice. We thank Sophian Messaadi and Teddy Grandjean for technical help.

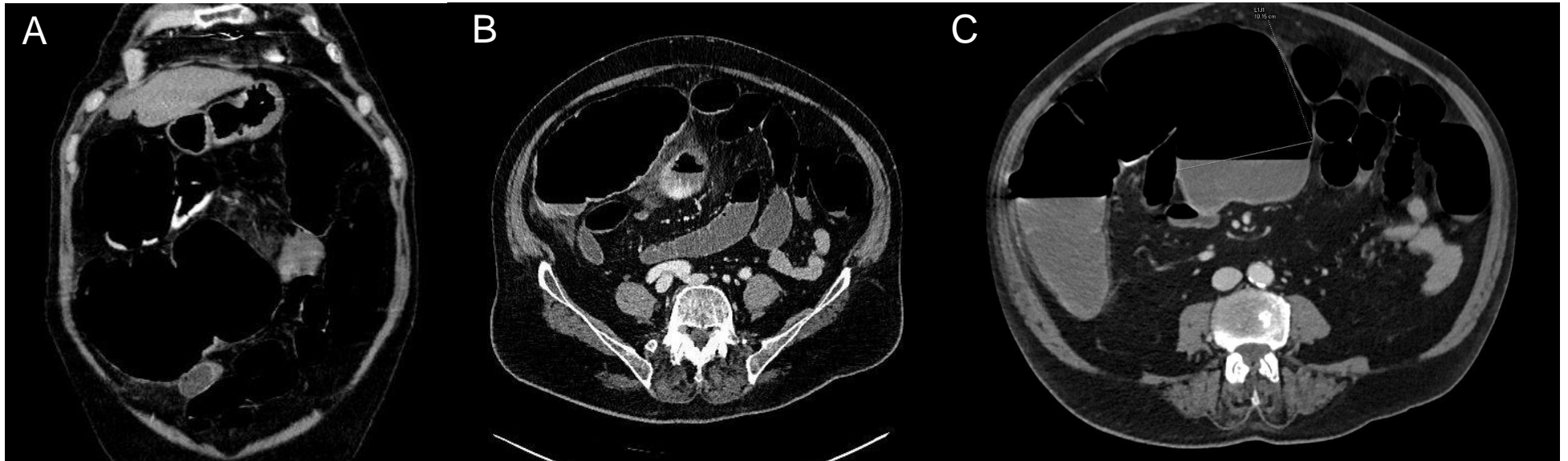
167 **Word count:** 1465 words

168 **References:**

- 169 1. Bode WE, Beart RW, Jr., Spencer RJ, Culp CE, Wolff BG, Taylor BM. 1984.
170 Colonoscopic decompression for acute pseudoobstruction of the colon (Ogilvie's
171 syndrome). Report of 22 cases and review of the literature. *Am J Surg* 147:243-5.
- 172 2. Tenofsky PL, Beamer L, Smith RS. 2000. Ogilvie syndrome as a postoperative
173 complication. *Arch Surg* 135:682-6; discussion 686-7.
- 174 3. Deitch EA. 1989. Simple intestinal obstruction causes bacterial translocation in
175 man. *Arch Surg* 124:699-701.
- 176 4. Merrett ND, Jorgenson J, Schwartz P, Hunt DR. 1994. Bacteremia associated
177 with operative decompression of a small bowel obstruction. *J Am Coll Surg*
178 179:33-7.
- 179 5. Hegde S, Lin YM, Golovko G, Khanipov K, Cong Y, Savidge T, Fofanov Y, Shi
180 XZ. 2018. Microbiota dysbiosis and its pathophysiological significance in bowel
181 obstruction. *Sci Rep* 8:13044.
- 182 6. O'Boyle CJ, MacFie J, Mitchell CJ, Johnstone D, Sagar PM, Sedman PC. 1998.
183 Microbiology of bacterial translocation in humans. *Gut* 42:29-35.
- 184 7. Al Rasheed MR, Senseng CG. 2016. *Sarcina ventriculi* : Review of the Literature.
185 *Arch Pathol Lab Med* 140:1441-1445.
- 186 8. Tuuminen T, Suomala P, Vuorinen S. 2013. *Sarcina ventriculi* in blood: the first
187 documented report since 1872. *BMC Infect Dis* 13:169.
- 188 9. Klindworth A, Pruesse E, Schweer T, Peplies J, Quast C, Horn M, Glockner FO.
189 2013. Evaluation of general 16S ribosomal RNA gene PCR primers for classical

- 190 and next-generation sequencing-based diversity studies. *Nucleic Acids Res*
191 41:e1.
- 192 10. Goodsir J, Wilson G. 1842. History of a Case in Which a Fluid Periodically
193 Ejected from the Stomach Contained Vegetable Organisms of an Undescribed
194 Form. *Edinb Med Surg J* 57:430-443.
- 195 11. Willems A, Collins MD. 1994. Phylogenetic placement of *Sarcina ventriculi* and
196 *Sarcina maxima* within group I Clostridium, a possible problem for future revision
197 of the genus Clostridium. Request for an opinion. *Int J Syst Bacteriol* 44:591-3.
- 198 12. Lawson PA, Rainey FA. 2016. Proposal to restrict the genus Clostridium
199 Prazmowski to Clostridium butyricum and related species. *Int J Syst Evol*
200 *Microbiol* 66:1009-1016.
- 201 13. Murphy EC, Frick IM. 2013. Gram-positive anaerobic cocci--commensals and
202 opportunistic pathogens. *FEMS Microbiol Rev* 37:520-53.
- 203 14. Sauter JL, Nayar SK, Anders PD, D'Amico M, Butnor KJ, Wilcox RL. 2013. Co-
204 existence of *Sarcina* Organisms and *Helicobacter pylori* Gastritis/Duodenitis in
205 Pediatric Siblings. *J Clin Anat Pathol (JCAP)* 1.
- 206 15. Crowther JS. 1971. *Sarcina ventriculi* in human faeces. *J Med Microbiol* 4:343-50.
- 207 16. Elvert JL, El Atrouni W, Schuetz AN. 2018. Photo Quiz: A Bacterium Better
208 Known by Surgical Pathologists than by Clinical Microbiologists. *J Clin Microbiol*
209 56.

210

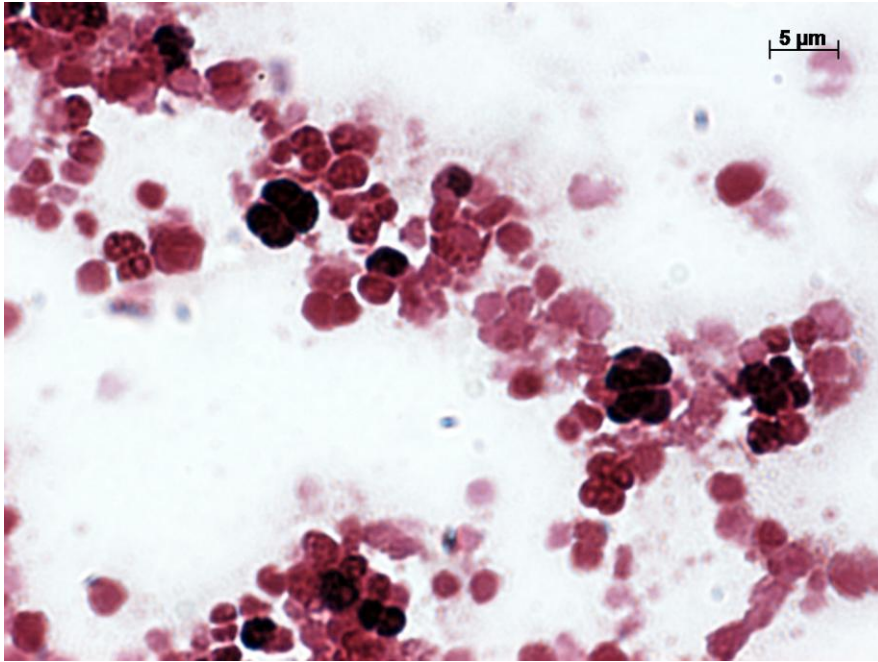


211

212 **Figure 1. Abdomen and pelvis CT scan images.**

213 A. Coronal view showing diffuse colonic and gastric distention. B and C. Axial views showing cecal distention and pericecal
214 mesenteric fat infiltration but no sign of pneumoperitonitis.

215



216

217 **Figure 2. Gram stain of *Clostridium ventriculi*.**

218 Gram stain from colonies on Meat-Yeast agar, image taken at magnification 1000x.

219 Presence of large Gram-positive cocci in clusters of tetrads (1.8 to 3 μm individual size).

220