



HAL
open science

Evaluation of the efficacy of a self-training programme in focus cardiac ultrasound with simulator

Anne Bernard, Pascale Chemaly, Fanny Dion, Said Laribi, Francis Remerand,
Denis Angoulvant, Fabrice Ivanès

► **To cite this version:**

Anne Bernard, Pascale Chemaly, Fanny Dion, Said Laribi, Francis Remerand, et al.. Evaluation of the efficacy of a self-training programme in focus cardiac ultrasound with simulator. Archives of cardiovascular diseases, 2019, 112 (10), pp.576-584. 10.1016/j.acvd.2019.06.001 . hal-02547835

HAL Id: hal-02547835

<https://hal.science/hal-02547835>

Submitted on 20 Jul 2022

HAL is a multi-disciplinary open access archive for the deposit and dissemination of scientific research documents, whether they are published or not. The documents may come from teaching and research institutions in France or abroad, or from public or private research centers.

L'archive ouverte pluridisciplinaire **HAL**, est destinée au dépôt et à la diffusion de documents scientifiques de niveau recherche, publiés ou non, émanant des établissements d'enseignement et de recherche français ou étrangers, des laboratoires publics ou privés.



Distributed under a Creative Commons Attribution - NonCommercial 4.0 International License

Evaluation of the efficacy of a self-training programme in focus cardiac ultrasound with simulator

Abbreviated title: Evaluation of self-training programme in focus cardiac ultrasound

Anne Bernard^{a,b,c,*}, Pascale Chemaly^a, Fanny Dion^a, Said Laribi^{c,d}, Francis Remerand^e, Denis Angoulvant^{a,b,c}, Fabrice Ivanes^{a,b,c}

^a *Service de Cardiologie, CHRU de Tours, 37044 Tours, France*

^b *EA4245, Loire Valley Cardiovascular Collaboration, Université de Tours, 37000 Tours, France*

^c *Centre Régional d'Enseignement par la Simulation en Santé, Faculté de Médecine, Université de Tours, 37032 Tours, France*

^d *Faculté de Médecine, Université de Tours, 37032 Tours; et Département de Médecine d'Urgence, CHRU de Tours, 37044 Tours, France*

^e *Inserm U1253, Université de Tours, 37032 Tours; and Service d'Anesthésie Réanimation 2, CHRU de Tours, 37044 Tours, France*

* Corresponding author at: Service de Cardiologie, Hôpital Trousseau, CHRU de Tours, 37044 Tours CEDEX 9, France.

E-mail address: anne.bernard@univ-tours.fr (A. Bernard).

Summary

Background. – Focus cardiac ultrasound is a great tool for quick evaluation of cardiac function in acute settings with limited time and expertise in echocardiography. Adequate training is essential for physicians willing to use this imaging technique.

Aim. – The goal of this study was to assess the efficacy of a self-training programme using a cardiac ultrasound simulator.

Methods. – Thirty-five trainees in cardiology, emergency medicine or anaesthesiology entered the programme, which started with an e-learning lecture on focus cardiac ultrasound, with practice on a simulator, followed by implementation on patients, and ended with self-training in image analysis on an online platform. A post-test evaluation was carried out at the end of the theoretical training, followed by a final live evaluation on patients (timed acquisition of the five reference views used in focus cardiac ultrasound, grading each view on a scale of 1 to 5). Trainees were also evaluated online regarding their interpretation of 20 video clips.

Results. – The median (interquartile range) interpretability scores following simulator training were 5 (4–5) for the parasternal long-axis view, 5 (4–5) for the apical four-chamber view, and 4 (4–5) for the subcostal window. Interpretability was significantly inferior in the live evaluation compared with the post-test evaluation, except for the parasternal long-axis and subcostal views. The mean score for the video clips (out of 20) was 14.5 ± 2.4 .

Conclusions. – After a short self-training programme, trainees were able to acquire the main views of focus cardiac ultrasound with sufficient quality and in a short time period.

Résumé

Contexte. – L'échoscopie cardiaque permet une évaluation rapide de la fonction cardiaque en situation d'urgence. La formation pratique des médecins utilisant cette technique d'imagerie est primordiale.

Objectif. – L'objectif de cette étude était d'évaluer l'efficacité d'un programme d'auto-formation avec mannequin de simulation en échoscopie cardiaque.

Méthodes. – 35 apprenants en cardiologie, médecine d'urgence et anesthésie-réanimation ont participé à ce programme. Il comprenait une partie théorique (enseignement en e-learning et manipulation sur mannequin de simulation), puis une partie pratique en situation réelle sur patient,

puis un entraînement à l'analyse d'images échographiques sur une plate-forme en ligne. Un post-test était réalisé à la fin de la formation théorique, une évaluation sur patient était réalisée à la fin de la formation pratique (acquisition chronométrée des 5 coupes de référence en échoscopie cardiaque, chaque coupe étant évaluée de 1 à 5/5, la 3^{ème} phase était suivie d'une évaluation sur 20 questions.

Résultats. – Les notes d'interprétabilité des coupes après la formation sur mannequin étaient satisfaisantes avec une médiane de 5 (4–5) pour la vue parasternale long axe, 5 (4–5) pour la vue apicale 4 cavités et 4 (4–5) pour la vue sous-costale. L'interprétabilité des coupes était significativement inférieure lors de l'évaluation sur patient par rapport au post-test sauf pour les vues parasternale long axe et sous costale. La moyenne du test d'interprétation était de $14,5 \pm 2,4/20$.

Conclusions. – Une auto-formation de courte durée permet aux étudiants de réaliser les principales coupes d'échoscopie cardiaque, de bonne qualité, et rapidement.

KEYWORDS

Focus cardiac ultrasound;

Ultrasound;

Simulation;

e-Learning

MOTS CLÉS

échoscopie cardiaque ;

Ultrasons ;

Simulation ;

e-Learning

Abbreviations: A2CH, apical two-chamber view; A4CH, apical four-chamber view; FoCUS, focus cardiac ultrasound; PLAX, parasternal long-axis view; PSAX, parasternal short-axis view; S4CH, subcostal four-chamber view; TTE, transthoracic echocardiography.

Background

Focus cardiac ultrasound (FoCUS) is an ultrasound imaging technique that is generally used at a patient's bedside in an emergency setting. Both cardiologists and non-cardiologists (e.g. anaesthesiologists, emergency physicians and intensive care physicians) use it daily in clinical practice as a complement to clinical examination. An ultrasound examination carried out at the patient's bedside may be extremely useful when dealing with haemodynamically unstable patients.

The FoCUS examination must be distinguished from regular transthoracic echocardiography (TTE). Even in an emergency setting, TTE refers to a complete echocardiographic examination of cardiac morphology and function, carried out with a fully equipped machine by a certified professional trained to perform this test and interpret its results. The term FoCUS refers to an ultrasonic examination performed at the patient's bedside using a restricted scan protocol. The operator is generally a physician who must make a timely therapeutic decision but needs additional information beforehand; they do not necessarily have to be trained in echocardiography, only in FoCUS [1-3].

Previous training in FoCUS is mandatory for its use in daily practice, as it is necessary to understand the purpose and limits of this examination. The need for training is all the more important given that several specialties are interested in this technique [4]. To date there is no official FoCUS training programme. In line with the recent publication by the European Cardiovascular Imagery Association (EACVI) of a core curriculum for FoCUS, we postulated that a course of procedural simulation combined with appropriate theoretical knowledge could be of great value in FoCUS training, by giving the trainee experience on a simulator before live-patient practice [5, 6].

We set up a FoCUS training programme intended for novice residents specializing in cardiology, anaesthesiology or emergency medicine. The aim of our study was to evaluate the efficacy of this FoCUS self-training programme. The objectives of the programme were to acquire, first on a simulator, then on a patient, the theoretical and practical skills needed to produce the five reference views of the FoCUS examination, and to analyse video clips of typical emergent situations.

Methods

Study population

The group of trainees included first-month residents in cardiology and residents and assistant doctors in anaesthesiology and emergency medicine at a university hospital; all were novices in FoCUS or

echocardiography. Three experts in advanced TTE (with the highest degree of French certification in echocardiography) constituted a reference group; they all carried out FoCUS or TTE examinations in their daily clinical practice and had each performed more than 1000 examinations. All the participants were volunteers who had been briefed on the study.

Training content

This FoCUS self-training programme involved three stages (Fig. 1). The first phase lasted for 1 day. A short briefing introduced the principle of FoCUS, and the goals and content of the training; this was followed by an explanation of how the simulator works (Table A.1) and how the evaluation procedure was to be carried out. The trainees were split into groups of two or three, with free access to the online course on FoCUS and to a HeartWorks® TTE simulator (MedaPhor, Cardiff, UK) (Fig. 2). Both devices were in the same room. The simulator enabled a real-time three-dimensional reconstitution of the heart anatomy; this allowed good correlation of the position of the sectional view and the probe with respect to the heart structures. The trainees could follow the e-lectures at their own pace, and simultaneously practice on the simulation manikin. An expert echocardiographer was always available in case of technical difficulties and/or questions.

The second phase consisted of a half-day immersion in the echocardiography laboratory, up to a month after the simulator training. Each trainee practiced FoCUS on at least 10 consecutive patients scheduled for a TTE (after the patient's oral consent was obtained).

The third phase consisted of self-training in image analysis on an online platform. Trainees were asked to watch 100 video clips of various normal or pathological clinical cases, each displayed with a short comment.

e-Learning

The e-learning tools used in this self-training programme were available on the French national SIDES (Système Informatique Distribué d'Evaluation en Santé – Distributed Data Processing System for Health Evaluation) network, within the framework of the residents' training in cardiology and echocardiography. Three modules were used for a total teaching time of 75 minutes. These modules were online courses, including images and videos. Module 1 explained the bases of the sonographic scanning technique. Module 2 detailed the FoCUS five reference views [7] and the cardiac structures

visualized, and defined the quality criteria for each view: parasternal long-axis (PLAX) view, parasternal short-axis (PSAX) view, apical four-chamber (A4CH) view, apical two-chamber (A2CH) view and subcostal four-chamber (S4CH) view. Module 3 dealt with the qualitative and semiquantitative interpretation of images.

Evaluation of the trainees

The trainees were appraised with a pretest evaluation before starting the training, a post-test evaluation at the end of the self-training day with the simulator and a final evaluation with a patient at the end of the practical live training. The tests were identical at each stage, consisting of timed acquisition of a three-cardiac cycles loop of the five FoCUS reference views. The loops were graded according to four criteria: quality of the view; visualization of the structures; image stability; and interpretability (Table 1). The lowest grade was rated at 1 out of 5. A grade of 0 out of 5 was attributed only during the pretest evaluation, if the trainee was unable to obtain the required view. The final evaluation was performed in the echocardiography laboratory on a patient. The expert echocardiographer in charge of the training first checked the patient's echogenicity, to ensure that the five reference views could be acquired with no unexpected technical difficulty. The score was established by two independent examiners certified in advanced TTE, blinded to each other. The last part of the evaluation programme was an online evaluation consisting of 20 multiple choice questions regarding the interpretation of 20 video clips. The settings of the video clips included normal left and right ventricles, left or right ventricular moderate or severe dilation, left or right ventricular moderate or severe systolic dysfunction and pericardial effusion.

Expert group

The experts performed the same test on real patients (i.e. timed acquisition of the five FoCUS views). The scoring system was identical.

Statistical analysis

The statistical analysis was performed on Microsoft Excel® (Microsoft Corp., Redmond, WA, USA) and GraphPad Prism® (GraphPad Software, Inc., San Diego, CA, USA). Continuous non-normally distributed data are reported as medians (interquartile ranges). A Wilcoxon test was used to compare

the time necessary to acquire the views and the mean scores for each reference view, after both simulator training and live-session training. If the trainee failed to acquire a view, it was not scored and the time was not counted. However, if the trainee presented a view other than the one required, or if the view was abnormal, the time was counted and the view was scored using the usual criteria. A *P* value < 0.05 was considered significant.

Results

Study population

Forty-seven students followed the programme between September 2016 and February 2018. Twelve were excluded from the final study because they did not complete the programme, mainly as a result of schedule issues in their respective clinical departments. Eventually 35 participants completed the first two phases of the training: 11 residents in cardiology; 12 residents/fellows in emergency medicine; and 12 residents in anaesthesiology (Fig. 3).

All of the cardiology trainees followed the programme during the first month of their first year of residency. Ten of the anaesthesiology trainees were in their first year of residency, and the other two were in their second year and fourth year, respectively. The emergency medicine trainees were all at least at the end of their first year of residency; five of them were fellows, but all were new to FoCUS.

Image quality

The interpretability scores obtained during the pretest were 2 (1–3) for the PLAX view, 1 (0–2) for the PSAX view, 2 (1–3) for the A4CH view, 1 (0–2) for the A2CH view and 1 (0–2) for the S4CH view. The results of the post-test and final evaluations regarding view quality, structural visualization, image stability and overall interpretability of the five reference views are detailed in Table 2. All of the post-test and final evaluation scores were significantly higher than the pretest evaluation scores. The post-test and final evaluation scores were not significantly different for the PLAX and S4CH views, while the final evaluation scores were significantly lower for the PSAX, A4CH and A2CH views (Fig. 4). An example is provided in Fig. 5. The experts obtained the maximum score (i.e. 5 out of 5) for all four criteria for the five reference views.

Time required to obtain the five reference views

During the post-test evaluation on the simulator, the trainees took significantly less time to obtain the five views than during the final live evaluation. For the PLAX view, the median acquisition time was 25 (15–35) seconds during the post-test evaluation, as opposed to 45 (30–58) seconds during the final evaluation ($P < 0.0001$). Times for the PSAX view were 20 (13–32) seconds and 31 (20–48) seconds, respectively ($P = 0.01$). For the A4CH view, acquisition times were 32 (17–49) seconds and 70 (43–108) seconds, respectively ($P < 0.0001$). For the A2CH view, acquisition times were 21 (12–37) seconds and 57 (25–102) seconds, respectively ($P < 0.0001$). For the S4CH view, acquisition times were 27 (19–41) seconds and 40 (22–75) seconds, respectively ($P = 0.04$) (Fig. 6). The experts obtained the PLAX view in 7 (5–8) seconds ($P = 0.03$ versus the trainees), the PSAX view in 6 (4–8) seconds ($P = 0.17$ versus the trainees), the A4CH view in 10 (7–10) seconds ($P = 0.02$ versus the trainees), the A2CH view in 4 (2–4) seconds ($P = 0.03$ versus the trainees) and the S4CH view in 5 (3–11) seconds ($P = 0.03$ versus the trainees).

For the post-test evaluation on the simulator, the PLAX view was obtained in < 90 seconds by 28 trainees, the PSAX view by 33 trainees, the A4CH view by 32 trainees, the A2CH view by 27 trainees and the S4CH view by 28 trainees. For the final evaluation, the PLAX view was obtained in < 90 sec by 25 trainees, the PSAX view by 27 trainees, the A4CH view by 19 trainees, the A2CH view by 16 trainees and the S4CH view by 24 trainees.

Interpretation of clinical cases

Only 25 trainees completed the online evaluation, despite several reminders; the mean score (out of 20) was 14.5 ± 2.4 . No difference was observed between specialties.

Discussion

This study showed that our training programme combining self-learning simulation and then real-patient practice quickly led a population of young practitioners – novices in echocardiography – to the acquisition of adequate skills for the rapid procurement of the cross-sections required with FoCUS.

This is a pioneer programme in training physicians from several specialties (i.e. cardiology, emergency medicine and anaesthesiology), in that it uses the added value of simulation. Although the simulator interface needed to be explained adequately to the trainees, with an expert sonographer available to answer any questions, they mastered the simulator very quickly, which made self-training

in small groups feasible. We also demonstrated that, at the end of the training programme, they were able to interpret an image in most cases.

Practical skills

It is essential to acquire high-quality ultrasound reference views to be able to interpret them as precisely and reliably as possible. In a study by Biais et al. that compared cardiac images procured by an experienced sonographer using a pocket-size imaging device with images obtained by conventional echocardiography, the device demonstrated sufficient image quality to diagnose an alteration in left ventricular systolic function, a severe dilation of the right ventricle, a pericardial effusion or dilation of the inferior vena cava dilation [8].

In FoCUS, the A4CH and S4CH views are the most informative. The scores obtained for these two views were very good after simulator training and were equivalent to the live-patient scores for the S4CH view. The latter is very useful in cases of cardiocirculatory arrest or suspected tamponade. The notion of acquisition time for the views was important in this training. FoCUS can be an extension of a clinical examination or a diagnostic tool in emergency situations. It is therefore necessary to learn how to get informative views rapidly. Two studies analysing training programmes in cardiac ultrasound technique included in their success criteria the acquisition of a view in < 90 seconds [9, 10]; this objective was reached in our study, both on the simulator and in real patients.

Very few publications have reported on and evaluated programmes – for the most part in Northern Europe and the USA. Heiberg et al. [11] proposed a programme consisting of an e-learning segment followed by practice in obtaining views with cardiac ultrasound on models. The authors showed that, after a brief 12 hours of training, trainees were able to acquire at least one interpretable cardiac ultrasound view. Fredericksen et al. [9] showed that novices in sonography obtained 86% interpretable images after only 2 hours of theoretical teaching and practice on two healthy volunteers.

The recent publication of a core curriculum for the FoCUS examination by the European Society of Cardiovascular Imaging (endorsed by the Acute Cardiovascular Care Association [ACCA] of the European Society of Cardiology, the European Association of Cardiothoracic Anaesthesiology [EACTA], the European Society of Anaesthesiology [ESA], and the World Interactive Network Focused On Critical Ultrasound [WINFOCUS] [12]) [13] has set forth the principles of this examination, constituting a theoretical guide for teaching and training. Our practical and effective programme thus

provides a practical response to the need for training in the cardiac ultrasound technique, and could be used in any centre equipped with an echocardiographic simulator.

Gain achieved with simulation

The inclusion of simulation tools in cardiac ultrasound training programmes was proposed only recently [5]. Until now the simulation manikins were mainly used in transoesophageal echocardiography training. Simulation helps the trainee to develop his clinical skills independently (using basic knowledge), despite the shortage of time available for training. In our study, simulation was a means of putting the newly acquired knowledge immediately into practice, as the training combined theory and practice simultaneously. This experiential learning also furthers the acquisition of skills, without immediately compromising a trainee having difficulty at bedside; that was, in fact, their first comment after the training day with the simulator – they felt secure and confident. Skinner et al. [14] looked into the possibility of cardiac ultrasound training using only a simulator, by setting up a course with direct feedback and no teacher interaction. The authors showed that this was efficient in teaching the psychomotor and cognitive skills needed for the practice of cardiac ultrasound.

Before actually undertaking a course through simulation, it seems imperative to tackle two questions, starting with the scientific validity of manikins. In other words, are we certain that an expert does better than a novice with a simulation manikin? Bick et al. [15] showed that a transoesophageal echocardiographic simulator easily distinguishes novices from experts. Greenstein et al. also demonstrated that operators trained in cardiac ultrasound attained the same level of diagnostic conclusions as experts in echocardiography when they were tested on simulation manikins mimicking cardiocirculatory arrest [16]. The second question is how well knowledge acquired in simulation carries over into real-life situations. In a meta-analysis from Sidhu et al., the authors sought to discover whether teaching ultrasound techniques through simulation for diagnosis or certain interventional procedures enhanced the ability to carry out these examinations in real-life situations [17]. Among the 14 studies that matched the study criteria, there was no formal proof of any improvement in the practical clinical abilities of trainees taught through simulation. Unlike ours, however, few other studies proposed training that combined teaching through both simulation and real-life practice. A first phase with a simulator would give trainees confidence and speed the development of their skills, but it is also necessary to provide supervised real-life training.

Study limitations

We chose to perform the final evaluation on patients scheduled for an examination in the echocardiography laboratory, rather than on standardized patients or healthy subjects. This would certainly have improved the trainees' performance at the final evaluation. Nonetheless, as FoCUS is a bedside technique often performed in difficult circumstances, this evaluation came closer to real-life conditions than if it had been performed on healthy subjects.

Only 25 of the 47 trainees (53%) underwent the full training (i.e. completed the clinical case online evaluation). This suggests either switching this evaluation to a classroom session or rendering it mandatory for validation of the FoCUS training.

The idea of looking into the possibility of very early training in the emergency cardiac ultrasound technique through simulation for all medical trainees, even before the choice of a specialty, also needs to be considered [18]. Another limitation may be the short delay between the training and the final evaluation. One may hypothesize that the trainee's performance may be reduced after a while if they do not have the opportunity to keep practising FoCUS and/or regular TTE. Repeated evaluations with groups subjected to repeated training are warranted.

Conclusions

Our short course combining e-learning, training on a simulation manikin, practice on real patients and image analysis successfully taught trainees drawn from cardiology, anaesthesiology and emergency medicine to quickly acquire the main high-quality cross-sectional views of the FoCUS examination that are relevant to emergency situations. This short training at the beginning of residency would allow them to benefit throughout their curriculum from the knowledge and skills acquired, and thus to stand on their own in clinical practice.

Sources of funding

This research did not receive any specific grant from funding agencies in the public, commercial or not-for-profit sectors.

Disclosure of interest

The authors declare that they have no conflicts of interest concerning this article.

References

- [1] Labovitz AJ, Noble VE, Bierig M, et al. Focused cardiac ultrasound in the emergent setting: a consensus statement of the American Society of Echocardiography and American College of Emergency Physicians. *J Am Soc Echocardiogr* 2010;23:1225-30.
- [2] Neskovic AN, Edvardsen T, Galderisi M, et al. Focus cardiac ultrasound: the European Association of Cardiovascular Imaging viewpoint. *Eur Heart J Cardiovasc Imaging* 2014;15:956-60.
- [3] Spencer KT, Kimura BJ, Korcarz CE, Pellikka PA, Rahko PS, Siegel RJ. Focused cardiac ultrasound: recommendations from the American Society of Echocardiography. *J Am Soc Echocardiogr* 2013;26:567-81.
- [4] Duchenne J, Martinez M, Rothmann C, et al. Premier niveau de compétence pour l'échographie clinique en médecine d'urgence. Recommandations de la Société française de médecine d'urgence par consensus formalisé. *Ann Fr Med Urgence* 2016;6:284-95.
- [5] Amini R, Stolz LA, Javedani PP, et al. Point-of-care echocardiography in simulation-based education and assessment. *Adv Med Educ Pract* 2016;7:325-8.
- [6] Haute Autorité de Santé. Rapport de mission. Etat de l'art en matière de pratiques de simulation dans le domaine de la santé. 2012. Available at: https://www.has-sante.fr/portail/upload/docs/application/pdf/2012-01/simulation_en_sante_-_rapport.pdf.
- [7] Via G, Hussain A, Wells M, et al. International evidence-based recommendations for focused cardiac ultrasound. *J Am Soc Echocardiogr* 2014;27:683 e1- e33.
- [8] Biais M, Carrie C, Delaunay F, Morel N, Revel P, Janvier G. Evaluation of a new pocket echoscopic device for focused cardiac ultrasonography in an emergency setting. *Crit Care* 2012;16:R82.
- [9] Frederiksen CA, Juhl-Olsen P, Nielsen DG, Eika B, Sloth E. Limited intervention improves technical skill in focus assessed transthoracic echocardiography among novice examiners. *BMC Med Educ* 2012;12:65.
- [10] Neelankavil J, Howard-Quijano K, Hsieh TC, et al. Transthoracic echocardiography simulation is an efficient method to train anesthesiologists in basic transthoracic echocardiography skills. *Anesth Analg* 2012;115:1042-51.

- [11] Heiberg J, Hansen LS, Wemmelund K, et al. Point-of-Care Clinical Ultrasound for Medical Students. *Ultrasound Int Open* 2015;1:E58-66.
- [12] Price S, Via G, Sloth E, et al. Echocardiography practice, training and accreditation in the intensive care: document for the World Interactive Network Focused on Critical Ultrasound (WINFOCUS). *Cardiovasc Ultrasound* 2008;6:49.
- [13] Neskovic AN, Skinner H, Price S, et al. Focus cardiac ultrasound core curriculum and core syllabus of the European Association of Cardiovascular Imaging. *Eur Heart J Cardiovasc Imaging* 2018;19:475-81.
- [14] Skinner AA, Freeman RV, Sheehan FH. Quantitative Feedback Facilitates Acquisition of Skills in Focused Cardiac Ultrasound. *Simul Healthc* 2016;11:134-8.
- [15] Bick JS, Demaria S, Jr., Kennedy JD, et al. Comparison of expert and novice performance of a simulated transesophageal echocardiography examination. *Simul Healthc* 2013;8:329-34.
- [16] Greenstein YY, Martin TJ, Rolnitzky L, Felner K, Kaufman B. Goal-Directed Transthoracic Echocardiography During Advanced Cardiac Life Support: A Pilot Study Using Simulation to Assess Ability. *Simul Healthc* 2015;10:193-9; quiz 9-201.
- [17] Sidhu HS, Olubaniyi BO, Bhatnagar G, Shuen V, Dubbins P. Role of simulation-based education in ultrasound practice training. *J Ultrasound Med* 2012;31:785-91.
- [18] Gosai J, Purva M, Gunn J. Simulation in cardiology: state of the art. *Eur Heart J* 2015;36:777-83.

Figure legends

Figure 1. Training content.

Figure 2. Demonstration of the obtention of a parasternal long-axis view on the simulator.

Figure 3. Study population flow chart.

Figure 4. Comparison of the interpretability of the five reference views on pretest (PRE), post-test (POST) and final (EVAL) evaluations. A4CH: apical four-chamber view; A2CH: apical two-chamber view; PLAX: parasternal long-axis view; PSAX: parasternal short-axis view; S4CH: subcostal four-chamber view. * $P < 0.05$ versus pretest evaluation; † $P < 0.05$ versus post-test evaluation.

Figure 5. Example of apical four-chamber view images acquired by a trainee on pretest evaluation, post-test evaluation (on mannikin) and final evaluation (EVAL; on real patient).

Figure 6. Comparison of acquisition times for the five reference views on pretest (PRE), post-test (POST) and final (EVAL) evaluations. A4CH: apical four-chamber view; A2CH: apical two-chamber view; PLAX: parasternal long-axis view; PSAX: parasternal short-axis view; S4CH: subcostal four-chamber view. * $P < 0.05$ versus pretest evaluation; † $P < 0.05$ versus post-test evaluation.

Table 1 Detailed description of the different aspects of image analysis and scoring.

Quality of the view ^a	PLAX: interventricular septum as horizontal as possible; MV centred; Valsalva sinus of maximum diameter	PSAX: LV as circular as possible; MV not visualized; RV infundibulum visualized	A4CH: longest possible LV; symmetrical left and right atria; aorta not visualized	A2CH: longest possible LV; no visible wall structure in the ventricular cavity; aorta not visualized	S4CH: longest possible LV; symmetrical atria; aorta not visualized
Visualization of the structures ^a	PLAX: aorta and aortic valve, LV, MV and left auricle, RV	PSAX: overall view of the LV myocardium, anterior wall and RV infundibulum; both mitral papillaries visualized	A4CH: LV, RV, both atria, TV and MV	A2CH: lower left wall of the LV, anterior wall, left auricle, MV	S4CH: LV, RV, both atria, TV and MV
Image stability ^b	1: no image acquired	2: stable on less than one cardiac cycle	3: stable over one cardiac cycle	4: stable over two cardiac cycles	5: stable over three cardiac cycles, and proper probe handling
Interpretability ^b	1: no interpretation possible	2: interpretation uncertain	3: interpretation doubtful	4: interpretation possible	5: interpretation possible and reliable

A4CH: apical four-chamber; A2CH: apical two-chamber view; LV: left ventricle; MV: mitral valve; PLAX: parasternal long-axis view; PSAX: parasternal short-axis view; RV: right ventricle; S4CH: subcostal four-chamber view; TV: tricuspid valve.

^a The highest score was 5 points, with 1 point taken off for each item lacking; the lowest score was 1 point.

^b The highest score was 5 points.

Table 2 Detailed results for quality of the views acquired.

	Quality of the view		Visualization of the structures		Image stability		Interpretability	
	Post-test evaluation	Final evaluation	Post-test evaluation	Final evaluation	Post-test evaluation	Final evaluation	Post-test evaluation	Final evaluation
PLAX	4 (4–5) ^a	4 (4–5) ^a	5 (4–5) ^a	4 (4–5) ^a	4 (3–5) ^a	4 (3–5) ^a	5 (4–5) ^a	4 (4–5) ^a
PSAX	5 (4–5) ^a	4 (4–5) ^{a,b}	5 (4–5) ^a	4 (3–5) ^{a,b}	5 (4–5) ^a	4 (4–5) ^{a,b}	5 (4–5) ^a	4 (4–5) ^{a,b}
A4CH	4 (4–5) ^a	4 (4–5) ^a	5 (4–5) ^a	4 (4–5) ^{a,b}	4 (4–5) ^a	4 (4–5) ^a	5 (4–5) ^a	4 (4–5) ^{a,b}
A2CH	4 (3–4) ^a	4 (3–5) ^a	4 (4–5) ^a	4 (3–4) ^{a,b}	4 (3–4) ^a	4 (3–5) ^a	4 (4–5) ^a	4 (3–5) ^{a,b}
S4CH	4 (4–5) ^a	4 (3–4) ^a	4 (4–5) ^a	4 (3–5) ^a	4 (3–4) ^a	4 (3–5) ^a	4 (4–5) ^a	4 (3–4) ^a

Data are expressed as median (interquartile range). A4CH: apical four-chamber view; A2CH: apical two-chamber view; PLAX: parasternal long-axis view; PSAX: parasternal short-axis view; S4CH: subcostal four-chamber view.

^a $P < 0.05$ versus pretest evaluation.

^b $P < 0.05$ versus post-test evaluation.

Figure 1

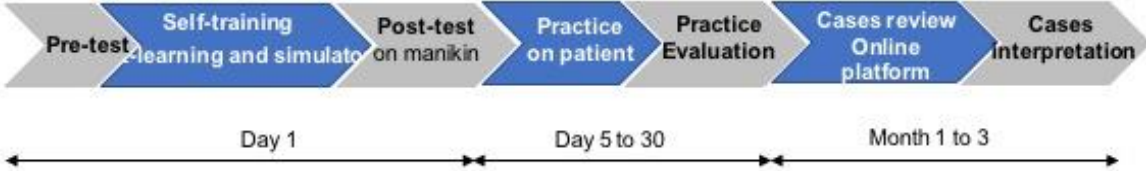

Figure 2

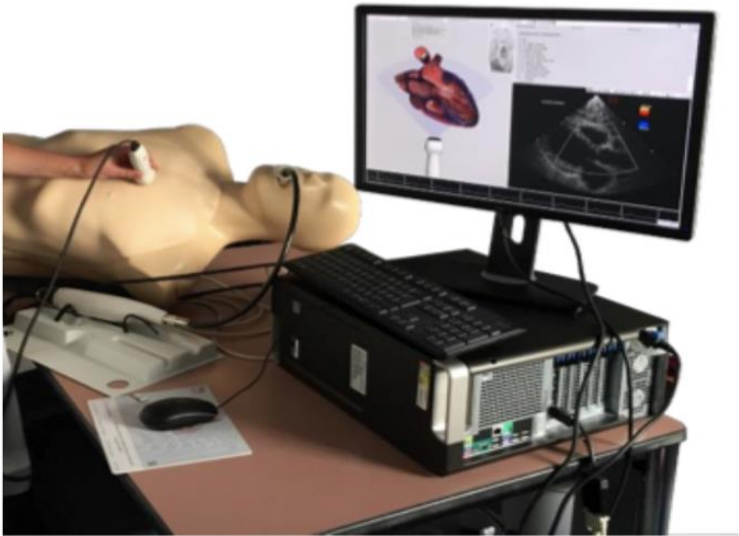


Figure 3

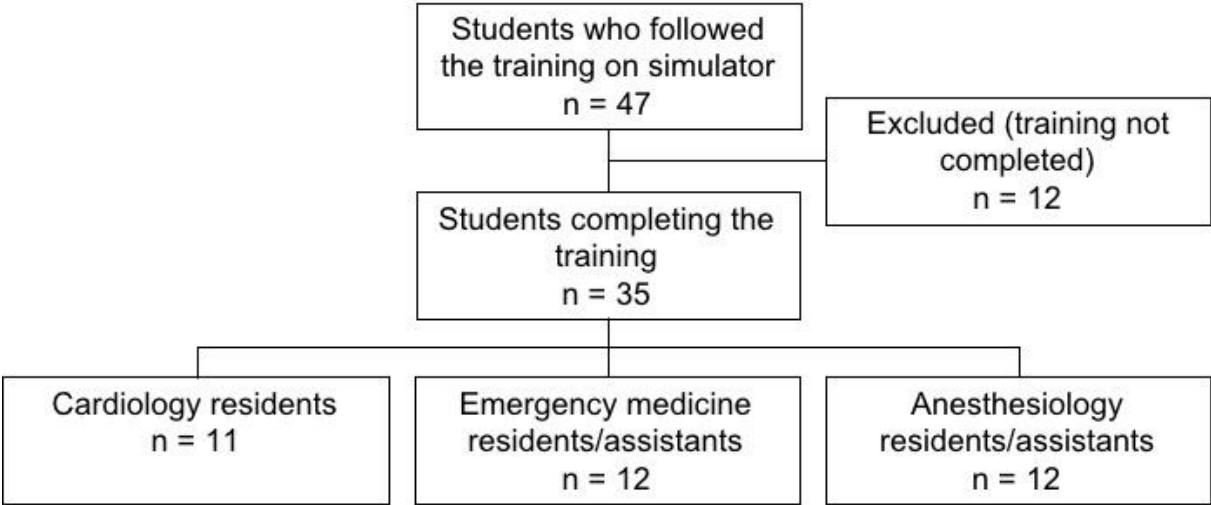


Figure 4

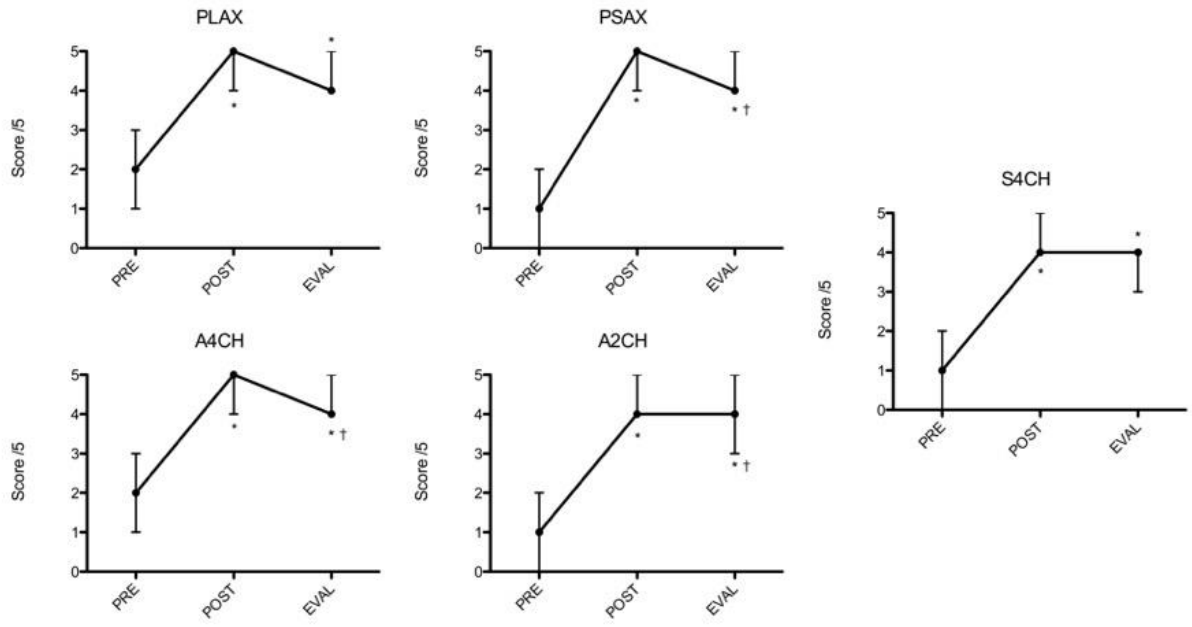
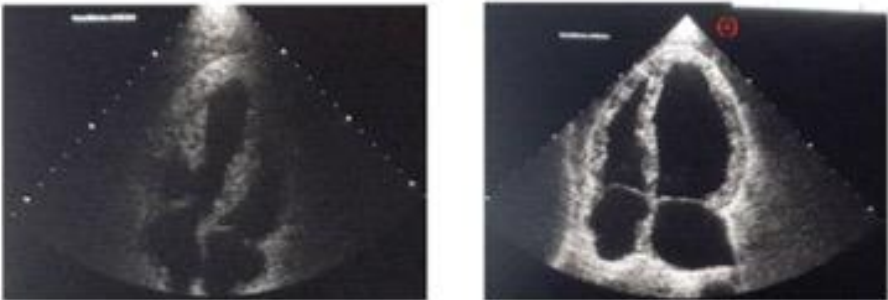
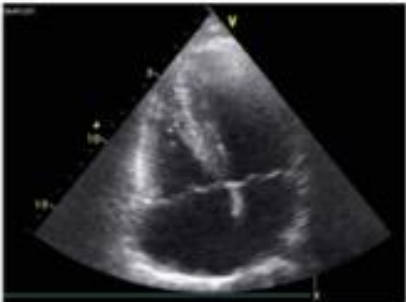


Figure 5



PRE TEST

POST TEST



EVAL on patient

Figure 6

