



HAL
open science

Three- and four-part displaced proximal humeral fractures in patients older than 70 years: reverse shoulder arthroplasty or nonsurgical treatment?

Matthieu Chivot, Damien Lami, Paul Bizzozero, Alexandre Galland,
Jean-Noël Argenson

► To cite this version:

Matthieu Chivot, Damien Lami, Paul Bizzozero, Alexandre Galland, Jean-Noël Argenson. Three- and four-part displaced proximal humeral fractures in patients older than 70 years: reverse shoulder arthroplasty or nonsurgical treatment?. *Journal of Shoulder and Elbow Surgery*, 2019, 28 (2), pp.252-259. 10.1016/j.jse.2018.07.019 . hal-02528759

HAL Id: hal-02528759

<https://hal.science/hal-02528759v1>

Submitted on 14 Apr 2020

HAL is a multi-disciplinary open access archive for the deposit and dissemination of scientific research documents, whether they are published or not. The documents may come from teaching and research institutions in France or abroad, or from public or private research centers.

L'archive ouverte pluridisciplinaire **HAL**, est destinée au dépôt et à la diffusion de documents scientifiques de niveau recherche, publiés ou non, émanant des établissements d'enseignement et de recherche français ou étrangers, des laboratoires publics ou privés.

Three- and four-part displaced proximal humeral fractures in patients older than 70 years: reverse shoulder arthroplasty or nonsurgical treatment?

Matthieu Chivot, MD^{a,b,*}, Damien Lami, MD^b, Paul Bizzozero, MD^{a,b},
Alexandre Galland, MD^b, Jean-Noël Argenson, MD, PhD^{a,b}

^aAix-Marseille University, Centre National de la Recherche Scientifique, L'Institut des Sciences Moléculaires Unité Mixte de Recherche 7287, Marseille, France

^bDepartment of Orthopedic Surgery and Traumatology, Institute of Movement and Locomotion, St. Marguerite Hospital, Marseille, France

Background: The objective of our study was to evaluate the results of surgical treatment by reverse shoulder arthroplasty (RSA) compared with nonsurgical treatment after 2 years of follow-up in patients aged 70 years or older with displaced 3-part or 4-part proximal humeral fractures.

Methods: Two groups were formed: the RSA group (n = 28) and the nonsurgical group (n = 32). Minimum follow-up was 2 years. We included patients with 3-part or 4-part fractures according to the Neer classification. Main outcome measures were the Constant-Murley score, the 11-item version of the Disabilities of the Arm, Shoulder and Hand score, and the Subjective Shoulder Value score. An autonomy score, a cognitive assessment score, and a pain score were also measured.

Results: Clinical features in the 2 groups were not significantly different. The Constant-Murley mean score was significantly higher for the RSA group (82.1% vs. 76.8%; $P = .03$). Amplitudes were all higher in favor of the RSA group ($P < .02$). There was no significant difference in mean score on the 11-item version of the Disabilities of the Arm, Shoulder and Hand score, the preoperative and postoperative Subjective Shoulder Value score, the autonomy score, the cognitive assessment score, or the pain score in both groups at the last follow-up. The complication rate was higher for the RSA group.

Conclusions: These results suggest that RSA treatment of proximal humeral fractures with 3-part or 4-part displaced fragments in elderly patients provides better functional outcomes than does nonsurgical treatment. However, the observed clinical difference was relatively small. This solution must be proposed only to patients who have a significant functional demand.

Level of evidence: Level III; Retrospective Cohort Design; Treatment Study

Keywords: Proximal humeral fracture; elderly; reverse shoulder arthroplasty; nonsurgical treatment; functional outcomes; QuickDASH

Institutional Review Board approval was not required because this was a retrospective study of patients whose surgery followed validated techniques and no unnecessary invasive examinations were performed.

*Reprint requests: Matthieu Chivot, MD, Aix Marseille University,

Institute for Movement and Locomotion, Department of Orthopedic Surgery

and Traumatology, St. Marguerite Hospital, 270 Boulevard Sainte Marguerite, BP 29 13274 Marseille, France.

Proximal humeral fractures (PHFs) account for 5% of skeletal fractures^{12,19} and constitute the third most common osteoporotic fracture,⁸ with an incidence of 6.6 per 1000 person-years.²² In the elderly, these are the second most common fractures of the upper limb.² This incidence has tripled in the last 30 years²¹ and is expected to increase further in the next 20 years due to population growth and aging of the population.^{23,37} The distribution of these fractures is uneven, with most occurring after minor trauma in the elderly population affected with osteoporosis.¹³

Slight displacement is found in 50%-90% of PHFs, and these are usually treated nonsurgically, with good functional outcomes.^{6,13,15,31} Poor outcomes are usually associated with displaced multifragment fractures and have led surgeons to search for surgical solutions.^{20,27,30,33} Surgical treatment has not, however, demonstrated its effectiveness compared with nonsurgical treatment in elderly patients with a displaced fracture.^{29,38} Any surgical treatment would be a risk factor for death in patients who come to the emergency department (ED) with an isolated fracture.³²

Nonsurgical treatment when imposed by a surgical contraindication gives bad results.⁶ However, when chosen by the surgeon, it can provide good long-term results, even on displaced fractures.^{6,48}

Osteosynthesis locking-plate technology, which has certain advantages in osteoporotic bones, has been investigated in randomized trials, but this surgery has not demonstrated its effectiveness compared with nonsurgical treatment.^{14,35,39,42} Intramedullary nailing osteosynthesis has also not demonstrated its superiority.²⁶

Hemiarthroplasty is another surgical option but has not been shown to be significantly superior to nonsurgical or plate osteosynthesis.^{5,36} Reverse shoulder arthroplasty (RSA) is also a tool to treat these fractures, with several case series having been published^{9,28,40} and reporting good functional outcomes.³⁴ This prosthetic design, lowering and medializing center of rotation of the shoulder, creates a mechanical advantage for the deltoid muscle, which becomes the main driver of anterior elevation and active abduction.¹⁶ Studies comparing RSA with hemiarthroplasty for treatment of PHFs have reported better outcomes on pain scores and functional findings after reverse joint replacement.^{4,43,44}

The use of RSA for the treatment of PHFs is steadily increasing.¹ However, the complication rate is high, up to 21%,^{10,34} among which instability and stiffness in rotation are the most important. These arthroplasty procedures are reserved for patients older than 65 years because of poor

alternatives after a complication and a short lifetime.¹⁸ The best surgical option for these fractures in older populations therefore seems to be RSA. To our knowledge no study to date has compared nonsurgical treatment with this procedure. The objective of our study was to evaluate outcomes of surgical treatment by RSA compared with nonsurgical treatment after 2 years of follow-up in patients aged 70 years or older with displaced 3-part or 4-part PHF.

Materials and methods

This was a multicenter retrospective and comparative study. Two centers within the same city participated in the study. One center was a Level 1 trauma center, the other did not have an ED. Data collection was done after receiving informed consent from each patient.

Inclusion and exclusion criteria

Inclusion criteria were as follows:

- a patient aged 70 or older;
- admitted to 1 of the 2 centers between January 2011 and January 2015;
- in general condition allowing surgery, with an American Society of Anesthesiologists (ASA) physical status classification score of <IV;
- a fracture with 3 or 4 fragments displaced from the proximal end of the humerus according to the Neer classification³¹ (Table I);
- recent (<15 days);
- surgically treated by RSA or nonsurgical treatment; and
- a minimum follow-up of 24 months.

Patients were excluded when consent was not possible because of cognitive impairment (Mini-Mental State Examination [MMSE] score⁴⁷ <17) or language barriers, if they lived in institutions or were not autonomous at home (Katz Index of Independence in Activities of Daily Living²⁴ score <4), were in poor general condition (ASA score >III), or had a pre-existing functional impairment of the upper limb, another concomitant fracture, an open fracture, a pathologic fracture, a fracture with glenohumeral dislocation, a “split head fracture” with separation of the cartilaginous cap, absence of bone contact between the humeral diaphysis and 1 of the proximal fragments, or vascular or axillary nerve involvement.

Radiologic analysis

To classify fractures and collect data, standard x-ray images and computed tomography (CT) scans of patients aged 70 years or older with PHF were analyzed by a single observer. A CT scan was available

Table I Neer classification for proximal humeral fractures and radiologic inclusion criteria

Potential fracture “part”	Greater tuberosity (GT), lesser tuberosity (LT) head (H), shaft (S)
Definition of a “part”	>1 cm displacement or >45° rotation Normal neck shaft angle 130°
Radiologic inclusion criteria	3-part fractures: H + GT, S and LT H + LT, S and GT H, LT + GT and S H, GT, LT + S H, LT, GT + S 4-part fractures: H, GT, LT, S

for all patients. The displacement of the fragments and the angulation of the humeral head were calculated with a ruler and a digital goniometer. The cervicodiaphyseal angle of reference was 130°. Fracture displacement was defined according to the Neer criteria (Table I).³¹ The translation of the fragments was measured on several incidences, and the average of the measurements was retained. Rotation was measured on a strict frontal x-ray image and CT scan in the frontal plane.

Surgical treatment

Patients undergoing total RSA were operated on within 15 days of the trauma. A standardized procedure was performed by the same operator in the 2 centers. The patients were operated on under general anesthesia and placed in a half-sitting position. The fractured upper limb was attached to a sterile articulated arm. A systemic antibioprophyllaxis with intravenous cefazolin (2 g) was administered.

A deltopectoral approach was performed. The Trabecular Metal Reverse Shoulder System implant (Zimmer Biomet, Warsaw, IN, USA) was used in all patients. To restore humeral height, medial calcar and upper edge of the insertion of the pectoralis major muscle were used as landmarks. Retroversion of 20° was restored using the ancillary instrumentation. The bicipital groove was used as a reference for the repositioning of tuberosities.

Two holes were drilled on the proximal diaphysis with a 2.5-mm wick in which 2 nonabsorbable Mersutures size 2 threads (Ethicon, Inc., Somerville, NJ, USA) were inserted in double strands. A plug with subchondral bone from the humeral head was positioned in the diaphyseal shaft. All the stems were cemented using an injector gun. A Biostop cement (DePuy, Leeds, UK) with Palamed G gentamycin antibiotic cement (Heraeus Medical GmbH, Wehrheim, Germany) was used.

Particular care was taken to leave the proximal part of the stalk covered with the trabecular metal implant without cement for reinsertion of tuberosities. The lower part of the tuberosities was repositioned on the diaphysis facilitated by the wires left in place. The tuberosities were fixed on the prosthesis using 4 Mersutures size 2 previously positioned in double strands at the tendon–bone junction of the infraspinatus and teres minor when they were involved in the fracture.

The supraspinatus tendon was resected in all cases. Two sutures were intended for the reinsertion of the greater tuberosity and the other 2 for the smaller tuberosity. Once the tuberosities were in anatomic position, the threads were blocked by a “Nice knot.”³

Standard radiographs were obtained before the patient was moved from the operating room. The patients were immobilized by a simple analgesic scarf. During the first 2 weeks, the patient practiced mobilization of the elbow, wrist, and hand, without mobilization of the shoulder, with physiotherapist supervision. Between weeks 2 and 6, pendulum mobilization with abduction and passive elevation at 100° was allowed without working rotations. Between weeks 6 and 12, passive mobilization without limit was allowed with the rotations. Active motion was allowed up to 90° of abduction and anterior elevation. After 12 weeks, active motion in all planes was allowed and unlimited.

Nonsurgical treatment

The elbow in patients treated nonsurgically was immobilized, with the arm in internal rotation for 6 weeks. The follow-up consulta-

tions allowed controlling the tolerance of the treatment as well as the skin condition under immobilization. The rehabilitation protocol was the same as for the patients who underwent operations.

Monitoring and evaluation criteria

Patients were received in the ED in 1 of the 2 centers and by outpatient clinics in the center that did not have an ED. Patients were systematically reviewed for orthopedic consultation after their stay in the ED or in hospital. Each option was explained. All patients were assessed by the mobile geriatrics and anesthesia team.

Each patient was seen within 7 days of the trauma and was reviewed at 3, 6, 12, and 24 weeks and then annually. All patients with more than 2 years of follow-up were reviewed in consultation. Clinical evaluations were performed by 2 examiners. Examination included complication assessment, visual analog pain scale, range of motion, Constant-Murley¹¹ score, the Subjective Shoulder Value (SSV) score, the 11-item version of the Disabilities of the Hand, Shoulder and Elbow (*QuickDASH*) score,¹⁷ the Katz score,²⁴ the MMSE score,⁴⁷ and a simple satisfaction score with 4 possibilities (disappointed, moderately satisfied, satisfied, or very satisfied).

Statistical analysis

All data were stored in an Excel software database (Microsoft, Redmond, WA, USA). The statistical analysis was performed by a statistician of the Department of Medical Information using R software (Comprehensive R Archive Network; The R Foundation for Statistical Computing, Vienna, Austria). The Shapiro-Wilk test was used to test the normality of the variables tested. The Student and Wilcoxon-Mann-Whitney *t* tests were used for quantitative variables based on distribution normality. Fisher exact and χ^2 tests were used for the qualitative variables. The significance level was set to $P < .05$.

Results

Constitution of groups

Analysis of the database, using the inclusion criteria, identified 518 patients. A flowchart (Fig. 1) was produced to explain the selection of patients for both groups. The final groups consisted of 28 patients for the RSA group and 32 for the nonsurgical treatment group.

Characteristics of the groups

The main clinical features of the patients in each group are summarized in Table II. The radiologic characteristics are presented in Table III.

The groups did not differ significantly in age, sex, percentage of dominant side, and preoperative ASA, SSV, activities of daily living, and MMSE scores. There was a significant difference in the mean body mass index, which was higher in the RSA group (27.19 vs. 25.83 kg/m²). There was no significant difference in the type or displacement of fractures between the 2 groups.

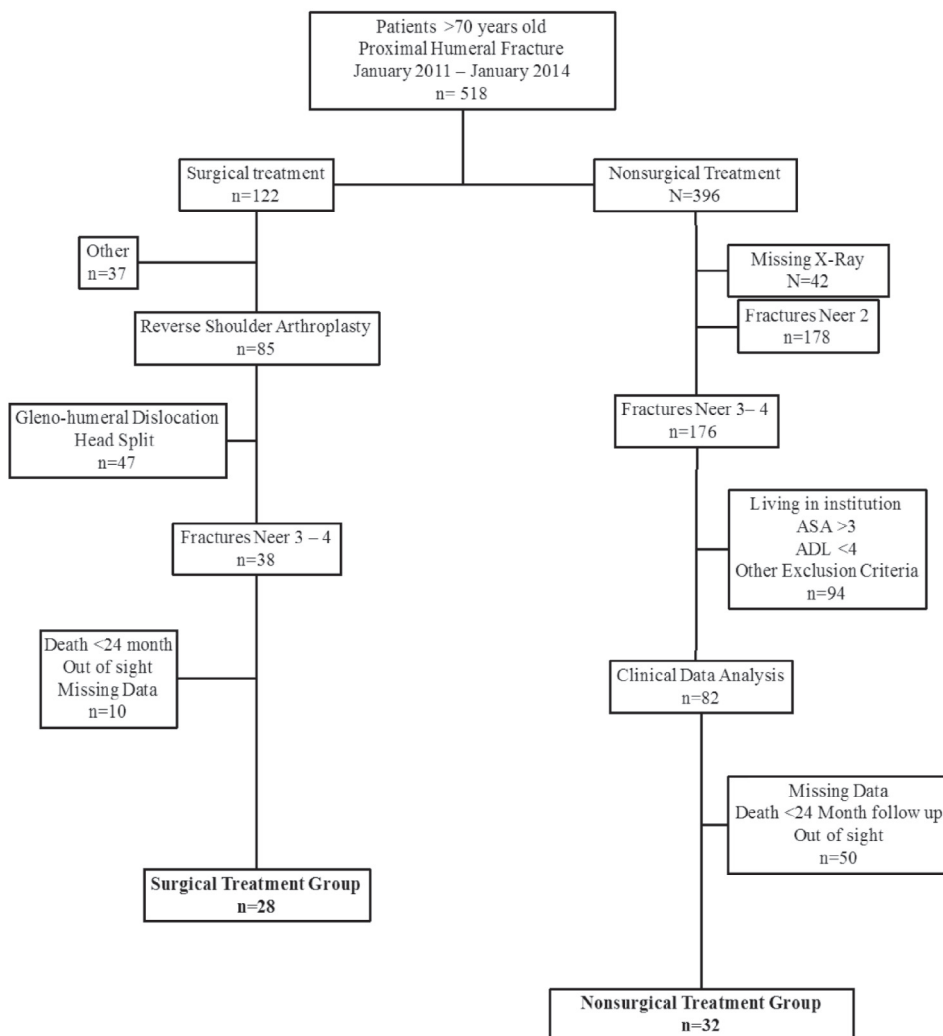


Figure 1 Flowchart explaining constitution of the 2 groups. ASA, American Society of Anesthesiologists physical status classification; ADL, activities of daily living.

Clinical and functional outcomes

Main results are provided in [Table IV](#). There was no significant difference in the mean scores of *QuickDASH*, preoperative and postoperative SSV, the preoperative and postoperative activities of daily living, the preoperative and postoperative mean MMSE, and the visual analog scale for pain in both groups at the last check.

There were, however, significant differences in the Constant-Murley mean score,¹¹ at 82.1% (56.5 points) vs. 76.8% (50.5 points) for the surgical treatment group ($P = .03$), and 19% of patients in the conservative treatment group had an inadequate functional result, with a weighted score of <70% vs. 10% in the surgical treatment group ($P = .03$). The amplitudes were all higher in favor of the surgical treatment group. Patients were mostly satisfied in the nonsurgical treatment group and very satisfied in the surgical treatment group ($P = .03$).

Radiologic results

The radiologic results are presented in [Table V](#). In the conservative treatment group, secondary displacement of fragments was <1 cm or 45°. No conflict with the scapula was identified in the surgical treatment group.

Complications

There were no complications in the nonsurgical treatment group. In the surgical treatment group, 2 patients (7%) experienced a complication directly related to the intervention. One patient presented with a traumatic dislocation after cardiologic syncope. There was no recurrence after external reduction. The other patient sustained a dislocation after a hematogenous infection of urinary origin with multiresistant bacteria. This patient underwent reoperation with removal of

Table II Clinical characteristics of the groups

Criteria	Reverse shoulder arthroplasty (n = 28)	Nonsurgical treatment (n = 32)	P
Age, yr	77 (70-92)	79.2 (70-92)	.23
Sex			.13
Male	6 (21.4)	2 (6.3)	
Female	22 (78.6)	30 (93.8)	
BMI, kg/m ²	27.19 (18.4-38.5)	25.83 (18.4-35.1)	.04
Side			.86
Right	16 (57.1)	19 (59.4)	
Left	12 (42.9)	13 (40.6)	
Dominant side	17 (60.7)	18 (58.1)	.72
Follow-up, mo	31.8 (24-52)	32.1 (24-43)	
ASA score	2.53	2.29	.3
Preoperative scores			
SSV, %	98 (70-100)	97 (70-100)	.78
ADL	5.66	5.8	.2
MMSE	29	29.53	.07

BMI, body mass index; ASA, American Society of Anesthesiologists; SSV, Subjective Shoulder Value; ADL, activities of daily living; MMSE, Mini-Mental State Examination.

Continuous data are presented as mean (range) and categoric data as number (%).

P values in bold are statistically significant ($P < .05$).

Table III Radiologic characteristics of the groups

Variable	Reverse shoulder arthroplasty (n = 28)	Nonsurgical treatment (n = 32)	P
Fracture type			.36
Neer 3	18 (64.3)	24 (75)	
Neer 4	10 (35.7)	8 (25)	
Rotation type			.49
Valgus	19 (67.9)	19 (59.4)	
Varus	9 (32.1)	13 (40.6)	
Translation, mm			
Surgical neck	25.7 (3-58)	20.4 (3-42)	.09
Greater tuberosity	12.1 (2-28)	12.9 (3-28)	.52
Lesser tuberosity	6.1 (1-17)	5 (1-17)	.44
Angulation, °			
Valgus	43 (3-78)	33 (2-56)	.08
Varus	42 (15-70)	26 (6-53)	.056

Categoric data are presented as number (%) and continuous data as mean (range).

the implant. Two patients in the surgical treatment group and 5 in the nonsurgical treatment group lost their autonomy and lived in institutions; however, the loss of autonomy for all patients was related to lower limb trauma or medical pathology.

Discussion

The results of our study demonstrate a significant benefit in functional outcomes in favor of RSA vs. nonsurgical treatment in independent elderly and healthy patients with a displaced PHF with 3 or 4 fragments. In addition, RSA as a first-line treatment was a safe surgical procedure with relatively low rates of complications (7%) and reoperations (3%). Regardless of the primary treatment, surgical or not, these multifragment fractures resulted in a functional impairment of the shoulder with a resonance on the SSV but also resulted in a decrease of autonomy of the patients. All ranges of motion in the patients in the surgical treatment group were significantly higher, unlike in the nonsurgical group. Patients in both groups were satisfied with their management, yet there were significantly more highly satisfied patients in the surgical group. However, there was no significant difference in the quality of life score of the *QuickDASH* upper limb or the pain score at 2 years of follow-up.

No other study, to our knowledge, has directly compared surgical treatment with RSA vs. nonsurgical treatment in elderly patients. Zyto⁴⁸ was the first author to explain that nonsurgical treatment should be considered for displaced fractures with absolute Constant scores between 50 and 60 points at 10 years of decline. These values are consistent with our results, despite the lower decline in our study.

Bouchet et al⁶ evaluated the results of nonsurgical treatment on multifragment fractures. Although their series had nondisplaced fractures and young patients, their results were close to those found in our study. There were no complications, with the exception of complaints of stiffness. No osteonecrosis required surgical treatment. The authors concluded that when nonsurgical treatment is chosen for nondisplaced fractures, the results are good; however, when nonsurgical treatment was imposed by a surgical contraindication, outcomes were insufficient. In our series, all patients in the nonsurgical treatment group with a displaced fracture were in good general condition and could have had surgery. For the most part, surgical treatment was offered to them, but they refused mainly for fear of surgery. The results of the series of nonsurgically treated patients from studies comparing surgical treatment vs. nonsurgical treatment without evidence of superiority were consistent with ours.^{5,14,26,29,35,36,39}

Regarding the group of patients surgically treated by RSA, we found a complication rate of 7% and a reintervention rate of 3%. This rate is low compared with previously published results.^{9,34,41} This observation is probably because we did not include patients with dislocation or preoperative humeral head separation, which are more complex lesions. The average 31-month follow-up probably underestimated the rate of late complications. Mean functional outcomes, functional scores, and patient satisfaction scores were similar to descriptions in the literature for this indication.^{7,28,34,40}

It is important to note that patients in the surgically treated group had greater internal rotation than patients in the nonsurgical group; however, 53% of the patients were only able

Table IV Clinical and functional outcomes

Criteria	Reverse shoulder arthroplasty	Nonsurgical treatment	P
	(n = 28)	(n = 32)	
Follow-up, mo	31.8 (24-52)	32.1 (24-43)	
QuickDASH	38.68 (6-91)	31.22 (6-59)	.11
Constant-Murley score	56.5 (32-71)	50.5 (39-66)	.03
Adjusted, %	82.1 (51-100)	76.8 (61-100)	
Adjusted <70%, %	10	19	
Anterior forward, °	110 (90-130)	98 (70-120)	.0005
External rotation, °	19 (0-40)	9 (0-40)	.0002
Internal rotation			.04
Hip	2 (7)	8 (25)	
Sacrum	13 (46)	17 (53)	
L3	2 (7)	1 (3)	
L1	3 (10)	2 (6)	
T12	8 (28)	4 (12)	
SSV, %			
Preoperative	98	97	.19
Postoperative	73	67	
ADL			
Preoperative	5.66	5.8	.74
Postoperative	5.07	5.19	
MMSE			
Preoperative	29	29.53	.66
Postoperative	27.57	28.31	
Satisfaction			.03
Disappointed	0	0	
Moderately satisfied	2 (7)	5 (15)	
Satisfied	12 (43)	21 (65)	
Very satisfied	14 (50)	6 (18)	
Visual analog scale			.47
No pain	15 (53)	19 (59)	
Intermittent	11 (39)	13 (41)	
Permanent	2 (7)	0	

QuickDASH, 11-item version of the Disabilities of the Arm, Shoulder and Hand; SSV, Subjective Shoulder Value; ADL, activities of daily living; MMSE, Mini-Mental State Examination.

Continuous data are presented as mean (range), or as indicated, and categorical data as number (%).

P values in bold are statistically significant ($P < .05$).

Table V Radiologic outcomes at last follow-up

Outcome	Reverse shoulder arthroplasty	Nonsurgical treatment
	(n = 28)	(n = 32)
	No. (%)	No. (%)
Greater tuberosity		
Anatomic healing	25 (89)	–
Resorption	3 (10)	–
Nonunion	0	–
Secondary displacement	–	4 (12)
Osteonecrosis	–	3 (9)
Nonunion	–	1 (3)
Resorption	–	3 (9)

to reach the sacrum, which is insufficient. This weak internal rotation is also at the origin of the decline in the Katz autonomy score.²⁴ Most patients could no longer dress themselves without assistance. These data are important to take into account when explaining to patients that, whatever their treatment, there is a 50% chance they will have difficulties with dressing. This has been confirmed in several series.^{4-6,34}

Despite the significant difference observed in our results, the mean Constant-Murley scores between the 2 groups were deferred by 6 points. Studies have reported that the minimal clinically important difference for the Constant-Murley score is between 5.7 and 10 points.^{25,45} This corresponds with our results. The retrospective design of the study automatically led to a bias in the selection and monitoring of patients because of a large number of lost files. The statistical power of the study was therefore relatively weak.

Nevertheless, it was an original study, the first to directly compare the surgical treatment by RSA against nonsurgical treatment in patients aged at least 70 years in good general condition and autonomous with displaced multifragment fractures. The 2 retrospectively constituted groups were comparable in their overall characteristics and in the radiographic analysis of the fractures. The follow-up was identical for all patients, and the implant and the operator were unique. The only difference was the treatment received.

Conclusion

The results of our study suggest that the treatment of PHFs with 3-part to 4-part displaced fragments by RSA in patients aged at least 70 years provides better functional outcomes than does nonsurgical treatment. Although the results of reverse arthroplasty treatment were significantly better, the observed clinical difference was relatively small but did reach the minimal clinically important difference.^{25,45} However, the quality of life score for the 2 treatments was similar. Reverse arthroplasty treatment is therefore an effective solution but should be offered only to patients with significant functional demands. These results should be validated by a randomized prospective study, one of which is in progress by the authors.⁴⁶

Acknowledgment

The authors thank Mathilde Marechal for helping with the statistical analysis.

Disclaimer

Jean-Noël Argenson is an educational consultant for Zimmer, Symbios, and Adler, and receives royalties from Zimmer. The other authors, their immediate families, and any research foundations with which they are affiliated have not received any financial payments or other benefits from any commercial entity related to the subject of this article.

References

1. Acevedo DC, Vanbeek C, Lazarus MD, Williams GR, Abboud JA. Reverse shoulder arthroplasty for proximal humeral fractures: update on indications, technique, and results. *J Shoulder Elbow Surg* 2014;23:279-89. <http://dx.doi.org/10.1016/j.jse.2013.10.003>
2. Baron JA, Barrett JA, Karagas MR. The epidemiology of peripheral fractures. *Bone* 1996;18(Suppl 1.):209S-213S.
3. Boileau P, Alami G, Rumian A, Schwartz DG, Trojani C, Seidl AJ. The doubled-suture nice knot. *Orthopedics* 2017;40:e382-6. <http://dx.doi.org/10.3928/01477447-20161202-05>
4. Bonneville N, Tournier C, Clavert P, Ohl X, Sirveaux F, Saragaglia D, et al. Hemiarthroplasty versus reverse shoulder arthroplasty in 4-part displaced fractures of the proximal humerus: multicenter retrospective study. *Orthop Traumatol Surg Res* 2016;102:569-73. <http://dx.doi.org/10.1016/j.otsr.2016.02.014>
5. Boons HW, Goosen JH, van Grinsven S, van Susante JL, van Loon CJ. Hemiarthroplasty for humeral four-part fractures for patients 65 years and older: a randomized controlled trial. *Clin Orthop Relat Res* 2012;470:3483-91. <http://dx.doi.org/10.1007/s11999-012-2531-0>
6. Bouchet R, Block D, D'ollonne T, Gadea F, Gaillot J, Sirveaux F, et al. Non-operative treatment of four-part fractures of the proximal end of the humerus: results of a prospective and retrospective multicentric study. *Int Orthop* 2016;40:1669-74. <http://dx.doi.org/10.1007/s00264-015-3090-2>
7. Bufquin T, Hersan A, Hubert L, Massin P. Reverse shoulder arthroplasty for the treatment of three- and four-part fractures of the proximal humerus in the elderly: a prospective review of 43 cases with a short-term follow-up. *J Bone Joint Surg Br* 2007;89:516-20. <http://dx.doi.org/10.1302/0301-620X.89B4.18435>
8. Calvo E, Morcillo D, Foruria AM, Redondo-Santamaría E, Osorio-Picorne F, Caeiro JR, et al. Nondisplaced proximal humeral fractures: high incidence among outpatient-treated osteoporotic fractures and severe impact on upper extremity function and patient subjective health perception. *J Shoulder Elbow Surg* 2011;20:795-801. <http://dx.doi.org/10.1016/j.jse.2010.09.008>
9. Cazeneuve JF, Cristofari DJ. The reverse shoulder prosthesis in the treatment of fractures of the proximal humerus in the elderly. *J Bone Joint Surg Br* 2010;92:535-9. <http://dx.doi.org/10.1302/0301-620X.92B4.22450>
10. Cheung E, Willis M, Walker M, Clark R, Frankle MA. Complications in reverse total shoulder arthroplasty. *J Am Acad Orthop Surg* 2011;19:439-49.
11. Constant CR, Murley AH. A clinical method of functional assessment of the shoulder. *Clin Orthop Relat Res* 1987;(214):160-4.
12. Court-Brown CM, Caesar B. Epidemiology of adult fractures: a review. *Injury* 2006;37:691-7. <http://dx.doi.org/10.1016/j.injury.2006.04.130>
13. Court-Brown CM, Garg A, McQueen MM. The epidemiology of proximal humeral fractures. *Acta Orthop Scand* 2001;72:365-71.
14. Fjalestad T, Hole MØ, Hovden IA, Blücher J, Strømsøe K. Surgical treatment with an angular stable plate for complex displaced proximal humeral fractures in elderly patients: a randomized controlled trial. *J Orthop Trauma* 2012;26:98-106. <http://dx.doi.org/10.1097/BOT.0b013e31821c2e15>
15. Gaebler C, McQueen MM, Court-Brown CM. Minimally displaced proximal humeral fractures: epidemiology and outcome in 507 cases. *Acta Orthop Scand* 2003;74:580-5. <http://dx.doi.org/10.1080/00016470310017992>
16. Grammont P, Trouilloud P, Laffay J, Deries X. Concept study and realization of a new total shoulder prosthesis. *Rhumatologie* 1987;39:407-18 [in French].
17. Gummesson C, Ward MW, Atroshi I. The shortened Disabilities of the Arm, Shoulder and Hand questionnaire (Quick DASH): validity and reliability based on responses within the full-length DASH. *BMC Musculoskelet Disord* 2006;7:44. <http://dx.doi.org/10.1186/1471-2474-7-44>
18. Handoll HHG, Branson S. Interventions for treating proximal humeral fractures in adults. *Cochrane Database Syst Rev* 2015;(11):CD000434. <http://dx.doi.org/10.1002/14651858.CD000434.pub4>
19. Horak J, Nilsson BE. Epidemiology of fracture of the upper end of the humerus. *Clin Orthop Relat Res* 1975;(112):250-3.
20. Kancherla VK, Singh A, Anakwenze OA. Management of acute proximal humeral fractures. *J Am Acad Orthop Surg* 2017;25:42-52. <http://dx.doi.org/10.5435/JAAOS-D-15-00240>
21. Kannus P, Niemi S, Sievänen H, Parkkari J. Stabilized incidence in proximal humeral fractures of elderly women: nationwide statistics from Finland in 1970-2015. *J Gerontol A Biol Sci Med Sci* 2017;72:1390-3. <http://dx.doi.org/10.1093/gerona/glx073>

22. Kannus P, Palvanen M, Niemi S, Parkkari J, Järvinen M, Vuori I. Increasing number and incidence of osteoporotic fractures of the proximal humerus in elderly people. *BMJ* 1996;313:1051-2.
23. Kannus P, Palvanen M, Niemi S, Parkkari J, Järvinen M, Vuori I. Osteoporotic fractures of the proximal humerus in elderly Finnish persons: sharp increase in 1970-1998 and alarming projections for the new millennium. *Acta Orthop Scand* 2000;71:465-70.
24. Katz S. Assessing self-maintenance: activities of daily living, mobility, and instrumental activities of daily living. *J Am Geriatr Soc* 1983;31:721-7.
25. Kukkonen J, Kauko T, Vahlberg T, Joukainen A, Äärimala V. Investigating minimal clinically important difference for Constant score in patients undergoing rotator cuff surgery. *J Shoulder Elbow Surg* 2013;22:1650-5. <http://dx.doi.org/10.1016/j.jse.2013.05.002>
26. Lange M, Brandt D, Mittlmeier T, Gradl G. Proximal humeral fractures: non-operative treatment versus intramedullary nailing in 2-, 3- and 4-part fractures. *Injury* 2016;47(Suppl. 7):S14-9. [http://dx.doi.org/10.1016/S0020-1383\(16\)30848-8](http://dx.doi.org/10.1016/S0020-1383(16)30848-8)
27. Lanting B, MacDermid J, Drosdowech D, Faber KJ. Proximal humeral fractures: a systematic review of treatment modalities. *J Shoulder Elbow Surg* 2008;17:42-54. <http://dx.doi.org/10.1016/j.jse.2007.03.016>
28. Lenarz C, Shishani Y, McCrum C, Nowinski RJ, Edwards TB, Gobezie R. Is reverse shoulder arthroplasty appropriate for the treatment of fractures in the older patient? Early observations. *Clin Orthop Relat Res* 2011;469:3324-31. <http://dx.doi.org/10.1007/s11999-011-2055-z>
29. Mao F, Zhang DH, Peng XC, Liao Y. Comparison of surgical versus non-surgical treatment of displaced 3- and 4-part fractures of the proximal humerus: a meta-analysis. *J Invest Surg* 2015;28:215-24. <http://dx.doi.org/10.3109/08941939.2015.1005781>
30. Murray IR, Amin AK, White TO, Robinson CM. Proximal humeral fractures: current concepts in classification, treatment and outcomes. *J Bone Joint Surg Br* 2011;93:1-11. <http://dx.doi.org/10.1302/0301-620X.93B1.25702>
31. Neer CS. Displaced proximal humeral fractures. I. Classification and evaluation. *J Bone Joint Surg Am* 1970;52:1077-89.
32. Neuhaus V, Bot AG, Swellengrebel CH, Jain NB, Warner JJ, Ring DC. Treatment choice affects inpatient adverse events and mortality in older aged inpatients with an isolated fracture of the proximal humerus. *J Shoulder Elbow Surg* 2014;23:800-6. <http://dx.doi.org/10.1016/j.jse.2013.09.006>
33. Nho SJ, Brophy RH, Barker JU, Cornell CN, MacGillivray JD. Management of proximal humeral fractures based on current literature. *J Bone Joint Surg Am* 2007;89(Suppl. 3):44-58. <http://dx.doi.org/10.2106/JBJS.G.00648>
34. Obert L, Saadnia R, Tournier C, Bonneville N, Saragaglia D, Sirveaux F, et al. Four-part fractures treated with a reversed total shoulder prosthesis: prospective and retrospective multicenter study. Results and complications. *Orthop Traumatol Surg Res* 2016;102:279-85. <http://dx.doi.org/10.1016/j.otsr.2016.01.019>
35. Olerud P, Ahrengart L, Ponzer S, Saving J, Tidermark J. Internal fixation versus nonoperative treatment of displaced 3-part proximal humeral fractures in elderly patients: a randomized controlled trial. *J Shoulder Elbow Surg* 2011;20:747-55. <http://dx.doi.org/10.1016/j.jse.2010.12.018>
36. Olerud P, Ahrengart L, Ponzer S, Saving J, Tidermark J. Hemiarthroplasty versus nonoperative treatment of displaced 4-part proximal humeral fractures in elderly patients: a randomized controlled trial. *J Shoulder Elbow Surg* 2011;20:1025-33. <http://dx.doi.org/10.1016/j.jse.2011.04.016>
37. Palvanen M, Kannus P, Niemi S, Parkkari J. Update in the epidemiology of proximal humeral fractures. *Clin Orthop Relat Res* 2006;442:87-92.
38. Rabi S, Evaniew N, Sprague SA, Bhandari M, Slobogean GP. Operative vs non-operative management of displaced proximal humeral fractures in the elderly: a systematic review and meta-analysis of randomized controlled trials. *World J Orthop* 2015;6:838-46. <http://dx.doi.org/10.5312/wjo.v6.i10.838>
39. Rangan A, Handoll H, Brealey S, Jefferson L, Keding A, Martin BC, et al. Surgical vs nonsurgical treatment of adults with displaced fractures of the proximal humerus: the PROFHER randomized clinical trial. *JAMA* 2015;313:1037-47. <http://dx.doi.org/10.1001/jama.2015.1629>
40. Ross M, Hope B, Stokes A, Peters SE, McLeod I, Duke PF. Reverse shoulder arthroplasty for the treatment of three-part and four-part proximal humeral fractures in the elderly. *J Shoulder Elbow Surg* 2015;24:215-22. <http://dx.doi.org/10.1016/j.jse.2014.05.022>
41. Russo R, Della Rotonda G, Cautiero F, Ciccarelli M. Reverse shoulder prosthesis to treat complex proximal humeral fractures in the elderly patients: results after 10-year experience. *Musculoskelet Surg* 2015;99(Suppl. 1):S17-23. <http://dx.doi.org/10.1007/s12306-015-0367-y>
42. Sanders RJ, Thissen LG, Teepen JC, van Kampen A, Jaarsma RL. Locking plate versus nonsurgical treatment for proximal humeral fractures: better midterm outcome with nonsurgical treatment. *J Shoulder Elbow Surg* 2011;20:1118-24. <http://dx.doi.org/10.1016/j.jse.2011.01.025>
43. Schairer WW, Nwachukwu BU, Lyman S, Craig EV, Gulotta LV. Reverse shoulder arthroplasty versus hemiarthroplasty for treatment of proximal humerus fractures. *J Shoulder Elbow Surg* 2015;24:1560-6. <http://dx.doi.org/10.1016/j.jse.2015.03.018>
44. Sebastián-Forcada E, Cebrián-Gómez R, Lizaur-Utrilla A, Gil-Guillén V. Reverse shoulder arthroplasty versus hemiarthroplasty for acute proximal humeral fractures. A blinded, randomized, controlled, prospective study. *J Shoulder Elbow Surg* 2014;23:1419-26. <http://dx.doi.org/10.1016/j.jse.2014.06.035>
45. Simovitch R, Flurin PH, Wright T, Zuckerman JD, Roche CP. Quantifying success after total shoulder arthroplasty: the minimal clinically important difference. *J Shoulder Elbow Surg* 2018;27:298-305. <http://dx.doi.org/10.1016/j.jse.2017.09.013>
46. Smith GC, Bateman E, Cass B, Damiani M, Harper W, Jones H, et al. Reverse Shoulder Arthroplasty for the treatment of Proximal humeral fractures in the Elderly (ReShAPE trial): study protocol for a multicentre combined randomised controlled and observational trial. *Trials* 2017;18:91. <http://dx.doi.org/10.1186/s13063-017-1826-6>
47. Tombaugh TN, McIntyre NJ. The Mini-Mental State Examination: a comprehensive review. *J Am Geriatr Soc* 1992;40:922-35.
48. Zyto K. Non-operative treatment of comminuted fractures of the proximal humerus in elderly patients. *Injury* 1998;29:349-52.