



HAL
open science

Vocal tract anatomy of king penguins: morphological traits of two-voiced sound production

Hannah Joy Kriesell, Céline Le Bohec, Alexander Cerwenka, Moritz Hertel, Jean-Patrice Robin, Bernhard Ruthensteiner, Manfred Gahr, Thierry Aubin, Daniel Normen Düring

► To cite this version:

Hannah Joy Kriesell, Céline Le Bohec, Alexander Cerwenka, Moritz Hertel, Jean-Patrice Robin, et al.. Vocal tract anatomy of king penguins: morphological traits of two-voiced sound production. *Frontiers in Zoology*, 2020, 17 (1), pp.5. 10.1186/s12983-020-0351-8 . hal-02519512

HAL Id: hal-02519512

<https://hal.science/hal-02519512>

Submitted on 16 Sep 2020

HAL is a multi-disciplinary open access archive for the deposit and dissemination of scientific research documents, whether they are published or not. The documents may come from teaching and research institutions in France or abroad, or from public or private research centers.

L'archive ouverte pluridisciplinaire **HAL**, est destinée au dépôt et à la diffusion de documents scientifiques de niveau recherche, publiés ou non, émanant des établissements d'enseignement et de recherche français ou étrangers, des laboratoires publics ou privés.

Vocal tract anatomy of king penguins: Morphological traits of two voiced sound production

Hannah Joy Kriesell^{1,2,3,4,5} hkriesell@centrescientifique.mc,

Céline Le Bohec^{1,2,3} celine.lebohec@iphc.cnrs.fr,

Alexander Cerwenka⁶ cerwenka@snsb.de,

Moritz Hertel⁷ hertel@orn.mpg.de,

Jean-Patrice Robin² jean-patrice.robin@iphc.cnrs.fr,

Bernhard Ruthensteiner⁶ bruthensteiner@snsb.de

Manfred Gahr⁷ gahr@orn.mpg.de

Thierry Aubin^{4*} thierry.aubin@u-psud.fr,

Daniel Normen Düring^{7,8,9*} dnd@ini.ethz.ch

¹ Centre Scientifique de Monaco, Département de Biologie Polaire, MC 98000, Monaco

² Université de Strasbourg, CNRS, IPHC UMR 7178, F-67000 Strasbourg, France

³ Laboratoire International Associé BioSensib (LIA 647, CSM-CNRS-Unistra), MC 98000, Monaco

⁴ Institut des NeuroSciences Paris-Saclay (Neuro-PSI), UMR 9197 (CNRS, Université Paris XI), Orsay, France

⁵ Department of Electronic Systems, Norwegian University of Science and Technology, 7491 Trondheim, Norway

⁶ Zoologische Staatssammlung München, Münchhausenstraße 21, 81247 München, Germany.

⁷ Department of Behavioral Neurobiology, Max Planck Institute for Ornithology, Seewiesen, Germany

⁸ Institute of Neuroinformatics, ETH Zurich & University of Zurich, Switzerland

⁹ Neuroscience Center Zurich (ZNZ), Zurich, Switzerland

*Contributed equally

Corresponding authors: dnd@ini.ethz.ch, hannah.kriesell@ntnu.no

Abstract

Background: The astonishing variety of sounds that birds can produce have been the subject of many studies aiming to identify the underlying anatomical and physical mechanisms of sound production. An interesting feature of some bird vocalisations is the production of two simultaneous frequencies. While most work has been focusing on songbirds, much less is known about dual-sound production in non-passerines, although their sound production organ, the syrinx, would technically allow many of them to produce “two voices”. Here, we focus on the king penguin, a colonial seabird whose calls consist of two frequency bands and their respective harmonics. The calls are produced during courtship and for partner and offspring reunions, and encode the birds’ identity. Here, we dissected, μ CT-scanned and analysed the vocal tracts of 4 adult king penguins from Possession Island, Crozet Archipelago.

Results: King penguins possess a bronchial type syrinx that similar to the songbird’s tracheobronchial syrinx has two sets of vibratory tissues, and thus two separate sound sources. Left and right medial labium differ in diameter between 0.5% and 3.2%, with no consistent laterality between left and right side. The trachea has a conical shape, increasing in diameter from caudal to cranial by 16%. About 80% of the king penguins’ trachea is medially divided by a septum consisting of soft elastic tissue (septum trachealis medialis).

Conclusions:

The king penguins’ vocal tract appears to be mainly adapted to the life in a noisy colony of a species that relies on individual recognition. The offset between the two voices encoding for individuality seems morphologically dictated by the length difference between left and right medial labium. The septum medialis trachealis might support this offset and could therefore be an important anatomical feature that aids in the individual recognition process.

Keywords: Syrinx anatomy, micro computed tomography, 3D reconstruction

Background

Birds exhibit a huge variety of vocal sounds and have exploited the use of acoustic signals in many behavioural contexts, e.g. mate choice and territory defence (reviewed in [1-3]). The characteristics of the sounds produced, the physical mechanisms of sound production and the underlying anatomy of avian vocalisations have been studied in many bird species [4-12]. While mammals produce sound in the larynx, birds have evolved a novel organ for sound production called syrinx [10]. Despite different evolutionary origins of larynx and syrinx, the underlying physical mechanism of sound production in both mammals [11,12] and birds [12] is based on self-

sustained oscillations of the vibratory tissues caused by pressure differences of expiratory air-flow [12,14]. This myoelastic-aerodynamic (MEAD) principle allows biological systems to produce acoustic signals solely based on air flow and does not require direct neurological input or muscular control [12,16]. However, in addition to MEAD-based sound production, many of the often complex sounds produced by birds and their specific acoustic characteristics require precise input of highly specialized muscles that affect the timing and spatial characteristics of the oscillations [17,18]. In addition to musculature, cartilaginous structures and ossified syringeal elements can play an important role in the biomechanics of sound production, e.g. by impacting the position of the vibrating tissues [4,16,17].

Similar to the tissues present in the vocal apparatus of terrestrial mammals, the syrinx and trachea of birds mainly consist of four anatomical elements: bone, cartilage, muscle and vibratory soft tissue. The vibrating tissues of birds are analogous to the vocal folds of the larynx in mammals [18] and typically consist of medial labia (ML), medial tympaniform membranes (MTM) and lateral labia (LL) [22,23]. Goller and Larsen [24] experimentally disabled the MTM in zebra finches *Taeniopygia guttata* and northern cardinals *Cardinalis cardinalis* and concluded that ML and LL are most likely responsible for sound production.

In addition to the often highly specialized anatomy of the syrinx, the respiratory tract [25], oropharyngeal-esophageal cavity [23], larynx, tongue [24], and beak also influence the sound production [22,25].

The detailed anatomy, i.e. the number and location of membranes, morphology of ossified elements as well as the number of muscles and their exact insertion sites on the syrinx differs immensely between species and adds to the intricacy of produced sounds (reviewed in [5,9,25,29]). The general location of the vibratory soft tissues defines the syrinx into one of three types, tracheal, bronchial or tracheobronchial. While bronchial and tracheobronchial syrinx types have one set of ML and LL in each bronchus, tracheal type syringes have only one set of ML and LL in the trachea. Both the tracheobronchial and the bronchial syringes allow birds to produce two sounds simultaneously as vibrations can potentially be created independently at each bronchus [30]. Songbirds are able to produce sounds of different frequencies independently in each bronchus [31,32] owing to their complex intrinsic syringeal musculature [7,33] and lateralizations in size of the vibratory tissues as reported for European starlings *Sturnus vulgaris* [31], white-crowned sparrows and zebra finches [32]. Only few studies also demonstrated the ability to simultaneously produce two sounds in non-songbirds, e.g. wood ducks *Aix sponsa* [33] and the Greater sage-grouse *Centrocercus urophasianus* [34], that produces a “double whistle”. Investigating the vocal tract in non-vocal learners (non-passerines) may allow us to identify

direct links between specific acoustic features such as dual-sound production and the underlying morphological mechanisms because we can assume that the vocal output is more directly linked to anatomical constraints [35–37].

The display calls of king penguins *Aptenodytes patagonicus* have been shown to be emitted during mate choice [39] and sex-differences in the fundamental frequency of the calls and the syllable pattern have been identified [40]. Furthermore, playback experiments have shown that the king penguin call is vital for individual recognition [41,42]. Given that a breeding king penguin couple takes turns to take care of the egg or later the chick, there is a high pressure on individuals to find back their mate and later locate the chick in the colony among thousands of conspecifics. The king penguin display call consists of a succession of frequency modulated syllables with two simultaneous series of harmonically related bands of slightly different frequencies and their respective harmonics, a “two-voice signal” [38,41,43]. It is likely that the underlying mechanism of the ability to produce two related frequency bands in king penguins lies primarily in the anatomical structure of the syrinx [38,43] and can neither be actively modulated nor attributed to nonlinear phenomena, such as subharmonics or biphonation [44].

Detailed knowledge about the vocal tract anatomy of penguins however is generally lacking. The first study conducted by Meckel [47] on the anatomy of the vocal tracts of three specimens of African penguins *Spheniscus demersus*, reports a septum of the trachea that became caudally thicker and was strongest just before the bifurcation of the two bronchi. Watson [46] described the tracheal septum as being present in Procellariidea, but not in the Southern rockhopper penguin *Eudyptes chrysocome* or the little penguins *Eudyptula minor*. Zeek [47] investigated the vocal apparatus of African penguins and confirmed the presence of the septum calling it a “double trachea”. Despite the presence in some penguin species, king and emperor penguins have been reported to “appear” to have no tracheal septum [48]. However, Davenport and colleagues also suggested that penguins’ tracheae need to be studied more thoroughly to draw conclusions on the functional adaptation of a tracheal septum.

Here, we present the detailed anatomy of the entire vocal tract of king penguins, who have previously been reported to use two-voiced sound production [38]. We describe syringeal skeleton, soft tissues and cartilaginous parts using high-resolution micro-computed tomography (μ CT) and analyse structural elements in three-dimensional (3D) reconstructions.

Results

Vocal tract anatomy

We find no major differences in the overall anatomical structure of vocal tracts between male and female king penguins. Therefore, the anatomical features described subsequently are only shown exemplarily in one of the two sexes.

The king penguin has a bronchial syrinx (Figure 1A), with a medial labium and a medial tympaniform membrane (MTM) as vibratory tissues (Figure 1A, B). The vascularization in the medial labium was considerably more prominent than in the MTM that contained almost no macroscopically visible blood vessels (Figure 1A, left side). Each primary bronchus has a total of 22 rings of different shapes and tissue types (Figure 1B). Beginning at the bifurcation the bronchial rings B1-B6 are ossified. B1-B4 superior to the labia are full rings. B3 and B4 are partially fused, dorsomedially flattened and here of a comparatively large circumference. Two half-rings follow, B5 and the partially rudimentarily developed B6, which are partially fused at their free ventromedial endings. The remaining bronchial rings, B7-B22, are cartilaginous. The first four, B7-B10, are half-rings and attached to the vibratory tissues, the medial labium and the MTM. Twelve c-shaped cartilaginous rings follow up to the hilum of the lung.

The trachea is separated by a septum: septum trachealis medialis, STM (Figure 2A, B). The STM extends over 21 cm of the 27 cm long trachea ($\approx 78\%$). The STM begins at the bifurcation of the trachea and ends 6 cm below the larynx between the 94th/96th rings (Figure 2A). The septum consists mainly of soft elastic tissue, but in its caudal third contains ossified plates located at the height of the tracheal rings 6 to 21 (Figure 2B, C).

The lungs were indented dorsally by the vertebral ribs. The male trachea shows 125 partially ossified cartilaginous rings (Figure 23A). It is elastic and had a length of 27 cm in the relaxed position in both males. The trachea of both male and female king penguins was not looped but lay straight in the thorax (Figure 3B). While the overall structure of the vocal tract was the same for males and females, we found slight differences in tracheal length between the sexes (Table 1).

The tracheolateralis (TL) muscle runs alongside the trachea and attaches between the 2nd and 3rd tracheal rings, well before the skeletal elements directly connected to the vocal membranes (Figure 4A, B). The sternotrachealis (ST) muscle inserts ventrally at the lower trachea between the tracheal rings 10 and 11 (Figure 4, 4B).

3D reconstruction and analysis of the upper vocal tract, specifically of the head and throat (Figure 5), shows no particular differences or anomalies as compared to other birds [49,50] that could hint towards an adaptation for two voiced sound production. The basihyale is located at the base of the tongue and extends into the urohyale. Basihyale und urohyale are fused, with an articulated connection to the paired ceratobranchiale. The articulated connection is located at the transition of basi- and urohyale. The basihyal, urohyal, and the paired ceratobranchial and epibranchial bones are part of the hyoid apparatus [49]. The basihyal bone and urohyal bone form the paraglossale, i.e. the structure which is connected to the base of the tongue. The tongue is a rigid structure that contains dorsally lingual filiform-like papillae [51]. The epibranchial bones are arched, bilaterally paired bones that form the tip of the hyoid structure. They are connected by joints to the ceratobranchial bones. Thus, their location does not correspond to their natural position. The ossified cricoid, arythenoids and procricoid form the larynx.

The two male specimens had a shorter overall trachea length while the females had a smaller overall trachea width (Table 1). For the four specimens, the trachea width increased from caudal to cranial on average by 16%. Length of left and right ML differs consistently between all individuals with no obvious side dominance. The length difference between right and left ML appears to be larger in females than in males (Table 1).

Table 1: Size measurements of two male and two female vocal tracts.

Sex	Trachea length (mm)	Diameter Trachea caudal end (mm)	Diameter mid Trachea (mm)	Diameter Trachea cranial end (mm)	Right ML length (mm)	Left ML length (mm)	Δ ML (mm)
Male 1	270	17.6	21.9	23.0	19.3	19.1	0.2
Male 2	270	18.9	21.6	21.0	20.6	20.5	0.1
Female 1	295	18.6	20.0	21.1	19.7	19.5	0.2
Female 2	275	18.2	19.6	20.5	18.4	19.0	0.6

ML=medial labium. The total trachea length is reported as well as trachea diameters measured at three points. Delta ML is the difference between right ML and left ML.

Call analyses

Male and female king penguins differ significantly in the frequency bandwidth of the two voices (Welch's *t*-test, *t*, Table 2). We find the bandwidth between the fundamental frequencies of the first and the second voice, i.e. FO_1 and FO_2 , to be consistently higher for female king penguins with 49.0 ± 12.9 than for males with 40.3 ± 11.5 . This appears to be in consistency with the larger offset in ML size for female king penguins. There were no sex differences between FO_1 and FO_2 (Table 2). For the individual recognition process in king penguins, both the frequency modulation of the call and the beats generated by the interaction of FO_1 and FO_2 are equally

important [41]. A smaller frequency bandwidth generates a longer beat period. Consequently, males had a significantly longer period of beats than females (Table 2).

Table 2: Measurements and statistical comparison of the two voices of male and female king penguin calls.

Variable	Males (n=42)	Females (n=19)	P-value	DF	t-value
FO ₁ [Hz]	423.23 ± 54.57	439.18 ± 41.66	0.217 n.s.	44.91	1.25
FO ₂ [Hz]	463.48 ± 55.59	488.18 ± 45.90	0.07 n.s.	41.74	1.82
Frequency bandwidth FO ₂ [Hz] - FO ₁ [Hz]	40.25 ± 11.54	49.00 ± 12.87	0.011*	59.00	2.62
Period of Beats (1/ frequency bandwidth) [s]	0.027 ± 0.007	0.022 ± 0.006	0.009**	38.01	-2.76

Mean ± standard deviation and results of Welch's t-tests comparing the first (FO₁) and the second voice (FO₂) between males and females. The bandwidth did not follow a normal distribution and we thus performed a generalized linear model with a gamma transformation.

Discussion

We hypothesize that the ritualized calling position of King penguins (Figure 7A), during which they do not move, results in the stability of the vocal output, i.e. the stereotypy of the frequency of the two voices. A similar conclusion was drawn by [35] for African penguins. Using endoscopic imaging in living birds, Goller and Larssen [21] observed that the phonation process in two songbird species was preceded by the contraction of the TL muscles leading to an upward movement of the syrinx and consequentially, the bronchial half-rings were pulled apart and the vibratory tissues stretched. It is possible that a similar mechanism is used by king penguins. Additionally, contraction of the TL would pull the ossified plates of the STM closer together causing the STM to stiffen. Furthermore, the calling position, i.e. stretching and pointing the beak upwards (Figure 6A) enhances the propagation of the call in the crowded and noisy colony [52,53]. The increased tracheal diameter from caudal to cranial likely increases the overall amplitude of the produced sound and therefore improves the chances to be heard by the target conspecific. We, therefore, hypothesize that this calling position has evolved to enhance signal propagation and does not serve size exaggeration [54].

The key feature that allows both male and female king penguins to produce two simultaneous fundamental frequencies is their bronchial syrinx type. Using a mechanical model of the avian syrinx, Elemans et al. [58] showed that the fundamental frequency of the vocal output highly correlates with the fundamental oscillation frequency of the vibrating membrane. In general, the membranes' fundamental frequency is determined by the elastic properties, size and tension of the membranes [20,57]. Düring et al. [20] showed that increasing the length of the medial labia in various directions through muscle activation results in higher fundamental frequencies. Given the absence of intrinsic syringeal musculature, the frequency bandwidth in the king penguins beat, i.e. the offset between the two voices (FO₁-FO₂), is most likely determined through

the different sizes of the vibratory tissues on each side of the syrinx. Lateralization of the syrinx as the source of acoustic features has been proposed in numerous studies [29,57–59]. Albeit the small sample size, our size measurements suggest a larger lateralization in females, which appears to be consistent with a larger beat bandwidth. The exact role of the extrinsic ST and TL muscle remains unclear, however, it is possible that the activation of the TL leads to passive stretching of the vibratory tissues and thus also influences the two-voice frequencies [60]. Future *ex vivo* studies [9] or biomechanical models based on tissue properties [17,61] would be necessary, to reveal the precise mechanism and control possibilities of the two voices of king penguins.

The size, location and type of tissue of the STM suggests some impact on the vocal output as well. The STM could, for example, play an important role in keeping the two independently produced sounds separated until the cranial end of the trachea. Therefore, it might allow or enhance the psychoacoustic recognition of the two synchronously produced voices. Favaro et al. (35) used computational models of African penguin vocal tracts and showed that the difference between air resonance in a single versus a two-tube model was related to a variation in formant position and dispersion. However, the authors simplified their model assuming that “the trachea is divided by a septum for all its length”, which is not the case, neither in African [47] nor in king penguins. Still, formant frequencies have been shown to be individually distinct and might encode individual identity, e.g. in African penguins [36] and in corncrakes *Crex crex* [62]. While the king penguin display call does not exhibit clear resonances (formants), it is still possible that the septum has an influence on the spectral separation of the two voices. However, given that a tracheal septum has also been reported for other aquatic species, one should consider that it might have originally evolved for a different, non-acoustic function. For example, a recent study conducted by Ponganis et al. (64) concerned the adaptation of lungs and air sacs of Adélie *Pygoscellis Adeliae*, king and emperor penguins for baroprotection. They performed computer-tomographic scans on alive birds, subsequently segmented the lungs, air sacs and trachea, and determined individual body densities and lung/air sac and body volume. They did not analyse the anatomy of the different structures in detail, yet, the 3D reconstructions allowed for a better understanding of the location of the different structures of interest. Ponganis et al. (64) concluded that diving penguins probably reduce the air volume of the parabronchial, tracheobronchial and lung air spaces through compression or muscle constriction or blood engorgement to prevent pulmonary barotrauma. Structures that are involved in a communication system and in signal production often already underwent adaptations related to other behaviours or environmental conditions. The trachea and the connected structures are used for breathing and therefore need to be adapted to high external pressures, which might

have led to the development of the STM. However, the lack of an STM in other deep diving species [64,65] points against it as having a primarily baroprotective function. An alternative explanation for the presence of an STM was given by Davenport et al. (50). They reported a tracheal septum in leatherback turtles, which divides about 60% of the trachea into two lumina. The authors suggested that it might be an adaptation to allow simultaneous feeding and breathing. If the animal captures prey and subsequently comes to the surface to breath, food items will still pass through the lower part of the oesophagus. The tracheal septum might play a vital role in preventing the compression of the lower part of the trachea caused by the food-filled oesophagus in this situation and hence might facilitate breathing.

Tracheal septa have further been reported to be present in little penguins [66], African penguins [36], dugongs *Dugong dugon* [47], and leatherback turtles *Dermochelys coriacea* [48]. Reports on leatherback turtle and dugong vocalisations are scarce and provide little or no evidence for individual vocal signatures (leatherback turtles [67,68], dugongs [69]). Convincing evidence for two voices is thus only available for King penguins and African penguins (McInnes et al. 2018). King penguins can dive up to 343m depths [70] and therefore experience high pressure (34.5 bar under standard atmospheric conditions at 343m in saltwater) to which their bodies, including their respiratory tract, must be adapted. A study on Magellanic penguins *Spheniscus magellanicus* suggested that not only prey capture but also ingestion happen underwater, followed by breathing at the surface [71]. Hence, the STM could also assist in preventing the collapse of the trachea while penguins ingest prey items at deep depths.

Conclusion

Male and female King penguins do not differ substantially in basic anatomical features of the vocal tract. Both sexes possess a bronchial type syrinx allowing for the simultaneous production of the two voices featured in the king penguins characteristic display calls. The difference in size between left and right labia results in an offset between the two fundamental frequencies, i.e. the beat that encodes for individuality in Aptenodytes. The STM separating the trachea into two lumina may further favour the production or psychoacoustic recognition of the two voices. The increased diameter from caudal to cranial in connection with the calling position adopted by king penguins during vocalising is likely an adaptation to improve the propagation of this important signal of individuality in the environment of a noisy seabird colony.

Methods

Sample collection

Specimens (n=4) were collected in “La Grande Manchotière” king penguin colony between November 2015 and April 2016. Vocal tracts were dissected from two male and two female individuals that were most likely freshly deceased from predation. While the exact age of the birds is unknown, plumage coloration indicates that all individuals were adults, i.e. at least four years or older. Sex was determined for all birds through macroscopic identification of the gonads during dissection, following Hocken [66]. Vocal tracts were removed *in toto*, i.e. head (without the orbital region, brain case and brain), beak, tongue, hyoid bones, trachea, syrinx, lungs and attached muscles as one connected structure (**Figure 3B**). Vocal tracts were stored in 4% phosphate-buffered Paraformaldehyde (PFA) solution at +4°C.

Ex vivo measurements

Tracheal diameter was measured at three different levels, (i) cranial just below the larynx, (ii) the middle of the trachea and (iii) caudal just above the bronchial bifurcation. Tracheal length was measured between the bronchial bifurcation and the last tracheal ring just below the larynx. Width measurements of medial labia were taken at the inside of bronchial bone B7. All measurements were performed *ex vivo* on fixed vocal tracts.

Soft tissue counterstaining and sample preparation for Micro-computed tomography

To visualize soft tissues [72,73], the syrinx of a female and the entire vocal tract of a male and a female specimen were counterstained with 10% Lugol's solution (Sigma Aldrich, St. Louis, MO, USA) for up to 7 days. Lugol's solution was replaced every two days until the iodine coloration of the staining liquid remained stable. To prevent samples from moving during image acquisition we prepared customized polystyrene forms for each sample. Forms were prepared to fixate each sample in a position resembling *in vivo* positioning as close as possible. Each form and the containing sample were subsequently placed in separate PMMA (Polymethyl methacrylate) tubes for μ CT scanning. Prior to scanning, we added a few ml of water to the tubes to prevent interference due to changes in humidity caused by x-ray related temperature fluctuations.

Micro-computed tomography

Scans were performed using a Phoenix nanotom m cone beam CT scanner (GE Measurement and Control, Wunstorf, Germany). Scans for the entire vocal tracts were conducted using three slightly overlapping field of views (FOV), each acquiring 1600 projections during a 360° rotation

at a voltage of 120 kV and 100 mA current. The female syrinx dataset was acquired as one individual FOV scan with the same settings. All scans were performed using a tungsten (“standard”) target with an additional 0.1 mm aluminum filter. Voxel size of the female syrinx was 0.04 μm and of the male syrinx 0.05 μm .

Visualization and analysis of μCT data

Micro-CT raw data were reconstructed and filtered using the software phoenix datosix 2 (GE Sensing & Inspection Technologies GmbH, Germany). Subsequently, they were cropped and converted to 8bit using VGStudio MAX 2.2 (Volume Graphics, Heidelberg, Germany) Stitching of multiple data sets, threshold based 3D renderings and manual annotations of the μCT data was performed with Amira 6.0.1 (FEI Visualization Sciences Group, Burlington MA, USA), following the protocol of Ruthensteiner and Hess [74].

Call recordings and analyses

King penguin vocalisations were recorded in “La Grande Manchotière” king penguin colony (approx. 16 000 breeding pairs [75]), in the Baie du Marin (BDM) at Possession Island, Crozet Archipelago (46°25’S, 51°45’E) between November 2015 and April 2016. Display calls of 42 males and of 19 females were recorded using an omnidirectional Sennheiser K6-me62 microphone (frequency response: 20 - 20000 Hz \pm 2.5 dB) mounted on the end of a 2 m rod held by a human observer and connected to a Marantz PMD 661 digital recorder (frequency response: 20 Hz-24 kHz \pm 1 dB, sampling frequency: 44.1 kHz), the microphone being at approximately 1 m distance from one side of the bird’s beak.

In calling, king penguins adopt a particular posture: they raise their beaks slowly to a vertical position and stretch their necks to the fullest extent and then emit a call (**Figure 6A**). This posture limits signal-to-noise ratio reduction caused by the screening effect of the bodies of the birds gathered in dense flocks in the breeding areas [76].

The display call is highly stereotyped within individuals and highly variable between individuals. For mate or parent identification, king penguins perform a complex analysis of the call, using both frequency modulation and the beat pattern of the two-voice [42]. We measured the overall frequency of the two fundamentals and of their difference in frequency in syllables of males and females. As display calls of king penguins are highly redundant, consisting of successive syllables with a repetition of the same individual information many times (one syllable is sufficient to elicit recognition; [77], our frequency measurements were taken on the first syllable only, in a 0.1 s time window of the syllable (see **Figure 6B, C**).

Signals were analysed using Avisoft SASLab Pro (version 5.2.09, [78]) and down-sampled prior to analysis to 22.05 kHz and high-pass filtered at 0.20 kHz to remove the background noise. Frequency measurements of the two fundamentals F_{01} and F_{02} were done on the spectrum (FFT length of 1024, Blackman window). In cases where we had recorded and measured the two voices of more than one call ($N_{\text{females}}=12$, $N_{\text{males}}=28$), the measurements were averaged for each individual. We analysed the two-voice frequencies for a total of $N=42$ males and $N=19$ females. To compare two-voice measurements between the sexes, we performed (1) Welch's t -tests on the first (F_{01}) and second (F_{02}) voices and on the beats, i.e. $1/(F_{02} - F_{01})$, and (2) a generalized linear model (family = gamma) on the non-normally distributed frequency bandwidth, i.e. $F_{02} - F_{01}$.

Figures

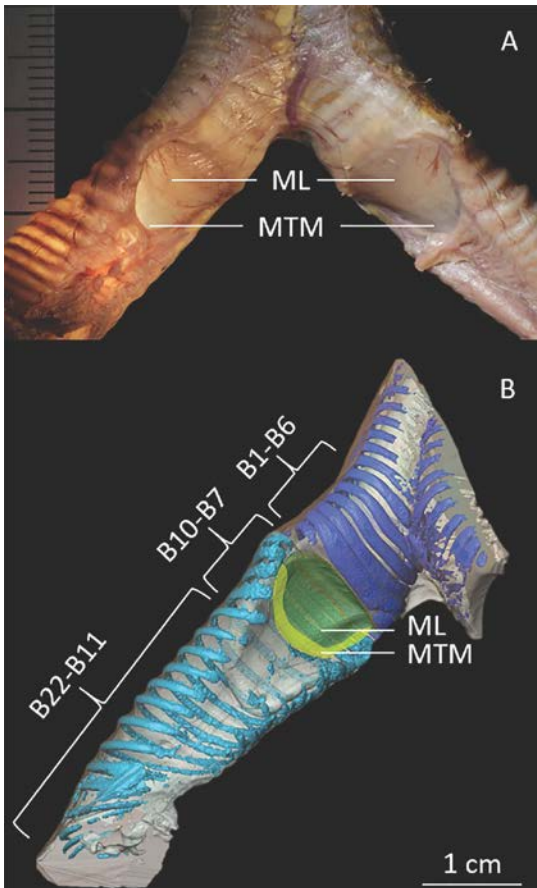


Figure 1: Syrinx anatomy of the king penguin.

A: Ex vivo image of a male king penguin's syrinx at the bifurcation of the trachea in the two primary bronchi (dorsal view). Internal illumination of the left bronchus reveals the pronounced vasculature of the medial labium.

B: Digital reconstruction of the right bronchus showing osseous tracheal rings and osseous (dark blue) and cartilaginous (light blue) bronchial rings surrounding the vibratory membranes B1-B5 are completely ossified bronchial full rings, while B6 is a c-shaped half rings. B7-B22 are c-shaped cartilaginous half rings. B5-BB11-B22: C-shaped cartilaginous rings of the main bronchus.

Figure 2: King penguin trachea and septum trachealis medialis (STM) separating the trachea into two lumina.

A: Ex vivo image of the upper vocal tract of a male king penguin. The right side of the trachea is removed and put aside to expose the medial septum. The STM originates at the bifurcation of the trachea into the two primary bronchi and stretches to the 94th/96th tracheal ring, 6 cm below the larynx. Tracheal rings are numbered 1-125.

B/C: 3D reconstructions of trachea, syrinx and bronchi showing different densities of the trachea and STM. Blue indicates ossified tracheal and bronchial rings. Yellow depicts ossified plates within the connective tissue (grey) of the tracheal septum.

B: Craniocaudal view into the double lumen trachea showing the STM separating the two tracheal tubes and the irregular ossified plates (yellow) segmentally lined up within the septum.

C: Lateral view of the trachea and the ossified plates of the STM.

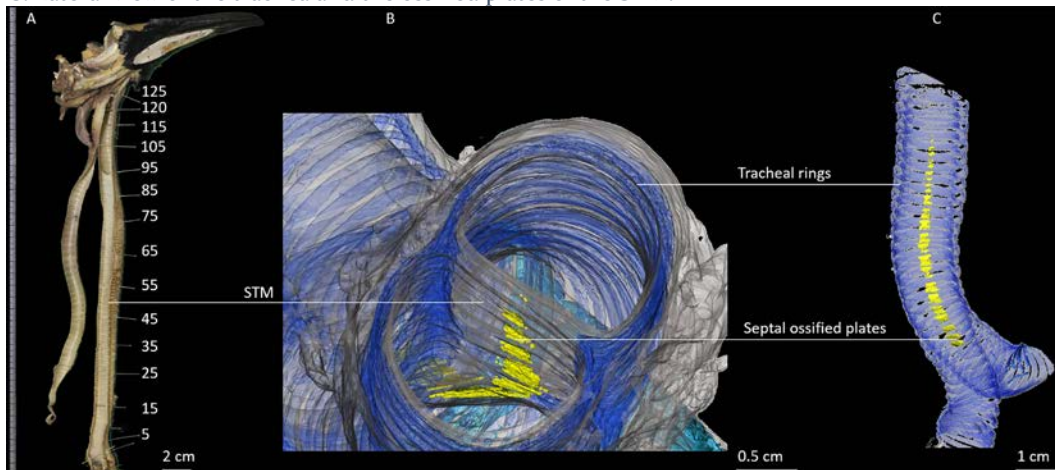


Figure 3: General anatomical structure of the king penguin vocal tract.

A: Photograph of a male adult king penguin with a schematic drawing of the vocal tract to illustrate its location in the body.

B: *Ex vivo* image of the entire vocal tract of a male king penguin including beak, upper respiratory tract, trachea, syrinx, lower respiratory tract with main bronchi and lungs. White box indicates the position of the bronchial type syrinx. (R = right, L = left).

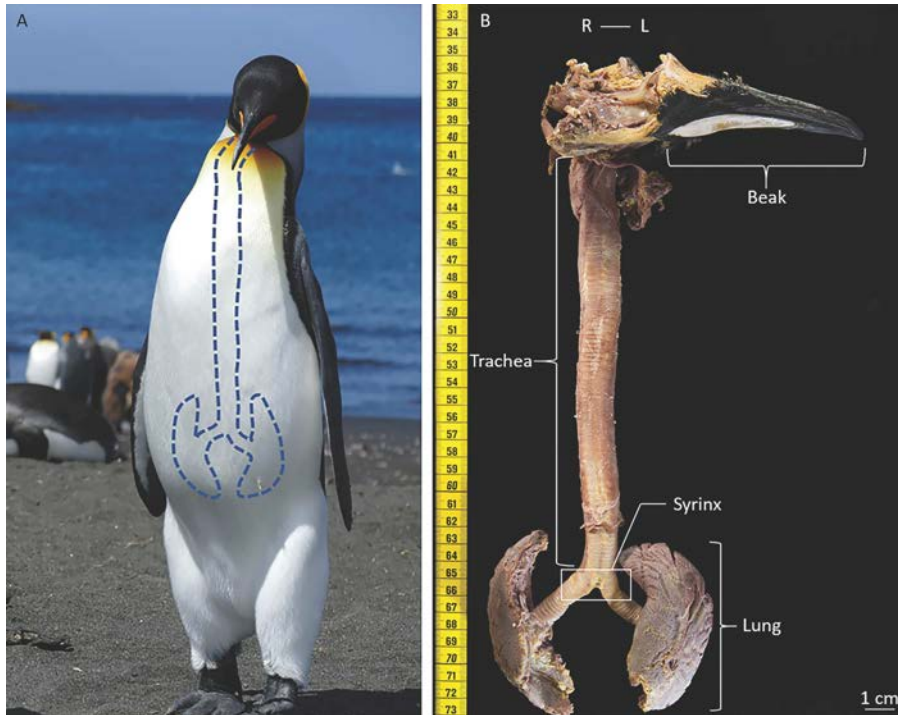


Figure 4: Syrinx location in situ and connected structures of a male king penguin.

A: Craniodorsal view in situ: the sternum is lifted upwards. The right tympaniform membrane is covered by the right lateral side of the right bronchus. Note that the heart has been removed to allow better visibility of the bronchi.

B: Ventral view of the syrinx. ST = Sternotracheal muscles, TL = Tracheolateral muscles.

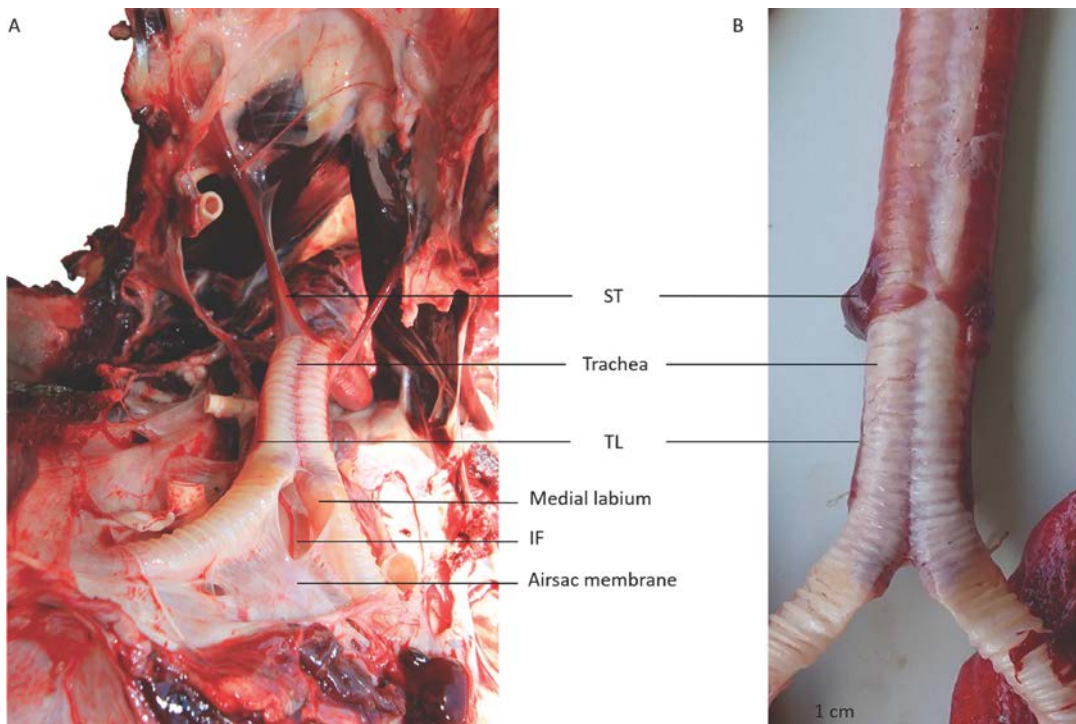


Figure 5: Views of the skull and the upper vocal tract (rostral side) of a male king penguin.

A: Skull, tongue, hyoid, larynx and upper trachea seen from laterocaudal, left side.

B: Craniocaudal view of the hyoid apparatus and the larynx. Note that both ceratobranchial bones are fractured and both epibranchiale, connected through joints with the ceratobranchiale in the living bird, were dislocated in this specimen. At the left edge of the figure the tip of the beak is missing due to limitations of the physical space in the CT-scanner.

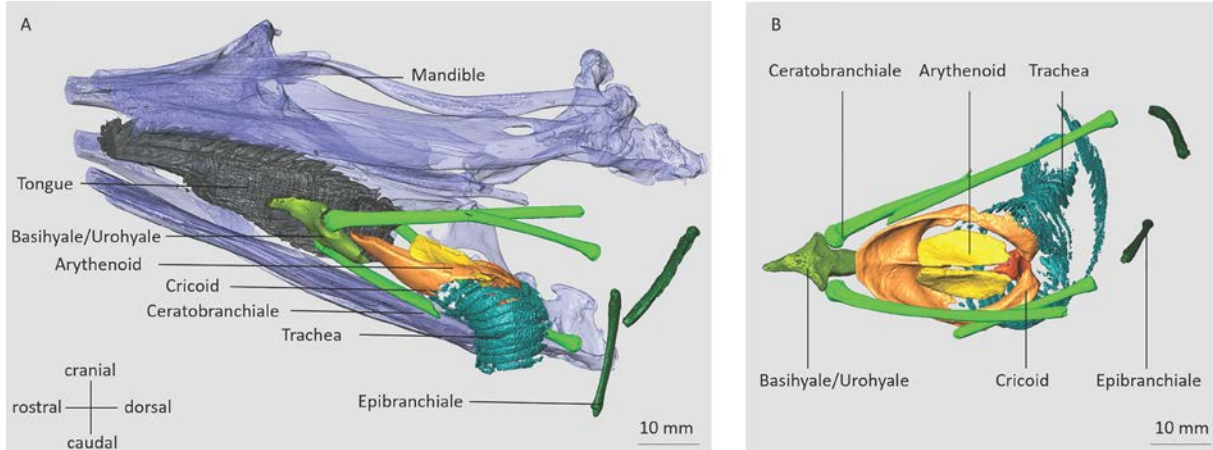


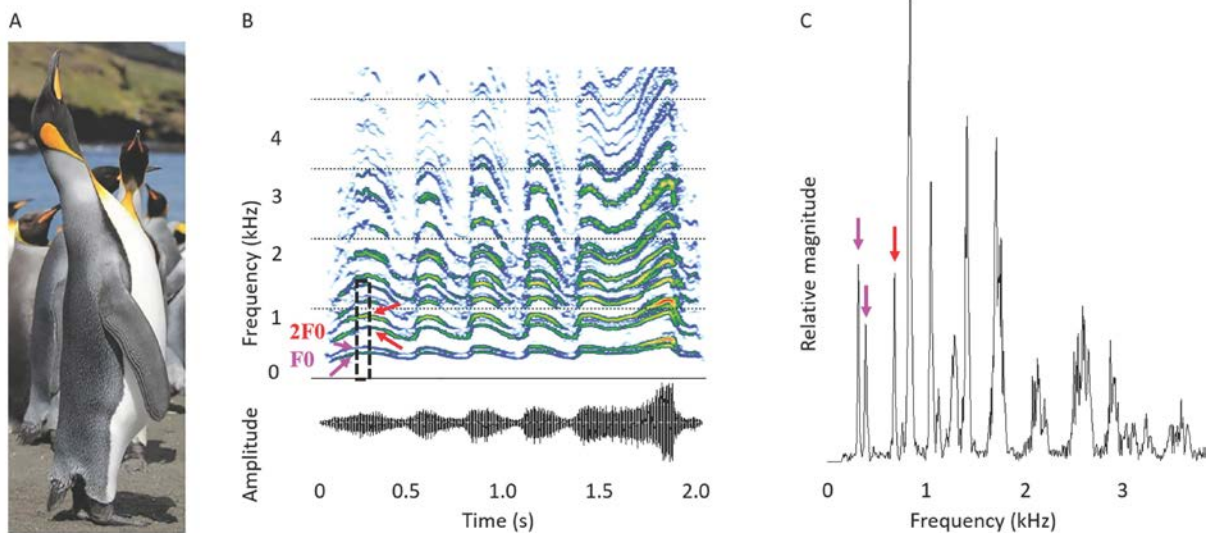
Figure 6: Body postures of a calling king penguin and a male call's spectrogram and power spectrum indicating the two voices.

A: Adult king penguin in the typical calling position emitting a call.

B: Spectrogram (FFT length 1024, 98.43% overlap, Blackman window) of an adult male king penguin call. Below the oscillogram of the call.

C: Amplitude spectrum of the call section marked with a dotted rectangle in B (duration: 0.1s).

B and C: F_0 = Fundamental frequency (first harmonic), $2F_0$ = Second harmonic. The pink and the red arrows indicate the two-voices for F_0 and $2F_0$, respectively.



Declarations

Acknowledgements

This study was supported by the Institut Polaire Français Paul-Emile Victor (IPEV) within the framework of the Programmes I37, by the Centre Scientifique de Monaco (CSM) through budget allocated to the Laboratoire International Associé 647 *BioSensib* (CSM//Institut Pluridisciplinaire Hubert Curien CNRS-University of Strasbourg) and by the Centre National de la Recherche Scientifique (CNRS) (Programme Zone Atelier de Recherches sur l'Environnement Antarctique et Subantarctique). This study was approved by the Ethics committee of IPEV. We thank the workshop in Seewiesen for providing the customized PMMA tubes for μ CT scanning. We are thankful to Werner Kriesell for taking the ex-vivo photos in Figure 1, 2 and 3.

Data availability

The datasets used and/or analyzed during the current study are available from the corresponding authors on reasonable request.

Competing interests

The authors declare that they have no competing interests.

Authors contributions:

HJK, CLB, MG, TA & DND conceived of the study. HJK & JPR collected tissue and sound data. HJK, MH, AFC, BR & DND contributed to tissue preparation and CT-scanning. BR, MG, TA & DND provided material. HJK & DND analysed all data. HJK & DND wrote the manuscript. All authors read and approved the final version of the manuscript

References

1. Ames PL. The morphology of the syrinx in passerine birds. Vol. 37, Yale Peabody Museum Bulletin. 1971. 194 p.
2. Greenwalt C. H. Bird Song: Acoustics and Physiology. Washington, DC: Smithsonian Press; 1968. 194 p.
3. Casey RM, Gaunt AS. Theoretical models of the avian syrinx. J Theor Biol. 1985;
4. Düring DN, Ziegler A, Thompson CK, Ziegler A, Faber C, Müller J, et al. The songbird syrinx morphome: A three-dimensional, high-resolution, interactive morphological map of the zebra finch vocal organ. BMC Biol. 2013;11:1.
5. Gaunt AS. An hypothesis concerning the relationship of syringeal structure to vocal abilities. Auk. 1983;100(October):853–62.

6. King AS. Functional anatomy of the syrinx. In: King AS, McLelland J, editors. *Form and Function in Birds*. 4th ed. New York: Academic Press; 1989. p. 105–92.
7. Larsen ON, Goller F. Direct observation of syringeal muscle function in songbirds and a parrot. *J Exp Biol*. 2002;
8. Riede T, Goller F. Peripheral mechanisms for vocal production in birds - differences and similarities to human speech and singing. *October*. 2011;115(1):69–80.
9. Elemans CPH, Rasmussen JH, Herbst CT, Düring DN, Zollinger SA, Brumm H, et al. Universal mechanisms of sound production and control in birds and mammals. *Nat Commun*. 2015;6.
10. Huxley TH. *A manual of the anatomy of vertebrated animals*. D. Appleton and company. New York: Appleton; 1872. 442 p.
11. Titze IR. The physics of small-amplitude oscillation of the vocal folds. *J Acoust Soc Am*. 1988;83(4):1536–52.
12. van den Berg J. Myoelastic-Aerodynamic Theory of Voice Production. *J Speech Lang Hear Res*. 1958;1(3):227.
13. Story BH. Mechanisms of Voice Production. In: Redford MA, editor. *The Handbook of Speech Production*. John Wiley & Sons, Inc.; 2015.
14. Elemans CPH, Spierts ILY, Müller UK, Van Leeuwen JL, Goller F. Superfast muscles control dove's trill. *Nature*. 2004;
15. Elemans CPH, Mead AF, Rome LC, Goller F. Superfast vocal muscles control song production in songbirds. *PLoS One*. 2008;
16. Elemans CPH. The singer and the song: The neuromechanics of avian sound production. Vol. 28, *Current Opinion in Neurobiology*. 2014. p. 172–8.
17. Düring DN, Knörlein BJ, Elemans CPH. In situ vocal fold properties and pitch prediction by dynamic actuation of the songbird syrinx. *Sci Rep*. 2017;
18. Riede T, Goller F. Peripheral mechanisms for vocal production in birds - differences and similarities to human speech and singing. *Brain Lang*. 2010;115(1):69–80.
19. Miskimen M. Sound Production in Passerinc Birds. *Auk*. 1951;68:493–504.
20. Larsen ON, Goller F. Role of syringeal vibrations in bird vocalizations. *Proc R Soc B Biol Sci*. 1999;

21. Goller F, Larsen ON. A new mechanism of sound generation in songbirds. *Proc Natl Acad Sci*. 1997;94:14787–91.
22. Düring DN, Elemans CPH. Embodied Motor Control of Avian Vocal Production. In: Suthers RA, Fitch TW, Fay RR, Poppers AN, editors. *Vertebrate Sound Production and Acoustic Communication*. 2016. p. 119–57.
23. Ohms VR, Snelderwaard PC, ten Cate C, Beckers GJL. Vocal tract articulation in zebra finches. *PLoS One*. 2010;5(7).
24. Beckers GJL, Nelson BS, Suthers RA. Vocal-Tract Filtering by Lingual Articulation in a Parrot. *Curr Biol*. 2004;14:1592–7.
25. Hoese WJ, Podos J, Boetticher NC, Nowicki S. Vocal tract function in birdsong production: experimental manipulation of beak movements. *J Exp Biol* [Internet]. 2000;203:1845–55. Available from: <http://www.ncbi.nlm.nih.gov/pubmed/10821742>
26. Suthers RA. How birds sing and why it matters. *Nature's Music Sci Birdsong*. 2004;272–95.
27. Suthers RA. Peripheral vocal mechanisms in birds: Are songbirds special? *Netherlands J Zool*. 2001;51(2):217–42.
28. Suthers RA. Contributions to birdsong from the left and right sides of the intact syrinx. *Nature*. 1990;347:473–7.
29. Suthers RA, Zollinger SA. From brain to song: The vocal organ and vocal tract. *Neurosci Birdsong*. 2008;(January 2008):78–98.
30. Goller F, Suthers RA. Role of syringeal muscles in gating airflow and sound production in singing brown thrashers. *J Neurophysiol*. 1996;
31. Prince B, Riede T, Goller F. Sexual dimorphism and bilateral asymmetry of syrinx and vocal tract in the European starling (*Sturnus vulgaris*). *J Morphol*. 2011;
32. Riede T, Goller F. Functional morphology of the sound-generating labia in the syrinx of two songbird species. *J Anat*. 2010;216:23–36.
33. Miller B, Miller DB. Two-voice phenomenon in Birds: Further evidence. *Auk*. 1977;94:567–72.
34. Krakauer AH, Tyrrell M, Lehmann K, Losin N, Goller F, Patricelli GL. Vocal and anatomical evidence for two-voiced sound production in the greater sage-grouse *Centrocercus urophasianus*. *J Exp Biol*. 2009;

35. Favaro L, Gamba M, Alfieri C, Pessani D, McElligott AG. Vocal individuality cues in the African penguin (*Spheniscus demersus*): A source-filter theory approach. *Sci Rep*. 2015;
36. Favaro L, Gamba M, Gili C, Pessani D. Acoustic correlates of body size and individual identity in banded penguins. *PLoS One*. 2017;
37. Gamba M, Friard O, Giacoma C. Vocal Tract Morphology Determines Species-Specific Features in Vocal Signals of Lemurs (*Eulemur*). *Int J Primatol*. 2012;
38. Aubin T, Jouventin P, Hildebrand C. Penguins use the two-voice system to recognize each other. *Proc Biol Sci*. 2000;267:1081-7.
39. Jouventin P. Visual and vocal signals in penguins, their evolution and adaptive characters. *Fortschr Verhaltensforsch*. 1982;24:148.
40. Kriesell HJ, Aubin T, Planas-Bielsa V, Benoiste M, Bonadonna F, Gachot-Neveu H, et al. Sex identification in King Penguins *Aptenodytes patagonicus* through morphological and acoustic cues. *Ibis (Lond 1859)*. 2018;
41. Lengagne T, Lauga J, Aubin T. Intra-syllabic acoustic signatures used by the king penguin in parent-chick recognition: an experimental approach. *J Exp Biol*. 2001;204:663-72.
42. Aubin T, Jouventin P. How to vocally identify kin in a crowd: The penguin model. In 2002.
43. Robisson P. Vocalizations in aptenodytes penguins : Application of the two-voice theory. *Auk*. 1992;109(3):654-8.
44. Wilden I, Herzog H, Peters G, Tembrock G. Subharmonics, biphonation, and deterministic chaos in Mammal vocalization. *Bioac*. 1988;9(3):171-96.
45. Meckel JF. Theilung der Luftröhre durch eine Scheidewand bei der Fettgans (*Aptenodytes demersa*). In: *Archiv für Anatomie und Physiologie* [Internet]. 6th ed. 1832. p. 48-54. Available from: <https://books.google.fr/books?id=dR2Lp2n-SigC&pg=PA48&lpg=PA48&dq=Theilung+der+Luftröhre+durch+eine+Scheidewand+bei+der+Fett+Gans,+Aptenodytes+demersa&source=bl&ots=iJbGPGweRg&sig=qcn8lQp75UBiFRnNlkDOJgZGKls&hl=en&sa=X&ved=0ahUKEwjTmoXtv87YAhXrCMAKHRT2A3I>
46. Watson M. *The Voyage of H.M.S. Challenger*. In: 1st ed. London: Longmans and Co.; 1885.
47. Zeek PM. Double trachea in penguins and sea lions. *Anat Rec*. 1951;111(3):327-43.
48. Davenport J, Jones TT, Work TM, Balazs GH. Unique characteristics of the trachea of the juvenile leatherback turtle facilitate feeding, diving and endothermy. *J Exp Mar Bio Ecol*.

2014;

49. Homberger DG. The avian tongue and larynx: Multiple functions in nutrition and vocalisation. In: Adams NJ, Slotow RH, editors. Proceedings of the 22nd International Ornithological Congress. Johannesburg: BirdLife South Africa; 1999. p. 94–113.
50. Casteleyn C, Cornillie P, Van Cruchten S, Van den Broeck W, Van Ginneken C, Simoens P. Anatomy of the upper respiratory tract in domestic birds, with emphasis on vocalization. *Journal of Veterinary Medicine Series C: Anatomia Histologia Embryologia*. 2018.
51. Kobayashi K, Kumakura M, Yoshimura K. Fine Structure of the Tongue and Lingual Papillae of the Penguin. Vol. 61, *Arch. Histol. Cytol.* 1998.
52. Lengagne T, Aubin T, Lauga J, Jouventin P. How do king penguins (*Aptenodytes patagonicus*) apply the mathematical theory of information to communicate in windy conditions? *Proc R Soc B Biol Sci.* 1999;
53. Lengagne T, Jouventin P, Aubin T. Finding One's Mate In A King Penguin Colony: Efficiency of Acoustic Communication. *Behaviour.* 1999;136:833–46.
54. Fitch WT. Acoustic exaggeration of size in birds via tracheal elongation: Comparative and theoretical analyses. *J Zool.* 1999;
55. Elemans CPH, Muller M, Larsen ON, van Leeuwen JL. Amplitude and frequency modulation control of sound production in a mechanical model of the avian syrinx. *J Exp Biol.* 2009;
56. Titze IR. Principles of Voice Production. 2nd ed. Iowa City: National Center for Voice and Speech; 2000. 409 p.
57. Riede T, Goller F. Morphological basis for the evolution of acoustic diversity in oscine songbirds. *Proc R Soc B Biol Sci.* 2014;
58. Suthers RA, Goller F. Motor correlates of vocal diversity in songbirds. *Curr Ornithol.* 1997;14:235–88.
59. Zollinger SA, Riede T, Suthers R a. Two-voice complexity from a single side of the syrinx in northern mockingbird *Mimus polyglottos* vocalizations. *J Exp Biol.* 2008;211:1978–91.
60. Goller F, Riede T. Integrative physiology of fundamental frequency control in birds. Vol. 107, *Journal of Physiology.* 2013. p. 230–42.
61. Elemans CPH, Zaccarelli R, Herzog H. Biomechanics and control of vocalization in a non-songbird. *J R Soc Interface.* 2008;5(24):691–703.

62. Budka M, Osiejuk TS. Formant Frequencies are Acoustic Cues to Caller Discrimination and are a Weak Indicator of the Body Size of Corncrake Males. *Ethology*. 2013;
63. Ponganis PJ, St Leger J, Scadeng M. Penguin lungs and air sacs: implications for baroprotection, oxygen stores and buoyancy. *J Exp Biol*. 2015;
64. Cozzi B, Bagnoli P, Acocella F, Costantino ML. Structure and biomechanical properties of the trachea of the striped dolphin *Stenella coeruleoalba*: Evidence for evolutionary adaptations to diving. *Anat Rec - Part A Discov Mol Cell Evol Biol*. 2005;
65. Moore C, Moore M, Trumble S, Niemeyer M, Lentell B, McLellan W, et al. A comparative analysis of marine mammal tracheas. *J Exp Biol*. 2014;
66. Hocken AG. Post-mortem examination of penguins. *Dep Conserv New Zealand, Sci Intern Ser*. 2002;65:1-25.
67. Cook SL, Forrest TG. Sounds produced by nesting leatherback sea turtles (*Dermochelys coriacea*). *Herpetol Rev*. 2005;36(4):387-90.
68. Mrosovsky N. Spectrographs of the Sounds of Leatherback Turtles. *Herpetologica*,. 1972;28(3):256-8.
69. Anderson PK, Barclay RMR. Acoustic Signals of Solitary Dugongs: Physical Characteristics and Behavioral Correlates. *J Mammal*. 1995;76(4):1226-37.
70. Pütz K, Cherel Y. The diving behaviour of brooding king penguins (*Aptenodytes patagonicus*) from the Falkland Islands: Variation in dive profiles and synchronous underwater swimming provide new insights into their foraging strategies. *Mar Biol*. 2005;
71. Wilson RP, Steinfurth A, Ropert-Coudert Y, Kato A, Kurita M. Lip-reading in remote subjects: An attempt to quantify and separate ingestion, breathing and vocalisation in free-living animals using penguins as a model. *Mar Biol*. 2002;140(1):17-27.
72. Metscher BD. MicroCT for developmental biology: A versatile tool for high-contrast 3D imaging at histological resolutions. *Dev Dyn*. 2009;
73. Metscher BD. Micro CT for comparative morphology: Simple staining methods allow high-contrast 3D imaging of diverse non-mineralized animal tissues. *BMC Physiol*. 2009;
74. Ruthensteiner B, Heß M. Embedding 3D models of biological specimens in PDF publications. *Microsc Res Tech*. 2008;
75. Delord K, Barbraud C, Weimerskirch H. Long-term trends in the population size of king

penguins at Crozet archipelago: Environmental variability and density dependence? *Polar Biol.* 2004;27(12):793–800.

76. Lengagne T, Aubin T, Jouventin P, Lauga J. Acoustic communication in a king penguin colony: Importance of bird location within the colony and of the body position of the listener. *Polar Biol.* 1999;
77. Lengagne T, Aubin T, Jouventin P, Lauga J. Perceptual salience of individually distinctive features in the calls of adult king penguins. *J Acoust Soc Am.* 2000;
78. Specht R. AVISOFT-SASLab Pro. Berlin: Avisoft Bioacoustics; 2004.