



HAL
open science

Seizure-onset patterns in focal cortical dysplasia and neurodevelopmental tumors: Relationship with surgical prognosis and neuropathologic subtypes

Stanislas Lagarde, Francesca Bonini, Aileen Mcgonigal, Patrick Chauvel, Martine Gavaret, Didier Scavarda, Romain Carron, Jean Régis, Sandrine Aubert, Nathalie Villeneuve, et al.

► To cite this version:

Stanislas Lagarde, Francesca Bonini, Aileen Mcgonigal, Patrick Chauvel, Martine Gavaret, et al.. Seizure-onset patterns in focal cortical dysplasia and neurodevelopmental tumors: Relationship with surgical prognosis and neuropathologic subtypes. *Epilepsia*, 2016, 57 (9), pp.1426 - 1435. 10.1111/epi.13464 . hal-02513966

HAL Id: hal-02513966

<https://hal.science/hal-02513966v1>

Submitted on 6 Apr 2020

HAL is a multi-disciplinary open access archive for the deposit and dissemination of scientific research documents, whether they are published or not. The documents may come from teaching and research institutions in France or abroad, or from public or private research centers.

L'archive ouverte pluridisciplinaire **HAL**, est destinée au dépôt et à la diffusion de documents scientifiques de niveau recherche, publiés ou non, émanant des établissements d'enseignement et de recherche français ou étrangers, des laboratoires publics ou privés.



Seizure-onset patterns in focal cortical dysplasia and neurodevelopmental tumors: Relationship with surgical prognosis and neuropathologic subtypes

*†Stanislas Lagarde, *†Francesca Bonini, *†Aileen McGonigal, *†Patrick Chauvel, *†Martine Gavaret, ‡Didier Scavarda, †§Romain Carron, †§Jean Régis, *Sandrine Aubert, *Nathalie Villeneuve, †Bernard Giusiano, ¶Dominique Figarella-Branger, *†Agnès Trebuchon, and *†Fabrice Bartolomei

Epilepsia, 57(9):1426–1435, 2016
doi: 10.1111/epi.13464

SUMMARY

Objectives: The study of intracerebral electroencephalography (EEG) seizure-onset patterns is crucial to accurately define the epileptogenic zone and guide successful surgical resection. It also raises important pathophysiologic issues concerning mechanisms of seizure generation. Until now, several seizure-onset patterns have been described using distinct recording methods (subdural, depth electrode), mostly in temporal lobe epilepsies or with heterogeneous neocortical lesions.

Methods: We analyzed data from a cohort of 53 consecutive patients explored by stereoelectroencephalography (SEEG) and with pathologically confirmed malformation of cortical development (MCD; including focal cortical dysplasia [FCD] and neurodevelopmental tumors [NDTs]).

Results: We identified six seizure-onset patterns using visual and time-frequency analysis: low-voltage fast activity (LVFA); preictal spiking followed by LVFA; burst of polyspikes followed by LVFA; slow wave/DC shift followed by LVFA; theta/alpha sharp waves; and rhythmic spikes/spike-waves. We found a high prevalence of patterns that included LVFA (83%), indicating nevertheless that LVFA is not a constant characteristic of seizure onset. An association between seizure-onset patterns and histologic types was found ($p = .001$). The more prevalent patterns were as follows: (1) in FCD type I LVFA (23.1%) and slow wave/baseline shift followed by LVFA (15.4%); (2) in FCD type II burst of polyspikes followed by LVFA (31%), LVFA (27.6%), and preictal spiking followed by LVFA (27.6%); (3) in NDT, LVFA (54.5%). We found that a seizure-onset pattern that included LVFA was associated with favorable postsurgical outcome, but the completeness of the EZ resection was the sole independent predictive variable.

Significance: Six different seizure-onset patterns can be described in FCD and NDT. Better postsurgical outcome is associated with patterns that incorporate LVFA.

KEY WORDS: Epilepsy, Focal cortical dysplasia, Neurodevelopmental tumors, Malformation of cortical development, Stereoelectroencephalography, Seizure onset, Epilepsy surgery, Epileptogenic zone.



Stanislas Lagarde is a resident in neurology and doctoral student in the Epileptology Department, APHM, Timone Hospital Marseille.

Accepted June 13, 2016; Early View publication July 13, 2016.

*Clinical Neurophysiology and Epileptology Department, APHM, Timone Hospital, Marseille, France; †Inserm, Aix Marseille Univ, Inserm, INS, Institut de Neurosciences des Systèmes, Marseille, France; Departments of ‡Pediatric Neurosurgery; §Functional and Stereotactic Neurosurgery; and ¶Anatomopathology, APHM, Timone Hospital, Marseille, France

Address correspondence to Fabrice Bartolomei, 264 Rue Saint-Pierre, 13005 Marseille, France. E-mail: fabrice.bartolomei@ap-hm.fr

Wiley Periodicals, Inc.

© 2016 International League Against Epilepsy

KEY POINTS

- We identified six seizure-onset patterns using visual and time-frequency analysis in focal cortical dysplasia and neurodevelopmental tumors
- We found a high prevalence of patterns that included high-frequency discharges (LVFA)
- High frequency production is not a constant characteristic of seizure onset
- Seizure-onset patterns varied according to histologic subtypes (slow patterns are almost absent in FCD type II)
- A seizure-onset pattern that included LVFA was a significant predictive variable of favorable postsurgical outcome

Malformations of cortical development (MCDs), including focal cortical dysplasia (FCD) and neurodevelopmental tumor (NDT), are important causes of chronic epilepsy in humans.^{1,2} They are often pharmacoresistant and subsequently referred for surgical consideration.^{1,3–5} The International League Against Epilepsy (ILAE) classification⁶ divides FCD into three subtypes (type I, II, and III) and nine subgroups (Ia, Ib, Ic, IIa, IIb, IIIa, IIIb, IIIc, and IIId), characterized by their cortical architectural abnormalities, the presence or not of dysmorphic ectopic neurons, and the presence or not of an associated lesion (i.e., hippocampal sclerosis). Although this new classification has improved interobserver agreement, some issues remain debated (in particular dual-pathology classification or subclassification of FCD type I).^{6,7}

NDTs are congenital lesions and represent the second most prevalent MCD, essentially represented by dysembryoplastic neuroepithelial tumors (DNETs) and gangliogliomas.⁸ They are found in about 15–30% of all operated focal pharmacoresistant epilepsy.^{8,9} They are classified in the World Health Association (WHO) Classification of the Central Nervous System as grade I tumors of neuroepithelial tissue, neuronal, and mixed neuronal-glial tumors.¹⁰ NDTs are characterized by cytoarchitectural changes that may be present in the adjacent cortex, having similarities to developmental FCDs, and these are now grouped as FCD type IIIb in the ILAE classification. However, NDTs remain difficult to classify, particularly tumors with “nonspecific” or diffuse growth patterns.¹¹

Epilepsy surgery is an efficient treatment to achieve seizure freedom in patients with MCDs. About 65% of patients are Engel class I after surgery for FCD^{7,12} and up to 80% in cases of NDTs.⁸ In the presurgical assessment of MCDs, stereo-electroencephalography (SEEG) may be required to accurately define the epileptogenic zone, guiding the delimitation of the zone to be resected.^{13–15}

Intracranial EEG seizure-onset patterns (SOPs) have long been studied.^{16–27} Some studies suggested the relevance of intracranial EEG SOP to guide successful surgical resections and estimate potential surgical outcome. Some characteristic interictal (i.e., repetitive and rhythmic spikes, polyspikes, or waves) and ictal (rhythmic activity followed by low-voltage fast activity) electrophysiologic patterns have been described in FCD.^{2,13,14,17,27} Nevertheless the association between SEEG SOP, histologic type, and surgical prognosis remains unknown in MCD.

In this study, we reviewed SEEG data from a cohort of 53 consecutive patients with pathologically confirmed FCD or NDT. Our main objective was to investigate possible associations between the SOP, histologic type, and the postsurgical outcome.

MATERIALS AND METHODS

Patient selection

Among all patients (children and adults) who underwent SEEG in our department from 2000 to 2014, we analyzed 53 consecutive patients with pathologically proven FCD or NDT. We excluded one patient in whom no seizure was recorded during SEEG. During the same period, 21 patients with magnetic resonance imaging (MRI) suggestive of and subsequently pathologically proven MCD (5 FCD and 16 NDT) were operated without SEEG exploration. In addition, 18 patients with MRI suggestive of MCD (FCD or NDT) had SEEG but were not operated, and 72 patients with negative MRI underwent SEEG of whom 42 were not operated (the main reasons being bilateral or multifocal epileptogenic zone [EZ], or/and unacceptable functional risk of the surgery).

An expert neuropathologist (DFB) reviewed data and established the pathologic diagnosis according to ILAE⁶ and WHO¹⁰ classifications. We included in this study, patients with isolated FCD type I or type II, and patients with NDT. The institutional review board of the French Institute of Health (IRB15226) approved this study.

All patients had detailed evaluation including medical history, neurologic examination, and MRI. In this study, all patients required invasive recordings after the noninvasive phase and SEEG exploration was carried out during long-term video-EEG monitoring, as part of patients' normal clinical care. SEEG was indicated when the EZ was suspected to be larger than the lesion and/or when extratemporal regions were suspected to be involved in temporal lobe seizures and/or when bilateralism was suspected.¹⁵ The placement of electrodes was selected, in each patient, based on available noninvasive information providing hypotheses about the localization of the EZ.

SEEG recordings

Recordings were performed using intracerebral multiple contacts electrodes (10–15 contacts with length 2 mm,

diameter 0.8 mm, and 1.5 mm apart; for details see Bartolomei et al.²⁸). Signals were recorded on a 256-channel Natus system. They were sampled at 256, 512, or 1,024 Hz, depending on the period of recording, and recorded on a hard disk (16 bits/sample) using no digital filter. Two hardware filters were present in the acquisition procedure: a high-pass filter (cutoff frequency equal to 0.16 Hz at -3 dB), and an anti-aliasing low-pass filter (cutoff frequency equal to 97 Hz at 256 Hz, 170 Hz at 512 Hz, or 340 Hz at 1,024 Hz).

The surgical outcome was assessed regularly during postoperative follow-up and coded according to the Engel surgical outcome classification.²⁹ For analysis, we used the surgical outcome score at the latest available follow-up.

Signal analysis

The seizure-onset SEEG pattern assessment was carried out blindly with regard to patient clinical data. Two epileptologists (SL and FBo) independently reviewed the SEEG data, without software filters, in order to determine the SOP. The SOPs were describing using visual analysis and spectral analysis (using Amadeus software; LTSI Rennes). The discrepancies were solved through consensus after discussion with a senior epileptologist (FB). The seizure onset was defined as the first change of intracranial EEG signal within the context of a sustained rhythmic discharge and subsequent appearance of clinical signs. Seizures in which clinical manifestations preceded the electrographic onset were excluded from the analysis. The seizure-onset SEEG patterns were assessed on the earliest involved electrodes. We visually assessed the contacts of electrodes inside, adjacent to, or remote from the lesion, using co-registration of pre-SEEG MRI and computed tomography (CT) with electrodes. We estimated the median discharge frequency over the first 5 seconds of the seizure (on the same contacts used to assess SOP). The EZ organization was classified as focal or network according to the number of structure(s) with high normalized epileptogenicity index (EI),²⁸ similar to our previous study.¹⁵ Focal organization corresponded to a situation where only one structure had an EI value >0.4 . Network organization was considered present in situations where at least two distinct structures disclosed an EI value >0.4 . The localization of the EZ was expressed in term of cerebral lobe.

Statistical analysis

For statistical analysis, we defined one SOP per patient. For patients with different SOP (only two patients in this series), we used the most prevalent pattern as the representative SOP.

We performed univariate statistical analysis to describe patients' features according to the SOP and the surgical outcome. The aim of these preliminary analyses was to select relevant factors for further multivariable analysis, not to conclude as to potential associations. Because of the

limited number of observations in some categories (<5), we used nonparametric tests. The Kruskal-Wallis rank-sum test was performed to analyze numerical variables, and Fisher's two-tailed exact test was used to analyze nominal variables.

To achieve our main objectives with limited effect of confounding factors and no inflation of the error-risk, we used multiple logistic regression analyses. We included in these analyses the previous factors with a p -value ≤ 0.1 on univariate analyses. We fitted one logistic regression analysis to test the predictive factors of the SOP, and another logistic regression analysis to test the predictive factors of postsurgical outcome. In these analyses, an adjusted (Bonferroni correction) p -value ≤ 0.025 was considered to be statistically significant. Statistical tests were performed with the software Statistical Package for the Social Sciences (SPSS) for Mac, version 22.

RESULTS

Patients' features

Fifty-three patients (26 women) were selected for this study. Histopathologic diagnoses were the following: FCD type I (13; FCD Ia = 7; FCD Ib = FCD Ic = 1), FCD type II (29; FCD IIa = 6; FCD IIb = 23), NDT (11; 9 DNET, 1 ganglioglioma, and 1 angiocentric glioma). The mean age at epilepsy onset was 7 years (range 0–19); the mean age at SEEG was 24.7 years (range 2.75–56) and the mean epilepsy duration before SEEG was 17.8 years (range 2–45). Forty-one patients had a visible lesion on MRI and 12 were considered to be MRI negative. Fourteen patients had a visible MRI lesion in the frontal lobe, including four patients with lesions encroaching on or close to the primary motor cortex, and one patient with a lesion involving an eloquent language area.

The localization of the EZ was frontal in 23 patients, temporal in 16, parietal in 11, occipital in 3, and 4 patients had also insular involvement (one fronto-insular, 2 parieto-insular, and one fronto-parieto-insular). The EZ organization was "focal" in 20 patients and "network" in 33 patients (examples are shown in Figs. S1 and S2). The surgical outcome was: Engel class I for 29 patients (54%), Engel class II for 8 patients (15%), Engel class III for 6 patients (5%), and Engel class IV for 10 patients (18%). The mean follow-up duration after surgery was 4.9 years (range 0.25–15). The epilepsy duration prior to SEEG was shorter in patients with NDT (median = 12.7; range = 2–38) compared to those with FCD type II (median = 17.6; range = 2.75–36) or FCD type I (median = 22.5; range = 3–45; Fig. 1A). The lobar localization of the lesion varied according to the histologic type: FCD type II were more likely to be localized within frontal lobes (18/29), and NDT were more likely to be localized within temporal lobes (8/11; Fig. 1B). Patients' features according to the histologic type are summarized in Table 1.

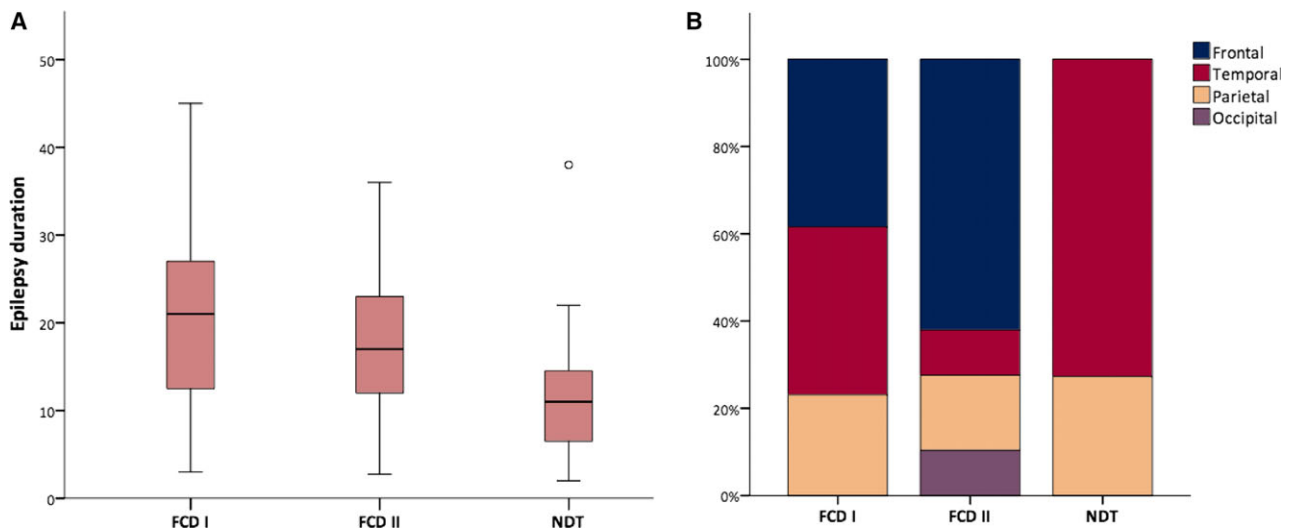


Figure 1.

(A) Epilepsy duration before SEEG according to the histologic type. The epilepsy duration is expressed in years. Empty circle represents extreme values. The horizontal solid bars represent the median. FCD, focal cortical dysplasia; DNT, neurodevelopmental tumor. (B) Lobar localization of the epileptogenic zone (EZ) according to the histologic type. Histogram represents the absolute number of patients. FCD, focal cortical dysplasia; NDT, neurodevelopmental tumor.

Epilepsia © ILAE

Table 1. Patients features according to the histologic type

	Histologic type		
	FCD I	FCD II	NDT
Patients	13	29	11
Sex (F/M)	5/8	20/9	4/7
Age at epilepsy onset (y, range)	8.8 (2–19)	6.6 (0–17)	6 (0.5–14)
Epilepsy duration (y, range)	22.5 (3–45)	17.6 (2.75–36)	12.7 (2–38)
Age at SEEG (y, range)	31.3 (8–56)	24.1 (2.75–50)	18.7 (4–40.5)
MRI lesion	8	22	11
Localization			
Frontal	5	18	0
Occipital	0	3	0
Parietal	3	5	3
Temporal	5	3	8
EZ organization (Focal/NTW)	2/11	13/16	5/6
Engel class			
I	6	19	4
II	1	4	3
III	3	2	1
IV	3	4	3
Follow-up duration (y, range)	4.8 (1–15)	4.9 (0.25–10.3)	5 (0.5–12.5)

FCD, focal cortical dysplasia; NDT, neurodevelopmental tumor; F, female; M, male; y, years; SEEG, stereoelectroencephalography; MRI, magnetic resonance imaging; EZ, epileptogenic zone; NTW, network.

For quantitative data, we expressed the median and we reported the range. Follow-up duration means after surgery.

SEEG implantation

A median of 10 electrodes were implanted per patients (range 5–13), including 26 patients with bilateral electrodes. The number of implanted electrodes did not differ between the histologic groups (median of 9 electrodes per patients with FCD type I; 10 per patients with FCD type II; and 10 per patients with NDT). The total number of electrodes was 218 electrodes in frontal lobes (median per patient 3, range 0–11); 166 electrodes in temporal lobes (median per patient 3, range 0–8); 85 electrodes in parietal lobes (median per patient 1, range 0–5); 36 electrodes in occipital lobes (median per patient 0, range 0–5); and 8 electrodes in insula (median per patient 0, range 0–2). Among the 41 patients with an MRI lesion, at least one electrode was located in the core of the lesion or in the immediate surrounding cortex.

Seizure-onset patterns

We reviewed a total of 227 seizures. We excluded 5 seizures because the clinical onset preceded the electrophysiologic onset. Therefore, we analyzed a total of 222 seizures (median per patient 3, range 1–22).

Figure 2 shows the different patterns of seizure onset. Based on both visual and time frequency analysis, we finally identified six main SOP:

- 1 Low-voltage fast activity (LVFA), with rhythmic fast oscillations >14 Hz (median frequency 36 Hz, range 14–97) starting apparently with no initial changes and with low initial amplitude <30 μ V (Fig. 2A).

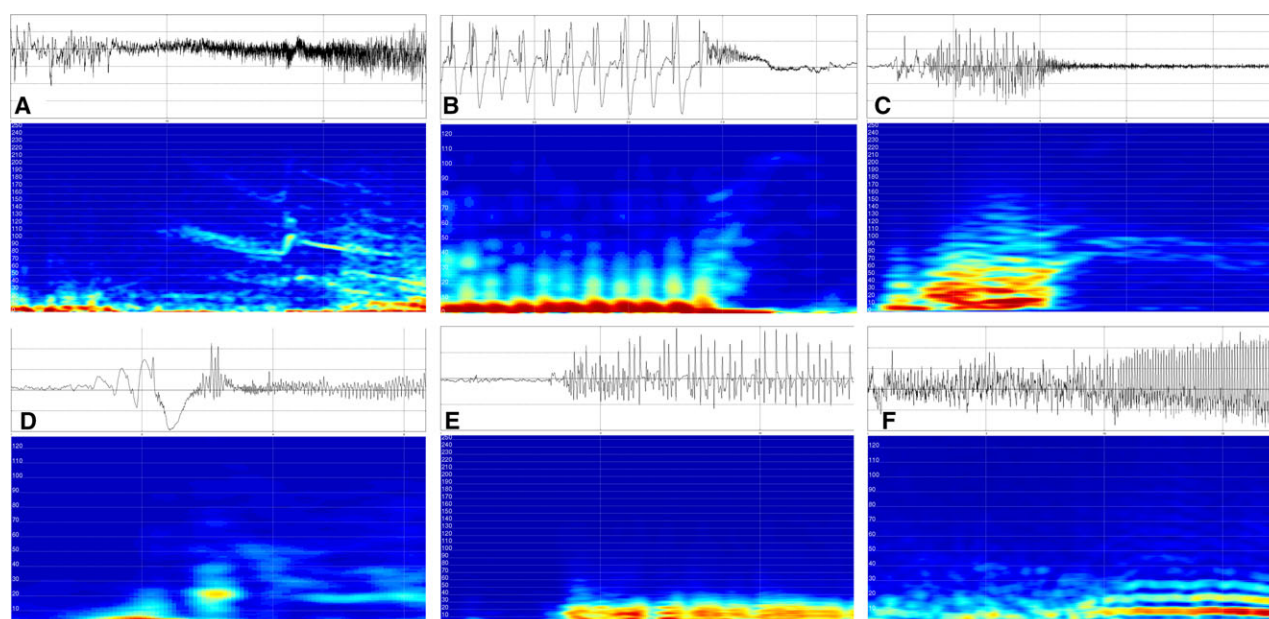


Figure 2.

The six patterns of seizure onset according to the time-frequency representation from SEEG trace. **(A)** Low-voltage fast activity (LVFA). **(B)** Preictal spiking with rhythmic spikes of low frequency followed by LVFA. **(C)** Burst of polyspikes of high frequency and amplitude followed by LVFA. **(D)** Slow wave or baseline shift followed by LVFA. **(E)** Rhythmic spikes or spike-waves, at low frequency and with high amplitude. **(F)** Theta/alpha sharp activity with progressive increasing amplitude.

Epilepsia © ILAE

- 2 Preictal spiking with rhythmic spikes of low frequency (median 1.5 Hz, range 1–3), high amplitude (median 660 μ V, range 450–1,400), prolonged duration (median 20 s, range 4–130) followed by LVFA with lower frequency than isolated LVFA (median 23 Hz, range 19.5–32; Fig. 2B).
- 3 Burst of polyspikes of high frequency and amplitude (median frequency 19.3 Hz, range 12.5–24.5, median amplitude 420 μ V, range 260–800) and short duration (median 3.3 s, range 0.5–6) followed by LVFA (median frequency 28 Hz, range 15.5–37; Fig. 2C).
- 4 Slow wave or baseline shift (median amplitude 400 μ V, range 250–500) followed by LVFA (median frequency 31 Hz, range 20–108; Fig. 2D).
- 5 Rhythmic spikes or spike-waves, at lower frequency (median 3.5 Hz, range 4–18) and with high amplitude (median 1,200 μ V, range 900–1,500; Fig. 2E).
- 6 Theta/alpha sharp activity with the lowest frequency (median 9.5 Hz, range 6–11), and progressive increasing amplitude (median 400 μ V, range 80–750; Fig. 2F).

The most prevalent patterns were, in descending order of prevalence: LVFA (pattern 1, 32.1%), followed by bursts of polyspikes (pattern 3, 18.9%), and preictal spiking (pattern 2, 17%) followed by LVFA, then SW/DC shift followed by LVFA (pattern 4, 15.1%), and then theta-alpha sharp waves (pattern 6, 11.3%) and rhythmic spikes/spike-waves (pattern 5, 5.7%). Notably, we found a remarkably high prevalence of patterns including LVFA (Fig. S3): 44 of our 53

patients analyzed (83%), which nevertheless indicates that LVFA is not a constant characteristic of these seizures.

By comparison, the seizure-onset patterns observed in the nonoperated patients (MRI suggestive of MCD or negative = 60 patients with eight patients excluded because lack of seizure or clinical onset before electrophysiologic onset) are indicated in supplementary material. Overall, the seizure-onset pattern distribution was close to that observed in operated patients. Nevertheless there was a tendency of underrepresentation of patterns 2 and 3 (preictal and burst of polyspikes prior to LVFA: 9/52 and 5/52, respectively) and overrepresentation of patterns 1 and 4 (LVFA and slow wave or baseline shift followed by LVFA: 22/52 and 12/52, respectively) in the nonoperated patients. Moreover, 25 patients were not operated because of multifocal EZ. In these patients we found similar tendency (overrepresentation of patterns 1 and 4: 10/25 and 7/25, respectively; underrepresentation of patterns 2 and 3: both 3/25).

Seizure-onset pattern and histologic type

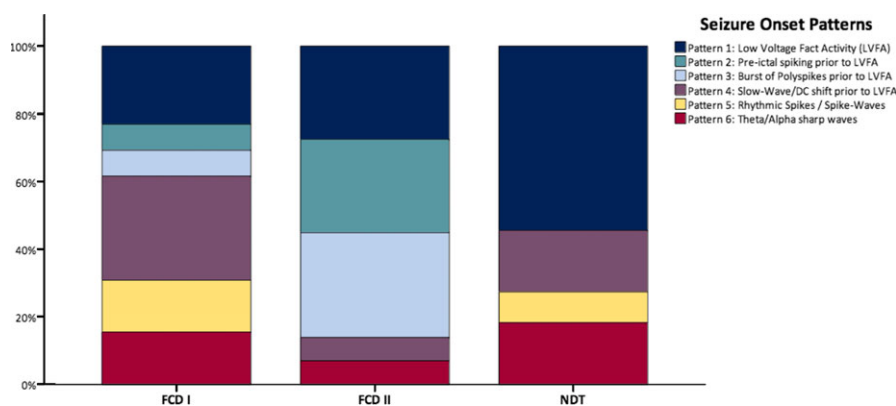
The majority of the SOP were common to all histologic types, with the exception of pattern 5 (rhythmic spikes/spike-waves) not found in FCD type II, patterns 2 and 3 (preictal spiking and burst of polyspikes followed by LVFA) not found in NDT.

Moreover, the SOP prevalence varied according to the histologic types (Fig. 3), summarized as follows:

Figure 3.

Frequency of the seizure-onset patterns according to the histologic types. The frequency is expressed in percentage of the total number of patients for each histologic type. Patterns without fast activity (5–6) are almost absent in patients with FCD type II.

Epilepsia © ILAE



- In FCD type I, the most prevalent SOP were pattern 4 (slow wave or baseline shift followed by LVFA; 4/13) and pattern 1 (LVFA; 3/13);
- In FCD type II, the most prevalent were pattern 3 (burst of polyspikes followed by LVFA; 9/29), pattern 1 (LVFA; 8/29), and pattern 2 (preictal spiking followed by LVFA; 8/29);
- In NDT, the most prevalent pattern was pattern 1 (LVFA; 6/11).

Taken as a whole, patterns with no LVFA (patterns 5 and 6: 14/53; ~25% of cases) were essentially observed in FCD type I and NDT. They were observed within the visible (or histopathologically proven) lesion, suggesting that they represent a mode of seizure onset in these cases (see Fig. S4).

We used preliminary univariate analysis to select the variables with statistical difference according to the SOP. Significant differences were found for histologic subtypes ($p = 0.01$) and epilepsy duration (shorter in pattern 6; $p = 0.02$). We did not find significant difference for the others features (for detail see Table S1).

Then we included in the multiple logistic regression analysis the following variables: histologic type, epilepsy duration, and gender. We fitted a logistic regression to test these variables as predictors of the SOP ($R^2 = 0.674$ [Cox & Snell] 0.699 [Nagelkerke] 0.335 [McFadden]; Model $\chi^2(20) = 59.476$; $p < 0.01$). We found an overall association between SOP and histologic type ($\chi^2(10) = 34.366$; $p < 0.01$) and epilepsy duration ($\chi^2(5) = 26.884$; $p < 0.01$). There was no significant association with gender ($\chi^2(5) = 10.297$; $p = 0.07$).

Surgical outcome

There was an overall significant association between the seizure-onset pattern and the postsurgical outcome (Engel class; univariate analysis, Table S2; $p = 0.04$). Best results were associated with pattern 3 (burst of polyspikes followed by LVFA). Grouping all patterns disclosing LVFA at seizure onset (patterns 1, 2, 3, and 4), we found an association with better postsurgical outcome ($p = 0.007$, 61.4% Engel class I).

A majority (40/53) of patients had complete removal of the SEEG-defined EZ. Notably no patient without complete removal of the EZ was in Engel class I. Among the patients with complete removal of EZ, the best results were observed in patients with pattern 3 (burst of polyspikes followed by LVFA; 8/9 Engel class I), pattern 2 (preictal spiking followed by LVFA; 5/6 Engel class I), and pattern 4 (slow wave or baseline shift followed by LVFA; 5/6 Engel class I; Fig. 4). The poorest results were seen in patients with pattern 5 (slow rhythmic spikes/spike-waves, no Engel class I outcome).

We first used a univariate analysis to select the variables reaching statistical difference according to the surgical outcome (see Table S2). Then we included in the multiple logistic regression analysis the following variables: EZ complete removal, and seizure-onset pattern. We fitted a logistic regression to test these variables as predictors of the probability of achieving Engel class I outcome ($R^2 = 0.658$ [Cox & Snell]; 0.727 [Nagelkerke] 0.456 [McFadden]; model $\chi^2(18) = 56.873$; $p < 0.01$). There was a significant association between Engel class and the complete removal of the EZ ($\chi^2(3) = 29.525$; $p < 0.01$). There was no significant association between Engel class and the SOP ($\chi^2(15) = 25.685$; $p = 0.04$).

DISCUSSION

The main objective of this study was to describe the SEEG SOP in FCD and NDT because no previous study has specifically investigated this relationship. We identified six different SOP and showed significant association with histologic type and postsurgical outcome.

SEEG seizure-onset patterns are mainly based on two types of activities

We describe six main intracerebral EEG SOPs: pattern 1 (LVFA), pattern 2 (preictal spiking followed by LVFA), pattern 3 (burst of polyspikes followed by LVFA), pattern 4 (slow wave/baseline shift followed by LVFA), pattern 5 (rhythmic spikes/spike-waves), and finally, pattern 6 (theta/alpha sharp activity). The patterns that we report here

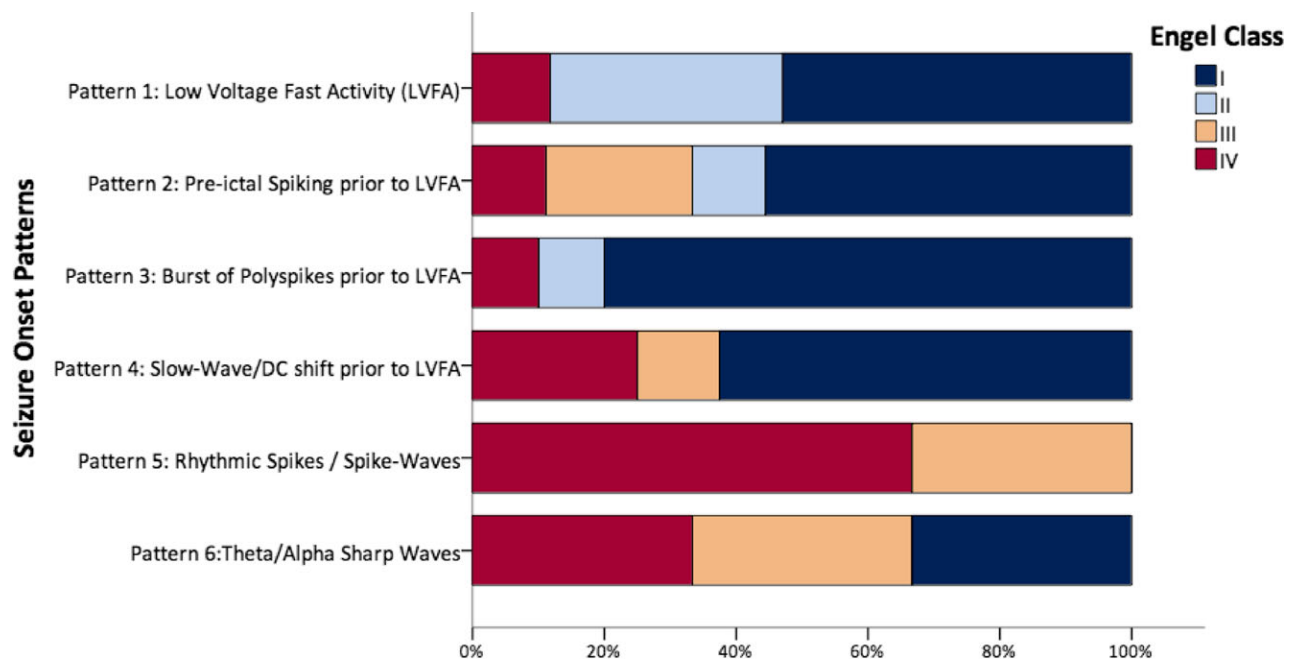


Figure 4.

Postsurgical outcome according to the seizure-onset pattern. Postsurgical outcome is based on Engel class collected at the last follow-up visit for each patient.

Epilepsia © ILAE

confirm and extend some previously described patterns (see for recent review Ref. 30). We did not find burst-suppression and delta brush patterns, two patterns recently described,²⁷ but these patterns were rare in this previous study. We also did not observe a diffuse electrodecremental pattern, which probably reflects a seizure onset not directly in the epileptogenic zone, as may occur with superficial cortical exploration (grids recording¹⁷ vs. depth electrodes in our study). Notably, we reported a significant prevalence of slow wave or baseline shift in our cohort. This pattern is well known in animal experiments and in human subdural electrode recording.³¹ A similar pattern (ictal slow wave) was also reported in temporal epilepsy using depth and subdural electrodes.³² Our data confirm that this pattern is not rare at seizure onset in human MCD-associated focal seizures.

Interestingly, SOP were not limited to fast activities; even slower activities at ictal onset (patterns 5 and 6) were rare in this etiologic context (nine patients [17%] in our series). Such patterns have been already reported in relation to seizure onset,³⁰ and it has been proposed^{20,22} to distinguish patterns including LVFA (with or without previous paroxysms) from those patterns characterized by slow rhythmic activity (theta-alpha sharp activity, rhythmic spikes/spike-waves).

One classical explanation could be that these patterns with rhythmic activities (theta/alpha activity, slow rhythmic spikes/spike-waves) are more likely than the true SOP to

represent propagated activities. It is indeed commonly observed in SEEG recordings that LVFA is observed in the EZ while slower rhythmic activity often characterizes propagation areas.²⁸ Nevertheless, we have shown here that such slow SOP can also be observed within epileptogenic lesions, essentially in FCD type I and in NDT, and may therefore represent a particular mode of seizure onset in these lesions.

This highlights the fact that intracranial SOP are crucially based on two major features (possibly associated): low voltage fast oscillations and high amplitude slow rhythmic paroxysms. Notably, these two types of oscillations have also been found frequently in animal model experimental seizures and have been proven to be a sufficient basis with which to model seizure dynamics.³³

The association between SEEG seizure-onset patterns and histologic types of MCD

We confirm the possibility for one type of histologic lesion to generate different forms of SOP, and conversely for different types of histologic lesions to generate apparently similar SOP. This fact has already been highlighted in SEEG recording²⁷ and experimental studies,^{33,34} suggesting a limited repertoire for seizure expression at least as recorded at the macroelectrode EEG level. Our main result is the existence of significant association between SEEG SOP and the histologic type of the lesion. To the best of our knowledge, this is the first report of such an association in neocortical epilepsy.

Relatively few previous studies have focused on FCD and SOP,^{13,14,17,27} all of which reported a high prevalence of LVFA. Fewer reports specifically studied FCD with depth electrodes.^{13–15,35} Depth electrodes, as used in the SEEG method, are particularly suited for studying FCD because they can capture signal change from para-sulcal and mesial areas and explore different anatomically separate sites along the same trajectory. They are particularly indicated when a larger EZ is suspected or to study the relations with eloquent cortex.⁷ Our data clearly confirm that LVFA (median frequency 36 Hz) is the most frequently observed SOP in MCD, recorded with depth electrodes. Furthermore, we reported a notably high prevalence of bursts of polyspikes and preictal spiking prior to low-voltage fast discharge in patients with FCD type II in line with a previous study focusing on SEEG aspects of FCD.¹³ Of interest, most of the recorded seizures in FCD type II included fast activity, whereas FCD type I and NDT may start by slow-onset patterns (5 and 6).

In the past, most of the previous studies dealing with SOP focused on temporal lobe epilepsy.^{19,21,24,36} They found two main patterns: LVFA and preictal spiking/synchrony,²⁴ the latter pattern being mostly associated with mesial temporal sclerosis. Although we found a lower prevalence of this pattern in our cohort, it is probable that this kind of pattern can be also observed in neocortical epilepsy and MCD.

The association between SEEG seizure-onset pattern and patient features

We also studied possible associations between SOP and patient features. We reported a significant association between the SOP and epilepsy duration (shorter in patients with seizure-onset pattern 6, theta/alpha sharp activities). This raises the possibility that LVFA could be an evolution of this pattern in some patients. Previous studies suggested an association between SOP and the extension of the seizure-onset zone. Thus, it was suggested that LVFA is associated with regional onset and low frequency rhythmic spikes with focal onset.³⁰ Moreover, an experimental study reported shorter spreading delay in cases of LVFA at seizure onset.³⁷

The presence of ictal LVFA in FCD is associated with postsurgical outcome

Previous studies explored association between SOP and postsurgical outcome, and suggested better outcome with LVFA patterns in mesial temporal and neocortical epilepsy.^{16,17,21,25,38–40} Nevertheless, these previous studies reported heterogeneous populations with regard to the neocortical lesion and used mostly subdural electrodes. We reported an overall association between the SOP and the postsurgical outcome in our patients. Then, we found that the patients with patterns including LVFA at the seizure onset had the best postsurgical outcome (Engel class I), but

this association was not significant after multivariate analysis. The completeness resection of the EZ was the strongest predictor of postsurgical outcome.

Data concerning other SOP are currently limited to a low number of patients.^{17,25,26,38} The main point is the poorer outcome associated with activities of lower frequency.³⁰ Similarly, our study suggests poorer prognosis with rhythmic spikes/spike-waves as SOP (since no patient with this pattern achieved Engel class I outcome).

In addition, two recent studies reported an association between postsurgical outcome (seizure control) and diffuse electrodecremental pattern (poorer outcome¹⁷); and delayed second ictal pattern.¹⁷ The electrodecremental pattern described was almost exclusively found with subdural electrodes. It was suggested that this diffuse electrodecremental pattern more likely reflects the extension of the seizure onset, or the associated cortical change.³⁰ Moreover, from our point of view, the latency of second ictal patterns are mostly linked to spreading of the epileptic discharge.

Study limitations

Our study has some limitations, including the low number of patients for some SOP (limiting the statistical analysis of association between one specific pattern and other patient features such as histologic type) and the limited spatial sampling inherent to the SEEG method. Therefore, further studies with larger populations would be useful to confirm these findings with better statistical testing. On the other hand, this is the first study dealing with SEEG SOP that specifically focuses on histologically proven epileptogenic neocortical lesions (FCD and NDT). We also respected some suggested methodologic precautions³⁰: independent interpretations by two EEG readers blinded to clinical data and inclusion and analysis of all consecutive patients. Furthermore, we used time-frequency analysis to help with SOP description.

CONCLUSION

Different SOP can be described in FCD and NDT using data from SEEG recordings. In MCDs, SOPs are linked to the histologic type. Patterns including LVFA are the most often observed, but slow/rhythmic activity may also be seen at seizure onset in patients with NDT and FCD type I. In FCD type II, preictal spiking or bursts of polyspikes followed by LVFA are the most frequent patterns.

ACKNOWLEDGMENTS

We thank Henry Dufour and Jean-Claude Peragut for surgical procedures in some of the selected patients. We thank Dr. Lisa Vaugier, Maxime Guye, Mathieu Milh, and Dr. Anne Lépine in clinical management for some included patients; Dr. Angela Marchi for its help in the collection of clinical data.

DISCLOSURE

None of the authors have any conflict of interest to disclose. We confirm that we have read the Journal's position on issues involved in ethical publication and affirm that this report is consistent with those guidelines.

REFERENCES

- Guerrini R, Dobyns WB. Malformations of cortical development: clinical features and genetic causes. *Lancet Neurol* 2014;13:710–726.
- Palmini A. Revising the classification of focal cortical dysplasias. *Epilepsia* 2011;52:188–190.
- Honavar M, Janota I, Polkey CE. Histological heterogeneity of dysembryoplastic neuroepithelial tumour: identification and differential diagnosis in a series of 74 cases. *Histopathology* 1999;34:342–356.
- Chassoux F, Landre E, Mellerio C, et al. Dysembryoplastic neuroepithelial tumors: epileptogenicity related to histologic subtypes. *Clin Neurophysiol* 2013;124:1068–1078.
- Krsek P, Maton B, Jayakar P, et al. Incomplete resection of focal cortical dysplasia is the main predictor of poor postsurgical outcome. *Neurology* 2009;72:217–223.
- Blumcke I, Thom M, Aronica E, et al. The clinicopathologic spectrum of focal cortical dysplasias: a consensus classification proposed by an ad hoc Task Force of the ILAE Diagnostic Methods Commission. *Epilepsia* 2011;52:158–174.
- Guerrini R, Duchowny M, Jayakar P, et al. Diagnostic methods and treatment options for focal cortical dysplasia. *Epilepsia* 2015;56:1669–1686.
- Englot DJ, Berger MS, Barbaro NM, et al. Factors associated with seizure freedom in the surgical resection of glioneuronal tumors. *Epilepsia* 2012;53:51–57.
- Damas-Duport C. Dysembryoplastic neuroepithelial tumours. *Brain Pathol* 1993;3:283–295.
- Louis DN, Ohgaki H, Wiestler OD, et al. The 2007 WHO classification of tumours of the central nervous system. *Acta Neuropathol* 2007;114:97–109.
- Thom M, Blumcke I, Aronica E. Long-term epilepsy-associated tumors. *Brain Pathol* 2012;22:350–379.
- Rowland NC, Englot DJ, Cage TA, et al. A meta-analysis of predictors of seizure freedom in the surgical management of focal cortical dysplasia. *J Neurosurg* 2012;116:1035–1041.
- Francione S, Nobili L, Cardinale F, et al. Intra-lesional stereo-EEG activity in Taylor's focal cortical dysplasia. *Epileptic Disord* 2003;5 (Suppl. 2):S105–S114.
- Chassoux F, Devaux B, Landre E, et al. Stereoelectroencephalography in focal cortical dysplasia: a 3D approach to delineating the dysplastic cortex. *Brain* 2000;123(Pt 8):1733–1751.
- Aubert S, Wendling F, Regis J, et al. Local and remote epileptogenicity in focal cortical dysplasias and neurodevelopmental tumours. *Brain* 2009;132:3072–3086.
- Holtkamp M, Sharan A, Sperling MR. Intracranial EEG in predicting surgical outcome in frontal lobe epilepsy. *Epilepsia* 2012;53:1739–1745.
- Jimenez-Jimenez D, Nekkare R, Flores L, et al. Prognostic value of intracranial seizure onset patterns for surgical outcome of the treatment of epilepsy. *Clin Neurophysiol* 2015;126:257–267.
- Kutsy RL, Farrell DF, Ojemann GA. Ictal patterns of neocortical seizures monitored with intracranial electrodes: correlation with surgical outcome. *Epilepsia* 1999;40:257–266.
- Mathern GW, Babb TL, Pretorius JK, et al. The pathophysiologic relationships between lesion pathology, intracranial ictal EEG onsets, and hippocampal neuron losses in temporal lobe epilepsy. *Epilepsy Res* 1995;21:133–147.
- Ogren JA, Bragin A, Wilson CL, et al. Three-dimensional hippocampal atrophy maps distinguish two common temporal lobe seizure-onset patterns. *Epilepsia* 2009;50:1361–1370.
- Wennberg R, Arruda F, Quesney LF, et al. Preeminence of extrahippocampal structures in the generation of mesial temporal seizures: evidence from human depth electrode recordings. *Epilepsia* 2002;43:716–726.
- Spencer SS, Guimaraes P, Katz A, et al. Morphological patterns of seizures recorded intracranially. *Epilepsia* 1992;33:537–545.
- Townsend JB, Engel J Jr. Clinicopathological correlations of low voltage fast and high amplitude spike and wave mesial temporal stereoencephalographic ictal onsets. *Epilepsia* 1991;32:21.
- Velasco AL, Wilson CL, Babb TL, et al. Functional and anatomic correlates of two frequently observed temporal lobe seizure-onset patterns. *Neural Plast* 2000;7:49–63.
- Lee SA, Spencer DD, Spencer SS. Intracranial EEG seizure-onset patterns in neocortical epilepsy. *Epilepsia* 2000;41:297–307.
- Wetjen NM, Marsh WR, Meyer FB, et al. Intracranial electroencephalography seizure onset patterns and surgical outcomes in nonlesional extratemporal epilepsy. *J Neurosurg* 2009;110:1147–1152.
- Perucca P, Dubeau F, Gotman J. Intracranial electroencephalographic seizure-onset patterns: effect of underlying pathology. *Brain* 2014;137:183–196.
- Bartolomei F, Chauvel P, Wendling F. Epileptogenicity of brain structures in human temporal lobe epilepsy: a quantified study from intracerebral EEG. *Brain* 2008;131:1818–1830.
- Engel J. Update on surgical treatment of the epilepsies. Summary of the Second International Palm Desert Conference on the Surgical Treatment of the Epilepsies (1992). *Neurology* 1993;43:1612–1617.
- Singh S, Sandy S, Wiebe S. Ictal onset on intracranial EEG: do we know it when we see it? State of the evidence. *Epilepsia* 2015;56:1629–1638.
- Ikeda A, Terada K, Mikuni N, et al. Subdural recording of ictal DC shifts in neocortical seizures in humans. *Epilepsia* 1996;37:662–674.
- Bragin A, Claeys P, Vonck K, et al. Analysis of initial slow waves (ISWs) at the seizure onset in patients with drug resistant temporal lobe epilepsy. *Epilepsia* 2007;48:1883–1894.
- Jirsa VK, Stacey WC, Quilichini PP, et al. On the nature of seizure dynamics. *Brain* 2014;137:2210–2230.
- Pitkanen A, Lukasiuk K. Mechanisms of epileptogenesis and potential treatment targets. *Lancet Neurol* 2011;10:173–186.
- Tassi L, Colombo N, Garbelli R, et al. Focal cortical dysplasia: neuropathological subtypes, EEG, neuroimaging and surgical outcome. *Brain* 2002;125:1719–1732.
- Faught E, Kuzniecky RI, Hurst DC. Ictal EEG wave forms from epidural electrodes predictive of seizure control after temporal lobectomy. *Electroencephalogr Clin Neurophysiol* 1992;83:229–235.
- Bragin A, Azizyan A, Almajano J, et al. The cause of the imbalance in the neuronal network leading to seizure activity can be predicted by the electrographic pattern of the seizure onset. *J Neurosci* 2009;29:3660–3671.
- Jung WY, Pacia SV, Devinsky R. Neocortical temporal lobe epilepsy: intracranial EEG features and surgical outcome. *J Clin Neurophysiol* 1999;16:419–425.
- Kim DW, Kim HK, Lee SK, et al. Extent of neocortical resection and surgical outcome of epilepsy: intracranial EEG analysis. *Epilepsia* 2010;51:1010–1017.
- Spanedda F, Cendes F, Gotman J. Relations between EEG seizure morphology, interhemispheric spread, and mesial temporal atrophy in bitemporal epilepsy. *Epilepsia* 1997;38:1300–1314.

SUPPORTING INFORMATION

Additional Supporting Information may be found in the online version of this article:

Figure S1. SEEG recordings showing a focal onset in a patient with FCD type II in the lateral premotor region (explored by the electrode SA').

Figure S2. SEEG recordings showing a “network” onset in a patient with FCD type I (normal MRI, histopathology showed FCD type I).

Figure S3. Prevalence of pattern with low-voltage fast activity (with LVD = LVFA + preictal spiking + burst of polyspikes + slow-wave/baseline shift following by LVFA) according to the histologic type.

Figure S4. SEEG recordings showing a seizure-onset pattern type 6 (theta/alpha sharp activity) within a network including the MRI lesion (explored by the electrode contacts C10–11 and TA 8–9) but also remote areas (explored

by the electrode contacts TP1–2, A7–8, B2–3) in a patient with a DNET.

Table S1. Patients' features and seizure-onset patterns.

Table S2. Patients' features and surgical outcome.