



Artificial white light photodynamic therapy for actinic keratosis: a study of 38 patients in private office practice (Letter to the editor)

C Maire, Anne-Sophie S Vignion-Dewalle, H Cartier, Serge Mordon

► To cite this version:

C Maire, Anne-Sophie S Vignion-Dewalle, H Cartier, Serge Mordon. Artificial white light photodynamic therapy for actinic keratosis: a study of 38 patients in private office practice (Letter to the editor). Journal of the European Academy of Dermatology and Venereology, 2019. hal-02503978

HAL Id: hal-02503978

<https://hal.science/hal-02503978>

Submitted on 10 Mar 2020

HAL is a multi-disciplinary open access archive for the deposit and dissemination of scientific research documents, whether they are published or not. The documents may come from teaching and research institutions in France or abroad, or from public or private research centers.

L'archive ouverte pluridisciplinaire **HAL**, est destinée au dépôt et à la diffusion de documents scientifiques de niveau recherche, publiés ou non, émanant des établissements d'enseignement et de recherche français ou étrangers, des laboratoires publics ou privés.

Letter to the editor: Artificial white light photodynamic therapy for actinic keratosis: a study of 38 patients in private office practice

C. Maire^{1,2}, A.S. Vignion-Dewalle¹, H. Cartier², S. Mordon¹

¹Univ. Lille, INSERM, CHU Lille, U1189 – ONCO-THAI – Image Assisted Laser Therapy for Oncology, F-59000 Lille, France

²Centre Médical Saint Jean, F-62000 Arras, France

Corresponding author: Anne-Sophie Vignion-Dewalle
INSERM U1189 ONCO-THAI,
1, avenue Oscar Lambret,
F-59037 LILLE Cedex,
France
Telephone number: 33 (0) 320 446 717
E-mail: anne-sophie.vignion@inserm.fr

Manuscript word count: 584

Manuscript table count: 0

Manuscript figure count: 2

ORCID:

C. Maire <https://orcid.org/0000-0002-1073-5030>

A.S. Vignion-Dewalle <https://orcid.org/0000-0003-0979-3310>

H. Cartier <https://orcid.org/0000-0003-3334-7601>

S. Mordon <https://orcid.org/0000-0002-1208-7153>

Funding sources:

This study received no funding.

Conflicts of interest:

The authors have none conflicts of interest to declare.

Key words:

Photodynamic therapy, actinic keratosis, artificial white light.

Dear Editor

Photodynamic therapy (PDT) using daylight as the photoactivating light source requires weather conditions and temperature to be suitable for effective treatment and for patients to stay comfortably outdoors¹. In order to get rid of such requirements, artificial white light sources have been proposed as photoactivating alternatives to daylight, particularly for the treatment of actinic keratosis (AK)²⁻⁵. Such is the case of Dermaris (Surgiris, Croix, France), a new CE-marked device specifically designed for the treatment of AK, which delivers a uniform illumination with 2.9 mW/cm² white light over a 314 cm² surface. Recently, two studies have provided preliminary clinical data indicating that PDT using the Dermaris, below referred to as artificial white light PDT (AWL-PDT), could be an effective and nearly painless treatment for patients with AK lesions^{6,7}. Here, we reported the clinical outcomes, in terms of efficacy and tolerability, of 38 male patients with AK lesions of the scalp, who were treated in daily practice with AWL-PDT. These patients with a minimum of 10 clinically diagnosed grade I or II AK lesions of the scalp were selected from the patient population of our private-practice dermatology clinic. AWL-PDT was administered as follows: after standard skin preparation, 2 g of MAL cream (Metvixia, Galderma, France) was applied on lesions and the surrounding normal skin, immediately after which the Dermaris was placed 20 cm from the scalp and switched on for 2.5 hours of photoactivation leading to a total light dose: 26.1 J/cm². Once AWL-PDT was completed, pain level, discomfort and pruritus during the treatment were rated by the patient on an 11-point scale. Seven days following the treatment, crusts were rated by a dermatologist using a 6-point scale, while patients rated discomfort and pruritus they had experienced during the six days post-treatment on an 11-point scale. At three months after the treatment, AK lesions were counted by a dermatologist without differentiation between new and recurrent lesions. In case of five or more AK lesions, and

provided that all of them were grade I or II, a second AWL-PDT was performed either on the day or within seven days. Otherwise, a suitable alternative treatment was applied. Analysis of clinical outcomes was performed. Regarding the efficacy outcomes, 22 of the 38 patients (58%) had no more AK lesions at three months after the treatment and therefore received no further treatment, 12 patients (32%) required a second AWL-PDT due to more than five grade I–II AK lesions, and the remaining four patients (11%) showed one to four AK lesions, which were all grade I–II and subsequently were cured by topical ingenol mebutate. Regarding the tolerability outcomes, 33 of the 38 patients (87%) of patients experienced no pain during the treatment and the remaining five patients (13%) rated their pain level as one. In addition, discomfort and pruritus were almost always rated as mild or less (97%) except one very moderate rate for both (3%) (Figure 1), while crusts were rated as mild or less in 33 of the 38 patients (87%) and as moderate in 5 patients (13%) (Figure 2). These results demonstrated that AWL-PDT, as administered in the study, is an effective and nearly painless treatment with minimal side effects for patients with AK lesions of the scalp. Moreover, the simplicity and reproducibility of the treatment (constant light dose), the rapid treatment implementation (no drug-light interval), the absence of treatment discontinuations due to pain, the high patient acceptability of treatment... make AWL-PDT a convenient and attractive treatment option for both patients and health professionals.

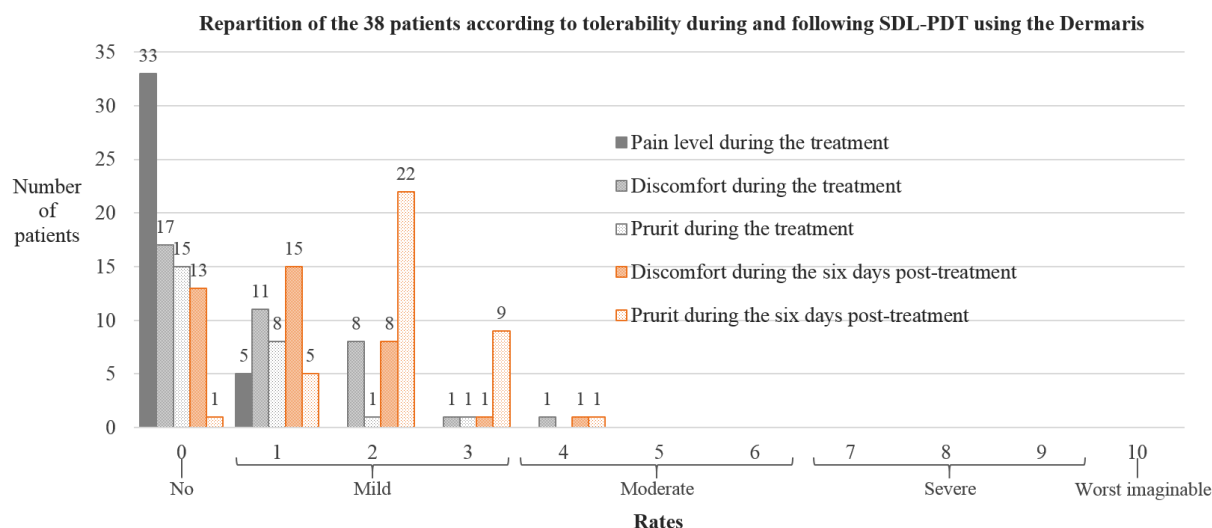


Figure 1: Distribution of scores of pain level, discomfort and pruritus in patients receiving SDL-PDT using the Dermalis for the treatment of AKs.

SDL-PDT: Simulated DayLight PhotoDynamic Therapy; AKs: Actinic Keratoses.

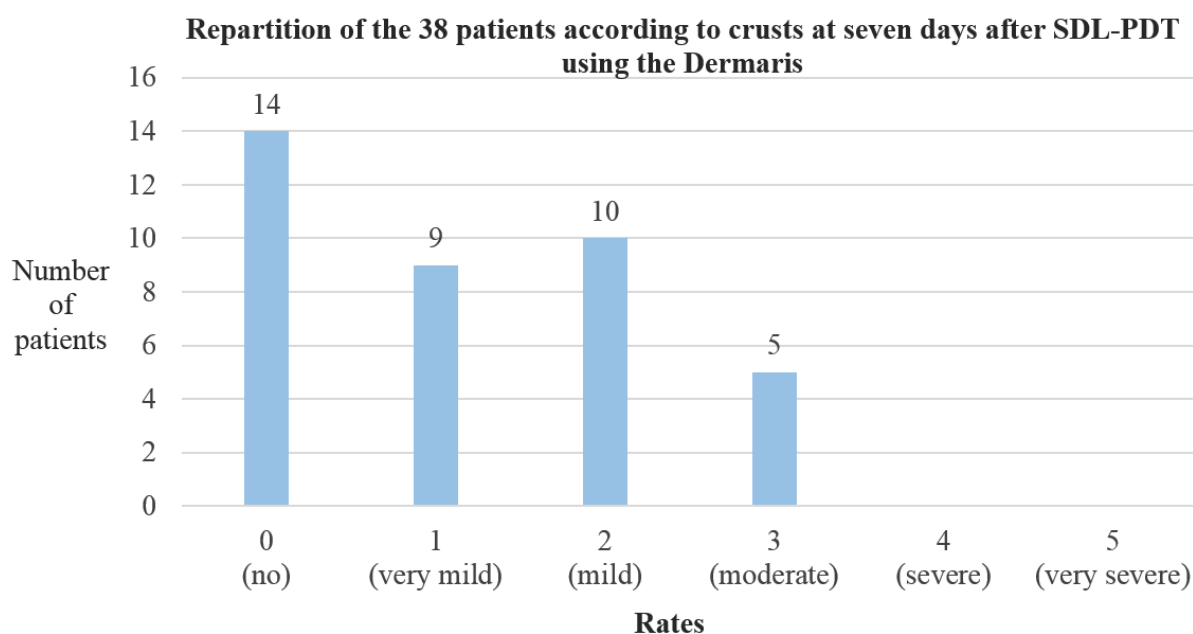


Figure 2: Distribution of rates of crusts in patients receiving SDL-PDT using the Dermalis for the treatment of AKs.

SDL-PDT: Simulated DayLight PhotoDynamic Therapy; AKs: Actinic Keratoses.

References:

- 1 Wiegell SR, Fabricius S, Heydenreich J *et al.* Weather conditions and daylight-mediated photodynamic therapy: protoporphyrin IX-weighted daylight doses measured in six geographical locations. *Br J Dermatol* 2013; **168**: 186-91.
- 2 Mordon S, Vignion-Dewalle AS, Thecuia E *et al.* Can daylight-PDT be performed indoor? *G Ital Dermatol Venereol* 2018; **153**: 811-6.
- 3 O'Gorman SM, Clowry J, Manley M *et al.* Artificial White Light vs Daylight Photodynamic Therapy for Actinic Keratoses: A Randomized Clinical Trial. *JAMA Dermatol* 2016; **152**: 638-44.
- 4 O'Mahoney P, Haigh N, Wood K *et al.* A novel light source with tuneable uniformity of light distribution for artificial daylight photodynamic therapy. *Photodiagnosis Photodyn Ther* 2018; **23**: 144-50.
- 5 Lerche CM, Heerfordt IM, Heydenreich J *et al.* Alternatives to Outdoor Daylight Illumination for Photodynamic Therapy--Use of Greenhouses and Artificial Light Sources. *Int J Mol Sci* 2016; **17**: 309.
- 6 Schmitz L, Stockfleth E. First clinical experiences on MAL-PDT with an artificial white light irradiation device (Dermaris®) in patients with multiple AK of the face and scalp: a split face study. *EuroPDT Brussels 2019*. 2019.
- 7 Maire C, Mordon S. Simulated daylight (SDL-PDT) treatment of AK with a new LED white light device: clinical results in a prospective observational pilot series of 30 patients. *EuroPDT Brussels 2019*. 2019.