



HAL
open science

Feasibility of First Injection of Autologous Adipose Tissue-Derived Stromal Vascular Fraction in Human Scarred Vocal Folds: A Nonrandomized Controlled Trial

Alexia Mattei, Baptiste Bertrand, Elisabeth Jouve, Théo Blaise, Cecile Philandrianos, Fanny Grimaud, Laurent Giraudo, Houssein Aboudou, Chloe Dumoulin, Laurent Arnaud, et al.

► To cite this version:

Alexia Mattei, Baptiste Bertrand, Elisabeth Jouve, Théo Blaise, Cecile Philandrianos, et al.. Feasibility of First Injection of Autologous Adipose Tissue-Derived Stromal Vascular Fraction in Human Scarred Vocal Folds: A Nonrandomized Controlled Trial. Archives of Otorhinolaryngology - Head & Neck Surgery, 2020, 10.1001/jamaoto.2019.4328 . hal-02485357

HAL Id: hal-02485357

<https://hal.science/hal-02485357>

Submitted on 20 Feb 2020

HAL is a multi-disciplinary open access archive for the deposit and dissemination of scientific research documents, whether they are published or not. The documents may come from teaching and research institutions in France or abroad, or from public or private research centers.

L'archive ouverte pluridisciplinaire **HAL**, est destinée au dépôt et à la diffusion de documents scientifiques de niveau recherche, publiés ou non, émanant des établissements d'enseignement et de recherche français ou étrangers, des laboratoires publics ou privés.

Feasibility of First Injection of Autologous Adipose Tissue–Derived Stromal Vascular Fraction in Human Scarred Vocal Folds

A Nonrandomized Controlled Trial

Alexia Mattei, MD; Baptiste Bertrand, MD, PhD; Elisabeth Jouve, MSc; Théo Blaise, MSc; Cécile Philandrianos, MD; Fanny Grimaud, PharmD; Laurent Giraud, MSc; Houssein Aboudou; Chloé Dumoulin, MSc; Laurent Arnaud, MSc; Joana Revis, PhD; Camille Galant, MSc; Mélanie Velier, MSc; Julie Veran, PhD; Françoise Dignat-George, PharmD, PhD; Patrick Dessi, MD, PhD; Florence Sabatier, PharmD, PhD; Jérémy Magalon, PharmD, PhD; Antoine Giovanni, MD, PhD

IMPORTANCE Patients with scarred vocal folds, whether congenitally or after phonosurgery, often exhibit dysphonia that negatively affects daily life and is difficult to treat. The autologous adipose tissue–derived stromal vascular fraction (ADSVF) is a readily accessible source of cells with angiogenic, anti-inflammatory, immunomodulatory, and regenerative properties.

OBJECTIVE To evaluate the feasibility and tolerability of local injections of autologous ADSVF in patients with scarred vocal folds.

DESIGN, SETTING, AND PARTICIPANTS CELLCORDES (Innovative Treatment for Scarred Vocal Cords by Local Injection of Autologous Stromal Vascular Fraction) is a prospective, open-label, single-arm, single-center, nonrandomized controlled trial with a 12-month follow-up and patient enrollment from April 1, 2016, to June 30, 2017. Eight patients with severe dysphonia attributable to vocal fold scarring associated with a congenital malformation or resulting from microsurgical sequelae (voice handicap index score >60 of 120) completed the study. Data analysis was performed from September 1, 2018, to January 1, 2019.

INTERVENTIONS Injection of ADSVF into 1 or 2 vocal folds.

MAIN OUTCOMES AND MEASURES The primary outcomes were feasibility and the number and severity of adverse events associated with ADSVF-based therapy. The secondary outcomes were changes in vocal assessment, videolaryngostroboscopy, self-evaluation of dysphonia, and quality of life at 1, 6, and 12 months after cell therapy.

RESULTS Seven women and 1 man (mean [SD] age, 44.6 [10.4] years) were enrolled in this study. Adverse events associated with liposuction and ADSVF injection occurred; most of them resolved spontaneously. One patient received minor treatment to drain local bruising, and another experienced a minor contour defect at the liposuction site. At 12 months, the voice handicap index score was improved in all patients, with a mean (SD) improvement from baseline of 40.1 (21.5) points. Seven patients (88%) were considered to be responders, defined as improvement by 18 points or more in the voice handicap index score (the minimum clinically important difference).

CONCLUSIONS AND RELEVANCE The findings suggest that autologous ADSVF injection in scarred vocal folds is feasible and tolerable. The findings require confirmation in a randomized clinical trial with a larger population.

TRIAL REGISTRATION ClinicalTrials.gov Identifier: [NCT02622464](https://clinicaltrials.gov/ct2/show/study/NCT02622464)

JAMA Otolaryngol Head Neck Surg. doi:10.1001/jamaoto.2019.4328
Published online February 13, 2020.

- [+ Author Audio Interview](#)
- [+ Video and Supplemental content](#)

Author Affiliations: Author affiliations are listed at the end of this article.

Corresponding Author: Alexia Mattei, MD, Department of Oto-Rhino-Laryngology and Head and Neck Surgery, Assistance Publique-Hôpitaux de Marseille, La Conception University Hospital, 147 Bd Baille, 13385 Cedex Marseille, France (alexia.mattei@laposte.net or alexia.mattei@ap-hm.fr).

The microstructure of the vocal folds is complex^{1,2} in particular because of their foliated organization. The proportions and organization of the extracellular matrix components in each layer determine the mechanical properties of the vocal folds. Vocal fold scarring is sometimes observed after laryngeal microsurgery because of the partial disappearance of the lamina propria, with the superficial and/or intermediate layer replaced by fibrous tissue, thereby inducing vibration disorder. This scarring is often accompanied by loss of volume and a glottal defect. Noniatrogenic scar tissue owing to congenital issues or acquired as a result of trauma or chronic inflammatory phenomena is also found.

Such scarring can be disabling, especially for communication professionals. Patients usually present with long-lasting dysphonia, loss of vocal control, vocal fatigue, and a breathy voice that is frequently too high-pitched and has difficulty sustaining tone.

Current therapeutic options are limited in part because of the high complexity of the microstructure of the vocal folds.¹ In cases in which an insufficient glottic closure is the predominant issue, medialization procedures have proved to be effective.^{1,3} When rigidity is the major feature, other techniques have been described (eg, scar resection, microflap,⁴ and hyaluronic acid^{5,6}) but are often disappointing, especially in the long term,⁷⁻⁹ and may worsen the situation by leading to additional scarring. Thus, development of innovative strategies to improve the vibrational mechanical properties of the vocal folds is an important clinical challenge.^{1,3}

The autologous adipose tissue–derived stromal vascular fraction (ADSVF) is a heterogeneous population of cells that comprise mesenchymal stem cells (MSCs) or adipose-derived stem cells (ADSCs), fibroblasts, leukocytes, endothelial cells, progenitors, and pericytes.¹⁰ The ADSCs can be used alone as a homogeneous cell product, but their culture requires several weeks. However, ADSVF is a heterogeneous cell product; its components exert a synergistic effect, and it does not require culture. Furthermore, its preparation based on enzymatic digestion of adipose tissue takes merely hours, facilitating its autologous use.

The ADSVF is a readily accessible source of cells with angiogenic, anti-inflammatory, immunomodulatory, and regenerative properties.¹¹ Recent experimental and clinical reports also supported the antifibrotic potential of ADSVF, which was mainly attributed to the ADSC subset.

A preclinical study¹² found that cultured ADSCs are associated with the processes underlying vocal fold scarring. Coculture of ADSCs with scar tissue fibroblasts was associated with decreased proliferation and expression of α -smooth muscle actin (a marker of myofibroblast differentiation) and with production of an extracellular matrix with less collagen and more hyaluronic acid.^{13,14} Some in vivo animal studies¹⁴ reported significant improvements in vocal fold scarring after injection of ADSCs immediately after injury or after a longer interval, as evidenced by the macroscopic and histologic structures of the vocal folds¹⁵⁻²⁴ along with their viscoelastic properties.^{16,18,22,25} We hypothesized that use of whole ADSVF has advantages over ADSCs alone. The complementary properties of its various components could optimize the healing process.

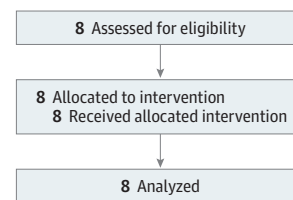
Key Points

Question Is autologous adipose tissue–derived stromal vascular fraction feasible as a new treatment for scarred vocal folds?

Findings In this nonrandomized controlled trial of 8 patients (7 women and 1 man) with severe dysphonia due to vocal fold scarring, only anticipated adverse events associated with liposuction and adipose tissue–derived stromal vascular fraction injection occurred but resolved spontaneously.

Meaning The findings suggest that injection of autologous adipose tissue–derived stromal vascular fraction in scarred vocal folds is feasible and deserves further evaluation in a randomized clinical trial.

Figure 1. CONSORT Flow Diagram for the Single-Arm, Open-Label, Phase 1 Clinical Trial



The safety and efficacy of ADSVF cells have been examined in various conditions, including those with vascular or immune components, such as burn wound healing,²⁶ lower-limb ischemia,²⁷ myocardial infarction,²⁸ graft-vs-host disease,²⁹ and systemic sclerosis.³⁰ However, extrapolation of the benefits of ADSVF to the vocal folds requires caution because the actors in the scarring process, including fibroblasts, extracellular matrix components, and growth factors, differ depending on the tissue.³¹ Nevertheless, the outcomes of the second patient treated (who was included in this study) encouraged us to evaluate ADSVF in a larger number of patients.³² We evaluated the feasibility and tolerability and performed a preliminary assessment of the potential efficacy of local injections of autologous ADSVF as an innovative therapeutic strategy for patients with scarred vocal folds.

Methods

Study Design and Eligibility Criteria

CELLCORDES (Innovative Treatment for Scarred Vocal Cords by Local Injection of Autologous Stromal Vascular Fraction) is a prospective, open-label, single-arm, single-center, nonrandomized controlled trial designed to evaluate the feasibility and tolerability of local injection of autologous ADSVF into scarred vocal folds (trial protocol in Supplement 1). Eight patients with scarred vocal folds were enrolled in the study from April 1, 2016, to June 30, 2017 (Figure 1). Data analysis was performed from September 1, 2018, to January 1, 2019. The study was approved by the French National Agency for Medicines and Health Products Safety and the French ethics committee (Comite de Protection des Personnes *Sud Mediterranee V*) and

was conducted in accordance with the tenets of the Declaration of Helsinki. All patients provided written informed consent. A data and safety monitoring board reviewed and evaluated the accumulated study data in terms of participants' safety, study conduct, and progress. This study followed the Consolidated Standards of Reporting Trials (CONSORT) reporting guideline.

In addition to a thorough medical history, videolaryngostroboscopy was used for diagnosis based on the following major clinical features¹: a spindle-shaped glottis during phonation (insufficient glottic closure and air leakage) and impaired vocal fold vibration (reduced amplitude and mucosal wave). In 4 patients, prior interventions had failed (scar resection [n = 4] and corticosteroid injection [n = 1]). All participants had received extensive voice therapy without improvement before enrollment. All the patients fulfilled the inclusion criteria, and none met the exclusion criteria (Box).

Collection of Adipose Tissue Samples and Preparation of ADSVF

Adipose tissue samples were collected with the patient under conscious sedation with local anesthesia. The fat harvesting site was determined during the first consultation with the plastic surgeon based on the patient's adipose tissue distribution (in order of preference: subumbilical region and flank-peritrochanteric area). The adipose tissue sample was harvested using a 10-mL syringe in a closed circuit with a 3-mm Khouri cannula and a 500-mL collection bag. At least 100 mL of lipoaspirate was collected, immediately transported to the authorized cell therapy unit, and transferred into the Celution 800/CRS system (Cytori Therapeutics Inc). Collected lipoaspirate was washed and enzymatically digested to obtain ADSVF in accordance with the European regulations and Good Manufacturing Practice for advanced therapy medicinal products. Cells were concentrated, washed, aseptically recovered, and resuspended in 5 mL of lactated Ringer solution using Good Manufacturing Practice–grade reagents. At least 1 mL was obtained for injection, and the remaining cells were used for biological characterization^{32,33} (eMethods 1 in Supplement 2). During the preparation of ADSVF (4 hours), patients were transported to the recovery room.

Treatment Procedure

The second surgical step consisted of reinjection of ADSVF while the patient was under general anesthesia (suspension direct laryngoscopy). The ADSVF suspension was injected using a 14-gauge needle into the anterior and/or middle third of the scarred vocal fold(s). Fibrous tissue in the area was not resected to avoid increasing the atrophy of the vocal fold. All ADSVF injections were performed by 1 laryngologist (A.G.).

Patients were allowed to leave the hospital in the evening (outpatient surgery) or on the following day with a prescription for 1 g of acetaminophen to be taken 4 times a day for 7 days in case of pain and 1 g of amoxicillin and 125 mg of clavulanic acid to be taken 3 times a day for 2 days. The standard postoperative speech therapy was prescribed after surgery.

Box. Inclusion and Exclusion Criteria for the CELLCORDES Clinical Trial

Inclusion Criteria

- Subscription to the French Social Security System
- Signed informed consent
- Voice Handicap Index score >60 of 120
- Scarred vocal folds, congenital (sulcus) or after phonosurgery
- Scarred middle third in stroboscopy
- At least 1 year of dysphonia after initial surgery if appropriate
- Aged between 18 and 65 years
- Good general condition
- Negative pregnancy test result and contraception for women of childbearing age

Exclusion Criteria

Specific

- Refusal of speech therapy
- History of malignant lesion or severe dysplasia of the scarred vocal fold
- Contraindication to anesthesia
- Anticoagulant treatment
- Coagulation disorders (prothrombin time <65%, kaolin-activated partial thromboplastin time >1.2 seconds)
- Active infectious diseases
- Positive serologic test results for HIV, hepatitis B virus, hepatitis C virus, human T-lymphotropic virus, or syphilis
- Necessity of intraoperative prophylactic antibiotics

Nonspecific

- Persons having taken an investigational medicinal product in the last 3 months
- Refusal or inability to comply with study procedures
- Pregnant and lactating women
- Patients under curatorship or guardianship
- Persons living in public health facilities or residential care
- Minors
- Persons without French Social Security System coverage
- Persons deprived of liberty or detainees
- Persons in high-risk and emergency situations

Clinical Assessment

The primary end points were feasibility of subepithelial injection without epithelial rupture (sufficient product fluid) during surgery and adverse events and the status of the injection site and airway using videolaryngoscopy after injection. The assessments were performed at day 7 (± 4 days) and months 1 (± 7 days), 6 (± 30 days), and 12 (± 30 days). The secondary end point was potential efficacy at months 1, 6, and 12 (except for the Medical Outcomes Study 36-Item Short-Form Health Survey [SF-36], which was evaluated at 6 and 12 months).

The vocal assessment included the following: (1) self-evaluation of dysphonia using the Voice Handicap Index (VHI); (2) self-evaluation of quality of life using the SF-36; (3) videolaryngostroboscopy assessment of glottal closure, regularity, and vibration (mucosal wave)³⁴; (4) perceptual analysis using the Hirano simplified GRB scale³⁵ (G, global; R, roughness; and B, breathiness); (5) acoustic analysis, including the signal to noise ratio and vocal range; and (6) aerodynamic analysis, including maximum phonation time, oral airflow, and estimated subglottic pressure at the phonatory threshold (eMethods 2 in Supplement 2).³⁴

Table 1. Patient Demographics and Treatment Doses

Patient No.	Cause	Disease Duration, y ^a	Volume Injected, mL		VNCs Injected, Cells ×10 ⁶	
			Left Vocal Fold	Right Vocal Fold	Left Vocal Fold	Right Vocal Fold
1	Phonosurgery	8	0.30	0.70	4.1	9.5
2	Phonosurgery	4	0.45	0.45	6.1	6.1
3	Sulcus	>20	0.50	0.75	1.1	1.6
4	Phonosurgery	13	0.50	0.50	3.6	3.6
5	Phonosurgery	6	0.00	1.00	0.0	10.3
6	Sulcus	>20	0.50	0.50	3.2	3.2
7	Phonosurgery	3	0.40	0.60	0.9	1.3
8	Phonosurgery	1	0.30	0.70	2.3	5.5
Mean (SD)	NA	5.8 (4.3)	0.37 (0.17)	0.65 (0.18)	2.7 (2.0)	5.1 (3.4)
Median (range)	NA	5 (1-13)	0.42 (0.00-0.45)	0.65 (0.50-1.00)	2.8 (0.0-6.1)	4.5 (1.3-10.3)

Abbreviation: VNCs, viable nucleated cells.

^a Statistical analysis performed only for noncongenital origins (n = 6).

The VHI is composed of 3 subscales (emotional, functional, and physical), with lower scores indicating better voice perception. Patients were considered to be responders if they achieved the minimal clinically important difference, defined by Jacobson et al³⁶ as a shift in the total VHI score of 18 points or more.

The SF36 is a generic quality-of-life scale that consists of 36 items that describe 8 dimensions³⁷ and 2 summary measures (ie, the physical and mental component summary scores).³⁸ The score for each dimension ranges from 0 to 100, with higher scores indicating better perceived state of health.

Videolaryngoscopic records at baseline and month 12 were analyzed by the same experienced laryngologist (A.G.) in a randomized and blinded manner.³⁴ For the perception analysis, all vocal records were rated at baseline, month 6, and month 12 by a jury that comprised 3 experienced speech therapists (including J.R. and C.G.) assigned in a randomized and blinded manner.

Statistical Analysis

No formal sample size calculation was performed. The sample size was fixed at 8 patients based on empirical considerations, as in similar early-phase studies³⁹; this was a phase 1 study without a formal hypothesis, with tolerability as the primary end point. In addition, the clinical situation is relatively rare, and studies on innovative therapies typically have small populations. Efficacy end points were deemed to be exploratory. The tolerability analysis was descriptive and based on the reported treatment-emergent adverse events (AEs). The AEs were coded according to an established and validated adverse reaction dictionary.⁴⁰ Continuous data are shown as mean (SD) or as median (range); 95% CIs were calculated when differences were clinically relevant. Statistical analysis was performed using SPSS software, version 20.0 (IBM Corp).

Results

Characteristics of the Patients and the ADSVF

Seven women and 1 man (mean [SD] age, 44.6 [10.4] years) were enrolled in this study. The demographic characteristics

of the 8 patients and the ADSVF are given in **Table 1**. The median body mass index (calculated as weight in kilograms divided by height in meters squared) was 25.6 (range, 20.4-28.1). Adipose tissue samples were harvested from abdominal fat in 6 patients and from crural fat in 2 patients. All enrolled patients underwent surgery; there were no dropouts or patients lost to follow-up. All subepithelial injections were completed without epithelial rupture, demonstrating the feasibility of the approach. One patient did not undergo postoperative speech therapy. The patients received a median of 7.5×10^6 (range, 2.2 - 13.6×10^6) viable nucleated cells. The characteristics of the cell subsets in ADSVF as determined by flow cytometry are given in eTable 1 in **Supplement 2**. There was no association between potential efficacy and the number or type of injected ADSVF cells.

Adverse Event Profile of Autologous ADSVF Injection

All patients were discharged from the hospital within 24 hours of surgery. No serious AEs linked to ADSVF injection occurred during follow-up, and videolaryngoscopy showed only edema 1 week after injection. Two severe AEs were declared to pharmacovigilance: acute pancreatitis and mammary prosthesis rupture; neither was deemed to be associated with the study procedures or ADSVF. Minor AEs deemed to be potentially associated with the procedure (doubtful or possible) are given in **Table 2**. Most of these AEs resolved spontaneously. One patient received minor treatment for persistent crural pain. One patient experienced a cosmetic contour defect associated with liposuction (fat defect with subcutaneous depression). This contour defect was corrected without sequelae by crural lipofilling 6 months after the initial surgery. Abdominal lipoaspiration sample points healed in less than 7 days after surgery. Self-evaluated dysphonia did not worsen for any patient.

Preliminary Efficacy Profile of Autologous ADSVF Injection

Self-evaluated Dysphonia

The mean improvement in dysphonia at 12 months was a decrease of 40.1 points (95% CI, -58.1 to -22.2 points) in the VHI score compared with baseline (**Figure 2**). In addition, each of the emotional, functional, and physical subscales was

Table 2. Adverse Events Potentially Associated With the Procedure for Each Patient and Adverse Event Duration

Adverse Event ^a	Adverse Event Duration							
	Patient 1	Patient 2	Patient 3	Patient 4	Patient 5	Patient 6	Patient 7	Patient 8
Odynophagia	3 d	NA	NA	NA	4 d	NA	NA	NA
Mouth ulceration	NA	NA	NA	9 d	NA	NA	NA	NA
Asthenia	NA	NA	NA	8 d	NA	NA	NA	NA
Postprocedural hematoma or ecchymosis	1 mo	7 d	1 mo	19 d	22 d	5 d	7 d	15 d
Procedural pain	NA	1 mo	NA	NA	NA	NA	1 mo	12 mo
Pain in jaw	NA	5 d	8 mo ^b	NA	NA	NA	NA	NA
Dysgeusia	NA	NA	1 mo	NA	NA	NA	NA	NA
Headache	NA	NA	1 mo ^b	NA	NA	NA	NA	NA
Tremor	NA	NA	2 mo ^b	NA	NA	NA	NA	NA
Hemoptysis ^c	NA	NA	7 d	NA	NA	NA	3 d	NA
Productive cough	NA	NA	1 mo	NA	NA	NA	NA	NA
Rhinorrhea	NA	NA	NA	NA	NA	NA	NA	NA
Allergic dermatitis ^d	NA	NA	NA	16 d	NA	NA	NA	NA
Lipodystrophy ^e	NA	NA	NA	6 mo	NA	NA	NA	NA

Abbreviation: NA, not applicable.

^a Preferred term according to MedDRA MSSO.⁴⁰

^b Patient 3 reported symptoms associated with the recovery of a high-intensity voice: a feeling of resonance in the skull, cheeks, and even lower limbs.

^c Hemoptysis consisted of rusty sputum.

^d Dermatitis allergic to plaster.

^e Patient 4 had a cosmetic contour defect.

improved (Figure 2). Seven of the 8 treated patients (88%) were considered to be responders (improvement ≥ 18 points) (eTable 2 and eTable 3 in Supplement 2).

Quality of Life

The physical and mental component summary SF-36 scores did not improve.

Videolaryngostroboscopy

Clinical improvement, as determined in videolaryngostroboscopy, in glottal closure was noted in 5 patients (62%) and in vocal fold vibration in 4 patients (50%). Video 1 shows the videolaryngostroboscopy results for patient 6 before and 12 months after injection. The data indicate an improvement in glottal closure and vibration of the middle third of the 2 vocal folds.

Perceptive, Acoustic, and Aerodynamic Assessments

A potentially clinically meaningful difference in roughness of voice was detected in the perceptual analysis at month 12 (mean difference, -0.5 ; 95% CI, -1.1 to 0.1). The voices of the responder patients were less hoarse, more stable, and without breathiness (Video 2). This improvement was also noticed during singing in patient 8. Another potentially clinically meaningful difference was observed in the signal to noise ratio at month 12 (mean difference, 2.6 ; 95% CI, -1.3 to 6.6). There was no improvement in the aerodynamic outcomes.

Discussion

To our knowledge, this nonrandomized controlled trial is the first evaluation of autologous ADSVF to treat vocal fold scarring in humans. To date, preclinical research and animal

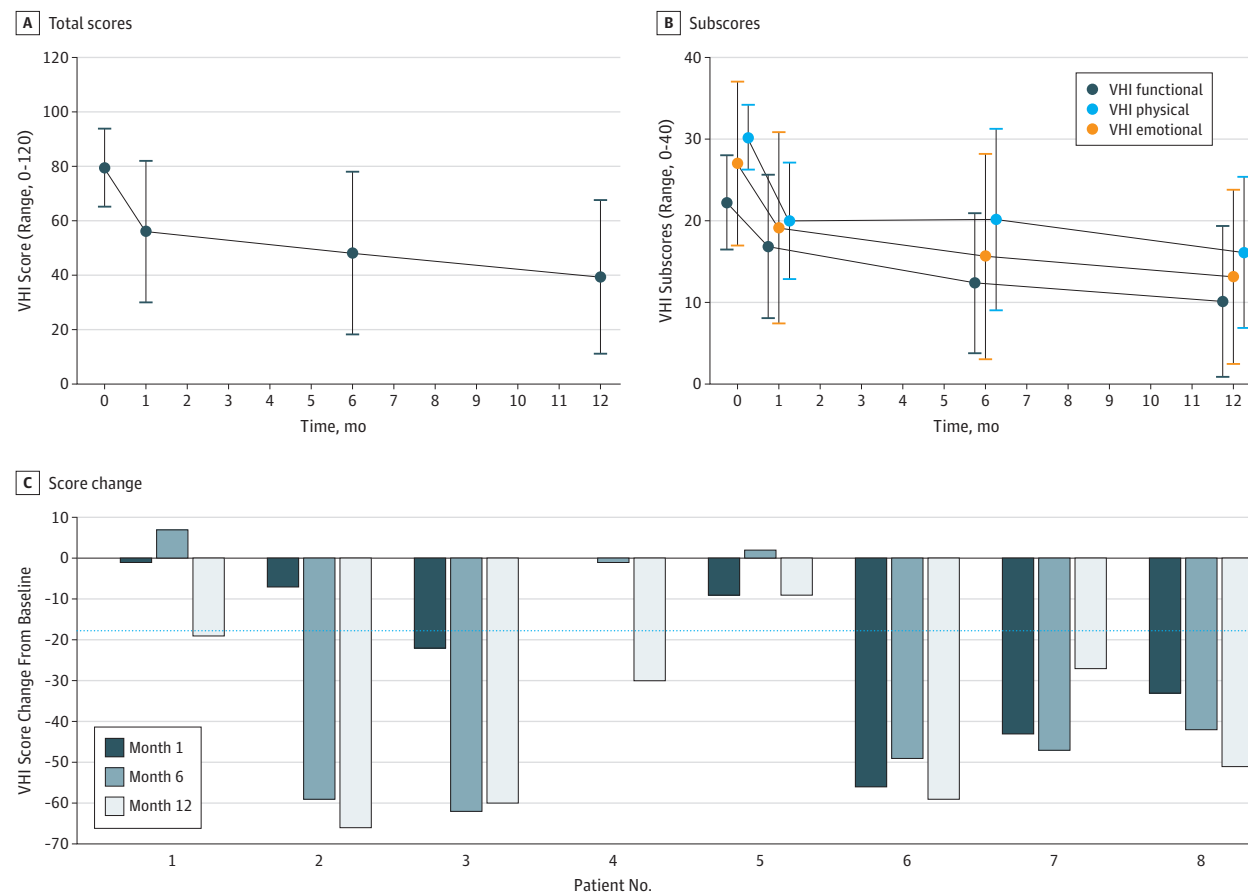
models have suggested the potential of stem cell injection into the vocal folds.¹² This new cell-based therapy is particularly attractive because current therapeutic options are limited and do not fully resolve voice handicap.

The feasibility and tolerability of injection of autologous ADSVF into scarred vocal folds were demonstrated by the lack of treatment-related serious AEs. Treatment-related AEs were limited to those normally associated with lipoaspiration and direct laryngoscopy. This finding is consistent with the good tolerance profile of local injection of ADSVF in other clinical contexts, including those characterized by fibrosis, such as hand disability in patients with systemic sclerosis.^{30,41,42}

The results also support the potential efficacy of ADSVF injection because VHI scores were reduced, including after 1 year. The VHI is the most widely used tool for self-assessment of dysphonia. The response rate of ADSVF treatment was 88% at 1 year, which is particularly encouraging given the long disease duration of the patients (5.8 [4.3] years for noncongenital origins and >20 -year disease histories in 2 patients with congenital lesions). Improvement in the VHI score was associated with a potentially clinically meaningful improvement of vocal roughness. In some cases, typical rigid vocal folds recovered an almost normal amplitude and vibration regularity, suggesting that ADSVF injection is not limited to a simple volumizing outcome but may also be associated with regeneration of the lamina propria by replacing fibrotic tissue. The SF-36 scores were not improved, but 3 patients described major life changes after voice recovery (2 returned to work, and 1 returned to activity as a professional singer).

A variety of treatment options for vocal-fold scarring have been developed. Despite all efforts, complete restoration of altered vocal fold structure and vibration has not been reported. Surgical techniques, including manipulation

Figure 2. Voice Handicap Index (VHI) Scores During 12-Month Follow-up After Adipose Tissue–Derived Stromal Vascular Fraction (ADSVF) Injection



A, Total mean (SD) VHI score during the 12-month follow-up after ADSVF injection. B, Mean (SD) physical, functional, and emotional VHI subscores. C, Changes in VHI scores from baseline during 12-month follow-up after ADSVF injection for each patient. The dotted blue line represents the minimal shift in

the total VHI score required to be clinically significant (18 points).³⁶ Sample sizes were 8 patients at baseline and months 6 and 12 and 7 patients at month 1 (data missing for patient 4).

of the lamina propria, have a risk of an unfavorable outcome with potential for worsening the situation by additional scarring. Thus, conservative therapies are considered to be first-line treatment modalities. Injection of hyaluronic acid, acellular matrix, calcium hydroxyapatite, or corticosteroids are candidates,^{5,6,43} but none has been adopted in daily practice. Welham et al⁵ reported no improvement in vocal function indices, including the VHI, and the case series described by Young et al,⁴³ in which corticosteroids were used, revealed a mean improvement of 15 points in the VHI score with a follow-up of only 3 months after injection. In addition, the only cell-based approach reported to date is use of expanded autologous fibroblasts from the oral mucosa in 5 patients; 4 achieved an 18-point improvement in the VHI score at 1 year. However, this improvement was achieved after 3 injections in each vocal fold at 2-week intervals.³⁹

Although the mechanisms of the association of ADSVF with scarred vocal folds are unknown, the MSCs are highly represented within ADSVF and may be important contributors. Although early research attributed the outcomes of

MSC therapies primarily to their capacity for local engraftment and differentiation into multiple tissues, more recent studies^{16,44,45} have revealed that implanted cells do not survive for long and that the benefits are more likely attributable to the bioactive factors secreted by MSCs.⁴⁶ These paracrine functions of MSCs play a key role in the regulation of immunosuppressive and inflammatory responses.⁴⁷⁻⁴⁹ The MSC secretome also includes an array of antiapoptotic and growth factors that promote regeneration of damaged tissue. Of importance, MSCs also exert an antifibrotic outcome that could be beneficial to reduce scar formation. The mechanisms of the antifibrotic outcomes of MSCs are unclear, but candidates include inhibition of the transforming growth factor β 1 pathway, stimulation of hepatocyte growth factor expression, reduction of oxidative stress, and restoration of external matrix degradation.⁵⁰ In preclinical animal models of scarred vocal folds, MSCs enhanced healing and reduced granuloma, inflammation, and fibrosis.¹² The vocal folds became less atrophic, and their viscoelasticity and vibration amplitude recovered. Regarding the extracellular matrix, the authors reported reduced levels of

collagen and fibronectin and increased levels of hyaluronic acid and elastin. Transforming growth factor β 1 expression was reduced, as was inflammatory cell infiltration.⁵¹

However, ADSVF and ADSCs are markedly different products: ADSVF is an uncultured and minimally processed product that contains a heterogeneous population of cells, whereas ADSCs are a purified and ex vivo expanded multipotent MSC population. Hirose et al⁵² recently found that ADSVF secretes higher levels of cytokines and soluble proteins compared with ADSCs, indicating that it is a source of more multifunctional cells. The hematopoietic cells in ADSVF, including macrophages of the anti-inflammatory M2 phenotype and regulatory T cells that express high levels of immunosuppressive cytokines, are emerging as important contributors to the immunomodulatory findings of ADSVF. Many elements of the innate and adaptive immune response participate in the differentiation and activation of fibroblasts, and acute inflammatory reactions play an important part in triggering fibrosis in a variety of organ systems.⁵³ To our knowledge, there are no available data regarding the use of ADSVF in preclinical models of scarred vocal folds. However, ADSVF significantly reduced the clinical and histologic findings of hypertrophic scars in the epidermis and dermis compared with the control 8 weeks after injection in a humanized mouse model,⁵⁴ suggesting an antifibrotic outcome. Therefore, the regenerative and antifibrotic properties of ADSVF are likely associated with the favorable outcomes. In this trial, the possibility that the association was independent of the cells and mediated only on the volumizing finding of the injection procedure is unlikely because, in such a scenario, the improvement would have rapidly decreased over time and mucosal vibration would not have been affected.

Limitations

The main limitations of this study are the small number of patients, imbalanced male-to-female ratio, and the different causes of vocal fold scarring. However, iatrogenic and noniatrogenic causes are based on the same anatomical description and are included in 1 classification.⁵⁵ The absence of a control arm and the open-label protocol prevented determination of whether the positive changes in subjective factors were attributable to the placebo effect. In addition, speech therapy after surgery was not standardized and could have contributed to voice improvement. The patients received a wide range of viable nucleated cells, and although the number of cells injected was not associated with potential efficacy, it should be constant in a randomized clinical trial.

Conclusions

This single-center, nonrandomized controlled trial found that ADSVF treatment was feasible and well tolerated in patients with scarred vocal folds. Additional safety studies of ADSVF in scarred vocal folds after cordectomy for laryngeal neoplasia are warranted. Although we could not reach a conclusion regarding the efficacy of ADSVF injection, the observed data were encouraging. Longer-term, larger, multicenter, randomized, double-blind studies with a more homogeneous population are needed to evaluate the effect of ADSVF therapy on the long-term prognosis. In addition, future studies should delineate the contribution of each cell subpopulation in ADSVF and identify the mechanisms underlying its association with scarred vocal folds.

ARTICLE INFORMATION

Accepted for Publication: December 8, 2019.

Published Online: February 13, 2020.
doi:10.1001/jamaoto.2019.4328

Author Affiliations: Department of Oto-Rhino-Laryngology and Head and Neck Surgery, Assistance Publique–Hôpitaux de Marseille, La Conception University Hospital, Marseille, France (Mattei, Revis, Galant, Dessi, Giovanni); Laboratoire Parole et Langage, Centre National de la Recherche Scientifique, Aix Marseille University, Aix-en-Provence, France (Mattei, Revis, Galant, Giovanni); Department of Plastic and Reconstructive Surgery, Assistance Publique–Hôpitaux de Marseille, La Conception University Hospital, Marseille, France (Bertrand, Philandrianos); Assistance Publique–Hôpitaux de Marseille, Institut National de la Santé et de la Recherche Médicale, Institut de Neurosciences des Systèmes, Service de Pharmacologie Clinique et Pharmacovigilance, Centre d'Investigation Clinique Centre de Pharmacologie Clinique et d'Évaluation Thérapeutique, Aix Marseille University, Marseille, France (Jouve, Blaise); Cell Therapy Department, Assistance Publique–Hôpitaux de Marseille, Institut National de la Santé et de la Recherche Médicale, La Conception University Hospital, Aix Marseille University, Marseille, France (Grimaud, Giraudo, Aboudou, Dumoulin, Arnaud, Velier, Veran, Dignat-George, Sabatier, Magalon); Institut National de la Santé et de la Recherche Médicale and Institut

National de la Recherche Agronomique, Aix Marseille University, Centre Recherche en Cardiovasculaire et Nutrition, Marseille, France (Velier, Dignat-George, Sabatier, Magalon); French National Centre for Scientific Research, Centre National de la Recherche Scientifique, Etablissement Français du Sang, Anthropologie bio-culturelle, Droit, Ethique et Santé, Aix Marseille University, Marseille, France (Dessi).

Author Contributions: Drs Mattei and Giovanni had full access to all the data in the study and take responsibility for the integrity of the data and the accuracy of the data analysis.

Concept and design: Mattei, Bertrand, Jouve, Veran, Dessi, Sabatier, Giovanni.

Acquisition, analysis, or interpretation of data: Mattei, Jouve, Blaise, Grimaud, Giraudo, Aboudou, Dumoulin, Arnaud, Revis, Galant, Velier, Dignat-George, Sabatier, Magalon, Giovanni, Philandrianos.

Drafting of the manuscript: Mattei, Jouve, Blaise, Arnaud, Velier, Veran, Magalon, Giovanni.

Critical revision of the manuscript for important intellectual content: Mattei, Bertrand, Jouve, Blaise, Grimaud, Giraudo, Aboudou, Dumoulin, Revis, Galant, Dignat-George, Dessi, Sabatier, Magalon, Philandrianos.

Statistical analysis: Mattei, Jouve, Blaise.

Obtained funding: Veran, Sabatier, Magalon, Giovanni.

Administrative, technical, or material support: Mattei, Bertrand, Grimaud, Giraudo, Aboudou,

Dumoulin, Revis, Galant, Veran, Dignat-George, Magalon, Giovanni, Philandrianos.

Supervision: Mattei, Dignat-George, Dessi, Sabatier, Giovanni.

Conflict of Interest Disclosures: Drs Mattei and Giovanni reported receiving grants from Fondation de l'Avenir pour la Recherche Médicale Appliquée and Fondation des Gueules Cassées during the conduct of the study. No other disclosures were reported.

Funding/Support: The project was promoted by the Assistance Publique des Hôpitaux de Marseille, with a funding from grant ET-3714 from the Fondation de l'Avenir pour la Recherche Médicale Appliquée and grant 48-2014 from the Fondation des Gueules Cassées.

Role of the Funder/Sponsor: The funding sources had no role in the design and conduct of the study; collection, management, analysis, and interpretation of the data; preparation, review, or approval of the manuscript; and decision to submit the manuscript for publication.

REFERENCES

1. Friedrich G, Dikkers FG, Arens C, et al; European Laryngological Society, Phonosurgery Committee. Vocal fold scars: current concepts and future directions: consensus report of the Phonosurgery Committee of the European Laryngological Society. *Eur Arch Otorhinolaryngol*. 2013;270(9):2491-2507. doi:10.1007/s00405-013-2498-9

2. Hirano M. Phonosurgery: basic and clinical investigation. *Otologia (Fukuoka)*. 1975;21:239-440.
3. Graupp M, Bachna-Rotter S, Gerstenberger C, et al. The unsolved chapter of vocal fold scars and how tissue engineering could help us solve the problem. *Eur Arch Otorhinolaryngol*. 2016;273(9):2279-2284. doi:10.1007/s00405-015-3668-8
4. Sataloff RT, Spiegel JR, Heuer RJ, et al. Laryngeal mini-microflap: a new technique and reassessment of the microflap saga. *J Voice*. 1995;9(2):198-204. doi:10.1016/S0892-1997(05)80253-X
5. Welham NV, Choi SH, Dailey SH, Ford CN, Jiang JJ, Bless DM. Prospective multi-arm evaluation of surgical treatments for vocal fold scar and pathologic sulcus vocalis. *Laryngoscope*. 2011;121(6):1252-1260. doi:10.1002/lary.21780
6. Molteni G, Bergamini G, Ricci-Maccarini A, et al. Auto-crosslinked hyaluronan gel injections in phonosurgery. *Otolaryngol Head Neck Surg*. 2010;142(4):547-553. doi:10.1016/j.otohns.2009.12.035
7. Hertegård S, Hallén L, Laurent C, et al. Cross-linked hyaluronan versus collagen for injection treatment of glottal insufficiency: 2-year follow-up. *Acta Otolaryngol*. 2004;124(10):1208-1214. doi:10.1080/00016480410017701
8. Liu Y, Zheng Shu X, Prestwich GD. Biocompatibility and stability of disulfide-crosslinked hyaluronan films. *Biomaterials*. 2005;26(23):4737-4746. doi:10.1016/j.biomaterials.2005.01.003
9. Zhang Y, Rossi F, Papa S, et al. Non-invasive in vitro and in vivo monitoring of degradation of fluorescently labeled hyaluronan hydrogels for tissue engineering applications. *Acta Biomater*. 2016;30:188-198. doi:10.1016/j.actbio.2015.11.053
10. Magalon J, Velier M, Simoncini S, et al. Molecular profile and proangiogenic activity of the adipose-derived stromal vascular fraction used as an autologous innovative medicinal product in patients with systemic sclerosis. *Ann Rheum Dis*. 2019;78(3):391-398. doi:10.1136/annrheumdis-2018-214218
11. Dykstra JA, Facile T, Patrick RJ, et al. Concise review: fat and furious: harnessing the full potential of adipose-derived stromal vascular fraction. *Stem Cells Transl Med*. 2017;6(4):1096-1108. doi:10.1002/sctm.16-0337
12. Mattei A, Magalon J, Bertrand B, Philandrianos C, Veran J, Giovanni A. Cell therapy and scarred vocal folds. *Eur Ann Otorhinolaryngol Head Neck Dis*. 2017;296(17):30103-30105.
13. Kumai Y, Kobler JB, Park H, et al. Crosstalk between adipose-derived stem/stromal cells and vocal fold fibroblasts in vitro. *Laryngoscope*. 2009;119(4):799-805. doi:10.1002/lary.20149
14. Kumai Y, Kobler JB, Park H, Galindo M, Herrera VL, Zeitels SM. Modulation of vocal fold scar fibroblasts by adipose-derived stem/stromal cells. *Laryngoscope*. 2010;120(2):330-337.
15. Hiwatashi N, Hirano S, Mizuta M, et al. Adipose-derived stem cells versus bone marrow-derived stem cells for vocal fold regeneration. *Laryngoscope*. 2014;124(12):E461-E469. doi:10.1002/lary.24816
16. Hiwatashi N, Hirano S, Suzuki R, et al. Comparison of ASCs and BMSCs combined with atelocollagen for vocal fold scar regeneration. *Laryngoscope*. 2016;126(5):1143-1150. doi:10.1002/lary.25667
17. Xu W, Hu R, Fan E, Han D. Adipose-derived mesenchymal stem cells in collagen-hyaluronic acid gel composite scaffolds for vocal fold regeneration. *Ann Otol Rhinol Laryngol*. 2011;120(2):123-130. doi:10.1177/000348941112000209
18. Kim YM, Oh SH, Choi JS, et al. Adipose-derived stem cell-containing hyaluronic acid/alginate hydrogel improves vocal fold wound healing. *Laryngoscope*. 2014;124(3):E64-E72. doi:10.1002/lary.24405
19. Kwon SK, Lee BJ. The combined effect of autologous mesenchymal stem cells and hepatocyte growth factor on vocal fold regeneration and fibrosis in vocal fold wound. *J Tissue Eng Regen Med*. 2008;5(4-6):735-742.
20. Shiba TL, Hardy J, Luegmair G, Zhang Z, Long JL. Tissue-engineered vocal fold mucosa implantation in rabbits. *Otolaryngol Head Neck Surg*. 2016;154(4):679-688. doi:10.1177/0194599816628501
21. Valerie A, Vassiliki K, Irini M, Nikolaos P, Karampela E, Apostolos P. Adipose-derived mesenchymal stem cells in the regeneration of vocal folds: a study on a chronic vocal fold scar. *Stem Cells Int*. 2016;2016:9010279. doi:10.1155/2016/9010279
22. de Bonnecaze G, Chaput B, Woisard V, et al. Adipose stromal cells improve healing of vocal fold scar: morphological and functional evidences. *Laryngoscope*. 2016;126(8):E278-E285. doi:10.1002/lary.25867
23. Hong SJ, Lee SH, Jin SM, et al. Vocal fold wound healing after injection of human adipose-derived stem cells in a rabbit model. *Acta Otolaryngol*. 2011;131(11):1198-1204. doi:10.3109/00016489.2011.599816
24. Hu R, Ling W, Xu W, Han D. Fibroblast-like cells differentiated from adipose-derived mesenchymal stem cells for vocal fold wound healing. *PLoS One*. 2014;9(3):e92676. doi:10.1371/journal.pone.0092676
25. Lee BJ, Wang SG, Lee JC, et al. The prevention of vocal fold scarring using autologous adipose tissue-derived stromal cells. *Cells Tissues Organs*. 2006;184(3-4):198-204. doi:10.1159/000099627
26. Atalay S, Coruh A, Deniz K. Stromal vascular fraction improves deep partial thickness burn wound healing. *Burns*. 2014;40(7):1375-1383. doi:10.1016/j.burns.2014.01.023
27. Bura A, Planat-Benard V, Bourin P, et al. Phase I trial: the use of autologous cultured adipose-derived stroma/stem cells to treat patients with non-revascularizable critical limb ischemia. *Cytotherapy*. 2014;16(2):245-257. doi:10.1016/j.jcyt.2013.11.011
28. Leblanc AJ, Tourou JS, Hoying JB, Williams SK. Adipose stromal vascular fraction cell construct sustains coronary microvascular function after acute myocardial infarction. *Am J Physiol Heart Circ Physiol*. 2012;302(4):H973-H982. doi:10.1152/ajpheart.00735.2011
29. Hashmi S, Ahmed M, Murad MH, et al. Survival after mesenchymal stromal cell therapy in steroid-refractory acute graft-versus-host disease: systematic review and meta-analysis. *Lancet Haematol*. 2016;3(1):e45-e52. doi:10.1016/S2352-3026(15)00224-0
30. Granel B, Daumas A, Jouve E, et al. Safety, tolerability and potential efficacy of injection of autologous adipose-derived stromal vascular fraction in the fingers of patients with systemic sclerosis: an open-label phase I trial. *Ann Rheum Dis*. 2015;74(12):2175-2182. doi:10.1136/annrheumdis-2014-205681
31. Karbiener M, Darnhofer B, Frisch MT, Rinner B, Birner-Gruenberger R, Gugatschka M. Comparative proteomics of paired vocal fold and oral mucosa fibroblasts. *J Proteomics*. 2017;155:11-21. doi:10.1016/j.jprot.2017.01.010
32. Mattei A, Magalon J, Bertrand B, et al. Autologous adipose-derived stromal vascular fraction and scarred vocal folds: first clinical case report. *Stem Cell Res Ther*. 2018;9(1):202. doi:10.1186/s13287-018-0842-0
33. Bourin P, Bunnell BA, Casteilla L, et al. Stromal cells from the adipose tissue-derived stromal vascular fraction and culture expanded adipose tissue-derived stromal/stem cells: a joint statement of the International Federation for Adipose Therapeutics and Science (IFATS) and the International Society for Cellular Therapy (ISCT). *Cytotherapy*. 2013;15(6):641-648. doi:10.1016/j.jcyt.2013.02.006
34. Dejonckere PH, Bradley P, Clemente P, et al; Committee on Phoniatrics of the European Laryngological Society (ELS). A basic protocol for functional assessment of voice pathology, especially for investigating the efficacy of (phonosurgical) treatments and evaluating new assessment techniques: guideline elaborated by the Committee on Phoniatrics of the European Laryngological Society (ELS). *Eur Arch Otorhinolaryngol*. 2001;258(2):77-82. doi:10.1007/s004050000299
35. Hirano M. Psycho-acoustic evaluation of voice: GRBAS Scale for evaluating the hoarse voice. In: Hirano M, ed. *Clinical Examination of Voice*. Wien, Germany: Springer Verlag; 1981:81-84.
36. Jacobson B, Johnson A, Grywalski C, et al. The Voice Handicap Index (VHI): development and validation. *Am J Speech Lang Pathol*. 1997;6:66-70. doi:10.1044/1058-0360.0603.66
37. Ware JE, Kosinski M, Gandek B. *SF-36® Health Survey: Manual & Interpretation Guide*. Lincoln, RI: QualityMetric Inc; 1993.
38. Ware JE, Kosinski M, Keller SD. *SF-36 Physical and Mental Health Summary Scales: A User's Manual*. Boston, MA: The Health Institute; 1994.
39. Chhetri DK, Berke GS. Injection of cultured autologous fibroblasts for human vocal fold scars. *Laryngoscope*. 2011;121(4):785-792. doi:10.1002/lary.21417
40. MedDRA MSSO. *Medical Dictionary for Regulatory Activities*. Version 21.0. <https://www.meddra.org/>. Accessed November 1, 2018.
41. Daumas A, Magalon J, Jouve E, et al. Long-term follow-up after autologous adipose-derived stromal vascular fraction injection into fingers in systemic sclerosis patients. *Curr Res Transl Med*. 2017;65(1):40-43. doi:10.1016/j.retram.2016.10.006
42. Guillaume-Jugnot P, Daumas A, Magalon J, et al. Autologous adipose-derived stromal vascular fraction in patients with systemic sclerosis: 12-month follow-up. *Rheumatology (Oxford)*. 2016;55(2):301-306. doi:10.1093/rheumatology/kev323
43. Young WG, Hoffman MR, Koszewski JJ, Whited CW, Ruel BN, Dailey SH. Voice outcomes following a single office-based steroid injection for

- vocal fold scar. *Otolaryngol Head Neck Surg.* 2016; 155(5):820-828. doi:10.1177/0194599816654899
44. Svensson B, Nagubothu SR, Nord C, et al. Stem cell therapy in injured vocal folds: a three-month xenograft analysis of human embryonic stem cells. *Biomed Res Int.* 2015;2015:754876. doi:10.1155/2015/754876
45. Hertegård S, Cedervall J, Svensson B, et al. Viscoelastic and histologic properties in scarred rabbit vocal folds after mesenchymal stem cell injection. *Laryngoscope.* 2006;116(7):1248-1254. doi:10.1097/01.mlg.0000224548.68499.35
46. Rohban R, Pieber TR. Mesenchymal stem and progenitor cells in regeneration: tissue specificity and regenerative potential. *Stem Cells Int.* 2017; 2017:5173732. doi:10.1155/2017/5173732
47. Vizoso FJ, Eiro N, Cid S, Schneider J, Perez-Fernandez R. Mesenchymal stem cell secretome: toward cell-free therapeutic strategies in regenerative medicine. *Int J Mol Sci.* 2017;18(9): E1852. doi:10.3390/ijms18091852
48. Ma OK, Chan KH. Immunomodulation by mesenchymal stem cells: interplay between mesenchymal stem cells and regulatory lymphocytes. *World J Stem Cells.* 2016;8(9):268-278. doi:10.4252/wjsc.v8.i9.268
49. Li N, Hua J. Interactions between mesenchymal stem cells and the immune system. *Cell Mol Life Sci.* 2017;74(13):2345-2360. doi:10.1007/s00018-017-2473-5
50. Song Y, Peng C, Lv S, et al. Adipose-derived stem cells ameliorate renal interstitial fibrosis through inhibition of EMT and inflammatory response via TGF- β 1 signaling pathway. *Int Immunopharmacol.* 2017;44:115-122. doi:10.1016/j.intimp.2017.01.008
51. Hiwatashi N, Bing R, Kraja I, Branski RC. Mesenchymal stem cells have antifibrotic effects on transforming growth factor- β 1-stimulated vocal fold fibroblasts. *Laryngoscope.* 2017;127(1):E35-E41. doi:10.1002/lary.26121
52. Hirose Y, Funahashi Y, Matsukawa Y, et al. Comparison of trophic factors secreted from human adipose-derived stromal vascular fraction with those from adipose-derived stromal/stem cells in the same individuals. *Cytotherapy.* 2018;20(4): 589-591. doi:10.1016/j.jcyt.2018.02.001
53. Wynn TA, Ramalingam TR. Mechanisms of fibrosis: therapeutic translation for fibrotic disease. *Nat Med.* 2012;18(7):1028-1040. doi:10.1038/nm.2807
54. Domergue S, Bony C, Maumus M, et al. Comparison between stromal vascular fraction and adipose mesenchymal stem cells in remodeling hypertrophic scars. *PLoS One.* 2016;11(5):e0156161. doi:10.1371/journal.pone.0156161
55. Hantzakos A, Dikkers FG, Giovanni A, et al. Vocal fold scars: a common classification proposal by the American Laryngological Association and European Laryngological Society. *Eur Arch Otorhinolaryngol.* 2019;276(8):2289-2292. doi:10.1007/s00405-019-05489-3