



HAL
open science

A new approach in the clinical decision-making for cerebral palsy using three-dimensional subject-specific musculoskeletal reconstructions.

Abir Massaad, Ayman Assi, Ziad Bakouny, Wafa Skalli, Ismat Ghanem

► To cite this version:

Abir Massaad, Ayman Assi, Ziad Bakouny, Wafa Skalli, Ismat Ghanem. A new approach in the clinical decision-making for cerebral palsy using three-dimensional subject-specific musculoskeletal reconstructions.. Lebanese Medical Journal, 2016, 64 (3), pp.152-159. 10.12816/0031524. hal-02479221

HAL Id: hal-02479221

<https://hal.science/hal-02479221>

Submitted on 14 Feb 2020

HAL is a multi-disciplinary open access archive for the deposit and dissemination of scientific research documents, whether they are published or not. The documents may come from teaching and research institutions in France or abroad, or from public or private research centers.

L'archive ouverte pluridisciplinaire **HAL**, est destinée au dépôt et à la diffusion de documents scientifiques de niveau recherche, publiés ou non, émanant des établissements d'enseignement et de recherche français ou étrangers, des laboratoires publics ou privés.

A NEW APPROACH IN THE CLINICAL DECISION-MAKING FOR CEREBRAL PALSY USING THREE-DIMENSIONAL SUBJECT-SPECIFIC MUSCULOSKELETAL RECONSTRUCTIONS

Abir MASSAAD^{1,2}, Ayman ASSI^{1,3}, Ziad BAKOUNY¹, Wafa SKALLI³, Ismat GHANEM^{1,4}

ABSTRACT • Cerebral palsy (CP) is a neurological disorder which can cause muscular spasticity. Children with this condition suffer from a combination of gait deviations, skeletal deformities and muscular abnormalities. Precise evaluation of each of these three components is crucial for management planning in children with CP. The aim of this study is to review the latest innovative methods used for three-dimensional (3D) gait analysis and musculoskeletal modeling in children with cerebral palsy. 3D gait analysis is a quantitative objective method based on the use of infrared cameras. It allows the evaluation of dynamic joint angles, forces and moments applied on joints and is usually coupled with dynamic electromyography. Skeletal evaluation is usually based on two-dimensional X-rays and physical examination in clinical practice. However, a novel method based on stereoradiographic 3D reconstruction of biplanar low dose X-rays allows a more thorough evaluation of skeletal deformities, and in particular torsional anomalies. Muscular evaluation of children with CP is most commonly based on magnetic resonance imaging, whereby delimitation of lower limb muscles on axial slices allows 3D reconstruction of these muscles. Novel innovative techniques allow similar reconstructions by extrapolation, thus limiting the necessary quantity of axial slices that need to be manually delimited.

Keywords: cerebral palsy, three-dimensional, musculoskeletal reconstruction, gait analysis, modeling

INTRODUCTION

Cerebral palsy (CP) is a neurological disorder that can cause abnormal muscle tone. The increased muscle tone of patients with CP is known to affect their posture and walking pattern [1]. Spasticity, posture abnormalities, delays in gaining independent walking and gait alterations, conjointly cause skeletal malalignments of the lower limbs in the three planes [2, 3]. Although the primary neurological problem is not progressive, the muscle

RÉSUMÉ • La paralysie cérébrale (PC) est un syndrome neurologique qui peut causer une spasticité musculaire. Les enfants ayant ce syndrome souffrent d'une combinaison de troubles de la marche, déformations squelettiques et anomalies musculaires. L'évaluation précise de chacune de ces trois composantes est cruciale dans la prise en charge des enfants ayant une PC. Le but de cette étude est de passer en revue les méthodes innovatrices utilisées pour l'analyse de la marche tridimensionnelle (3D) et la modélisation musculo-squelettique chez les enfants ayant une PC. L'analyse quantifiée de la marche permet l'évaluation des angles dynamiques articulaires, des forces et moments articulaires et est couplée à une électromyographie dynamique. L'évaluation squelettique est habituellement basée sur des radiographies bidimensionnelles et l'examen clinique. En revanche, une nouvelle méthode basée sur une reconstruction 3D stéréoradiographique des radiographies biplanaires à basse dose d'irradiation permet l'évaluation des troubles de torsion. L'évaluation musculaire des enfants ayant une PC est le plus souvent basée sur l'imagerie par résonance magnétique, durant laquelle la délimitation des contours musculaires des membres inférieurs sur les coupes axiales permet la reconstruction musculaire en 3D. Une méthode innovatrice permet des reconstructions musculaires grâce à des extrapolations, limitant ainsi le nombre nécessaire de coupes axiales à délimiter manuellement.

pathology does progress with growth affecting muscle morphology [4].

The assessment of gait pathology as well as skeletal and muscular abnormalities is mandatory for optimal treatment in children with CP. Three-dimensional gait analysis (3DGA) is usually used for the diagnosis of gait pathology in children with CP [1, 5]. 3DGA allows the simultaneous analysis of kinematics and kinetics of lower limb joints along with dynamic muscular activity. Physical examination [6, 7], and two-dimensional (2D) X-rays are used in daily practice to assess skeletal abnormalities in children with CP. However, torsional abnormalities, such as excessive femoral anteversion or tibial torsion, are frequently encountered in children with CP and cannot be measured using conventional 2D X-rays [8]. The assessment of muscle length, volume and cross-sectional area in children with CP is most commonly based on either ultrasonography or MRI. These techniques often

¹Laboratory of Biomechanics and Medical Imaging, Faculty of Medicine, Saint-Joseph University (USJ), Beirut, Lebanon.

²SESOBEL, Aintoura, Lebanon.

³Institut de Biomécanique Humaine Georges Charpak, Arts et Métiers, ParisTech, Paris, France.

⁴Hôtel-Dieu de France Hospital, USJ, Beirut, Lebanon.

Corresponding author: Ayman Assi, PhD.
e-mail: ayman.assi@gmail.com

require the intervention of an operator and are considered to be very time consuming [9].

Novel management strategies of children with CP require an integrated approach combining 3DGA and assessment of musculoskeletal abnormalities in the three planes. In this study we will be exposing the latest innovative methods used for three-dimensional gait analysis and musculoskeletal modeling in children with cerebral palsy.

NATURAL HISTORY of MUSCULOSKELETAL ANOMALIES in CHILDREN with CEREBRAL PALSY

The primary problem of children with CP is abnormally excessive muscle tone. The increased muscle tone in children with CP limits children's mobility and therefore successive muscular contraction and relaxation. The repetitive sequence of contraction and relaxation is normally crucial for muscle development [4]. The lack of such normal development leads to the occurrence of muscle contractures in children with CP, with an ensuing decrease in muscle length [10].

At a young age, management of children with CP is aimed at decreasing muscle spasticity, mainly with botulinum toxin injections [11] and baclofen pumps [12], in order to limit the development of muscle contractures. After the onset of muscle contractures, and because of the eventual deficiency of the muscle-tendon unit, children with CP start to develop lever arm dysfunction [13], whereby abnormal forces and moments are exercised on their joints. This eventually leads to a variety of skeletal deformities such as hip dislocation, torsional deformities of long bones, and/or foot deformities [4, 13].

Along with the muscular and skeletal abnormalities of these children, anomalies in gait frequently develop in these patients. These gait deviations can vary in severity and can be either causes or consequences of the musculoskeletal deformities in children with CP [1].

Consequently, children with such gait anomalies often require targeted surgical treatment of their musculoskeletal deformities in order to improve their walking abilities.

Such surgeries necessitate accurate assessment of both the morphological and dynamic problems of these children.

We will be exposing innovative methods which allow quantitative evaluation of both gait and musculoskeletal anomalies in children with CP using 3D subject-specific reconstruction of musculoskeletal geometry.

THREE-DIMENSIONAL GAIT ANALYSIS

Three-dimensional gait analysis has radically changed the orthopedic treatment of children with CP [14]. Surgical recommendations from experienced surgeons in the treatment of cerebral palsy have been shown to change in up to 52% of cases [15], with a resultant decrease in surgical procedures and associated reduction in treatment costs. The most frequently used system for 3DGA is based on the use of optoelectronic cameras. These cameras transmit and receive infrared light in order to calculate the position of reflective markers located on body segments. The placement of reflective markers is based on previously validated biomechanical models. The Davis protocol is the most frequently used lower limb biomechanical model for gait analysis [16].

Using mathematical calculations, the variation of angles between adjacent skeletal segments during a gait cycle is made possible by 3DGA. Joint angles are commonly calculated at the level of the pelvis, hips, knees and ankles in the three planes. These data will be displayed as curves and are called *gait kinematics*. Furthermore, force plates imbedded in the floor are used to record the forces applied by the patient on the floor during gait. These are referred to as *gait kinetics* and are used in order to calculate moments applied on the different joints of the lower limbs in the three planes.

Simultaneously with kinematic and kinetic data acquisition, muscle activity is studied using surface electromyography (EMG). The patterns of muscle activation during gait complement the understanding of the gait of subjects with CP (Figure 1).

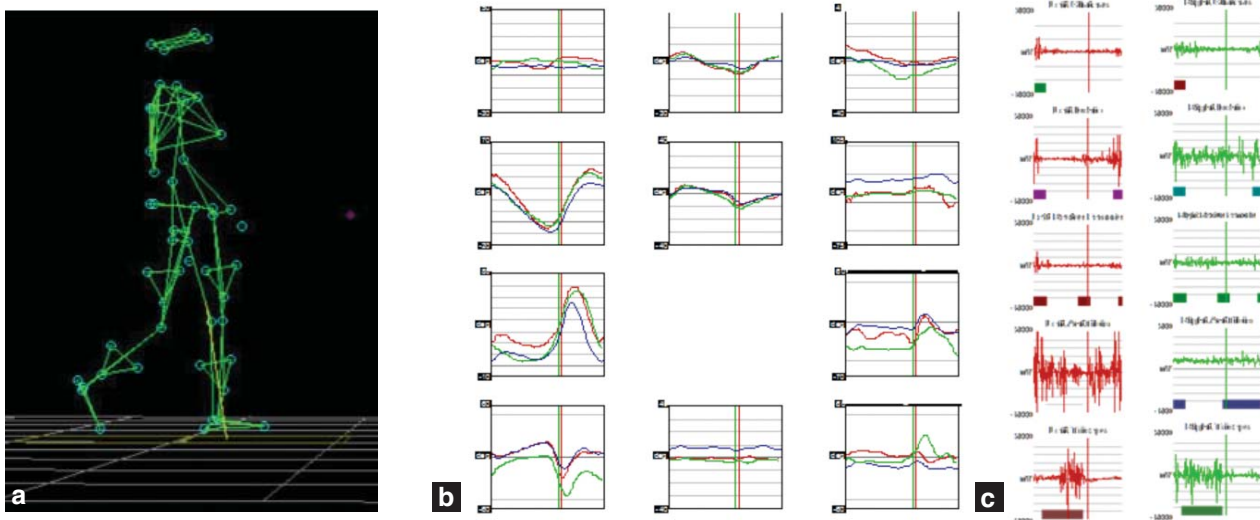


FIGURE 1. Three-dimensional gait analysis: a) 3D motion capture b) Joint kinematics in the 3 planes (sagittal, frontal and horizontal) of the pelvis, hips, knees, ankles and feet during a gait cycle c) EMG of lower limb muscles during the gait cycle

The quantitative analysis of gait using 3DGA has led to a greater understanding of the gait pathology of patients with cerebral palsy. This has culminated in the elaboration of classifications which subdivide the gait of these patients into multiple types. Multiple cerebral palsy gait pathology classifications, based on gait kinematics, have been developed for patients with cerebral palsy with either hemiplegia or diplegia.

The Sutherland classification for patients with spastic diplegia is based on knee kinematics in the sagittal plane and divides gait into the following four patterns: crouch gait, stiff knee gait, recurvatum knee gait and jump knee gait [17].

Roda *et al.* also described a classification of gait pathology for subjects with spastic diplegia which is based on the sagittal plane kinematics of the ankles, knees, hips and pelvis [18]. This classification divides the gait of subjects with cerebral palsy into the following five types of gait: true equinus, jump gait, apparent equinus, crouch gait and asymmetric gait.

A classification for patients with spastic hemiplegia

was also described by Winter *et al.*, who subdivided the gait of this population into four types of gait patterns (from I to IV), wherein the severity of the gait pathology increases from type I to IV [19].

These classifications have allowed the standardization of inter-clinician communication and allow the clinician to guide his decision-making depending on the type of gait pathology.

Furthermore, children with CP often present to the clinician with a complex combination of primary gait deviations with ensuing secondary and tertiary gait compensations. The interpretation of kinematic, kinetic and EMG data derived from 3DGA allows the clinician to differentiate primary gait problems from secondary and tertiary compensatory mechanisms. This has become an essential part of the management of patients with cerebral palsy, whereby clinicians only aim to treat primary gait problems and not compensatory mechanisms, that would resolve after treatment of the primary problems [13]. These compensatory mechanisms do not therefore necessitate treatment specifically targeted at their correction.

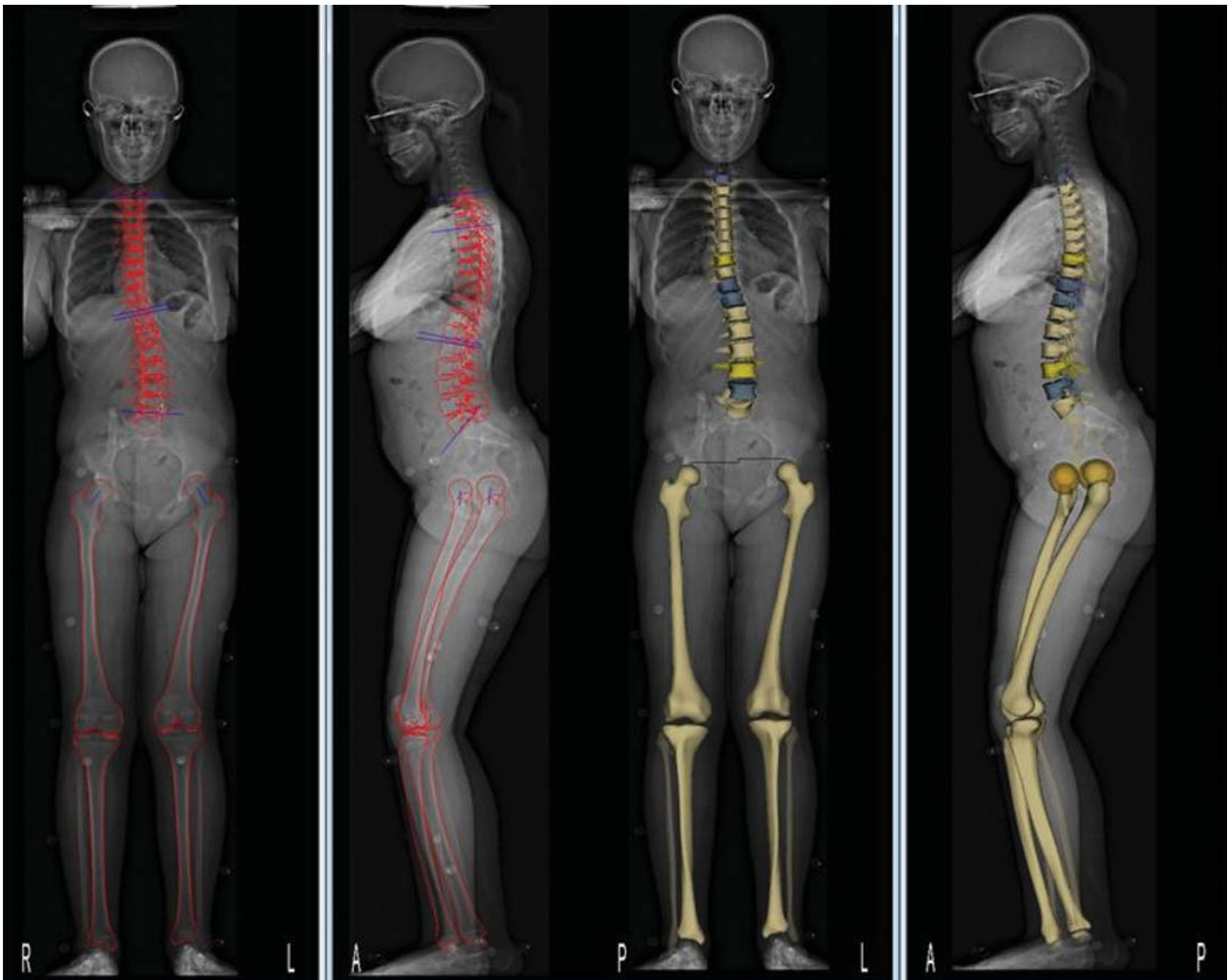


FIGURE 2. Three-dimensional skeletal reconstruction of the spine and lower limbs using the EOS® system.

Moreover, 3DGA has become an essential tool in the evaluation of treatment outcomes in children with CP, both in clinical and research settings [1]. Such objective and quantitative treatment evaluation allows clinicians to evaluate whether a procedure was successful and to evaluate the need for further complementary procedures to be performed.

Furthermore, musculoskeletal modeling associated with gait analysis are widely used in the literature [20, 21] using the OpenSim® software. This modeling software allows the creation of simulations and the calculation of internal joint forces and lever arms. OpenSim® is known to be easy to use and the model used in this software is mainly generic and can be partially personalized.

THREE-DIMENSIONAL SKELETAL RECONSTRUCTION

The assessment of skeletal malalignments is of paramount importance in surgical decision-making for children with CP [22]. It is usually based on physical examination and 2D X-ray imaging [7, 23]. These diagnostic tools lack accurate evaluation of skeletal deformities in the transverse plane, such as abnormal femoral anteversion and tibial torsion, which are frequently encountered in children with CP.

Computed tomography (CT) and magnetic resonance imaging (MRI) allow the evaluation of torsional deformities in either 2D or 3D [24, 25]. However, each of these methods has some limitations. Two-dimensional CT has been shown to have limited precision in evaluating torsional parameters and 3D CT is regarded as entailing an unacceptably high dose of irradiation, which limits its use in daily practice [23]. Furthermore, MRI has been previously shown to underestimate femoral anteversion and is often regarded as being too expensive and time-consuming for use in clinical practice [26].

Low dose biplanar full body X-rays with stereoradiographic 3D reconstruction (Figure 2) of skeletal segments (EOS®) [27] is a reliable and novel method which allows accurate evaluation of lower limb and pelvic skeletal parameters, among which femoral anteversion and tibial torsion, in children with cerebral palsy [28].

The acquisition is performed in the free standing position, whereby the subject is asked to stand with his feet facing forward and his shoulders flexed to about 30° [29]. Two X-ray tubes, equipped with collimators and specific gas-based detectors that limit radiation diffusion, scan the full body of the subject with an acquisition time of 5 to 10 seconds.

The semi-automated reconstruction first requires the operator to use geometrical shapes and axes in order to localize specific bony landmarks of the lower limbs. A personalized model of each skeletal segment is then generated and adjusted by the operator. The final adjusted 3D model is then used for the calculation of relevant 3D skeletal parameters (Figure 3), among which: femoral anteversion, neck shaft angle, knee valgus angle, tibial mechanical angle and tibial torsion. These reconstruction techniques have been previously validated in the literature [30-34].

Pelvic 3D reconstruction is a new tool which is based on the same reconstruction technique [35-37]. This reconstruction allows the calculation of commonly used sagittal pelvic parameters such as pelvic incidence, sacral slope and pelvic tilt. Furthermore, the importance of the 3D reconstruction of the pelvis is that it allows the evaluation of acetabular orientation parameters in the three planes, such as: acetabular abduction, anteversion and tilt.

The relationship between the femoral head and the acetabulum can also be quantified by the percentage of coverage of the femoral head by the acetabulum

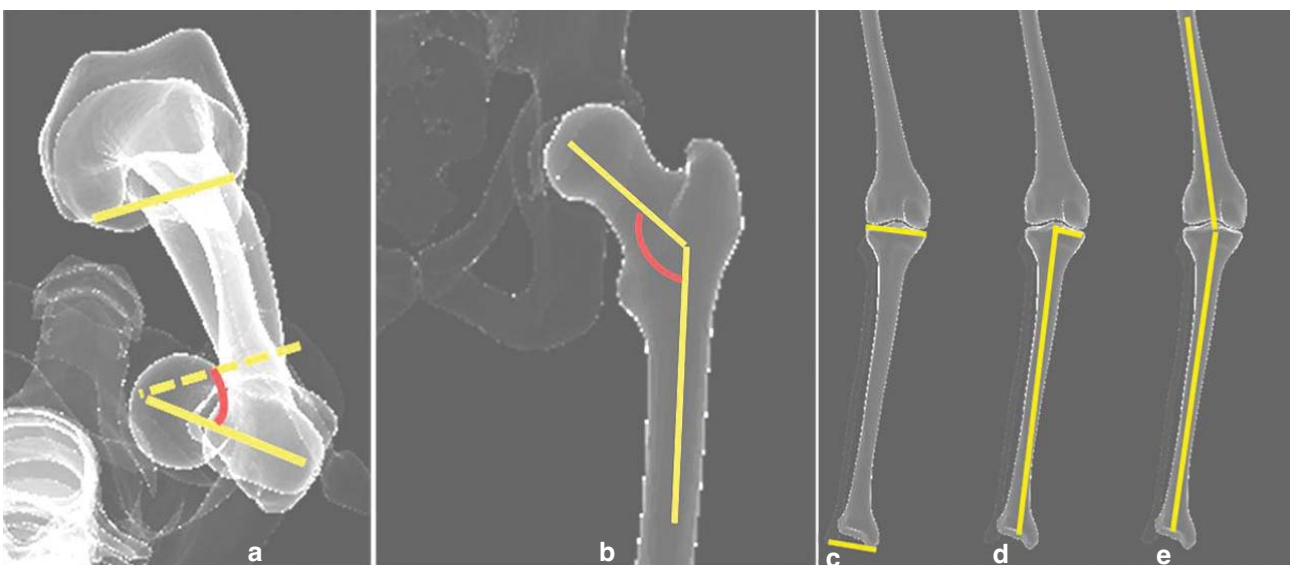


FIGURE 3. Illustration of three-dimensional lower limb parameters **a)** Femoral anteversion **b)** Neck shaft angle **c)** Tibial torsion **d)** Tibial mechanical angle **e)** Knee valgus angle

(Figure 4). Such parameters can be crucial in the evaluation of a variety of hip disorders in children with CP. A further added value of such a technique is that it is performed in the, functionally relevant, standing position.

The simultaneous acquisition of the whole body in the standing position also allows the calculation of the following 2D and 3D postural parameters in the frontal and lateral planes: coronal plumb line offset, sagittal vertical axis, spino-sacral angle, thoracic kyphosis, T1 and T9 tilt, lumbar lordosis and knee flexion. These parameters are important for the quantification of postural anomalies, which are frequently encountered in children with CP. For example, a recent study comparing children with spastic cerebral palsy to a control group of typically developing children found that children with CP had anatomical and positional pelvic anomalies, with most notably a sig-

nificant increase in pelvic incidence and sacral slope in children with CP [38]. Furthermore, femoral anteversion and neck-shaft angle were found to be increased in children with CP [39]. Such proximal femoral deformities are known to affect gait patterns in this population and are commonly treated with osteotomies. However, slightly affected children with spastic CP were not found to have anomalies in acetabular orientation when compared to typically developing children [38].

THREE-DIMENSIONAL MUSCULAR RECONSTRUCTION

Muscle spasticity is the primary problem in children with cerebral palsy. It affects muscle morphology during growth with significant reduction in muscle lengths and volumes [40].

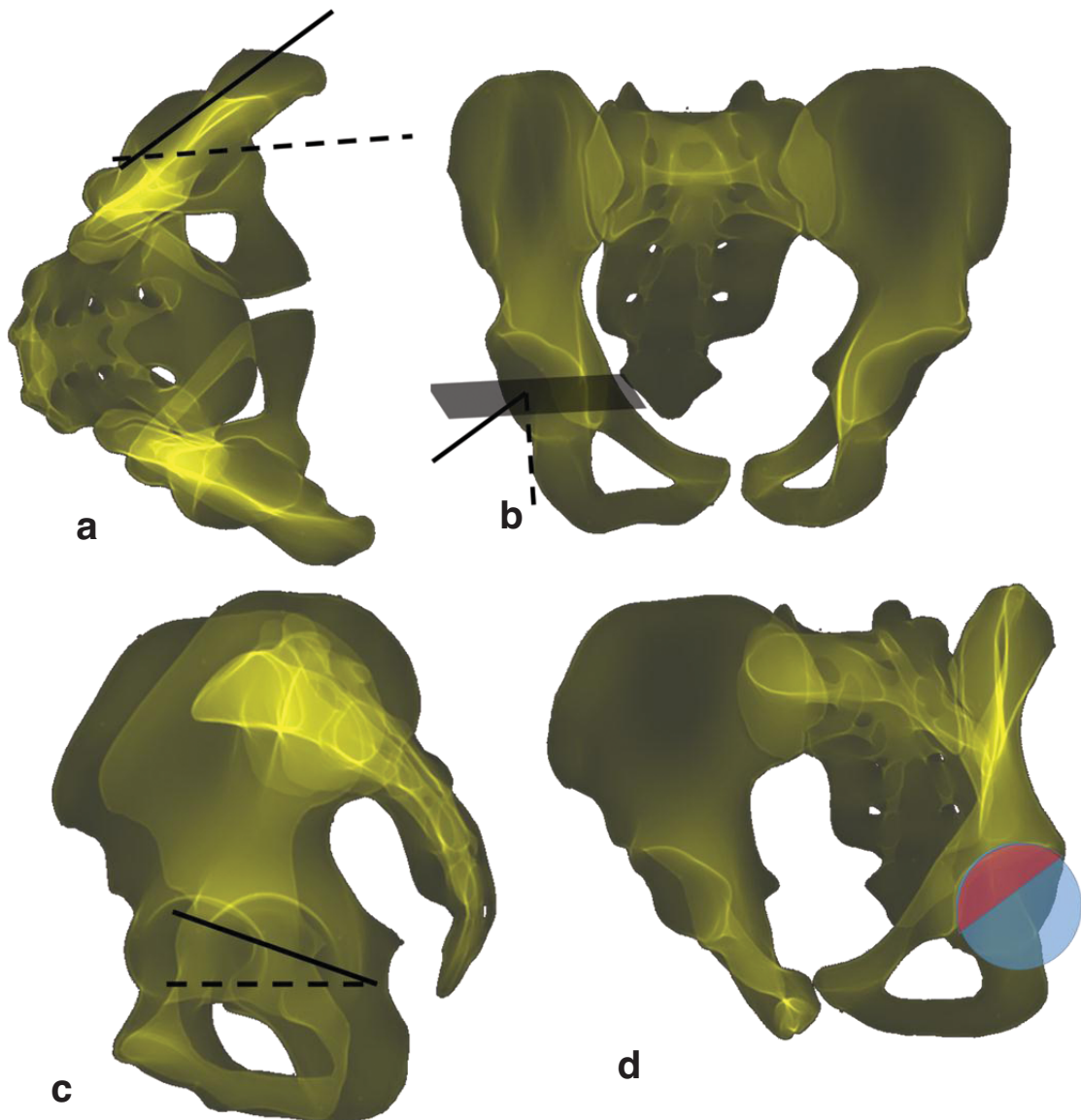


FIGURE 4. Illustration of three-dimensional acetabular orientation and coverage parameters
a) Acetabular anteversion b) Acetabular abduction c) Acetabular tilt d) Acetabular coverage

The precise evaluation of muscle morphology is essential for the comprehension of how muscular abnormalities evolve during growth in children with CP. Understanding these changes is of paramount importance because muscle spasticity, contracture and abnormal morphology could cause skeletal deformities and gait anomalies.

Muscle lengths (normalized to limb or whole body length), volume and cross-sectional area (normalized to body mass index) are frequently used as quantitative tools for the assessment of muscle morphology [41]. While computed tomography is considered the gold standard for the evaluation of skeletal morphology and also allows visualization of lower limb muscles, a detailed study of lower limb muscles by CT would entail an unacceptable amount of X-ray exposure.

Furthermore, while ultrasonography has the advantage of being a non-ionising and cost-effective technique, it can only be used to study superficial muscle groups [42-44].

The MRI technique has shown to be an accurate method for the evaluation of muscle morphology [45]. It is a non-invasive, non-ionising technique which allows the study of the totality of lower limb muscles.

The use of MRI for the determination of muscle morphology parameters would require the 3D reconstruction of all lower limb muscles by manually delimitating each muscle in each axial slice [46]. However, a recently described semi-automatic method allows 3D reconstruction of lower limb muscles by delimitating muscle contours on a reduced number of axial slices. These contours are then extrapolated to the whole belly muscle surface. This technique has been previously validated and allows the reduction of the time necessary for the 3D reconstruction of lower limb muscles [47, 48] (Figure 5).

The gastrocnemii and solei muscles have been the most studied muscles in the literature, primarily using the ultrasonography-based technique. Multiple studies have concluded that gastrocnemius volume, cross-sectional area and fascicle length are significantly reduced in spastic children with CP compared to typically developing children [40, 43].

While children with CP are known to present increased distal motor impairment [49], proximal muscle morphology seems to also be affected. The cross-sectional area and fascicle length of the rectus femoris have been shown to be reduced by 48.5% and 27% (respectively) in children with CP compared to typically developing children [50].

A study based on 3D MRI reconstruction of lower limb muscles has shown that hamstrings, quadriceps, gastrocnemii, solei and anterior tibialis muscle volumes are significantly reduced in children with CP compared to typically developing children [51, 52]. Muscle lengths of the gastrocnemius, semi-membranosus, semi-tendinosus, rectus femoris and vastii have also been found to be significantly reduced in children with CP compared to typically developing children [51]. These alterations seem to be more pronounced in children with greater motor impairment [53].

These findings are important to consider when planning the management of children with CP since most muscular interventions aiming to improve muscle tone and gait in this population also decrease muscle volume, and consequently muscle strength [54, 55]. This is particularly true for the calf muscles which are known to be particularly weak in children with CP [56]. Clinicians should therefore particularly consider calf muscle morphology during management planning.

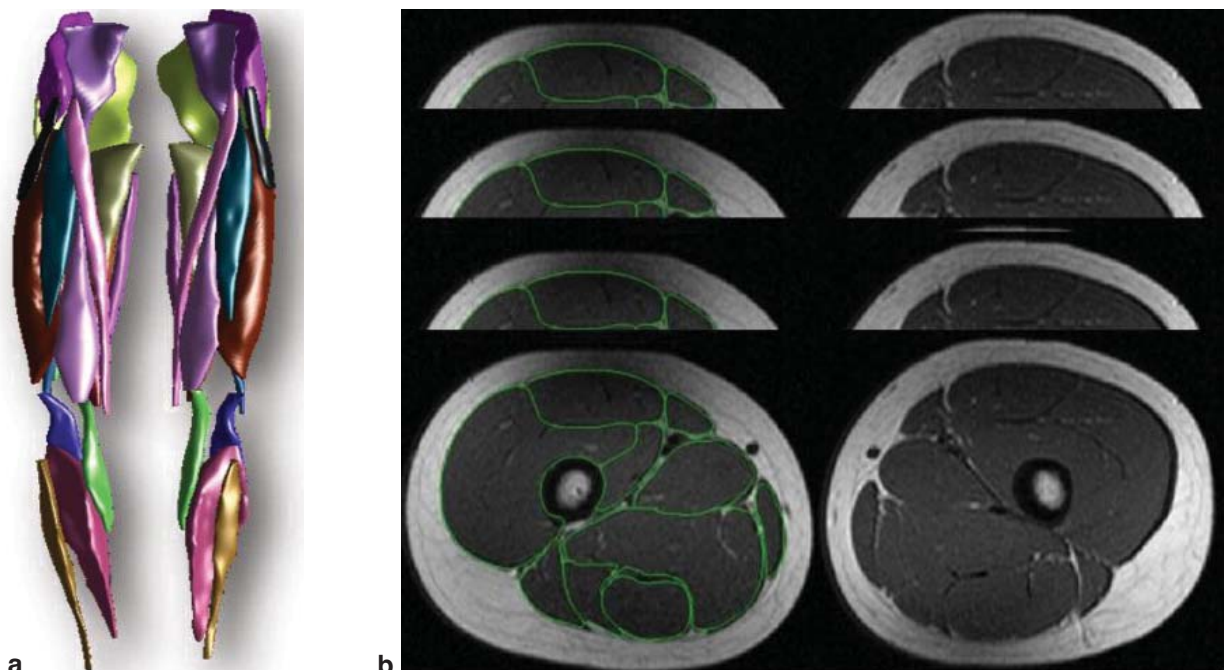


FIGURE 5. Three-dimensional lower limb muscle reconstructions: a) From axial slices b) Using magnetic resonance imaging

Furthermore, while all current measures of muscle length using MRI only consider belly muscle length (excluding the tendons), future work should further study whole muscle length.

Precisely evaluating the full length of muscles is crucial for accurate evaluation of lever arm anomalies, which are particularly frequent in children with cerebral palsy.

CONCLUSION

The management of children with spastic cerebral palsy has become increasingly reliant on an approach which evaluates three essential components: gait deviations, skeletal deformities and muscular morphology. The tools used for such an evaluation are 3D gait analysis as well as skeletal and muscular subject-specific 3D reconstructions. The innovative, previously validated, methods described in this work have increased the precision of baseline, pre-operative and postoperative outcome evaluation. Work is in progress in order to evaluate the musculoskeletal deformities, using both 3D reconstructions of the skeleton and muscles, in different classifications of children with CP. Future work should focus on evaluating the dynamic changes of skeletal and muscular parameters during gait by combining musculoskeletal models, similar to those currently used in OpenSim® models, with 3D gait analysis. Such simulations, when personalized, could be used to predict surgical outcomes and accordingly adjust surgical management.

ACKNOWLEDGMENT

This study has been funded by the Research Council of Saint Joseph University (grant # FM 244) and the CEDRE project (grant N# 11 SCI F 44/L36).

REFERENCES

1. Gage JR, Novacheck TF. An update on the treatment of gait problems in cerebral palsy. *J Pediatr Orthop Part B/ Eur Paediatr Orthop Soc Pediatr Orthop Soc North Am* 2001; 10: 265-74.
2. Robin J, Graham HK, Selber P, Dobson F, Smith K, Baker R. Proximal femoral geometry in cerebral palsy: a population-based cross-sectional study. *J Bone Joint Surg Br* 2008; 90: 1372-9.
3. Aktas S, Aiona MD, Orendurff M. Evaluation of rotational gait abnormality in the patients cerebral palsy. *J Pediatr Orthop* 2000; 20: 217-20.
4. Kerr Graham H, Selber P. Musculoskeletal aspects of cerebral palsy. *J Bone Jt Surg* 2003; 85: 157-66.
5. Davids JR. Identification of common gait disruption patterns in children with cerebral palsy. *J Am Acad Orthop Surg* 2014; 22: 782-90.
6. Novacheck TF, Trost JP, Sohrweide S. Examination of the child with cerebral palsy. *Orthop Clin North Am* 2010; 41: 469-88.
7. Viehweger E, Bérard C, Berruyer A, Simeoni MC. Bilan articulaire des membres inférieurs d'un enfant atteint d'une infirmité motrice cérébrale. *Ann Readapt Med Phys* 2007; 50: 258-65.
8. Bobroff ED, Chambers HG, Sartoris DJ, Wyatt MP. Femoral anteversion and neck shaft angle in children with cerebral palsy. *Clin Orthop Relat Res* 1999; 364: 194-204.
9. Barrett R, Lichtwark G. Gross muscle morphology and structure in spastic cerebral palsy: a systematic review. *Dev Med Child Neurol* 2010; 52: 794-804.
10. Kheder A, Nair KPS. Spasticity: pathophysiology, evaluation and management. *Pract Neurol* 2012; 12: 289-98.
11. Heinen F, Desloovere K, Schroeder AS et al. The updated European Consensus 2009 on the use of Botulinum toxin for children with cerebral palsy. *Eur J Paediatr Neurol* 2010; 14: 45-66.
12. Mietton C, Nuti C, Dohin B et al. Clinical practices in in-rathecal baclofen pump implantation in children with cerebral palsy in France. *Ann Phys Rehabil Med* 2016; 9-11.
13. Novacheck TF, Gage JR. Orthopedic management of spasticity in cerebral palsy. *Childs Nerv Syst* 2007; 23: 1015-31.
14. Gage JR. Gait analysis. An essential tool in the treatment of cerebral palsy. *Clin Orthop Relat Res* 1993: 126-34.
15. DeLuca PA, Davis RB 3rd, Ounpuu S, Rose S. Alterations in surgical decision making in patients with cerebral palsy based on three-dimensional gait analysis. *J Pediatr Orthop* 1997; 17: 608-14.
16. Davis RB, Ounpuu S, Tyburski D, Gage JR. A gait analysis data collection and reduction technique. *Hum Mov Sci* 1991; 10: 575-87.
17. Sutherland DH, Davids JR. Common gait abnormalities of the knee in cerebral palsy. *Clin Orthop Relat Res* 1993; 288: 139-47.
18. Rodda JM, Graham HK, Carson L, Galea MP, Wolfe R. Sagittal gait patterns in spastic diplegia. *J Bone Joint Surg Br* 2004; 86: 251-8.
19. Winters TF Jr, Gage JR HR. Gait patterns in spastic hemiplegia in children and young adults. *J Bone Jt Surg Am* 1987; 69: 437-41.
20. Arnold AS, Delp SL. Rotational moment arms of the medial hamstrings and adductors vary with femoral geometry and limb position: Implications for the treatment of internally rotated gait. *J Biomech* 2001; 34: 437-47.
21. Scheys L, Spaepen A, Suetens P, Jonkers I. Calculated moment-arm and muscle-tendon lengths during gait differ substantially using MR based versus rescaled generic lower-limb musculoskeletal models. *Gait Posture* 2008; 28: 640-8.
22. Davids JR, Marshall AD, Blocker ER, Frick SL, Blackhurst DW. Femoral anteversion in children with cerebral palsy. *J Bone Jt Surg* 2003; 85: 481-8.
23. Ruwe PA, Gage JR, Ozonoff MB, DeLuca PA. Clinical determination of femoral anteversion. A comparison with established techniques. *J Bone Joint Surg Am* 1992; 74: 820-30.
24. Pons C, Rémy-Néris O, Médée B, Brochard S. Validity and reliability of radiological methods to assess proximal hip geometry in children with cerebral palsy: A systematic review. *Dev Med Child Neurol* 2013; 55: 1089-102.
25. Riccio AI, Carney CD, Hammel LC, Stanley M, Cassidy J, Davids JR. Three-dimensional computed tomography for determination of femoral anteversion in a cerebral palsy model. *J Pediatr Orthop* 2015; 35: 167-71.
26. Botser IB, Ozoude GC, Martin DE, Siddiqi AJ, Kuppiswami S. Femoral anteversion in the hip: comparison of measurement by computed tomography, magnetic

- resonance imaging, and physical examination. *Arthroscopy* 2012; 28: 619-27.
27. Chaibi Y, Cresson T, Aubert B et al. Fast 3D reconstruction of the lower limb using a parametric model and statistical inferences and clinical measurements calculation from biplanar X-rays. *Comput Methods Biomech Biomed Engin* 2012; 15: 457-66.
 28. Assi A, Chaibi Y, Presedo A, Dubouset J, Ghanem I, Skalli W. Three-dimensional reconstructions for asymptomatic and cerebral palsy children's lower limbs using a biplanar X-ray system: A feasibility study. *Eur J Radiol* 2013; 82: 2359-64.
 29. Steffen JS, Obeid I, Aurouer N et al. 3D postural balance with regard to gravity line: An evaluation in the transversal plane on 93 patients and 23 asymptomatic volunteers. *Eur Spine J* 2010; 19: 760-7.
 30. Folinais D, Thelen P, Delin C, Radier C, Catonne Y, Lazennec JY. Measuring femoral and rotational alignment: EOS system versus computed tomography. *Orthop Traumatol Surg Res* 2013; 99: 509-16.
 31. Escott BG, Ravi B, Weathermon AC et al. EOS low-dose radiography: A reliable and accurate upright assessment of lower-limb lengths. *J Bone Jt Surg* 2013; 95: e183.
 32. Guenoun B, Zadegan F, Aim F, Hannouche D, Nizard R. Reliability of a new method for lower-extremity measurements based on stereoradiographic three-dimensional reconstruction. *Orthop Traumatol Surg Res* 2012; 98: 506-13.
 33. Pomerantz LM, Glaser D, Doan J, Kumar S, Edmonds EW. Three-dimensional biplanar radiography as a new means of accessing femoral version: A comparative study of EOS three-dimensional radiography versus computed tomography. *Skeletal Radiol* 2015; 44: 255-60.
 34. Baudoin A, Skalli W, de Guise JA, Mitton D. Parametric subject-specific model for in vivo 3D reconstruction using bi-planar X-rays: Application to the upper femoral extremity. *Med Biol Eng Comput* 2008; 46: 799-805.
 35. Mitton D, Deschênes S, Laporte S et al. 3D reconstruction of the pelvis from bi-planar radiography. *Comput Methods Biomech Biomed Engin* 2006; 9: 1-5.
 36. Humbert L, Carlioz H, Baudoin A, Skalli W, Mitton D. 3D Evaluation of the acetabular coverage assessed by biplanar X-rays or single anteroposterior X-ray compared with CT-scan. *Comput Methods Biomech Biomed Engin* 2008; 11: 257-62.
 37. Ghostine B, Sauret C, Assi A et al. Influence of patient axial malpositioning on the trueness and precision of pelvic parameters obtained from 3D reconstructions based on biplanar radiographs. *Eur Radiol* 2016 doi: 10.1007/s00330-016-4452-x.
 38. Massaad A, Assi A, Bakouny Z, Sauret C, Khalil N, Skalli W. Three-dimensional evaluation of skeletal deformities of the pelvis and lower limbs in ambulant children with cerebral palsy. *Gait Posture* 2016. doi:0.1016/j.gaitpost.2016.06.029.
 39. Thépaut M, Brochard S, Leboucher J et al. Measuring physiological and pathological femoral anteversion using a biplanar low-dose X-ray system: validity, reliability, and discriminative ability in cerebral palsy. *Skeletal Radiol* 2016; 45: 243-50.
 40. Barber L, Hastings-Ison T, Baker R, Barrett R, Lichtwark G. Medial gastrocnemius muscle volume and fascicle length in children aged 2 to 5 years with cerebral palsy. *Dev Med Child Neurol* 2011; 53: 543-8.
 41. Handsfield GG, Meyer CH, Abel MF et al. Heterogeneity of muscle sizes in the lower limbs of children with cerebral palsy. *Muscle Nerve* 2016 Jun; 53 (6): 933-45.
 42. Fry NR, Gough M, Shortland AP. Three-dimensional realisation of muscle morphology and architecture using ultrasound. *Gait Posture* 2004; 20: 177-82.
 43. Mohagheghi AA, Khan T, Meadows TH, Giannikas K, Baltzopoulos V, Maganaris CN. In vivo gastrocnemius muscle fascicle length in children with and without diplegic cerebral palsy. *Dev Med Child Neurol* 2008; 50: 44-50.
 44. Matthiasdottir S, Hahn M, Yaraskavitch M, Herzog W. Muscle and fascicle excursion in children with cerebral palsy. *Clin Biomech* 2014; 29: 458-62.
 45. Engstrom CM, Loeb GE, Reid JG, Forrest WJ, Avruch L. Morphometry of the human thigh muscles. A comparison between anatomical sections and computer tomographic and magnetic resonance images. *J Anat* 1991; 176: 139-56.
 46. Lampe R, Grassl S, Mitternacht J, Gerdesmeyer L, Gradinger R. MRT-measurements of muscle volumes of the lower extremities of youths with spastic hemiplegia caused by cerebral palsy. *Brain Dev* 2006; 28: 500-6.
 47. Jolivet E, Daguet E, Pomero V, Bonneau D, Laredo JD, Skalli W. Volumic patient-specific reconstruction of muscular system based on a reduced dataset of medical images. *Comput Methods Biomech Biomed Engin* 2008; 11: 281-90.
 48. Hausselle J, Assi A, El Helou A et al. Subject-specific musculoskeletal model of the lower limb in a lying and standing position. *Comput Methods Biomech Biomed Engin* 2014; 17: 480-7.
 49. Fowler EG, Staudt LA, Greenberg MB. Lower-extremity selective voluntary motor control in patients with spastic cerebral palsy: Increased distal motor impairment. *Dev Med Child Neurol* 2010; 52: 264-9.
 50. Moreau N, Teeffey S, Damiano D. In vivo muscle architecture and size of the rectus femoris and vastus lateralis in children and adolescents with cerebral palsy. *Dev Med Child Neurol* 2009; 51: 800-6.
 51. Oberhofer K, Stott NS, Mithraratne K, Anderson IA. Subject-specific modelling of lower limb muscles in children with cerebral palsy. *Clin Biomech* 2010; 25: 88-94.
 52. Noble JJ, Fry NR, Lewis AP, Keevil SF, Gough M, Shortland AP. Lower limb muscle volumes in bilateral spastic cerebral palsy. *Brain Dev* 2014; 36: 294-300.
 53. Massaad A, Assi A, Sauret C et al. Comparison of subject-specific 3D musculoskeletal parameters between children with spastic cerebral palsy and typically developing children. *Gait Posture Suppl* 2015; 42: S36.
 54. Moreau NG, Simpson KN, Teeffey SA, Damiano DL. Muscle architecture predicts maximum strength and is related to activity levels in cerebral palsy. *Phys Ther* 2010; 90: 1619-30.
 55. Elder G, Kirk J, Steward G et al. Contributing factors to muscle weakness in children with cerebral palsy. *Dev Med Child Neurol* 2003; 45: 542-50.
 56. Eek MN, Beckung E. Walking ability is related to muscle strength in children with cerebral palsy. *Gait Posture* 2008; 28: 366-71.