



Fertiloscopy in women with unexplained infertility: Long-term cumulative pregnancy rate

Roxane Vanspranghels, Aurélie Abergel, Geoffroy Robin, Estelle Jean Dit
Gautier-Gaudenzi, Géraldine Giraudet, Chrystelee Rubod

► To cite this version:

Roxane Vanspranghels, Aurélie Abergel, Geoffroy Robin, Estelle Jean Dit Gautier-Gaudenzi, Géraldine Giraudet, et al.. Fertiloscopy in women with unexplained infertility: Long-term cumulative pregnancy rate. Journal of Gynecology Obstetrics and Human Reproduction, 2020, 49 (2), pp.101671. 10.1016/j.jogoh.2019.101671 . hal-02476546

HAL Id: hal-02476546

<https://hal.science/hal-02476546>

Submitted on 21 Jul 2022

HAL is a multi-disciplinary open access archive for the deposit and dissemination of scientific research documents, whether they are published or not. The documents may come from teaching and research institutions in France or abroad, or from public or private research centers.

L'archive ouverte pluridisciplinaire **HAL**, est destinée au dépôt et à la diffusion de documents scientifiques de niveau recherche, publiés ou non, émanant des établissements d'enseignement et de recherche français ou étrangers, des laboratoires publics ou privés.



Distributed under a Creative Commons Attribution - NonCommercial 4.0 International License

Fertiloscopy in Women with Unexplained Infertility: Long-Term Cumulative Pregnancy Rate

Roxane Vanspranghels¹, Aurélie Abergel¹, Geoffroy Robin², Estelle Jean Dit Gautier – Gaudenzi¹, Géraldine Giraudet¹, Chrystèle Rubod¹

¹ Gynecological Department, Jeanne de Flandre Hospital, University Hospital, Lille Cedex, 59037, France.

² CHU Lille, Department of Endocrine Gynecology and Reproductive Medicine, Hospital Jeanne de Flandre, 2, rue E. Avinée, F-59000 Lille, France

Corresponding author :

Pr Chrystèle Rubod

Gynecological Department, Jeanne de Flandre Hospital, CHRU Lille

Avenue Eugène Avinée, 59037 Lille Cedex, France

Tel: 0033 (0)3.20.44.6626 Fax: 0033 (0)3.20.44.63.11

Email: chrystele.rubod@chru-lille.fr

This research did not receive any specific grant from funding agencies in the public, commercial, or not-for-profit sectors.

Abstract

Objective. Fertiloscopy is as safe as laparoscopy in literature, but we don't know its relevance in women with unexplained infertility (UI). Our objective was to assess the effects of fertiloscopy procedures on the outcomes of subsequent pregnancy occurrences in patients with UI.

Methods. Retrospective, single-center study of all patients followed up after fertiloscopy procedures between 2002 and 2007. The occurrence and outcome of pregnancies were studied in the five years following the procedure.

Results. 124 fertiloscopies were performed. Pelvic exploration was considered as sufficient in 83.8% of cases, of which no abnormalities were found in 78.2%. Laparoconversions occurred for 19 patients (16.5%). The pregnancy rate at five years was 76.9%. The mean delay for pregnancy occurrence was 10.7 months (± 17).

Conclusion. The pregnancy rate in our study is similar to that after laparoscopy. Fertiloscopy, a less intrusive procedure, should be considered as a reliable option for the management of patients with UI.

Key words: unexplained infertility, fertiloscopy, laparoscopy, tubal disease

INTRODUCTION

[dataset] Infertility is a “disease of the reproductive system defined by the failure to achieve a clinical pregnancy after 12 months or more of regular unprotected sexual intercourse,” and it occurs in 10 to 15% of couples. Almost 15% of infertilities remain unexplained after a proper medical check-up [1], which traditionally relies on detailed anamnesis, a blood test assessing the ovulatory function of cycles, sperm analysis, and radiological exams traditionally including a pelvic ultrasound and a hysterosalpingography.

There is no perfect standard in the management of this kind of infertility, and it is still a matter of debate whether this check-up should include a laparoscopy. Surgery has two objectives: diagnostic and therapeutic. [dataset] Kahyaoglu et al. argue for laparoscopy because it may change the therapeutic strategy in 43 to 49% of cases [2]. [dataset] While medically assisted reproduction techniques are improving, the role of laparoscopy is still justified [3,4]. [dataset] It is even recommended as a first step in endometriotic patients [5].

[dataset] Currently, the literature primarily looks at exploratory laparoscopy combined or not with surgical treatment [6–8]. [dataset] Researchers recognize the economic benefit of laparoscopy compared to medically assisted reproduction as a first-line treatment [9].

[dataset] Fertiloscopy, as attested by FLY study [10,11], is a less intrusive approach than traditional laparoscopy. It has a low complication rate and seems as accurate as laparoscopy in exploring the pelvis. The technique consists of a transvaginal hydropelviscopy combined with hysteroscopy. For diagnostic purposes, this procedure offers obvious advantages (a less invasive approach, reduced morbidity, and ambulatory service) while allowing a complete exploration of the pelvis (except for the vesico-uterine pouch) with organ visualization in anatomical position. Moreover, it can substitute for therapeutic laparoscopy in some cases, as it allows for ovarian drilling and some limited adhesiolysis or

electrocoagulation of superficial endometriosis lesions. Nonetheless, fertiloscopy procedures are not in widespread use, with some arguing that the pelvic exploration is too partial and others claiming that the procedure adds surgical risks in cases of laparoconversion. Some authors describe the possibility of conducting fertiloscopy without general anesthesia, even if that is not the most common option chosen by patients. Few studies exist on this procedure, and even fewer on long-term outcomes in cases of unexplained infertility (UI).

The objective of our work was to study outcomes on pregnancy occurrence after fertiloscopy in patients with UI.

METHODS

This retrospective study included all patients who underwent fertiloscopy for UI between June 2007 and December 2012 in one center (Lille, France). Every patient was followed for five years after surgery.

Inclusion criteria

Patients with primary or secondary UI were assessed by the following criteria: infertility ≥ 12 months; normal clinical exam; ovulatory cycles and pelvic ultrasound either normal, with polyp, or approachable for hysteroscopic resection fibroma. Hysterosalpingography was consistently performed, and patients with normal or doubtful results were included. Sperm exams were normal. Patients suitable for fertiloscopy may or may not have had intra-uterine insemination. None of the patients had a contraindication for this exam: specifically, the clinical exam did not reveal an endometriotic lesion of the Douglas pouch or a fixed uterine retroversion.

[dataset] This study was approved by the French Data Protection Authority and relies partially on a previous published database [12]. Every patient in the medically assisted procreation program in our center was included in the InfoFIV database.

Surgical procedure

Every fertiloscopy was performed under general anesthesia and included first a transvaginal hydropelviscopy and then a hysteroscopy, but this operating order was reversed if an intra-uterine pathology that might prevent tubal permeability was suspected (e.g., a pre-ostial polyp or sub-mucous fibroid). In the absence of complications, the procedure was conducted in an ambulatory way. No prophylactic antibiotic treatment was administrated. Vaginal touch was done to ensure the absence of contraindications to hydropelviscopy.

The transvaginal hydropelviscopy began with the application of a Pozzy forceps on the posterior lip of the cervix. After Douglas-pouch identification, the posterior vaginal pouch was punctured with a Veress needle (springload needle) approximately one centimeter under the cervix. Five hundred milliliters of saline serum was instilled in free flow after safety tests. A sterilizable 5 mm metallic trocar was introduced into the peritoneal cavity, followed by a 2.9 mm optic (Storz®, 30° tilt) with its diagnostic folder. A complete and attentive examination of the pelvic cavity was performed, including the posterior side of the uterus, fallopian tubes, ovaries, and ovarian fossae. The utero-ovarian ligament and tubo-ovarian mobility were always identified. Exploration was considered as adequate if we had correctly explored the anatomical elements cited above. The hydropelviscopy concluded with a methylene-blue test for tubal permeability after catheterization of the uterine cavity by a Cohen canula. At the end, the liquid was evacuated through the 5 mm trocar. When the needle site did not bleed, the vaginal pouch was not sutured. A diagnostic hysteroscopy was then conducted, associated or not with a therapeutic action, followed by an endometrial biopsy with a No. 6 curette. In cases of hydrosopic-approach failure, non-satisfactory vision, or surgical indication, we proceeded to laparoconversion.

In our center, the laparoscopic approach as a first-line treatment is proposed only in cases of ovarian or tubal surgical gesture (ovarian cyst with surgical indication, hydrosalpinx, etc.), when endometriosis has been diagnosed by medical check-up, or when fertiloscopy is contra-indicated.

Post-surgery follow-up

After surgery, medically assisted procreation was proposed, either intra-uterine insemination or in-vitro fertilization according to surgical observations. Pregnancy was defined by the obtention of a positive human chorionic gonadotropin dosage outside the stimulation protocol. Only the first pregnancy was recorded.

Statistical analysis

The results are shown as median or mean and standard deviation. The data were analyzed with SPSS (IBM SPSS Statistics version 25).

RESULTS

Population

During our study period, 340 fertiloscopies were performed, 124 of them on patients with UI corresponding to our inclusion criteria. The patients' characteristics and their previous care for infertility are summarized in Table 1.

Surgical results

Two fertiloscopy complications were observed in our series, both of them uterine-wall perforations due to hysteroscopy and not to hydropelviscopy. In cases in which fertiloscopy did not succeed, the subsequent laparoscopy found pelvic endometriosis in three cases, and in one case the pelvic cavity was normal. 40% of laparoscopy conversion were proceeded in the first year of the study. When exploration was not satisfactory, laparoscopy found pelvic endometriosis in four patients, pelvic adhesions in three patients, unilateral distal-tubal obstruction in one patient, and nothing in the last patient. Hysteroscopy discovered 32 abnormalities, with only eight of them suspected in the pelvic ultrasound (Table 2).

Eighty (64.5%) procedures were conducted by a senior surgeon, 44 (33%) by a junior surgeon. Twenty-four patients (19%) underwent a therapeutic action during surgery.

Outcomes after fertiloscopy

Five-year outcomes were collected for 91 patients, which represented 73.4% of our initial population. They are summarized in Table 3. Seventy patients became pregnant, 50 of those (71%) in the year following surgery. Most underwent medically assisted reproduction. The global pregnancy rate in time is illustrated in Figure 1.

DISCUSSION

Our study is the first that provides information on pregnancy rates after fertiloscopy in patients with UI. Fertiloscopy exploration was satisfactory in 83.5% of our patients. Pelvic abnormalities were found in 22.2% of hydropelviscopies and 19.2% of hysteroscopies. Table 4 summarizes the literature on UI; except for our study, all data are about laparoscopic outcomes, and only one study considers laparoscopy and hysteroscopy. The pregnancy rate after surgery is very diverse from one study to another, ranging from 36.7% to 75%. In our series, we obtained a 76.9% pregnancy occurrence.

[dataset] Every patient with a satisfactory fertiloscopy had an ambulatory hospitalization. Some authors, such Watrelot et al. [13], even argue for the practice of conducting surgery under local anesthesia (19.2% in his series of 1490 patients). Fertiloscopy allows surgical actions; in addition to ovarian drilling, a minima adhesiolysis with surgical scissors or bipolar electrode can be performed.

Fertiloscopy is not a widespread technique, and its broader adoption is constrained by the necessity of learning it. [dataset] Franz et al. compared fertiloscopy's learning curve through 110 procedures at a 'beginner' and at an 'expert' center [14]; one case required a laparoconversion at the beginner center owing to an intraoperative complication (a punctiform rectal lesion). Median operating time was similar at both centers after 40 procedures. In our series, 33% of patients were operated on by a junior surgeon, with no increase in the complication rate, but we noticed more laparoconversion in the first year of the study.

One particularity of our study is that every patient underwent a hysteroscopy. [dataset] The Cochrane Database in 2013 evaluated the effects of hysteroscopy in cases of UI and found that its benefit was clearly demonstrated only in cases of uterine fibroids, with a possible improvement in endo-uterine polyps [15]. It was quite surprising to notice in our

series that only 25% of the anomalies found in hysteroscopy were suspected by echography. [dataset] This is in line with the findings of Seyam et al., who compared pregnancy occurrences at one year after hysteroscopy for UI; thirty percent of patients presented an endo-uterine anomaly, and the pregnancy rate was higher in the group that underwent hysteroscopy (28.5% vs. 15%) [16]. Nevertheless, hysteroscopy alone cannot make a complete diagnostic checkup of the pelvic floor.

In our series, hydropelviscopy was normal in 78.2% of our patients. [dataset] This rate is similar to that seen in the literature; in a study by Bohuz et al., 58 fertiloscopies (28.6%) out of 229 revealed lesions requiring laparoconversion [17], while Watrelot et al. [13] found no pathology in 67.1% of cases. This rate is considerably lower than the prevalence found in laparoscopy, in which between 60 and 83% of patients have an anomaly, as mentioned in Table 4.

This difference may be explained by divergent inclusion criteria; studies about laparoscopy often include patients with a longer period of infertility, or only those with abnormal hysterosalpingography, or patients with multiple failures of medically assisted reproduction. Another explication may be that hydropelviscopy does not provide access to the anterior side of the uterus or to the superior abdominal cavity. We may nonetheless question the imputability of such anomalies to our patients' fertility, in particular when the Douglas pouch and tubal function remain clear. Laparoscopy may diagnose additional anomalies whose impact on fertility is unclear.

One specificity of our study is the long follow-up period of five years. This long delay partially explains our loss of sight rate. Laparoscopic studies extend from six to 36 months of follow-up (Table 4).

[dataset] In Braidy and colleagues' literature review comparing fertiloscopy to laparoscopy, technical surgical aspects are emphasized [18]. They found an accordance on pathology diagnosis of 80% between the two techniques and a potential reduction of laparoscopy numbers of between 40 and 93%. In our study, pelvic exploration was satisfactory in 78% of the patients while avoiding laparoscopy. The pregnancy rate seems equal or even perhaps improved compared with laparoscopic studies, without any increase in the complication rate.

[dataset] The complication rate associated with the laparoscopic approach varies from one to 20 out of 1000 [19,20]. Trocar introduction may create parietal hematoma, umbilical hernia, or infection of puncture sites and also a vascular, digestive, or vesical lesion. No complication linked to hydropelviscopy was observed in our series. [dataset] The complication rate in the literature remains low: five complications (2.5%) without major consequence in Bohuz et al., including two rectal punctiform lesions, two hemorrhagic complications, and one post-operative salpingitis [17].

To conclude, we obtained in our series a similar pregnancy rate to that seen in the literature on the same type of population while avoiding laparoscopy in 80% of our patients, generally without complications. Fertiloscopy may be considered as a less invasive option in patients with UI after providing them with information on the risk of laparoconversion.

Practice points

- A surgical approach is considered with women with unexplained infertility.
- We know that fertiloscopy is a less intrusive approach than laparoscopy, but we don't know the outcomes on pregnancy rate in patients with unexplained infertility.

- In our study, pregnancy rate was 76.9% after fertiloscopy procedure, a similar rate to those after laparoscopy procedure.
- Fertiloscopy may be considered as a less invasive option in patients with unexplained infertility.

Research Agenda

Further research could focus on a randomized trial comparing fertiloscopy to laparoscopy on patients with unexplained fertility.

Table 1. Population characteristics.

Patients (n = 124)	Median (\pm standard deviation) or n (%)
Age (years)	30 (\pm 4.1)
Gravidity	
0	83 (66.9%)
≥ 1	41 (33.1%)
Parity	
0	103 (83.1%)
≥ 1	21 (16.9%)
Infertility type	
Primary	96 (77.4%)
Secondary	28 (22.6%)
Infertility duration (months) (min–max)	36 (12–132)
Hysterosalpingography	
Normal	52 (41.9%)
Subnormal	72 (58.1%)
In subnormal hysterosalpingographies:	
Unilateral obstacle	35 (47%)
Proximal	20 (57%)
Distal	15 (43%)
Bilateral obstacle	13 (17.5%)
Proximal	5 (38%)
Distal	4 (31%)
Proximal & distal	4 (31%)
Previous care in medically assisted procreation (intra-uterine insemination)	65 (52.4%)

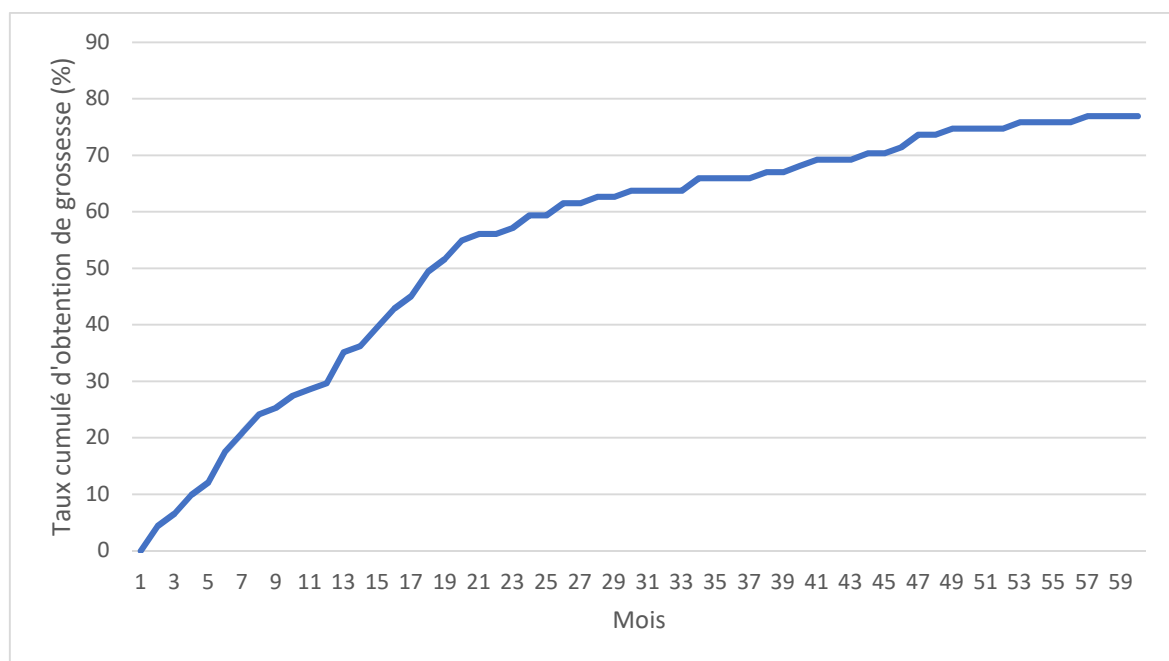
Table 2. Surgical results.

Fertiloscopy	n (%)
Satisfactory exploration	104 (83.8%)
Normal hydropelviscopy	97 (78.2%)
Pelvic pathology [diagnosed by fertiloscopy / in a second step with laparoscopy]	
Endometriosis	11 [7 / 4]
Adhesions	10 [9 / 1]
Tubal pathology	
Unilateral	9 [4 / 5]
Bilateral	2 [2 / 0]
Laparoconversion	19 (16.5%)
Non-satisfactory exploration	10 (8.6%)
Surgical indication	5 (4.3%)
Fertiloscopy failure	4 (3.4%)
Normal hysteroscopy	93 (80.8%)
Endo-uterine pathology	
Endometrial hyperplasia	13 (10.5%)
Polyp	14 (11.2%)
Synechia	6 (4.8%)

Table 3. Clinical pregnancy occurrence.

Pregnancy (on 91 patients followed up to 5 years)	Mean (\pm standard deviation) or n (%)
Pregnancy occurrence before 5 years	70 (76.9%)
Pregnancies conducted till term	62 (68%)
Spontaneous	13 (18.6%)
Medically assisted procreation technique	57 (81.4%)
Intra-uterine insemination	23 (32.8%)
In-vitro fertilization	34 (48.6%)
Duration before pregnancy occurrence (years)	10.7 (\pm 17)
Minimal	1
Maximal	60

Figure 1. Cumulative pregnancy rate following fertiloscopy.



Study	Kind of surgery	Minimal infertility duration (months)	Population characteristics	Time of study	Number of patients	Mean age (years)	Pelvic disease diagnostic	Treatment during surgery	Post-surgery treatment	Pregnancy rate
Bonneau et al. [7]	L	18	Only pathological hysterosalpingography	November 2003–October 2009	114	32.2	83%	Endometriosis 63% Adhesions 40% Tubal disease 25%	Personalized	75% (mean follow up: 39 months)
Kahyaoglu et al. [2]	L	12		April 2001–April 2003	191	28	60% if primary infertility, 69% if secondary infertility	43% if primary infertility, 49% if secondary infertility		
Nakagawa et al. [6]	L		Patients with 6 failures of stimulation or IIU, under 35 years	August 2002–January 2005	47	33	87.2% (with 51.2% endometriosis)		Always ART	48.9% at 27 months
Badawy et al. [8]	L	60	No pelvic ultrasound before surgery	January 2003–December 2007	256	29	73.7%		Always ART	55.2% at 6 months
Shimizu et al. [21]	L	12	Randomization between IVF first or surgery first	January 2000–December 2007	51	32	82.3% (with 62.7% endometriosis)		IVF at 6 months if no spontaneous pregnancy	76.5% at 36 months
Mahran et al. [3]	L+ H	24		January 2012–December 2014	229	26.1			Personalized	36.7%
Our study	F	12		June 2007–December 2012	124	30.6	21.8%	19% surgical action	Personalized	76.9% at 60 months

Table 4. Comparative table of studies on surgery effects on unexplained infertility. Only studies on unexplained infertility have been summarized here. L=laparoscopy; F=fertiloscopy; H=hysteroscopy; ART: assisted reproduction techniques; IVF: in-vitro fertilization

REFERENCES

- [1] Health (UK) NCC for W and C. Unexplained infertility. Royal College of Obstetricians & Gynaecologists; 2013.
- [2] Kahyaoglu S, Kahyaoglu I, Yilmaz B, Var T, Ertas IE, Mollamahmutoglu L, et al. Should diagnostic laparoscopy be performed initially or not, during infertility management of primary and secondary infertile women? A cross-sectional study. *J Obstet Gynaecol Res* 2009;35:139–44.
- [3] Mahran A, Abdelraheim AR, Eissa A, Gadelrab M. Does laparoscopy still has a role in modern fertility practice? *Int J Reprod Biomed* 2017;15:787–94.
- [4] Boujenah J, Montforte M, Hugues JN, Sifer C, Poncelet C. [Laparoscopy in ART?]. *Gynecol Obstet Fertil* 2015;43:604–11.
- [5] Tardieu A, Sire F, Gauthier T. [Diagnosis accuracy of endoscopy (laparoscopy, hysteroscopy, fertiloscopy, cystoscopy, colonoscopy) in case of endometriosis: CNGOF-HAS Endometriosis Guidelines]. *Gynecol Obstet Fertil Senol* 2018.
- [6] Nakagawa Koji, Ohgi Shirei, Horikawa Takashi, Kojima Rieko, Ito Megumu, Saito Hidekazu. Laparoscopy should be strongly considered for women with unexplained infertility. *J Obstet Gynaecol Res* 2007;33:665–70. <https://doi.org/10.1111/j.1447-0756.2007.00629.x>.
- [7] Bonneau C, Chanelles O, Sifer C, Poncelet C. Use of laparoscopy in unexplained infertility. *Eur J Obstet Gynecol Reprod Biol* 2012;163:57–61.
- [8] Badawy A, Khiary M, Ragab A, Hassan M, Sherif L. Laparoscopy – or not – for management of unexplained infertility. *J Obstet Gynaecol* 2010;30:712–5.
- [9] Moayeri SE, Lee HC, Lathi RB, Westphal LM, Milki AA, Garber AM. Laparoscopy in women with unexplained infertility: a cost-effectiveness analysis. *Fertil Steril* 2009;92:471–80.
- [10] Watrelot A, Nisolle M, Chelli H, Hocke C, Rongières C, Racinet C, et al. Is laparoscopy still the gold standard in infertility assessment? A comparison of fertiloscopy versus laparoscopy in infertility. Results of an international multicentre prospective trial: the “FLY” (Fertiloscopy-Laparoscopy) study. *Hum Reprod Oxf Engl* 2003;18:834–9.
- [11] Gordts S, Brosens I, Gordts S, Puttemans P, Campo R. Progress in transvaginal hydrolaparoscopy. *Obstet Gynecol Clin North Am* 2004;31:631–9, x.
- [12] Abergel A, Rubod C, Merlot B, Petit E, Leroy M, Dewailly D, et al. Intérêt de la fertiloscopie dans la prise en charge de l’infertilité : étude rétrospective, à propos de 262 cas. *Gynécologie Obstétrique Fertil* 2014;42:97–103.
- [13] Watrelot A. Place of transvaginal fertiloscopy in the management of tubal factor disease. *Reprod Biomed Online* 2007;15:389–95.
- [14] f the learning curve of fertiloscopy with and without ovarian drilling. *Reprod Biomed Online* 2015;30:408–14. <https://doi.org/10.1016/j.rbmo.2014.12.015>.
- [15] Bosteels J, Kasius J, Weyers S, Broekmans FJ, Mol BWJ, D’Hooghe TM. Hysteroscopy for treating subfertility associated with suspected major uterine cavity abnormalities. *Cochrane Database Syst Rev* 2015:CD009461.
- [16] Seyam EM, Hassan MM, Mohamed Sayed Gad MT, Mahmoud HS, Ibrahim MG. Pregnancy Outcome after Office Microhysteroscopy in Women with Unexplained Infertility. *Int J Fertil Steril* 2015;9:168–75.
- [17] Nohuz E, Pouly J-L, Bolandard F, Rabischong B, Jardon K, Cotte B, et al. Fertiloscopie : l’expérience clermontoise. *Gynécologie Obstétrique Fertil* 2006;34:894–9.

- [18] Braidy C, Nazac A, Legendre G, Capmas P, Fernandez H. [Comparison of fertiloscopy versus laparoscopy in the exploration of the infertility: analysis of the literature]. *J Gynecol Obstet Biol Reprod (Paris)* 2014;43:488–95.
- [19] Ahmad G, O’Flynn H, Duffy JMN, Phillips K, Watson A. Laparoscopic entry techniques. *Cochrane Database Syst Rev* 2012:CD006583.
- [20] Perugini RA, Callery MP. Complications of laparoscopic surgery. *Zuckschwerdt*; 2001.
- [21] Shimizu Y, Yamaguchi W, Takashima A, Kaku S, Kita N, Murakami T. Long-term cumulative pregnancy rate in women with unexplained infertility after laparoscopic surgery followed by in vitro fertilization or in vitro fertilization alone. *J Obstet Gynaecol Res* 2011;37:412–5.