

# FAILURE LOAD PREDICTION OF METASTATIC VERTEBRAE USING NUMERICAL SIMULATION

V. ALLARD<sup>1,2</sup> , C. CONFAVREUX<sup>1,3</sup>, F. BERMOND<sup>2</sup>, D. MITTON<sup>2</sup>, H. FOLLET<sup>1</sup>

<sup>1</sup> *Université de Lyon, LYOS, INSERM-UCBL*

<sup>2</sup> *Université de Lyon, LBMC , Univ. Eiffel / IFSTTAR-UCBL*

<sup>3</sup> *Service de rhumatologie Sud, Hospices Civils de Lyon*



# General context – Clinical features

- **Bone metastasis = secondary cancer**
  - Osteolytic (75%)
  - Osteoblastic (15%)
  - Mixed (10%)
- **Median survival rates (Selvaggi et al. 2005)**
  - From 6 months to 5 years
- **Main problem of bone metastasis (Macedo et al. 2017):**
  - Pathological fracture : 10-30% of all cancer patients
  - Spinal cord compression syndrome : 5%

Primary tumor	Incidence of bone metastasis
Breast	47 to 85 %
Prostate	33 to 85 %
Thyroid	28 to 60 %
Bronchus	30 to 55 %
Kidney	33 to 40 %

From Coleman et al., 2020

**Clinical problem** : Help clinician answer patients : « What kind of activities can I do ? »

# General context – Failure prediction

- **Fracture prediction : SINS (Spine Instability Neoplastic Score)**  
From Fisher et al. 2010

Component	Score
<b>Location</b>	
Junctional (O-C2; C7-T2; T11-L1; L5-S1)	3
Mobile spine (C3-6; L2-4)	2
Semirigid (T3-10)	1
Rigid (S2-S5)	0
<b>Mechanical pain</b>	
Yes	3
No	2
Pain free lesion	1
<b>Bone lesion</b>	
Lytic	2
Mixed (lytic/blastic)	1
Blastic	0
<b>Radiographic spinal alignment</b>	
Subluxation/translation present	4
Deformity (kyphosis/scoliosis)	2
Normal	0
<b>Vertebral body collapse</b>	
>50% collapse	3
<50% collapse	2
No collapse with >50% body involved	1
None of the above	0
<b>Posterolateral involvement</b>	
Bilateral	3
Unilateral	1
None of the above	0

Score	Score between 0 and 18		
	1 to 6	7 to 12	13 to 18
Clinical status	stable	<b>possibly unstable</b>	unstable

Spine stability according to SINS (Fox et al. 2017)

Bayley et al. 2019 :  
SINS = subjective+ poor reproductivity between clinicians

# Subject-specific model with metastases

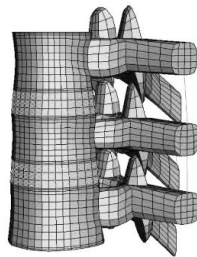
- **Vertebral body**

Whyne et al. (2001) → Anitha et al. (2017)

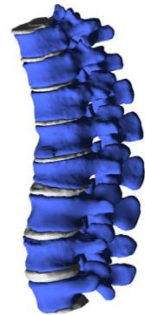- **Single vertebrae**

Parra et al. (2018), Costa et al. (2019), Athira et al. (2019)

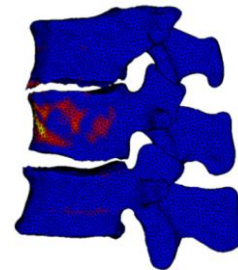
- **Spinal segment**



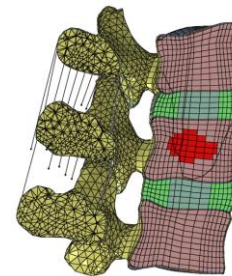
O'reilly et al. (2008)



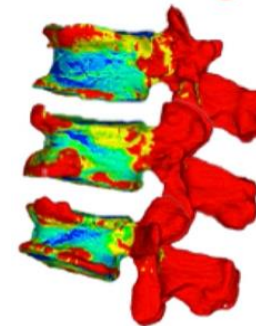
Galbusera et al. (2017)



Groenen et al. (2018)



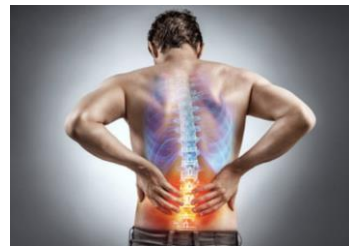Salvatore et al. (2018)



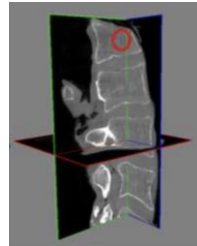
Costa et al. (2019)

# Global objective

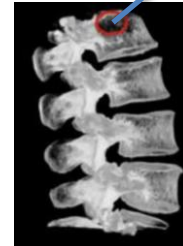**Evaluate bone strength of a lumbar vertebrae with metastatic lesion using calibrated clinical QCT**



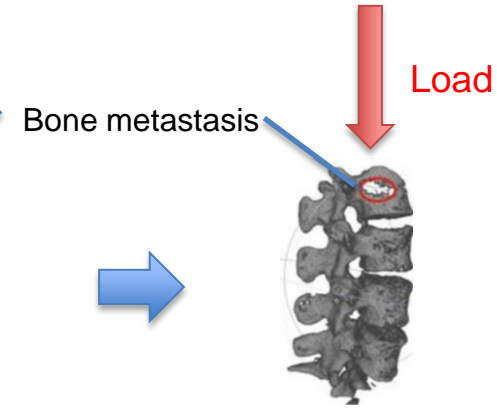
Patient (n=130)



QCT scan




3D reconstruction



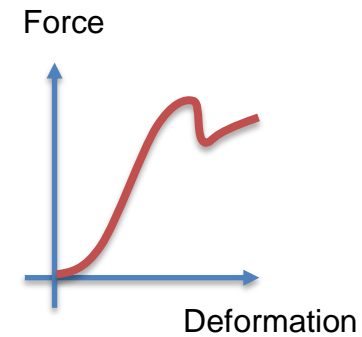
**Failure load estimation**



Ex-vivo lumbar segment (n=30)



Compression



# Thank you



To contact me :

Valentin ALLARD

[valentin.allard@inserm.fr](mailto:valentin.allard@inserm.fr)

[www.lyos.fr](http://www.lyos.fr)

# LYON