



**HAL**  
open science

## **Surgical indications for pituitary tumors during pregnancy: a literature review**

Thomas Graillon, Thomas Cuny, Frederic Castinetti, Blandine Courbiere, Marie Cousin, Frédérique Albarel, Isabelle Morange, Nicolas Bruder, Thierry Brue, Henry Dufour

### **► To cite this version:**

Thomas Graillon, Thomas Cuny, Frederic Castinetti, Blandine Courbiere, Marie Cousin, et al.. Surgical indications for pituitary tumors during pregnancy: a literature review. *Pituitary*, 2020, 23 (2), pp.189-199. 10.1007/s11102-019-01004-3 . hal-02468520

**HAL Id: hal-02468520**

**<https://hal.science/hal-02468520>**

Submitted on 12 May 2021

**HAL** is a multi-disciplinary open access archive for the deposit and dissemination of scientific research documents, whether they are published or not. The documents may come from teaching and research institutions in France or abroad, or from public or private research centers.

L'archive ouverte pluridisciplinaire **HAL**, est destinée au dépôt et à la diffusion de documents scientifiques de niveau recherche, publiés ou non, émanant des établissements d'enseignement et de recherche français ou étrangers, des laboratoires publics ou privés.

# Surgical indications for pituitary tumors during pregnancy: a literature review

Thomas Graillon<sup>1,2</sup> · Thomas Cuny<sup>2,3</sup> · Frédéric Castinetti<sup>2,3</sup> · Blandine Courbière<sup>4</sup> · Marie Cousin<sup>5</sup> ·  
Frédérique Albarel<sup>3</sup> · Isabelle Morange<sup>3</sup> · Nicolas Bruder<sup>6</sup> · Thierry Brue<sup>2,3</sup> · Henry Dufour<sup>1,2</sup>

## Abstract

**Purpose** Surgical indications for pituitary tumors during pregnancy are rare, and are derived from a balance between expected benefits, particularly for maternal benefits, and anesthetic/surgical risks.

**Methods** A literature review was performed to define the optimal surgical indications for pituitary adenomas (PA) and other pituitary tumors during pregnancy.

**Results** Main benefits are expected in case of critical visual impairment and/or life-threatening endocrine disturbances. Multidisciplinary patient management is systematically required although nonobstetric surgery presents a reasonable risk during pregnancy. The risks of congenital malformation during the first trimester and those of premature birth during the third trimester make the second trimester the optimal period for surgery. In prolactin-secreting, nonsecreting, GH- and TSH-secreting PAs, transsphenoidal surgery (TS) is recommended in cases involving severe visual impairment, characterized by severe visual field deficit, visual acuity impairment, and abnormal optical coherence tomography findings, and when no other medical alternatives are possible and/or sufficient. Uncontrolled and severe Cushing's disease (CD) during pregnancy increases both maternal and fetal morbimortality, thus justifying TS or sometimes dopamine agonist therapy as a safer alternative. Finally, metyrapone, ketoconazole, or bilateral adrenalectomy could be recommended in certain cases after the failure of medical therapies and/or TS. Surgery is also required for suprasellar meningiomas, craniopharyngiomas, and pituitary cysts in the case of severe visual deficit.

**Conclusion** Surgical indications for pituitary tumors are rare during pregnancy; therefore, surgery should be avoided when possible. Further, the second trimester should be considered as the optimal surgical period. Severe visual disturbance and uncontrolled CD are the main surgical indications during pregnancy.

**Keywords** Pituitary adenoma · Pregnancy · Surgery · Meningioma · Craniopharyngioma · Pituitary cyst

---

✉ Thomas Graillon  
Thomas.Graillon@ap-hm.fr

<sup>1</sup> Neurosurgery Department, Aix-Marseille Univ, APHM, CHU Timone, La Timone Hospital, 264 rue Saint-Pierre, 13005 Marseille, France

<sup>2</sup> Aix-Marseille Univ, INSERM, MMG, Marseille, France

<sup>3</sup> Endocrinology Department, Aix-Marseille Univ, APHM, CHU Conception, Marseille, France

<sup>4</sup> Centre Clinico-Biologique d'AMP, Pôle Femmes-Parents-Enfants, Hôpital de La Conception, AP-HM, Marseille/Aix Marseille Univ, Avignon Univ, CNRS, IRD, IBME, Marseille, France

<sup>5</sup> Cabinet d'Ophtalmologie, Saint-Rémy de Provence, France

<sup>6</sup> Anesthesiology-Intensive Care Department, Aix-Marseille Univ, APHM, CHU Timone, Marseille, France

## Introduction

The diagnosis of pituitary adenomas (PAs) and other pituitary tumors during pregnancy is uncommon, which explains the scarcity of the available data in the literature to guide the treatment using a case-by-case approach. Surgical indications and medical alternatives are actively discussed by expert pituitary teams. In usual neurosurgical practice, surgery during pregnancy is exceptional, mainly reported for lumbar disc herniation and/or neurovascular pathologies. Regarding our team, we have reported only two cases of pituitary tumor surgery in the last 3 years. Surgical indications are estimated while balancing between anesthetic/surgical risks and potential surgical benefits. Between these, the latter is principally related to the mother, whereas the

risks are shared by the mother and fetus; further, they could exceptionally be vital but more likely functional in cases of visual loss or endocrine disturbances. Here, a literature review is provided to assess the anesthetic and surgical risks as well as the benefits expected for the mother and fetus. Then, we detail surgical strategies depending on different pituitary tumors given the current literature data and knowledge.

## Surgical indications

### For vital benefit

A surgery performed for pituitary tumors for vital risks in a pregnant patient is an exceptional situation. Indeed, it is almost always characterized by the occurrence of life-threatening pituitary apoplexy, which could also be the cause of severe and acute corticotroph deficiency [1].

### For visual benefit

Visual improvement is the main functional benefit expected from surgery. Visual benefit is proportional to preoperative severity of visual loss. The definition of severe visual loss, which indicates surgery without delay, remains unclear. It could be practically defined as a combination of severe visual impairment and related handicap, potential of recovery, and a high risk of definitive visual sequelae. Therefore, surgery is likely required when the delay until delivery may lead to irreversible damages to optic pathways. Complete visual examination includes examination of visual acuity (VA), visual field (VF), and the retinal nerve fiber layer (RNFL); fundus examination; and optical coherence tomography (OCT) for the ganglion cell complex. Visual prognostic factors are well described in the general population: patient aged  $\geq 50$  years, optic nerve compression lasting for  $\geq 1$  year, tumor type and volume, preoperative VF and acuity, and optic nerve atrophy [2]. In pregnant women, young age and short-term preoperative compression are the frequent favorable prognostic factors. In the meta-analysis conducted by Muskens et al., which included patients with PAs responsible for visual disturbances, postoperative VF improvement occurred in approximately 80% of patients, which included only 67.5% of patients with VA impairment [3]. The degree of preoperative VF impairment is a strong prognostic factor for postoperative visual outcome. In patients with complete postoperative VF recovery, preoperative VF impairment was significantly less pronounced than in those with only partial VF recovery. More specifically, Gnanalingham et al. showed that the severity of preoperative temporal VF deficit was a strong prognostic factor for postoperative

visual outcome. The mean preoperative quantitative VF as per the Humphrey field was  $-20$  dcb in the upper temporal VF in the case of partial recovery and  $-10$  dcb in the case of complete recovery [4]. The mean preoperative quantitative VF was  $-16$  dcb in the lower temporal VF in the case of partial recovery and  $-8$  dcb in the case of complete recovery. In the study by Barzaghi et al., the mean preoperative quantitative VF was  $-15.6 \pm 0.8$  dcb in the case of partial recovery and  $-8.5 \pm 0.6$  dcb in the case of complete recovery [5]. This study also underlined the relevance of preoperative VA to predict visual outcome. Among patients with preoperative VA deficit, one-third of patients had complete recovery, one-third had partial recovery, and the remaining did not show any postoperative improvement [5]. In this study, the mean preoperative VA was 0.9 for patients with complete recovery and 0.6 for those with partial recovery. Abnormal OCT findings of RNFL thickness are other prognostic factors, e.g., alterations in RNFL found on OCT impair the potential of optic nerve recovery and are prognostic factors for central and peripheral VF recovery [6–8]. The threshold for the optic nerve fiber diameter for complete recovery was found to be  $\geq 85 \mu\text{m}$  [8]. Blanch et al. highlighted the higher sensitivity of RNFL and ganglion cell complex (GCC) alteration observed on OCT compared to classical VF assessment [9]. Moreover, sensitivity of GCC-OCT may be higher than RNFL-OCT to assess chiasmal compression [9, 10]. Therefore, severe visual impairment that could lead to definitive visual sequelae and that require immediate surgery includes severe VF impairment with mean VF of  $-15$  to  $-20$  dcb, VA impairment, and severe RNFL and GCC-OCT deterioration (Table 1).

### For endocrine functions

In cases of hormone hypersecretion, surgery is the most beneficial in Cushing's disease (CD) [11]. In GH-, PRL-, or TSH-secreting PAs, surgical relevance remains limited given the efficacies of different medical therapies, and it still raises the concerns of the risk of pituitary deficiencies.

**Table 1** Preoperative situations with severe visual disturbance leading to a high risk of nonrecoverable optic nerve lesion and definitive visual sequelae

---

Severe visual impairment requiring non-delayed surgery
Severe VF impairment (VF quantitative measure between $-15$ and $-20$ dcb)
VA impairment
Severe RNFL thickness and GCC loss detected by OCT

---

## Maternal- and fetal-related risks of anesthesia and pituitary surgery during pregnancy

### Main principles of surgical management

It is of utmost importance that surgical management will be conducted using a multidisciplinary approach at an expert pituitary center. Preoperative assessment by an obstetrician is also strongly recommended [12–15]. All anesthetic drugs cross the placenta. Teratogenic anesthetic agents should be avoided, but no anesthetic agent currently used has been associated with teratogenic effects on humans. The maximal risk of teratogenicity likely occurs between 13 and 60 days after gestation. During the third trimester, neurotoxicity and abnormal neural tube closure should be considered, but their incidence is probably rare. In animal studies, anesthetic agents have shown to induce neuronal apoptosis, disruption of brain circuit formation, and impairment of neurogenesis and synaptogenesis, leading to morphological and functional alterations in the brain and long-term cognitive dysfunction after a single exposure to anesthesia [16, 17]. However, clinical studies did not demonstrate any adverse effects on the cognitive functions of children anesthetized in the first year of age [18, 19]. Considering the uncertainty of the effects of anesthetic agents on the developing brain, surgery should be avoided whenever possible during pregnancy. To assess the fetal risk related to premature birth, a recent study on 6696 births in 24–34 gestational week (GW) showed 59.1% fetal survival at 25 GW, 75.3% at 26 GW, 93.6% between 27 and 31 GW, and 98.9% between 32 and 34 GW. In the same study, the rate of hospital discharge without severe neonatal pathologies was 0% at 23 GW, 11.6% at 24 GW, 30.0% at 25 GW, 47.5% at 26 GW, 81.3% between 27 and 31 weeks, and 96.8% between 32 and 34 GW [20]. Therefore, the risk related to premature birth is minimal between 27 and 31 GW, and birth is safe from 32 GW.

Preoperative and postoperative imaging should strictly be limited to necessity. Brain MRI without gadolinium enhancement is sufficient in most cases for diagnosis and operational planning. Gadolinium enhancement-caused fetal toxicity remains undemonstrated and uncertain, but gadolinium enhancement is rarely required. CT should be avoided considering X-ray toxicity [21].

### Orotracheal intubation and patient installation

Difficult oro-tracheal intubation is more frequent during the second and third trimesters, and it is related to swelling and friability of the oropharyngeal airway mucosa. From

the second trimester, high abdominal pressure increases the risk of active reflux, regurgitation, and aspiration (Mendelson's syndrome), leading to pulmonary infection or acute respiratory failure. Compression of the inferior vena cava because of gravid uterus should be avoided from the second trimester. Reduced venous return to the heart causes hypotension, placental insufficiency, or decreased cerebral blood flow during surgery. Patients should be positioned in the supine position with a chopping block under the right hip to tilt the body to the left or in the lateral decubitus ("park bench") position. Deep vein thrombosis should be prevented. From 18 to 24 GW, fetal monitoring should be performed before and after surgery [22–25]. After 25 GW, continuous fetal monitoring during anesthesia remains particularly debated given the lack of proven benefits.

### During the surgery

Moderate hypotension classically used in endonasal surgery should be avoided. Hypothermia, arterial hypotension, preoperative hyperventilation, hypoxia, acidosis, and dehydration should also be avoided. The use of diuretic drugs is not recommended. Electrolyte and hemoglobin concentrations should be tightly monitored. Hematocrit should be maintained at  $\geq 28\%$ , and abdominal pressure should be avoided to limit inferior vena cava compression. Local vasoconstrictive injection and administration of hemostatic agents with fibrin are allowed. Prophylactic anticonvulsant agents should be avoided when not necessary and are associated with adverse effects on the fetus. Tocolytics, prophylactic agents, could be administered during the third trimester in the case of contractions and cervical modifications. Mannitol (0.5–1 g/kg) can be administered in the case of high intracranial pressure, but if not required, mannitol should also be avoided given the risk of fetal dehydration [13, 26].

### During the postoperative period

A close monitoring of natremia and the hormonal status is required for the prevention of maternal dehydration, even more in the case of diuretic or mannitol use. Eventual hormonal ante and/or neurohypophysis deficit should be rapidly substituted. Endonasal surgeries cause moderate postoperative pain, for which paracetamol is usually sufficient. The use of nonsteroidal anti-inflammatory drugs and prophylactic anticonvulsant agents should be avoided. A rapid decrease in the dose of postoperative corticosteroids is also recommended [27]. Early mobilization is required to prevent venous thrombosis. Moreover, the risk of postoperative cerebrospinal fluid leak should be closely monitored given high maternal abdominal pressure. Overall, obstetric and

fetal monitoring should be continued during the postoperative period.

### Risk assessment of nonobstetric surgery during pregnancy

During nonobstetric surgery, maternal mortality is exceptional, whereas the risk of congenital malformations is considered limited. During the initial 15 days after gestation, this risk is considered “all or nothing,” whereas it is considered maximal from 13 to 60 days after gestation [28]. The proportion of major malformations is estimated to be 2% during the entire pregnancy and 3.9% during the first trimester. The possibility of neurotoxicity and abnormality of neural tube closure is considered maximal during the third trimester [29]. The risk of miscarriage is estimated to be 5.8% during the entire pregnancy and 10.5% during the first trimester, with the risk of fetal loss being 2.5% [30]. Therefore, anesthetic and surgical risks during pregnancy appear reasonable when surgery is needed, but the risks are still difficult to assess with precision. Whenever possible, surgical indications during the first trimester should be delayed to the second trimester, with the latter being the optimal period for surgery. When surgery is considered during the third trimester, Lynch et al. have recommended to delay surgery after 30 GW given that fetal survival is 50–70% at 26–27 GW and 90% after 27 GW [31]. Finally, general anesthesia during pregnancy should be performed only when required without any valuable medical alternatives [14, 24, 28, 30].

## Management of PAs during pregnancy

### Microprolactinomas and macroprolactinomas

Prolactinomas are the most frequent type of PAs in pregnant women. An increase in the tumor volume is well known during pregnancy, secondary to estrogen-induced pituitary lactotroph hyperplasia, but it rarely leads to symptoms. Indeed, an increase in symptomatic prolactinomas likely occurs in 1.3% of cases of microprolactinomas and 23.2% of macroprolactinomas [32]. Moreover, it has clearly been demonstrated that this increase was more frequent in undiagnosed macroprolactinomas without pre-pregnancy treatment [33]. Follow-up and management of microprolactinomas and macroprolactinomas during pregnancy are well described and well established [34, 35]. The available data on dopamine agonists demonstrate a good safety profile, particularly for cabergoline, and good overall antitumor efficacy [36]. Therefore, surgical indications in the case of prolactinomas are mainly represented by macroadenomas with a symptomatic tumor volume increase and severe visual defect

### Macro / Microprolactinomas (and non-functioning pituitary adenomas)

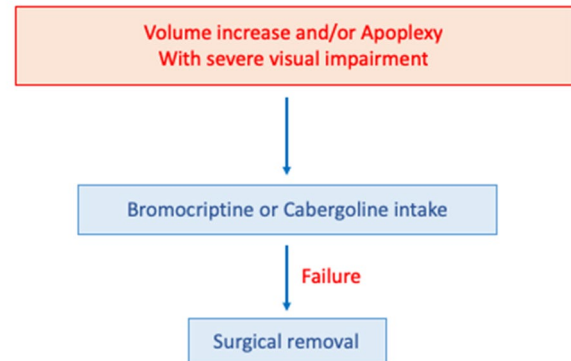


Fig. 1 Therapeutic strategy for prolactinomas during pregnancy

when dopamine agonists fail or are not tolerated by patients (Fig. 1).

### Cushing's disease (CD)

Cases of CD diagnosed during pregnancy are also particularly rare. Approximately 200 cases of Cushing's syndromes (CS) are reported in the literature; however, in these cases, corticotroph adenomas represent only 15–40% of cases of CS, whereas cortisol-secreting adrenal adenoma represent the most frequent etiology [37, 38]. Related data strongly suggest the necessity to control CS during pregnancy. In the meta-analysis conducted by Bronstein et al., which included 150 women with uncontrolled hypercortisolemia, arterial blood hypertension was observed in 68% of the cases, diabetes or glucose intolerance in 25%, pre-eclampsia occurred in 14%, cardiac disease in 3%, and psychiatric disorders 4%. Moreover, fetal prematurity occurred in 43% of cases, birth death in 6%, intrauterine growth restriction in 21%, and fetal loss in 5% when CS was uncontrolled [39]. Likewise, in the study conducted by Caimari et al. (263 pregnancy in 220 patients), metabolic and obstetric comorbidities were more prevalent in patients with uncontrolled CS than in those with controlled CS, i.e., arterial hypertension (50% vs. 2.3%), diabetes mellitus (36.9% vs. 2.3%), pre-eclampsia (26.3% vs. 2.3%), fetal loss (23.6% vs. 8.5%), and fetal morbidity (33.3% vs. 4.9%) [40, 41].

During pregnancy, TS is considered the preferred treatment for CD [11]. It should be performed during the second trimester and could be recommended during the third with an increased risk of prematurity. The reported cases of TS for CD during pregnancy are limited, but they have resulted in a safe and efficient outcome, so that the surgical risk can be considered reasonable [42–47]. Remarkably,



many cases of adrenalectomy for adrenal adenomas have also been reported with a good outcome, particularly during the second trimester, suggesting this therapeutic alternative for severe and uncontrolled CD [48–50].

Medical alternatives that have to be discussed include DA, particularly cabergoline [a dopamine subtype 2 receptor (D2R) agonist]. D2R is expressed in approximately 80% of cases of corticotroph PA, and it reportedly controls 30% of cases of CD in the long term [51–53]. For example, Ferriere et al. reported 20–25% of control cases of CD during pregnancy [54]. Some cases are reported during pregnancy with favorable outcomes [55, 56]. Data on DA adverse effects and teratogenicity during pregnancy suggest it to be safe. Cases of CD treated with metyrapone during pregnancy are also reported with interesting efficacy but with adverse effects such as blood pressure elevation and pre-eclampsia [57, 58]. Ketoconazole administration during pregnancy has also been reported with demonstrated efficiency. Adverse effects such as fetal corticotroph deficiency at childbirth are reported, but they remain uncertain and undefined [59–62].

Therefore, we propose the administration of cabergoline first, particularly in the case of nonsevere CD (Fig. 2). In the case of DA failure and close to the pregnancy term, TS should be particularly discussed given the risk of prematurity. Sam et al. recommend to delay surgery after delivery and vaginal over cesarean delivery given the risk of infectious wounds [14]. Medical therapies (metyrapone and ketoconazole) in these situations are of interest and should be discussed [35]. Planned delivery with second TS appears to be a relevant alternative.

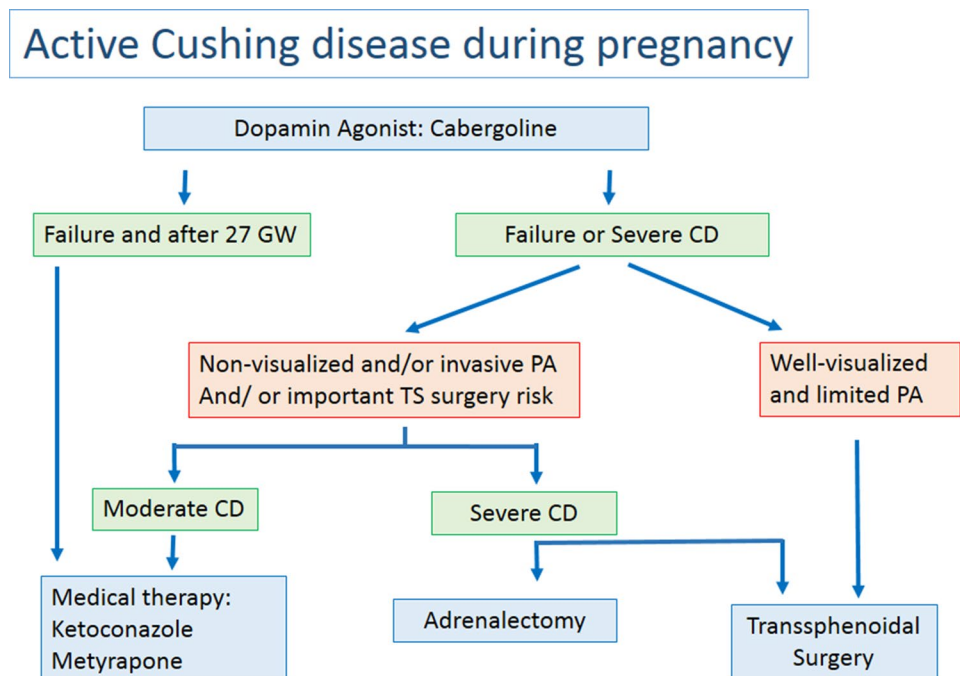
In the case of DA failure and/or severe CD, with identified PA on MRI, TS is the preferred treatment. In the case of normal or doubtful MRI, the optimal management remains debated; in the case of moderate CD, medical therapy should be preferred; and in the case of severe CD or medical therapy failure, TS and adrenalectomy are relevant alternatives but have to be discussed. TS increases the risk of anterior pituitary deficiencies, cerebrospinal fluid leak, and meningitis with a lower cure rate. In the case of normal preoperative MRI, TS showed a 50% remission rate during the early postoperative period [63]; therefore, in the case of severe CD uncontrolled by medical therapies, adrenalectomy should also be considered.

Petrosal sinus catheterization is debated and reported in the literature, but the association between the risk related to the iodinated contrast medium added to radiations and expected benefits is debatable [64].

### Acromegaly and thyrotroph adenomas

The occurrence of somatotroph or thyrotroph PA during pregnancy is also rare. Medical therapy with somatostatin analogs and/or DA is generally efficient but is rarely used because a certain degree of biochemical remission is observed during pregnancy [65–69]. As such, medical therapy for acromegaly (dopamine agonists, somatostatin analogs, and GH receptor antagonists) is generally interrupted before or at the diagnosis of pregnancy, and TS is discussed in very few cases involving symptomatic tumor volume increase, which causes symptoms through a mass effect [68]. For TSH-secreting adenomas, medical drugs can

**Fig. 2** Therapeutic strategy for Cushing’s disease during pregnancy



antagonize thyroid hormone effect, and only one case of SSA-resistant thyrotroph PA with visual impairment requiring TS has been reported with good outcome. Therefore, surgical indications are mainly proposed in the case of medical therapy failure and severe visual impairment.

### Nonsecreting adenomas

Surgical indications are considered in the case of severe visual impairment and apoplexy. Apoplexy of nonfunctioning PA (NFPA) during pregnancy is rare, and macroprolactinomas are essentially concerning. In the study by Enfer-Vat-taut, only 2/9 cases of NFPA presented symptomatic tumor volume increase (Thèse de Médecine, Toulouse, 2005). Volume increase was also observed in 1/7 case of NFPA diagnosed before conception and 3/5 cases diagnosed during pregnancy [35]. Bromocriptine was efficient in one case and surgery was required in the second case. Their surgical indications and strategies are similar to those of prolactinomas during pregnancy (Fig. 1).

### Pituitary apoplexy

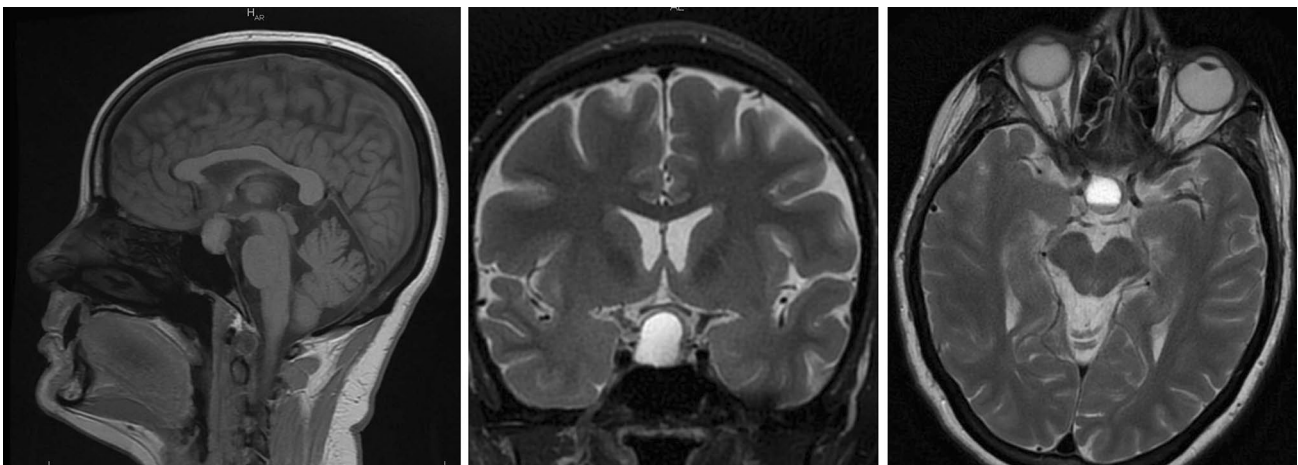
Pituitary apoplexy during pregnancy remains an exceptional condition with < 50 cases currently described in the literature and an estimated prevalence of 1/10,000 pregnancy at term [70]. Its mean gestational age of occurrence is 24 GW [28]. Notably, 11% occurred during the postpartum period. Macroprolactinomas are mainly concerning. The clinical symptoms of pituitary apoplexy are similar to those

of nonpregnant patients. Headaches are present in 95% of patients, visual disturbances in 59%, and nausea in 35% [70]. Pregnancy is considered a risk factor given intratumoral vascular and hormonal changes, blood hypertension, and pregnancy stress. Surgical indications remain limited to vital necessity and severe visual disturbances. In the review published by Grand'maison et al. only 42% of cases of pituitary apoplexy required surgery during pregnancy. Hormone replacement was required in 61% of cases. Remarkably, dopamine agonists were administered to 31% of patients. In this series, adverse effects on the mother and fetus seemed limited with only one case of fetal loss. Therefore, surgical tumor removal should not be systematically recommended when pituitary apoplexy occurs during pregnancy. Surgical indications in the case of apoplexy during pregnancy include deteriorating level of consciousness or a significant or progressive neuro-ophthalmological deficit as described in the case illustrated in Fig. 3 [71].

### Management of other intra or suprasellar tumors during pregnancy

#### Meningiomas

Meningiomas are the most frequent intracranial tumors in adults with a female-to-male ratio of 2/1. They express receptors of progesterone (70–90%) [72, 73], prolactin (50%–60%) [74, 75], and estrogen (8%–40%) [76, 77]. The hormone-dependent status of meningiomas, particularly in



**Fig. 3** Macroprolactinoma apoplexy at 28 gestational week. The case of a 32-year-old pregnant woman (28 gestational weeks) who presented with intermittent headaches and left visual loss for 2 weeks. Regarding the left eye, visual acuity was 6/10 with an altered visual field. Visual acuity and field were normal for the right side. Prolactin was considered in the normal range for the pregnancy term (450 ng/ml). No diplopia was observed, and MRI revealed apoplexy

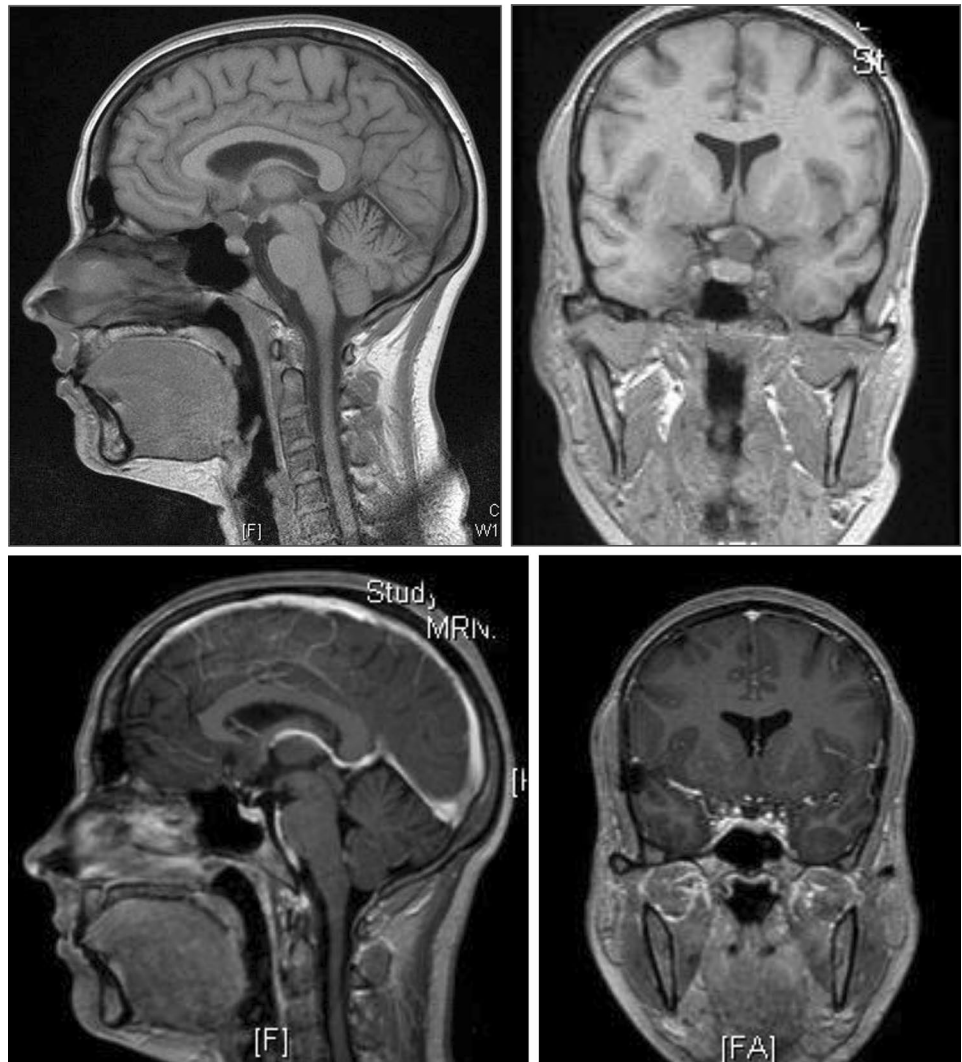
of a pituitary adenoma with intratumoral fluid–fluid level. The tumor was removed using a transsphenoidal approach. Histological results concluded the tumor to be of prolactinoma grade 1a according to the classification reported by Trouillas et al. Vaginal delivery occurred at 40+2 GW with excellent outcome, and breastfeeding was possible without dopamine agonist therapy. Visual findings returned to normal levels at postpartum 3 months

the case of progestin-related meningiomas, is well demonstrated [78]. Meningiomas diagnosed during pregnancy are mainly located on the skull base [27, 79]. An increase in the tumor volume is usual during pregnancy, whereas a decrease is usual in postpartum [80, 81]. Several mechanisms may be involved: hormonal impregnation involving progesterone rather than prolactin or estrogen with tumoral turgescence; hemodynamic changes; higher growth factor secretion and tumor growth acceleration; increase in the volume of the normal pituitary gland (in suprasellar meningiomas) as described in the following clinical case (Fig. 4) [82, 83].

Meningiomas with nonsymptomatic growth do not require surgery during pregnancy; close follow-up is required, and radiologic assessment is indicated in postpartum. Surgery is considered depending on postpartum neurological and visual outcomes, but suprasellar meningiomas are an exception. Proximity with visual pathways explains that limited tumor growth rapidly leads to visual impairment. Kanaan et al. reported 18 patients with meningiomas

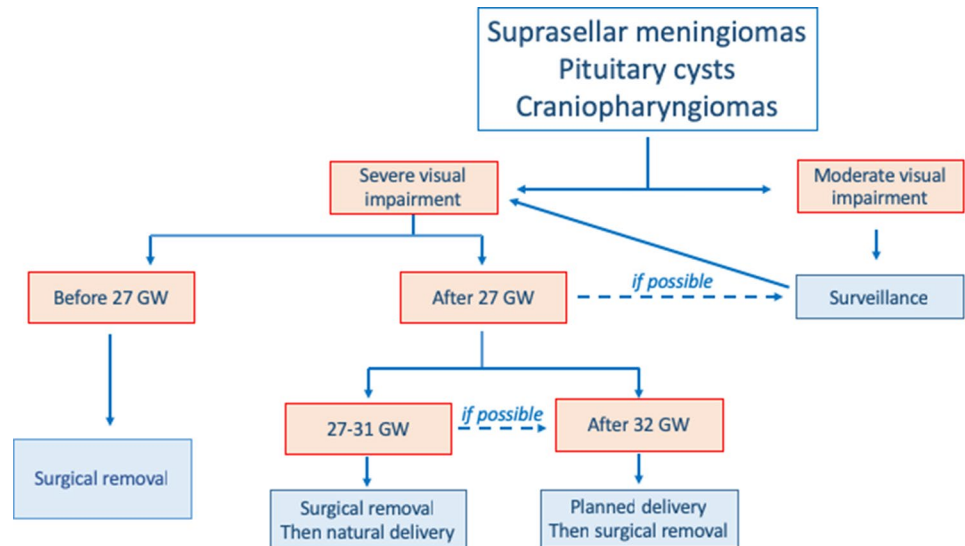
diagnosed during pregnancy [27], among which 12 patients presented visual impairment. All 7 operated patients had visual impairment. Laviv et al. compared the management of 104 patients with suprasellar meningiomas operated during (40%) or after (60%) pregnancy [84]. A similar rate of premature birth (37% and 39%, respectively) was observed; however, maternofetal morbimortality was higher in the group operated during pregnancy with two maternal mortality and two fetal mortality. Despite OR being 14.7, no significant differences were observed in terms of maternofetal mortality; we hypothesize that most cases of severe meningiomas were operated during pregnancy. After 27 GW, the authors concluded that a delayed surgery during the postpartum period was preferable when possible [80]. If not, two alternatives could be considered: a planned Caesarian delivery followed by surgery for the meningioma or surgery followed by vaginal delivery. No data are currently available to determine the optimal alternative. When possible, delivery should be delayed to 32 GW. We suggest the consideration

**Fig. 4** Suprasellar meningioma during pregnancy. The case of a 31-year-old pregnant woman at 32 GW presented for left visual loss (visual acuity: 6/10) with altered visual field. Cesarean delivery was planned before tumor removal, but the patient consulted 3 days later for worsening of visual disturbances. At this point, left visual acuity was at 3/10; therefore, transcranial surgical removal was performed. Complete recovery was observed at postoperative 4 days. Preoperative MRI displayed a typical suprasellar meningioma with optic pathway compression with a considerable increase in the pituitary volume compared with that observed on postoperative 3-month MRI, suggesting the involvement of the increase in the pituitary gland volume





**Fig. 5** Therapeutic strategy for suprasellar meningiomas, pituitary cysts, and craniopharyngiomas



of surgery first between 27 and 32 GW and planned delivery after 32 GW. The surgical strategy is summarized in Fig. 5.

Surgical considerations include epilepsy risk management. Epilepsy prevention should not be systematic. Blood loss and carotid lesion must be avoided. Prophylactic corticosteroids are indicated for fetal lung maturation, but prolonged postoperative corticosteroid administration should be avoided to limit fetal toxicity. Histologically, meningiomas excised during pregnancy appear mostly benign WHO grade I tumors [79, 82, 85].

Considering the possibility and the management of a pregnancy in a patient bearing a meningioma, literature data are poor. There is no formal contraindication, but concerns remain, particularly in case of proximity with the optic pathway. Case-by-case management should be proposed.

### Craniopharyngiomas and pituitary cysts

The diagnosis of craniopharyngiomas or pituitary cysts during pregnancy remains exceptional. Eight cases of craniopharyngiomas diagnosed during pregnancy are currently published [86]. Among these, 6 cases had visual disturbance at diagnosis. The relation of volume increase with pregnancy is highly uncertain. No progesterone, estrogen, or prolactin receptors were detected. In craniopharyngiomas, as in different pituitary cysts, surgery is required in the case of severe visual deficit (Fig. 5). Good outcome has been reported for surgical cases in the literature.

### Conclusion

Nonobstetric surgery is reasonable during pregnancy if its benefits outweigh the risks for the mother and fetus. The risks of congenital malformations during the first

trimester and those of premature birth during the third trimester lead to a preference for the second trimester to consider surgery. Although limited, surgical risks remain difficult to assess, and surgery should be proposed only when safer medical alternatives are lacking.

In macroprolactinomas, nonsecreting as well as GH- and TSH-secreting PAs, TS should be recommended only in the case of failure of medical therapies with severe visual impairment. Surgery is also required in suprasellar meningiomas, craniopharyngiomas, and pituitary cysts in the case of severe visual deficit. Severe visual impairment could be defined by severe VF deficit, VA impairment, and abnormal OCT findings for optic fiber thickness.

Uncontrolled CD during pregnancy increases maternal-fetal morbimortality. The preferred treatment is TS, but cabergoline appears as a safer alternative in the first-line treatment. Metirapone and ketoconazole could be recommended in specific situations as adrenalectomy in the case of severe CD and failure of medical therapy and TS.

**Acknowledgements** Club Français de l'Hypophyse.

**Funding** No Funding.

### Compliance with ethical standards

**Conflict of interest** The authors declare that they have no conflict of interest.

**Ethical approval** All procedures performed in studies involving human participants were in accordance with the 1964 Helsinki declaration and its later amendments.

**Informed consent** Informed consent was obtained from all participants included in the study.

## References

1. Witek P, Zielinski G, Maksymowicz M, Zgliczynski W (2012) Transsphenoidal surgery for a life-threatening prolactinoma apoplexy during pregnancy. *Neuro Endocrinol Lett* 33(5):483–488
2. Lee J, Kim SW, Kim DW, Shin JY, Choi M, Oh MC, Kim SM, Kim EH, Kim SH, Byeon SH (2016) Predictive model for recovery of visual field after surgery of pituitary adenoma. *J Neurooncol* 130(1):155–164. <https://doi.org/10.1007/s11060-016-2227-5>
3. Muskens IS, Zamanipour Najafabadi AH, Briceno V, Lamba N, Senders JT, van Furth WR, Versteegen MJT, Smith TRS, Mekary RA, Eenhorst CAE, Broekman MLD (2017) Visual outcomes after endoscopic endonasal pituitary adenoma resection: a systematic review and meta-analysis. *Pituitary* 20(5):539–552. <https://doi.org/10.1007/s11102-017-0815-9>
4. Gnanalingham KK, Bhattacharjee S, Pennington R, Ng J, Mendoza N (2005) The time course of visual field recovery following transphenoidal surgery for pituitary adenomas: predictive factors for a good outcome. *J Neurol Neurosurg Psychiatry* 76(3):415–419. <https://doi.org/10.1136/jnnp.2004.035576>
5. Barzaghi LR, Medone M, Losa M, Bianchi S, Giovanelli M, Mortini P (2012) Prognostic factors of visual field improvement after trans-sphenoidal approach for pituitary macroadenomas: review of the literature and analysis by quantitative method. *Neurosurg Rev* 35(3):369–378. <https://doi.org/10.1007/s10143-011-0365-y> (discussion 378–369)
6. Jacob M, Raverot G, Jouanneau E, Borson-Chazot F, Perrin G, Rabilloud M, Tilikete C, Bernard M, Vighetto A (2009) Predicting visual outcome after treatment of pituitary adenomas with optical coherence tomography. *Am J Ophthalmol* 147(1):64–70. <https://doi.org/10.1016/j.ajo.2008.07.016>
7. Danesh-Meyer HV, Wong A, Papchenko T, Matheos K, Stylli S, Nichols A, Frampton C, Daniell M, Savino PJ, Kaye AH (2015) Optical coherence tomography predicts visual outcome for pituitary tumors. *J Clin Neurosci* 22(7):1098–1104. <https://doi.org/10.1016/j.jocn.2015.02.001>
8. Garcia T, Sanchez S, Litre CF, Radoi C, Delemer B, Rousseaux P, Ducasse A, Arndt C (2014) Prognostic value of retinal nerve fiber layer thickness for postoperative peripheral visual field recovery in optic chiasm compression. *J Neurosurg* 121(1):165–169. <https://doi.org/10.3171/2014.2.JNS131767>
9. Blanch RJ, Micieli JA, Oyesiku NM, Newman NJ, Biousse V (2018) Optical coherence tomography retinal ganglion cell complex analysis for the detection of early chiasmal compression. *Pituitary* 21(5):515–523. <https://doi.org/10.1007/s11102-018-0906-2>
10. Tieger MG, Hedges TR 3rd, Ho J, Erlich-Malona NK, Vuong LN, Athappilly GK, Mendoza-Santiesteban CE (2017) Ganglion cell complex loss in chiasmal compression by brain tumors. *J Neuroophthalmol* 37(1):7–12. <https://doi.org/10.1097/WNO.0000000000000424>
11. Brue T, Amodru V, Castinetti F (2018) Management of endocrine disease: management of Cushing's syndrome during pregnancy: solved and unsolved questions. *Eur J Endocrinol* 178(6):R259–R266. <https://doi.org/10.1530/EJE-17-1058>
12. Cohen-Gadol AA, Friedman JA, Friedman JD, Tubbs RS, Munis JR, Meyer FB (2009) Neurosurgical management of intracranial lesions in the pregnant patient: a 36-year institutional experience and review of the literature. *J Neurosurg* 111(6):1150–1157. <https://doi.org/10.3171/2009.3.JNS081160>
13. Carvalho CS, Resende F, Centeno MJ, Ribeiro I, Moreira J (2013) Anesthetic approach of pregnant woman with cerebral arteriovenous malformation and subarachnoid hemorrhage during pregnancy: case report. *Braz J Anesthesiol* 63(2):223–226. <https://doi.org/10.1016/j.bjane.2012.05.004>
14. Sam S, Molitch ME (2003) Timing and special concerns regarding endocrine surgery during pregnancy. *Endocrinol Metab Clin North Am* 32(2):337–354
15. Xia Y, Ma X, Griffiths BB, Luo Y (2018) Neurosurgical anesthesia for a pregnant woman with macroprolactinoma: a case report. *Medicine (Baltimore)* 97(37):e12360. <https://doi.org/10.1097/MD.00000000000012360>
16. Wagner M, Ryu YK, Smith SC, Patel P, Mintz CD (2014) Review: effects of anesthetics on brain circuit formation. *J Neurosurg Anesthesiol* 26(4):358–362. <https://doi.org/10.1097/ANA.0000000000000118>
17. Vutskits L, Xie Z (2016) Lasting impact of general anaesthesia on the brain: mechanisms and relevance. *Nat Rev Neurosci* 17(11):705–717. <https://doi.org/10.1038/nrn.2016.128>
18. Graham MR (2017) Clinical update regarding general anesthesia-associated neurotoxicity in infants and children. *Curr Opin Anaesthesiol* 30(6):682–687. <https://doi.org/10.1097/ACO.0000000000000520>
19. Perna RB, Loughan AR, Le JA, Hertz J (2015) Prenatal and perinatal anesthesia and the long-term cognitive sequelae: a review. *Appl Neuropsychol Child* 4(1):65–71. <https://doi.org/10.1080/21622965.2013.779275>
20. Ancel PY, Goffinet F, Kuhn P, Langer B, Matis J, Hernandez X, Chabanier P, Joly-Pedespan L, Lecomte B, Vendittelli F, Dreyfus M, Guillois B, Burguet A, Sagot P, Sizun J, Beuchee A, Rouget F, Favreau A, Saliba E, Bednarek N, Morville P, Thiriez G, Marpeau L, Marret S, Kayem G, Durrmeyer X, Granier M, Baud O, Jarreau PH, Mitanchez D, Boileau P, Boulot P, Cambonie G, Daude H, Bedu A, Mons F, Fresson J, Vieux R, Alberge C, Arnaud C, Vayssiere C, Truffert P, Pierrat V, Subtil D, D'Ercole C, Gire C, Simeoni U, Bongain A, Sentilhes L, Roze JC, Gondry J, Leke A, Deiber M, Claris O, Picaud JC, Ego A, Debillon T, Poulichet A, Coline E, Favre A, Flechelles O, Samperiz S, Ramful D, Branger B, Benhammou V, Foix-L'Helias L, Marchand-Martin L, Kaminski M (2015) Survival and morbidity of preterm children born at 22 through 34 weeks' gestation in France in 2011: results of the EPIPAGE-2 cohort study. *JAMA Pediatr* 169(3):230–238. <https://doi.org/10.1001/jamapediatrics.2014.3351>
21. Committee on Obstetric Practice (2017) No. 723: guidelines for diagnostic imaging during pregnancy and lactation. *Obstet Gynecol* 130(4):e210–e216. <https://doi.org/10.1097/AOG.00000000000002355>
22. Horrigan TJ, Villarreal R, Weinstein L (1999) Are obstetrical personnel required for intraoperative fetal monitoring during nonobstetric surgery? *J Perinatol* 19(2):124–126
23. Kendrick JM, Neiger R (2000) Intraoperative fetal monitoring during nonobstetric surgery. *J Perinatol* 20(4):276–277
24. Reitman E, Flood P (2011) Anaesthetic anaerations for non-obstetric surgery during pregnancy. *Br J Anaesth* 107(Suppl 1):i72–78. <https://doi.org/10.1093/bja/aer343>
25. ACOG committee opinion (2003) Nonobstetric surgery in pregnancy. *Int J Gynaecol Obstet* 83(1):135
26. Tuncali B, Aksun M, Katircioglu K, Akkol I, Savaci S (2006) Intraoperative fetal heart rate monitoring during emergency neurosurgery in a parturient. *J Anesth* 20(1):40–43. <https://doi.org/10.1007/s00540-005-0359-4>
27. Kanaan I, Jallu A, Kanaan H (2003) Management strategy for meningioma in pregnancy: a clinical study. *Skull Base* 13(4):197–203. <https://doi.org/10.1055/s-2004-817695>
28. Tuchmann-Duplessis H (1983) The teratogenic risk. *Am J Ind Med* 4(1–2):245–258
29. Mazze RI, Kallen B (1989) Reproductive outcome after anesthesia and operation during pregnancy: a registry study of 5405 cases. *Am J Obstet Gynecol* 161(5):1178–1185
30. Cohen-Kerem R, Railton C, Oren D, Lishner M, Koren G (2005) Pregnancy outcome following non-obstetric

- surgical intervention. *Am J Surg* 190(3):467–473. <https://doi.org/10.1016/j.amjsurg.2005.03.033>
31. Lynch JC, Gouvea F, Emmerich JC, Kokinovrachos G, Pereira C, Welling L, Kislanov S (2011) Management strategy for brain tumour diagnosed during pregnancy. *Br J Neurosurg* 25(2):225–230. <https://doi.org/10.3109/02688697.2010.508846>
  32. Maiter D (2016) Prolactinoma and pregnancy: from the wish of conception to lactation. *Ann Endocrinol (Paris)* 77(2):128–134. <https://doi.org/10.1016/j.ando.2016.04.001>
  33. Molitch ME (1999) Management of prolactinomas during pregnancy. *J Reprod Med* 44(12 Suppl):1121–1126
  34. Melmed S, Casanueva FF, Hoffman AR, Kleinberg DL, Montori VM, Schlechte JA, Wass JA (2011) Diagnosis and treatment of hyperprolactinemia: an Endocrine Society clinical practice guideline. *J Clin Endocrinol Metab* 96(2):273–288. <https://doi.org/10.1210/jc.2010-1692>
  35. Lambert K, Rees K, Seed PT, Dhanjal MK, Knight M, McCance DR, Williamson C (2017) Macroprolactinomas and nonfunctioning pituitary adenomas and pregnancy outcomes. *Obstet Gynecol* 129(1):185–194. <https://doi.org/10.1097/AOG.0000000000001747>
  36. Molitch ME (2015) Endocrinology in pregnancy: management of the pregnant patient with a prolactinoma. *Eur J Endocrinol* 172(5):R205–213. <https://doi.org/10.1530/EJE-14-0848>
  37. Lindsay JR, Jonklaas J, Oldfield EH, Nieman LK (2005) Cushing's syndrome during pregnancy: personal experience and review of the literature. *J Clin Endocrinol Metab* 90(5):3077–3083. <https://doi.org/10.1210/jc.2004-2361>
  38. Buescher MA, McClamrock HD, Adashi EY (1992) Cushing syndrome in pregnancy. *Obstet Gynecol* 79(1):130–137
  39. Bronstein MD, Paraiba DB, Jallad RS (2011) Management of pituitary tumors in pregnancy. *Nat Rev Endocrinol* 7(5):301–310. <https://doi.org/10.1038/nrendo.2011.38>
  40. Caimari F, Corcoy R, Webb SM (2018) Cushing's disease: major difficulties in diagnosis and management during pregnancy. *Minerva Endocrinol* 43(4):435–445. <https://doi.org/10.23736/S0391-1977.18.02803-1>
  41. Caimari F, Valassi E, Garbayo P, Steffensen C, Santos A, Corcoy R, Webb SM (2017) Cushing's syndrome and pregnancy outcomes: a systematic review of published cases. *Endocrine* 55(2):555–563. <https://doi.org/10.1007/s12020-016-1117-0>
  42. Abbassy M, Kshetry VR, Hamrahian AH, Johnston PC, Dobri GA, Avitsian R, Woodard TD, Recinos PF (2015) Surgical management of recurrent Cushing's disease in pregnancy: a case report. *Surg Neurol Int* 6(Suppl 25):S640–645. <https://doi.org/10.4103/2152-7806.170472>
  43. Casson IF, Davis JC, Jeffreys RV, Silas JH, Williams J, Belchetz PE (1987) Successful management of Cushing's disease during pregnancy by transsphenoidal adenectomy. *Clin Endocrinol (Oxf)* 27(4):423–428
  44. Mellor A, Harvey RD, Pobereskin LH, Sneyd JR (1998) Cushing's disease treated by trans-sphenoidal selective adenectomy in mid-pregnancy. *Br J Anaesth* 80(6):850–852
  45. Ross RJ, Chew SL, Perry L, Erskine K, Medbak S, Afshar F (1995) Diagnosis and selective cure of Cushing's disease during pregnancy by transsphenoidal surgery. *Eur J Endocrinol* 132(6):722–726
  46. Verdugo C, Alegria J, Grant C, Briano E, Gonzalez MI, Meza H, Amthauer N, Paiva O, Viguera R, Madariaga J (2004) Cushing's disease treatment with transsphenoidal surgery during pregnancy. *Rev Med Chil* 132(1):75–80
  47. Jolly K, Darr A, Arlt W, Ahmed S, Karavitaki N (2019) Surgery for Cushing's disease in pregnancy: our experience and a literature review. *Ann R Coll Surg Engl* 101(1):e26–e31. <https://doi.org/10.1308/rcsann.2018.0175>
  48. Wang W, Yuan F, Xu D (2015) Cushing's syndrome during pregnancy caused by adrenal cortical adenoma: a case report and literature review. *Front Med* 9(3):380–383. <https://doi.org/10.1007/s11684-015-0407-x>
  49. Sasmour RN, Saiegh L, Matter I, Gonen R, Shechner C, Cohen M, Ohel G, Dickstein G (2012) Adrenalectomy for adrenocortical adenoma causing Cushing's syndrome in pregnancy: a case report and review of literature. *Eur J Obstet Gynecol Reprod Biol* 165(1):1–7. <https://doi.org/10.1016/j.ejogrb.2012.05.030>
  50. Martinez Garcia R, Martinez Perez A, del Pozo CD, Sospedra Ferrer R (2016) Cushing's syndrome in pregnancy. Laparoscopic adrenalectomy during pregnancy: the mainstay treatment. *J Endocrinol Invest* 39(3):273–276. <https://doi.org/10.1007/s40618-015-0345-0>
  51. Pivonello R, De Martino MC, Cappabianca P, De Leo M, Faggiano A, Lombardi G, Hofland LJ, Lamberts SW, Colao A (2009) The medical treatment of Cushing's disease: effectiveness of chronic treatment with the dopamine agonist cabergoline in patients unsuccessfully treated by surgery. *J Clin Endocrinol Metab* 94(1):223–230. <https://doi.org/10.1210/jc.2008-1533>
  52. Godbout A, Manavela M, Danilowicz K, Beauregard H, Bruno OD, Lacroix A (2010) Cabergoline monotherapy in the long-term treatment of Cushing's disease. *Eur J Endocrinol* 163(5):709–716. <https://doi.org/10.1530/EJE-10-0382>
  53. Sek KS, Deepak DS, Lee KO (2017) Use of cabergoline for the management of persistent Cushing's disease in pregnancy. *BMJ Case Rep*. <https://doi.org/10.1136/bcr-2016-217855>
  54. Ferriere A, Cortet C, Chanson P, Delemer B, Caron P, Chabre O, Reznik Y, Bertherat J, Rohmer V, Briet C, Raingard I, Castinetti F, Beckers A, Vroonen L, Maiter D, Cephise-Velayoudom FL, Nunes ML, Haissaguerre M, Tabarin A (2017) Cabergoline for Cushing's disease: a large retrospective multicenter study. *Eur J Endocrinol* 176(3):305–314. <https://doi.org/10.1530/EJE-16-0662>
  55. Nakhleh A, Saiegh L, Reut M, Ahmad MS, Pearl IW, Shechner C (2016) Cabergoline treatment for recurrent Cushing's disease during pregnancy. *Hormones (Athens)* 15(3):453–458. <https://doi.org/10.14310/horm.2002.1685>
  56. Woo I, Ehsanipoor RM (2013) Cabergoline therapy for Cushing disease throughout pregnancy. *Obstet Gynecol* 122(2 Pt 2):485–487. <https://doi.org/10.1097/AOG.0b013e31829e398a>
  57. Lim WH, Torpy DJ, Jeffries WS (2013) The medical management of Cushing's syndrome during pregnancy. *Eur J Obstet Gynecol Reprod Biol* 168(1):1–6. <https://doi.org/10.1016/j.ejogrb.2012.12.015>
  58. Close CF, Mann MC, Watts JF, Taylor KG (1993) ACTH-independent Cushing's syndrome in pregnancy with spontaneous resolution after delivery: control of the hypercortisolism with metyrapone. *Clin Endocrinol (Oxf)* 39(3):375–379
  59. Prebtani AP, Donat D, Ezzat S (2000) Worrisome striae in pregnancy. *Lancet* 355(9216):1692
  60. Amado JA, Pesquera C, Gonzalez EM, Otero M, Freijanes J, Alvarez A (1990) Successful treatment with ketoconazole of Cushing's syndrome in pregnancy. *Postgrad Med J* 66(773):221–223
  61. Berwaerts J, Verhelst J, Mahler C, Abs R (1999) Cushing's syndrome in pregnancy treated by ketoconazole: case report and review of the literature. *Gynecol Endocrinol* 13(3):175–182. <https://doi.org/10.3109/09513599909167552>
  62. Zieleniewski W, Michalak R (2017) A successful case of pregnancy in a woman with ACTH-independent Cushing's syndrome treated with ketoconazole and metyrapone. *Gynecol Endocrinol* 33(5):349–352. <https://doi.org/10.1080/09513590.2017.1290070>
  63. Yamada S, Fukuhara N, Nishioka H, Takeshita A, Inoshita N, Ito J, Takeuchi Y (2012) Surgical management and outcomes in patients with Cushing disease with negative pituitary magnetic resonance imaging. *World Neurosurg* 77(3–4):525–532. <https://doi.org/10.1016/j.wneu.2011.06.033>

64. Pinette MG, Pan YQ, Oppenheim D, Pinette SG, Blackstone J (1994) Bilateral inferior petrosal sinus corticotropin sampling with corticotropin-releasing hormone stimulation in a pregnant patient with Cushing's syndrome. *Am J Obstet Gynecol* 171(2):563–564
65. Muhammad A, Neggers SJ, van der Lely AJ (2017) Pregnancy and acromegaly. *Pituitary* 20(1):179–184. <https://doi.org/10.1007/s11102-016-0740-3>
66. Hannon AM, Frizelle I, Kaar G, Hunter SJ, Sherlock M, Thompson CJ, O'Halloran DJ (2019) Octreotide use for rescue of vision in a pregnant patient with acromegaly. *Endocrinol Diabetes Metab Case Rep*. <https://doi.org/10.1530/edm-19-0019>
67. Hannon AM, O'Shea T, Thompson CA, Hannon MJ, Dineen R, Khattak A, Gibney J, O'Halloran DJ, Hunter S, Thompson CJ, Sherlock M (2019) Pregnancy in acromegaly is safe and is associated with improvements in IGF-I concentrations. *Eur J Endocrinol* 180(4):K21–K29. <https://doi.org/10.1530/EJE-18-0688>
68. Chanson P, Vialon M, Caron P (2019) An update on clinical care for pregnant women with acromegaly. *Expert Rev Endocrinol Metab* 14(2):85–96. <https://doi.org/10.1080/17446651.2019.1571909>
69. Perdomo CM, Arabe JA, Idoate MA, Galofre JC (2017) Management of a pregnant woman with thyrotropinoma: a case report and review of the literature. *Gynecol Endocrinol* 33(3):188–192. <https://doi.org/10.1080/09513590.2016.1260110>
70. Grand'Maison S, Weber F, Bedard MJ, Mahone M, Godbout A (2015) Pituitary apoplexy in pregnancy: a case series and literature review. *Obstet Med* 8(4):177–183. <https://doi.org/10.1177/1753495X15598917>
71. Rajasekaran S, Vanderpump M, Baldeweg S, Drake W, Reddy N, Lanyon M, Markey A, Plant G, Powell M, Sinha S, Wass J (2011) UK guidelines for the management of pituitary apoplexy. *Clin Endocrinol (Oxf)* 74(1):9–20. <https://doi.org/10.1111/j.1365-2265.2010.03913.x>
72. Baxter DS, Orrego A, Rosenfeld JV, Mathiesen T (2014) An audit of immunohistochemical marker patterns in meningioma. *J Clin Neurosci* 21(3):421–426. <https://doi.org/10.1016/j.jocn.2013.06.008>
73. Bozzetti C, Camisa R, Nizzoli R, Manotti L, Guazzi A, Naldi N, Mazza S, Nizzoli V, Cocconi G (1995) Estrogen and progesterone receptors in human meningiomas: biochemical and immunocytochemical evaluation. *Surg Neurol* 43(3):230–233 (**discussion 234**)
74. Muccioli G, Ghe C, Faccani G, Lanotte M, Forni M, Ciccarelli E (1997) Prolactin receptors in human meningiomas: characterization and biological role. *J Endocrinol* 153(3):365–371
75. Carroll RS, Schrell UM, Zhang J, Dashner K, Nomikos P, Fahlbusch R, Black PM (1996) Dopamine D1, dopamine D2, and prolactin receptor messenger ribonucleic acid expression by the polymerase chain reaction in human meningiomas. *Neurosurgery* 38(2):367–375
76. Carroll RS, Zhang J, Black PM (1999) Expression of estrogen receptors alpha and beta in human meningiomas. *J Neurooncol* 42(2):109–116
77. Hsu DW, Efird JT, Hedley-Whyte ET (1997) Progesterone and estrogen receptors in meningiomas: prognostic considerations. *J Neurosurg* 86(1):113–120. <https://doi.org/10.3171/jns.1997.86.1.0113>
78. Bernat AL, Oyama K, Hamdi S, Mandonnet E, Vexiau D, Pocard M, George B, Froelich S (2015) Growth stabilization and regression of meningiomas after discontinuation of cyproterone acetate: a case series of 12 patients. *Acta Neurochir (Wien)* 157(10):1741–1746. <https://doi.org/10.1007/s00701-015-2532-3>
79. Priddy BH, Otto BA, Carrau RL, Prevedello DM (2018) Management of skull base tumors in the obstetric population: a case series. *World Neurosurg* 113:e373–e382. <https://doi.org/10.1016/j.wneu.2018.02.038>
80. Chacko JG, Miller JL, Angtuaco EJ (2010) Spontaneous postpartum resolution of vision loss caused by a progesterone receptor-positive tuberculoma sellae meningioma. *J Neuroophthalmol* 30(2):132–134. <https://doi.org/10.1097/WNO.0b013e3181da9d59>
81. Smith JS, Quinones-Hinojosa A, Harmon-Smith M, Bollen AW, McDermott MW (2005) Sex steroid and growth factor profile of a meningioma associated with pregnancy. *Can J Neurol Sci* 32(1):122–127
82. Lusic EA, Scheithauer BW, Yachnis AT, Fischer BR, Chicoine MR, Paulus W, Perry A (2012) Meningiomas in pregnancy: a clinicopathologic study of 17 cases. *Neurosurgery* 71(5):951–961. <https://doi.org/10.1227/NEU.0b013e31826adf65>
83. Ebner FH, Bornemann A, Wilhelm H, Ernemann U, Honegger J (2008) Tuberculoma sellae meningioma symptomatic during pregnancy: pathophysiological considerations. *Acta Neurochir (Wien)* 150(2):189–193. <https://doi.org/10.1007/s00701-007-1417-5> (**discussion 193**)
84. Laviv Y, Bayoumi A, Mahadevan A, Young B, Boone M, Kasper EM (2018) Meningiomas in pregnancy: timing of surgery and clinical outcomes as observed in 104 cases and establishment of a best management strategy. *Acta Neurochir (Wien)* 160(8):1521–1529. <https://doi.org/10.1007/s00701-017-3146-8>
85. Moscovici S, Fraifeld S, Cohen JE, Dotan S, Elchalal U, Shoshan Y, Spektor S (2014) Parasellar meningiomas in pregnancy: surgical results and visual outcomes. *World Neurosurg* 82(3–4):e503–512. <https://doi.org/10.1016/j.wneu.2013.06.019>
86. Zoia C, Cattalani A, Turpini E, Custodi VM, Benazzo M, Pagella F, Carena P, Lovati E, Lucotti P, Gaetani P (2014) Haemorrhagic presentation of a craniopharyngioma in a pregnant woman. *Case Rep Neurol Med* 2014:435208. <https://doi.org/10.1155/2014/435208>

**Publisher's Note** Springer Nature remains neutral with regard to jurisdictional claims in published maps and institutional affiliations.