



**HAL**  
open science

## Late infective endocarditis after transcatheter tricuspid valve-in-valve implantation: A pediatric case report

A. Gavotto, O. Werner, P. Amedro

### ► To cite this version:

A. Gavotto, O. Werner, P. Amedro. Late infective endocarditis after transcatheter tricuspid valve-in-valve implantation: A pediatric case report. Archives de Pédiatrie, 2020, 27 (2), pp.107-109. 10.1016/j.arcped.2019.12.002 . hal-02447039

**HAL Id: hal-02447039**

**<https://hal.science/hal-02447039>**

Submitted on 4 Jul 2020

**HAL** is a multi-disciplinary open access archive for the deposit and dissemination of scientific research documents, whether they are published or not. The documents may come from teaching and research institutions in France or abroad, or from public or private research centers.

L'archive ouverte pluridisciplinaire **HAL**, est destinée au dépôt et à la diffusion de documents scientifiques de niveau recherche, publiés ou non, émanant des établissements d'enseignement et de recherche français ou étrangers, des laboratoires publics ou privés.

# Late infective endocarditis after transcatheter tricuspid valve-in-valve implantation: A pediatric case report

A. Gavotto<sup>a,\*</sup>, O. Werner<sup>b</sup>, P. Amedro<sup>a</sup>

<sup>a</sup> Department of Pediatric and Congenital Cardiology, M3 C Regional Reference Center, Montpellier University Hospital, PhyMedExp, Inserm, CNRS, University of Montpellier, 34295 Montpellier, France

<sup>b</sup> Pediatric and Congenital Cardiology Department, M3 C Regional Center, University Hospital, 34295 Montpellier, France

## ABSTRACT

In patients with congenital heart diseases, new procedures, such as transcatheter valve replacement, have been associated with a non-negligible incidence of infective endocarditis (IE): up to 4% patient-year IE incidence. Prosthetic IE after percutaneous tricuspid valve replacement (PTVR) has been scarcely reported. We report the first pediatric case of IE after percutaneous tricuspid Melody™ valve-in-valve implantation in a boy who was diagnosed with Eisenmenger syndrome, related to patent ductus arteriosus. This first pediatric case of late IE (4 years) after PTVR is added to eight previously reported cases of IE from the valve-in-valve international database registry (VIVID registry).

## Keywords:

Transcatheter tricuspid valve-in-valve  
Eisenmenger  
Infective endocarditis  
Pediatrics.

## 1. Introduction

Infective endocarditis (IE) is a relatively rare complication associated with significant morbidity and mortality [1]. Prevention of IE has not decreased its incidence (3–7 per 100,000 person-years) [2], reportedly as a consequence of medical progress.

In patients with congenital heart diseases (CHD), medical advances have modified the epidemiology of this population, as well as the profile of patients at risk of IE [3]. The incidence of IE in adults with CHD has been estimated as between 15 and 140 times that of the general population, representing 0.4–4% of hospitalizations.

In the past two decades, transcatheter valve replacement has been considered as a major advance for patients with CHD. Indeed, Bonhoeffer et al. reported in 2000 the first experience of transcatheter pulmonary valve replacement in a right-ventricle-to-pulmonary-artery prosthetic conduit with valve dysfunction, in a 12-year-old child [4]. Today, this percutaneous procedure stands as the standard of care for many young CHD patients with dysfunctional right-ventricular-to-pulmonary artery conduits and pulmonary bioprosthetic valves or homografts [5]. In 2010, the first case of transcatheter tricuspid valve-in-valve implantation was reported, using the Edwards Sapien balloon expandable

bioprosthesis [6]. Since then, successful percutaneous tricuspid valve replacement (PTVR) procedures have been reported, using the Edwards Sapien valve or the Melody™ valve [7]. The Medtronic Melody™ balloon-expandable valve is a stented bovine jugular vein graft, available in three sizes (20, 22, and 24 mm, i.e., outer diameter). The Sapien balloon expandable valve is composed of bovine pericardium leaflets sutured in a stent, and is available in three sizes (23, 26, and 29 mm).

Alongside these great advances, a warning signal has been launched of an infective risk of these devices with a 2–4% patient-year incidence of IE after transcatheter pulmonary valve replacement in patients with CHD [8]. Several risk factors have been identified, such as male gender, abrupt aspirin discontinuation, additional unprotected invasive procedures, history of endocarditis, and irregular right outflow tract [8].

Prosthetic infective endocarditis after tricuspid valve-in-valve implantation has been scarcely reported, especially beyond the first months after the procedure [9]. We report the first pediatric case of late IE that occurred in a 13-year-old boy, 5 years after percutaneous tricuspid Melody™ valve-in-valve implantation.

Informed consent was obtained from the patient's parents for publication of the case report and accompanying images.

## 2. Observation

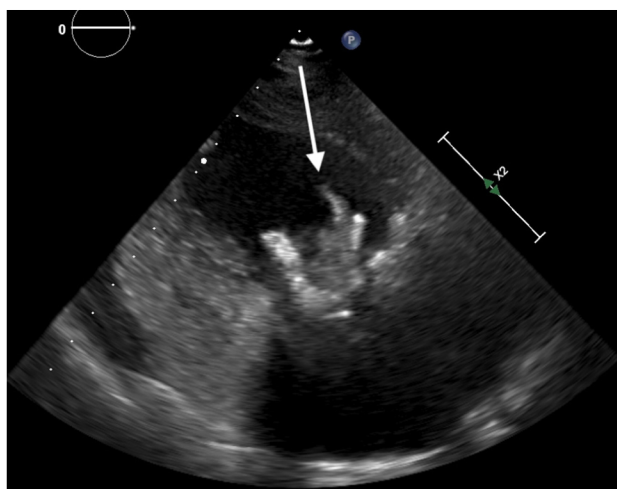
At the age of 14 months, our male patient was diagnosed with Eisenmenger syndrome, related to atrial septal defect (ASD) and patent ductus arteriosus. Non-reversible pulmonary arterial

\* Corresponding author at: Pediatric and Congenital Cardiology Department CHU Arnaud De Villeneuve, 371, avenue du Doyen Gaston-Giraud, 34295 Montpellier cedex 5, France.

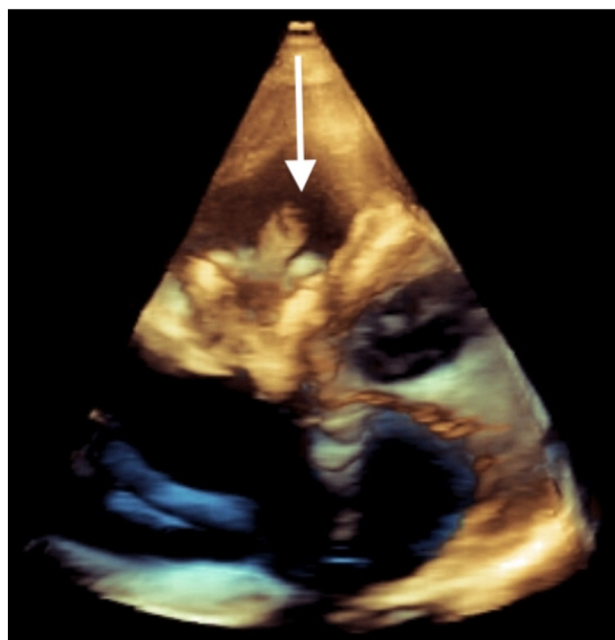
E-mail address: a-gavotto@chu-montpellier.fr (A. Gavotto).

hypertension (PAH) with elevated pulmonary vascular resistance was assessed by cardiac catheterization. Under medical treatment including diuretics and bosentan, he developed right heart failure, associated with severe tricuspid valve regurgitation. At the age of 5 years (weight of 20 kg), the patient underwent surgical valve replacement (27-mm bioprosthetic Carpentier–Edwards valve). Subsequently, the patient's symptoms significantly improved. In 2013, at the age of 9 years (weight of 22 kg), the patient was diagnosed with bioprosthetic tricuspid valve degeneration (mean gradient of 14 mmHg) and significant right-to-left atrial shunt on the basis of an echocardiogram, requiring cardiac catheterization before valve replacement. After considering the surgical risks related to PAH, an interventional cardiac catheterization procedure was preferred. Therefore, the patient underwent transcatheter tricuspid valve-in-valve implantation, using a Melody™ pulmonary valve (Medtronic Inc., Minneapolis, MN, USA). As the right-to-left shunt remained significant, a transcatheter closure of ostium secundum ASD was performed during the same procedure, using the Amplatzer Atrial Septal Occluder Device (AGA Medical Corporation, Golden Valley, MN, USA). At the end of the procedure, a hemodynamic evaluation measured an iso-systemic pulmonary arterial pressure with left-to-right PDA shunt, an aortic oxygen saturation of 95%, and a mean tricuspid gradient of 4 mmHg. The patient was discharged from the hospital 2 days after the interventional catheterization procedure, on diuretics (spironolactone, furosemide), bosentan (4 mg/kg/day), aspirin (5 mg/kg/day), and warfarin (INR range from 1.5 to 2.5, with coagulation self-testing using the Coaguchek XS device, from Roche Diagnostics, Meylan, France). Withdrawal of diuretic drugs was possible 3 months after the procedure and the patient remained stable for 4 years under aspirin, warfarin, and bosentan treatment (NYHA functional class I, SpO<sub>2</sub> 95%).

At the age of 13 years (weight of 40 kg), the patient presented with prolonged fever and diarrhea. It is worth noting that he had been treated with topical antimicrobials for several furuncles 3 weeks before the symptoms started. Transthoracic echocardiography found a voluminous vegetation of more than 10 mm attached to the Melody™ valve, with no incidence on hemodynamic and valvular functions (Figs. 1 and 2). Blood cultures were positive in less than 24 h and revealed oxacillin-resistant *Staphylococcus epidermidis*. The patient underwent intravenous antibiotic treatment with vancomycin, rifampin, and gentamicin during the first 48 h. Fever decreased after 48 h of antibiotic administration and the first negative blood culture was obtained



**Fig. 1.** Right ventricle, long-axis view with 2D transthoracic echocardiography. The arrow indicates the hyperechoic vegetation inside the tricuspid valve (Melody™ valve-in-valve implantation).



**Fig. 2.** Right ventricle, 3D transthoracic echocardiographic view. The arrow indicates the vegetation inside the tricuspid valve (Melody™ valve-in-valve implantation).

after 72 h of treatment. Fever reoccurred after 8 days of antibiotics, and the blood culture was positive again (with the same bacteria) after 12 days of antibiotics. Simultaneously, the echocardiogram showed an increase in the size of the vegetation, an increased tricuspid mean gradient of 22 mmHg, suggesting tricuspid valve obstruction. The patient was referred to a cardiac surgeon who performed prosthetic valve removal and tricuspid valve replacement (27-mm bioprosthesis), under cardiopulmonary bypass, with a favorable peri- and postprocedural outcome. Intravenous antibiotics with vancomycin and rifampin were administered for 2 weeks, followed by oral antibiotics with linezolid and rifampin for an additional 2 weeks. The patient was discharged from intensive care on day 9 and from hospital on day 21 after surgery, and he then underwent cardiac rehabilitation with an intensive patient/family education program on IE prophylaxis. The follow-up 12 months after surgery remains favorable.

### 3. Discussion

To our knowledge, this is the first pediatric case report of late IE, 4 years after transcatheter tricuspid valve-in-valve implantation in a child with severe CHD. In the VIVID registry, an unsponsored valve-in-valve international database dedicated to patients with acquired or congenital heart diseases, eight cases of IE were reported, from an overall cohort of 306 patients in 80 centers [9]. These eight patients were diagnosed with IE related to various causative agents (2 *Staphylococcus aureus*, 1 *Enterococcus*, 1 *Candida albicans*, 1 *Kingella*, 1 *Haemophilus influenzae*, 2 negative cultures), affecting both Melody™ and Sapien™ valves similarly and with a delay of 2–29 months after PTVR, representing an annualized incidence rate of 1.5% per patient–year. Interestingly, patients with prior IE were not at higher risk for adverse valve-related outcomes after PTVR. In our patient, it is regrettable that his furuncles were not treated appropriately, using both local and systemic antibiotics, and that blood cultures were not obtained earlier at the onset of fever.



In the recent guidelines, IE prevention strategies have restricted antibiotic prophylaxis and reinforced nonspecific hygiene measures [3]. For CHD patients, antibiotic prophylaxis before dental procedures is now recommended in only five situations: prosthetic valve, previous infective endocarditis, unrepaired cyanotic CHD (including palliative shunts and conduits), completely repaired congenital heart defect with prosthetic material or device (whether placed using surgery or catheter intervention, during the first 6 months after the procedure), and repaired CHD with residual defects at the site or adjacent to the site of a prosthetic patch or prosthetic device [3]. The reasons for such a change in antibiotic prophylaxis are multifactorial [2,3]. From a general perspective, the expert consensus to limit antibiotic prophylaxis relies on the lack of scientific evidence for the efficacy of antibiotic prophylaxis, the estimated huge number of patients that may need to be treated to prevent one single case of IE, the small but existing risk of anaphylaxis, and the general problem of the emergence of resistant microorganisms resulting from widespread, often inappropriate, use of antibiotics. Nevertheless, IE still remains a serious issue in cardiology, as neither the incidence nor the mortality of this disease have decreased over the past decades, especially in patients with complex CHD, whose prevalence has markedly increased over the past few decades. The proportion of CHD in patients with IE has been estimated between 2% and 18%, e.g., 5–40 times higher than in the general population [10]. Moreover, there is an important infective risk for percutaneous valve implantation, especially with the Melody valve, as reported by the French working group of Cardiac Catheterization in Congenital Heart Disease Patients with a cumulative IE incidence at 11.8% and annualized IE incidence at 3.6% [11]. This risk may be less common with the Sapien compared with the Melody valve. [12].

In parallel with these more targeted IE guidelines, patients with CHD have recently become eligible for modern transcatheter valve replacement procedures, which should definitely be considered as a great medical advance, especially for young patients with severe cardiac conditions. When considering our patient, we still believe that transcatheter tricuspid valve-in-valve replacement was a good option, since a second tricuspid surgical repair would have represented a very high risk in the context of pulmonary hypertension. Nevertheless, we should not underestimate the importance of patient education dedicated to IE prevention in CHD patients after transcatheter valve replacement.

#### 4. Conclusion

The present pediatric case of IE after transcatheter tricuspid valve-in-valve implantation is in line with the recently issued

warning on the infective risk of transcatheter pulmonary valve replacement in patients with CHD. In the context of medical advances in complex percutaneous procedures in this young population, and in the absence of clear identified risk factors, our community should reinforce patient education dedicated to IE prevention in CHD patients after transcatheter valve replacement.

#### Funding

This research did not receive any specific grant from any funding agency in the public, commercial or not-for-profit sector.

#### Disclosure of interest

The authors declare that they have no competing interest.

#### References

- [1] Murray CJL, Vos T, Lozano R, et al. Disability-adjusted life years (DALYs) for 291 diseases and injuries in 21 regions, 1990–2010: a systematic analysis for the Global Burden of Disease Study 2010. *Lancet Lond Engl* 2012;380:2197–223.
- [2] Duval X, Delahaye F, Alla F, et al. Temporal trends in infective endocarditis in the context of prophylaxis guideline modifications: three successive population-based surveys. *J Am Coll Cardiol* 2012;59:1968–76.
- [3] Habib G, Lancellotti P, Antunes MJ, et al. 2015 ESC Guidelines for the management of infective endocarditis: The Task Force for the Management of Infective Endocarditis of the European Society of Cardiology (ESC). Endorsed by: European Association for Cardio-Thoracic Surgery (EACTS), the European Association of Nuclear Medicine (EANM). *Eur Heart J* 2015;36:3075–128.
- [4] Bonhoeffer P, Boudjemline Y, Saliba Z, et al. Percutaneous replacement of pulmonary valve in a right-ventricle to pulmonary-artery prosthetic conduit with valve dysfunction. *Lancet Lond Engl* 2000;356:1403–5.
- [5] McElhinney DB, Hellenbrand WE, Zahn EM, et al. Short- and medium-term outcomes after transcatheter pulmonary valve placement in the expanded multicenter US melody valve trial. *Circulation* 2010;122:507–16.
- [6] Hon JKF, Cheung A, Ye J, et al. Transcatheter tricuspid valve-in-valve implantation of balloon expandable bioprosthesis. *Ann Thorac Surg* 2010;90:1696–7.
- [7] Scarsini R, Lunardi M, Pesarini G, et al. Long-term follow-up after transcatheter tricuspid valve-in-valve replacement with balloon-expandable aortic valves. *Int J Cardiol* 2017;235:141–6.
- [8] McElhinney DB, Benson LN, Eicken A, et al. Infective endocarditis after transcatheter pulmonary valve replacement using the Melody valve: combined results of 3 prospective North American and European studies. *Circ Cardiovasc Interv* 2013;6:292–300.
- [9] McElhinney DB, Aboulhosn JA, Dvir D, et al. Mid-Term Valve-Related Outcomes After Transcatheter Tricuspid Valve-in-Valve or Valve-in-Ring Replacement. *J Am Coll Cardiol* 2019;73:148–57.
- [10] Baumgartner H. Infective endocarditis in adults with congenital heart disease: is it time to change our approach to prophylaxis based on new insights into risk prediction? *Eur Heart J* 2011;32:1835–7.
- [11] Malekzadeh-Milani S, Houeijeh A, Jalal Z, et al. French national survey on infective endocarditis and the Melody™ valve in percutaneous pulmonary valve implantation. *Arch Cardiovasc Dis* 2018;111:497–506.
- [12] Hascoet S, Mauri L, Claude C, et al. Infective Endocarditis Risk After Percutaneous Pulmonary Valve Implantation With the Melody and Sapien Valves. *JACC Cardiovasc Interv* 2017;10:510–7.