



HAL
open science

Digestive Bleeding in a Georgian Liver Transplant Recipient

Guillaume Desoubieux, Fanny Dujardin, Sandrine Féau-Lecerf, Jean Marc Perarnau, Éric Bailly, Pierre Marty, Jacques Chandener

► **To cite this version:**

Guillaume Desoubieux, Fanny Dujardin, Sandrine Féau-Lecerf, Jean Marc Perarnau, Éric Bailly, et al.. Digestive Bleeding in a Georgian Liver Transplant Recipient. *Clinical Infectious Diseases*, 2015. hal-02443874

HAL Id: hal-02443874

<https://hal.science/hal-02443874>

Submitted on 17 Jan 2020

HAL is a multi-disciplinary open access archive for the deposit and dissemination of scientific research documents, whether they are published or not. The documents may come from teaching and research institutions in France or abroad, or from public or private research centers.

L'archive ouverte pluridisciplinaire **HAL**, est destinée au dépôt et à la diffusion de documents scientifiques de niveau recherche, publiés ou non, émanant des établissements d'enseignement et de recherche français ou étrangers, des laboratoires publics ou privés.

Digestive Bleeding in a Georgian Liver Transplant Recipient

(See page 1083 for the Photo Quiz.)

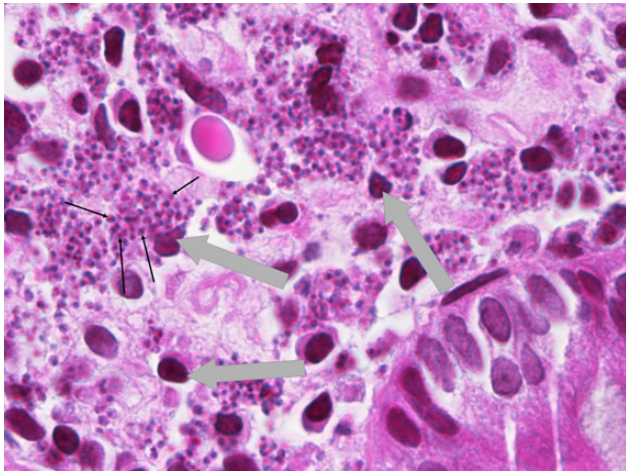


Figure 1. Pathology slide from the cecal biopsy specimen (hematoxylin and eosin staining, magnification $\times 1000$). Although the mucosa of the colon is on the whole preserved, overabundance of the *lamina propria* indicates noticeable local inflammation (3 nuclei are indicated by large gray arrows). Numerous *Leishmania* species amastigotes are clearly visible within the cytoplasm of mononuclear cells (thin black arrows) as oval, small bodies, 1–5 μm long \times 1–2 μm wide, with indistinct cytoplasm and 1 single large nucleus. No other causes of bleeding were found by means of microbiological or histological investigations.

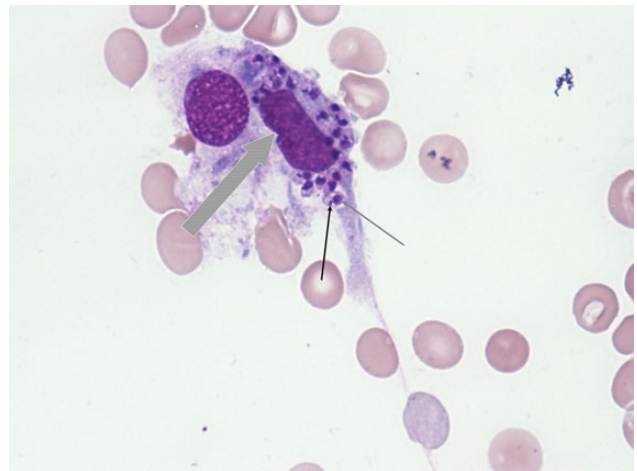

Figure 2. Smear of bone marrow aspirate (May-Grünwald-Giemsa, magnification $\times 1000$). This image shows intracellular amastigotes, although most parasites are generally observed free between mononuclear cells. The nucleus of the parasitized histiocyte is indicated by the large gray arrow. Amastigotes were unambiguously identified by the association of their rod-shaped kinetoplast (thin black arrow) and single nucleus (thin gray arrow).

Diagnosis: Visceral leishmaniasis in a liver transplant recipient.

The pathology slides showed numerous rounded structures, about 5 μm in diameter, inside macrophages (Figure 1). A single stick-like organelle was visible inside some of these structures. These findings are consistent with amastigote forms of *Leishmania* protozoa, also called Leishman–Donovan bodies. The parasites were thereafter identified in smears of bone marrow aspirate (Figure 2), and the serology was positive (*Leishmania*-Spot IF, bioMérieux; *Leishmania* immunoglobulin [IgG] enzyme-linked immunosorbent assay, Novagnost Siemens; and *Leishmania* Western blot IgG, LDBio Diagnostics). *Leishmania* DNA was detected in the blood by polymerase chain reaction (PCR) (primers RV1/RV2), and the species *Leishmania infantum* was identified by sequencing.

Leishmaniasis is an anthroponotic parasitosis transmitted by sandfly bites. About 30 *Leishmania* species have been

described, but only 2, *L. infantum* and *Leishmania donovani*, have been found to cause visceral leishmaniasis (VL); the other species are limited to the cutaneous or mucosal diseases. Asymptomatic VL is 6–7 times more frequent than symptomatic VL [1]. VL is endemic in East Africa, India, Central Asia, the Amazonian forest, and the Mediterranean basin. Although less well known, VL is also endemic in Georgia. The first report of VL in this country was in 1913, and about 2500 local cases of VL were recorded between 1928 and 2008. The frequency appears to have been increasing since 1996, especially in and around Tbilisi (with 5–10 new cases per 10 000 inhabitants in 2008).

In cases of VL, bone marrow, liver, and the spleen are the most commonly infected organs, and this typically results in cytopenia and organomegaly. However, amastigotes may disseminate through all tissues in cases of severe immunosuppression [2]. The digestive tract may be invaded as in our patient. Most

cases of disseminated VL have involved human immunodeficiency virus (HIV)-infected subjects, but new populations at risk of disseminated VL have recently emerged, including solid organ transplant patients. About 100 such cases have been reported [3]: Spain, France, Greece, Italy, and Portugal are countries with the highest incidence, and are all in southern Europe. Because kidney transplant is the most frequent solid organ transplant, a large proportion (77%) of these VL cases involve kidney recipients [3]. As in our patient, the origin of leishmanial infection in transplant recipients is frequently unclear; one possibility—which is mainly observed in endemic areas—is that the recipient may already have been infected with *Leishmania* before transplant, and the infection subsequently reactivated [4]. By contrast, it is more unlikely that the transplanted organ directly infects the recipient, although serological tests should systematically be performed for screening undiagnosed leishmaniasis in donors from endemic areas [5]. Last, the recipient may also be infected by a sandfly bite after his transplant, especially during the summer months in temperate countries such as Georgia [6]. Irrespective of the cause, the immunosuppressive regimen usually reveals belatedly the clinical signs (between a few months to several years after the transplant, with a median delay of 18 months) [3]. The first and major symptom is the onset of fever. Splenomegaly and hepatomegaly are less frequent than in immunocompetent subjects. Although the diagnosis can be confirmed by smears of bone marrow aspirate and/or histology, serology is generally informative in transplant recipients (as in our case, positive in >90% of cases), unlike in HIV-infected subjects (<50%) [7]. PCR is also valuable both for diagnosis and, applied to sequential blood samples, follow-up [8, 9].

The evolution of VL in transplant recipients is always fatal without specific treatment [7]. Consequently, numerous drugs have been assessed for the treatment of VL. Currently, liposomal amphotericin B is the standard treatment in developed countries, because the alternative pentavalent antimonials are associated with severe toxicity, which sometimes results in toxic hepatitis and pancreatitis, and other alternative drugs (eg, miltefosine, paromomycin) are not available everywhere [10]. Our patient received 6 doses of liposomal amphotericin B at 3 mg/kg over 6 days. The digestive bleeding definitively disappeared, and a substantial normalization of the anemia (to 11.2 g/L) was observed after 3 months. Even in cases receiving appropriate antileishmanial therapy, special vigilance is required because of the possibility of further relapse, especially in immunocompromised patients: 58 episodes of recurrence were reported among 21 transplant recipients with VL [11]. Rigorous follow-up for a long period is therefore recommended. Either liposomal amphotericin B, pentamidine, or pentavalent antimonials are proposed for individuals with heavy immunosuppression (eg, HIV infection) until immunity has been

restored [12, 13]. However, we did not administer any secondary prophylaxis to our patient, because his white blood cell count was normal at that time. Furthermore, there is no official guideline for solid organ transplants [5, 12], and VL has usually a low rate of recurrences in such a context [3]. Nonetheless, our patient relapsed 1 year later, because we found evidence of location of amastigotes in the liver.

Notes

Acknowledgments. We thank Dr Ravel of the Centre National de Référence for his expert help with species identification. We are very grateful to Dr Godart for performing the ileocolonoscopy, which allowed diagnosis. We thank the patient for his cooperation. The patient gave his informed consent for the publication of this article. A professional scientific editing and translation company (Alex Edelman & Associates) was involved in the translation of this manuscript from French into English.

Potential conflicts of interest. All authors report no potential conflicts. All authors have submitted the ICMJE Form for Disclosure of Potential Conflicts of Interest. Conflicts that the editors consider relevant to the content of the manuscript have been disclosed.

**Guillaume Desoubaux,^{1,2} Eve-Anne Guéry,¹
Fanny Dujardin,³ Sandrine Féau-Lecerf,⁴
Jean-Marc Perarnau,⁴ Éric Bailly,¹
Pierre Marty,^{5,6} and Jacques Chandanier^{1,2}**

¹CHU de Tours, Service de Parasitologie–Mycologie–Médecine
Tropicale, ²Université François Rabelais, Faculté de Médecine,
Centre d'Étude des Pathologies Respiratoires–INSERM U1100/E.A. 6305,
³CHU de Tours, Service d'Anatomie et Cytologie Pathologiques,
⁴CHU de Tours, Service de Gastro-entérologie, Tours, ⁵CHU de Nice,
Laboratoire de Parasitologie-Mycologie, and ⁶Université de
Nice-Sophia-Antipolis, Faculté de Médecine, INSERM U1065,
Équipe 6, Nice, France

References

1. Van Griensven J, Diro E. Visceral leishmaniasis. *Infect Dis Clin North Am* **2012**; 26:309–22.
2. Rosenthal E, Marty P, del Giudice P, et al. HIV and *Leishmania* coinfection: a review of 91 cases with focus on atypical locations of *Leishmania*. *Clin Infect Dis* **2000**; 31:1093–5.
3. Antinori S, Cascio A, Parravicini C, Bianchi R, Corbellino M. Leishmaniasis among organ transplant recipients. *Lancet Infect Dis* **2008**; 8:191–9.
4. Kubar J, Marty P, Lelièvre A, et al. Visceral leishmaniasis in HIV-positive patients: primary infection, reactivation and latent infection. Impact of the CD4+ T-lymphocyte counts. *AIDS* **1998**; 12: 2147–53.
5. Fishman JA. Infections in immunocompromised hosts and organ transplant recipients: essentials. *Liver Transpl* **2011**; 17(suppl 3):S34–7.
6. Michel G, Pomares C, Ferrua B, Marty P. Importance of worldwide asymptomatic carriers of *Leishmania infantum* (*L. chagasi*) in human. *Acta Trop* **2011**; 119:69–75.
7. Basset D, Faraut F, Marty P, et al. Visceral leishmaniasis in organ transplant recipients: 11 new cases and a review of the literature. *Microbes Infect Inst Pasteur* **2005**; 7:1370–5.
8. Lachaud L, Dereure J, Chabbert E, et al. Optimized PCR using patient blood samples for diagnosis and follow-up of visceral leishmaniasis, with special reference to AIDS patients. *J Clin Microbiol* **2000**; 38: 236–40.

9. Cota GF, de Sousa MR, Demarqui FN, Rabello A. The diagnostic accuracy of serologic and molecular methods for detecting visceral leishmaniasis in HIV infected patients: meta-analysis. *PLoS Negl Trop Dis* **2012**; 6:e1665.
10. Bern C, Adler-Moore J, Berenguer J, et al. Liposomal amphotericin B for the treatment of visceral leishmaniasis. *Clin Infect Dis* **2006**; 43: 917–24.
11. Simon I, Wissing KM, Del Marmol V, et al. Recurrent leishmaniasis in kidney transplant recipients: report of 2 cases and systematic review of the literature. *Transpl Infect Dis* **2011**; 13:397–406.
12. Hernández-Pérez J, Yebra-Bango M, Jiménez-Martínez E, et al. Visceral leishmaniasis (kala-azar) in solid organ transplantation: report of five cases and review. *Clin Infect Dis* **1999**; 29:918–21.
13. Buffet PA, Rosenthal É, Gangneux J-P, et al. Therapy of leishmaniasis in France: consensus on proposed guidelines [in French]. *Presse Méd* **2011**; 40:173–84.

Correspondence: Guillaume Desoubeaux, MD, PhD, CHU de Tours, Service de Parasitologie–Mycologie–Médecine tropicale, Hôpital Bretonneau, Pôle de Biologie Médicale, Bâtiment B2A–1^{er} étage, 2 boulevard Tonnellé, 37044 CHU de Tours Cedex 9, France (guillaume.desoubeaux@univ-tours.fr).

Clinical Infectious Diseases® 2015;60(7):1131–3

© The Author 2015. Published by Oxford University Press on behalf of the Infectious Diseases Society of America. All rights reserved. For Permissions, please e-mail: journals.permissions@oup.com.

DOI: 10.1093/cid/ciu962