



**HAL**  
open science

## **Diffuse Glioneuronal tumour with Oligodendroglioma-like features and Nuclear Clusters (DGONC) – a molecularly-defined glioneuronal CNS tumour class displaying recurrent monosomy 14**

Maximilian Deng, Martin Sill, Dominik Sturm, Damian Stichel, Hendrik Witt,  
Jonas Ecker, Andreas Wittmann, Jens Schittenhelm, Martin Ebinger, Martin  
Schuhmann, et al.

### **► To cite this version:**

Maximilian Deng, Martin Sill, Dominik Sturm, Damian Stichel, Hendrik Witt, et al.. Diffuse Glioneuronal tumour with Oligodendroglioma-like features and Nuclear Clusters (DGONC) – a molecularly-defined glioneuronal CNS tumour class displaying recurrent monosomy 14. *Neuropathology and Applied Neurobiology*, 2019, 10.1111/nan.12590 . hal-02441024

**HAL Id: hal-02441024**

**<https://hal.science/hal-02441024v1>**

Submitted on 18 Jun 2024

**HAL** is a multi-disciplinary open access archive for the deposit and dissemination of scientific research documents, whether they are published or not. The documents may come from teaching and research institutions in France or abroad, or from public or private research centers.



L'archive ouverte pluridisciplinaire **HAL**, est destinée au dépôt et à la diffusion de documents scientifiques de niveau recherche, publiés ou non, émanant des établissements d'enseignement et de recherche français ou étrangers, des laboratoires publics ou privés.



Distributed under a Creative Commons Attribution - NonCommercial - NoDerivatives 4.0  
International License



# Diffuse glioneuronal tumour with oligodendroglioma-like features and nuclear clusters (DGONC) – a molecularly defined glioneuronal CNS tumour class displaying recurrent monosomy 14

M. Y. Deng<sup>1,2</sup>, M. Sill<sup>1,3</sup>, D. Sturm<sup>1,2,4</sup>, D. Stichel<sup>5,6</sup>, H. Witt<sup>1,3,4</sup>, J. Ecker<sup>1,4,7</sup>, A. Wittmann<sup>1,2</sup>, J. Schittenhelm<sup>8</sup> , M. Ebinger<sup>9</sup>, M. U. Schuhmann<sup>10</sup>, D. Figarella-Branger<sup>11</sup>, E. Aronica<sup>12</sup>, O. Staszewski<sup>13</sup>, M. Preusser<sup>14</sup>, C. Haberler<sup>15</sup>, M. Lauten<sup>16</sup>, U. Schüller<sup>17</sup>, C. Hartmann<sup>18</sup>, M. Snuderl<sup>19</sup>, C. Dunham<sup>20</sup>, N. Jabado<sup>21,22</sup>, P. Wesseling<sup>23,24</sup>, M. Deckert<sup>25</sup>, K. Keyvani<sup>26</sup>, N. Gottardo<sup>27,28,29</sup>, F. Giangaspero<sup>30,31</sup>, K. von Hoff<sup>32</sup>, D. W. Ellison<sup>33</sup>, T. Pietsch<sup>34</sup>, C. Herold-Mende<sup>35</sup>, T. Milde<sup>1,4,7</sup>, O. Witt<sup>1,4,7</sup>, M. Kool<sup>1,3</sup>, A. Korshunov<sup>5,6</sup>, W. Wick<sup>36,37</sup>, A. von Deimling<sup>5,6</sup>, S. M. Pfister<sup>1,3,4</sup>, D. T. W. Jones<sup>1,2,1</sup> and F. Sahn<sup>1,5,6\*</sup> 

<sup>1</sup>Hopp Children's Cancer Center Heidelberg (KiTZ), University Hospital Heidelberg, Heidelberg, Germany, <sup>2</sup>Junior Research Group Pediatric Glioma Research, German Cancer Research Center (DKFZ), Heidelberg, Germany, <sup>3</sup>Division of Pediatric Neurooncology, German Cancer Research Center (DKFZ), German Cancer Consortium (DKTK), Heidelberg, Germany, <sup>4</sup>Department of Pediatric Oncology, Hematology and Immunology, Hopp Children's Cancer Center (KiTZ), University Hospital Heidelberg, Heidelberg, Germany, <sup>5</sup>Department of Neuropathology, Institute of Pathology, University Hospital Heidelberg, Heidelberg, Germany, <sup>6</sup>Clinical Cooperation Unit Neuropathology, German Cancer Consortium (DKTK), German Cancer Research Center (DKFZ), Heidelberg, Germany, <sup>7</sup>Clinical Cooperation Unit Pediatric Oncology, German Cancer Research Center (DKFZ), German Consortium for Translational Cancer Research (DKTK), Heidelberg, Germany, <sup>8</sup>Department of Neuropathology, Institute of Pathology and Neuropathology and Comprehensive Cancer Center Tübingen-Stuttgart, University Hospital of Tübingen, Tübingen, Germany, <sup>9</sup>Department of Pediatric Hematology/Oncology, Children's University Hospital, Tübingen, Germany, <sup>10</sup>Department of Neurosurgery, Division of Pediatric Neurosurgery, University Hospital Tübingen, Tübingen, Germany, <sup>11</sup>Inst Neuropathol, CHU Timone, Service d'Anatomie Pathologique et de Neuropathologie, Aix Marseille Univ, APHM, CNRS, INP, Marseille, France, <sup>12</sup>Department of (Neuro)Pathology, Amsterdam Neuroscience, Amsterdam UMC, University of Amsterdam, Amsterdam, The Netherlands, <sup>13</sup>Institute of Neuropathology, Medical Faculty, University of Freiburg, Freiburg, Germany, <sup>14</sup>Clinical Division of Oncology, Department of Medicine I, Comprehensive Cancer Center Vienna, Medical University of Vienna, Vienna, Austria, <sup>15</sup>Institute of Neurology, Comprehensive Cancer Centre Vienna, Medical University of Vienna, Vienna, Austria, <sup>16</sup>Department of Paediatrics, Paediatric Haematology and Oncology, University of Lübeck, Lübeck, Germany, <sup>17</sup>Department of Paediatric Haematology and Oncology and Institute of Neuropathology, University Medical Centre Hamburg-Eppendorf, Research Institute at the Children's Cancer Centre Hamburg, Hamburg, Germany, <sup>18</sup>Department of Neuropathology, Institute of Pathology, Hannover Medical School (MHH), Hannover, Germany, <sup>19</sup>Department of Pathology, Division of Neuropathology, NYUSoM, New York, NY, USA, <sup>20</sup>Department of Pathology and Laboratory Medicine, University of British Columbia, Vancouver, Canada, <sup>21</sup>Department of Human Genetics, McGill University, Montreal, QC, Canada, <sup>22</sup>Department of Pediatrics, McGill University, McGill University Health Centre Research Institute, Montreal, QC, Canada, <sup>23</sup>Department of Pathology, Amsterdam Universities Medical Centers/VUmc, Brain Tumor Center Amsterdam University Medical Center, Amsterdam, The Netherlands, <sup>24</sup>Princess Máxima Center for Pediatric Oncology, Utrecht, University Medical Center Utrecht, Utrecht, The Netherlands, <sup>25</sup>Institute of Neuropathology, University Hospital of Cologne, Cologne, Germany, <sup>26</sup>Institute of Neuropathology, University of Duisburg-Essen, Essen, Germany, <sup>27</sup>Telethon Kids Institute, Perth, WA, Australia, <sup>28</sup>Centre for Child Health Research, University of Western Australia, Perth, WA, Australia, <sup>29</sup>Department of Oncology, Princess Margaret Hospital, Perth, WA, Australia, <sup>30</sup>Department of Radiological, Oncological and Anatomopathological Science, Sapienza University of Rome, Rome, Italy, <sup>31</sup>IRCCS Neuromed, Pozzilli (Is), Italy, <sup>32</sup>Department of Paediatric Haematology and Oncology, Charité-Universitätsmedizin, Berlin, Germany, <sup>33</sup>Department of Pathology, St. Jude Children's Research Hospital, Memphis, TN, USA, <sup>34</sup>Institute of Neuropathology, Brain Tumor Reference

Center of the Society for Neuropathology and Neuroanatomy, University of Bonn Medical Center, Bonn, Germany, <sup>35</sup>Division of Experimental Neurosurgery, Department of Neurosurgery, University Hospital Heidelberg, Heidelberg, Germany, <sup>36</sup>Department of Neurology and Neurooncology Program, National Center for Tumor Diseases, Heidelberg University Hospital, Heidelberg, Germany and <sup>37</sup>Clinical Cooperation Unit Neurooncology, German Cancer Research Center (DKFZ), German Consortium for Translational Cancer Research (DKTK), Heidelberg, Germany

---

M. Y. Deng, M. Sill, D. Sturm, D. Stichel, H. Witt, J. Ecker, A. Wittmann, J. Schittenhelm, M. Ebinger, M. U. Schuhmann, D. Figarella-Branger, E. Aronica, O. Staszewski, M. Preusser, C. Haberler, M. Lauten, U. Schüller, C. Hartmann, M. Snuderl, C. Dunham, N. Jabado, P. Wesseling, M. Deckert, K. Keyvani, N. Gottardo, F. Giangaspero, von K. Hoff, D. W. Ellison, T. Pietsch, C. Herold-Mende, T. Milde, O. Witt, M. Kool, A. Korshunov, W. Wick, von A. Deimling, S. M. Pfister, D. T. W. Jones and F. Sahm (2020) *Neuropathology and Applied Neurobiology*

### **Diffuse glioneuronal tumour with oligodendroglioma-like features and nuclear clusters (DGONC) – a molecularly defined glioneuronal CNS tumour class displaying recurrent monosomy 14**

**Aims:** DNA methylation-based central nervous system (CNS) tumour classification has identified numerous molecularly distinct tumour types, and clinically relevant subgroups among known CNS tumour entities that were previously thought to represent homogeneous diseases. Our study aimed at characterizing a novel, molecularly defined variant of glioneuronal CNS tumour. **Patients and methods:** DNA methylation profiling was performed using the Infinium MethylationEPIC or 450 k BeadChip arrays (Illumina) and analysed using the ‘conumee’ package in R computing environment. Additional gene panel sequencing was also performed. Tumour samples were collected at the German Cancer Research Centre (DKFZ) and provided by multinational collaborators. Histological sections were also collected and independently reviewed. **Results:** Genome-wide DNA methylation data from >25 000 CNS tumours were screened for clusters separated from established DNA methylation classes,

revealing a novel group comprising 31 tumours, mainly found in paediatric patients. This DNA methylation-defined variant of low-grade CNS tumours with glioneuronal differentiation displays recurrent monosomy 14, nuclear clusters within a morphology that is otherwise reminiscent of oligodendroglioma and other established entities with clear cell histology, and a lack of genetic alterations commonly observed in other (paediatric) glioneuronal entities. **Conclusions:** DNA methylation-based tumour classification is an objective method of assessing tumour origins, which may aid in diagnosis, especially for atypical cases. With increasing sample size, methylation analysis allows for the identification of rare, putative new tumour entities, which are currently not recognized by the WHO classification. Our study revealed the existence of a DNA methylation-defined class of low-grade glioneuronal tumours with recurrent monosomy 14, oligodendroglioma-like features and nuclear clusters.

**Keywords:** brain tumour, DNA methylation classification, glioneuronal tumour, monosomy 14, paediatric

---

Correspondence: Felix Sahm, Department of Neuropathology, University Hospital Heidelberg, Im Neuenheimer Feld 224, 69120 Heidelberg, Germany. Tel: +49 6221 56-37886; Fax: +49 6221 56 4566; E-mail: felix.sahm@med.uni-heidelberg.de and

David T. W. Jones, Paediatric Glioma Research Group (B360), German Cancer Research Centre (DKFZ), Im Neuenheimer Feld 280, 69120 Heidelberg, Germany. Tel: +49 6221 424675; Fax: +49 6221 424639; E-mail: david.jones@kitz-heidelberg.de

\*Indicates shared senior authorship.

## **Introduction**

For optimal management of patients suffering from the central nervous system (CNS) tumours, accurate diagnosis is crucial to predicting clinical course and to the rational selection of the appropriate therapy for each individual patient. However, the extensive diversity of CNS tumours – exceeding currently recognized histologically defined tumour entities – poses a challenge for the

standardization of diagnostic processes [1,2]. Extensive DNA methylation profiling of brain tumours – representing a combination of somatic, tumour-specific DNA methylation changes together with a presumed ‘molecular memory’ of the specific cell of origin for a given tumour type – has revealed the existence of novel, molecularly defined CNS tumour entities and provided insight into clinically relevant molecular subgroups among known CNS tumour types, which were previously thought to represent a homogenous disease [3–11].

In the WHO 2016 classification, glioneuronal CNS tumours (GNTs) were represented by a diverse spectrum of tumour entities, including gangliogliomas (WHO grade I), anaplastic ganglioglioma (WHO grade III), desmoplastic infantile astrocytoma and ganglioglioma (WHO grade I), papillary glioneuronal tumour (papillary GNT) (WHO grade I), rosette-forming GNT (WHO grade I) and diffuse leptomeningeal GNT (DLGNT). The aforementioned tumour entities were associated with underlying, characteristic genetic alterations, including *BRAF V600E* mutations in gangliogliomas, *KIAA1549-BRAF* fusions in DLGNT, *SLC44A1-PRKCA* fusion in papillary GNT and mutation of *PIK3CA* and *FGFR1* in rosette-forming GNT [1,12,13].

Recent studies have shown that based on DNA methylation classification, most histopathological GNT entities cluster into corresponding methylation classes. Furthermore, GNT entities such as DLGNT could be further stratified into clinically relevant, molecularly distinct subgroups [5].

Here, we introduce a novel, molecularly defined CNS tumour type with glioneuronal features, nuclear clusters and recurrent monosomy 14, for which we provisionally propose the term ‘diffuse glioneuronal tumour with oligodendroglioma-like features and nuclear clusters’, or DGONC. To elucidate the underlying molecular mechanisms, we performed molecular characterization of this entity based on DNA methylation and copy number profiling, RNA and targeted DNA sequencing together with clinical and neuropathological re-evaluation.

## Materials and methods

### Tumour samples and patient population

Tumour samples and clinical patient data were collected from the archives of the Dept. of Neuropathology, Neurosurgery, Medical Oncology or Paediatric Oncology at

Heidelberg, Berlin, Bonn, Cologne, Essen, Freiburg, Hamburg, Hannover, Tübingen, Freiburg, Lübeck (Germany), Vienna (Austria), Marseille (France), Amsterdam (The Netherlands), Rome (Italy), Memphis, New York (USA), Montreal (Canada) and Perth (Australia). Tumour tissue and clinical data were analysed in accordance with the local ethical regulations. Informed consent was obtained from all patients and/or their legal representative according to local guidelines. Additional clinical details are listed in the Table S1.

### DNA and RNA extraction, RNA and targeted gene panel sequencing, and DNA methylation profiling

DNA and/or RNA from tumour tissue with tumour cell content over 80% by histopathological evaluation were extracted from FFPE tissue (Maxwell 16 FFPE Plus LEV DNA Purification Kit and Maxwell 16 LEV RNA FFPE Kit, Promega, Madison, WI, USA). RNA and targeted gene panel sequencing were performed as previously described [14,15]. DNA methylation profiling was conducted using the Infinium MethylationEPIC (850k) BeadChip (Illumina, San Diego, CA, USA) or Infinium HumanMethylation450 (450k) BeadChip (Illumina) array, as previously described [4,8]. Further processing and genome-wide analyses were performed using the ‘conumee’ package in R (<http://www.bioconductor.org>) [3,9].

### Patient cohort selection

Genome-wide DNA methylation data from >25 000 CNS tumours in the extended Heidelberg cohort were screened for clusters of tumours separated from established DNA methylation classes by t-SNE analysis (t-Distributed Stochastic Neighbor Embedding) as previously described [3,5,16], revealing a novel group comprising 31 tumours. A further targeted t-SNE analysis was performed based on the 10 000 most variably methylated probes, confirming the existence of a distinct methylation class when compared with 160 well-characterized reference samples representing CNS tumours of defined histological and/or molecular subgroups, confirming the distinct nature of DGONC (as described below). Unsupervised hierarchical clustering was performed using the 10 000 probes with the highest standard deviation. The Euclidean distance between samples was calculated and followed by applying Wards linkage method for sample clustering. In the heat map, probes

were reordered by complete linkage hierarchical clustering of the Euclidean distance between the probes.

In order to substantiate the robustness of the novel cluster, a more comprehensive t-SNE analysis was performed, using variance weighted 1-Pearson correlation distance (perplexity = 10) (Figure S2a), comprising all cases from Capper, Jones, Sill, Hovestadt *et al.* Nature 2018 [3] (<https://media.nature.com/original/nature-assets/nature/journal/v555/n7697/extref/nature26000-s3.xlsx>) and Deng *et al.* Acta Neuropathologica 2018 [5], representing the selected reference entities, as shown in Figure 1a. Both t-SNE analyses, the initial one with 160 reference samples and the larger subsequent analysis show that the DGONCs remain a distinct and robust tumour group. In addition, HDBSCAN analysis with minPts = 8 (<https://arxiv.org/pdf/1602.03730.pdf>) was performed with the subsequent larger reference cohort (Figure S2b). This was repeated 500 times on a random subset of 80% of the data, showing a high degree of stability in the number of detected clusters over 500 resampling iterations (Figure S2c), indicating a stable and distinct methylation group of DGONCs. Furthermore, cluster stability (Figure S2d) indicates the proportion of times when two samples are assigned to the same cluster averaged over all samples

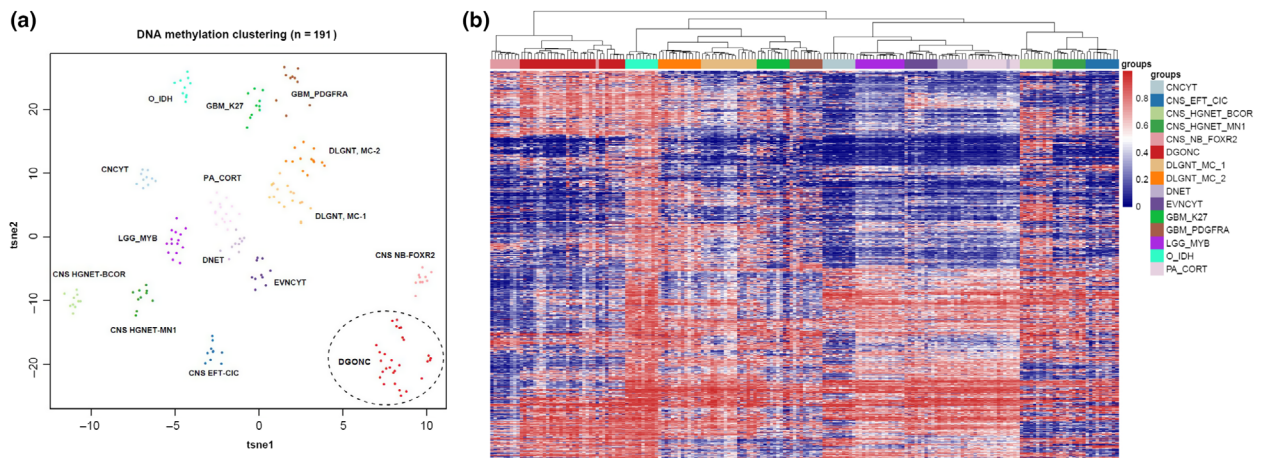
in the clustering of the complete data set. The heat map representing the consensus matrix (Figure S2e) shows how often two samples are assigned to the same cluster over 500 resampling iterations. Hence, the DNA methylation classification represents a robust tool in separating the different samples, while DGONCs display a distinct genome-wide DNA methylation profile when compared to other reference brain tumour entities.

## Histopathology and immunohistochemistry

Where possible (13/31), haematoxylin and eosin (H&E)-stained formalin-fixed paraffin-embedded (FFPE) sections from tumours in the DGONC methylation class were reviewed by experienced neuropathologists (FS, AK) according to WHO 2016 guidelines.

## Statistics

Overall survival (OS) and progression-free survival (PFS) were evaluated by Kaplan–Meier analysis and log-rank test. Binary and categorical patient characteristics between subgroups were analysed using two-sided Fisher's exact test. *P*-values <0.05 were considered significant. All analyses were performed using RStudio Version 1.2.1335.



**Figure 1.** DNA methylation profiling of DGONC. t-SNE (a) and unsupervised hierarchical clustering (b) analyses were performed based on the 10 000 most variably methylated probes, revealing the existence of a distinct DGONC methylation class. DGONC samples ( $n = 31$ ) were compared with 160 well-characterized reference samples representing CNS tumours of defined histological and/or molecular subgroups, confirming the distinct nature of the DGONC entity. Reference cohorts: CNCYT, central neurocytoma; CNS HGNET-BCOR, CNS high-grade neuroepithelial tumour with BCOR alteration; CNS EFT-CIC, CNS Ewing sarcoma family tumour with CIC alteration; CNS HGNET-MN1, CNS high-grade neuroepithelial tumour with MN1 alteration; CNS NB-FOXR2, CNS neuroblastoma with FOXR2 activation; DLGNT, MC-1 and 2, diffuse leptomeningeal glioneuronal tumour, methylation classes 1 and 2; DNET, dysembryoplastic neuroepithelial tumour; EVNCYT, extraventricular neurocytoma; GBM\_K27, Histone 3 K27M-mutant glioblastoma; GBM\_PDGFR, H3/IDH-wild-type glioblastoma RTK I group; LGG\_MYB, low-grade glioma, MYB/MYB-L1; O\_IDH, IDH glioma, subclass 1p/19q co-deleted oligodendroglioma; PA\_CORT, hemispheric pilocytic astrocytoma.

## Results

### DNA methylation profiling identifies a novel glioneuronal CNS tumour entity

Genome-wide DNA methylation data from >25 000 CNS tumours (generated via Illumina DNA methylation array) in the extended Heidelberg cohort were screened for clusters of tumours separated from established DNA methylation classes by t-SNE as previously described [5], revealing a novel group comprising 31 tumours. The distinct nature of this class was confirmed through a focused, t-SNE and unsupervised hierarchical clustering analysis of DNA methylation patterns comparing the 31 tumours with 160 well-characterized reference samples representing CNS tumours of known histological and/or molecular entities that were thought to be possible morphological mimics (Figure 1). There is also a hint of possible further substructure within this group based on the t-SNE analysis, but the numbers are too small to confirm this (or not) at present.

### Initial diagnoses of DGONC

Initial histological diagnoses were available for 29 of the 31 DGONC tumours, and included primitive neuroectodermal tumours WHO grade IV (9/29, 31%), atypical extraventricular neurocytoma WHO grade II (5/29, 17%), glioblastoma WHO grade IV (4/29, 14%), anaplastic oligodendroglioma WHO grade III (IDH and 1p/19q status not assessed for diagnosis, 4/29, 14%), low-grade glioma (3/29, 10%), as well as single cases originally diagnosed as central neurocytoma WHO grade II, complex dysembryoplastic neuroepithelial tumour WHO grade I (DNET) and ependymoma WHO grade II.

DGONCs available for neuropathological review ( $n = 13$ ; F.S. and A.K.) were characterized as clear cell neoplasms with diffuse infiltrative growth. The strong MAP2-positivity of DGONC tumours, in combination with predominant GFAP-negativity and mainly strong synaptophysin-positivity, suggests the glioneuronal nature of this tumour class (Figure 2).

Histological reports and personal communication regarding the remainder were compatible with these findings, except for three which had features qualifying for the diagnosis of CNS neuroblastoma. Thus, a distinctive combination of oligodendroglioma-like perinuclear haloes, clear cell appearance, vascular proliferation and nuclear

clusters represented the hallmark morphology of most DGONC (Figure S1). Nuclear clusters in DGONCs were generally narrowly arranged with scarce surrounding cytoplasm, partly resembling 'pennies on a plate' [17]. Neuropil-like islands in the perivascular region and the presence of focal lymphocytic infiltrations and macrophages were encountered in a subset of cases. Giant cells, perivascular pseudorosettes or calcifications were observed in single cases.

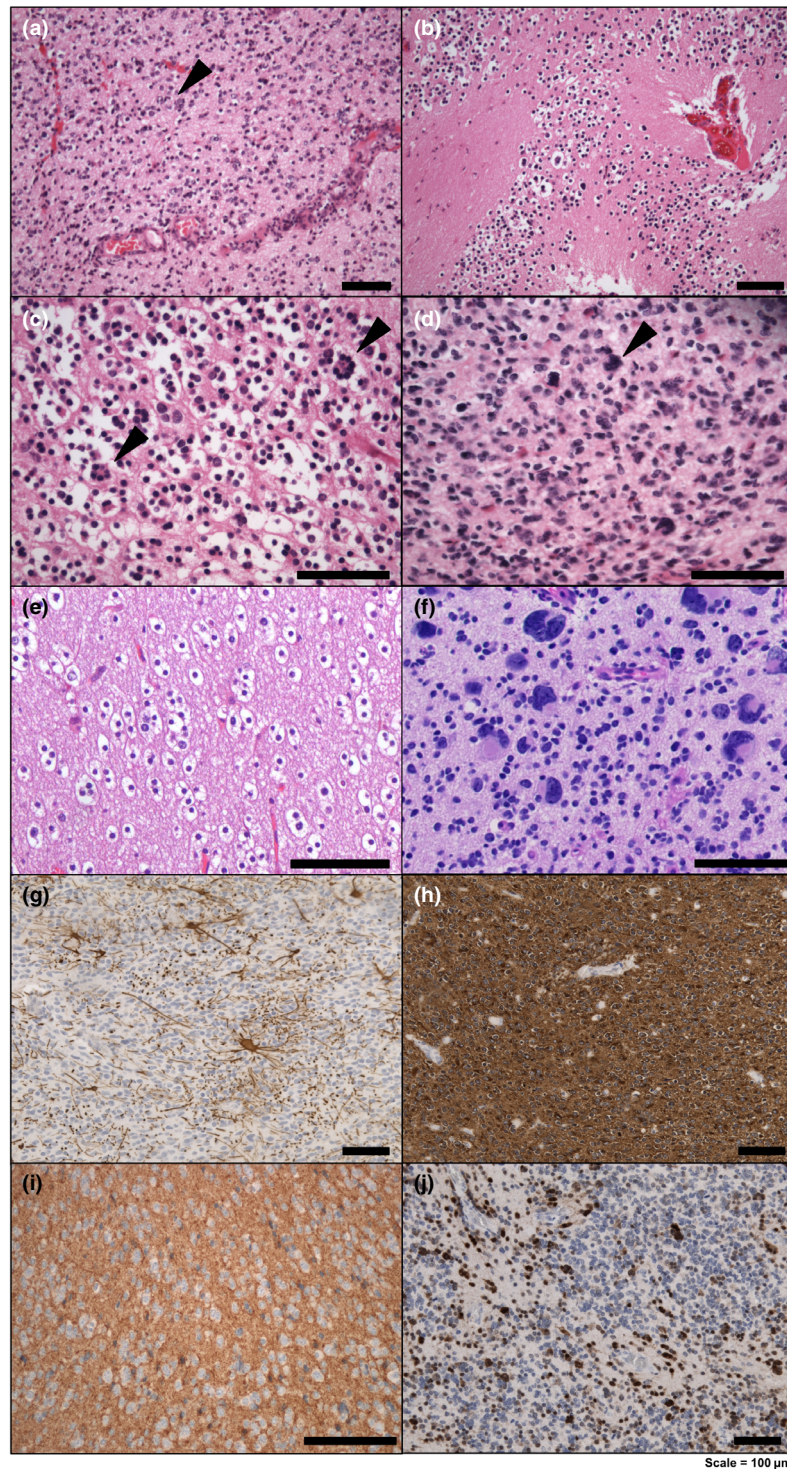
These findings also explain the spectrum of initial diagnoses: The diagnosis of oligodendroglioma, neurocytoma and DNET is in line with the clear cell histology of DGONC. In particular, positivity for MAP2 and lack of pronounced GFAP expression may trigger the diagnosis of oligodendroglioma, especially in absence of testing for 1p/19q and IDH status. In turn, with detection of strong synaptophysin expression and weak GFAP staining, provided a proven wild-type status of IDH and 1p/19q, the differential diagnoses of neurocytoma and DNET can be raised. With the impression of pleomorphism resulting from the nuclear clusters, and the diffuse infiltration, higher grade neuroepithelial tumours, including glioblastoma and primitive neuroectodermal tumours could also be considered.

### Recurrent monosomy 14 represents a hallmark in DGONC

Monosomy 14 represented a unifying molecular feature among DGONCs, encountered in 30 of 31 cases (97%) on copy number profiles derived from DNA methylation arrays. Further recurrent large-scale chromosomal alterations included gain of chromosomal arm 1q (8/31, 26%) and 17q (18/31, 58%), and loss of 19q (11/31, 35%) (Figure 3). While monosomy 14 is not exclusively found in DGONC, no other entity in the reference set showed a frequency of this alteration anywhere close to ~100% (Figure S3).

### Absence of characteristic genetic alterations compared with other glioneuronal CNS tumour entities

RNA ( $n = 8$ ) and gene panel DNA ( $n = 13$ ) sequencing were performed for a subset of cases with material available [15]. None of the tumours harboured somatic hotspot mutations in genes encoding histone 3 variants, *IDH1/2* or the *TERT* promoter region. Mutations



**Figure 2.** Histopathological features of molecularly defined DGONC. DGONCs display clear cell features with moderate- to high-cellularity and diffuse infiltration. Tumour cells exhibit isomorphic, round nuclei with oligodendroglioma-like perinuclear haloes (a–e). Vascular proliferation (a–b) and neuropil-like islands (b) were encountered in a subset of cases. Nuclear clusters (arrow) represent a hallmark feature in DGONCs (a, c, d). Giant cells were encountered in one case (f, DGNOC-22). DGONCs were preponderantly characterized by GFAP-negativity (g), strong MAP2- (h) and synaptophysin-positivity (i), and focal NeuN-positivity (j, not clearly discernible from residual cells). Scale bars represent 100  $\mu$ m.

affecting BRAF V600 were also absent, in contrast to various other glioneuronal CNS entities such as gangliogliomas. Copy number changes indicative of *KIAA1549:BRAF* fusions, as seen in pilocytic astrocytoma and diffuse leptomeningeal GNTs, were missing in DGONCs [18–20]. One case (DGONC-30) demonstrated a gain of *FGFR1* on copy number profile, while RNA sequencing remained inconspicuous for *FGFR1* fusions.

### Clinical characteristics and survival outcome

DGONCs were found to predominantly occur in paediatric patients (median: 9 years) with individual cases exhibiting a notably higher age at diagnosis (range 2–75 years). No gender predilection was observed in our series (M:F, 1:1). DGONCs were located in the cerebral hemispheres, preferentially emerging from the temporal lobes, and did not display tumour dissemination at initial presentation. Available follow-up data of 12 DGONC patients indicated a relatively favourable clinical course despite the fact that many of the original histological diagnoses were of high-grade lesions, with disease progression in 3 of 12 patients (5-year PFS: 79%). Two patients eventually died 25 and 96 months after the initial diagnosis (5-year OS: 86%; Figure 4).

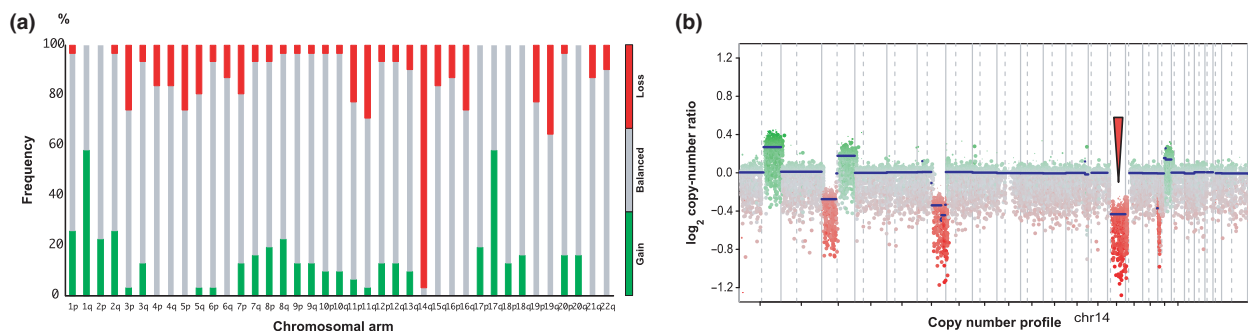
### Discussion

In recent years, large-scale genomic and epigenomic analyses have shown that DNA methylation-based CNS tumour classification utilizing machine learning represents a valuable tool, identifying clinically relevant subgroups in various CNS tumour entities, which were previously considered a homogenous disease [1,3–5,7–,11]. Especially in contrast to conventional

pathology, methylation-based tumour classification is not subjected to the pressure of assigning all tumours to established entities even for atypical cases. With increasing sample size, the methylation classifier allows and facilitates the identification of exceptionally rare, putative new tumour entities, which are currently not recognized by the WHO classification due to their rarity and/or histological overlap with existing entities [3,4,9].

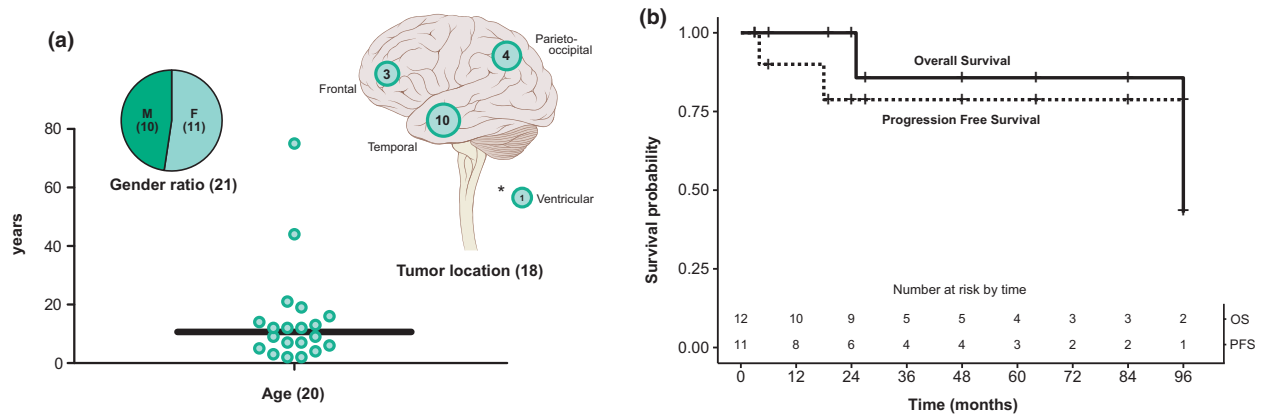
Here, our study led to the identification of a novel, methylation-defined glioneuronal CNS tumour class, provisionally designated ‘diffuse glioneuronal CNS tumour with oligodendroglioma-like features and nuclear clusters (DGONC)’. The histological profile of the DGONC tumour class exhibited a substantial overlap with other CNS tumour entities, including the presence of a clear cell morphology, vascular proliferation and GFAP-negativity, which are commonly seen in (anaplastic) oligodendroglioma, ‘paediatric oligodendroglioma’ or neurocytic tumours. Furthermore, DGONC tumours partly resemble ‘CNS-PNET’ based on their high, isomorphic cellularity in combination with the expression of synaptophysin, explaining the previous other designations of the tumours of this type in the light of the WHO classification criteria.

While oncogenic events, which are characteristic in other glioneuronal CNS tumour entities (e.g. *BRAF* or *FGFR* alterations), were absent in our series, further analyses with larger cohorts are required to elucidate the underlying mechanisms leading to the occurrence of this enigmatic DNA methylation-defined CNS tumour class. Implementation of this class into novel versions of the brain tumour classifier (moleculareuropathology.org) will also assist in identifying additional cases. Based on the as-yet limited survival analysis, this CNS tumour class may best correspond to WHO grade II,



**Figure 3.** Copy number profiles reveal recurrent monosomy 14 in DGONC. Summary of large-scale chromosomal gains and losses are shown in (a) for all cases. Copy number profiles derived from DNA methylation arrays (b) revealed monosomy 14 in 30 of the 31 cases.





**Figure 4.** Clinical patient information and survival analysis in DGONC. Patient age at diagnosis, gender distribution and tumour locations are shown in (a). Kaplan–Meier curves for progression-free and overall survival (b) are illustrated with numbers at risk at each time point.

although this hypothesis will require confirmation in larger series of uniformly treated patients.

Our findings illustrate the existence of a DNA methylation-defined class of low-grade GNTs with recurrent monosomy 14, nuclear clusters within a morphology that mimics various previously established entities, and a lack of oncogenic alterations commonly observed in other (paediatric) glioneuronal entities, representing a distinct molecular variant within a spectrum of low-grade GNTs.

## Acknowledgements

For outstanding technical support and expertise we sincerely thank the Microarray Unit of the German Cancer Research Centre (DKFZ) Genomics and Proteomics Core Facility and Hai-Yen Nguyen & Laura Doerner (Department of Neuropathology, Institute of Pathology at the University Hospital Heidelberg). The Editorial Board of Neuropathology and Applied Neurobiology is committed to peer-review integrity, upholding the highest standards during the review process. Thus, this article was peer-reviewed by independent, anonymous expert referees, and the authors had no influence during the editorial decision or the handling of the manuscript.

## Conflict of Interests

DC, MS, AvD, DTWJ and SMP have a patent pending: DNA methylation-based method for classifying tumour species of the brain (EP3067432A1). FS has received honoraria for advisory board or lectures from AbbVie and Illumina and Medac and travel support from Agilent. MP has received honoraria for lectures,

consultation or advisory board participation from the following for-profit companies: Bayer, Bristol-Myers Squibb, Novartis, Gerson Lehrman Group (GLG), CMC Contrast, GlaxoSmithKline, Mundipharma, Roche, BMJ Journals, MedMedia, Astra Zeneca, AbbVie, Lilly, Meda-head, Daiichi Sankyo, Sanofi, Merck Sharp & Dome, Tocagen. The following for-profit companies have supported clinical trials and contracted research conducted by MP with payments made to his institution: Böhringer-Ingelheim, Bristol-Myers Squibb, Roche, Daiichi Sankyo, Merck Sharp & Dome, Novocure, GlaxoSmithKline, AbbVie.

## Funding Information

This work was supported by the Everest Centre for Low-grade Paediatric Brain Tumours (The Brain Tumour Charity, UK), the Paediatric Low-Grade Astrocytoma Fund (PLGA Fund) at the Paediatric Brain Tumour Foundation (PBTF), the German Cancer Consortium (DKTK), and fellowships from the Mildred-Scheel doctoral program of the German Cancer Aid and the German National Academic Foundation to M.Y.D (grant number 70112667), the Else Kröner Excellence Program of the Else Kröner-Fresenius Stiftung (EKFS) to F.S., the Stichting Kinderen Kankervrij (KIKa) to E.A. The study was in part supported by grants from the Friedeberg Charitable Foundation and the Sohn Conference Foundation (M.S.).

## References

- 1 Louis DN; International Agency for Research on C, Wiestler OD. WHO *Classification of tumours of the central*

- nervous system: international agency for research on cancer; 2016
- 2 Louis DN, Ohgaki H, Wiestler OD, Cavenee WK, Burger PC, Jouvet A, *et al.* The 2007 WHO classification of tumours of the central nervous system. *Acta Neuropathol.* 2007; **114**: 97–109
  - 3 Capper D, Jones DTW, Sill M, Hovestadt V, Schrimpf D, Sturm D, *et al.* DNA methylation-based classification of central nervous system tumours. *Nature* 2018; **555**: 469–74
  - 4 Capper D, Stichel D, Sahm F, Jones DTW, Schrimpf D, Sill M, *et al.* Practical implementation of DNA methylation and copy-number-based CNS tumor diagnostics: the Heidelberg experience. *Acta Neuropathol.* 2018; **136**: 181–210
  - 5 Deng MY, Sill M, Chiang J, Schittenhelm J, Ebinger M, Schuhmann MU, *et al.* Molecularly defined diffuse leptomeningeal glioneuronal tumor (DLGNT) comprises two subgroups with distinct clinical and genetic features. *Acta Neuropathol.* 2018; **136**: 239–53
  - 6 Hovestadt V, Jones DT, Picelli S, Wang W, Kool M, Northcott PA, *et al.* Decoding the regulatory landscape of medulloblastoma using DNA methylation sequencing. *Nature* 2014; **510**: 537–41
  - 7 Pajtler KW, Witt H, Sill M, Jones DT, Hovestadt V, Krauchwil F, *et al.* Molecular classification of ependymal tumors across all CNS compartments, histopathological grades, and age groups. *Cancer Cell* 2015; **27**: 728–43
  - 8 Sahm F, Schrimpf D, Stichel D, Jones DTW, Hielscher T, Scheffzyk S, *et al.* DNA methylation-based classification and grading system for meningioma: a multicentre, retrospective analysis. *Lancet Oncol.* 2017; **18**: 682–94
  - 9 Sturm D, Orr BA, Toprak UH, Hovestadt V, Jones DTW, Capper D, *et al.* New brain tumor entities emerge from molecular classification of CNS-PNETs. *Cell* 2016; **164**: 1060–72
  - 10 Sturm D, Witt H, Hovestadt V, Khuong-Quang DA, Jones DT, Konermann C, *et al.* Hotspot mutations in H3F3A and IDH1 define distinct epigenetic and biological subgroups of glioblastoma. *Cancer Cell* 2012; **22**: 425–37
  - 11 Taylor MD, Northcott PA, Korshunov A, Remke M, Cho YJ, Clifford SC, *et al.* Molecular subgroups of medulloblastoma: the current consensus. *Acta Neuropathol.* 2012; **123**: 465–72
  - 12 Hou Y, Pinheiro J, Sahm F, Reuss DE, Schrimpf D, Stichel D, *et al.* Papillary glioneuronal tumor (PGNT) exhibits a characteristic methylation profile and fusions involving PRKCA. *Acta Neuropathol.* 2019; **137**: 837–46
  - 13 Wesseling P, Capper DWHO. Classification of gliomas. *Neuropathol Appl Neurobiol.* 2016; **2018**: 139–50
  - 14 Stichel D, Schrimpf D, Casalini B, Meyer J, Wefers AK, Sievers P, *et al.* Routine RNA sequencing of formalin-fixed paraffin-embedded specimens in neuropathology diagnostics identifies diagnostically and therapeutically relevant gene fusions. *Acta Neuropathol.* 2019; **138**: 827–35
  - 15 Sahm F, Schrimpf D, Jones DT, Meyer J, Kratz A, Reuss D, *et al.* Next-generation sequencing in routine brain tumor diagnostics enables an integrated diagnosis and identifies actionable targets. *Acta Neuropathol.* 2016; **131**: 903–10
  - 16 van der Maaten L, Hinton G. Visualizing data using t-SNE. *J Mach Learn Res.* 2008; **9**: 2579–605
  - 17 Perry A. Histological classification of gliomas. In *Handbook of Clinical Neurology.* Eds MSW Berger. Vol. **134** (3rd series). Elsevier B.V., 2016.
  - 18 Jones DT, Kocialkowski S, Liu L, Pearson DM, Backlund LM, Ichimura K, *et al.* Tandem duplication producing a novel oncogenic BRAF fusion gene defines the majority of pilocytic astrocytomas. *Cancer Res* 2008; **68**: 8673–7.
  - 19 Pfister S, Janzarik WG, Remke M, Ernst A, Werft W, Becker N, *et al.* BRAF gene duplication constitutes a mechanism of MAPK pathway activation in low-grade astrocytomas. *J Clin Invest* 2008; **118**: 1739–49
  - 20 Rodriguez FJ, Schniederjan MJ, Nicolaides T, Tihan T, Burger PC, Perry A. High rate of concurrent BRAF-KIAA1549 gene fusion and 1p deletion in disseminated oligodendroglioma-like leptomeningeal neoplasms (DOLN). *Acta Neuropathol* 2015; **129**: 609–10

## Supporting information

Additional Supporting Information may be found in the online version of this article at the publisher's web-site:

**Figure S1.** Histological features in diffuse glioneuronal tumour with oligodendroglioma-like features and nuclear clusters (DGONC).

**Figure S2.** (a) t-SNE analysis using variance weighted 1-Pearson correlation distance (perplexity = 10), comprising all cases representing the reference entities, as presented in Capper, Jones, Sill, Hovestadt *et al.* *Nature* 2018 (<https://media.nature.com/original/nature-assets/nature/journal/v555/n7697/extref/nature26000-s3.xlsx>) and Deng *et al.* *Acta Neuropathologica* 2018 .

**Figure S3.** Summary of copy number profiles representing all cases of the DNA methylation reference group, respectively, as shown in Figure 1.

**Table S1.** Clinical data, histological and molecular findings.

Received 1 August 2019

Accepted after revision 7 November 2019

Published online Article Accepted on 23 December 2019