



HAL
open science

CDKN2A homozygous deletion is a strong adverse prognosis factor in diffuse malignant IDH-mutant gliomas

Romain Appay, Caroline Dehais, Claude-Alain Maurage, Agusti Alentorn, Catherine Carpentier, Carole Colin, François Ducray, Fabienne Escande, Ahmed Idbaih, Aurélie Kamoun, et al.

► **To cite this version:**

Romain Appay, Caroline Dehais, Claude-Alain Maurage, Agusti Alentorn, Catherine Carpentier, et al.. CDKN2A homozygous deletion is a strong adverse prognosis factor in diffuse malignant IDH-mutant gliomas. *Neuro-Oncology*, 2019, 21 (12), pp.1519-1528. 10.1093/neuonc/noz124 . hal-02441014

HAL Id: hal-02441014

<https://hal.science/hal-02441014v1>

Submitted on 3 Jul 2024

HAL is a multi-disciplinary open access archive for the deposit and dissemination of scientific research documents, whether they are published or not. The documents may come from teaching and research institutions in France or abroad, or from public or private research centers.

L'archive ouverte pluridisciplinaire **HAL**, est destinée au dépôt et à la diffusion de documents scientifiques de niveau recherche, publiés ou non, émanant des établissements d'enseignement et de recherche français ou étrangers, des laboratoires publics ou privés.

CDKN2A homozygous deletion is a strong adverse prognosis factor in diffuse malignant *IDH*-mutant gliomas

Romain Appay, Caroline Dehais, Claude-Alain Maurage, Agusti Alentorn, Catherine Carpentier, Carole Colin, François Ducray, Fabienne Escande, Ahmed Idbaih, Aurélie Kamoun, Yannick Marie, Karima Mokhtari, Emeline Tabouret, Nesrine Trabelsi, Emmanuelle Uro-Coste, Jean-Yves Delattre, and Dominique Figarella-Branger; and the POLA Network

Department of Pathological Anatomy and Neuropathology, Timone Hospital, Public Assistance–Marseille Hospitals (APHM), Marseille, France (R.A., D.F.B.); Aix-Marseille University, Scientific Research National Center (CNRS), Institute of Neurophysiopathology, Marseille, France (R.A., C.C., E.T., D.F.B.); Department of Neurology 2–Mazarin, Public Assistance–Paris Hospitals (APHP), University Hospital Pitié Salpêtrière–Charles Foix, Paris, France (C.D., A.A., A.I., J.-Y.D.); Department of Pathology, Lille University Hospital, Lille, France (C.-A.M., F.E.); Sorbonne University, National Institute of Health and Medical Research (Inserm), CNRS, Brain and Spinal Cord Institute, University Hospitals of Pitié Salpêtrière–Charles Foix, Department of Neurology 2–Mazarin, Paris, France (C.C., A.I., Y.M., K.M., N.T., J.-Y.D.); Department of Neuro-Oncology, Civil Hospices of Lyon, Pierre Wertheimer Hospital, Bron, France (F.D.); Department of Cancer Cell Plasticity, Cancer Research Center of Lyon, Lyon, France (F.D.); Tumor Identity Card Program, National League Against Cancer, Paris, France (A.K.); Department of Neurology, Raymond Escourrolle Neuropathology Service, University Hospitals of Pitié Salpêtrière–Charles Foix, APHP, Paris, France (K.M.); Department of Neuro-Oncology, Timone Hospital, APHM, Marseille, France (E.T.); Department of Pathological Anatomy and Histology-Cytology, Rangueil Hospital, Toulouse, France (E.U.-C.); Center for Research in Cancerology, Inserm U1037, University of Toulouse, Toulouse, France (E.U.-C.)

Corresponding Author: D. Figarella-Branger, Aix-Marseille Univ, CNRS, INP, Inst Neurophysiopathol, Faculté de Médecine, 13385 Marseille, France (dominique.figarella-branger@univ-amu.fr).

Abstract

Background. The 2016 World Health Organization (WHO) classification of central nervous system tumors stratifies isocitrate dehydrogenase (*IDH*)-mutant gliomas into 2 major groups depending on the presence or absence of 1p/19q codeletion. However, the grading system remains unchanged and it is now controversial whether it can be still applied to this updated molecular classification.

Methods. In a large cohort of 911 high-grade *IDH*-mutant gliomas from the French national POLA network (including 428 *IDH*-mutant gliomas without 1p/19q codeletion and 483 anaplastic oligodendrogliomas, *IDH*-mutant and 1p/19q codeleted), we investigated the prognostic value of the cyclin-dependent kinase inhibitor 2A (*CDKN2A*) gene homozygous deletion as well as WHO grading criteria (mitoses, microvascular proliferation, and necrosis). In addition, we searched for other retinoblastoma pathway gene alterations (*CDK4* amplification and *RB1* homozygous deletion) in a subset of patients. *CDKN2A* homozygous deletion was also searched in an independent series of 40 grade II *IDH*-mutant gliomas.

Results. *CDKN2A* homozygous deletion was associated with dismal outcome among *IDH*-mutant gliomas lacking 1p/19q codeletion ($P < 0.0001$ for progression-free survival and $P = 0.004$ for overall survival) as well as among anaplastic oligodendrogliomas, *IDH*-mutant + 1p/19q codeleted ($P = 0.002$ for progression-free survival and $P < 0.0001$ for overall survival) in univariate and multivariate analysis including age, extent of surgery, adjuvant treatment, microvascular proliferation, and necrosis. In both groups, the presence of microvascular proliferation and/or necrosis remained of prognostic value only in cases lacking *CDKN2A* homozygous deletion. *CDKN2A* homozygous deletion was not recorded in grade II gliomas.

Conclusions. Our study pointed out the utmost relevance of *CDKN2A* homozygous deletion as an adverse prognostic factor in the 2 broad categories of *IDH*-mutant gliomas stratified on 1p/19q codeletion and suggests that the grading of these tumors should be refined.

Key Points

1. *CDKN2A* homozygous deletion characterizes diffuse malignant *IDH*-mutant gliomas with worst outcome.
2. Microvascular proliferation stratifies *IDH*-mutant gliomas lacking *CDKN2A* homozygous deletion.

Importance of the Study

The 2016 WHO classification of central nervous system tumors stratifies *IDH*-mutant gliomas in 2 major groups of distinct prognosis depending on the presence of 1p/19q codeletion. However, it remains controversial whether WHO histopathological grading remains significant in these groups. Here we showed in a large cohort of 428 malignant *IDH*-mutant gliomas lacking 1p/19q codeletion that *CDKN2A* homozygous deletion was a strong adverse prognosis factor. The same results were

recorded in 483 anaplastic oligodendrogliomas, *IDH*-mutant + 1p/19q codeleted. Moreover, in each group microvascular proliferation (associated or not with necrosis) was of prognostic relevance among tumors lacking *CDKN2A* homozygous deletion. Of importance, *CDKN2A* homozygous deletion was not recorded in an independent series of 40 grade II *IDH*-mutant gliomas. These results are of interest for a future grading approach of *IDH*-mutant gliomas.

Diffuse gliomas are the most frequent and aggressive primary brain tumors in adults. They are stratified according to the 2016 World Health Organization (WHO) classification of central nervous system tumors¹ into 3 major groups depending on the presence or absence of 2 genetic alterations: isocitrate dehydrogenase (*IDH*) mutation and 1p/19q codeletion. Among malignant diffuse gliomas in adults, the worst prognosis is recorded in glioblastoma (GB) *IDH* wild type (grade IV), the best in anaplastic oligodendroglioma (AO) *IDH* mutant + 1p/19q codeleted (grade III), whereas the last group of malignant glioma, *IDH* mutant without 1p/19q codeletion (which comprises anaplastic astrocytoma [AA], *IDH* mutant grade III; and GB, *IDH* mutant grade IV), carries an intermediate prognosis.

Besides, although *IDH* gene status has been the major criterion for the classification of adult diffuse gliomas, no change has been made in the 2016 WHO classification regarding the grading system based on histologic criteria and it is now unclear, whereas it can still be applied. Indeed, some recent studies have highlighted that grades II and III *IDH*-mutant astrocytic tumors share the same prognosis,²⁻⁶ whereas other authors still report a prognostic significance of the grade.⁷

Cyclin-dependent kinase inhibitor 2A (*CDKN2A*) is a gene located at chromosome 9, band p21.3. In the "pre-*IDH* era," some studies had reported a prognostic value of *CDKN2A* genetic alteration in different glioma subtypes, including grades II and III astrocytoma.^{8,9} Recent studies identified homozygous deletions involving *CDKN2A/B* as a statistically significant marker of poor prognosis in *IDH*-mutant astrocytic gliomas,^{7,10} whereas other authors reported the prognostic relevance of combined altered retinoblastoma

pathway gene alterations, including *CDKN2A/B*, *CDK4*, and *RB1*.¹¹⁻¹³ As a consequence, among *IDH*-mutant astrocytic tumors (ie, lacking 1p/19q codeletion) the actual 2016 WHO grading classification based solely on histologic criteria does not seem fully appropriate, and some authors^{7,11} have suggested including additional genetic markers such as copy number variation or *CDKN2A/B* status. Regarding AO *IDH* mutant + 1p/19q codeleted, we reported a few years ago that allelic loss of 9p21.3, including *CDKN2A*, was an adverse prognostic factor; however, we did not investigate the prognostic value of the specific *CDKN2A* locus homozygous deletion.¹⁴

In France, since 2008, a dedicated program has been set up to homogenize the management of de novo adult high-grade glioma with an oligodendroglial component (the POLA [Prise en charge des Oligodendrogliomes Anaplasiques/Management of Anaplastic Oligodendrogliomas] network). One of the aims of the program was to provide a pathological centralized review of glioma cases with an oligodendroglial component and histologic features of malignancy (including the presence of microvascular proliferation [MVP] or necrosis and, in cases lacking these criteria, a mitotic activity superior to 1 per 10 high-power field [HPF] for oligoastrocytomas and superior to 6 per 10 HPF for oligodendrogliomas). In the present study we took advantage of the large series of patients included in the POLA network to investigate the prognostic relevance of *CDKN2A* homozygous deletion as well as the prognostic value of the WHO 2016 grading system based on histologic criteria (MVP and necrosis) in 911 high-grade *IDH*-mutant gliomas, including 428 *IDH*-mutant high-grade astrocytic tumors (212 AA *IDH* mutant and 216 GB *IDH*

mutant) and 483 AO *IDH* mutant + 1p/19q codeleted. In addition, we searched for other retinoblastoma pathway gene alterations (*CDK4* amplification and *RB1* homozygous deletion) in a subset of patients. Because the POLA series lack grade II gliomas, we also searched for the occurrence of *CDKN2A* homozygous deletion in an independent series of 40 grade II *IDH*-mutant gliomas (20 diffuse astrocytomas *IDH* mutant and 20 oligodendrogliomas *IDH* mutant + 1p/19q codeleted).

Materials and Methods

Study Population

A total number of 911 patients from the French nationwide POLA network were included in this study. Inclusion criteria were: (i) the written consent of the patient for clinical data collection and genetic analysis according to national and POLA network policies, (ii) sufficient material for molecular studies allowing concordance with the WHO 2016 classification (ie, evaluation of *IDH* mutation + 1p/19q codeletion status), and (iii) an established diagnosis of high-grade glioma (WHO grade III or IV) with *IDH* mutation. This study was approved by the ethics committees or institutional review boards of all participating institutes.

Pathological Review

All cases were centrally reviewed by Prof D. Figarella-Branger (or Dr K. Mokhtari for the patients managed in the city of Marseille). Evaluated in all cases were the mitotic index (defined as the number of mitotic figures per 10 HPF), the Ki67 labeling index (defined as the number of immunostained nuclei with Ki67 antibody [clone Mib1, 1/100, Dako] in 400 cells in the most positive area), and the presence or absence of MVP and necrosis (either palisading or not). The mitotic activity threshold that should be used to distinguish WHO grade II diffuse astrocytoma from WHO grade III anaplastic astrocytoma is not provided by the WHO classification. In this study, we used the number of mitotic figures per 10 HPF superior to 1 as the threshold for the diagnosis of AA *IDH* mutant. Similarly, in the absence of MVP and necrosis we retained a diagnosis of AO *IDH* mutant + 1p/19q codeleted when the number of mitotic figures per 10 HPF was superior to 6.

IDH mutation status was assessed by immunohistochemistry with anti-*IDH1* R132H antibody (clone H09, 1/75, Dianova) and in almost all cases (901/911) by direct sequencing using the Sanger method and primers as previously described.¹⁵ The genomic profile and assessment of 1p/19q codeletion status was determined based on single nucleotide polymorphism (SNP) arrays, comparative genomic hybridization (CGH) arrays, or microsatellite marker analysis as previously described.¹⁵

Evaluation of Retinoblastoma Pathway Gene Alterations

CDKN2A homozygous deletion status was retrieved from POLA electronic case report forms. *CDKN2A* homozygous

deletion was evaluated by SNP arrays ($n = 552$) when DNA extracted from frozen tissue was available. Outsourced for the SNP array experiments (Integrigen) was 1.5 μ g of DNA. Two types of platforms were used: HumanCNV370-Quad and Human610-Quad from Illumina. When only DNA extracted from formalin-fixed paraffin embedded tissue was available, *CDKN2A* homozygous deletion was assessed using oligonucleotide-based CGH arrays (Agilent, $n = 111$) or next generation sequencing (NGS) (BrainCap Custom Capture from Roche, $n = 227$). Depending on the technology used, *CDKN2A* homozygous deletion was evaluated by visual assessment of copy number profiles for SNP array and CGH array analysis or visual examination of the depth of *CDKN2A* sequencing coverage compared with adjacent regions for NGS analysis. When the quantity of DNA was insufficient to perform SNP or CGH arrays ($n = 4$), the genomic profile was assessed by PCR-based loss-of-heterozygosity assays as described elsewhere.¹⁶

Additionally, we retrieved available SNP array data regarding *RB1* homozygous deletion and *CDK4* amplification status from 436 cases, including 189 *IDH*-mutant gliomas lacking 1p/19q codeletion and 247 AO *IDH* mutant + 1p/19q codeleted. As described previously, these alterations were evaluated by visual assessment of copy number profiles.

Clinical Characteristics

Clinical data collected included sex, age at diagnosis, extent of surgery (biopsy or resection), date of surgery, adjuvant treatment, date of relapse, and date of death or last contact. Progression-free survival (PFS) was defined as the time from the date of surgery to recurrence or death from any cause, censored at the date of the last documented disease evaluation. Overall survival (OS) was defined as the time from the date of surgery to death from any cause, censored at the date of last contact.

Additional Independent Cohort of Grade II IDH-Mutant Gliomas

We retrieved copy number variation analysis profiles for an additional independent cohort of 40 patients with grade II *IDH*-mutant gliomas, including 20 diffuse astrocytomas *IDH* mutant and 20 oligodendrogliomas *IDH*-mutant + 1p/19q codeleted. *IDH* mutation status of all these cases was assessed by both immunohistochemistry and Sanger sequencing, and the genomic profile was assessed using oligonucleotide-based CGH arrays as previously described. Follow-up data were not recorded for this series because these were cases of recent diagnosis.

Statistical Analysis

For statistical analysis, continuous variables were compared using the Mann-Whitney *U*-test. The Kaplan-Meier method was used to estimate survival distributions. Log rank tests were used for univariate comparisons. Cox proportional hazards models were used for multivariate analyses. Multivariate analysis included *CDKN2A* homozygous deletion and clinical or pathological characteristics with a *P*-value <0.05 in univariate analyses (ie, age at

diagnosis, extent of surgery, adjuvant treatment, and the presence of MVP and/or necrosis considered as composite criteria, which correspond to WHO grades III versus IV among the *IDH*-mutant gliomas lacking 1p/19q codeletion). All statistical tests were two-sided, and the threshold for statistical significance was $P = 0.05$. Statistical analysis was done using IBM SPSS statistics software v24. In addition, to explore how covariables can predict outcome, we used a machine learning algorithm based on the random survival forest method¹⁷ ("randomForestSRC" and "ggRandomForests" packages, R-project v3.3.3, <https://www.r-project.org>). It allows the determination of the variable importance as predictor of outcome (ie, corresponding to the delta error rate with vs without the inclusion of the variable in the model). We included *CDKN2A* deletion, 1p/19q codeletion status, MVP, and the presence of necrosis in the random forest survival using 1000 tree iteration to predict PFS and OS.

Results

Clinical and Pathological Features Among the WHO 2016 Subgroups

Patient characteristics are presented in Table 1. Nine hundred eleven patients with a diagnosis of *IDH*-mutant glioma were included in this study, 428 cases fulfilled the diagnosis of *IDH*-mutant malignant glioma without 1p/19q codeletion (212 AA *IDH* mutant and 216 GB *IDH* mutant) and 483 cases fulfilled the diagnosis of AO *IDH* mutant + 1p/19q codeleted.

Among patients with *IDH*-mutant malignant gliomas without 1p/19q codeletion, the median age at diagnosis was 39.5 years (range, 17.1–83.1 y). They were 239 men and 189 women. Seventy-seven percent benefited from surgical resection and half received adjuvant concomitant radiotherapy combined with temozolomide. The median follow-up was 35 months (range, 0–109 mo). During this follow-up period, 196 patients relapsed and 110 died. Among the clinical variables analyzed, age (≤ 39.5 y), surgical resection, and adjuvant treatment were predictive of a longer PFS (respectively $P = 0.004$, $P < 0.0001$, and $P < 0.0001$) and a longer OS (respectively $P = 0.001$, $P = 0.001$, and $P < 0.001$). In accordance with the 2016 WHO classification, among the 428 cases (AA and GB *IDH* mutant), the presence of MVP and/or necrosis (corresponding to GB *IDH* mutant) was associated with a shorter PFS ($P = 0.014$) and OS ($P < 0.001$). By definition AA *IDH* mutant displayed neither MVP nor necrosis. Among the 212 AA *IDH* mutant, we failed to identify a threshold for mitotic count or Ki67 labeling index that could be of prognostic significance (Supplementary Table 1). Among the 216 GB *IDH* mutant, necrosis, when present, was always associated with MVP, 143 cases demonstrated MVP without necrosis, whereas 73 displayed MVP and necrosis, and we did not observe a prognostic relevance of necrosis on PFS ($P = 0.277$) or OS ($P = 0.489$).

Regarding AO *IDH* mutant + 1p/19q codeleted, the median age at diagnosis was 49.5 years (range, 19.4–87.1 y). They were 286 men and 197 women. Eighty-two percent benefited from surgical resection and 37% received adjuvant

concomitant radiotherapy combined with temozolomide. The median follow-up was 45 months (range, 0–114 mo). During this follow-up period, 163 patients relapsed and 66 died. Among the clinical variables analyzed, age (≤ 49.5 y), surgical resection, and adjuvant treatment were predictive of a longer PFS (respectively $P = 0.013$, $P < 0.0001$, and $P < 0.0001$) and OS (respectively $P < 0.0001$, $P = 0.001$, and $P = 0.036$). In accordance with the 2016 WHO classification, the presence of MVP and/or necrosis was not associated with survival. Of note, necrosis, when present, was always associated with MVP. Furthermore, among the 119 AO *IDH* mutant + 1p/19q codeleted without MVP and/or necrosis, we failed to identify a threshold for mitotic count or Ki67 labeling index that could be of prognostic significance (Supplementary Table 1).

Univariate analysis performed in the whole group of 911 patients showed that the 2016 WHO integrated diagnosis was of prognostic value ($P < 0.0001$ for both PFS and OS; Fig. 1A). In addition, the machine learning algorithm based on the random survival forest method revealed that 1p/19q codeletion was the most important variable to predict both PFS and OS, followed by *CDKN2A* homozygous deletion and MVP, whereas necrosis was the worst variable (Supplementary Fig. 1).

Prognostic Relevance of Retinoblastoma Pathway Genetic Alterations Among *IDH*-Mutant Gliomas without 1p/19q Codeletion

Among the 428 *IDH*-mutant gliomas without 1p/19q codeletion (AA and GB), the presence of *CDKN2A* homozygous deletion was associated with worse outcome for PFS ($P < 0.0001$) and for OS ($P = 0.004$) (Table 1). In multivariate analysis including age at diagnosis, extent of surgery (resection versus biopsy), adjuvant treatment (radiotherapy plus chemotherapy vs others), MVP and necrosis, *CDKN2A* homozygous deletion was also predictive of shorter PFS ($P < 0.001$; hazard ratio [HR], 2.121; 95% CI = 1.399–3.216) and shorter OS ($P = 0.046$; HR, 1.722; 95% CI = 1.011–2.935) (Table 2).

Besides, the WHO 2016 grading system (ie, presence of MVP and/or necrosis) was still relevant for PFS ($P = 0.04$) and for OS ($P = 0.002$) among tumors lacking *CDKN2A* homozygous deletion ($n = 354$), whereas it lost its prognostic relevance among tumors with *CDKN2A* homozygous deletion ($n = 47$) ($P = 0.790$ for PFS and $P = 0.683$ for OS) (Fig. 2A).

Among *IDH*-mutant gliomas without 1p/19q codeletion, the presence of neither *RB1* homozygous deletion nor *CDK4* amplification had prognostic value (Table 1).

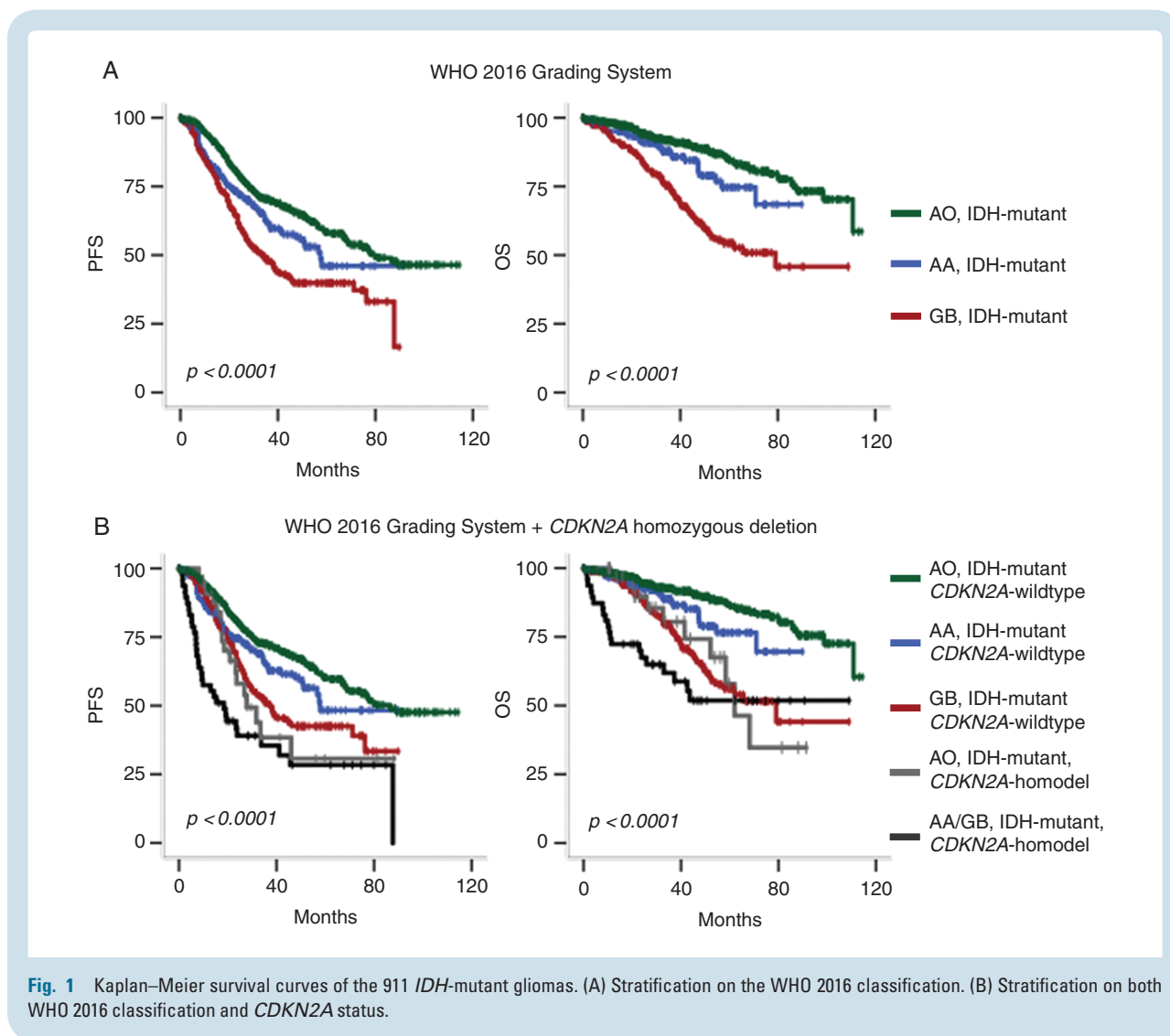
Prognostic Relevance of Retinoblastoma Pathway Genetic Alterations Among the AO *IDH* Mutant + 1p/19q Codeleted Subgroup

Among the 483 AO *IDH* mutant + 1p/19q codeleted subgroup, the presence of *CDKN2A* homozygous deletion was a strong adverse prognostic factor for PFS ($P = 0.002$) and OS ($P < 0.0001$) (Table 1). In multivariate analysis including age at diagnosis, extent of surgery, adjuvant treatment, and MVP and necrosis, *CDKN2A* homozygous deletion was

Table 1 Clinical, pathological, and molecular characteristics of the 911 IDH-mutant glioma cohort and their association with PFS and OS

Clinical, Pathological and Molecular Characteristics	IDH-Mutant Gliomas without 1p/19q Codeletion (All)			Anaplastic Astrocytoma IDH-Mutant			Glioblastoma IDH-Mutant			Anaplastic Oligodendroglioma IDH-Mutant + 1p/19q Codeleted		
	N (%)	PFS	OS	N (%)	PFS	OS	N (%)	PFS	OS	N (%)	PFS	OS
Total	428			212			216			483		
Median age (range)	39.5 (17.1–83.1)	0.004	0.001	39.2 (17.1–83.1)	0.014	0.002	40.2 (17.6–77)	0.064	0.042	49.5 (19.4–87.1)	0.013	<0.0001
Sex												
Female	189 (44)	0.423	0.806	101 (48)	0.760	0.349	88 (41)	0.147	0.492	197 (41)	0.06	0.541
Male	239 (56)			111 (52)			128 (59)			286 (59)		
Extent of surgery												
Resection	313 (73)			143 (67)			170 (79)			375 (78)		
Biopsy	92 (21)	<0.0001	0.001	56 (26)	0.062	0.023	36 (17)	<0.0001	<0.0001	81 (17)	<0.0001	0.001
Unknown	23 (5)			13 (6)			10 (5)			27 (6)		
Adjuvant treatment												
None	42 (10)	<0.0001	<0.0001	24 (11)	<0.0001	<0.0001	18 (8)	<0.0001	0.018	40 (8)	<0.0001	0.036
RT alone	20 (5)			7 (3)			13 (6)			93 (19)		
CT alone	52 (12)			32 (15)			20 (10)			89 (19)		
RT + PCV	96 (23)			69 (33)			27 (12)			83 (17)		
RT + TMZ	218 (50)			80 (38)			138 (64)			178 (37)		
Pathological features												
Microvascular proliferation	216 (50)	0.014	<0.0001	0	NA	NA	216 (100)	NA	NA	364 (75)	0.122	0.096
Necrosis	73 (17)	0.032	0.02	0	NA	NA	73 (34)	0.277	0.489	111 (23)	0.08	0.438
Genetic alterations												
CDKN2A homozygous deletion	47 (11)	<0.0001	0.004	12 (6)	0.03	0.06	35 (16)	0.003	0.08	33 (7)	0.002	<0.0001
CDK4 amplification	6 (3.2)	0.433	0.610	0	NA	NA	6 (4.7)	0.350	0.882	1 (0.4)	0.418	0.632
Fb1 homozygous deletion	9 (4.8)	0.696	0.756	5 (8.1)	0.353	0.964	4 (3.1)	0.014	0.378	0	NA	NA

Abbreviations: RT, radiotherapy; CT, chemotherapy; PCV, procarbazine + lomustine + vincristine; TMZ, temozolomide.



also predictive of shorter PFS ($P = 0.048$; HR, 1.750; 95% CI = 1.004–3.049) and shorter OS ($P = 0.026$; HR, 2.539; 95% CI = 1.121–5.750) (Table 2).

Besides, among tumors lacking *CDKN2A* homozygous deletion ($n = 450$) the presence of MVP and/or necrosis was relevant for OS ($P = 0.028$), although not statistically significant for PFS ($P = 0.085$) (Fig. 2B). On the other hand, among tumors with *CDKN2A* homozygous deletion ($n = 33$), the presence of MVP and/or necrosis was relevant for neither PFS ($P = 0.739$) nor OS ($P = 0.114$) (Fig. 2B).

Among AO *IDH* mutant + 1p/19q codeleted, the presence of neither *RB1* homozygous deletion nor *CDK4* amplification had prognostic value (Table 1).

Correlation Between *CDKN2A* Homozygous Deletion, Mitotic Index, and Ki67 Labeling Index

Among the 911 *IDH*-mutant gliomas, the presence of *CDKN2A* homozygous deletion was associated with higher mitotic count (median = 7 per 10 HPF, range 2–40, $P < 0.0001$) and higher Ki67 labeling index (median = 20%, range 2–70, $P < 0.0001$) compared with gliomas without

CDKN2A alteration (median mitotic count = 6 per 10 HPF, range 1–50, and median Ki67 labeling index = 15%, range 1–90) (Supplementary Fig. 2).

CDKN2A Homozygous Deletion Prevalence Among Grade II *IDH*-Mutant Gliomas

We did not observe any *CDKN2A* homozygous deletion among the 40 grade II *IDH*-mutant gliomas of our additional series including 20 diffuse astrocytoma *IDH* mutant and 20 oligodendrogliomas *IDH* mutant + 1p/19q codeleted (Supplementary Table 2).

Discussion

In the present study, we investigated the prognostic value of *CDKN2A* homozygous deletion as well as current histopathological criteria (mitosis, MPV and necrosis) in a large cohort of 911 high-grade *IDH*-mutant gliomas (428 *IDH*-mutant gliomas without 1p/19q codeletion and 483 AO *IDH*

Table 2 Multivariate Cox regression analysis

Clinical, Pathological, or Molecular Characteristics	IDH-Mutant Gliomas without 1p/19q Codeletion (N = 428)						Anaplastic Oligodendroglioma /IDH Mutant + 1p/19q Codeleted (N = 483)					
	PFS			OS			PFS			OS		
	P-value	HR	95% CI	P-value	HR	95% CI	P-value	HR	95% CI	P-value	HR	95% CI
Age (>median)	0.042	1.405	1.013–1.949	0.023	1.643	1.072–2.518	0.062	1.412	0.982–2.031	0.001	4.025	1.801–8.992
Surgical resection	0.014	0.616	0.419–0.905	0.002	0.457	0.277–0.753	0.025	0.634	0.426–0.946	0.089	0.580	0.310–1.088
Adjuvant treatment	<0.0001	0.328	0.230–0.468	<0.0001	0.293	0.188–0.456	0.065	0.731	0.524–0.1020	0.937	0.978	0.563–1.699
MVP and/or necrosis	<0.0001	1.855	1.311–2.625	<0.0001	2.936	1.792–4.810	0.052	1.570	0.995–2.475	0.241	1.614	0.725–3.593
CDKN2A homozygous deletion	0.001	2.084	1.374–3.162	0.049	1.707	1.001–2.911	0.020	1.909	1.106–3.294	0.015	2.673	1.209–5.908

mutant + 1p/19q codeleted) from the French national POLA network. In addition, we searched for other retinoblastoma pathway gene alterations (*CDK4* amplification and *RB1* homozygous deletion) in a subset of patients. We also searched for *CDKN2A* homozygous deletion in an independent cohort of 40 grade II *IDH*-mutant gliomas (20 diffuse astrocytomas *IDH* mutant and 20 oligodendroglioma *IDH* mutant + 1p/19q codeleted).

Our results point out the utmost prognostic relevance of *CDKN2A* homozygous deletion in the 2 categories of diffuse malignant *IDH*-mutant gliomas stratified on 1p/19q codeletion. Moreover, *CDKN2A* homozygous deletion appears as the first stratification risk, before the assessment of MVP and/or necrosis. Among them, MVP seems to be the most appropriate, since in our study it is of greater prognostic significance compared with necrosis. This last result is discrepant from a previous study⁷ that showed a greater prognostic relevance of necrosis compared with MVP and used this criterion (depending on the model, in addition or not to the copy number variable load value) to stratify *IDH*-mutant astrocytoma without *CDKN2A/B* alteration.

A limitation of our study design might be the potential effect on survival of the treatment, since the therapeutic recommendations evolved with the recommendations of the European Organisation for Research and Treatment of Cancer (EORTC)¹⁸ and the Radiation Therapy Oncology Group.¹⁹ Thus, we cannot exclude that the heterogeneity of the treatment within each histomolecular category might influence survival. Nonetheless, *CDKN2A* homozygous deletion remained of prognostic significance in multivariate analysis including treatment, therefore supporting its independent prognostic value.

The *CDKN2A* locus on chromosome band 9p21 encodes for 2 tumor suppressors, protein p14^{ARF} and p16^{INK4A}, both inhibiting cell cycle progression. P14^{ARF} activates the well-known “guardian of the genome,” p53, which plays an important role in growth arrest, DNA repair, and apoptosis.^{20–22} P16^{INK4A} inhibits *CDK4* and *CDK6*, which activate the retinoblastoma family of proteins and block G1 to S phase transition. In accordance with these functions, homozygous deletion of the *CDKN2A* locus alters its inhibitory function and might contribute to uncontrolled tumor cell proliferation. Not surprisingly, therefore, in our cohort of 911 high-grade *IDH*-mutant gliomas, we observed a strong correlation between *CDKN2A* homozygous deletion, mitotic count ($P < 0.001$), and Ki67 labeling index ($P < 0.001$). Previous studies reported the prognosis value of other retinoblastoma pathway alterations, including *RB1* homozygous deletion^{7,13} and *CDK4* amplification,^{11–13} but we did not observe a prognostic significance of these alterations in our study.

The major prognostic impact of *CDKN2A* homozygous deletion in malignant diffuse *IDH*-mutant gliomas might have strong implication in daily practice, since it will require the search for this genetic alteration in all malignant diffuse *IDH*-mutant gliomas. Whether this alteration should also be investigated in grade II remains to be resolved. We learned from our study that this alteration was not recorded in grade II *IDH*-mutant gliomas. The same results were also reported previously in a series of 54 grade II *IDH*-mutant gliomas lacking 1p/19q codeletion.⁷ However, other

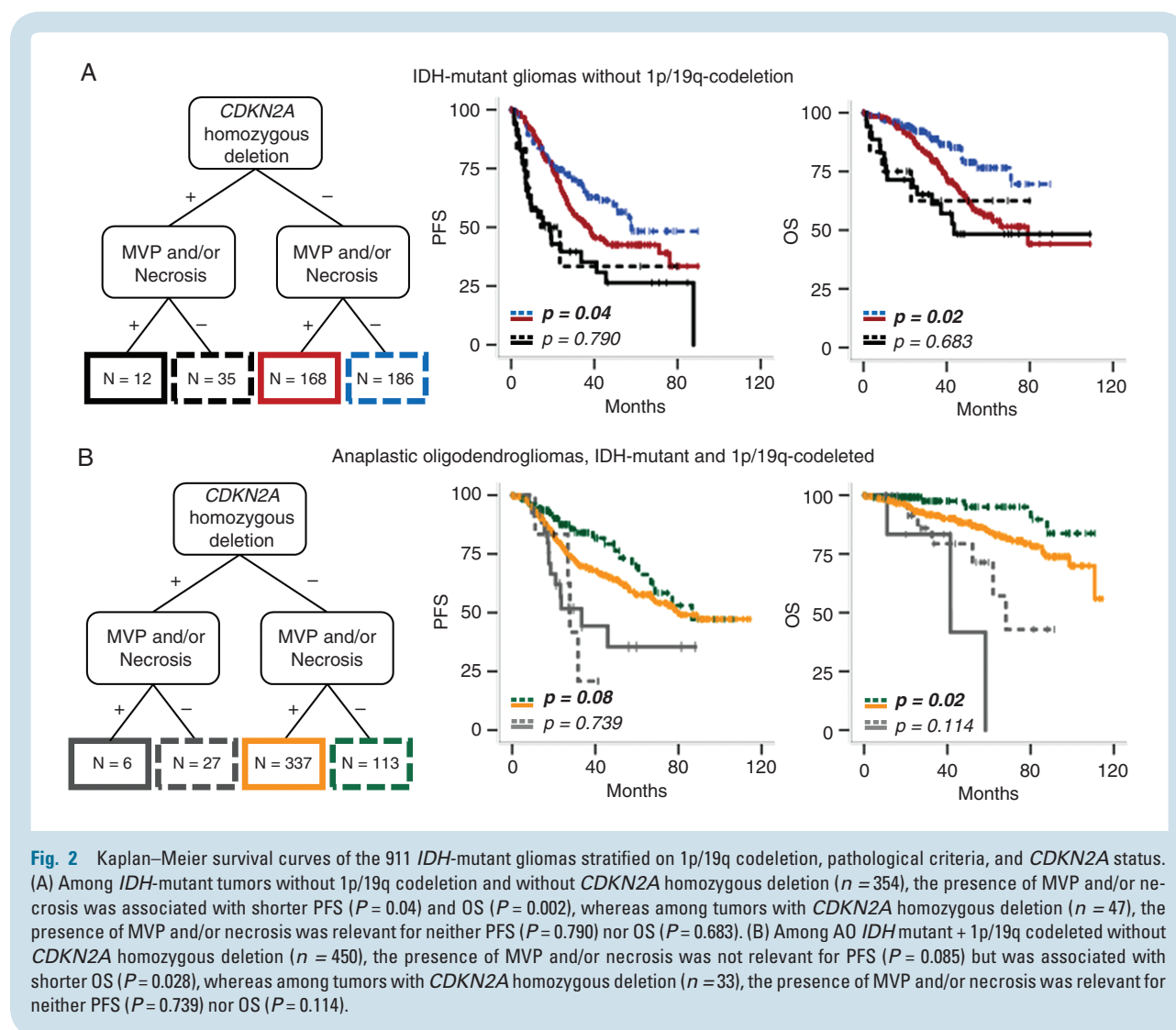


Fig. 2 Kaplan–Meier survival curves of the 911 *IDH*-mutant gliomas stratified on 1p/19q codeletion, pathological criteria, and *CDKN2A* status. (A) Among *IDH*-mutant tumors without 1p/19q codeletion and without *CDKN2A* homozygous deletion ($n = 354$), the presence of MVP and/or necrosis was associated with shorter PFS ($P = 0.04$) and OS ($P = 0.002$), whereas among tumors with *CDKN2A* homozygous deletion ($n = 47$), the presence of MVP and/or necrosis was relevant for neither PFS ($P = 0.790$) nor OS ($P = 0.683$). (B) Among AO *IDH* mutant + 1p/19q codeleted without *CDKN2A* homozygous deletion ($n = 450$), the presence of MVP and/or necrosis was not relevant for PFS ($P = 0.085$) but was associated with shorter OS ($P = 0.028$), whereas among tumors with *CDKN2A* homozygous deletion ($n = 33$), the presence of MVP and/or necrosis was relevant for neither PFS ($P = 0.739$) nor OS ($P = 0.114$).

authors observed *CDKN2A* loss in some cases of oligodendroglioma *IDH* mutant + 1p/19q codeleted.^{2,8}

The methods used for *CDKN2A* homozygous deletion assessment should be validated in each laboratory. Previous studies reported that p16 immunohistochemical detection cannot be considered as a surrogate technique to detect *CDKN2A* homozygous deletion.^{7,8,23} In our study, among the *IDH*-mutant gliomas without 1p/19q codeletion, the number of cases with *CDKN2A* homozygous deletion was similar regardless of the technique used for detection: 11% (28/257) with SNP array, 12% (7/57) with CGH array, and 12% (11/94) with NGS. Our results are comparable to the proportion of cases observed among the EORTC cohort (11%, 17/154) and the cohort from The Cancer Genome Atlas (14%, 31/224) reported by Shirahata et al,⁷ a little lower than their discovery cohort (18%, 38/211) and the Heidelberg cohort (23%, 25/108) and much lower than the cohort reported by Korshunov et al¹⁰ (43%, 42/97). We do not have a clear explanation for the low frequencies of retinoblastoma pathway gene alterations observed in our study in comparison with others but it is consistent with the longest OS of the GB *IDH*-mutant subgroup (median OS

in our study = 79 mo) compared with previously reported survival data among this histomolecular group^{7,10,12,24} (median OS ranging from 33 to 60 mo). Nevertheless, although the median OS was not reached among the *IDH*-mutant gliomas lacking 1p/19q codeletion with *CDKN2A* homozygous deletion, the Kaplan–Meier curve suggests a median OS of around 37 months, which is similar to the outcome reported in other studies.^{7,10}

Altogether, and as also suggested previously by other authors,^{7,11} our results suggest that the strong negative impact of *CDKN2A* homozygous deletion on survival in the subgroup of *IDH*-mutant astrocytomas should be included as a criterion in the grading scheme of these tumors (Fig. 1B). Therefore, a malignant *IDH*-mutant astrocytoma exhibiting *CDKN2A* homozygous deletion might be considered as grade IV and thus independently of the occurrence of MVP (or necrosis). Whether or not grade IV should be limited to *IDH*-mutant astrocytoma with *CDKN2A* homozygous deletion and thus a grade III be applied to malignant *IDH*-mutant astrocytomas that do not exhibit *CDKN2A* homozygous deletion despite the presence of MVP and/or necrosis is questionable. Regarding the group of *IDH*-mutant

astrocytomas without *CDKN2A* homozygous deletion or MVP (or necrosis), another major problem is the prognostic relevance of mitotic activity used to distinguish grade II from grade III. The mitotic activity threshold is not provided by the WHO classification and remains subjective depending on the size of the sample analyzed. Importantly, previous studies reported that mitotic activity was not relevant for outcome among *IDH*-mutant astrocytomas.^{3,25} In addition, in the present study we failed to find a threshold for either mitotic count or Ki67 labeling index that could be of prognostic significance among our cohort of AA *IDH* mutant. Whether a grade II should be considered for all *IDH*-mutant astrocytoma lacking *CDKN2A* homozygous deletion and MVP (or necrosis) represents another matter of debate.

Of major interest, our study points out that a similar approach might be applied to AO *IDH* mutant + 1p/19q codeleted. Indeed, these tumors also demonstrate a dismal prognosis when *CDKN2A* homozygous deletion is recorded. Of note, in our cohort the prognosis of AO *IDH* mutant + 1p/19q codeleted with *CDKN2A* homozygous deletion was close to or even worse than that of GB *IDH* mutant (Fig. 1B). Even though a grade IV in oligodendrogliomas has never been suggested before, this genetic alteration might be taken into account to stratify these patients. Regarding histologic criteria, recent studies reported a prognostic relevance of WHO grade,¹² whereas other authors reported that grades II and III oligodendrogliomas share the same prognosis.¹³ Our results suggest a stratification of AO without *CDKN2A* homozygous deletion or the presence of MVP and/or necrosis but (i) the observation period (<120 mo) may not be long enough and (ii) our cohort does not include grade II oligodendroglioma, avoiding prognostic comparison. Whether oligodendroglioma without *CDKN2A* homozygous deletion or MVP and necrosis shares a similar prognosis regardless of the number of mitoses remains to be confirmed by further investigations.

To conclude, in our study, performed on 911 malignant diffuse gliomas, *IDH* mutant included in the POLA cohort points out the utmost relevance of *CDKN2A* homozygous deletion as an adverse prognostic factor in 2 broad categories of patients stratified on 1p/19q codeletion as well as the prognostic relevance of MVP (associated or not with necrosis) among tumors lacking this alteration. Further studies, however, are required to confirm these findings, as well as the best technique to point out this genetic alteration. Nevertheless, we believe that these prognostic factors could be of great interest for a future grading approach of *IDH*-mutant gliomas.

Supplementary Material

Supplementary data are available at *Neuro-Oncology* online.

Keywords

anaplastic oligodendroglioma; *IDH*-mutant and 1p/19q codeleted; anaplastic astrocytoma, *IDH*-mutant;

glioblastoma, *IDH*-mutant; microvascular proliferation; *CDKN2A* homozygous deletion

Funding

This work is funded by the French Institut National du Cancer (INCa) and is part of the national program Cartes d'Identité des Tumeurs (CIT) (<http://cit.ligue-cancer.net/>), which is funded and developed by the Ligue Nationale Contre le Cancer.

Conflict of interest statement. The authors declare no conflict of interest.

Authorship statement. Data collection and pathological and molecular analysis: CD, CAM, KM, DFB, AK, YM, NT. Analysis and interpretation of the data: RA, CC, ET, DFB. All authors were involved in the writing of the manuscript and have read and approved the final version.

Acknowledgments

We thank the ARTC-Sud patients' association (Association pour le Recherche sur les Tumeurs Cérébrales), the Cancéropôle PACA and the SIRIC "CURAMUS" project. We would like to thank Raynier Devillier for the random forest variable importance analysis. Frozen specimens from the APHM institution were stored then provided by the APHM CRB-TBM tumor bank (authorization number AC-2018-31053, B-0033-00097). Frozen specimens from Bordeaux were stored in hôpital Haut Levêque CRB, 33604, Pessac, France. Frozen specimens from Montpellier were stored in CHU Montpellier, CCBH-M, 34825, Montpellier, France. Frozen specimens from Nantes were stored in IRCNA tumor bank, in CHU Nantes, Institut de Cancérologie de l'ouest, 44800 Saint-Herblain, France. Frozen specimens from Saint-Etienne were stored in CHU Saint-Etienne, CRB 42, 42055 Saint-Etienne, France. Frozen specimens from Lyon were stored in NeuroBioTec, Groupement Hospitalier Est, 69677 Bron cedex, France.

POLA Network

Amiens (C. Desenclos, H. Sevestre), Angers (P. Menei, A. Rousseau), Annecy (T. Cruel, S. Lopez), Besançon (M.-I. Mihai, A. Petit), Bicêtre (C. Adam, F. Parker), Brest (P. Dam-Hieu, I. Quintin-Roué), Bordeaux (S. Eimer, H. Loiseau), Caen (L. Bekaert, F. Chapon), Clamart (D. Ricard) Clermont-Ferrand (C. Godfraind, T. Khallil), Clichy (D. Cazals-Hatem, T. Faillot), Colmar (C. Gaultier, M. C. Tortel), Cornebarrieu (I. Carpiuc, P. Richard), Créteil (W. Lahiani), Dijon (H. Aubriot-Lorton, F. Ghiringhelli), Lille (C. A. Maurage, C. Ramirez), Limoges (E. M. Gueye, F. Labrousse),

Marseille (O. Chinot), Montpellier (L. Bauchet, V. Rigau), Nancy (P. Beauchesne, G. Gauchotte), Nantes (M. Campone, D. Loussouarn), Nice (D. Fontaine, F. Vandebos-Burel), Nîmes (A. Le Floch, P. Roger) Orléans (C. Blechet, M. Fesneau), Paris (A. Carpentier, J. Y. Delattre [POLA Network National coordinator], S. Elouadhani-Hamdi, M. Polivka), Poitiers (D. Larrieu-Ciron, S. Milin), Reims (P. Colin, M. D. Diebold), Rennes (D. Chiforeanu, E. Vauleon), Rouen (O. Langlois, A. Laquerriere), Saint-Etienne (F. Forest, M. J. Motso-Fotso), Saint-Pierre de la Réunion (M. Andraud, G. Runavot), Strasbourg (B. Lhermitte, G. Noel), Suresnes (S. Gaillard, C. Villa), Toulon (N. Desse), Tours (C. Rousselot-Denis, I. Zemmoura), Toulouse (E. Cohen-Moyal, E. Uro-Coste), Villejuif (F. Dhermain)

References

- Louis DN, Perry A, Reifenberger G, et al. The 2016 World Health Organization Classification of Tumors of the Central Nervous System: a summary. *Acta Neuropathol.* 2016;131(6):803–820.
- Cancer Genome Atlas Research Network, Brat DJ, Verhaak RGW, et al. Comprehensive, integrative genomic analysis of diffuse lower-grade gliomas. *N Engl J Med.* 2015;372(26):2481–2498.
- Olar A, Wani KM, Alfaro-Munoz KD, et al. IDH mutation status and role of WHO grade and mitotic index in overall survival in grade II-III diffuse gliomas. *Acta Neuropathol.* 2015;129(4):585–596.
- Pekmezci M, Rice T, Molinaro AM, et al. Adult infiltrating gliomas with WHO 2016 integrated diagnosis: additional prognostic roles of ATRX and TERT. *Acta Neuropathol (Berl).* 2017;133(6):1001–1016.
- Reuss DE, Mamatjan Y, Schrimpf D, et al. IDH mutant diffuse and anaplastic astrocytomas have similar age at presentation and little difference in survival: a grading problem for WHO. *Acta Neuropathol.* 2015;129(6):867–873.
- Suzuki H, Aoki K, Chiba K, et al. Mutational landscape and clonal architecture in grade II and III gliomas. *Nat Genet.* 2015;47(5):458–468.
- Shirahata M, Ono T, Stichel D, et al. Novel, improved grading system(s) for IDH-mutant astrocytic gliomas. *Acta Neuropathol.* 2018;136(1):153–166.
- Reis GF, Pekmezci M, Hansen HM, et al. CDKN2A loss is associated with shortened overall survival in lower-grade (World Health Organization grades II-III) astrocytomas. *J Neuropathol Exp Neurol.* 2015;74(5):442–452.
- Roy DM, Walsh LA, Desrichard A, et al. Integrated genomics for pinpointing survival loci within arm-level somatic copy number alterations. *Cancer Cell.* 2016;29(5):737–750.
- Korshunov A, Casalini B, Chavez L, et al. Integrated molecular characterization of IDH-mutant glioblastomas. *Neuropathol Appl Neurobiol.* 2019;45(2):108–118.
- Cimino PJ, Holland EC. Targeted copy number analysis outperforms histological grading in predicting patient survival for WHO grade II/III IDH-mutant astrocytomas. *Neuro Oncol.* 2019;21(12):819–821.
- Cimino PJ, Zager M, McFerrin L, et al. Multidimensional scaling of diffuse gliomas: application to the 2016 World Health Organization classification system with prognostically relevant molecular subtype discovery. *Acta Neuropathol Commun.* 2017;5(1):39.
- Aoki K, Nakamura H, Suzuki H, et al. Prognostic relevance of genetic alterations in diffuse lower-grade gliomas. *Neuro Oncol.* 2018;20(1):66–77.
- Alentorn A, Dehais C, Ducray F, et al; POLA Network. Allelic loss of 9p21.3 is a prognostic factor in 1p/19q codeleted anaplastic gliomas. *Neurology.* 2015;85(15):1325–1331.
- Tabouret E, Nguyen AT, Dehais C, et al; for POLA Network. Prognostic impact of the 2016 WHO classification of diffuse gliomas in the French POLA cohort. *Acta Neuropathol.* 2016;132(4):625–634.
- Kaloshi G, Benouaich-Amiel A, Diakite F, et al. Temozolomide for low-grade gliomas: predictive impact of 1p/19q loss on response and outcome. *Neurology.* 2007;68(21):1831–1836.
- Ishwaran H, Gerds TA, Kogalur UB, Moore RD, Gange SJ, Lau BM. Random survival forests for competing risks. *Biostatistics.* 2014;15(4):757–773.
- van den Bent MJ, Brandes AA, Taphoorn MJB, et al. Adjuvant procarbazine, lomustine, and vincristine chemotherapy in newly diagnosed anaplastic oligodendroglioma: long-term follow-up of EORTC brain tumor group study 26951. *J Clin Oncol.* 2013;31(3):344–350.
- Cairncross JG, Wang M, Jenkins RB, et al. Benefit from procarbazine, lomustine, and vincristine in oligodendroglioma tumors is associated with mutation of IDH. *J Clin Oncol.* 2014;32(8):783–790.
- Sherr CJ. Cancer cell cycles. *Science.* 1996;274(5293):1672–1677.
- Serrano M, Hannon GJ, Beach D. A new regulatory motif in cell-cycle control causing specific inhibition of cyclin D/CDK4. *Nature.* 1993;366(6456):704–707.
- Stott FJ, Bates S, James MC, et al. The alternative product from the human CDKN2A locus, p14(ARF), participates in a regulatory feedback loop with p53 and MDM2. *EMBO J.* 1998;17(17):5001–5014.
- Purkait S, Jha P, Sharma MC, et al. CDKN2A deletion in pediatric versus adult glioblastomas and predictive value of p16 immunohistochemistry. *Neuropathology.* 2013;33(4):405–412.
- Cohen A, Sato M, Aldape K, et al. DNA copy number analysis of grade II-III and grade IV gliomas reveals differences in molecular ontogeny including chromothripsis associated with IDH mutation status. *Acta Neuropathol Commun.* 2015;3:34.
- Duregon E, Bertero L, Pittaro A, et al. Ki-67 proliferation index but not mitotic thresholds integrates the molecular prognostic stratification of lower grade gliomas. *Oncotarget.* 2016;7(16):21190–21198.