



**HAL**  
open science

## Degenerative lumbar disc disease: in vivo data support the rationale for the selection of appropriate animal models

M Fusellier, J Clouet, O. Gauthier, M Tryfonidou, J. Guicheux, Catherine Le Visage

### ► To cite this version:

M Fusellier, J Clouet, O. Gauthier, M Tryfonidou, J. Guicheux, et al.. Degenerative lumbar disc disease: in vivo data support the rationale for the selection of appropriate animal models. *European Cells and Materials*, 2020, 39, pp.17-48. 10.22203/eCM.v039a02 . hal-02430633

**HAL Id: hal-02430633**

**<https://hal.science/hal-02430633>**

Submitted on 4 Jan 2023

**HAL** is a multi-disciplinary open access archive for the deposit and dissemination of scientific research documents, whether they are published or not. The documents may come from teaching and research institutions in France or abroad, or from public or private research centers.

L'archive ouverte pluridisciplinaire **HAL**, est destinée au dépôt et à la diffusion de documents scientifiques de niveau recherche, publiés ou non, émanant des établissements d'enseignement et de recherche français ou étrangers, des laboratoires publics ou privés.

## DEGENERATIVE LUMBAR DISC DISEASE: *IN VIVO* DATA SUPPORT THE RATIONALE FOR THE SELECTION OF APPROPRIATE ANIMAL MODELS

M. Fusellier<sup>1,2,\*</sup>, J. Clouet<sup>1,3,4,5</sup>, O. Gauthier<sup>1,6</sup>, M. Tryfonidou<sup>7</sup>, C. Le Visage<sup>1,3</sup> and J. Guicheux<sup>1,3,8</sup>

<sup>1</sup>INSERM, UMR 1229, RMeS, Regenerative Medicine and Skeleton, Université de Nantes, ONIRIS, Nantes, F-44042, France

<sup>2</sup>Department of Diagnostic Imaging, CRIP, ONIRIS, The Nantes-Atlantic National College of Veterinary Medicine, Food Science and Engineering, Nantes F-44307, France

<sup>3</sup>Université de Nantes, UFR Odontologie, Nantes, F-44042, France

<sup>4</sup>Université de Nantes, UFR Sciences Pharmaceutiques et Biologiques, Nantes, F-44042, France

<sup>5</sup>CHU Nantes, PHU11 Pharmacie Centrale, Nantes, F-44093, France

<sup>6</sup>Department of Surgery, CRIP, ONIRIS, The Nantes-Atlantic National College of Veterinary Medicine, Food Science and Engineering, Nantes F-44307, France

<sup>7</sup>Department of Clinical Sciences of Companion Animals, Faculty of Veterinary Medicine, Utrecht University, Utrecht, the Netherlands

<sup>8</sup>CHU Nantes, PHU4 OTONN, Nantes, F-44093, France

### Abstract

Since low-back pain is increasing in ageing populations, current research efforts are focused on obtaining a better understanding of the pathophysiology of intervertebral disc degeneration and on developing new therapeutic strategies. This requires adequate and clinically relevant models of the disease process. *Ex vivo* models can provide insights into isolated aspects of the degenerative/regenerative processes involved; although, ultimately, *in vivo* models are needed for preclinical translational studies. Such models have been developed in numerous animal species with significant variations in size and disc physiology and their number is considerable. Importantly, the choice of the model has to be tailored to the aim of the study. Given the number of available options, it is important to have a good understanding of the various models of disc degeneration and to be fully aware of their advantages and limitations. After comparing the anatomy and histology of intervertebral discs in animals and humans, the present study provides an overview of the different models of *in vivo* disc degeneration. It also provides a comprehensive guide with suggested criteria to select the most appropriate animal model in a question-driven manner.

**Keywords:** Animal model, intervertebral disc, degeneration, nucleus pulposus, disease model, review.

**\*Address for correspondence:** Dr M.S. Fusellier, ONIRIS Imaging Diagnosis, ONIRIS, Atlanpôle-La Chantrerie, Route de Gachet, Nantes, F-44307, France.

Email: marion.fusellier@oniris-nantes.fr

**Copyright policy:** This article is distributed in accordance with Creative Commons Attribution Licence (<http://creativecommons.org/licenses/by-sa/4.0/>).

### List of Abbreviations

ADAMTSs	a disintegrin and metalloproteinase with thrombospondin repeats	GAG	glycosaminoglycan
AF	annulus fibrosus	IL-1	interleukin-1
CD	chondrodystrophic	IVD	intervertebral disc
CEP	cartilaginous endplate	LBP	low-back pain
CT	computed tomography	MMP	matrix metalloproteinases
CTGF/CCN2	connective tissue growth factor	MRI	magnetic resonance imaging
DDD	degenerative disc disease	MRS	magnetic resonance spectroscopy
ECM	extracellular matrix	NCD	non-chondrodystrophic
FGF4	fibroblast growth factor 4	NP	nucleus pulposus
		PG	proteoglycan
		RTqPCR	reverse transcription polymerase chain reaction

SD	standard deviation
TGF- $\beta$	transforming growth factor beta
TNF- $\alpha$	tumour necrosis factor alpha

## Anatomical characteristics of the IVD and pathophysiology of DDD among species

Among the key criteria when choosing an *in vivo* model of DDD, anatomy (size, shape, *etc.*), cell content and biochemical structure of the IVD are the most relevant. Indeed, some species are not large enough to allow for testing of surgical protocols or implantable medical devices in conditions close to those in human surgeries. In other species, the IVD cell content, particularly in the NP, is too distant from that observed in humans, preventing their use in strategies that aim to stimulate cell growth or repair. Therefore, it seems important to provide an overview of IVD characteristics and pathophysiology in the main mammals used as models of DDD.

### Introduction

LBP is a major health concern and an increasing cause of disability. Its socio-economic impact related to treatments and loss of productive time is clear (Ricci *et al.*, 2006). 40 % of LBP is due to IVD degeneration (Johnson *et al.*, 2015). Therefore, research is focusing on improving the understanding of the molecular cascade and cellular events that lead to DDD. To properly assess the role of these different mechanisms in the onset and progression of DDD, many *in vivo* (Alini *et al.*, 2008), *in vitro* (Chan *et al.*, 2013; Watanabe *et al.*, 2010), *ex vivo* (Gantenbein *et al.*, 2015; Li *et al.*, 2016) and *in silico* (Reitmaier *et al.*, 2012) models have been used. They have notably been designed to investigate specific physiopathogenic components of DDD, with a controlled influence of cofounding factors (pH, oxygen level, osmolarity, *etc.*). Ideally, these models should closely mimic the human DDD. However, given the complexity of the IVD, they cannot faithfully replicate its environment and their use is restricted to physiopathogenic studies and screening of new therapies. In this context, animal models are required to apprehend more complex biochemical, biomechanical and cell-mediated processes and to test innovative therapeutic strategies.

Preclinical animal models have been considered in order to reproduce the *in vivo* disease and to overcome safety issues and ethical considerations before human clinical trials. These preclinical models have been developed to address the challenges regarding the etiopathogenesis and pathophysiological conditions of DDD and to favour translational research for the development of new regenerative therapeutics. Multiple models that can help the understanding of different scientific questions are available, but these models are not interchangeable and have to be carefully selected, considering the experimental purposes pursued. Therefore, while the choice of the species remains an important criterion regarding similarities to the human IVD, the DDD induction technique must not be overlooked.

In the present review, the anatomy and pathophysiology of the IVD in mammals are compared and multiple animal models that have been developed over the years are reviewed. Finally, the review highlights the criteria that can guide the selection of pertinent models as related to the goal pursued. Considering the initiating role of the NP degeneration in DDD (Colombier *et al.*, 2014b; Vergroesen *et al.*, 2015), IVD regenerative strategies generally target the NP. In this context, the present review mainly focusses on DDD models that can help address the understanding of NP degeneration/regeneration in the earlier disease phase.

### IVD degeneration: failure of a complete organ

In mammals, the IVD is a complex tripartite structure composed of the NP surrounded by the AF and sandwiched between two CEPs that confers flexibility to the spine and absorbs axial mechanical loading. Many species have a vertebral growth plate or endplate, which is contiguous with the CEPs or separated from those by a bony plate. The AF consists of two counter gradients of type I and type II collagen, with type I collagen concentrated in the outer part of the AF, while the inner part of the AF is richer in type II collagen. IVDs are formed during development by aggregation of mesenchymal cells around the notochord, followed by segmentation (Choi *et al.*, 2008). The NP is formed of notochordal cells, collagen II and elastin fibres in an aggrecan-containing gel. In humans, during ageing, notochordal cells progressively disappear because of apoptosis or differentiation into nucleopulpyocytes. In the present review, the term “nucleopulpyocytes” is used to replace the former and slightly confusing terms “chondrocyte-like cell” and “NP-like cell”. In humans, after the age of 10, notochordal cells are not observed in the NP (Amelot and Mazel, 2018; Smith *et al.*, 2011). The same phenomenon is observed in goats, sheep, cows and specific dog breeds. During NP maturation, a cellular dialog established between nucleopulpyocytes and notochordal cells maintains the NP homeostasis. Indeed, as notochordal cells secrete CTGF/CCN2 and TGF- $\beta$ , ECM synthesis by nucleopulpyocytes is stimulated. The ECM of the healthy NP is rich in aggrecan and type II collagen fibres. Since the NP is enclosed by the AF and CEP and due to the negative charge of its GAG side chains (Adams and Roughley, 2006), it traps water and maintains a homogeneous hydraulic pressure in the IVD. The NP is avascular and its cells are maintained in a permanent hypoxia, with a low pH and high osmolarity environment. Despite the pumping action due to weight bearing and diffusion of metabolites, the pH of the NP and its O<sub>2</sub> level are relatively low as compared to the rest of the body and have a gradient throughout the disc. Nutrients reach the NP by diffusion and convective fluid flow from the

capillaries located above the CEP. This phenomenon requires the integrity of all disc structures.

In both humans and animals, the DDD is a complex sequence of degenerative events that ultimately lead to decreased cellularity and degradation of the NP ECM with a loss of mechanical function (Colombier *et al.*, 2014b; Colombini *et al.*, 2008; Henry *et al.*, 2018). Initial factors that promote DDD are diverse and not completely elucidated, including cumulative trauma with abnormal loading (Stokes and Iatridis, 2004; Vergroesen *et al.*, 2015), impaired nutrition by calcification and/or thickening of the CEP (Accadbled *et al.*, 2008; Benneker *et al.*, 2005; Grignon *et al.*, 2000) and genetic predisposition (Feng *et al.*, 2016; Kalb *et al.*, 2012; Munir *et al.*, 2018). Disturbed cytokine biology and cellular dysfunction may be a response to a myriad of factors such as microtrauma, genetics and smoking, which ultimately alter the cell biology. Indeed, changes in CEP vasculature can be primary or the result of traumas and imbalance of the IL-1 system is a marker of degeneration rather than an initiating factor. Inheritance of some genes of the IL-1 family supports this assertion (Solovieva *et al.*, 2006). The same reasoning can be applied to TNF- $\alpha$  and other cytokines. Even if these cytokines promote and worsen matrix degradation, they could be more markers of disc lesions rather than promoters of DDD.

Changes in the cellular population of the NP play a pivotal role in the early stages of disc degeneration. In humans, the loss of notochordal cells seems to be one of the primary events of the degenerative process (Wang *et al.*, 2007b). As the cellularity of the NP decreases, the balance between ECM production and degradation is altered (Colombini *et al.*, 2008), resulting in NP dehydration and loss of structural and mechanical properties of the IVD. Indeed, while the catabolic activity of MMPs ADAMTSs increases (Roberts *et al.*, 2000), aggrecan is degraded in small fragments and its synthesis is downregulated. Thus, the ECM shows a progressive loss of PGs and a decrease in GAG content, with a transition from type II to type I collagen synthesis. The distinction between NP and AF becomes unclear and calcification of the NP is observed. At the same time, the permeability of the ECM decreases, preventing both the diffusion of nutrients and the removal of metabolites within the NP (Antonioni *et al.*, 1996). Sclerosis of the CEP subchondral bone participates in this decrease of diffusion. In parallel, cracks, fractures and clefts appear in the CEP. ECM impairment induces a decrease in osmotic pressure leading to a marked dehydration of the NP. The loss of hydration and the subsequent drop in intradiscal pressure causes a decrease in IVD height under load and an increased sensitivity to damage by physiological loading. This phenomenon is accompanied by structural lesions such as deformation of the AF, radial cracks and tears of the NP, CEP fracturing, bulging of the disc or even disc herniation.

### Comparison of IVD anatomy among animal models

The organisation of the IVD is highly comparable in all mammals, with a similar overall structure of NP, AF and CEP. Despite this similar organisation, some individual anatomical variations exist considering the IVD shape and size and the spine anatomy, which evolves from rodents to large mammals.

The anatomy and conformation of the disc matter when animal models are used to test surgical techniques and spinal implants and to evaluate their influence on the spine's biomechanics. The overall shape of a vertebra is similar in mammals: it is composed of a vertebral body topped with a dorsal arch that circumscribes the vertebral foramen. IVDs are attached to the vertebral bodies. The dorsal arch is bound to the vertebral body by means of two pedicles. Its dorsal side supports one spinous process and transversal and articular processes that articulate with adjacent vertebral processes. Variations in vertebral anatomy have been thoroughly studied in larger mammals. Regarding the pedicles of lumbar vertebrae, their height is greater in large animals than in humans and their width is similar in baboons, sheep, pigs, calves and deer (Busscher *et al.*, 2010; Sheng *et al.*, 2010). The mean width and depth of the human lumbar vertebral body are greater than those of these species but its dorsoventral diameter is smaller. Sheep lumbar vertebral body volumes are 48 % smaller than those of humans and the vertebral bodies are longer than they are wide, also different from humans (Mageed *et al.*, 2013b). These anatomical variations of the vertebrae have to be carefully considered when choosing a model because some surgical materials can be too large to be used in some species. This is particularly true for the articular processes in case of a transpedicular approach to the NP.

Considering the gross anatomy of the IVD, the lumbar discs are bean-shaped and the NP is eccentrically offset in the disc, positioned slightly dorsally. Compared to humans, rabbits have the most elliptical discs, with a smaller dorsoventral length/lateral length ratio (O'Connell *et al.*, 2007). Bovine tail IVDs are more rounded (Monaco *et al.*, 2016) and their NP is more central. The cow tail IVD is one of the thickest and its NP area normalised to the total disc area is one of the closest to humans (O'Connell *et al.*, 2007). The IVD ventrodorsal diameter varies considerably and increases from the cervical to the lumbar region in humans, although it remains relatively constant along the whole spine in sheep (Wilke *et al.*, 1997). When considering the sizes of the lumbar discs, the human lumbar IVD has systematically larger dimensions than in other primates, dog, pig, calf, goat or sheep lumbar IVDs (Table 1). Cow lumbar IVDs are the largest. Nevertheless, it is important to note that bibliographic data are quite variable even for the same species. This can be explained by the different techniques used for evaluating disc anatomy and size and also by

**Table 1. Comparison of cell content and geometry of lumbar IVD of animal models and humans.** Dimensions are expressed as mean  $\pm$  SD.

Species	Presence of notochordal cells in adulthood	Disc height (mean $\pm$ SD) (mm)	DV width (mm)	Lateral width (mm)	Disc surface (mm <sup>2</sup> )	NP area (mm <sup>2</sup> )	References
Mouse	Yes	0.29 $\pm$ 0.05 (c) 0.31 $\pm$ 0.03 (a, d)	0.98 $\pm$ 0.11 (c) 1.08 $\pm$ 0.09 (a) 1.24 $\pm$ 0.11 (d)	1.35 $\pm$ 0.06 (c) 1.82 $\pm$ 0.1 (a) 1.84 $\pm$ 0.03 (d)	1.04 $\pm$ 0.14 (c) 1.61 $\pm$ 0.18 (a) 1.81 $\pm$ 0.14 (d)	0.33 $\pm$ 0.07 (d) 0.43 $\pm$ 0.09 (a) 0.58 $\pm$ 0.2 (b)	a. Beckstein <i>et al.</i> , 2008 b. Cao <i>et al.</i> , 2017 c. Elliott and Sarver, 2004 d. O'Connell <i>et al.</i> , 2007
Rat	Yes	0.61 $\pm$ 0.17 (c) 0.77 $\pm$ 0.04 (a) 0.93 $\pm$ 0.24 (e) 1.02 $\pm$ 0.23 (d) 1.31 $\pm$ 0.27 (d)	2.75 $\pm$ 0.55 (c), 3.16 $\pm$ 0.27 (a), 3.2 (b), 4.36 $\pm$ 0.16 (e)	3.77 $\pm$ 0.54 (c) 4.49 $\pm$ 0.16 (a) 5.79 $\pm$ 0.29 (e)	8.28 $\pm$ 2.46 (c) 11.85 $\pm$ 0.92 (a) 20.4 $\pm$ 2.1 (e)	3.34 $\pm$ 0.68 (a) 5 $\pm$ 2.06 (e)	a. Beckstein <i>et al.</i> , 2008 b. Bowles <i>et al.</i> , 2012 c. Elliott and Sarver, 2004 d. Jaumard <i>et al.</i> , 2015 e. O'Connell <i>et al.</i> , 2007
Rabbit	Yes	1.42 $\pm$ 0.39 (b) 2.4 $\pm$ 0.23 (a)	6.59 $\pm$ 0.19 (b), 7.46 $\pm$ 0.65 (a)	12.7 $\pm$ 0.9 (b) 13.81 $\pm$ 1.19 (a)	73.4 $\pm$ 6.1 (b) 90 $\pm$ 10 (a)	18 $\pm$ 1.6 (b) 22.6 $\pm$ 6 (a)	a. Beckstein <i>et al.</i> , 2008 b. O'Connell <i>et al.</i> , 2007
Sheep	No	2.5 (b) 2.6 $\pm$ 0.5 (c) 3.3 $\pm$ 1 (c) 3.4 $\pm$ 0.46 (a) 3.93 $\pm$ 0.07 (e) 4.2 $\pm$ 0.4 (f) 4.5 $\pm$ 0.4 (f) 4.9 $\pm$ 0.4 (d)	18.3 $\pm$ 1.8 (d) 19.78 $\pm$ 1.43 (a) 21.6 $\pm$ 2.1 (e) 22 (b)	24.9 $\pm$ 1.7 (d) 30.03 $\pm$ 1.2 (a) 34.5 $\pm$ 2.9 (e)	511 $\pm$ 61 (a) 676 $\pm$ 122 (e)	193 $\pm$ 31 (a) 267 $\pm$ 79 (e)	a. Beckstein <i>et al.</i> , 2008 b. Casaroli <i>et al.</i> , 2017 c. Mageed <i>et al.</i> , 2013a d. Monaco <i>et al.</i> , 2016 e. O'Connell <i>et al.</i> , 2007 f. Wilke <i>et al.</i> , 1997
Goat	No	4.28 $\pm$ 0.73 (b) 7.1 $\pm$ 1 (a) 8.2 $\pm$ 1.4 (a)	21.2 $\pm$ 1.6 (b) 25.6 $\pm$ 1.6 (a)	35.9 $\pm$ 2.1 (b)	380.6 $\pm$ 32.6 (a) 404.9 $\pm$ 48.4 (a) 670 $\pm$ 71 (b)	173 $\pm$ 25 (b)	a. Paul <i>et al.</i> , 2017 b. Showalter <i>et al.</i> , 2013
Pig	Yes	2.6 $\pm$ 0.8 (b) 5.46 $\pm$ 0.71 (a) 7.8 $\pm$ 1.3 (c)	25 $\pm$ 2.3 (c) 25.56 $\pm$ 1.75 (a)	37.13 $\pm$ 1.35 (a) 38 $\pm$ 3.8 (c)	872 $\pm$ 80 (a)	232 $\pm$ 25 (a)	a. Beckstein <i>et al.</i> , 2008 b. Busscher <i>et al.</i> , 2010 c. Monaco <i>et al.</i> , 2016
Calf	No	6.09 $\pm$ 1.32	32.75 $\pm$ 1.9	39.33 $\pm$ 1.6	1100 $\pm$ 86	273 $\pm$ 25	Beckstein <i>et al.</i> , 2008
Human	No	6.07 $\pm$ 1.97 (e) 7.9 $\pm$ 1.8 (d) 8.8 $\pm$ 3.2 (b) 10 $\pm$ 1.6 (d) 10.9 $\pm$ 2.7 (c) 10.91 $\pm$ 0.83 (a) 11.3 $\pm$ 0.3 (f) 12.7 $\pm$ 2.6 (b)	37.2 $\pm$ 4.7 (f) 37.67 $\pm$ 2.02 (a)	55.38 $\pm$ 2.01 (a) 55.9 $\pm$ 9.4 (f)	1560 $\pm$ 320 (c) 1727 $\pm$ 550 (f) 1925 $\pm$ 184 (a)	479 $\pm$ 110 (f) 598 $\pm$ 46 (a)	a. Beckstein <i>et al.</i> , 2008 b. Busscher <i>et al.</i> , 2010 c. Elliott and Sarver, 2004 d. Mageed <i>et al.</i> , 2013a e. Miao <i>et al.</i> , 2013 f. O'Connell <i>et al.</i> , 2007

the differences in age or breed of the animals used, which are often not specified.

Human and sheep lumbar IVDs are domed on their rostral and caudal surface in a biconvex shape. On the contrary, pig's lumbar discs are convex rostrally and concave caudally. Bovine lumbar IVDs are described differently depending on the authors: cupola-shaped (Alini *et al.*, 2008) or biconvex (Cotterill *et al.*, 1986). IVDs are thinner dorsally and thicker in the ventral region. The height of the discs contributes to a substantial part of the total length of the lumbar spine in humans, accounting for 25 % of the spinal length, but this is no more than 10 % in calves. Sheep, goat, pig and calf lumbar IVDs are thinner than the human IVD, with the smallest disc area (Mageed *et al.*, 2013a; O'Connell *et al.*, 2007; Schmidt and Reitmaier, 2012). When considering not the gross dimensions but the relative dimensions of the disc (normalised disc height, *i.e.* disc height scaled by lateral width), the normalised disc height is less than in humans in most mammal species and, interestingly, mouse and rat

lumbar IVDs are the most geometrically analogous to the human IVD (O'Connell *et al.*, 2007). However, the thickness of mouse's disc increases from birth until 4 months and decreases with ageing (Cao *et al.*, 2017). These considerations are of interest because the size of the disc affects nutrition in relation with diffusion distance. Cellularity is also greatly influenced by size and diffusion (Guehring *et al.*, 2009).

These data must be interpreted with care, given that they are influenced by breed, individual size, gender and, of course, age. Large animal models seem to better mimic the challenging nutritional environment of human IVDs.

#### Cell content and biochemical pattern of the NP

As mentioned above, the cell population in the NP changes throughout the animal's life, more particularly during DDD. Biochemical composition also follows the same evolution. The cell population of the NP is not similar among species (Table 1) and differences must be known when studying IVD

**Table 2. Comparative water and collagen content of IVD among species.** Dimensions are expressed as mean  $\pm$  SD. L : lumbar disc, T : tail disc.

Species	Percentage of water content NP	GAG per dry weight (mg/mg)	Total collagen content normalised by dry weight (mg/mg)	References
Rat – L	82 $\pm$ 9	384 $\pm$ 108		Beckstein <i>et al.</i> , 2008
Rat -T	75 $\pm$ 7	95.2 $\pm$ 55.0		Beckstein <i>et al.</i> , 2008
Rabbit	82 $\pm$ 5	579 $\pm$ 158		Beckstein <i>et al.</i> , 2008
Sheep	75 $\pm$ 3 (a) 86 $\pm$ 4 (b)	547 $\pm$ 69.5 (a)	19.2 $\pm$ 10.6 (c)	a. Beckstein <i>et al.</i> , 2008 b. Reid <i>et al.</i> , 2002 c. Showalter <i>et al.</i> , 2013
Goat	74.7 $\pm$ 1.1 (a) 84 $\pm$ 3 (b)	335 $\pm$ 51 (b)	18.5 $\pm$ 5.8 (b)	a. Detiger <i>et al.</i> , 2013 b. Showalter <i>et al.</i> , 2013
Pig	83 $\pm$ 2 (a)	379 $\pm$ 160 (a)	5.8 $\pm$ 2.9 (b)	a. Beckstein <i>et al.</i> , 2008 b. Showalter <i>et al.</i> , 2013
Baboon	80 $\pm$ 4 (a)	971 $\pm$ 238 (a)	18.6 $\pm$ 6.7 (b)	a. Beckstein <i>et al.</i> , 2008 b. Showalter <i>et al.</i> , 2013
Calf	80 $\pm$ 2 (a)	384 $\pm$ 34.0 (a)	60.3 $\pm$ 18.5 (b)	a. Beckstein <i>et al.</i> , 2008 b. Showalter <i>et al.</i> , 2013
Cow – T	83 $\pm$ 3	548 $\pm$ 146		Beckstein <i>et al.</i> , 2008
Human	81 $\pm$ 3 (a) 78 $\pm$ 3 (b) 83 (c)	466 $\pm$ 205 (a)	15.6 $\pm$ 4 (d)	a. Beckstein <i>et al.</i> , 2008 b. Gower and Pedrini, 1969 c. Lyons <i>et al.</i> , 1981 d. Showalter <i>et al.</i> , 2013

degeneration/regeneration. Indeed, the pivotal role of notochordal cells in the cellular dialogue with nucleopulocytes is of scientific relevance (Colombier *et al.*, 2014a). The cell population influences, among other processes, PG metabolism (Aguilar *et al.*, 1999), hyaluronan production (Stevens *et al.*, 2000) and progenitor cell function (Chan *et al.*, 2014). Thus, the choice of an animal model in which notochordal cells persist in adulthood could greatly influence experimental results and modify responses to treatment by growth factors: notochordal cells could contribute to a self-repair process of the IVD that is not observed in humans. Similarly, results of cellular regenerative therapies could be affected by the potential presence of notochordal cells that could be responsible for regenerative effects instead of, or in combination with, transplanted cells.

The gradual disappearance of notochordal cells seems to be the common denominator in the process leading to DDD and has been observed in humans, dogs, sheep, goats, cows and monkeys (Table 1) (Bergknut *et al.*, 2012; Daly *et al.*, 2016; Hansen *et al.*, 2017; Hoogendoorn *et al.*, 2008). The example of the dog is particularly striking. Dogs are classically divided into two populations: CD and NCD. It has long been thought that DDD was induced by different processes in the two types of dogs, chondroid *versus* fibroid metaplasia. In fact, even if the time course of DDD onset is not similar, DDD involves the same process as in humans, *i.e.* a replacement of notochordal cells by nucleopulocytes (Hansen *et al.*, 2017). In NCD dogs, this phenomenon is delayed because notochordal cells persist longer than in CD dogs. Nonetheless, even in NCD dogs, DDD will

occur at preferential sites; with the highest incidence at the lumbosacral junction, a biomechanically challenging anatomical location. When degeneration occurs in NCD dogs, regardless of the location, the biochemical, histological, radiological and clinical representation resembles that of humans suffering LBP. Notochordal cells also persist in the NP of other species such as mice, rats, rabbits and pigs (Omlor *et al.*, 2009). Typically, notochordal cells persist in the NP of sand rats, mice and rats throughout their life and at least until 12 months old rabbits (Hunter *et al.*, 2004). Nevertheless, genetics strongly influence this phenomenon as the cell phenotype is dependent on the strain in mice (Choi *et al.*, 2018). In pigs, notochordal cells are also observed in the NP during adulthood.

While the NP cellular phenotype evolves, the biochemical profile also changes as the ECM synthesis decreases (anabolism) and its degradation increases (catabolism). This explains a depletion of GAG and a reduced water-binding capacity with a reduction of IVD height. GAG content in the NP of healthy IVDs varies from one species to another as does water content (Table 2). It is notable that in baboons, goats and sheep, NP hydration and collagen contents are similar to those observed in humans (Beckstein *et al.*, 2008), whereas pig IVDs exhibit half as much collagen as human IVDs. GAG content per dry weight is in the same range in humans, goats, calves, pigs, rabbits, rats and sheep. Once again, these experimental data must be taken with care since it has been clearly established that the composition varies not only with ageing but also with spinal level.

### Biomechanical characteristics of the IVD

Contrary to nearly all animals (except for non-human primates) used as models of DDD, humans have a bipedal locomotion. Therefore, the influence of quadrupedal locomotion on IVD biomechanics is often discussed.

First, in lumbar spine segments, the flexion and extension range are smaller for calves, sheep and pigs as compared to humans (Alini *et al.*, 2008). However, after normalisation by polar moment of inertia and disc height, axial torsional properties of lumbar discs of mice, rats, rabbits, calves, baboons and goats are similar to humans (Showalter *et al.*, 2013). Secondly, vertical posture significantly influences IVD mechanical loading because of the weight of the human upper body. Mechanical forces exerted on the human lumbar spine are of lower magnitude than in quadrupeds. The effect of the upright position seems largely counterbalanced by muscle contraction and ligament tension, which significantly contribute to the load to which IVDs are exposed (Wilke *et al.*, 2003). Thus, since muscle and ligament forces are necessary to stabilise the spine in a horizontal position, the force they exert on the IVD is greater in quadrupeds than in humans. As a result, even if direct measures differ, after normalisation by geometric parameters (disc height and area), the capacity of IVDs to resist mechanical constraints appears quite similar across quadruped species, including mice, rats, rabbits, calves, pigs, baboons and sheep (Beckstein *et al.*, 2008). Moreover, higher axial forces on the lumbar IVD of a quadruped cause higher intradiscal pressure than in humans, as demonstrated in sheep and runt cows (Buttermann *et al.*, 2009; Reitmaier *et al.*, 2013). Loading of the lumbar IVD is proposed to be greater in large quadrupeds than in humans, corroborated by the higher bone mineral density of the vertebral bodies of sheep, calves and pigs when compared to humans.

These data undoubtedly indicate that quadrupedal mammals can be considered relevant models of lumbar IVD biomechanics and degeneration as compared to bipedal organisms.

### Animal models of DDD

In an attempt to mimic the natural pathophysiological process of human IVD degeneration, numerous models have been developed, in both large and small animals (Table 3, 4a,b). These models mainly correspond to spontaneously occurring forms of DDD because of ageing or genetic conditions. Specific breeding environments (*e.g.* genetic backgrounds, rearing method, nutrition) can enhance or accelerate the occurrence of DDD. Besides these models, experimentally induced models have been proposed to achieve higher reliability, reproducibility, cost-effectiveness and development speed. In these models, DDD develops as a result of mechanical or

structural lesions of the disc. Mechanical models are based on alterations of mechanical stress applied to the IVD. They involve changes in motion (instability or immobilisation), modified loading by means of bending, postural changes or compression. Structural models are based on direct injury to a part of the IVD (AF or CEP with or without extension to NP). These lesions can be traumatic, inflammatory or chemical (Fig. 1).

### Spontaneous models of DDD

Animal models of spontaneously occurring DDD are limited in number and they have the drawback of an inconsistent onset and development over a long and sometimes variable period, which is in line with clinical development and progress of DDD. Furthermore, their costs are relatively high, especially for larger species. Nevertheless, they remain very useful when evaluating natural degenerative pathophysiological processes.

#### *Degeneration related to ageing*

DDD can spontaneously affect several animal species including specific strains of mice such as SM/J, sand rats, rabbits, sheep and dogs. Age-related IVD degeneration has also been described in C57BL/6 mice 14-22 months old (Ohnishi *et al.*, 2018), with severity progressing with ageing, but SM/J mice develop DDD as early as 17 weeks of age in parallel with decreased cellularity in the NP. Notwithstanding, considering that the genetic background of mice may have an influence on the healing capacity of joint cartilaginous tissues, it remains to be determined whether these also relate to a differential susceptibility in developing DDD. Mediterranean sand rats spontaneously develop early (by the age of 2 months) and widespread DDD, associated with diabetes mellitus, when fed with a standard laboratory diet (Silberberg, 1988). The DDD in this model is characterised by a loss of notochordal cells in the NP, annular disorganisation, end-plate sclerosis, osteophytosis associated with dehydration and NP osmotic pressure (Gruber *et al.*, 2002; Ziv *et al.*, 1992). These modifications alter the biomechanical properties of the whole IVD. The lesions extend from the lumbar IVD to the tail and affect around 50 % of the animals by the age of 18 months (Moskowitz *et al.*, 1990). DDD in the sand rat is also generally associated with diffuse idiopathic skeletal hyperostosis and radiographic signs of bony degeneration (facet changes, wedging, end plate spurring and calcification). Other animal species have been shown to develop spontaneous degeneration unrelated to diabetes, such as ageing in mice (Ohnishi *et al.*, 2018), rabbits (Clouet *et al.*, 2011; Leung *et al.*, 2008; Lucas *et al.*, 2012), dogs (Hansen *et al.*, 2017), sheep (Nisolle *et al.*, 2016), baboons and macaques (Lauerman *et al.*, 1992; Nuckley *et al.*, 2008; Platenberg *et al.*, 2001). In larger animal models, DDD has been characterised extensively with progressive

Table 3. Review of spontaneous animal models of IVD degeneration.

Type of models		Species	Onset of degeneration	References
Spontaneous aging		Mouse C57BL/6	14-22 months	Ohnishi <i>et al.</i> , 2018
		Mouse SM/J	17 weeks	Choi <i>et al.</i> , 2018
		Rabbit	6-30 months	Clouet <i>et al.</i> , 2011 Leung <i>et al.</i> , 2008
		Sheep	4-7 years	Nisolle <i>et al.</i> , 2016
		Macaque	22.3 years	Nuckley <i>et al.</i> , 2008
		Baboon	14-15.7 years	Lauerman <i>et al.</i> , 1992 Platenberg <i>et al.</i> , 2001
Accelerated degeneration	Spontaneous	Mediterranean sand rat	2-12 months	Gruber <i>et al.</i> , 2006
		CD dogs	3-7 years	Bergknut <i>et al.</i> , 2011
	Diabetes	Mediterranean sand rat	2-30 months	Adler <i>et al.</i> , 1983 Moskowitz <i>et al.</i> , 1990 Silberberg, 1988 Ziran; <i>et al.</i> , 1994 Ziv <i>et al.</i> , 1992
Inherited lesions	Kyphoscoliosis	Mouse	2.5 months	Mason and Palfrey, 1984 Venn and Mason, 1986
		NCD dogs	1-4 years	Faller <i>et al.</i> , 2014
	Chondrodystrophy	CD dogs	3-7 years	Bergknut <i>et al.</i> , 2011
Genetic models	Collagen type IX	Mouse	3 months	Boyd <i>et al.</i> , 2008 Kimura <i>et al.</i> , 1996
	Myostatin knockout	Mouse	6 months	Hamrick <i>et al.</i> , 2003
	Cmd aggrecan knockout mice	Mouse	4 weeks	Watanabe and Yamada, 2002
	Progressive ankylosis	Mouse	3 months	Sweet and Green, 1981
	Mutation in Mecom	Mouse	2 weeks	Juneja <i>et al.</i> , 2014
	Caveolin-1-null mice	Mouse	1 month	Bach <i>et al.</i> , 2016
	Murine progeroid syndrome	Mouse	5-6 months	Vo <i>et al.</i> , 2012
	Neurofibromatosis type 1 mice	Mouse	2-6 months	Rhodes <i>et al.</i> , 2015 Wang <i>et al.</i> , 2011
	<i>Col2a1</i> for collagen II	Mouse	1 month	Sahlman <i>et al.</i> , 2001
	HLA-B27	Rat	4-5 months	Taurog <i>et al.</i> , 1993

decrease of cellularity and dehydration of the NP (confirmed with Boos and Pfirrmann scoring), disc space narrowing and sclerosis of CEP.

#### *Degeneration related to inherited disorders*

Apart from the effect of ageing, some species have been shown to present IVD degeneration secondary

to the presence of congenital lesions such as kyphoscoliosis and chondrodystrophy.

In dogs and mice, kyphoscoliosis induces early IVD degeneration. Kyphoscoliosis is due to malformations of vertebral bodies caused by failure of vertebral ossification centres to form and/or to fuse properly during embryonic or foetal development.



**Table 4a. Review of experimentally induced mechanical animal models of IVD degeneration.**

Type of models		Species	Onset of degeneration	References
Forceful bending	Tail bending	Mouse	1 week	Court <i>et al.</i> , 2001
Compression	Static compression	Rat	1-2 months	Iatridis <i>et al.</i> , 1999 Yurube <i>et al.</i> , 2010
		Rabbit	1 month	Kroeber <i>et al.</i> , 2002
	Dynamic compression	Mouse	1 week	Walsh and Lotz, 2004
		Rat	0-14 d	Ching <i>et al.</i> , 2003; Ching <i>et al.</i> , 2004
Bipedalism		Mouse	3-12 months	Higuchi <i>et al.</i> , 1983
		Rat	1-3 months	Cassidy <i>et al.</i> , 1988
Bipedalism + pinealectomy		Rat	3 months	Machida <i>et al.</i> , 2005
Instability	Fusion	Rabbit	6-9 months	Phillips <i>et al.</i> , 2002
		CD dogs	6 months	Taylor <i>et al.</i> , 1976
	Fusion	Sheep	6-12 weeks	Foster <i>et al.</i> , 2002
	Facetectomy	Rabbit	6 months	Sullivan <i>et al.</i> , 1971
	Torsion + facetectomy	Rabbit	3 months	Hadjipavlou <i>et al.</i> , 1998
	Resection of spinous process	Mouse	6-12 months	Miyamoto <i>et al.</i> , 1991
	Facetectomy + resection of ligaments	Mouse	2-12 weeks	Oichi <i>et al.</i> , 2018
	Immobilisation	Rats	6-8 weeks	Che <i>et al.</i> , 2018
Sheep		6-26 weeks	Wang <i>et al.</i> , 2018	
Hyperactivity	Running	Dog	15-55 weeks	Puustjärvi <i>et al.</i> , 1994 Saamanen <i>et al.</i> , 1993

It induces spinal deformity that leads to dorsal (kyphosis) and lateral (scoliosis) curvature. In mice, the kyphoscoliosis peptidase gene (*ky*) has been identified. Its transcript has been identified in skeletal muscles and heart and the *ky* protein belongs to a family of transglutaminase-like proteins (Blanco *et al.*, 2004). A homozygous variant of this gene leads to neuromuscular disorder with decreased strength of postural muscles inducing kyphoscoliosis. In 80 d old homozygous recessive mice (*ky/ky*), kyphoscoliosis is associated with cervicothoracic DDD characterised by decreased cellularity, loss of distinction between NP and AF, reduced PG synthesis and size as well as smaller cervicothoracic IVD size (between the fifth cervical and the second thoracic vertebrae) (Mason and Palfrey, 1984; Venn and Mason, 1986). The mechanical effect of abnormal spine posture

or anomalous alignment of vertebrae on disc degeneration has been thoroughly documented in dogs in association with vertebral malformations (Faller *et al.*, 2014) (Fig. 2). Numerous malformations affect canine thoracic or thoracolumbar vertebrae and induce an alteration of shape such as hemivertebra, ventral hypoplasia or aplasia (Gutierrez-Quintana *et al.*, 2014).

Chondrodystrophy is also associated with premature disc degeneration. Chondrodystrophy is a disorder of endochondral ossification and chondrogenesis that results in impaired ossification and growth of long bones. The lesion is associated with a highly expressed *FGF4* retrogene insertion on chromosome 12 (Brown *et al.*, 2017; Parker *et al.*, 2009). Numerous popular canine breeds have been selected with this anomaly such as basset hound, beagle,

Table 4b. Review of experimentally induced structural animal models of IVD degeneration.

Type of models		Species	Onset of degeneration	References
Chemical methods	Chymopapain	Rabbit	6 d	Kiester <i>et al.</i> , 1994
		CD dogs	1 d to 32 weeks	Atilola <i>et al.</i> , 1988; Melrose <i>et al.</i> , 1996
		NCD dogs	1-3 weeks	Bradford <i>et al.</i> , 1983; Kudo <i>et al.</i> , 1993; Lü <i>et al.</i> , 1997; Spencer <i>et al.</i> , 1985; Wakano <i>et al.</i> , 1983
		Baboon	4 weeks	Zook and Kobrine, 1986
		Rhesus macaque	6 weeks	Sugimura <i>et al.</i> , 1996
		Cow	3 weeks	Roberts <i>et al.</i> , 2008
	Chondroitinase ABC	Rat	4-12 weeks	Boxberger <i>et al.</i> , 2008; Norcross <i>et al.</i> , 2003
		Rabbit	7-10 d	Henderson <i>et al.</i> , 1991; Takahashi <i>et al.</i> , 1996
		CD dogs	7-21 d	Fry <i>et al.</i> , 1991
		NCD dogs	1 week	Lü <i>et al.</i> , 1997
		Goat	12-26 weeks	Hoogendoorn <i>et al.</i> , 2008
		Sheep	1 week	Sasaki <i>et al.</i> , 2001
	Hyaluronidase	Rhesus macaque	6 weeks	Sugimura <i>et al.</i> , 1996
		Rabbit	2-6 d	Fusellier <i>et al.</i> , 2016
	Collagenase	NCD dogs	2 weeks	Bromley <i>et al.</i> , 1980; Spencer <i>et al.</i> , 1985
		Baboon	4 weeks	Zook and Kobrine, 1986
Rhesus macaque		7 d to 14 months	Stern and Coulson, 1976	
Cow		Immediate	Antoniou <i>et al.</i> , 2006	
Trypsin	Cow	16 h to 3 weeks	Mwale <i>et al.</i> , 2008; Roberts <i>et al.</i> , 2006	
Endplate injury	Ischemic lesion pingyangmycin	Rabbit	3-6 months	Wei <i>et al.</i> , 2015
		Rhesus macaque	1-3 months	Zhou <i>et al.</i> , 2013b
	Ischemic lesion bleomycin	Rhesus macaque	3-15 months	Wei <i>et al.</i> , 2014
	Perforation	Pig	3-7 months	Holm <i>et al.</i> , 2004 Cinotti <i>et al.</i> , 2005
Annulotomy	Needle puncture	Mouse	2-8 weeks	Martin <i>et al.</i> , 2013; Ohnishi <i>et al.</i> , 2016; Tian <i>et al.</i> , 2018
		Rat	7-28 d	Hsieh <i>et al.</i> , 2009; Issy <i>et al.</i> , 2013
		Rabbit	2-9 weeks	Chai <i>et al.</i> , 2016; Kim <i>et al.</i> , 2015; Luo <i>et al.</i> , 2018; Masuda <i>et al.</i> , 2004; Sobajima <i>et al.</i> , 2005
	AF incision	Rat	7-28 d	Rousseau <i>et al.</i> , 2007
		Rabbit	2-6 weeks	Lipson and Muir, 1981; Masuda <i>et al.</i> , 2004
		NCD dogs	4-12 weeks	Chen <i>et al.</i> , 2015
		Dog	4-6 months	Olsewski <i>et al.</i> , 1996
		Sheep	3-12 months	Freeman <i>et al.</i> , 2016; Schollum <i>et al.</i> , 2010
	Pig	3 months	Kääpä <i>et al.</i> , 1994	
	Annulotomy/drill bit	Goat	2 months	Zhang <i>et al.</i> , 2011
Partial annulotomy	Sheep	4-12 months	Osti <i>et al.</i> , 1990	
Annulotomy + collagenase	Rhesus macaque	7 d to 14 months	Stern and Coulson, 1976	
Nucleotomy		Rabbit	2-6 weeks	Lucas <i>et al.</i> , 2012a; Sakai <i>et al.</i> , 2005
		CD dogs	4-6 weeks	Serigano <i>et al.</i> , 2010; Bach <i>et al.</i> , 2018
		Sheep	12-48 weeks	Guder <i>et al.</i> , 2009; Reitmaier <i>et al.</i> , 2014; Russo <i>et al.</i> , 2016; Vadalà <i>et al.</i> , 2013; Vadalà <i>et al.</i> , 2015
		Pig	3-24 weeks	Acosta <i>et al.</i> , 2011; Omlor <i>et al.</i> , 2009
	Partial nucleotomy	NCD dogs	6 weeks	Ganey <i>et al.</i> , 2009
	Laser	Rabbit	60-90 d	Fusellier <i>et al.</i> , 2016; Lucas <i>et al.</i> , 2012a
	Cryoinjury	Pig	2 months	Flouzat-Lachaniette <i>et al.</i> , 2018

bulldogs, Cavalier King Charles spaniel, dachshund, Lhasa Apso, Pekingese and Welsh corgis (Brisson, 2010; Cherrone *et al.*, 2004; Griffin *et al.*, 2009; Priester, 1976). Animals affected exhibit premature IVD degeneration at all disc levels, with a high incidence of disc herniation at the thoracolumbar junction. For a long time, CD dogs were thought to have a specific form of DDD different from NCD dogs. This form had been named chondroid degeneration in CD breeds *versus* fibroid metaplasia in NCD dogs. This hypothesis has been recently disputed (Hansen *et al.*, 2017) and it has been demonstrated that the DDD of CD and NCD breeds follow the same pattern but with a different timeline. Therefore, canine DDD is similar to what is observed in human DDD, characterised by a replacement of notochordal cells by nucleopulpyocytes (Bergknut *et al.*, 2012) associated with an early decrease in PG and GAG content and increased MMP-2 activity. The notochordal cell decrease is more gradual in NCD breeds where they can still be found in the IVD during adulthood.

#### Degeneration related to alteration in gene expression

Genetically modified animals, including the use of knock-out models, have been developed to study the contribution of specific proteins or mutation to disc degeneration. Numerous varieties of transgenic mice have been investigated.

- Cmd aggrecan knockout mice have a haploinsufficiency of aggrecan and develop cervical DDD (Watanabe and Yamada, 2002).
- Mutation in type IX collagen induces mucous cervical DDD in mice (Allen *et al.*, 2009; Boyd *et al.*, 2008) and type IX collagen gene polymorphisms increase risk for disc degeneration in humans (Feng *et al.*, 2016; Paassilta *et al.*, 2001). In the same way, type II collagen mutation such as knockout

allele of *Col2a1* induces DDD and premature endplate calcification (Sahlman *et al.*, 2001).

- Myostatin knockout mice (*Mstn*<sup>-/-</sup>) exhibit increased muscle mass associated with increase of bone mineral density. Indeed, myostatin (GDF8) is a negative regulator of skeletal muscle growth. The mutation also induces disc degeneration associated with a decreased proteoglycan content in the hyaline end plates and inner AF (Hamrick *et al.*, 2003). Similarly, *GDF5* knockout mice present DDD demonstrated by a decreased T2 signal in MRI and disorganisation of NP with downregulation of aggrecan and type II collagen mRNA (Li *et al.*, 2004).
- In mice, other genetic models have been shown to be associated with DDD: progressive ankylosis mice (Sweet and Green, 1981), a Mecom mutation in mice (Juneja *et al.*, 2014), caveolin-1-null mice (Bach *et al.*, 2016), neurofibromatosis type 1 mice (Rhodes *et al.*, 2015; Wang *et al.*, 2011) and murine progeroid syndrome (Vo *et al.*, 2012). In rats, mutations have also been described such as HLA-B27 rats (Hammer *et al.*, 1990; Taurog *et al.*, 1993).

Other genetic murine models have been shown to be associated with DDD: progressive ankylosis (Sweet and Green, 1981), Mecom mutation (Juneja *et al.*, 2014), caveolin-1-null (Bach *et al.*, 2016), neurofibromatosis type 1 (Rhodes *et al.*, 2015; Wang *et al.*, 2011) and progeroid syndrome (Vo *et al.*, 2012). In rats, mutations have also been described such as HLA-B27 rats (Hammer *et al.*, 1990; Taurog *et al.*, 1993).

#### Experimentally induced disc disease

Contrary to spontaneous models that do not require direct intervention on the spine or IVD, numerous

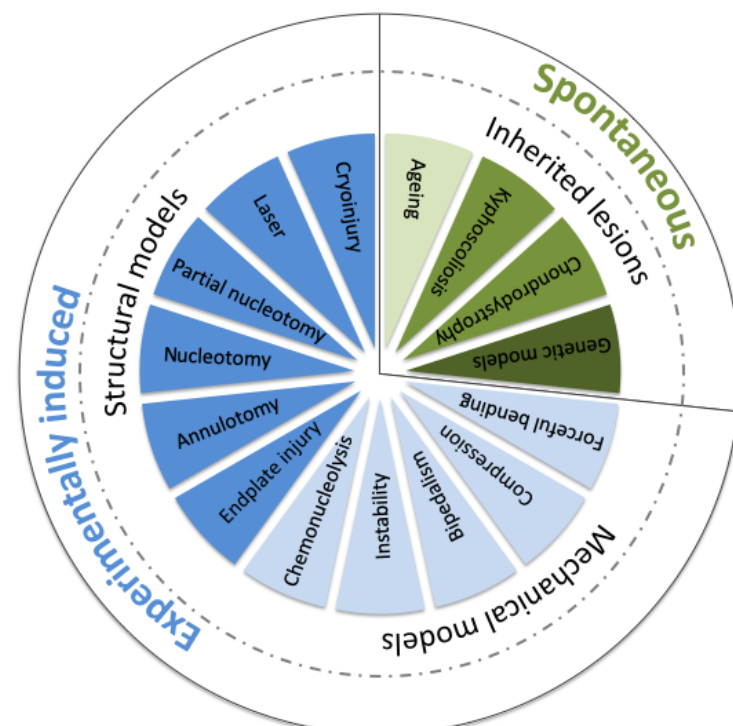


Fig. 1. Schematic representation of the different *in vivo* animal models of DDD.

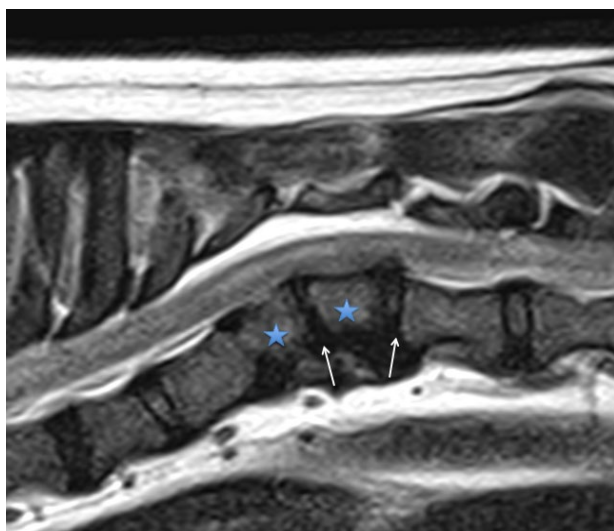
experimental models have been developed with the aim of more accurately controlling location and time course of the degeneration as well as the amplitude of the induced injury. These models require a modification of spine kinematics (mechanical models) or direct damage to the IVD or CEP (structural models).

#### *Mechanical models*

Mechanical models are based on the hypothesis that alterations of the mechanical stress applied to the spine would be the source of premature ageing of the IVD. This hypothesis is supported by epidemiological data suggesting an association between IVD degeneration and abnormal loading conditions, including immobilisation (Choi *et al.*, 2017). Stresses that have been tested are numerous and vary from overloading with static or dynamic disc compression (Ching *et al.*, 2003; Ching *et al.*, 2004; Court *et al.*, 2001; Iatridis *et al.*, 1999; Kroeber *et al.*, 2002; Lotz *et al.*, 1998; Walsh and Lotz, 2004) to postural changes such as bipedalism (Cassidy *et al.*, 1988; Higuchi *et al.*, 1983). Hyperactivity has been investigated in relation to running (Puustjarvi *et al.*, 1993; Puustjärvi *et al.*, 1994; Saamanen *et al.*, 1993) as well as instability or distraction (Hadjipavlou *et al.*, 1998; Kroeber *et al.*, 2005), fusion (Bushell *et al.*, 1978; Phillips *et al.*, 2002; Taylor *et al.*, 1976) and even immobilisation (Wang *et al.*, 2018). Most of these models require complex and invasive surgeries and some are barely compatible with ethical standards.

#### *Mechanical models – postural changes*

The idea of evaluating the impact of postural changes upon the ageing of the IVD came from the hypothesis that the human erect posture elicits



**Fig. 2. T2-weighted sagittal MRI of thoracolumbar spine of a dog with kyphoscoliosis.** In case of kyphoscoliosis, the disc adjacent to the malformation exhibits early degeneration, as observed with a decreased MRI T2 signal (blue star), which is adjacent to a malformed vertebra inducing kyphoscoliosis (white arrow).

increased mechanical stress on the spine, resulting in disc abnormalities and subsequent degeneration. From this premise, models of bipedal mice and rats have been developed to increase gravity loading in the lumbar spine by means of forelimb clipping or amputation (Cassidy *et al.*, 1988; Higuchi *et al.*, 1983). Bipedalism has sometimes been associated with pinealectomy (Machida *et al.*, 2005). Although ethically questionable, these models have initially shown that age-related disc degeneration accelerates in mice (Higuchi *et al.*, 1983), with replacement of notochordal cells by nucleopulpyocytes in the NP. Nevertheless, although it has been hypothesised that bipedalism may cause an increase in the time spent in the erect posture, it has been shown that bipedal rats spend less time in the erect posture than their quadruped equals (Bailey *et al.*, 2001). Therefore, the origin of disc degeneration in the models remains disputed. These models, for obvious ethical considerations, are no longer used.

#### *Mechanical models – compression*

Compression is thought to play a pivotal role in DDD. Indeed, compression of the IVD increases pressure in the NP, associated with tension in the AF. When stress applied to the IVD exceeds the swelling pressure, fluid leakage from the IVD is observed, with redistribution of compression to the AF. Moreover, excessive spinal loading is responsible for notochordal cell death and production of type II collagen and aggrecan in the NP and activation of proteolytic enzymes. Dynamic hydrostatic pressurisation induces maturation of notochordal cells in *ex vivo* porcine discs (Purmessur *et al.*, 2013c). Animal models have been developed to investigate the effects of different types of compression on disc health. Compression can be applied to the disc in two manners: static or cyclic. Static chronic compression has been applied to rat tails by means of bending (asymmetrical compression) or with an Ilizarov-type apparatus (Iatridis *et al.*, 1999). The effect of forceful bending was introduced in 1957 and was one of the first mechanical models of DDD (Lindblom, 1957). Lindblom fixed rat tails in bent shapes and, thus, induced degeneration of the AF on the concave side, with alteration of connective tissue and decreased cellularity correlated with the duration of the procedure. The same type of procedure was assessed in mice by applying forceful bending to the IVD between the coccygeal vertebrae for 1 week using an external device (Court *et al.*, 2001). Once again, DDD was objectivised by excessive mortality of cells in the AF and decreased aggrecan and type II collagen gene expression in the concave side. Symmetric compression induces a decrease in IVD height associated with a decrease in axial compliance and angular laxity (Iatridis *et al.*, 1999). A substantial decrease in total PG content is also observed in the caudal IVD of rats subjected to static compression, in association with disc thinning (Ching *et al.*, 2003; Ching *et al.*, 2004). Decreased notochordal cells,

with increased apoptotic cell death, are also present (Hirata *et al.*, 2014). This irreversible IVD thinning is also detected in rabbits and is associated with decreased cellularity in AF and CEP (Kroeber *et al.*, 2002). These results are confirmed by a gradual increase in MMP-3 in NP cells concomitantly with IVD degeneration, as observed by MRI (Yurube *et al.*, 2010). Downregulation of type II collagen and aggrecan in parallel with upregulation of MMP-3 and -13 is also observed in the bent rat-tail model (Xia *et al.*, 2018). In rabbits, the effects of a 28 d compression can be reversed by distraction (Kroeber *et al.*, 2005).

Caudal discs have also been subjected to a cyclical compression by means of a compression device set between two pins inserted in the caudal vertebral bodies of rats. The device delivers compressive stress at different frequencies and with different magnitudes and amplitudes (Ching *et al.*, 2003; Ching *et al.*, 2004). This system induces loss of IVD height with a response depending on the frequency of loading: the greatest effect is observed with static compression and the least effect in the 1.5 Hz group. Moreover, the effects of cyclic loading seem to be extended to adjacent levels. A murine tail model of dynamic loading confirmed the differential effects of dynamic loading depending on frequency and stress (Walsh and Lotz, 2004).

#### *Mechanical models – instability and immobilisation*

Instability models induce slow and progressive disc degeneration by allowing excessive movement of the spinal segment by means of surgical resection of tissues that maintain the rigidity of the spinal column (facet joints or spinous processes) or by stiffening the adjacent level through a fusion procedure. Overstimulation of spinal muscles and torsional injury have also been investigated. All these methods have the advantage of keeping the IVD intact and being close to the clinical condition. The degeneration initiates within 3-12 months, depending on the mechanism of instability and species. Many models have been investigated and are discussed below.

In a mouse model of surgical resection of spinous processes and associated ligaments as well as detachment of paravertebral muscles in cervical spine, mechanical instability was demonstrated. This, subsequently, induces accelerated IVD degeneration with decreased disc height, as confirmed by annular degradation with fibroblastic cell proliferation until fissures form and disruption occurs — even resulting in herniation and osteophytosis (Miyamoto *et al.*, 1991). Instability can also be achieved by facetectomy, *i.e.* unilateral or bilateral removal of a caudal articular process (facet) of a vertebra. In rabbits, facetectomy associated with torsional injury induces progressive DDD over a time course of 3 months. The disc narrowing is concomitant to an increase in phospholipase A2 content, reflecting inflammation, which is not observed with facetectomy alone (Hadjipavlou *et al.*, 1998). Facetectomy alone generates progressive IVD narrowing in the lumbar

spine of immature white rabbits (Sullivan *et al.*, 1971). The lesions observed are thinning of the posterior AF and disorganisation of the NP after 6 months. Instability seems to be less efficient in triggering DDD in the lumbar spine than in the cervical spine. Indeed, cervical spine curvature and musculature can increase the induced destabilisation. Nevertheless, in a mouse model of surgically induced instability (Oichi *et al.*, 2018), lumbar DDD has been evidenced as early as 2 weeks after surgery, with thinning of the IVD followed by osteophytosis, degeneration of NP and disorganisation of the AF within 12 weeks after resection of facet joints and supra- and interspinous ligaments.

Animal models using immobilisation of spinal segments have also been developed. Thus, vertebral fusion (arthrodesis) allows immobilisation of one spinal segment and causes stress at the adjacent sections. Immobilisation-induced DDD has also been achieved by means of pedicle screw and rod implantation in models as large as sheep (Wang *et al.*, 2018). In rabbits, lumbar fusion induces gradual DDD in adjacent treated IVDs and disc space narrowing, as evidenced by radiography (Phillips *et al.*, 2002). The authors described a progressive replacement of notochordal cells in the NP and proliferation of NP cells, a decrease in PG fibre length and fibrosis of the disc. The lesions are observed within 3 months following spine fusion. Osteophytosis and endplate sclerosis are also observed. IVD degeneration induced by fusion has also been studied in dogs (Bushell *et al.*, 1978; Taylor *et al.*, 1976). In immature beagles, fusion induced a decrease in collagen content in fused and adjacent IVDs, but it failed to produce DDD in adult greyhounds; the latter typically present notochordal cells in the healthy IVD.

#### *Structural models*

Structural models trigger DDD impairing the structural integrity of the IVD through a direct injury or a chemical alteration of the IVD or its adjacent structures such as the endplates. All these models require direct physical access to the IVD to reach AF, NP or endplates. Therefore, different ways to approach the IVD have been investigated and the surgical approaches may differ depending on the species-dependent anatomy. Initial approaches included a broad exposure of the lumbar spine with a ventral approach through a large laparotomy (Boxberger *et al.*, 2008; Sobajima *et al.*, 2005) or by lumbotomy with a retroperitoneal approach. The access is easy and facilitates the disc approach and visibility but the procedure requires surgical competence and, because of these large surgical wounds, high morbidity is present. The newest approaches are definitely less invasive and fluoroscopy has allowed the development of percutaneous methods (Kim *et al.*, 2015; Prologo *et al.*, 2012; Zhou *et al.*, 2013a). One of them is based on a percutaneous transannular access to the NP to trigger DDD through a simple puncture, aspiration,

enzyme injection or laser. This technique is painless and the least invasive. Moreover, the animal recovers quickly after surgery. Yet, it is not suitable for targeting the more caudal lumbar levels because the iliac bone covers the posterolateral part of the spine and hampers access to the disc space. More recently, a transpedicular approach has been described to target the NP without injuring the AF by means of a wire traveling in a vertebra through one of its pedicles and its caudal CEP (Vadalà *et al.*, 2013). This is inspired by methods used classically in spinal surgery for osteosynthesis (Ringel *et al.*, 2006) and cementoplasty (Galibert *et al.*, 1987; Taylor *et al.*, 2007) and has to be performed by well-trained surgeons. The size of the surgical approach rules out its use on the smallest animal species, reserving it for the largest, such as sheep and pigs (Le Fournier *et al.*, 2017; Vadalà *et al.*, 2018). This technique can also be used to explore IVD degeneration or as a route to inject treatments into the NP. The route through the vertebra and the endplate has to be filled after the procedure to limit the risk of leaking of the intradiscally injected materials or cells. This technique is attractive when inducing degeneration without damaging the AF. Nevertheless, it remains highly invasive and the risk of leakage of the regenerative treatment will probably limit its further use.

#### *Enzymatic models: chemonucleolysis*

Enzymatic nuclear alteration is defined as chemonucleolysis. It was initially considered as a clinical treatment for sciatica secondary to disc protrusion (Chicheportiche *et al.*, 1997). Chymopapain was the first enzyme used in 1964. It reduces disc volume by proteolytic digestion. Various enzymes have been tested in numerous models, including large ones such as dogs and pigs, in order to reproduce the selective degradation of PGs observed in disc degeneration. The enzyme is injected into the NP where it triggers dose-dependent degeneration. In the evaluation of regenerative strategies of the IVD, the most commonly used enzymes are chondroitinase ABC and chymopapain, which cause GAG degradation. Hyaluronidase is also regularly used (Antoniou *et al.*, 2006; Fusellier *et al.*, 2016). Conversely, collagenase damages collagen fibres (Antoniou *et al.*, 2006; Bromley *et al.*, 1980; Growney *et al.*, 2014; Spencer *et al.*, 1985; Stern and Coulson, 1976; Zook and Kobrine, 1986). Trypsin combines the two effects (Mwale *et al.*, 2008; Roberts *et al.*, 2008).

The effects of chymopapain have been investigated *in vivo* in rabbits (Gullbrand *et al.*, 2016; Kiester *et al.*, 1994), dogs (Atilola *et al.*, 1988; Bradford *et al.*, 1983; Kudo *et al.*, 1993; Lü *et al.*, 1997; Melrose *et al.*, 1996; Spencer *et al.*, 1985; Wakano *et al.*, 1983) and monkeys (Zook and Kobrine, 1986) and *ex vivo* in bovine disc explants (Chan *et al.*, 2013; Roberts *et al.*, 2008). Its proteolytic activity causes an *ex vivo* degeneration in the bovine disc explant model (Chan *et al.*, 2013). *In vivo*, it causes a quick decrease in PG content associated with a decrease in disc height

and deficiency in spine stability. The effect is due to a selective cleavage of the non-collagenous protein connections of PGs. It is dose-dependent and at low dosage, a restoration of PG content to near normal is observed over time; high doses cause more extensive and irreversible damage with AF disruption (Kiester *et al.*, 1994). Limited specificity of chymopapain is its principal drawback, acting on multiple ECM components, differently from the more specific chondroitinase ABC, hyaluronidase and collagenase (Lotz *et al.*, 2004; Sasaki *et al.*, 2001; Yamada *et al.*, 2001). Its use is currently uncommon.

Chondroitinase ABC induces dose-dependent DDD in animal models such as rats (Boxberger *et al.*, 2008; Norcross *et al.*, 2003), rabbits (Henderson *et al.*, 1991), sheep (Sasaki *et al.*, 2001), goats (Hoogendoorn *et al.*, 2007), monkeys (Sugimura *et al.*, 1996) and dogs (Fry *et al.*, 1991). Its action is mediated by a specific degradation of the chondroitin and dermatan sulphate side chains of the PGs. After intradiscal injection of chondroitinase ABC in the IVD, mild DDD can be observed by progressive disc space narrowing, decrease in intradiscal pressure (Fry *et al.*, 1991; Gullbrand *et al.*, 2017; Henderson *et al.*, 1991; Sasaki *et al.*, 2001), nuclear cellularity and PG content (Fry *et al.*, 1991; Norcross *et al.*, 2003) and biomechanical impairment, with an increased spine segment range of motion (Boxberger *et al.*, 2008; Gullbrand *et al.*, 2017). An increase in Pfirrmann grading as seen by MRI, indicative of degeneration, has also been reported (Gullbrand *et al.*, 2017).

Hyaluronidase, trypsin and collagenase are significantly less often used than chondroitinase in animal models of DDD. Although enzymatic methods seem appealing because they induce reproducible, gradual, measurable and controllable DDD, some of these enzymes are not spontaneously present in mammals and, thus, cannot induce disc damage mimicking the natural degenerative cascade.

#### *Physical models*

Physical models include numerous surgical injuries that can be induced on the IVD, such as incision of the AF, aspiration of the NP or endplate perforation. They are intended to mimic degeneration observed in humans because AF and CEP lesions are believed to play a pivotal role in disc degeneration. The lesion itself can be extensive or, on the contrary, minimal and trigger a cascade of cellular events that gradually lead to DDD, closer to the spontaneous phenomenon observed in human disc disease.

#### *Physical models – endplate injury*

Since the IVD is a bulky avascular structure, its nutrient supply diffuses up to the core of the disc axially from the CEP and radially through the AF (Travascio *et al.*, 2010; Urban *et al.*, 2004), with a greater contribution of the CEP route (Giers *et al.*, 2017; Naresh-Babu *et al.*, 2016). The diffusion through the AF is anisotropic and affected by compression. Diffusion decreases with ageing (Ibrahim *et al.*,

1995). CEP injuries have been identified as a possible trigger of DDD, mediated by limitation of nutrition and endplate sclerosis in humans (Benneker *et al.*, 2005; Bernick and Cailliet, 1982). CEP lesions can be mechanical (physical) or ischemic (*i.e.* induced by reduction of blood flow) and could mimic the degeneration process observed in human disease, with impaired subchondral bone vascularisation associated with slow degeneration, decreased cellularity and GAG content in NP, disorganised annular fibrocartilage lamellae and disc narrowing. These models have the advantage of keeping the AF intact. In a porcine model with perforations of the CEP made using a drill bit (Holm *et al.*, 2004) or a Kirschner wire (Cinotti *et al.*, 2005; Vadalà *et al.*, 2018), late DDD was induced and characterised by NP dehydration, a decrease in cell density in the outer AF, a decrease in PG as well as disorganisation of the nuclear gel-like structure and annular structure. Intradiscal pressure in the NP was minimised and the MRI signal decreased on T2-weighted images. The lesions progressed for 3-7 months and were related to the extent of CEP injury (Cinotti *et al.*, 2005). Blockade of the blood flow through the CEP can be achieved by injection of pingyangmycin or bleomycin in the vertebral subchondral bone. In rabbits, this procedure causes slowly progressive DDD, as confirmed by a decrease in IVD height and T2 signal within 3 months (Wei *et al.*, 2015). This model is also described in rhesus macaque (Wei *et al.*, 2014; Zhou *et al.*, 2013b). In contrast, in a canine model, such ischemic lesions and subsequent nutrition impairment, produced by injection of bone cement adjacent to CEPs, fail to induce degenerative changes up to 70 weeks (Hutton *et al.*, 2004). This could be related to the differences in CEP thickness among species. Indeed, distance between the core of the disc and the nearest blood supply can differ greatly, as can CEP porosity (Guehring *et al.*, 2009).

#### *Physical models – annulotomy*

Annulotomy is a surgical procedure consisting of laceration of the AF, a technique that was described for the first time in 1932 (Keyes and Compere, 1932). The lesions can be induced either ventrally or dorsolaterally to the disc and the more extensive lesions require a large surgical approach, making the procedure relatively invasive, especially in small animal models. Multiple lesions ranging from simple annular puncture with a needle (Hsieh *et al.*, 2009; Issy *et al.*, 2013; Kim *et al.*, 2005; Martin *et al.*, 2013; Masuda *et al.*, 2004; Michalek *et al.*, 2010; Sobajima *et al.*, 2005; Tian *et al.*, 2018) to extensive incision of the AF with a scalpel or drill bit (Kääpä *et al.*, 1994; Lipson and Muir, 1980; Lipson and Muir, 1981; Melrose *et al.*, 2002; Olsewski *et al.*, 1996; Osti *et al.*, 1990; Rousseau *et al.*, 2007; Schollum *et al.*, 2010; Zhang *et al.*, 2011) have been described. The annular puncture can easily be guided percutaneously by fluoroscopy or CT for rabbits (Chai *et al.*, 2016; Kim *et al.*, 2005) or larger animals and is less invasive (Zhou *et al.*, 2013b). The

method has been largely studied in rabbits (Kim *et al.*, 2015; Luo *et al.*, 2018; Masuda *et al.*, 2004; Sobajima *et al.*, 2005) but has also been investigated in mice (Martin *et al.*, 2013), rats (Hsieh *et al.*, 2009; Issy *et al.*, 2013; Rousseau *et al.*, 2007), dogs (Chen *et al.*, 2015), sheep (Freeman *et al.*, 2016), goats (Zhang *et al.*, 2011) and pigs (Kääpä *et al.*, 1994; Pfeiffer *et al.*, 1994). In rabbits, annular needle puncture has become popular because it is an easy and reproducible way to induce DDD. Nevertheless, the results depend on the extent of the lesion created: the larger the lesion the more severe the disc damage is and the earlier the degeneration takes place. Nevertheless, it is difficult to compare the efficacy and reproducibility of these different methods as the techniques described vary in width and depth, from partial-thickness annular injury to full-thickness annular stab with NP involvement. Therefore, a superficial incision or puncture leads to spontaneous healing of the AF with slow degeneration over weeks or months (Lipson and Muir, 1981; Osti *et al.*, 1990; Sobajima *et al.*, 2005; Zhang *et al.*, 2011). More extensive or deep lesions induce a very rapid degeneration with an increase in disc herniation or avulsion risk. In rabbit lumbar discs, blade laceration causes a quick narrowing of the disc and a blurry distinction between AF and NP as early as 1 week. The NP is replaced by a fibrotic tissue in 1 month. In sheep, an annular injury induces a decrease in disc height correlated with an increase in MRI Pfirrmann scoring and histological injury scoring (Freeman *et al.*, 2016). The outer AF can heal after partial-thickness ventral annulotomy 5 mm deep and the DDD progresses from outside to inside with centripetal lesions over several months (Osti *et al.*, 1990). The effects of annular lesions can be boosted by adjacent spinal fusion and subsequently increased mechanical stress. In pigs, annulotomy 13 mm deep leads to fibrous degeneration of the NP and partial destruction of the lamellar structure of the AF (Kääpä *et al.*, 1994).

In needle puncture models, the link between the diameter of the needle and the disc size has been evidenced, with a direct influence of gauge size on the extent of degeneration, with the larger needle inducing more severe lesions (Singh *et al.*, 2005). In mice, a puncture induces a significant DDD when the needle diameter/IVD height ratio exceeds 0.4. The rabbit lumbar disc puncture model has been extensively studied. The degeneration induced is reproducible and can be quantitatively assessed *in vivo* by radiographs and MRI (Sobajima *et al.*, 2005). The gross lesions are associated with replacement of notochordal cells by chondrocytic cells in the NP. The needle gauge must be selected carefully, considering that a 21-G needle does not induce measurable degeneration at 8 weeks (Masuda *et al.*, 2004). In contrast, when 16-G and 18-G needles are used, the decrease in disc height is slowly progressive and becomes apparent 2 weeks after injury (Masuda *et al.*, 2004). Contrary to annulotomy or nucleotomy, needle puncture produces very reproducible lesions,

inducing gradual and quite fast DDD (between 2 and 9 weeks in rabbits).

#### *Physical models – nuclear lesions*

Direct injuries to the NP are variable and include nucleotomy (aspiration of NP tissue) and heating or cryoinjury. Nucleotomy is the partial or complete aspiration of NP tissue commonly used for surgery of disc herniation and also used as an *in vivo* animal model of disc degeneration. By means of nuclear aspiration, the free space created within the NP is large enough to inject large volumes of cells with or without biomaterials. This technique is particularly useful in the context of assessing new cell-based therapeutic strategies (Acosta *et al.*, 2011; Ganey *et al.*, 2009; Sakai *et al.*, 2005; Serigano *et al.*, 2010; Vadalà *et al.*, 2015). The procedure consists of an NP aspiration with a 10 mL syringe (Kim *et al.*, 2015) through the AF (transannular approach) with an anterolateral approach guided fluoroscopically. This route triggers annular lesions that can alone be responsible for DDD and remains easy to perform and minimally invasive. On the contrary, the transpedicular approach allows preserving the AF integrity with the introduction of a wire in the caudal vertebra through the pedicle and the inferior endplate until it reaches the NP (Russo *et al.*, 2016; Vadalà *et al.*, 2013). Partial nucleotomy induces progressive DDD, as confirmed by MRI and histological analysis in ovine lumbar IVD (Guder *et al.*, 2009), Goettingen minipigs (Omlor *et al.*, 2009) and dogs (Bach *et al.*, 2018). In minipigs, DDD is also highlighted by a decrease in notochordal cell density and NP aggrecan content (Omlor *et al.*, 2009). While nucleotomy indeed induces DDD, size, depth and volume of the lesions are poorly reproducible. Nucleotomy can be complete (Vadalà *et al.*, 2015) or partial (Ganey *et al.*, 2009; Guder *et al.*, 2009; Omlor *et al.*, 2009; Sakai *et al.*, 2005; Serigano *et al.*, 2010). Moreover, the amount of aspirated NP is often not documented and quite difficult to control precisely (Kim *et al.*, 2005).

Laser is also a method derived from spinal surgery that has long been used for disc ablation (Dickey *et al.*, 1996). In addition, it has been employed to perform experimental nucleotomy (Sato *et al.*, 2003). A diode laser can be used to induce disc degeneration in rabbits (Lucas *et al.*, 2012). The lesions are demonstrated by X-ray, with a thinning of disc space, and on MRI, with a decrease in the T2-weighted signal. Degeneration of the NP ECM is confirmed by Boos scoring. This degeneration induced by laser is more progressive than aspiration-induced IVD degeneration (Lucas *et al.*, 2012) and chemonucleolysis (Fusellier *et al.*, 2016). Cryoinjury is based on cold-induced lesions applied with a cryoprobe. It has been described in a pig model and with a transpedicular approach, without AF lesions (Flouzat-Lachaniette *et al.*, 2018). Cryoinjury induces more severe lesions than AF lesions, as attested by more disc space narrowing, dehydration and higher histological scores (Flouzat-Lachaniette *et al.*, 2018).

### **How should the pertinent DDD model be selected? Strengths and limitations of the different models**

Choosing the most appropriate model is fundamental, because it will partly determine the relevance and quality of the results obtained. The model should reproduce the degenerative process that takes place in human DDD as faithfully as possible. Even more so, the model should recapitulate the cascade of events that relate to the research question posed.

#### **Choice of the model according to the research question**

Despite their limitations, animal models remain essential to improve the understanding of the disc physiopathology and to develop new therapies. The model must be selected primarily based on the question that needs to be answered. Indeed, the type of scientific study will guide the choice of all the model's criteria, such as persistence of notochordal cells, size of the IVD or mechanical properties.

#### *Genetic studies*

Numerous genes have been associated with DDD (Munir *et al.*, 2018). Ideally, the correlation between DDD and specific genes should be studied in human patients (Paassilta *et al.*, 2001). Indeed, these studies are not invasive, are cost-effective and can easily be conducted in large cohorts (Rajasekaran *et al.*, 2016). Nevertheless, spontaneous degeneration in humans is multifactorial. Therefore, the influence of specific genes on DDD is difficult to evaluate in large human populations. Transgenic animal models could make it possible to identify the main genes implicated in DDD. This is the objective of knockout models, such as *Col2a1* or *GDF8* knock-out mice (Hamrick *et al.*, 2003; Sahlman *et al.*, 2001). The main problem raised by these models is that they are developed for practical reasons in short-lifetime animals. Unfortunately, these species have notochordal cells throughout their life, which can influence DDD.

#### *Pathophysiology studies*

Understanding the mechanism that leads to human DDD requires a model that is as close as possible to spontaneous conditions in humans. Biomechanical factors are known to play a major role in triggering DDD and the significant roles of notochordal cell differentiation and apoptosis (Erwin *et al.*, 2011; Purmessur *et al.*, 2013c) as well as abnormal inflammatory factor secretion have also been clearly identified (Johnson *et al.*, 2015; Phillips *et al.*, 2015; Purmessur *et al.*, 2013b; Risbud and Shapiro, 2014). This major role of notochordal cells in DDD theoretically eliminates the use of species with persistence of notochordal cells in adulthood or with different enzymatic complexes, such as rodents and pigs. Nevertheless, even in these species, notochordal cells can decline in response to adequate initiating factors, including load (Purmessur *et al.*, 2013c),



osmolality (Spillekom *et al.*, 2014) and oxygen levels (Omlor *et al.*, 2014), making them relevant. The effect of mechanical stress can be explored by mechanical models, but the age of the animals should be taken into account. Indeed, isolated cells from old subjects are more susceptible to degenerative changes than cells of younger subjects when subjected to dynamic loading, as demonstrated in pigs (Cho *et al.*, 2011). The fact that most models rely on a triggering factor that is far from what is observed in spontaneous DDD is a major drawback. Indeed, annular puncture (Luo *et al.*, 2018), enzymatic injury (Fusellier *et al.*, 2016) and nucleotomy (Acosta *et al.*, 2011; Kim *et al.*, 2015) do not reproduce the pathological process. Moreover, most of the models present an acute onset of DDD, whereas DDD is a slowly progressive disease. In this context, according to the authors, two types of models seem the most appropriate to study physiology and senescence of the IVD: spontaneous models (Bergknut *et al.*, 2011; Choi *et al.*, 2018; Nisolle *et al.*, 2016; Ohnishi *et al.*, 2018) and mechanical models (dynamic or static loading or exercise) (Kroeber *et al.*, 2002; Puustjärvi *et al.*, 1994; Saamanen *et al.*, 1993), in absence of notochordal cells' persistence. Since the less invasive procedures induce a slower onset of degeneration, these models are time-consuming and, therefore, expensive. Of course, the best model remains the human degenerated disc itself, surgically removed, when available. In this context, an interesting model is the veterinary canine patient. Canine patients present with several clinical entities that relate to disc degeneration with herniation or protrusion with clear breed disposition, including cervical spondylomyelopathy, acute thoracolumbar disc herniation and LBP. Canine patients suffering clinical DDD are often represented in veterinary practice and owners are looking for new treatments. Owners are prone to take part in clinical trials studying the effect of novel and safe treatments as compared to the standard-of-care. Redundant surgical material can be employed for further research (including the herniated disc) and follow up can be conducted with similar read out parameters to humans, including questionnaires and longitudinal imaging.

#### *Therapeutic studies – gene therapy*

Performing gene therapy on discs during *ex vivo* culture is not relevant. Indeed, discs are largely avascular with low oxygen tension and low pH and this could alter the characteristics of the genetically modified cells, which may not survive after reimplantation in the complex environment of the IVD. However, direct *in vivo* gene transfer could be more efficient. Since gene transfer modifies the expression of the target cells and in the meantime can affect the metabolism of adjacent cells, the cellular composition of the treated disc is of great importance. However, testing gene therapy in discs with notochordal cells has little relevance because it cannot mimic the behaviour of cells present in the IVD at the time of the DDD.

#### *Therapeutic studies – surgical therapies*

Surgical treatments can be tested in all varieties of models. The animal's size has to be taken into account because some implants can be too large to be implanted. Larger animals are often preferred, even if biological disc implants have been evaluated in animals as small as rats (Gebhard *et al.*, 2010). Moreover, the anatomy of the model has to be close to the human anatomy, especially when evaluating surgical devices. Generally, implantable material devices such as interspinous devices or pedicle-screw-based stabilisation are tested in large species.

#### *Therapeutic studies – tissue engineering and cell-based therapies*

Tissue engineering for DDD aims at replacing the native NP by a cell-loaded natural or synthetic construct that needs to be tested successfully in animal models before proceeding to human studies. Biomaterials must restore biomechanical function of the NP and support reparative cells (exogenous or endogenous). As the biomaterials used have to replace the NP, they are mostly implanted after mechanical nucleotomy, which creates a cavity inside the NP. Nucleotomy can be performed after enzymatic degradation of the NP, but a high level of enzymes could result in decreased viability around the defect created (Vadalà *et al.*, 2015). Therefore, enzymatic models should be avoided if cells are associated with biomaterials. Moreover, enzymes could adversely affect stem cells of peripheral niches. Nucleotomy can be performed through the AF of the CEP. This transpedicular approach keeps the AF intact and must be preferred, because a larger amount of material can be injected without leakage from the AF.

When nucleotomy is not performed, injectable materials can be added to the degenerated NP, with the aim of keeping local cells and restoring their function. In this context, the environment in which the regenerative cells have to be implanted needs to be close to the environment of the human IVD to appropriately transpose the results obtained. Therefore, the model chosen must not present persistent notochordal cells. Indeed, it is important to ensure that the resident notochordal cells are not responsible for the regenerative effects instead of, or in combination with, the transplanted cells. Also, the disc of the model must be thick to reproduce the nutritional challenge of the human disc (low glucose supply, hypoxia, acidic and hypertonic environment). As such, larger animals are preferable to rodents with thin discs and persistence of notochordal cells.

#### *Therapeutic studies – endogenous-progenitor- and growth-factor-based therapy*

As an alternative to supplementation with exogenous cells, endogenous progenitors and growth factor strategies focus on activating endogenous progenitors to trigger self-repair by resident stem cells (Ma *et al.*, 2018) or to restore the balance of anabolic and

catabolic activities in the IVD. Enzymatic models of DDD must be avoided to test these therapies because they can affect the viability of resident cells (either nucleopulpyocytes or cells from niches). In addition, notochordal-cell-persistent models cannot reproduce the response of the human IVD to these therapies. Therefore, for these therapies, spontaneous models are more relevant.

### Outcomes measures

Measures that are performed to evaluate the evolution of degeneration or to assess the efficacy of a novel treatment being developed influence the choice of the model, as outcome measures may be technically limited by the size of the model and species-specific differences, all challenging the 3Rs rules (replacement, reduction, refinement).

Histological, cellular and molecular changes of the disc during the degeneration process can only be assessed *post mortem* (Keorochana *et al.*, 2010). The need for addressing the temporal changes of these outcome parameters results in increased numbers of animals and, hence, in increased global cost of the studies. Important tissue changes can be evidenced with conventional histological stains (haematoxylin and eosin, alcian blue-picricosirius red, Masson's trichrome, *etc.*), which can be used across species (Detiger *et al.*, 2014; Imanishi *et al.*, 2019; Paul *et al.*, 2018). However, distinction of cell populations in the NP may require specific biomarkers and specialised techniques to identify them (including immunohistochemistry, RTqPCR, proteomics, *etc.*) that may or may not be available in the intended animal model (de Campos *et al.*, 2016; Keorochana *et al.*, 2010; Roughley and Mort, 2012). As such, outlining the primary and secondary read-out parameters and taking them into account when choosing the appropriate animal model is recommended.

Follow-up, during several months, of the *in vivo* IVD changes can be performed using imaging procedures. These non-destructive imaging procedures allow to drastically reduce the number of sacrificed animals. Indeed, each animal can be used as its own control, thus improving the validity of statistical results. Among imaging procedures dedicated to IVD follow-up, X-ray, CT and MRI are particularly used. X-ray imaging can be applied to all animal models (Chai *et al.*, 2016; Fusellier *et al.*, 2016; Han *et al.*, 2008; Lai *et al.*, 2007; Lucas *et al.*, 2012; Takegami *et al.*, 2005) as its resolution is high. However, interest in this technique is limited as it only allows the detection of major abnormalities, including changes in disc height and osteophyte formation. CT and MRI can also be performed on all species but devices must be adapted to the size of the model as resolution varies greatly. CT allows measurement of IVD height and morphological description of vertebrae, CEP or lesions of bony structures (Colloca *et al.*, 2012; Vadalà *et al.*, 2013). Nevertheless, its use is limited when discrimination between AF and NP is needed, even if contrast-

enhancing techniques are deployed. CT remains of interest, notably for CT-guided surgical approach (Mackenzie *et al.*, 2014; Ohnishi *et al.*, 2016; Shi *et al.*, 2016; Wei *et al.*, 2015). MRI remains undoubtedly the best imaging tool to describe IVD morphology and allow evaluation of the DDD. A strong magnetic field is required to image small species such as mice or rats (Ohnishi *et al.*, 2016). The value of MRI is the excellent correlation it provides between biochemical and structural changes as well as improvement in the IVD MRI signal. Moreover, semi-quantitative evaluation (Pfirrmann 5-level grading) and more recent quantitative estimation (T2 relaxation time, T1 $\rho$  relaxation time, T2\* and apparent diffusion coefficient) of disc degeneration are possible. MRS is also used *in vivo* to assess PG and collagen content in IVD (Zuo *et al.*, 2013).

Behavioural assays could also improve our understanding of clinical DDD, by evaluating several parameters such as pain, quality of life or disability such as locomotor outcomes after degeneration. Indeed, pain is often the first symptom of DDD in humans (Park *et al.*, 2019) and in dogs, who also suffer clinical DDD with distinct clinical representation, depending on the breed (*i.e.* CD *vs.* NCD). Nevertheless, these read-out parameters require thorough observation of animal behaviour and adapted and specific pain scales adjusted to species in order to allow accurate and objective evaluation. These scales are well described in DDD rodent models (Lai *et al.*, 2015; Mosley *et al.*, 2017). In dogs, numerous techniques have been developed such as quality of life questionnaires, quantitative sensory testing, locomotor scoring systems and kinematic gait assessments (reviewed by Thompson *et al.*, 2018, specifically for the clinical representation of CD dogs). Furthermore, pain scales are available and have been employed in canine patients suffering DDD, including the modified Canine Brief Pain Inventory (Brown *et al.*, 2009), which was further modified and adapted for the chronic back pain canine patients (Suwankong *et al.*, 2007). By contrast, to the authors knowledge, specific pain scales usable for large mammals do not exist. In this context, most veterinary canine patients that suffer clinical entities related to DDD can already benefit from validated objective grids to assess pain and quality of life. Moreover, they can be carefully observed by owners trained for long time.

### Choice of IVD degeneration model

The choice of IVD degeneration model (spontaneous or induced) should follow several logical points, as discussed below. Some models can be used to answer multiple questions and studies can be performed in a block design, where more than one IVD is degenerated. Typically, these would involve 3 to 5 levels within the lumbar spine. These multi-level studies address ethical concerns as they reduce animal numbers employed and decrease experiments' cost. This is certainly true for large animal models

where multiple read-out parameters can be deduced from each single disc. However, how the different IVDs in multiple level studies may affect each other has yet to be studied. It is plausible that, in short-term studies, each IVD minimally influences the other discs, certainly considering intradiscal applications in moderate degeneration models. Nonetheless, paracrine effects of the interplay between disc and CEP cannot be excluded. As such, when choosing the appropriate model, the 3Rs need to be strongly implemented in the study design and compromises may have to be considered. A multi-level study may assist in screening among treatment strategies. Thereafter, further fine-tuning needs to be conducted for the separate primary read-out parameters in dedicated animal models.

#### *Spontaneous models*

Intuitively, spontaneous models of DDD seem particularly relevant because of their similarity to human degenerative disease. Moreover, they have been described in a wide variety of species from sand rats (Gruber *et al.*, 2002; Gruber *et al.*, 2006; Moskowitz *et al.*, 1990; Pokharna *et al.*, 1994; Tapp *et al.*, 2008; Ziv *et al.*, 1992) to non-human primates (Lauerma *et al.*, 1992; Nuckley *et al.*, 2008; Platenberg *et al.*, 2001), as well as rabbits (Clouet *et al.*, 2011; Leung *et al.*, 2008), dogs (Bergknut *et al.*, 2011; Bergknut *et al.*, 2012; Brisson, 2010; Cherrone *et al.*, 2004; Griffin *et al.*, 2009; Priester, 1976) and sheep (Nisolle *et al.*, 2016). Consequently, these models, which include species of different sizes, are compatible with a broad range of experimental protocols, notably those designed to evaluate surgical procedures related to regenerative strategies with injections into the NP. Genetic spontaneous models are likely more difficult to extrapolate to humans because of considerable species differences in the genes involved in DDD pathological processes.

Although of interest, these spontaneous models have limitations. Indeed, in animals as in humans, the progression of DDD is often long and unpredictable, with inconsistent onset. Moreover, this significantly increases the cost of the model because the number of animals required is larger and they have to be housed for a long time. Interestingly, client-owned dogs also suffer DDD that is very similar to clinical entities seen in humans at the level of clinical signs, diagnostics, therapeutic approaches, histology and biochemistry. As such, the inclusion of these dogs in veterinary clinical trials could be a valuable opportunity (Bach *et al.*, 2014; Thompson *et al.*, 2018).

#### *Experimental models – mechanical models*

Among mechanical models, those using postural changes, such as forced bipedalism, have to be ruled out given that they are no longer ethically acceptable because of the significant behavioural stress they induce. Instability and bending models induce a progressive DDD without any lesion of the AF and NP and they are, thus, presumed to closely mimic

human disc disease (Hadjipavlou *et al.*, 1998, Oichi *et al.*, 2018, Court *et al.*, 2001). Moreover, they can be applied to large animals. Therefore, they are a valuable *in vivo* model for exploration of the influence of mechanical stress on the IVD. Nevertheless, several drawbacks should be stressed: surgical procedures used to trigger mechanical stress (fusion, torsion, immobilisation) are extremely invasive and painful. The techniques require trained surgeons, expensive materials and fine-tuned analgesia to comply with the 3R principles. The progression of the degeneration is quite long and the onset is unpredictable and unreliable; therefore, the number of animals undergoing surgery must be increased. They remain ethically questionable regarding the pain level they induce even if pain management is systematically undertaken.

#### *Experimental models – structural models*

Among structural models, chemical models are well known to induce an imbalance in NP ECM homeostasis, notably to PG content, thereby inducing a reproducible and adjustable DDD. These models are easily transferable to all species and are cost-effective. Nevertheless, some limitations must be highlighted. First, chemonucleolysis causes intradiscal persistence of proteolytic enzymes and degradation factors with residual activities (Oegema *et al.*, 1992). All these factors are not free of cytotoxicity and could, thus, affect survival and behaviour of IVD resident cells or injected cells in the context of regenerative strategies. Secondly, the degeneration induced by enzyme injection is fast and does not completely reproduce the slow and naturally occurring DDD.

Interestingly, physical models have been developed in various and numerous species, even in the largest ones. They are relevant because AF lesions are believed to play a crucial role in triggering human DDD. Needle puncture is a reliable method with very reproducible lesions inducing gradual and quite fast DDD. This is not the case of annulotomy and nucleotomy, where lesions are less reproducible. Moreover, although AF lesions (incision or puncture) induce a degeneration quite close to spontaneous processes, nuclear aspiration is far from natural DDD and is a closer model of disc avulsion (separation), with the removal of cells and ECM from NP. Nucleotomy cannot serve as a pathogenic model of DDD. Nevertheless, it is widely used in experiments assessing regenerative therapeutics.

A final concern about the use of annular lesions is the possible leakage of injected cells or biomaterials through the AF aperture when the needle gauge is larger than 22-G (Wang *et al.*, 2007a). Keeping the AF intact using the transpedicular approach, for example, could be a useful alternative but the bone passage will need to be plugged to avoid backflow of NP tissue or injected substitute (Vadalà *et al.*, 2013). Nonetheless, the leakage observed in these models also simulated the possible implications of regenerative treatment strategies applied to human patients where the

AF is not intact. As such, regenerative strategies have evolved to develop biomaterials that have the propensity to be thermo-reversible and/or interact and adhere to the matrix component of the NP and, as such, prevent leakage of the injected therapeutic material (Schutgens *et al.*, 2015).

### Choice of animal species

The choice of the species should rationally be based on the presence of notochordal cells as well as size and anatomy of the IVD. Most particularly, the persistence of notochordal cells in the NP with ageing has to be taken into account because they appear to interact with surrounding cells, influencing their behaviour (Aguilar *et al.*, 1999). They have also been shown, in numerous studies, to exert regenerative and anti-inflammatory effects (reviewed by Bach *et al.*, 2014; Purmessur *et al.*, 2013a; Rodrigues-Pinto *et al.*, 2014). The interaction can be effective on native NP cells (nucleopulpcytes) but also on exogenous cells used during cell therapy treatment. Moreover, considering that notochordal cells exhibit progenitor cell characteristics (Sakai *et al.*, 2012), their presence could provide a bias in the interpretation of experimental results. There are examples where a regenerative treatment strategy is effective in a rabbit model, while it fails to show beneficial effects in a large animal model that lacks notochordal cells or even in human clinical trials (Sakai *et al.*, 2003). Therefore, the presence of notochordal cells in the selected animal model could be of interest for fundamental experiments exploring cellular behaviour during human disc maturation and the processes driving the disappearance of notochordal cells and their substitution by nucleopulpcytes with reduced regenerative capacities. Species lacking notochordal cells in adulthood are of greater relevance for (i) analysing IVD degenerative processes, especially spontaneous models of DDD with disease progression close to what is observed in humans, and (ii) testing the efficacy of regenerative biotherapies (cell-based, growth factors, biomaterials).

IVD size and height are also simple traits of the model, but they are crucial characteristics that have to be taken into account in the choice of the appropriate animal model. First, small discs preclude the use of some surgical procedures and require size adaptation of surgical ancillaries, which is extremely costly. Moreover, in the context of regenerative strategies, the volume of cells and/or biomaterials intradiscally injected is dependent on the size of the NP. For example, certain biomaterials may encounter technical challenges in terms of their injectability through small-gauge needles and small volumes, which are typically in the range of 1-2  $\mu\text{L}$  for mice and 10-20  $\mu\text{L}$  for rats. Nonetheless, small animal models are cost-effective and remain valuable for fundamental studies on the pathogenesis of DDD and screening of bioactives prior to translation towards large animal models. Importantly, the human disc is a large avascular structure and diffusion of nutrients

takes place primarily through the endplates. As such, disc height directly affects the nutritional environment (O'Connell *et al.*, 2007) and is, therefore, an important cofactor. Indeed, even though discs of rodents mimic the biomechanical properties observed in human discs, their small size limits the nutritional challenge observed in human discs. In terms of disc size, sheep, goats, pigs and cattle are considered the most appropriate and affordable experimental models. In particular, sheep and goats are widely used as DDD models, especially for spine surgery procedures, despite some anatomical differences (Benneker *et al.*, 2012; Wilke *et al.*, 1997; Zhang *et al.*, 2011).

To resume, in addition to the conditions described, when choosing the appropriate model, one must take into account many criteria:

- size of the animal, housing conditions and cost, as well as surgical procedures and biomechanics of the IVD;
- age of the animals: most often young animals are used because they are less expensive, but they are generally skeletally immature, with persistence of notochordal cells, a microenvironment very different from the one of the degenerated IVD;
- anatomy of spine and IVD;
- mechanical, histological and biochemical properties of the IVD: they should be as close as possible to those of human IVD before and after degeneration;
- time for the onset of degeneration;
- ethical aspects: each protocol has to be approved by an ethics committee;
- model itself: it must be standardised and must induce controllable, reproducible and cost-effective DDD. To reduce costs, time to onset of degeneration should be as short as possible.

### Conclusion

Ideally, the optimal *in vivo* model of DDD should induce a reproducible, measurable and controllable DDD and the degeneration process should mimic the histological and biomechanical features of the human disease. Unfortunately, all these criteria are not always met. First, the animal model chosen must not be species-driven and the selection of a degeneration model must precede the choice of animal species. Therefore, in almost all experiments, a spontaneous degeneration model should be preferred since it is the one that most closely matches human DDD. From this perspective, dogs, sheep and goats deserve attention because their IVD size is closer to that of humans. Ethical aspects and 3R rules have to be carefully considered to prevent the use of historical animal models of DDD (*i.e.* bipedal models) that did not always fulfil the 3R recommendations, notably regarding pain management in laboratory animals. However, the development of behavioural and pain evaluation provides new tools for

assessing and following both DDD and treatments. Notwithstanding, when employing canine patients in the translational chain, scientist needs to consider that, similarly to humans, canine patients present with multiple clinical entities of disc disease that differ in their therapeutic approach.

## References

- Accadbled F, Laffosse JM, Ambard D, Gomez-Brouchet A, De Gauzy JS, Swider P (2008) Influence of location, fluid flow direction, and tissue maturity on the macroscopic permeability of vertebral end plates. *Spine (Phila Pa 1976)* **33**: 612-619.
- Acosta FL, Metz L, Adkisson HD, Liu J, Carruthers-Liebenberg E, Milliman C, Maloney M, Lotz JC (2011) Porcine intervertebral disc repair using allogeneic juvenile articular chondrocytes or mesenchymal stem cells. *Tissue Eng Part A* **17**: 3045-3055.
- Adams MA, Roughley PJ (2006) What is intervertebral disc degeneration, and what causes it? *Spine (Phila Pa 1976)* **31**: 2151-2161.
- Adler JH, Schoenbaum M, Silberberg R (1983) Early onset of disk degeneration and spondylosis in sand rats (*Psammomys obesus*). *Vet Pathol* **20**: 13-22.
- Aguiar DJ, Johnson SL, Oegema TR (1999) Notochordal cells interact with nucleus pulposus cells: regulation of proteoglycan synthesis. *Exp Cell Res* **246**: 129-137.
- Alini M, Eisenstein SM, Ito K, Little C, Kettler AA, Masuda K, Melrose J, Ralphs J, Stokes I, Wilke HJ (2008) Are animal models useful for studying human disc disorders/degeneration? *Eur Spine J* **17**: 2-19.
- Allen KD, Griffin TM, Rodriguiz RM, Wetsel WC, Kraus VB, Huebner JL, Boyd LM, Setton LA (2009) Decreased physical function and increased pain sensitivity in mice deficient for type IX collagen. *Arthritis Rheum* **60**: 2684-2693.
- Amelot A, Mazel C (2018) The intervertebral disc: physiology and pathology of a brittle joint. *World Neurosurg* **120**: 265-273.
- Antoniou J, Mwale F, Demers CN, Beaudoin G, Goswami T, Aebi M, Alini M (2006) Quantitative magnetic resonance imaging of enzymatically induced degradation of the nucleus pulposus of intervertebral discs. *Spine (Phila Pa 1976)* **31**: 1547-1554.
- Antoniou J, Steffen T, Nelson F, Winterbottom N, Hollander AP, Poole RA, Aebi M, Alini M (1996) The human lumbar intervertebral disc: evidence for changes in the biosynthesis and denaturation of the extracellular matrix with growth, maturation, ageing, and degeneration. *J Clin Invest* **98**: 996-1003.
- Atilola MAO, Morgan JP, Bailey CS, Miyabayashi T (1988) Canine chemonucleolysis. *Vet Radiol* **29**: 168-175.
- Bach FC, Tellegen AR, Beukers M, Miranda-Bedate A, Teunissen M, de Jong WAM, de Vries SAH, Creemers LB, Benz K, Meij BP, Ito K, Tryfonidou MA (2018) Biologic canine and human intervertebral disc repair by notochordal cell-derived matrix: from bench towards bedside. *Oncotarget* **9**: 26507-26526.
- Bach FC, Zhang Y, Miranda-Bedate A, Verdonschot LC, Bergknut N, Creemers LB, Ito K, Sakai D, Chan D, Meij BP, Tryfonidou MA (2016) Increased caveolin-1 in intervertebral disc degeneration facilitates repair. *Arthritis Res Ther* **18**: 59. DOI:10.1186/s13075-016-0960-y.
- Bach FC, Willems N, Penning LC, Ito K, Meij BP, Tryfonidou Ma (2014) Potential regenerative treatment strategies for intervertebral disc degeneration in dogs. *BMC Vet Res* **10**: 3. DOI: 10.1186/1746-6148-10-3.
- Bailey AS, Adler F, Lai SM, Asher MA (2001) A comparison between bipedal and quadrupedal rats: do bipedal rats acutally assume an upright posture? *Spine (Phila Pa 1976)* **26**: 308-313.
- Beckstein JC, Sen S, Schaer TP, Vresilovic EJ, Elliott DM (2008) Comparison of animal discs used in disc research to human lumbar disc: axial compression mechanics and glycosaminoglycan content. *Spine (Phila Pa 1976)* **33**: E166-173.
- Benneker LM, Gisepp A, Krebs J, Boger A, Heini PF, Boner V (2012) Development of an *in vivo* experimental model for percutaneous vertebroplasty in sheep. *Vet Comp Orthop Traumatol* **25**: 173-177.
- Benneker LM, Heini PF, Alini M, Anderson SE, Ito K (2005) Vertebral endplate marrow contact channel occlusions and intervertebral disc degeneration. *Spine (Phila Pa 1976)* **30**: 167-173.
- Bergknut N, Auriemma E, Wijsman S, Voorhout G, Hagman R, Lagerstedt AS, Hazewinkel HAW, Meij BP (2011) Evaluation of intervertebral disk degeneration in chondrodystrophic and nonchondrodystrophic dogs by use of Pfirrmann grading of images obtained with low-field magnetic resonance imaging. *Am J Vet Res* **72**: 893-898.
- Bergknut N, Rutges JP, Kranenburg HJ, Smolders LA, Hagman R, Smidt HJ, Lagerstedt AS, Penning LC, Voorhout G, Hazewinkel HA, Grinwis GC, Creemers LB, Meij BP, Dhert WJ (2012) The dog as an animal model for intervertebral disc degeneration? *Spine (Phila Pa 1976)* **37**: 351-358.
- Bernick S, Cailliet R (1982) Vertebral end-plate changes with aging of human vertebrae. *Spine (Phila Pa 1976)* **7**: 97-102.
- Blanco G, Pritchard C, Underhill P, Breeds S, Townsend KMF, Greenfield A, Brown SDM (2004) Molecular phenotyping of the mouse ky mutant reveals UCP1 upregulation at the neuromuscular junctions of dystrophic soleus muscle. *Neuromuscul Disord* **14**: 217-228.
- Bowles RD, Gebhard HH, Dyke JP, Ballon DJ, Tomasino A, Cunningham ME, Härtl R, Bonassar LJ (2012) Image-based tissue engineering of a total intervertebral disc implant for restoration of function to the rat lumbar spine. *NMR Biomed* **25**: 443-451.
- Boxberger JI, Auerbach JD, Sen S, Elliott DM (2008) An *in vivo* model of reduced nucleus pulposus glycosaminoglycan content in the rat lumbar intervertebral disc. *Spine (Phila Pa 1976)* **33**: 146-154.

- Boyd LM, Richardson WJ, Allen KD, Flahiff C, Jing L, Li Y, Chen J, Setton LA (2008) Early-onset degeneration of the intervertebral disc and vertebral end plate in mice deficient in type IX collagen. *Arthritis Rheum* **58**: 164-171.
- Bradford DS, Cooper KM, Oegema Jr. TR (1983) Chymopapain, chemonucleolysis, and nucleus pulposus regeneration. *J Bone Jt Surg Am* **65**: 1220-1231.
- Brisson BA (2010) Intervertebral disc disease in dogs. *Vet Clin North Am Small Anim Pract* **40**: 829-858.
- Bromley JW, Hirst JW, Osman M, Steinlauf P, Gennace RE, Stern H (1980) Collagenase: an experimental study of intervertebral disc dissolution. *Spine (Phila Pa 1976)* **5**: 126-32.
- Brown DC, Boston R, Coyne JC, Farrar JT (2009) A novel approach to the use of animals in studies of pain: validation of the canine brief pain inventory in canine bone cancer. *Pain Med* **10**: 133-142.
- Brown EA, Dickinson PJ, Mansour T, Sturges BK, Aguilar M, Young AE, Korff C, Lind J, Ettinger CL, Varon S, Pollard R, Brown CT, Raudsepp T, Bannasch DL (2017) FGF4 retrogene on CFA12 is responsible for chondrodystrophy and intervertebral disc disease in dogs. *Proc Natl Acad Sci* **114**: 11476-11481.
- Bushell GR, Ghosh P, Taylor TKF, Sutherland JM, Braund KG (1978) The effect of spinal fusion on the collagen and proteoglycans of the canine intervertebral disc. *J Surg Res* **25**: 61-69.
- Busscher I, Ploegmakers JJW, Verkerke GJ, Veldhuizen AG (2010) Comparative anatomical dimensions of the complete human and porcine spine. *Eur Spine J* **19**: 1104-1114.
- Buttermann GR, Beaubien BP, Saeger LC (2009) Mature runt cow lumbar intradiscal pressures and motion segment biomechanics. *Spine J* **9**: 105-114.
- Cao Y, Liao S, Zeng H, Ni S, Tintani F, Hao Y, Wang L, Wu T, Lu H, Duan C, Hu J (2017) 3D characterization of morphological changes in the intervertebral disc and endplate during aging: a propagation phase contrast synchrotron microtomography study. *Sci Rep* **7**: 1-12.
- Casaroli G, Villa T, Galbusera F (2017) Finite element comparison between the human and the ovine lumbar intervertebral disc. *Muscles Ligaments Tendons J* **7**: 510-519.
- Cassidy JD, Yong-Hing K, Kirkaldy-Willis WH, Wilkinson AA (1988) A study of the effects of bipedism and upright posture on the lumbosacral spine and paravertebral muscles of the Wistar rat. *Spine (Phila Pa 1976)* **13**: 301-308.
- Chai JW, Kang HS, Lee JW, Kim SJ, Hong SH (2016) Quantitative analysis of disc degeneration using axial T2 mapping in a Percutaneous annular puncture model in rabbits. *Korean J Radiol* **17**: 103-110.
- Chan SC, Bürki A, Bonél HM, Benneker LM, Gantenbein-Ritter B (2013) Papain-induced *in vitro* disc degeneration model for the study of injectable nucleus pulposus therapy. *Spine J* **13**: 273-283.
- Chan WCW, Au TYK, Tam V, Cheah KSE, Chan D (2014) Coming together is a beginning: the making of an intervertebral disc. *Birth Defects Res C Embryo Today Rev* **102**: 83-100.
- Chen C, Jia Z, Han Z, Gu T, Li W, Li H, Tang Y, Wu J, Wang D, He Q, Ruan D (2015) Quantitative T2 relaxation time and magnetic transfer ratio predict endplate biochemical content of intervertebral disc degeneration in a canine model. *BMC Musculoskelet Disord* **16**: 157. DOI: 10.1186/s12891-015-0610-6.
- Cherrone KL, Dewey CW, Coates JR, Bergman RL (2004) A retrospective comparison of cervical intervertebral disk disease in nonchondrodystrophic large dogs *versus* small dogs. *J Am Anim Hosp Assoc* **40**: 316-320.
- Chicheportiche V, Parlier-Cuau C, Champsaur P, Laredo J-D (1997) Lumbar chymopapain chemonucleolysis. *Semin Musculoskelet Radiol* **1**: 197-206.
- Ching CTS, Chow DHK, Yao FYD, Holmes AD (2003) The effect of cyclic compression on the mechanical properties of the inter-vertebral disc: an *in vivo* study in a rat tail model. *Clin Biomech* **18**: 182-189.
- Ching CTS, Chow DHK, Yao FYD, Holmes AD (2004) Changes in nuclear composition following cyclic compression of the intervertebral disc in an *in vivo* rat-tail model. *Med Eng Phys* **26**: 587-594.
- Cho H, Seth A, Warmbold J, Robertson JT, Hasty KA (2011) Aging affects response to cyclic tensile stretch: paradigm for intervertebral disc degeneration. *Eur Cell Mater* **22**: 137-146.
- Choi H, Tessier S, Silagi ES, Kyada R, Yousefi F, Pleshko N, Shapiro IM, Risbud MV (2018) A novel mouse model of intervertebral disc degeneration shows altered cell fate and matrix homeostasis. *Matrix Biol* **70**: 102-122.
- Choi KS, Cohn MJ, Harfe BD (2008) Identification of nucleus pulposus precursor cells and notochordal remnants in the mouse: implications for disk degeneration and chordoma formation. *Dev Dyn* **237**: 3953-3958.
- Choi W, Song S, Chae S, Ko S (2017) Comparison of the extent of degeneration among the normal disc, immobilized disc, and immobilized disc with an endplate fracture. *Clin Orthop Surg* **9**: 193-199.
- Cinotti G, Della Rocca C, Romeo S, Vittur F, Toffanin R, Trasimeni G (2005) Degenerative changes of porcine intervertebral disc induced by vertebral endplate injuries. *Spine (Phila Pa 1976)* **30**: 174-180.
- Clouet J, Pot-Vaucel M, Grimandi G, Masson M, Lesoeur J, Fella BH, Gauthier O, Fusellier M, Cherel Y, Maugars Y, Guicheux J, Vinatier C (2011) Characterization of the age-dependent intervertebral disc changes in rabbit by correlation between MRI, histology and gene expression. *BMC Musculoskelet Disord* **12**: 147. DOI:10.1186/1471-2474-12-147.
- Colloca CJ, Gunzburg R, Freeman BJ, Szpalski M, Afifi M, Moore RJ (2012) Biomechanical quantification of pathologic manipulable spinal lesions: an *in vivo* ovine model of spondylolysis and intervertebral disc

- degeneration. *J Manipulative Physiol Ther* **35**: 354-366.
- Colombier P, Camus A, Lescaudron L, Clouet J, Guicheux J (2014a) Intervertebral disc regeneration: a great challenge for tissue engineers. *Trends Biotechnol* **32**: 433-435.
- Colombier P, Clouet J, Hamel O, Lescaudron L, Guicheux J (2014b) The lumbar intervertebral disc: from embryonic development to degeneration. *Jt Bone Spine* **81**: 125-129.
- Colombini A, Lombardi G, Corsi MM, Banfi G (2008) Pathophysiology of the human intervertebral disc. *Int J Biochem Cell Biol* **40**: 837-842.
- Cotterill PC, Kostuik JP, D'Angelo G, Fernie GR, Maki BE (1986) An anatomical comparison of the human and bovine thoracolumbar spine. *J Orthop Res* **4**: 298-303.
- Court C, Colliou OK, Chin JR, Liebenberg E, Bradford DS, Lotz JC (2001) The effect of static *in vivo* bending on the murine intervertebral disc. *Spine J* **1**: 239-245.
- Daly C, Ghosh P, Jenkin G, Oehme D, Goldschlager T (2016) A review of animal models of intervertebral disc degeneration: pathophysiology, regeneration, and translation to the clinic. *Biomed Res Int* **2016**: 5952165. DOI:10.1155/2016/5952165.
- de Campos MF, de Oliveira CP, Neff CB, Correa OM de T, Pinhal MAS, Rodrigues LMR (2016) Studies of molecular changes in intervertebral disc degeneration in animal model. *Acta Ortop Bras* **24**: 16-21.
- Detiger SEL, Holewijn RM, Hoogendoorn RJW, van Royen BJ, Helder MN, Berger FH, Kuijer JPA, Smit TH (2014) MRI T2\* mapping correlates with biochemistry and histology in intervertebral disc degeneration in a large animal model. *Eur Spine J* **24**: 1935-1943.
- Dickey DT, Bartels KE, Henry GA, Stair EL, Schafer SA, Fry TR, Nordquist RE (1996) Use of the holmium yttrium aluminum garnet laser for percutaneous thoracolumbar intervertebral disk ablation in dogs. *J Am Vet Med Assoc* **208**: 1263-1267.
- Elliott DM, Sarver JJ (2004) Young investigator award winner: validation of the mouse and rat disc as mechanical models of the human lumbar disc. *Spine* **29**: 713-722.
- Erwin WM, Islam D, Inman RD, Fehlings MG, Tsui FWL (2011) Notochordal cells protect nucleus pulposus cells from degradation and apoptosis: implications for the mechanisms of intervertebral disc degeneration. *Arthritis Res Ther* **13**: R215. DOI: 10.1186/ar3548.
- Faller K, Penderis J, Stalin C, Guevar J, Yeamans C, Gutierrez-Quintana R (2014) The effect of kyphoscoliosis on intervertebral disc degeneration in dogs. *Vet J* **200**: 449-451.
- Feng Y, Egan B, Wang J (2016) Genetic factors in intervertebral disc degeneration. *Genes Dis* **3**: 178-85.
- Flouzat-Lachaniette C-H, Jullien N, Bouthors C, Beohou E, Laurent B, Bierling P, Dubory A, Rouard H (2018) A novel *in vivo* porcine model of intervertebral disc degeneration induced by cryoinjury. *Int Orthop* **42**: 2263-2272.
- Le Fournier L, Fusellier M, Halgand B, Lesoeur J, Gauthier O, Menei P, Montero-Menei C, Guicheux J, Clouet J (2017) The transpedicular surgical approach for the development of intervertebral disc targeting regenerative strategies in an ovine model. *Eur Spine J* **26**: 2072-2083.
- Freeman BJC, Kuliwaba JS, Jones CF, Shu CC, Colloca CJ, Zarrinkalam MR, Mulaibrahimovic A, Gronthos S, Zannettino ACW, Howell S (2016) Allogeneic mesenchymal stem cells promote healing in postero-lateral annular lesions and improve indices of lumbar intervertebral disc degeneration in an ovine model. *Spine (Phila Pa 1976)* **41**: 1331-1339.
- Fry TR, Eurell JC, Johnson a L, Brown MD, Losonsky JM, Schaeffer DJ (1991) Radiographic and histologic effects of chondroitinase ABC on normal canine lumbar intervertebral disc. *Spine (Phila Pa 1976)* **16**: 816-819.
- Fusellier M, Colombier P, Lesoeur J, Youl S, Madec S, Gauthier O, Hamel O, Guicheux J, Clouet J (2016) Longitudinal comparison of enzyme- and laser-treated intervertebral disc by MRI, X-ray, and histological analyses reveals discrepancies in the progression of disc degeneration: a rabbit study. *Biomed Res Int* **2016**: 5498271. DOI: 10.1155/2016/5498271.
- Galibert P, Deramond H, Rosat P, Le Gars D (1987) [Preliminary note on the treatment of vertebral angioma by percutaneous acrylic vertebroplasty]. *Neurochirurgie* **33**: 166-168.
- Ganey T, Hutton WC, Moseley T, Hedrick M, Meisel H-J (2009) Intervertebral disc repair using adipose tissue-derived stem and regenerative cells: experiments in a canine model. *Spine (Phila Pa 1976)* **34**: 2297-2304.
- Gantenbein B, Illien-Jünger S, Chan SC, Walser J, Haglund L, Ferguson SJ, Iatridis JC, Grad S (2015) Organ culture bioreactors - platforms to study human intervertebral disc degeneration and regenerative therapy. *Curr Stem Cell Res Ther* **10**: 339-352.
- Gebhard H, Bowles R, Dyke J, Saleh T, Doty S, Bonassar L, Härtl R (2010) Total disc replacement using a tissue-engineered intervertebral disc *in vivo*: new animal model and initial results. *Evid Based Spine Care J* **1**: 62-66.
- Giers MB, Munter BT, Eyster KJ, Ide GD, Newcomb AGUS, Lehrman JN, Belykh E, Byvaltsev VA, Kelly BP, Preul MC, Theodore N (2017) Biomechanical and endplate effects on nutrient transport in the intervertebral disc. *World Neurosurg* **99**: 395-402.
- Gower WE, Pedrini V (1969) Age-related variations in proteinopolysaccharides from human nucleus pulposus, annulus fibrosus, and costal cartilage. *J Bone Joint Surg Am* **51**: 1154-1162.
- Griffin JF, Levine J, Kerwin S, Cole R (2009) Canine thoracolumbar intervertebral disk disease: diagnosis, prognosis, and treatment. *Compend Contin Educ Vet* **31**: E3.
- Grignon B, Grignon Y, Mainard D, Braun M, Netter P, Roland J (2000) The structure of the

cartilaginous end-plates in elder people. *Surg Radiol Anat* **22**: 13-19.

Growney EA, Sell SA, Bledsoe JG (2014) Developing a mechanical and chemical model of degeneration in young bovine lumbar intervertebral disks and reversing loss in mechanical function. *J Spinal Disord Tech* **27**: E168-175.

Gruber HE, Ingram J a, Hanley EN (2006) Immunolocalization of thrombospondin in the human and sand rat intervertebral disc. *Spine (Phila Pa 1976)* **31**: 2556-2561.

Gruber HE, Johnson TL, Leslie K, Ingram JA, Martin D, Hoelscher G, Banks D, Phieffer L, Coldham G, Hanley EN (2002) Autologous intervertebral disc cell implantation: a model using *Psammomys obesus*, the sand rat. *Spine (Phila Pa 1976)* **27**: 1626-1633.

Guder E, Hill S, Kandziora F, Schnake KJ (2009) Partial nucleotomy of the ovine disc as an *in vivo* model for disc degeneration. *Z Orthop Unfall* **147**: 52-58.

Guehring T, Wilde G, Sumner M, Grünhagen T, Karney GB, Tirlapur UK, Urban JPG (2009) Notochordal intervertebral disc cells: sensitivity to nutrient deprivation. *Arthritis Rheum* **60**: 1026-1034.

Gullbrand SEE, Malhotra NRR, Schaer TPP, Zawacki Z, Martin JTT, Bendigo JRR, Milby AHH, Dodge GRR, Vresilovic EJJ, Elliott DMM, Mauck RLL, Smith LJJ (2017) A large animal model that recapitulates the spectrum of human intervertebral disc degeneration. *Osteoarthritis Cartilage* **25**: 146-156.

Gullbrand SE, Ashinsky BG, Martin JT, Pickup S, Smith LJ, Mauck RL, Smith HE (2016) Correlations between quantitative T2 and T1 $\rho$  MRI, mechanical properties and biochemical composition in a rabbit lumbar intervertebral disc degeneration model. *J Orthop Res* **34**: 1-25.

Gutierrez-Quintana R, Guevar J, Stalin C, Faller K, Yeamans C, Penderis J (2014) A proposed radiographic classification scheme for congenital thoracic vertebral malformations in brachycephalic "screw-tailed" dog breeds. *Vet Radiol Ultrasound* **55**: 585-591.

Hadjipavlou AG, Simmons JW, Yang JP, Bi LX, Ansari GA, Kaphalia BS, Simmons DJ, Nicodemus CL, Necessary JT, Lane R, Esch O (1998) Torsional injury resulting in disc degeneration: I. An *in vivo* rabbit model. *J Spinal Disord* **11**: 312-317.

Hammer RE, Maika SD, Richardson JA, Tang JP, Taurog JD (1990) Spontaneous inflammatory disease in transgenic rats expressing HLA-B27 and human  $\beta$ 2m: an animal model of HLA-B27-associated human disorders. *Cell* **63**: 1099-1112.

Hamrick MW, Pennington C, Byron CD (2003) Bone architecture and disc degeneration in the lumbar spine of mice lacking GDF-8 (myostatin). *J Orthop Res* **21**: 1025-1032.

Han B, Zhu K, Li F-CC, Xiao Y-XX, Feng J, Shi Z-LL, Lin M, Wang J, Chen Q-XX (2008) A simple disc degeneration model induced by percutaneous

needle puncture in the rat tail. *Spine (Phila Pa 1976)* **33**: 1925-1934.

Hansen T, Smolders LA, Tryfonidou MA, Rn B, Meij P, Vernooij JCM, Bergknut N, Grinwis GCM (2017) The Myth of fibroid degeneration in the canine intervertebral disc: a histopathological comparison of intervertebral disc degeneration in chondrodystrophic and nonchondrodystrophic dogs. *Vet Pathol* **54**: 945-952.

Henderson N, Stanescu V, Cauchoix J (1991) Nucleolysis of the rabbit intervertebral disc using chondroitinase ABC. *Spine (Phila Pa 1976)* **16**: 203-208.

Henry N, Clouet J, Le Bideau J, Le Visage C, Guicheux J (2018) Innovative strategies for intervertebral disc regenerative medicine: from cell therapies to multiscale delivery systems. *Biotechnol Adv* **36**: 281-294.

Higuchi M, Abe K, Kaneda K (1983) Changes in the nucleus pulposus of the intervertebral disc in bipedal mice. *Clin Orthop Relat Res* **175**: 251-257.

Hirata H, Yurube T, Kakutani K, Maeno K, Takada T, Yamamoto J, Kurakawa T, Akisue T, Kuroda R, Kurosaka M, Nishida K (2014) A rat tail temporary static compression model reproduces different stages of intervertebral disc degeneration with decreased notochordal cell phenotype. *J Orthop Res* **32**: 455-463.

Holm S, Holm AK, Ekström L, Karladani A, Hansson T (2004) Experimental disc degeneration due to endplate injury. *J Spinal Disord Tech* **17**: 64-71.

Hoogendoorn RJW, Helder MN, Kroeze RJ, Bank R a, Smit TH, Wuisman PIJM (2008) Reproducible long-term disc degeneration in a large animal model. *Spine (Phila Pa 1976)* **33**: 949-954.

Hoogendoorn RJ, Wuisman PI, Smit TH, Everts VE, Helder MN (2007) Experimental intervertebral disc degeneration induced by chondroitinase ABC in the goat. *Spine (Phila Pa 1976)* **32**: 1816-1825.

Hsieh AH, Hwang D, Ryan D a, Freeman AK, Kim H (2009) Degenerative anular changes induced by puncture are associated with insufficiency of disc biomechanical function. *Spine (Phila Pa 1976)* **34**: 998-1005.

Hunter CJ, Matyas JR, Duncan NA (2004) Cytomorphology of notochordal and chondrocytic cells from the nucleus pulposus: a species comparison. *J Anat* **205**: 357-362.

Hutton WC, Murakami H, Li J, Elmer WA, Yoon ST, Minamide A, Akamaru T, Tomita K (2004) The effect of blocking a nutritional pathway to the intervertebral disc in the dog model. *J Spinal Disord Tech* **17**: 53-63.

Iatridis JC, Mente PL, Stokes IA, Aronsson DD, Alini M (1999) Compression-induced changes in intervertebral disc properties in a rat tail model. *Spine (Phila Pa 1976)* **24**: 996-1002.

Ibrahim MA, Houghton VM, Hyde JS (1995) Effect of disk maturation on diffusion of low-molecular-weight gadolinium complexes: an experimental study in rabbits. *Am J Neuroradiol* **16**: 1307-1311.



- Imanishi T, Akeda K, Murata K, Sudo A (2019) Effect of diminished flow in rabbit lumbar arteries on intervertebral disc matrix changes using MRI T2-mapping and histology. *BMC Musculoskelet Disord* **20**: 347. DOI: 10.1186/s12891-019-2721-y.
- Issy AC, Castania V, Castania M, Salmon CEG, Nogueira-Barbosa MH, Del Bel E, Defino HLA (2013) Experimental model of intervertebral disc degeneration by needle puncture in Wistar rats. *Brazilian J Med Biol Res* **46**: 235-244.
- Jaumard N V, Leung J, Gokhale AJ, Guarino BB, Welch WC, Winkelstein BA (2015) Relevant anatomic and morphological measurements of the rat spine: considerations for rodent models of human spine trauma. *Spine (Phila Pa 1976)* **40**: E1084-E1092.
- Johnson ZI, Schoepflin ZR, Choi H, Shapiro IM, Risbud M V (2015) Disc in flames : roles of TNF- $\alpha$  and IL-1 $\beta$  in intervertebral disc degeneration. *Eur Cells Mater* **30**: 104-117.
- Juneja SC, Vonica A, Zeiss C, Lezon-Geyda K, Yatsula B, Sell DR, Monnier VM, Lin S, Ardito T, Eyre D, Reynolds D, Yao Z, Awad HA, Yu H, Wilson M, Honnons S, Boyce BF, Xing L, Zhang Y, Perkins AS (2014) Deletion of *mecom* in mouse results in early-onset spinal deformity and osteopenia. *Bone* **60**: 148-161.
- Kääpä E, Holm S, Han X, Takala T, Kovanen V, Vanharanta H (1994) Collagens in the injured porcine intervertebral disc. *J Orthop Res* **12**: 93-102.
- Kalb S, Martirosyan NL, Kalani MYS, Broc GG, Theodore N (2012) Genetics of the degenerated intervertebral disc. *World Neurosurg* **77**: 491-501.
- Kasch R, Mensel B, Schmidt F, Drescher W, Pfuhl R, Ruetten S, Merk HR, Kayser R (2012) Percutaneous disc decompression with nucleoplasty-volumetry of the nucleus pulposus using ultrahigh-field MRI. *PLoS One* **7**: 1-8.
- Keorochana G, Johnson JS, Taghavi CE, Liao JC, Lee KB, Yoo JH, Ngo SS, Wang JC (2010) The effect of needle size inducing degeneration in the rat caudal disc: evaluation using radiograph, magnetic resonance imaging, histology, and immunohistochemistry. *Spine J* **10**: 1014-1023.
- Keyes DC, Compere EL (1932) The normal and pathological physiology of the nucleus pulposus of the intervertebral disc. *J Bone Jt Surg Am* **14**: 897-938.
- Kiester DP, Williams JM, Andersson GB, Thonar EJ, McNeill TW (1994) The dose-related effect of intradiscal chymopapain on rabbit intervertebral discs. *Spine (Phila Pa 1976)* **19**: 747-751.
- Kim DW, Chun H-J, Lee S-K (2015) Percutaneous needle puncture technique to create a rabbit model of traumatic degenerative disc disease. *World Neurosurg* **84**: 1-8.
- Kim KS, Yoon ST, Li J, Park JS, Hutton WC (2005) Disc degeneration in the rabbit: a biochemical and radiological comparison between four disc injury models. *Spine (Phila Pa 1976)* **30**: 33-37.
- Kimura T, Nakata K, Tsumaki N, Miyamoto S, Matsui Y, Ebara S, Ochi T (1996) Progressive degeneration of articular cartilage and intervertebral discs. An experimental study in transgenic mice bearing a type IX collagen mutation. *Int Orthop* **20**: 177-181.
- Kroeber M, Unglaub F, Guehring T, Guegring T, Nerlich A, Hadi T, Lotz J, Carstens C (2005) Effects of controlled dynamic disc distraction on degenerated intervertebral discs: an *in vivo* study on the rabbit lumbar spine model. *Spine (Phila Pa 1976)* **30**: 181-187.
- Kroeber MW, Unglaub F, Wang H, Schmid C, Thomsen M, Nerlich A, Richter W (2002) New *in vivo* animal model to create intervertebral disc degeneration and to investigate the effects of therapeutic strategies to stimulate disc regeneration. *Spine (Phila Pa 1976)* **27**: 2684-2690.
- Kudo T, Sumi A, Hashimoto A (1993) Experimental chemonucleolysis with chymopapain in canine intervertebral disks. *J Vet Med Sci* **55**: 211-215.
- Lai A, Chow DHK, Siu WS, Holmes AD, Tang FH (2007) Reliability of radiographic intervertebral disc height measurement for *in vivo* rat-tail model. *Med Eng Phys* **29**: 814-819.
- Lai A, Moon A, Purmessur D, Skovrlj B, Winkelstein BA, Cho SK, Hecht AC, Iatridis JC (2015) Assessment of functional and behavioral changes sensitive to painful disc degeneration. *J Orthop Res* **33**: 755-764.
- Lauerman W, Platenberg R, Cain J, Deeney V (1992) Age-related disk degeneration: preliminary report of a naturally occurring baboon model. *J Spinal Disord* **5**: 170-175.
- Leung VYL, Hung SC, Li LC, Wu EX, Luk KDK, Chan D, Cheung KMC (2008) Age-related degeneration of lumbar intervertebral discs in rabbits revealed by deuterium oxide-assisted MRI. *Osteoarthritis Cartilage* **16**: 1312-1318.
- Li X, Leo BM, Beck G, Balian G, Anderson DG (2004) Collagen and proteoglycan abnormalities in the GDF-5-deficient mice and molecular changes when treating disk cells with recombinant growth factor. *Spine (Phila Pa 1976)* **29**: 2229-2234.
- Li Z, Lezuo P, Pattappa G, Collin E, Alini M, Grad S, Peroglio M (2016) Development of an *ex vivo* cavity model to study repair strategies in loaded intervertebral discs. *Eur Spine J* **25**: 2898-2908.
- Lindblom K (1957) Intervertebral disc degeneration considered as a pressure atrophy. *J Bone Jt Surg* **39**: 933-945.
- Lipson SJ, Muir H (1980) Vertebral osteophyte formation in experimental disc degeneration. Morphologic and proteoglycan changes over time. *Arthritis Rheum* **23**: 319-324.
- Lipson SJ, Muir H (1981) Experimental intervertebral disc degeneration: morphologic and proteoglycan changes over time. *Arthritis Rheum* **24**: 12-21.
- Lotz JC (2004) Animal models of intervertebral disc degeneration lessons learned. *Spine (Phila Pa 1976)* **29**: 2742-2750.
- Lotz JC, Colliou OK, Chin JR, Duncan NA, Liebenberg E (1998) Compression-induced

- degeneration of the intervertebral disc: an *in vivo* mouse model and finite-element study. *Spine (Phila Pa 1976)* **23**: 2493-506.
- Lü DS, Shono Y, Oda I, Abumi K, Kaneda K (1997) Effects of chondroitinase ABC and chymopapain on spinal motion segment biomechanics. An *in vivo* biomechanical, radiologic, and histologic canine study. *Spine (Phila Pa 1976)* **22**: 182818-182835.
- Lucas O, Hamel O, Blanchais A, Lesoeur J, Abadie J, Fellah BH, Fusellier M, Gauthier O, Bord E, Grimandi G, Vinatier C, Guicheux J, Clouet J (2012) Laser-treated nucleus pulposus as an innovative model of intervertebral disc degeneration. *Exp Biol Med* **237**: 1359-1367.
- Luo TD, Marquez-Lara A, Zabarsky ZK, Vines JB, Mowry KC, Jinnah AH, Ma X, Berwick BW, Willey JS, Li Z, Smith TL, O'Gara TJ (2018) A percutaneous, minimally J *Orthop Surg* **26**: 1-8.
- Lyons G, Eisenstein S, Sweet M (1981) Biochemical changes in intervertebral disc degeneration. *Biochim Biophys Acta* **673**: 443-453.
- Ma K, Chen S, Li Z, Deng X, Huang D, Xiong L, Shao Z (2018) Mechanisms of endogenous repair failure during intervertebral disc degeneration. *Osteoarthritis Cartilage* **27**: 41-48.
- Machida M, Saito M, Dubousset J, Yamada T, Kimura J, Shibasaki K (2005) Pathological mechanism of idiopathic scoliosis: experimental scoliosis in pinealectomized rats. *Eur Spine J* **14**: 843-488.
- Mackenzie SD, Caswell JL, Brisson BA, Gaitero L, Chalmers HJ (2014) Comparison between computed tomography, fluoroscopy, and ultrasonography for guiding percutaneous injection of the canine intervertebral disc. *Vet Radiol Ultrasound* **55**: 571-581.
- Mageed M, Berner D, Jülke H, Hohaus C, Brehm W, Gerlach K (2013a) Is sheep lumbar spine a suitable alternative model for human spinal researches? Morphometrical comparison study. *Lab Anim Res* **29**: 183-189.
- Mageed M, Berner D, Jülke H, Hohaus C, Brehm W, Gerlach K (2013b) Morphometrical dimensions of the sheep thoracolumbar vertebrae as seen on digitised CT images. *Lab Anim Res* **29**: 138-147.
- Martin JT, Gorth DJ, Beattie EE, Harfe BD, Smith LJ, Elliott DM (2013) Needle puncture injury causes acute and long-term mechanical deficiency in a mouse model of intervertebral disc degeneration. *J Orthop Res* **31**: 1276-1282.
- Mason RM, Palfrey AJ (1984) Intervertebral disc degeneration in adult mice with hereditary kyphoscoliosis. *J Orthop Res* **2**: 333-338.
- Masuda K, Aota Y, Muehleman C, Imai Y, Okuma M, Thonar EJ, Andersson GB, An HS (2004) A novel rabbit model of mild, reproducible disc degeneration by an anulus needle puncture: correlation between the degree of disc injury and radiological and histological appearances of disc degeneration. *Spine (Phila Pa 1976)* **30**: 5-14.
- Melrose J, Taylor TK, Ghosh P, Holbert C, Macpherson C, Bellenger CR (1996) Intervertebral disc reconstitution after chemonucleolysis with chymopapain is dependent on dosage. *Spine (Phila Pa 1976)* **21**: 9-17.
- Melrose J, Roberts S, Smith S, Menage J, Ghosh P (2002) Increased nerve and blood vessel ingrowth associated with proteoglycan depletion in an ovine annular lesion model of experimental disc degeneration. *Spine (Phila Pa 1976)* **27**: 1278-1285.
- Miao J, Wang S, Wan Z, Park WM, Xia Q, Wood K, Li G (2013) Motion characteristics of the vertebral segments with lumbar degenerative spondylolisthesis in elderly patients. *Eur Spine J* **22**: 425-431.
- Michalek AJ, Funabashi KL, Iatridis JC (2010) Needle puncture injury of the rat intervertebral disc affects torsional and compressive biomechanics differently. *Eur Spine J* **19**: 2110-2116.
- Miyamoto S, Yonenobu K, Ono K (1991) Experimental cervical spondylosis in the mouse. *Spine (Phila Pa 1976)* **16**: S495-500.
- Monaco LA, Dewitte-Orr SJ, Gregory DE (2016) A comparison between porcine, ovine, and bovine intervertebral disc anatomy and single lamella annulus fibrosus tensile properties. *J Morphol* **277**: 244-251.
- Moskowitz RW, Ziv I, Denko CW, Boja B, Jones PK, Adler JH (1990) Spondylosis in sand rats: a model of intervertebral disc degeneration and hyperostosis. *J Orthop Res* **8**: 401-411.
- Mosley GE, Evashwick-Rogler TW, Lai A, Iatridis JC (2017) Looking beyond the intervertebral disc: the need for behavioral assays in models of discogenic pain. *Ann N Y Acad Sci* **1409**: 51-66.
- Munir S, Rade M, Määttä JH, Freidin MB, Williams FMK (2018) Intervertebral disc biology: genetic basis of disc degeneration. *Curr Mol Biol Rep* **4**: 143-150.
- Mwale F, Demers CN, Michalek AJ, Beaudoin G, Goswami T, Beckman L, Iatridis JC, Antoniou J (2008) Evaluation of quantitative magnetic resonance imaging, biochemical and mechanical properties of trypsin-treated intervertebral discs under physiological compression loading. *J Magn Reson Imaging* **27**: 563-573.
- Naresh-Babu J, Neelima G, Reshma Begum S, Siva-Leela V (2016) Diffusion characteristics of human annulus fibrosus-a study documenting the dependence of annulus fibrosus on end plate for diffusion. *Spine J* **16**: 1007-1014.
- Nisolle J, Bihin B, Kirschvink N, Neveu F, Clegg P, Dugdale A, Wang X, Vandeweerdt J (2016) Prevalence of age-related changes in ovine lumbar intervertebral discs during computed tomography and magnetic resonance imaging. *Comp Med* **66**: 300-307.
- Norcross JP, Lester GE, Weinhold P, Dahners LE (2003) An *in vivo* model of degenerative disc disease. *J Orthop Res* **21**: 183-188.
- Nuckley DJ, Kramer PA, Del Rosario A, Fabro N, Baran S, Ching RP (2008) Intervertebral disc degeneration in a naturally occurring primate model: radiographic and biomechanical evidence. *J Orthop Res* **26**: 1283-1288.

- O'Connell GD, Vresilovic EJ, Elliott DM (2007) Comparison of animals used in disc research to human lumbar disc geometry. *Spine* **32**: 328-333.
- Oegema T, Swedenberg S, Johnson S, Madison M, Bradford D (1992) Residual chymopapain activity after chemonucleolysis in normal intervertebral discs in dogs. *J Bone Jt Surg* **74**: 831-838.
- Ohnishi T, Sudo H, Iwasaki K, Tsujimoto T, Ito YM, Iwasaki N (2016) *In vivo* mouse intervertebral disc degeneration model based on a new histological classification. *PLoS One* **11**: e0160486. DOI: 10.1371/journal.pone.0160486.
- Ohnishi T, Sudo H, Tsujimoto T, Iwasaki N (2018) Age-related spontaneous lumbar intervertebral disc degeneration in a mouse model. *J Orthop Res* **36**: 224-232.
- Oichi T, Taniguchi Y, Soma K, Chang SH, Yano F, Tanaka S, Saito T (2018) A mouse intervertebral disc degeneration model by surgically induced instability. *Spine (Phila Pa 1976)* **43**: E557-E564.
- Olsewski JM, Schendel MJ, Wallace LJ, Ogilvie JW, Gundry CR (1996) Magnetic resonance imaging and biological changes in injured intervertebral discs under normal and increased mechanical demands. *Spine (Phila Pa 1976)* **21**: 1945-1951.
- Omlor GW, Nerlich AG, Tirlapur UK, Urban JP, Guehring T (2014) Loss of notochordal cell phenotype in 3D-cell cultures: implications for disc physiology and disc repair. *Arch Orthop Trauma Surg* **134**: 1673-1681.
- Omlor GW, Nerlich AG, Wilke H, Pfeiffer M, Lorenz H, Schaaf-keim M, Bertram H, Richter W, Carstens C, Guehring T (2009) A new porcine *in vivo* animal model of disc degeneration: response of annulus fibrosus cells, chondrocyte-like nucleus pulposus cells, and notochordal nucleus pulposus cells to partial nucleotomy. *Spine (Phila Pa 1976)* **34**: 2730-2739.
- Osti OL, Vernon-Roberts B, Fraser RD (1990) 1990 Volvo Award in Experimental Studies: Anulus tears and intervertebral disc degeneration: an experimental study using an animal model. *Spine (Phila Pa 1976)* **15**: 762-767.
- Paassilta P, Lohiniva J, Goring HH, Perala M, Raina SS, Karppinen J, Hakala M, Palm T, Kroger H, Kaitila I, Vanharanta H, Ott J, Ala-Kokko L (2001) Identification of a novel common genetic risk factor for lumbar disk disease. *JAMA* **285**: 1843-1849.
- Park EH, Moon SW, Suh HR, Hochman S, Lee M-G, Kim YI, Jang IT, Han HC (2019) Disc degeneration induces a mechano-sensitization of disc afferent nerve fibers that associates with low back pain. *Osteoarthritis Cartilage* **27**: 1608-1617.
- Parker HG, Vonholdt BM, Quignon P, Margulies EH, Mosher DS, Spady TC, Elkhouloun A, Cargill M, Paul G, Maslen CL, Acland GM, Sutter NB, Kuroki K, Bustamante D, Wayne RK, Ostrander EA (2009) An expressed *fgf4* retrogene is associated with breed-defining chondrodysplasia in domestic dogs. *Science* **325**: 995-998.
- Paul CPL, Smit TH, de Graaf M, Holewijn RM, Bisschop A, van de Ven PM, Mullender MG, Helder MN, Strijkers GJ (2018) Quantitative MRI in early intervertebral disc degeneration: T1rho correlates better than T2 and ADC with biomechanics, histology and matrix content. *PLoS One* **13**: e0191442. DOI: 10.1371/journal.pone.0191442.
- Pfeiffer M, Griss P, Franke P, Bornscheuer C, Orth J, Wilke a, Clausen JD (1994) Degeneration model of the porcine lumbar motion segment: effects of various intradiscal procedures. *Eur Spine J* **3**: 8-16.
- Phillips FM, Reuben J, Wetzel FT (2002) Intervertebral disc degeneration adjacent to a lumbar fusion. An experimental rabbit model. *J Bone Joint Surg Br* **84**: 289-294.
- Phillips KLE, Cullen K, Chiverton N, Michael ALR, Cole AA, Breakwell LM, Haddock G, Bunning RAD, Cross AK, Le Maitre CL (2015) Potential roles of cytokines and chemokines in human intervertebral disc degeneration: interleukin-1 is a master regulator of catabolic processes. *Osteoarthritis Cartilage* **23**: 1165-1177.
- Platenberg R, Hubbard GB, Ehler WJ, Hixson CJ (2001) Spontaneous disc degeneration in the baboon model: magnetic resonance imaging and histopathologic correlation. *J Med Primatol* **30**: 268-272.
- Pokharna HK, Boja B, Monnier V, Moskowitz RW (1994) Effect of age on pyridinoline and pentosidine matrix cross-links in the desert sand rat intervertebral disc. *Glycosylation Dis* **1**: 185-190.
- Priester WA (1976) Canine intervertebral disc disease – occurrence by age, breed, and sex among 8,117 cases. *Theriogenology* **6**: 293-303.
- Prologo JD, Pirasteh A, Tenley N, Yuan L, Corn D, Hart D, Love Z, Lazarus HM, Lee Z (2012) Percutaneous image-guided delivery for the transplantation of mesenchymal stem cells in the setting of degenerated intervertebral discs. *J Vasc Interv Radiol* **23**: 1084-1088.
- Purmessur D, Cornejo MC, Cho SK, Hecht AC, Iatridis JC (2013a) Notochordal cell-derived therapeutic strategies for discogenic back pain. *Glob Spine J* **3**: 201-217.
- Purmessur D, Walter BA, Roughley PJ, Laudier DM, Hecht AC, Iatridis J (2013b) A role for TNF $\alpha$  in intervertebral disc degeneration: a non-recoverable catabolic shift. *Biochem Biophys Res Commun* **433**: 151-156.
- Purmessur D, Guterl CC, Cho SK, Cornejo MC, Lam YW, Ballif BA, Laudier DM, Iatridis JC (2013c) Dynamic pressurization induces transition of notochordal cells to a mature phenotype while retaining production of important patterning ligands from development. *Arthritis Res Ther* **15**: R122. DOI: 10.1186/ar4302.
- Puustjärvi K, Lammi M, Helminen H, Inkinen R, Tammi M (1994) Proteoglycans in the intervertebral disc of young dogs following strenuous running exercise. *Connect Tissue Res* **30**: 225-240.

- Puustjarvi K, Lammi M, Kiviranta I, Helminen HJ, Tammi M (1993) Proteoglycan synthesis in canine intervertebral discs after long-distance running training. *J Orthop Res* **11**: 738-746.
- Rajasekaran S, Kanna RM, Reddy RR, Natesan S, Raveendran M, Cheung KMC, Chan D, Kao PYP, Yee A, Shetty AP (2016) How reliable are the reported genetic associations in disc degeneration? The influence of phenotypes, age, population size, and inclusion sequence in 809 patients. *Spine (Phila Pa 1976)* **41**: 1649-60.
- Reid JE, Meakin JR, Robins SP, Skakle JMS, Hukins DWL (2002) Sheep lumbar intervertebral discs as models for human discs. *Clin Biomech* **17**: 312-314.
- Reitmaier S, Schmidt H, Ihler R, Kocak T, Graf N, Ignatius A, Wilke HJ (2013) Preliminary investigations on intradiscal pressures during daily activities: an *in vivo* study using the merino sheep. *PLoS One* **8**: 1-10.
- Reitmaier S, Shirazi-Adl A, Bashkuev M, Wilke HJ, Gloria A, Schmidt H (2012) *In vitro* and *in silico* investigations of disc nucleus replacement. *J R Soc Interface* **9**: 1869-1879.
- Rhodes SD, Zhang W, Yang D, Yang H, Chen S, Wu X, Li X, Yang X, Mohammad KS, Guise TA, Bergner AL, Stevenson DA, Yang FC (2015) Dystrophic spinal deformities in a neurofibromatosis type 1 murine model. *PLoS One* **10**: e0119093. DOI: 10.1371/journal.pone.0119093.
- Ricci JA, Stewart WF, Chee E, Leotta C, Foley K, Hochberg MC (2006) Back pain exacerbations and lost productive time costs in United States workers. *Spine (Phila Pa 1976)* **31**: 3052-3060.
- Ringel F, Stoffel M, Stüer C, Meyer B (2006) Minimally invasive transmuscular pedicle screw fixation of the thoracic and lumbar spine. *Neurosurgery* **59**: ONS361-367.
- Risbud MV, Shapiro IM (2014) Role of cytokines in intervertebral disc degeneration: pain and disc content. *Nat Rev Rheumatol* **10**: 44-56.
- Roberts S, Caterson B, Menage J, Evans EH, Jaffray DC, Eisenstein SM (2000) Matrix metalloproteinases and aggrecanase: their role in disorders of the human intervertebral disc. *Spine (Phila Pa 1976)* **25**: 3005-3013.
- Roberts S, Menage J, Sivan S, Urban JPG (2008) Bovine explant model of degeneration of the intervertebral disc. *BMC Musculoskelet Disord* **9**: 24. DOI: 10.1186/1471-2474-9-24.
- Rodrigues-Pinto R, Richardson SM, Hoyland JA (2014) An understanding of intervertebral disc development, maturation and cell phenotype provides clues to direct cell-based tissue regeneration therapies for disc degeneration. *Eur Spine J* **23**: 1803-1814.
- Roughley PJ, Mort JS (2012) Analysis of aggrecan catabolism by immunoblotting and immunohistochemistry. *Methods Mol Biol* **836**: 219-237.
- Rousseau MA, Ulrich JA, Bass EC, Rodriguez AG, Liu JJ, Lotz JC (2007) Stab incision for inducing intervertebral disc degeneration in the rat. *Spine (Phila Pa 1976)* **32**: 17-24.
- Russo F, Hartman RA, Bell KM, Vo N, Sowa GA, Kang JD, Vadalà G, Denaro V (2016) Biomechanical evaluation of transpedicular nucleotomy with intact annulus fibrosus. *Spine (Phila Pa 1976)* **42**: 193-201.
- Saamanen AM, Puustjarvi K, Ilves K, Lammi M, Kiviranta I, Jurvelin J, Helminen HJ, Tammi M (1993) Effect of running exercise on proteoglycans and collagen content in the intervertebral disc of young dogs. *Int J Sport Med* **14**: 48-51.
- Sahlman J, Inkinen R, Hirvonen T, Lammi MJ, Lammi PE, Nieminen J, Lapveteläinen T, Prockop DJ, Arita M, Li SW, Hyttinen MM, Helminen HJ, Puustjärvi K (2001) Premature vertebral endplate ossification and mild disc degeneration in mice after inactivation of one allele belonging to the Col2a1 gene for type II collagen. *Spine (Phila Pa 1976)* **26**: 2558-2565.
- Sakai D, Mochida J, Iwashina T, Watanabe T, Nakai T, Ando K, Hotta T, Regeneration D (2005) Differentiation of mesenchymal stem cells transplanted to a rabbit degenerative disc model: potential and limitations for stem cell therapy in disc regeneration. *Spine (Phila Pa 1976)* **30**: 2379-2387.
- Sakai D, Mochida J, Yamamoto Y, Nomura T, Okuma M, Nishimura K, Nakai T, Ando K, Hotta T (2003) Transplantation of mesenchymal stem cells embedded in Atelocollagen® gel to the intervertebral disc: a potential therapeutic model for disc degeneration. *Biomaterials* **24**: 3531-3541.
- Sakai D, Nakamura Y, Nakai T, Mishima T, Kato S, Grad S, Alini M, Risbud M V, Chan D, Cheah KSE, Yamamura K, Masuda K, Okano H, Ando K, Mochida J (2012) Exhaustion of nucleus pulposus progenitor cells with ageing and degeneration of the intervertebral disc. *Nat Commun* **3**: 1264. DOI: 10.1038/ncomms2226.
- Sasaki M, Takahashi T, Miyahara K, Hirose aT (2001) Effects of chondroitinase ABC on intradiscal pressure in sheep: an *in vivo* study. *Spine (Phila Pa 1976)* **26**: 463-468.
- Sato M, Asazuma T, Ishihara M, Ishihara M, Kikuchi T, Kikuchi M, Fujikawa K (2003) An experimental study of the regeneration of the intervertebral disc with an allograft of cultured annulus fibrosus cells using a tissue-engineering method. *Spine (Phila Pa 1976)* **28**: 548-553.
- Schmidt H, Reitmaier S (2012) Is the ovine intervertebral disc a small human one? A finite element model study. *J Mech Behav Biomed Mater* **17**: 229-241.
- Schollum ML, Appleyard RC, Little CB, Melrose J (2010) A detailed microscopic examination of alterations in normal anular structure induced by mechanical destabilization in an ovine model of disc degeneration. *Spine (Phila Pa 1976)* **35**: 1965-1973.
- Schutgens EM, Tryfonidou MA, Smit TH, Cumhur Öner F, Krouwels A, Ito K, Creemers LB (2015) Biomaterials for intervertebral disc regeneration: past

- performance and possible future strategies. *Eur Cells Mater* **30**: 210-231.
- Serigano K, Sakai D, Hiyama A, Tamura F, Tanaka M, Mochida J (2010) Effect of cell number on mesenchymal stem cell transplantation in a canine disc degeneration model. *J Orthop Res* **28**: 1267-1275.
- Sheng SR, Wang XY, Xu HZ, Zhu GQ, Zhou YF (2010) Anatomy of large animal spines and its comparison to the human spine: a systematic review. *Eur Spine J* **19**: 46-56.
- Shi ZY, Gu T, Zhang C, Wang DL, He Q, Ruan DK (2016) Computed tomography-guided nucleus pulposus biopsy for canine intervertebral disc degeneration preparation: a radiology and histology study. *Spine J* **16**: 252-258.
- Showalter BL, Beckstein JC, Martin JT, Elizabeth E, Oriás AAE, Schaer TP, Edward J, Elliott DM (2013) Comparison of animal discs used in disc research to human lumbar disc : torsion mechanics and collagen content. *Spine (Phila Pa 1976)* **37**: 1-17.
- Silberberg R (1988) The vertebral column of diabetic sand rats (*Psammodromus obesus*). *Exp Cell Biol* **56**: 217-220.
- Singh K, Masuda K, An HS (2005) Animal models for human disc degeneration. *Spine J* **5**: 267S-279S.
- Smith LJ, Nerurkar NL, Choi K-S, Harfe BD, Elliott DM (2011) Degeneration and regeneration of the intervertebral disc: lessons from development. *Dis Model Mech* **4**: 31-41.
- Sobajima S, Kompel JF, Kim JS, Wallach CJ, Robertson DD, Vogt MT, Kang JD, Gilbertson LG (2005) A slowly progressive and reproducible animal model of intervertebral disc degeneration characterized by MRI, X-ray, and histology. *Spine (Phila Pa 1976)* **30**: 15-24.
- Solovieva S, Lohiniva J, Leino-Arjas P, Raininko R, Luoma K, Ala-Kokko L, Riihimäki H (2006) Intervertebral disc degeneration in relation to the COL9A3 and the IL-1 $\beta$  gene polymorphisms. *Eur Spine J* **15**: 613-619.
- Spencer DL, Miller JA, Schultz AB (1985) The effects of chemonucleolysis on the mechanical properties of the canine lumbar disc. *Spine (Phila Pa 1976)* **10**: 555-561.
- Spillekom S, Smolders LA, Grinwis GCM, Arkesteijn ITM, Ito K, Meij BP, Tryfonidou MA (2014) Increased osmolarity and cell clustering preserve canine notochordal cell phenotype in culture. *Tissue Eng Part C Methods* **20**: 652-662.
- Stern WE, Coulson WF (1976) Effects of collagenase upon the intervertebral disc in monkeys. *J Neurosurg* **44**: 32-44.
- Stevens JW, Kurriger GL, Carter AS, Maynard JA (2000) CD44 expression in the developing and growing rat intervertebral disc. *Dev Dyn* **219**: 381-390.
- Stokes I, Iatridis JC (2004) Mechanical conditions that accelerate intervertebral disc degeneration: overload *versus* immobilization. *Spine (Phila Pa 1976)* **29**: 2724-2732.
- Sugimura T, Kato F, Mimatsu K, Takenaka O, Iwata H (1996) Experimental chemonucleolysis with chondroitinase ABC in monkeys. *Spine (Phila Pa 1976)* **21**: 161-165.
- Sullivan J, Farfan H, Kahn D (1971) Pathologic changes with intervertebral joint rotational instability in the rabbit. *Can J Surg* **14**: 71-79.
- Suwankong N, Meij BP, Van Klaveren NJ, Van Wees AMTC, Meijer E, Van Den Brom WE, Hazewinkel HAW (2007) Assessment of decompressive surgery in dogs with degenerative lumbosacral stenosis using force plate analysis and questionnaires. *Vet Surg* **36**: 423-431.
- Sweet HO, Green MC (1981) Progressive ankylosis, a new skeletal mutation in the mouse. *J Hered* **72**: 87-93.
- Takahashi T, Kurihara H, Nakajima S, Kato T, Matsuzaka S, Sekiguchi T, Onaya M, Miyauchi S, Mizuno S, Horie K, Fujita Y, Hirose T (1996) Chemonucleolytic effects of chondroitinase ABC on normal rabbit intervertebral discs. Course of action up to 10 days postinjection and minimum effective dose. *Spine (Phila Pa 1976)* **21**: 2405-2411.
- Takegami K, An HS, Kumano F, Chiba K, Thonar EJ, Singh K, Masuda K (2005) Osteogenic protein-1 is most effective in stimulating nucleus pulposus and annulus fibrosus cells to repair their matrix after chondroitinase ABC-induced *in vitro* chemonucleolysis. *Spine J* **5**: 231-238.
- Tapp H, Deepe R, Ingram JA, Kuremsky M, Hanley EN, Gruber HE (2008) Adipose-derived mesenchymal stem cells from the sand rat: transforming growth factor beta and 3D co-culture with human disc cells stimulate proteoglycan and collagen type I rich extracellular matrix. *Arthritis Res Ther* **10**: R89. DOI:10.1186/ar2473.
- Taurog JD, Maika SD, Simmons WA, Breban M, Hammer RE (1993) Susceptibility to inflammatory disease in HLA-B27 transgenic rat lines correlates with the level of B27 expression. *J Immunol* **150**: 4168-4178.
- Taylor RS, Fritzell P, Taylor RJ (2007) Balloon kyphoplasty in the management of vertebral compression fractures: an updated systematic review and meta-analysis. *Eur Spine J* **16**: 1085-1100.
- Taylor TKF, Ghosh P, Braund KG, Sutherland JM, Sherwood AA (1976) The effect of spinal fusion on intervertebral disc composition: an experimental study. *J Surg Res* **21**: 91-104.
- Thompson K, Moore S, Tang S, Wiet M, Purmessur D (2018) The chondrodystrophic dog: a clinically relevant intermediate-sized animal model for the study of intervertebral disc-associated spinal pain. *JOR Spine* **1**: e1011. DOI:10.1002/jsp2.1011.
- Tian Z, Ma X, Yasen M, Mauck RL, Qin L, Shofer FS, Smith LJ, Pacifici M, Enomoto-Iwamoto M, Zhang Y (2018) Intervertebral disc degeneration in a percutaneous mouse tail injury model. *Am J Phys Med Rehabil* **97**: 170-177.
- Travascio F, Jackson A, Brown M, Gu WY (2010) Relationship between solute transport properties and tissue morphology in human annulus fibrosus. *J Orthop Res* **27**: 1625-1630.

- Urban JPG, Smith S, Fairbank JCT (2004) Nutrition of the intervertebral disc. *Spine (Phila Pa 1976)* **29**: 2700-2709.
- Vadalà G, Russo F, Pattappa G, Peroglio M, Stadelman V, Roughley P, Grad S, Alini M, Stadelmann VA, Roughley P, Grad S, Alini M, Denaro V (2015) A nucleotomy model with intact annulus fibrosus to test intervertebral disc regeneration strategies. *Tissue Eng Part C Methods* **21**: 1117-1124.
- Vadalà G, Russo F, Pattappa G, Schiuma D (2013) The transpedicular approach as an alternative route for intervertebral disc regeneration. *Spine (Phila Pa 1976)* **38**: 319-324.
- Vadalà G, Russo F, De Strobel F, Bernardini M, De Benedictis GM, Cattani C, Denaro L, D'Este M, Eglind D, Alini M, Denaro V (2018) Novel stepwise model of intervertebral disc degeneration with intact annulus fibrosus to test regeneration strategies. *J Orthop Res* **36**: 1-9.
- Vadalà G, De Strobel F, Bernardini M, Denaro L, D'Avella D, Denaro V (2013) The transpedicular approach for the study of intervertebral disc regeneration strategies: *in vivo* characterization. *Eur Spine J* **22**: 972-978.
- Venn G, Mason RM (1986) Changes in mouse intervertebral-disc proteoglycan synthesis with age. Hereditary kyphoscoliosis is associated with elevated synthesis. *Biochem J* **234**: 475-479.
- Vergroesen PPA, Kingma I, Emanuel KS, Hoogendoorn RJW, Welting TJ, van Royen BJ, van Dieën JH, Smit TH (2015) Mechanics and biology in intervertebral disc degeneration: a vicious circle. *Osteoarthritis Cartilage* **23**: 1057-1070.
- Vo N, Seo H-Y, Robinson A, Sowa G, Bentley D, Taylor L, Studer R, Usas A, Huard J, Alber S, Watkins SC, Lee J, Coehlo P, Wang D, Loppini M, Robbins P, Niedernhofer LJ, Kang J (2012) Accelerated aging of intervertebral discs in a mouse model of progeria. *J Orthop Res* **28**: 1600-1607.
- Wakano K, Kasman R, Chao EY, Bradford DS, Oegema TR (1983) Biomechanical analysis of canine intervertebral discs after chymopapain injection. A preliminary report. *Spine (Phila Pa 1976)* **8**: 59-68.
- Walsh AJL, Lotz JC (2004) Biological response of the intervertebral disc to dynamic loading. *J Biomech* **37**: 329-337.
- Wang JL, Tsai YC, Wang YH (2007a) The leakage pathway and effect of needle gauge on degree of disc injury post anular puncture: a comparative study using aged human and adolescent porcine discs. *Spine (Phila Pa 1976)* **32**: 1809-1815.
- Wang J, Tang T, Yang H, Yao X, Chen L, Liu W, Li T (2007b) The expression of Fas ligand on normal and stabbed-disc cells in a rabbit model of intervertebral disc degeneration: a possible pathogenesis. *J Neurosurg Spine* **6**: 425-430.
- Wang T, Pelletier MH, Christou C, Oliver R, Mobbs RJ, Walsh WR (2018) A novel *in vivo* large animal model of lumbar spinal joint degeneration. *Spine J* **18**: 1896-1909.
- Wang W, Nyman JS, Ono K, Stevenson DA, Yang X, Elefteriou F (2011) Mice lacking Nf1 in osteochondroprogenitor cells display skeletal dysplasia similar to patients with neurofibromatosis type I. *Hum Mol Genet* **20**: 3910-3924.
- Watanabe H, Yamada Y (2002) Chondrodysplasia of gene knockout mice for aggrecan and link protein. *Glycoconj J* **19**: 269-273.
- Watanabe T, Sakai D, Yamamoto Y, Iwashina T, Serigano K, Tamura F, Mochida J (2010) Human nucleus pulposus cells significantly enhanced biological properties in a coculture system with direct cell-to-cell contact with autologous mesenchymal stem cells. *J Orthop Res* **28**: 623-630.
- Wei F, Zhong R, Pan X, Khaleel M, Hammoud A, Zhou Z, Liu S, Sun H, Zhao Y, Zou X, Jiang B, Zhuang W, Chen N, Chen Y (2015) Computed tomography guided subendplate injection of pingyangmycin for a novel rabbit model of slowly progressive disc degeneration. *Spine J* **19**: e6-e18.
- Wei F, Zhong R, Zhou Z, Wang L, Pan X, Cui S, Zou X, Gao M, Sun H, Chen W, Liu S (2014) *In vivo* experimental intervertebral disc degeneration induced by bleomycin in the rhesus monkey. *BMC Musculoskelet Disord* **15**: 340. DOI: 10.1186/1471-2474-15-340.
- Wilke HJ, Kettler A, Wenger KH, Claes LE (1997) Anatomy of the sheep spine and its comparison to the human spine. *Anat Rec* **247**: 542-555.
- Wilke HJ, Rohlmann A, Neller S, Graichen F, Claes L, Bergmann G (2003) ISSLS Prize Winner: A novel approach to determine trunk muscle forces during flexion and extension. *Spine (Phila Pa 1976)* **28**: 2585-2593.
- Xia W, Zhang LL, Mo J, Zhang W, Li HT, Luo ZP, Yang HL (2018) Effect of static compression loads on intervertebral disc: an *in vivo* bent rat tail model. *Orthop Surg* **10**: 134-143. DOI: 10.1111/os.12377.
- Yamada K, Tanabe S, Ueno H, Oinuma A, Takahashi T, Miyauchi S, Shigeno S, Hirose T, Miyahara K, Sato M (2001) Investigation of the short-term effect of chemonucleolysis with chondroitinase ABC. *J Vet Med Sci* **63**: 521-525.
- Yurube T, Nishida K, Suzuki T, Kaneyama S, Zhang Z, Kakutani K, Maeno K, Takada T, Fujii M, Kurosaka M, Doita M (2010) Matrix metalloproteinase (MMP)-3 gene up-regulation in a rat tail compression loading-induced disc degeneration model. *J Orthop Res* **28**: 1026-1032.
- Zhang Y, Drapeau S, An HS, Markova D, Lenart BA, Anderson DG (2011) Histological features of the degenerating intervertebral disc in a goat disc-injury model. *Spine (Phila Pa 1976)* **36**: 1519-1527.
- Zhou RP, Zhang ZM, Wang L, Huang MJ, Zheng XC, Cui YN, Yin M, Wang XK, Yao NZ, Chen TY, Chen J, Bai XC, Jin D Di (2013a) Establishing a disc degeneration model using computed tomography-guided percutaneous puncture technique in the rabbit. *J Surg Res* **181**: e65-74.

Zhou ZZ, Jiang B, Zhou ZZ, Pan X, Sun H, Huang B, Liang T, Ringgaard S, Zou X (2013b) Intervertebral disk degeneration: T1 $\rho$  MR imaging of human and animal models. *Radiology* **268**: 492-500.

Ziran BH, Pineda S, Pokharna H, Esteki A, Mansour JM, Moskowitz RW (1994) Biomechanical, radiologic, and histopathologic correlations in the pathogenesis of experimental intervertebral disc disease. *Spine (Phila Pa 1976)* **19**: 2159-2163.

Ziv I, Moskowitz RW, Krause I, Adler JH, Maroudas A (1992) Physicochemical properties of the aging and diabetic sand rat intervertebral disc. *J Orthop Res* **10**: 205-210.

Zook BC, Koberne AI (1986) Effects of collagenase and chymopapain on spinal nerves and intervertebral

discs of cynomolgus monkeys. *J Neurosurg* **64**: 474-483.

Zuo J, Joseph GB, Li X, Link TM, Hu SS, Berven SH, Kurhanewicz J, Majumdar S, PhD1 (2013) *In-vivo* intervertebral disc characterization using magnetic resonance spectroscopy and T1 $\rho$  imaging: association with discography and Oswestry disability index and SF-36. *Spine (Phila Pa 1976)* **37**: 214-221.

**Editor's note:** All comments/questions by the reviewers were answered by making changes in the text. Hence, there is no Discussion with Reviewers section.

The Scientific Editor responsible for this paper was Mauro Alini.