



HAL
open science

Lateralization of the Vocal Fold: Results of an Exclusive Transoral Approach

Christol Fabre, Nathalie Henrich Bernardoni, Marie-Pierre Aboussouan, Paul Castellanos, Ihab Atallah

► **To cite this version:**

Christol Fabre, Nathalie Henrich Bernardoni, Marie-Pierre Aboussouan, Paul Castellanos, Ihab Atallah. Lateralization of the Vocal Fold: Results of an Exclusive Transoral Approach. *Journal of Voice*, 2019, 10.1016/j.jvoice.2019.11.009 . hal-02429707

HAL Id: hal-02429707

<https://hal.science/hal-02429707>

Submitted on 13 Jun 2023

HAL is a multi-disciplinary open access archive for the deposit and dissemination of scientific research documents, whether they are published or not. The documents may come from teaching and research institutions in France or abroad, or from public or private research centers.

L'archive ouverte pluridisciplinaire **HAL**, est destinée au dépôt et à la diffusion de documents scientifiques de niveau recherche, publiés ou non, émanant des établissements d'enseignement et de recherche français ou étrangers, des laboratoires publics ou privés.



Distributed under a Creative Commons Attribution - NonCommercial 4.0 International License

Lateralization of the vocal fold: results of an exclusive transoral approach

Christol Fabre, MD¹, Nathalie Henrich Bernardoni, PhD², Marie-Pierre Aboussouan, MD³,

Paul F. Castellanos, MD, FCCP^{4*}, Ihab Atallah, MD-PhD^{1, 5*}

Affiliation of authors:

- 1- Otolaryngology-Head & Neck Surgery Department, Grenoble Alpes University Hospital, BP 217, 38043 Grenoble Cedex 09, France
- 2- Grenoble Alpes University, CNRS, Grenoble INP, GIPSA-lab, 11 Rue des Mathématiques, 38400 Saint-Martin-d'Hères, France
- 3- Department of Anesthesiology and Intensive Care Medicine, Grenoble Alpes University Hospital, BP 217, 38043 Grenoble Cedex 09, France
- 4- Bangor, ME 04401-3073, USA
- 5- Grenoble Alpes University, School of Medicine, Domaine de la Merci, BP 170 La Tronche, 38042 Grenoble Cedex 9, France

* Both are senior authors for this manuscript

This work was presented in the meeting of American Laryngological Association at COSM 2019 (May 1-5 in Austin, TX, USA)

Conflict of interest: none

Abstract

Objective: Vocal fold paralysis in adduction can result in dyspnea. The authors have previously described an original vocal fold lateralization technique performed exclusively through an endoscopic approach. In this work, we studied long and short-term results of this procedure on dyspnea, phonation, and swallowing.

Study Design: Retrospective cohort study through data from medical records and operative notes. Patients with unilateral or bilateral vocal fold paralysis in adduction who underwent transoral lateralization were included.

Methods: In all patients, under laryngosuspension, a supraglottic laryngotomy was performed with CO₂ laser and a lateralization suture was passed through the thyroid cartilage to the vocal process of the vocal fold with the desired tension allowing lateralization of the arytenoid and corresponding vocal fold. We studied evolution of breathing, phonation and swallowing in all patients who underwent lateralization suture. We tried to correlate symptoms to preoperative and postoperative glottic area, inter-arytenoid distance, and anterior glottic angle.

Results: Eighteen patients were included in the study. Three patients were tracheostomy-dependent and were successfully decannulated. All other cases presented short and long-term significant improvement of their dyspnea index score ($p < 0.001$) in correlation with glottic area enlargement ($p < 0.001$). There was no statistical difference between preoperative and postoperative voice and swallowing parameters.

Conclusion: Our transoral lateralization technique allows enlargement of the glottic aperture in case of laryngeal dyspnea secondary to vocal fold paralysis in adduction. This technique optimally preserves laryngeal structures, especially the mucosa. It is reproducible and reliable for all laryngologists experienced in reconstructive transoral laser microsurgery.

Keywords: Vocal fold paralysis in adduction; vocal fold lateralization; arytenoidopexy; reconstructive transoral laser microsurgery; R-TLM, anterior glottic angle, tracheostomy

1. Introduction

Vocal folds play a crucial role in phonation, breathing and airway protection during swallowing. Laryngeal branches of the vagus nerve innervate muscles responsible for their mobility. Vocal fold paralysis in adduction could be responsible for inspiratory dyspnea at rest by obstructing the glottic aperture necessitating in some cases urgent tracheostomy, especially in bilateral paralysis¹⁻³. Patients with unilateral vocal fold paralysis in adduction can only experience exertional dyspnea due to narrowed glottis aperture. The management of this pathology is complex because of the difficulty to find the balance between breathing, swallowing and phonation.

Treatment of unilateral or bilateral vocal fold paralysis in adduction is different from one team to another. It could be more or less conservative through open, endoscopic, or combined approach⁴.

We have previously described an original technique of lateralization of the vocal process of the vocal fold and the arytenoid through an exclusive endoscopic approach⁵. This technique is easy to perform by any laryngologist experienced in reconstructive transoral laser microsurgery (R-TLM). It is inexpensive because it does not require any specific instrumentation, conservative, reversible, and could be performed in an emergency to avoid tracheostomy in bilateral vocal fold paralysis in adduction⁶.

Here, we study short and long-term results of transoral vocal fold lateralization on breathing, phonation and swallowing in a cohort of patients with unilateral and bilateral vocal fold paralysis in adduction.

2. Material and methods

A cohort of all patients undergoing endoscopic vocal fold lateralization from 2016 to 2018 was retrospectively reviewed at a tertiary referral laryngology center. Informed consent for data collection in medical records was obtained. All procedures performed in the study were in accordance with the ethical standards of the institution and with the 1964 Helsinki declaration and its later amendments. Exclusion criteria were any peroperative associated laryngeal procedure other than lateralization or any history of laryngeal surgery for vocal fold paralysis, patients under the age of 18, and death before postoperative follow-up secondary to a well-identified cause independent of surgery. Time elapsed from onset of vocal fold paralysis to the lateralization procedure was at least one year. Different objective and subjective criteria of the three laryngeal functions were evaluated preoperatively and on all post-operative follow-up visits.

2.1 Operative technique

Transoral lateralization suture technique was described in one of our previous works (figure 1) ⁵. In brief, the procedure is performed under general anesthesia with suspension laryngoscopy and the patient is optimally ventilated by low-frequency jet ventilation, using a jet ventilation tube positioned in the posterior commissure or through a metal tube connected and integrated into the laryngoscope (Lindholm laryngoscope, KARL STORZ, Germany) to perform supraglottic jet ventilation. After anesthetic induction, 120 mg of methylprednisolone and 2 g/200 mg of amoxicillin-clavulanic acid are administered by intravenous injection.

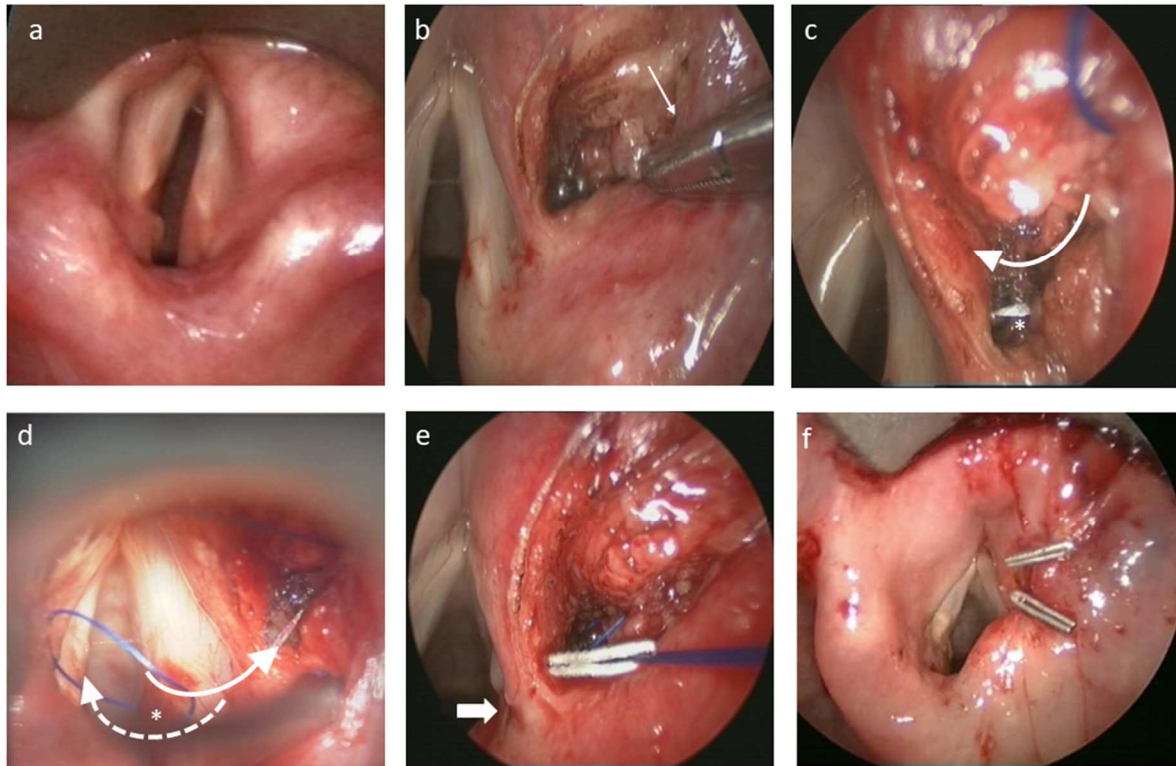


Figure 1: Endoscopic arytenoid and vocal fold lateralization technique. a) Right vocal fold paralysis in adduction. b) Supraglottic laryngotomy and paraglottic dissection as far as the inner perichondrium of the thyroid cartilage (arrow). c) The needle is inserted subperichondrally in the inner surface of the thyroid cartilage from proximal to distal (arrow showing the direction of insertion of the needle and asterisk showing the needle tip). d) The needle is inserted below (dashed arrow) the vocal process (asterisk) and then above (solid arrow) the vocal process, exiting through the supraglottic laryngotomy. e) The two sutures are held together by a clip with the desired tension allowing lateralization of the vocal process (arrow) together with the corresponding vocal fold. Excess suture material is cut with micro-instruments or laser. f) The supraglottic laryngotomy is closed by two absorbable sutures secured by clips. Note the lateral position of the right vocal fold compared to its position at the beginning of the procedure (a).

Classical transoral laser reconstructive microsurgery instruments are used ⁷. Good exposure of the posterior part of the larynx is essential to perform this technique. Supraglottic laryngotomy, lateral to the ventricular fold, is performed with CO₂ laser in Super Pulse mode (Lumenis, Israel). Dissection is continued with micro-instruments and laser in the paraglottic space as far as the inner perichondrium of the thyroid cartilage.

The lateralization suture is performed with 4/0 polypropylene suture material using a triangular needle. The first step consists of passing the needle through the perichondrium and the inner aspect of the thyroid cartilage from proximal to distal. The needle is then advanced below and then above the vocal process of the arytenoid and subsequently redirected towards

the laryngotomy. A second needle passage, identical to the first, can be performed to reinforce the lateralization suture. The two sutures are tightened together and held with a clip with the desired tension allowing lateralization of the arytenoid and corresponding vocal fold. Excess suture material is then cut with micro-instruments or laser. The supraglottic laryngotomy is then closed by one or two absorbable sutures maintained by clips.

2.2 Breathing evaluation

All patients without tracheostomy filled out a Dyspnea Index questionnaire (score range: 0 to 40) preoperatively and on each postoperative visit ⁸. For patients with tracheostomy, successful decannulation was the key to determining the effectiveness of the surgical treatment. All patients underwent trans-nasal flexible laryngotracheoscopy under local anesthesia with a color video, flexible endoscope (Xion EndoSTROBE®, Berlin, Germany) to evaluate glottic aperture. For each patient, on superior laryngeal view, we captured images for three forced deep inspirations. Images were analyzed after correcting the optical distortion of the lens of the endoscope using MATLAB and Vision Toolbox Release 2016b (The MathWorks, Inc., Natick, Massachusetts, USA) (figure 2). Each image was then presented three times randomly to an expert physician different from the one who performed laryngeal examination and surgery to guarantee independence between measurements. The images were annotated manually using a Matlab® script. Measurements included glottic area, inter-arytenoid distance (distance between the vocal processes of the arytenoids), and anterior glottic angle (angle between the anterior third of the vocal folds) (figure 3). Images were then randomly presented again to the expert after reporting the normal side or the unoperated side, to measure the length of the normal or unoperated vocal fold in unilateral and bilateral vocal fold paralysis. The script then made it possible to normalize the different variables over the measured length of the unoperated vocal fold, and then to average different normalized values of the three images. For each patient, the mean values of the preoperative endoscopy

measurements were used as references and the postoperative changes were therefore in relative values.

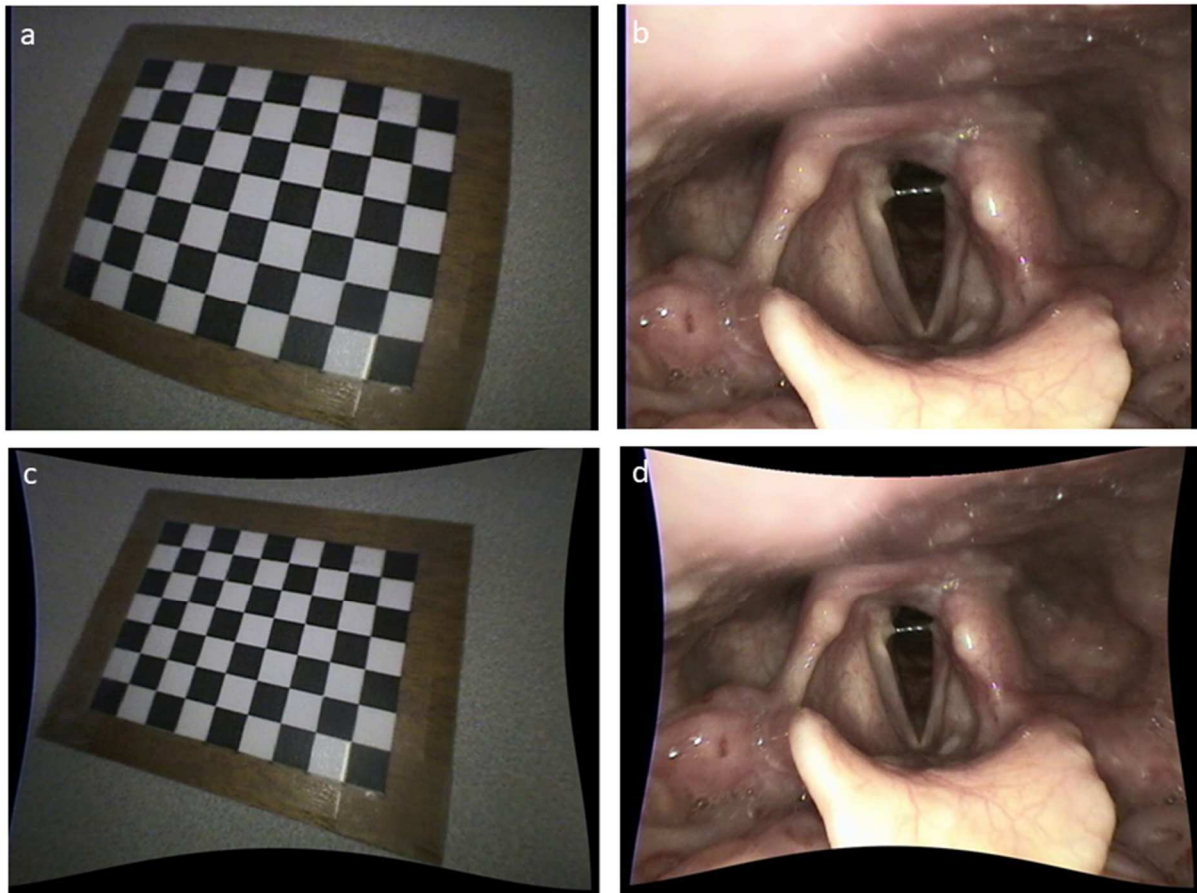


Figure 2: correction of the optical distortion of the lens of the endoscope. Distorted reference image (a) and laryngeal image (b). After correction of optical distortion (c and d) using MATLAB and Vision Toolbox Release.

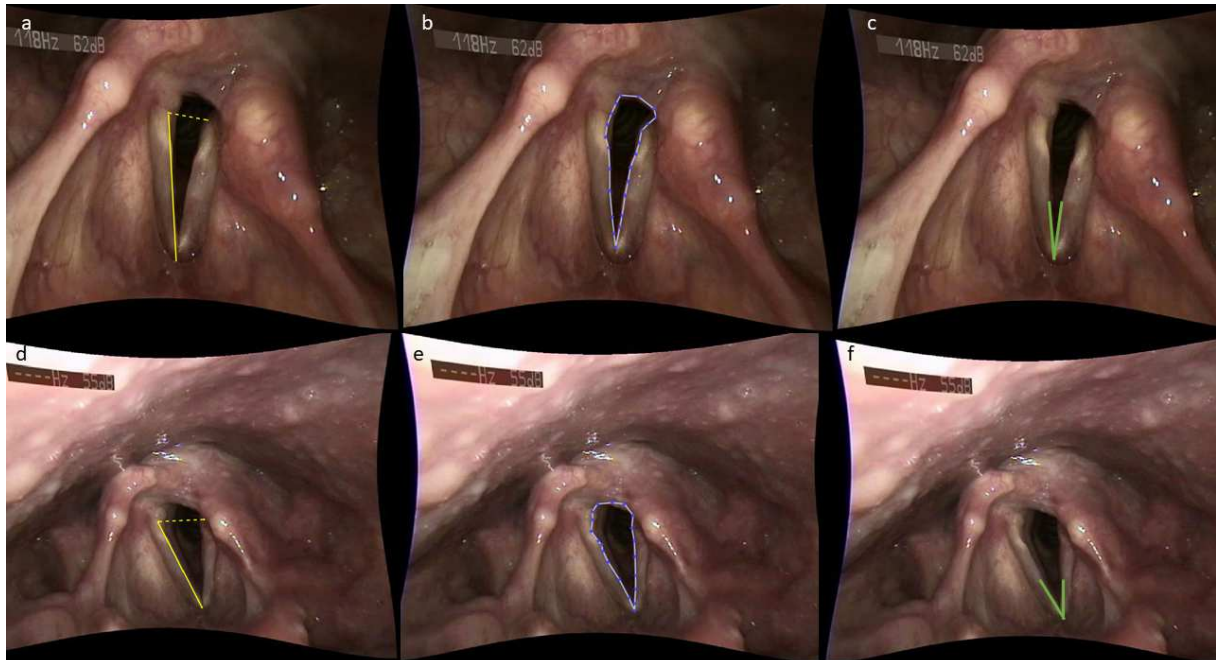


Figure 3: Glottic aperture measurements. Example of preoperative measurements of glottic aperture (a: interarytenoid distance and normal vocal fold length, b: glottic area, c: anterior glottic angle) and postoperative measurements (d: interarytenoid distance and normal vocal fold length, e: glottic area, and f: anterior glottic angle) in a patient with left vocal fold paralysis. Images were selected in forced deep inspiration.

2.3 Evaluation of phonation

We studied the results of preoperative and postoperative VHI-10 (Voice Handicap Index-10) and VRQOL (Voice-Related Quality Of Life) questionnaires^{9, 10}.

We analyzed the acoustic parameters of fundamental frequency (F0 in Hz), the Jitter, the Shimmer, the maximum phonation time (MPT) and the harmonics-to-noise ratio (HNR, dB) of a sustained vowel [i]. Acoustic parameters were calculated using the PRAAT 10 software.

2.4 Swallowing evaluation

All patients filled out an EAT-10 (Eating Assessment Tool) questionnaire preoperatively and on each postoperative visit¹¹. They were checked for aspiration symptoms to solids or liquids during follow-up. Modified barium swallow was performed in patients with suspected aspiration.

2.5 Statistical analysis

Statistical analyzes were conducted on R (version 3.5.2(2018-12-20) Copyright (C) 2018, The R Foundation for Statistical Computing). Paired nonparametric Friedman's test and Nemenyi test were used if normality assumption was not retained with an adjustment of the p-value with Bonferroni correction, in which case medians are given. In case of normal data, we performed repeated ANOVA test followed by Tukey's test. We also used linear mixed model with an individual random effect (the normality of the residues was verified) thanks to the 'nlme' package. Significance level was set to 0.05.

3. Results

In an initial cohort of 30 patients who underwent endoscopic vocal fold lateralization, we excluded 12 patients. Out of the 12 excluded patients, there were 2 infants, 8 patients who got complementary procedure to lateralization suture in the same operative time, and 2 patients died before the first postoperative visit secondary to well identified causes independent of the surgery (cerebral metastasis, and liver failure secondary to hepatocellular carcinoma).

Eighteen patients were retained for the study. The characteristics of these patients are shown in table I. The average operative time was 45 minutes. Each patient had at least three postoperative visits (C1, C2, C3): C1 at 1 month, C2 at 4 months, and C3 at 12 months. The average follow-up period was 17 months.

Age		mean : 64 years	Range : 50-78 years
		n	Percentage
Sex	female	11	61
	male	7	39
Side of vocal fold paralysis	right	6	33
	left	9	50
	bilateral	3	17
Side of the lateralization procedure	right	9	50
	left	9	50
Patients with tracheostomy ^Δ		3	17
Etiology of vocal fold paralysis	Iatrogenic [*]	12	67
	Traumatic ⁺	1	5
	neuromuscular ^ϕ	5	28

Table I: patients with vocal fold paralysis in adduction who underwent lateralization procedure

^Δ: patients with tracheostomy were decannulated following transoral lateralization. ^{*}: thyroidectomy (n=8), thoracic surgery (left lobectomy and mediastinoscopy, n=2) cervical surgery (paraganglioma resection and cervical spinal fusion, n=2). ⁺: traumatic intubation. ^ϕ: Guillain-Barré syndrome (n=1), myasthenia gravis (n=1), degenerative neuromuscular disorders (n=2), and idiopathic vocal fold palsy (n=1).

3.1 Breathing

Three tracheostomy dependent patients with bilateral vocal fold palsy were decannulated three months after the lateralization surgery. Their DI score at the last follow-up visit was 6.7 on average.

For the other 15 patients, the median DI score was 26 versus 7.5, 3.5 and 7 on C1, C2 and C3 follow-up visits, respectively (p <0.001) (Figure 4, a). The comparison of the scores of the different post-operative controls was not statistically significant: C1-C2 (p = 0.99), C2-C3 (p = 0.18), C1-C3 (p = 0.26).

In terms of videoendoscopic analyzes, reproducibility calculated for the measurements of the three presentations of each image was 92% for interarytenoid distance, 85% for glottic area and 91% for anterior glottic angle measurements.

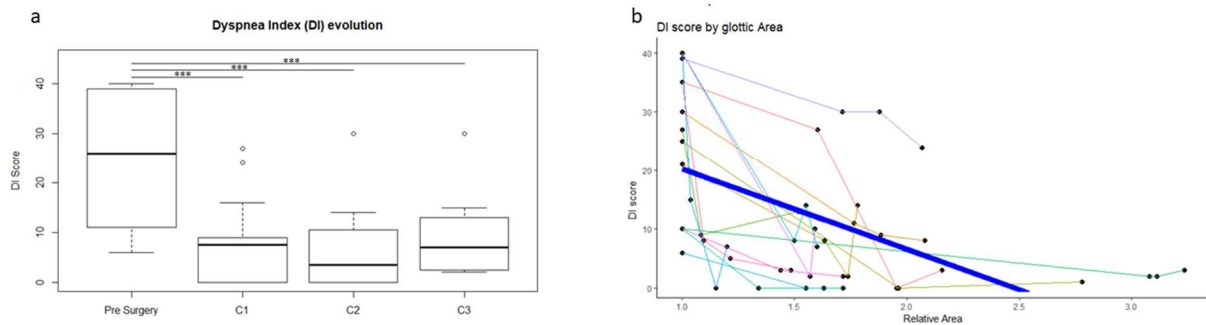


Figure 4: Evolution of Dyspnea Index (DI) score in patients with vocal fold paralysis in adduction who underwent transoral lateralization procedure. a) Preoperative and post-operative DI score in three follow-up visits (C) (C1: 1 month, C2: 4 months, C3: 12 months). b) DI score according to the glottic area.

***: highly significant

The mean anterior glottic angle was $20.9^{\circ} \pm 5.6$ preoperatively and statistically different from postoperative follow-up visits: $27.3^{\circ} \pm 6.9$ ($p < 0.001$) on C1, $31^{\circ} \pm 5.4$ ($p < 0.001$) on C2, $30.53^{\circ} \pm 7$ ($p < 0.001$) on C3. On the other hand, the measured angles are not significantly different between different follow-up visits (C1-C2: $p = 0.07$, C2-C3: $p = 0.97$, C1-C3: $p = 0.3$). (figure 5, b)

The estimated postoperative relative glottic area (1.65 ± 0.54 for C1, 1.81 ± 0.55 for C2 and 1.85 ± 0.56 for C3) was significantly increased compared to the preoperative estimated area of reference 1. Post-operative glottic area was not statistically different between C1, C2 and C3 (C1-C2 $p = 0.26$, C2-C3: $p = 0.87$, C1-C3: $p = 0.08$) (figure 5, a). In the same way, the relative interarytenoid distance was 1.46 ± 0.35 for C1, 1.58 ± 0.52 for C2, 1.62 ± 0.41 for C3 (figure 5, c) and was statistically different from the preoperative one. Interarytenoid distance was not statistically different between C1, C2 and C3 (C1-C2: $p = 0.45$, C2-C3: $p = 0.94$, C1-C3: $p = 0.13$). After removal of the preoperative values, the correlation (ρ)

between the estimated glottic area and the estimated inter-arytenoid distance was 0.76 95% CI (0.58-0.87) ($p < 0.001$) (figure 5, d.). The estimated area ($\rho = 0.28$ 95% CI (- 0.06-0.55)) and the inter-arytenoid distance are not correlated with the anterior angle ($\rho = 0.25$ 95% CI (- 0.08-0.53)).

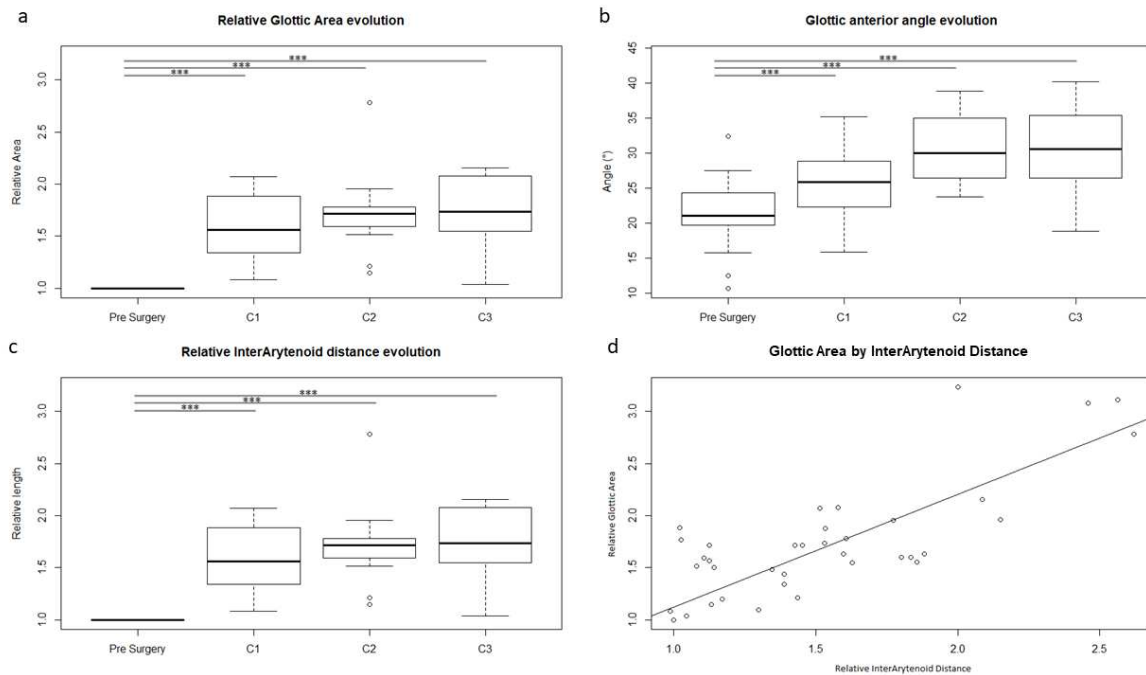


Figure 5: Evolution of glottic aperture in patients with vocal fold paralysis in adduction who underwent transoral lateralization procedure. a) Relative glottic areas during different follow-up visits. b) Evolution of anterior glottic angle. c) Evolution of the interarytenoid distance. d) Correlation between interarytenoid distance and relative estimated glottic area.

C1: follow-up visit at 1 month, C2: follow-up visit at 4 months, C3: follow-up visit at 12 months.

***: highly significant

We introduced the variables: anterior glottic angle, glottic area, and unilateral / bilateral vocal fold paralysis in our linear mixed model for the DI score explanation. Step-by-step selection of the three variables did not allow to retain the anterior glottic angle nor unilateral / bilateral paralysis as factors that affect the DI score. In contrast, glottic area explains about 60% of the variance with a decrease of 13.6 +/- 2.6 at the DI score for a relative increase of one point of the estimated glottic area ($p < 0.001$, $\text{pseudoR}^2 = 0.59$). (figure 4, b).

Finally, dynamic analysis of vocal folds mobility on forced deep inspirations showed aspiration of the paralyzed vocal fold and/or the vocal process of the arytenoid in six cases of unilateral vocal fold paralysis in addition to narrowing of the glottic aperture by the adducted position of the immobile vocal fold. These findings disappeared post-operatively after the lateralization suture.

3.2 Phonation

For the VHI-10 and VRQOL questionnaires, there were no significant statistical differences between preoperative scores and follow-up visits (Friedman test: $p = 0.07$ and $p = 0.33$ respectively) (Fig. 6 a, b). The correlation (ρ) between scores was 0.83, 95% CI (0.73-0.90) ($p < 0.001$).

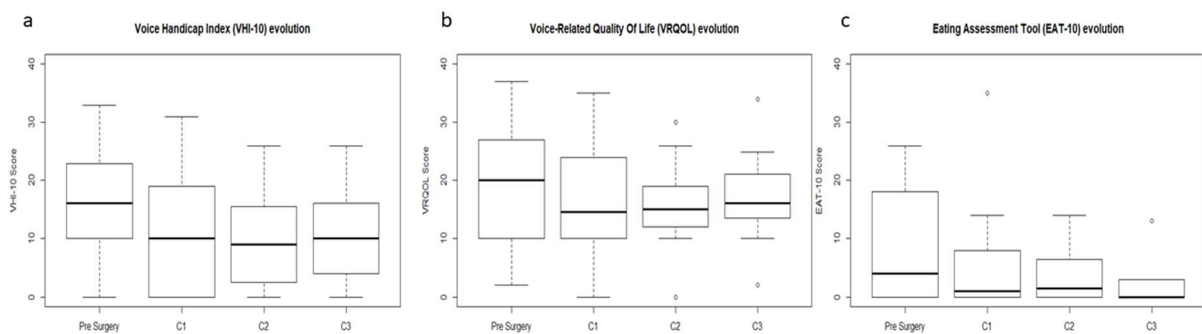


Figure 6: Evolution of voice and swallowing symptoms in patients with vocal fold paralysis in adduction who underwent transoral lateralization procedure. There is no significant difference between preoperative and postoperative symptoms (C1: follow-up visit at 1 month, C2: follow-up visit at 4 months, C3: follow-up visit at 12 months)

For the acoustic parameters: Jitter, Shimmer, MPT, F0, HNR, there were no differences between the pre- and postoperative follow-up visits ($p = 0.52$, $p = 0.54$, $p = 0.24$, $p = 0.48$, $p = 0.35$) (figure 7). Jitter and shimmer were highly correlated ($\rho = 0.73$ 95% CI (0.55, 0.91)). Statistical models did not allow the acoustic data to be used as an explanatory variable for the VHI-10 and VRQOL scores.

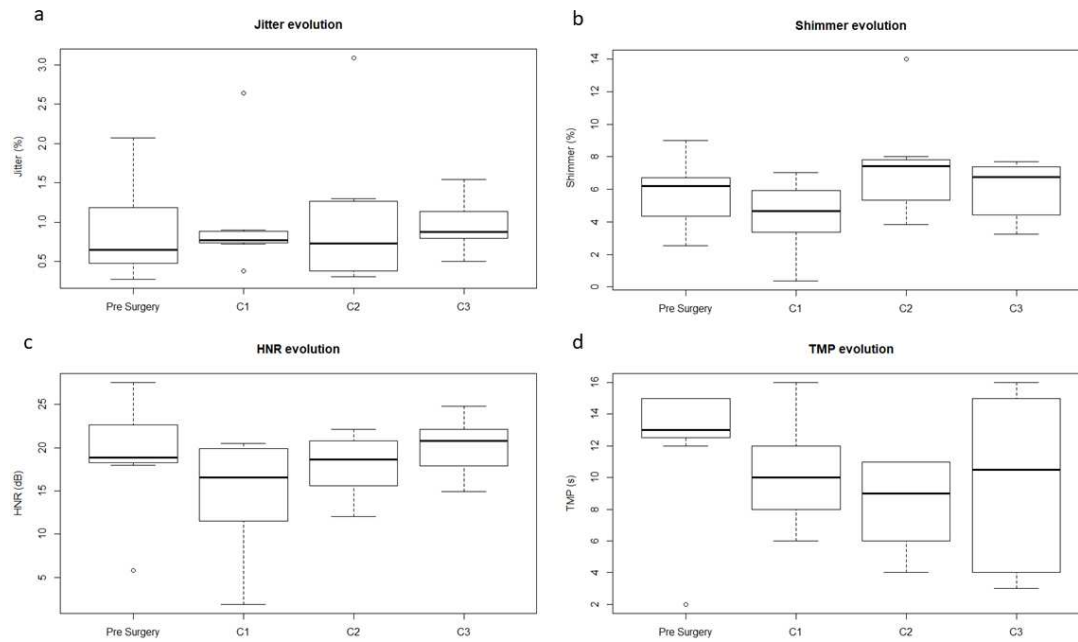


Figure 7: Evolution of voice parameters in patients with vocal fold paralysis in adduction who underwent transoral lateralization procedure. a) Jitter, b) Shimmer, c) Harmonics-to-noise ratio (HNR, dB), d) Maximum phonation time (TMP, sec). There is no significant difference between preoperative and postoperative voice parameters (C1: follow-up visit at 1 month, C2: follow-up visit at 4 months, C3: follow-up visit at 12 months).

We tried to link the video data and the DI score with the results of the VHI-10 and VRQOL scores, with stepwise selection procedure, although low (value = 0.24 +/- 0.06), the linear mixed model found a link between DI score and VRQOL score ($p = 0.009$, $\text{pseudoR}^2 = 0.91$). We could not highlight the relationship between acoustic data and endoscopic data, especially the anterior glottic angle.

3.3 Swallowing

The pre- and postoperative EAT-10 scores were not significantly different (Friedman test: $p = 0.15$) (figure 6, c). Aspiration for solids and liquids were reported in 22% of cases preoperatively (four patients, including two tracheostomy dependent patients, and the two patients with past history of paraganglioma resection and Guillain-Barré syndrome) with no change in their swallowing postoperatively. In one patient with tracheostomy, swallowing improved after decannulation.

4. Discussion

Vocal fold paralysis in adduction, especially when it is bilateral, can induce severe and poorly tolerated inspiratory dyspnea, requiring intubation or tracheostomy especially for bilateral paralysis in adduction. Unilateral vocal fold paralysis in adduction can cause breathing difficulties, especially on exertion. This can result from one or more factors that include decreased or absent abductory support during inspiration, a medially tipped arytenoid body, synkinesis with adductory activity during inspiration, and post-paralysis contracture of the cricoarytenoid joint capsule ¹². In addition, flail vocal fold following unilateral paralysis may result in airway obstruction on excretion during inspiration. Management of vocal fold paralysis in adduction represents a delicate challenge for the laryngologist who has to optimize the balance between the three main functions of the larynx ¹³. There are many options to manage vocal fold paralysis in adduction but some of them are non-conservative procedures and others require specific instrumentation ^{4, 6, 14}.

We have described a technique for vocal fold lateralization that can be performed through an exclusive endoscopic approach without any skin incision, thereby avoiding a neck scar. It can also be performed by a single operator without the need for an assistant to control and assist in placement of the extralaryngeal suture ⁵. This technique allows easy control of the appropriate tension and lateralization of the vocal fold and arytenoid cartilage with respect to the midline.

In our series, tracheostomy dependent patients with bilateral vocal fold paralysis in adduction were decannulated after performing the lateralization suture. Patients without tracheostomy with unilateral vocal fold paralysis in adduction and with respiratory symptoms showed decrease in their DI score after vocal fold lateralization. Subjective improvement in dyspnea is obvious immediately after surgery and results are stable after one year of follow-up,

without causing any significant disturbance in voice quality or swallowing, and even improving swallowing disorders after decannulation of one tracheostomy-dependent patient.

Wang has demonstrated that the configuration of the cricoarytenoid joint is responsible for superior lateral and vertical translational movement of the arytenoid cartilage during abduction ¹⁵. Various anatomical studies have shown the advantage of conservative physiological lateralization techniques that widen the posterior commissure thus facilitating breathing without harming the vocal folds and the anterior commissure ^{16, 17}. Our lateralization suture technique is performed under direct visual control thus joins the EAAL technique (Endoscopic Arytenoid Abduction Lateropexy) described by Ròvo by allowing this physiological movement of the cricoarytenoid joint to occur ¹⁴. Our results are thus relatively similar to the results of the EAAL technique in term of improvement of the glottic area, dyspnea, and voice quality ^{12, 18}.

Our results of postoperative glottic anterior angle are found to be in the lower limit of the measures done by Dailey et al. on non-pathological population ¹⁹. Our endoscopic lateralization suture technique stretches vocal folds allowing a phonation of better quality. The glottic area is significantly increased (gain greater than 60%) postoperatively and is much more related to the increase of the interarytenoid distance than to the anterior glottic angle. This explains improvement of breathing symptoms without disturbing phonation parameters. The posterior commissure is therefore a particularly important element not to neglect for the restoration of breathing quality.

It is interesting to note a possible correlation of the VRQOL score with the DI score which would remain to be explored in a larger series, for which we can hypothesize a breath-related speech flow problem to explain this correlation. We have chosen to study the classical acoustic parameters like Jitter, Shimmer and HNR, although their role in vocal evaluation for laryngeal immobility remains to be clarified, particularly with regard to the voice handicap felt by patients. However, these parameters are stable and easy to extract allowing robust intra-individual comparison^{20, 21}. Novel and more reliable scores in terms of voice-based acoustic assessment exist (DSI (Dysphonia Severity Index), AVQI (Acoustic Voice Quality Index), VEM (Vocal Extent Measure, and Cepstral Spectral Index of Dysphonia) but require a relatively standardized procedure to be comparable²²⁻²⁵.

In our initial cohort, we excluded 8 patients that underwent additional procedure to the lateralization suture in the same operative time in order to exclusively study the effect of the lateralization suture on glottic aperture. Outside this study, we stress on the fact that transoral lateralization suture could be associated with any other endoscopic procedures to improve glottic aperture in the same operative time because it shows a great utility in widening the interarytenoid distance in the setting of cricoarytenoid joint ankyloses as described in one of our previous works²⁶.

Glottic enlargement by EAAL has been described in the treatment of laryngeal paralysis of the infant, and seems to be an alternative solution to tracheostomy^{27, 28}. It seems possible to us to use our transoral lateralization suture in pediatric population with vocal fold paralysis in adduction because it has the advantage to achieve vocal fold lateralization without the need to

perform any transfixing suture of the thyroid cartilage thus decreasing the risk of laryngeal cartilaginous frame deformation, cervical vessels injury and neck scar.

The video annotation algorithm presented in this work is original and seems quite coherent and reproducible given the stability of measurements performed on different follow up visits using different endoscopes. Although it is impossible to perform measurements in absolute values outside the anterior glottic angle values, we have been able to determine good correlation between the estimated relative values of the glottic area and the interarytenoid distance thus proving the reliability of the analysis.

5. Conclusion

We have evaluated the vocal fold lateralization suture through exclusive transoral approach. It showed to be highly effective in improving breathing symptoms without affecting phonation or swallowing abilities. It can be used as first-line technique in patients with respiratory symptoms. This technique also optimally preserves laryngeal structures. It is reproducible and reliable for all laryngologists experienced in laryngeal microsurgery.

References

1. Tucker HM. Vocal cord paralysis--1979: etiology and management. *Laryngoscope*. 1980;90:585-590.
2. Hagan PJ. Vocal cord paralysis. *Ann Otol Rhinol Laryngol*. 1963;72:206-222.
3. Goff WF. Vocal cord paralysis analysis of 229 cases. *JAMA*. 1970;212:1378-1379.
4. Li Y, Garrett G, Zeale D. Current Treatment Options for Bilateral Vocal Fold Paralysis: A State-of-the-Art Review. *Clin Exp Otorhinolaryngol*. 2017;10:203-212.

5. Fabre C, Righini CA, Castellanos PF, Atallah I. Endoscopic lateralization of the vocal fold. *Eur Ann Otorhinolaryngol Head Neck Dis.* 2018.
6. Lichtenberger G, Toohill RJ. Technique of endo-extralaryngeal suture lateralization for bilateral abductor vocal cord paralysis. *Laryngoscope.* 1997;107:1281-1283.
7. Atallah I, Manjunath MK, Omari AA, Righini CA, Castellanos PF. Reconstructive transoral laser microsurgery for posterior glottic web with stenosis. *Laryngoscope.* 2017;127:685-690.
8. Gartner-Schmidt JL, Shembel AC, Zullo TG, Rosen CA. Development and validation of the Dyspnea Index (DI): a severity index for upper airway-related dyspnea. *J Voice.* 2014;28:775-782.
9. Hogikyan ND, Sethuraman G. Validation of an instrument to measure voice-related quality of life (V-RQOL). *J Voice.* 1999;13:557-569.
10. Rosen CA, Lee AS, Osborne J, Zullo T, Murry T. Development and validation of the voice handicap index-10. *Laryngoscope.* 2004;114:1549-1556.
11. Belafsky PC, Mouadeb DA, Rees CJ, et al. Validity and reliability of the Eating Assessment Tool (EAT-10). *Ann Otol Rhinol Laryngol.* 2008;117:919-924.
12. Matievics V, Bach A, Sztano B, et al. Functional outcomes of endoscopic arytenoid abduction lateropexy for unilateral vocal cord paralysis with dyspnea. *Eur Arch Otorhinolaryngol.* 2017;274:3703-3710.
13. Belafsky PC. Bilateral vocal fold immobility. *Curr Opin Otolaryngol Head Neck Surg.* 2011;19:415.
14. Rovo L, Madani S, Sztano B, et al. A new thread guide instrument for endoscopic arytenoid lateropexy. *Laryngoscope.* 2010;120:2002-2007.
15. Wang RC. Three-dimensional analysis of cricoarytenoid joint motion. *Laryngoscope.* 1998;108:1-17.

16. Sztano B, Szakacs L, Madani S, et al. Comparison of endoscopic techniques designed for posterior glottic stenosis--a cadaver morphometric study. *Laryngoscope*. 2014;124:705-710.
17. Szakacs L, Sztano B, Matievics V, et al. A comparison between transoral glottis-widening techniques for bilateral vocal fold immobility. *Laryngoscope*. 2015;125:2522-2529.
18. Szakacs L, Sztano B, Matievics V, Bere Z, Castellanos PF, Rovo L. Glottic configuration changes and outcomes of endoscopic arytenoid abduction lateropexy. *Eur Arch Otorhinolaryngol*. 2019;276:167-173.
19. Dailey SH, Kobler JB, Hillman RE, et al. Endoscopic measurement of vocal fold movement during adduction and abduction. *Laryngoscope*. 2005;115:178-183.
20. Desuter G, Dedry M, Schaar B, van Lith-Bijl J, van Benthem PP, Sjogren EV. Voice outcome indicators for unilateral vocal fold paralysis surgery: a review of the literature. *Eur Arch Otorhinolaryngol*. 2018;275:459-468.
21. Gillespie AI, Gooding W, Rosen C, Gartner-Schmidt J. Correlation of VHI-10 to voice laboratory measurements across five common voice disorders. *J Voice*. 2014;28:440-448.
22. Uloza V, Latoszek BBV, Ulozaite-Staniene N, Petrauskas T, Maryn Y. A comparison of Dysphonia Severity Index and Acoustic Voice Quality Index measures in differentiating normal and dysphonic voices. *Eur Arch Otorhinolaryngol*. 2018;275:949-958.
23. Pommee T, Maryn Y, Finck C, Morsomme D. Validation of the Acoustic Voice Quality Index, Version 03.01, in French. *J Voice*. 2018.

24. Caffier PP, Moller A, Forbes E, Muller C, Freymann ML, Nawka T. The Vocal Extent Measure: Development of a Novel Parameter in Voice Diagnostics and Initial Clinical Experience. *Biomed Res Int*. 2018;2018:3836714.
25. Lee JM, Roy N, Peterson E, Merrill RM. Comparison of Two Multiparameter Acoustic Indices of Dysphonia Severity: The Acoustic Voice Quality Index and Cepstral Spectral Index of Dysphonia. *J Voice*. 2018;32:515 e511-515 e513.
26. Atallah I, Mk M, Al Omari A, Righini CA, Castellanos PF. Cricoarytenoid Joint Ankylosis: Classification and Transoral Laser Microsurgical Treatment. *J Voice*. 2018.
27. Madani S, Bach A, Matievics V, et al. A new solution for neonatal bilateral vocal cord paralysis: Endoscopic arytenoid abduction lateropexy. *Laryngoscope*. 2017;127:1608-1614.
28. Sztano B, Bach A, Matievics V, et al. Endoscopic arytenoid abduction lateropexy for the treatment of neonatal bilateral vocal cord paralysis - Long-term results. *Int J Pediatr Otorhinolaryngol*. 2019;119:147-150.