



HAL
open science

Brain abnormalities detection in de Novo Parkinsonian patients

Verónica Muñoz Ramírez, Florence Forbes, Alexis Arnaud, Michel Dojat

► **To cite this version:**

Verónica Muñoz Ramírez, Florence Forbes, Alexis Arnaud, Michel Dojat. Brain abnormalities detection in de Novo Parkinsonian patients. OHBM 2019 - 25th Annual Meeting of the Organization for Human Brain Mapping, Jun 2019, Rome, Italy. pp.1-11. hal-02415101

HAL Id: hal-02415101

<https://hal.science/hal-02415101>

Submitted on 16 Dec 2019

HAL is a multi-disciplinary open access archive for the deposit and dissemination of scientific research documents, whether they are published or not. The documents may come from teaching and research institutions in France or abroad, or from public or private research centers.

L'archive ouverte pluridisciplinaire **HAL**, est destinée au dépôt et à la diffusion de documents scientifiques de niveau recherche, publiés ou non, émanant des établissements d'enseignement et de recherche français ou étrangers, des laboratoires publics ou privés.

BRAIN ABNORMALITIES DETECTION IN *DE NOVO* PARKINSONIAN PATIENTS

Verónica Muñoz Ramírez^{a,b}, Florence Forbes^b, Alexis Arnaud^{a,b}, Michel Dojat^a

a Grenoble Institut des Neurosciences, Inserm U1216, Univ. Grenoble Alpes, 38000 Grenoble, France

b Univ. Grenoble Alpes, Inria, CNRS, Grenoble INP, LJK, 38000 Grenoble, France

Introduction: The diagnosis of Parkinson's disease (PD) is primarily based on the identification of motor symptoms that appear late in the course of the disease when many dopaminergic neurons are lost. However, non-motor symptoms and abnormalities in subcortical brain structures appear earlier and could be serve as PD biomarkers. We propose to take advantage of the informative nature of quantitative MRI [1] to construct statistical models that characterize the physiological properties of subcortical structures in Control Subjects (CS) and recently diagnosed ("de novo") PD patients.

Methods: Our approach is based on the modelisation of multiparametric MRI data by Mixtures of Multiple-scale Student distributions (MSD) [2, 3]. Mixture models are probabilistic data driven models that represent subpopulations, within an overall population, without prior knowledge (unsupervised learning). Then, the Expectation-Maximization algorithm (EM) [2] is used to compute, using a slope heuristic, the number of mixture components and find the best fit of the underlying MSD given the data. We choose MSD as they offer shape flexibility, for instance, they are not constrained to elliptical shapes like Gaussian distributions. We fused perfusion (cerebral blood flow) and diffusion (fractional anisotropy and mean diffusivity) parameter maps from 3 CS (865 635 voxels) and 10 PD (2 973 263 voxels) in such a way that each voxel v has three corresponding feature values $y_v = (FA_v, MD_v, CBF_v)$. A reference model (RM) is constructed by fitting an MSD mixture to the values of all voxels belonging to CS. Then, we calculate the log-density (or log-score) for all voxels for all subjects, as a measure of proximity of the associated values of each voxel v with respect to RM. The rational is that CS voxels are more likely to have a high log-score while PD voxels may not be well explained by RM and consequently have a lower log-score. We chose a log-score threshold τ to separate CS from PD with an associated false positive error rate α equal to 5%. All voxels whose log-score are below τ are then labeled as abnormal and their corresponding measures are fitted with a new MSD mixture resulting on the abnormality model (AM). AM is eventually used to account for the fact that voxels detected as abnormal may reveal different patient phenotypes. The proportion of voxels assigned to each abnormal class may constitute their signature (Fig. 1 left). Abnormality detection can be refined by spatially cleaning all abnormal clusters formed by less than 4 voxels. We compute a hierarchical clustering of the signatures for patients subtyping (Fig. 1 right).

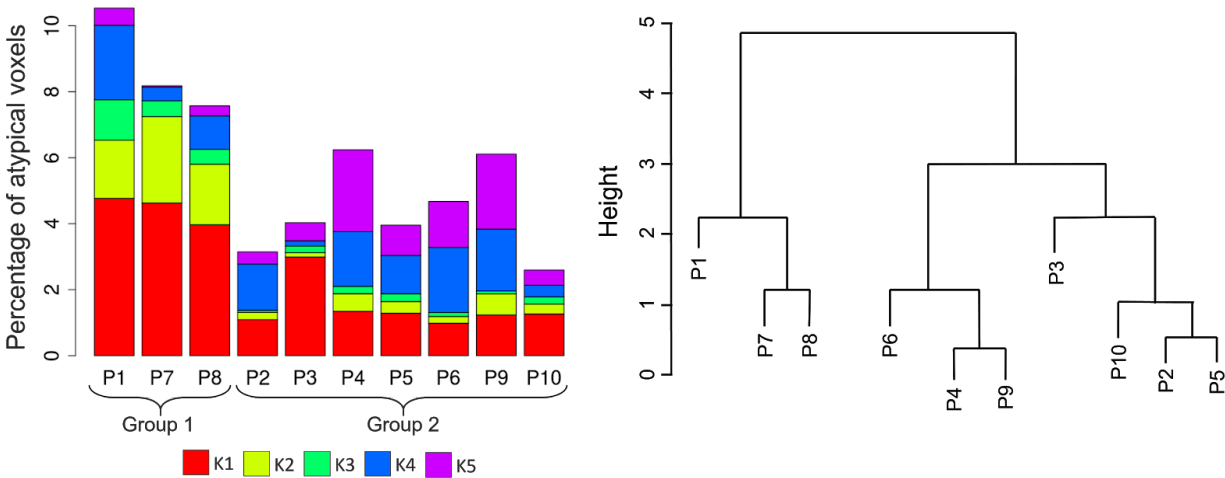


Figure 1: (left) Individual signatures i.e. percentage of each atypical class in every PD patient. (right) Hierarchical cluster of the patients signatures reveals two groups : {P1,P7,P8} and {P2,P3,P4,P5,P6,P9,P10}

In order to accurately localize the detected abnormalities we registered on each individual two atlases, one for subcortical structures: MNIPD25 template [4] (red nucleus, substantia nigra, subthalamic nucleus, caudates, putamen, globus pallidus and thalamus), and for other brain regions, the Neuromorphometrics template [5].

Results: For a 5 class Reference Model, 12% of the PD voxels (462 188) were detected as abnormal and subsequently modeled by a 5 class Anormal Model. After post-treatment 4.6% remained as abnormal. Based on their signatures, two groups of patients emerged, Group 1, composed of 3 patients (P1, P7 and P8), displayed the most important abnormalities, mainly in subcortical structures, the brainstem and the diencephalon. Group 2 was more heterogeneous, but shared effects in the substantia nigra and the transverse temporal gyrus.

Conclusion: We have demonstrated the feasibility of our approach on a reduced number of subjects without the need for annotated datasets. Although more subjects and MRI maps are required to robustly define biomarkers, these preliminary results show that the combination of quantitative MR data with relevant mixture models renders possible the PD detection and the subtyping of PD patients into classes for which specific personal follow-up may be envisaged.

References :

- [1] P. Tofts, Quantitative MRI of the brain, Wiley, 1st edition, 2005.
- [2] F. Forbes and D. Wraith, "A new family of multivariate heavy-tailed distributions with variable marginal amounts of tailweight: application to robust clustering," Statistics and Computing, vol. 24, no. 6, pp. 971–984, 2014.
- [3] A. Arnaud & al., "Fully Automatic Lesion Localization and Characterization: Application to Brain Tumors Using Multiparametric Quantitative MRI Data," IEEE Transactions on Medical Imaging, vol. 37, no. 7, pp. 1678–1689, 2018.

- [4] Y. Xiao & al., "Multi-contrast unbiased MRI atlas of a Parkinson's disease population," *International Journal of Computer Assisted Radiology and Surgery*, vol. 10, no. 3, pp. 329–341, 2015.
- [5] R. Bakker & al., "The Scalable Brain Atlas: instant web-based access to public brain atlases and related content," *Neuroinformatics*, 2015.