



HAL
open science

Long-term survival of hybrid total hip arthroplasty with the uncemented CLS cup, cemented Müller cobalt-chromium stem, and 28-mm Metasul™ bearings: Retrospective review of 115 hips after a minimum of 17.8 years

Roger Erivan, Guillaume Villatte, Thibaut Lecointe, Aurélien Mulliez, Stéphane Descamps, Stéphane Boisgard

► To cite this version:

Roger Erivan, Guillaume Villatte, Thibaut Lecointe, Aurélien Mulliez, Stéphane Descamps, et al.. Long-term survival of hybrid total hip arthroplasty with the uncemented CLS cup, cemented Müller cobalt-chromium stem, and 28-mm Metasul™ bearings: Retrospective review of 115 hips after a minimum of 17.8 years. *Orthopaedics & Traumatology: Surgery & Research*, 2019, 105 (7), pp.1289-1295. 10.1016/j.otsr.2019.06.019 . hal-02409548

HAL Id: hal-02409548

<https://hal.science/hal-02409548v1>

Submitted on 20 Jul 2022

HAL is a multi-disciplinary open access archive for the deposit and dissemination of scientific research documents, whether they are published or not. The documents may come from teaching and research institutions in France or abroad, or from public or private research centers.

L'archive ouverte pluridisciplinaire **HAL**, est destinée au dépôt et à la diffusion de documents scientifiques de niveau recherche, publiés ou non, émanant des établissements d'enseignement et de recherche français ou étrangers, des laboratoires publics ou privés.



Distributed under a Creative Commons Attribution - NonCommercial 4.0 International License

**Long-Term Survival of Hybrid Total Hip Arthroplasty with the Uncemented CLS Cup,
Cemented Müller Cobalt-Chromium Stem, and 28-mm Metasul™ Bearings:
Retrospective Review of 115 Hips after a Minimum of 17.8 Years**

Roger **Erivan**^{a*}, Guillaume **Villatte**^a, Thibaut **Lecoïnte**^b, Aurélien **Mulliez**^c, Stéphane
Descamps^a, Stéphane **Boisgard**^a

a: Université Clermont Auvergne, CHU Clermont-Ferrand, CNRS, SIGMA Clermont, ICCF,
F-63000 Clermont–Ferrand, France

b : Université Clermont Auvergne, CHU Clermont-Ferrand, F-63000 Clermont–Ferrand,
France

c : Délégation à la Recherche Clinique et aux Innovations (DRCI) - CHU Clermont-Ferrand,
F-63000 Clermont–Ferrand, France

***Corresponding author:** Orthopaedic and Trauma Surgery Department, Hôpital Gabriel

Montpied, CHU de Clermont Ferrand BP 69, 63003 Clermont Ferrand, France

Tel.: +33 473 751 535

E-mail: rerivan@chu-clermontferrand.fr

ABSTRACT

Background: Hard-on-hard bearings require a meticulous implantation technique but may be associated with lower wear rates in young active patients. Among them, metal-on-metal (MoM) bearings have been blamed for specific complications including adverse reactions to metal debris and metal hypersensitivity. These complications have been chiefly reported with large-head MoM implants (except when used for hip resurfacing). Most of the published data on small-head MoM implants were obtained using uncemented stems. To our knowledge, no information on outcomes beyond 15 years is available for small-head MoM implants with cemented cobalt-nickel-chromium (Co-Ni-Cr) stems, which might increase the risk of complications. The objective of this study was to collect long-term follow-up data on patients who underwent hybrid total hip arthroplasty (THA) with 28-mm MoM Metasul™ bearings in order to assess: 1) long-term survival (based on the revision rate), 2) and the occurrence of adverse reactions to metal debris documented during revision.

Hypothesis: Survival of 28-mm Metasul™ bearings used with hybrid THA is acceptable.

Patients and Methods: A single-centre retrospective study was conducted in consecutive patients managed using 28-mm Metasul™ bearings in a press-fit cup, with a cemented Co-Ni-Cr stem. Follow-up was at least 17 years. The clinical and radiographic data were analysed. Mean age at surgery was 57.3 ± 7.9 years (range, 29.6-75.3 years).

Results: The study included 115 hips with a mean follow-up of 20.3 ± 0.8 years (range, 17.8-21.6 years). Survival to revision for any reason was 86.10% (95%CI, 79.8-92.4%) and survival to revision for aseptic loosening was 92.6% (95%CI, 87.7-97.6). Half the specimens obtained during revision showed a macrophage reaction and a non-specific inflammatory infiltrate. No patient experienced complications specifically related to the use of Metasul™ bearings with a cemented Co-Ni-Cr stem.

Discussion: Long-term survival of 28-mm MoM Metasul™ bearings was close to that of metal-on-polyethylene bearings and lower than that of ceramic-on-ceramic or small-head MoM bearings in other studies. No complications specifically related to the use of small-head MoM bearings with a cemented Co-Ni-Cr stem were recorded.

Level of evidence: IV, retrospective study

Key Words: Aseptic lymphocyte-dominated vasculitis-associated lesion. Adverse reaction to metal debris. Metal-on-metal. Total hip arthroplasty. Survival.

1. Introduction

Over 160 000 primary total hip arthroplasties (THAs) and over 28 000 hip prosthesis revisions were performed in France in 2015. The most common reason for revision is aseptic loosening with the release of wear products from the bearing surfaces [1]. Minimising wear would therefore be expected to increase long-term prosthesis survival [2]. In the 1980s, after a study of metal-on-metal (MoM) McKee-Farrar THAs, Weber et al. [3,4] worked with Sulzer Medical Technology (Winterthur, Switzerland) to develop a second-generation small-head MoM implant, whose high carbon content was designed to minimise wear. In the first clinical studies, 10-year survival was 97.9% to revision for any reason and 100% to aseptic loosening [5]. In contrast, when this small-head MoM bearing is used with a cup cemented directly onto the bone with no backing, the risk of loosening is increased [6].

During the same period, stemmed second-generation large-head MoM implants were reported to induce specific complications including adverse reactions to metal debris (ARMDs) such as aseptic lymphocyte-dominated vasculitis-associated lesions (ALVALs), metallosis, and pseudo-tumours [7]; as well as a systemic type IV hypersensitivity reaction with nephrotoxicity and cardiotoxicity [8]. These complications were chiefly reported with large-head MoM implants on a femoral stem (except when used for resurfacing) and were chiefly related to modularity. This type of implant was therefore abandoned, with a manufacturer recall and a recommendation to provide close follow-up to previously treated patients [9]. The rationale for using a large femoral head was that prosthetic hip stability would be improved [2,10]. However, a large head increases the bearing surface area and carries a risk of jamming if the joint is too tight [10]. After a string of failures of large-head implants, the Food and Drug Administration placed all MoM implants in the high-risk category, thereby tarnishing the reputation of MoM bearings, even when used with small-diameter femoral heads [11].

Most studies of small-head MoM implants used an uncemented stem. To our knowledge, no data are available on outcomes seen more than 15 years after small-head (28 mm) MoM THA with a cemented cobalt-nickel-chromium (Co-Ni-Cr) stem, which might increase the risk of complications related both to corrosion of the Morse taper (between the Co-Cr head and the Co-Ni-Cr stem) and to contact -- with potential micro-mobility -- of the cement with the Co-Ni-Cr stem.

The objective of this study was to collect long-term follow-up data on patients who underwent hybrid total hip arthroplasty (THA) with 28-mm MoM Metasul™ bearings in order to assess: 1) long-term survival (based on the revision rate), 2) and the occurrence of ARMDs documented during revision. The working hypothesis was that survival of 28-mm Metasul™ bearings used with hybrid THA is acceptable.

2. Material and Methods

2.1 Patients

This single-centre retrospective study included consecutive patients who underwent MoM THA with 28-mm Metasul™ bearings between June 1995 and December 1999. The study was approved by our institutional review board (#CE-CIC-GREN-09-05).

The study included 115 hips in 106 patients for whom follow-up was at least 17.8 years. Table 1 reports their main features. For each hip, the following were recorded: patient age, sex, body weight, and height; reason for THA; Postel-Merle-d'Aubigné (PMA) score [12]; and radiographic findings. Mean age at surgery was 57.3 ± 7.9 years (range, 29.6-75.3 years). Of the 115 hips, 48 (41.7%) were in females. Mean body mass index was 26.2 ± 2.9 kg/m² (range, 16.4-40.6 kg/m²) (missing for 5 hips). The reason for THA was primary osteoarthritis in 81 (70.4%) hips. In the 34 (29.6%) remaining hips, the cause of secondary osteoarthritis was avascular necrosis of the femoral head in 22 (18.3%) cases, dysplasia in 7 (6.1%) cases,

and post-traumatic osteoarthritis in 5 (4.3%) cases; no patient had inflammatory hip disease. The mean pre-operative PMA score was 11.4 ± 21.8 (range, 6-16) (missing for 8 hips).

2.2 Methods

Seven surgeons performed the THA procedures. The total number of THAs performed in our department during the study period was about 1300. MoM implants were used in patients who were young or had active lifestyles. Patients were asked about a history of renal dysfunction or hypersensitivity to metals. The lateral approach described by Hardinge was used in all patients [13]. All the implants were from Zimmer-Biomet (Warsaw, IN, USA). The femoral component was a cemented self-locking Müller stem made of a Co-Ni-Cr alloy. The bearing couple comprised a 28-mm Metasul™ wrought-forged high-carbon Co-Cr head and a Metasul™ insert housed in a polyethylene sandwich. An uncemented CLS Spotorno cup was used in all cases (Figure 1). The stem was fixed using Palacos-Gentamicin cement (Heraeus, Wehrheim, Germany) composed of polymethylmethacrylate with zirconium as the radiopaque agent.

2.3 Assessment methods

The patients were re-evaluated and their medical files reviewed to obtain the following information: THA revisions with the reasons, clinical and radiological implant survival, and reasons for failure, specific to each implant type. Clinical implant survival was defined as absence of revision surgery and radiological survival as absence of radiological evidence of loosening of the cup, stem, or both [14–16]. Surviving patients were re-evaluated. The surgical reports of revisions were reviewed to determine the reason for the procedure. The patients were categorised based on the Charnley class [17], Devane's activity score [18], PMA score, and Harris Hip Score [19].

Radiographic evidence of loosening was assessed by examining the DeLee and Charnley zones at the cup [20] and the zones described by Gr uen et al. at the stem [21]. Each zone was examined for osteolysis or signs of loosening according to Massin et al. at the cup [14] and Harris et al. at the stem [16]. Loosening was defined as at least 5 mm or 5° of migration for the cup and as varus/valgus displacement or at least 5 mm of migration for the stem. Cup position was described according to Widmer [22]. Cup malposition was defined as inclination outside the 30°-50° safety zone [23]; this criterion was met by 9 (7.8%) hips. Stem malposition defined as varus or valgus was present in 1 (0.9%) hip.

2.4 Statistics

Qualitative data were described as n (%) and quantitative variables as mean±SD. A case-by-case analysis of reasons for failure was performed to look for complications specifically related to the implants and to the patients; the endpoint used to plot the Kaplan-Meier survival curves was revision (aseptic loosening; cup, stem, or both; septic loosening; impingement; or instability). Times to revision were assessed. Missing data were estimated based on the mean value of available data, and the number of cases with missing data was specified.

3. Results

The study included 115 hips, in 106 patients, with a follow-up of at least 17.8 years. At last follow-up, 51 patients had died and 55 were alive. Of the 52 hips in the 51 patients who died, 5 had been revised. The 55 surviving patients, with 63 included hips, were re-evaluated. Figure 2 is the patient flow diagram. Mean follow-up was 20.3±0.8 years (range, 17.8-21.6 years).

In all, 16 (13.9%) THAs were revised, in 15 patients, 11 survivors and 5 non-survivors. The reasons for revision were as follows: loosening of both components (n=1, 0.9%) or of the cup (n=7, 6.1%), infection (n=3, 2.6%), ilio-psoas irritation (n=3, 2.6%), and recurrent dislocation (n=2, 1.7%) (Table 2). No patient experienced stem loosening. Joint aspiration was performed routinely before revision surgery to test for infection.

After 17.8 years, survival to revision for any reason was 86.1% (95%CI, 79.8-92.4) and survival to revision for aseptic loosening was 92.6% (95%CI, 87.7-97.6) (Figures 3 and 4). At the same time point, survival without radiological evidence of aseptic or septic loosening was 86.9% (95%CI, 80.6-93.3). Mean time from primary THA to revision was 11.4±8.1 years (range, 5 days to 21.5 years).

Mean initial cup inclination was 43.7°±4.6 ° (range, 30°-60°) (missing for 1 hip). Cup malposition did not correlate with survival: revision was required for 3 of 13 hips with cup malposition and 13 of 102 hips with good cup position (log-rank test, $p=0.296$). Mean age at last follow-up was 75.2±7.6 years (range, 50.6-90.5 years). Table 3 reports the data on Charnley class, Devane's activity score, clinical scores, and quality-of-life scores.

Migration of more than 5 mm was noted for 2 cups. Migration did not occur for any of the stems. Table 4 shows the data on osteolysis and loosening.

Ilio-psoas irritation and instability were among the reasons for revision. In 3 hips, the Spotorno cup impinged on the ilio-psoas muscle. Early loosening of the MoM Metasul™ cup occurred in 2 cases.

Intra-operative specimens obtained during 14 (87.5%) of the 16 revision procedures were examined histologically. Metal debris were found consistently. In addition, a macrophage reaction and a non-specific inflammatory infiltrate were evidenced in 7 (50%) cases.

4. Discussion

Our results confirm our working hypothesis: MoM THA with the 28-mm Metasul™ implant had a low revision rate. Complications specifically related to the MoM bearing can occur, although none were recorded in our population. Hard-on-hard bearings can be beneficial in young, physically active patients at risk for wear and aseptic loosening due to polyethylene damage. However, the use of MoM bearings is declining in response to reports of complications seen with large-head implants, which are dominated by ARMDs caused by corrosion of the modular head-neck junction or by poor tribological performance.

We obtained data over a long follow-up of at least 17.8 years, with a mean of 20.3 ± 0.8 years (range, 17.8-21.6 years) for the clinical and radiological evaluations. Survival rates were 86.1% to revision for any reason and 92.6% to revision for aseptic loosening. We are aware of a single study with a follow-up of more than 15 years after 28-mm MoM THA [24]. After 18 years, survival rates were 87% (95%CI, 82.6-91.4) to revision for any reason and 93% (95%CI, 89.5-96.5) to revision for aseptic loosening. Table 5 [24–29] shows the results of the main studies of MoM THA. In meta-analyses of comparative studies of MoM THA, revision rates were far higher than with other bearing couples. However, no difference was made in these studies between small-head second-generation Metasul™ implants and large-head implants. Some studies documented good outcomes of cementless MoM THA, notably in young patients [30]. We have no explanation for the fairly high infection rate of 2.6% in our study. Infection was one of the main reasons for revision in our patients. Another was the design of the Spotorno cup with fins that can impinge on the ilio-psoas muscle or break off [31,32]. The exact frequency of this last event in our cohort could not be determined.

Survival studies of implants with other bearing couples should be discussed separately. With ceramic-on-ceramic bearings, Kim et al. [33] found that the 15-year rate of survival to revision for aseptic loosening was 100%, while Higuchi et al. [34] reported an 8-year survival

rate of 98.2% with ceramic-on-ceramic versus 98.6% with MoM implants. In a study by Halley et al. [35] of metal-on-polyethylene bearings, 20-year survival to revision for any reason was 85.4%. A randomised comparison of ceramic-on-ceramic and MoM bearings by Desmarchelier et al. [36] found similar 9-year survival rates in the two groups.

The analysis of reasons for failure identified complications specifically related to this type of implant, namely, overhang related to the design of the uncemented Spotorno cup, with soft-tissue impingement, and cup fin breakage. No cases of pseudo-tumour were recorded.

The limitations of our study should be acknowledged. Given the retrospective design, the comparisons of assessment scores were confined to a single time point. No randomisation was performed, the study population was heterogeneous, and no sample size estimation was performed. The 5.7% proportion of hips lost to follow-up may have affected the results, if the results in the missing patients were unfavourable. Most of the previously published studies of the Metasul™ implant included young patients with high levels of physical activity. Mean age at primary THA was only 57.3 years in our study, but data on the baseline level of activity were not collected. All hips in our study were managed using a cemented stem, whereas all the previous studies of small-head MoM THA used cementless stems (Table 5). Only 1 of our patients experienced stem loosening, and the stem survival rate was 99% after over 17 years, confirming the good performance of the cemented stem used in our study [37]. The total number of hips with ilio-psoas irritation was not recorded. However, ilio-psoas irritation was the reason for revision in 3 of 16 cases, and the frequency of this complication may have been underestimated. Recommendations about monitoring patients after MoM THA include blood metal ion assays and, in some cases, magnetic resonance imaging or ultrasonography. Blood metal ion levels were not determined routinely in our patients and were therefore not included among the study parameters, which may have resulted in underestimation of the complication rate. Nonetheless, the French High Authority for Health (HAS) does not recommend routine

metal ion assays in patients with 28-mm heads. Metal ion assays are highly specific tests whose results vary across laboratories, although a maximum value of 7 µg/L is widely accepted for MoM THA [38,39]. Analysing the outcomes according to neck length might have identified differences. Slice imaging (ultrasound or magnetic resonance imaging) was not performed routinely in asymptomatic patients. Although this constitutes a limitation, routine slice imaging would have resulted in excessive costs. The radiopaque agent in the cement was zirconium, which can release zircon crystal debris, a point that was not investigated in our study. Despite these limitations, our large and comprehensive study with a very long follow-up provides an overall picture of the outcomes of the severely criticised MoM implant design.

5. Conclusion

Long-term survival of the 28-mm MoM Metasul™ implant was very close to that of metal-on-polyethylene bearings and lower than that of ceramic-on-ceramic or MoM Metasul™ bearings in previous studies. The complication rate in our study was lower than expected, and no complications specific of MoM bearings were recorded. Clinical and radiological follow-up must be provided at regular intervals throughout the lifespan of this type of hip implant. We have stopped using these implants because of the potential risk of ARMDs, although none of these were observed in the present study. The use of a cemented Co-Ni-Cr stem in combination with Metasul™ bearings did not cause any specific complications.

Disclosure of interest: None of the authors has any conflicts of interest to declare in relation with this study. Stéphane Boisgard is a consultant for Zimmer.

Funding: None

Contributions of each author: RE contributed to design the study and to draft and revise the manuscript. GV contributed to draft and revise the manuscript. TL contributed to design the study, re-evaluate the patients, and draft the manuscript. AM performed the statistical analysis. SD contributed to supervise the study and to perform the surgical procedures. SB contributed to supervise the study and to perform the surgical procedures.

References

- [1] Willert HG, Semlitsch M. Reactions of the articular capsule to wear products of artificial joint prostheses. *J Biomed Mater Res* 1977;11:157–64.
- [2] Rieker CB. Tribology of total hip arthroplasty prostheses: What an orthopaedic surgeon should know. *EFORT Open Rev* 2016;1:52–7.
- [3] McKee GK, Watson-Farrar J. Replacement of arthritic hips by the McKee-Farrar prosthesis. *J Bone Joint Surg Br* 1966;48:245–59.
- [4] Weber BG. Experience with the Metasul total hip bearing system. *Clin Orthop Relat Res* 1996:S69-77.
- [5] Delaunay CP. Metal-on-metal bearings in cementless primary total hip arthroplasty. *J Arthroplasty* 2004;19:35–40.
- [6] Nich C, Rampal V, Vandebussche E, Augereau B. Metal-metal-backed polyethylene cemented hip arthroplasty: mid-term results. *Rev Chir Orthop* 2006;92:118–24.
- [7] Langton DJ, Jameson SS, Joyce TJ, Hallab NJ, Natu S, Nargol AVF. Early failure of metal-on-metal bearings in hip resurfacing and large-diameter total hip replacement: A consequence of excess wear. *J Bone Joint Surg Br* 2010;92:38–46.
- [8] Drummond J, Tran P, Fary C. Metal-on-metal hip arthroplasty: A review of adverse reactions and patient management. *J Funct Biomater* 2015;6:486–99.
- [9] Hannemann F, Hartmann A, Schmitt J, Lützner J, Seidler A, et al. European multidisciplinary consensus statement on the use and monitoring of metal-on-metal bearings for total hip replacement and hip resurfacing. *Orthop Traumatol Surg Res* 2013;99:263–71.
- [10] Fehring TK, Odum S, Sproul R, Weathersbee J. High frequency of adverse local tissue reactions in asymptomatic patients with metal-on-metal THA. *Clin Orthop Relat Res* 2014;472:517–22.

- [11] Cohen D. How safe are metal-on-metal hip implants? *BMJ* 2012;344:e1410.
- [12] Merle D'Aubigné R. Numerical classification of the function of the hip. 1970. *Rev Chir Orthop* 1990;76:371–4.
- [13] Hardinge K. The direct lateral approach to the hip. *J Bone Joint Surg Br* 1982;64:17–9.
- [14] Massin P, Schmidt L, Engh CA. Evaluation of cementless acetabular component migration. An experimental study. *J Arthroplasty* 1989;4:245–51.
- [15] Nunn D, Freeman MA, Hill PF, Evans SJ. The measurement of migration of the acetabular component of hip prostheses. *J Bone Joint Surg Br* 1989;71:629–31.
- [16] Harris WH, McCarthy JC, O'Neill DA. Femoral component loosening using contemporary techniques of femoral cement fixation. *J Bone Joint Surg Am* 1982;64:1063–7.
- [17] Charnley J. Total hip replacement by low-friction arthroplasty. *Clin Orthop Relat Res* 1970;72:7–21.
- [18] Devane PA, Horne JG, Martin K, Coldham G, Krause B. Three-dimensional polyethylene wear of a press-fit titanium prosthesis. Factors influencing generation of polyethylene debris. *J Arthroplasty* 1997;12:256–66.
- [19] Harris WH. Traumatic arthritis of the hip after dislocation and acetabular fractures: treatment by mold arthroplasty. An end-result study using a new method of result evaluation. *J Bone Joint Surg Am* 1969;51:737–55.
- [20] DeLee JG, Charnley J. Radiological demarcation of cemented sockets in total hip replacement. *Clin Orthop Relat Res* 1976:20–32.
- [21] Gruen TA, McNeice GM, Amstutz HC. “Modes of failure” of cemented stem-type femoral components: a radiographic analysis of loosening. *Clin Orthop Relat Res* 1979:17–27.
- [22] Widmer K-H. A simplified method to determine acetabular cup anteversion from plain radiographs. *J Arthroplasty* 2004;19:387–90.

- [23] Lewinnek GE, Lewis JL, Tarr R, Compere CL, Zimmerman JR. Dislocations after total hip-replacement arthroplasties. *J Bone Joint Surg Am* 1978;60:217–20.
- [24] Ayoub B, Putman S, Cholewinski P, Paris A, Migaud H, Girard J. Incidence of adverse reactions to metal debris from 28-mm metal-on-metal total hip arthroplasties with minimum 10 years of follow-up: Clinical, laboratory, and ultrasound assessment of 44 cases. *J Arthroplasty* 2017;32:1206–10.
- [25] Lass R, Gröbl A, Kolb A, Domayer S, Csuk C, Kubista B, et al. Primary cementless total hip arthroplasty with second-generation metal-on-metal bearings: a concise follow-up, at a minimum of seventeen years, of a previous report. *J Bone Joint Surg Am* 2014;96:e37.
- [26] Tardy N, Maqdes A, Boisrenoult P, Beaufils P, Oger P. Small diameter metal-on-metal total hip arthroplasty at 13 years - a follow-up study. *Orthop Traumatol Surg Res* 2015;101:929–36.
- [27] Randelli F, Banci L, D’Anna A, Visentin O, Randelli G. Cementless Metasul metal-on-metal total hip arthroplasties at 13 years. *J Arthroplasty* 2012;27:186–92.
- [28] Delaunay C, Petit I, Learmonth ID, Oger P, Vendittoli PA. Metal-on-metal bearings total hip arthroplasty: The cobalt and chromium ions release concern. *Orthop Traumatol Surg Res* 2010;96:894–904.
- [29] Innmann MM, Gotterbarm T, Kretzer JP, Merle C, Ewerbeck V, Weiss S, et al. Minimum ten-year results of a 28-mm metal-on-metal bearing in cementless total hip arthroplasty in patients fifty years of age and younger. *Int Orthop* 2014;38:929–34.
- [30] Migaud H, Putman S, Krantz N, Vasseur L, Girard J. Cementless metal-on-metal versus ceramic-on-polyethylene hip arthroplasty in patients less than fifty years of age: a comparative study with twelve to fourteen-year follow-up. *J Bone Joint Surg Am* 2011;93 Suppl 2:137–42.

- [31] Smeekees C, de Witte PB, Ongkiehong BF, van der Wal BCH, Barnaart AFW. Long-term results of total hip arthroplasty with the CementLess Spotorno (CLS) system. *Hip Int* 2017;27:465–71.
- [32] Terré RA. Estimated survival probability of the Spotorno total hip arthroplasty after a 15- to 21-year follow-up: one surgeon's results. *Hip Int* 2010;20 Suppl 7:S70-78.
- [33] Kim YH, Park JW, Kim JS. Long-term results of third-generation ceramic-on-ceramic bearing cementless total hip arthroplasty in young patients. *J Arthroplasty* 2016;31:2520–4.
- [34] Higuchi Y, Seki T, Takegami Y, Komatsu D, Morita D, Ishiguro N. Same survival but higher rate of osteolysis for metal-on-metal Ultamet versus ceramic-on-ceramic in patients undergoing primary total hip arthroplasty after 8 years of follow-up. *Orthop Traumatol Surg Res* 2018;104:1155–61.
- [35] Halley DK, Glassman AH. Twenty- to twenty-six-year radiographic review in patients 50 years of age or younger with cemented Charnley low-friction arthroplasty. *J Arthroplasty* 2003;18:79–85.
- [36] Desmarchelier R, Viste A, Chouteau J, Lerat JL, Fessy MH. Metasul vs Cerasul bearings: a prospective, randomized study at 9 years. *J Arthroplasty* 2013;28:296–302.
- [37] Erivan R, Villatte G, Khelif YR, Pereira B, Galvin M, Descamps S, et al. The Müller self-locking cemented total hip prosthesis with polyethylene liner: After twenty years, what did they become? *Int Orthop* 2016.
- [38] Lardanchet JF, Taviaux J, Arnalsteen D, Gabrion A, Mertl P. One-year prospective comparative study of three large-diameter metal-on-metal total hip prostheses: serum metal ion levels and clinical outcomes. *Orthop Traumatol Surg Res* 2012;98:265–74.
- [39] Reito A, Lainiala O, Nieminen J, Eskelinen A. Repeated metal ion measurement in patients with bilateral metal on metal (ASR™) hip replacements. *Orthop Traumatol Surg Res* 2016;102:167–73.

FIGURE LEGENDS

Figure 1. Antero-posterior radiographs of the pelvis pre-operatively and hip post-operatively; metal-backed CLS Spotorno™ cup and cemented Müller stem (Zimmer-Biomet). **1a:** pre-operative radiograph. **1b:** early post-operative radiograph. **1c:** radiograph after 1 year. **1d:** radiograph at last follow-up after 19 years.

Figure 2. Patient flow diagram (MoM: Metal on Metal bearing, THA: Total Hip Arthroplasty).

Figure 3. Abnormal antero-posterior radiographs: retro-acetabular osteolysis on the right. **3a:** pre-operative radiograph. **3b:** early post-operative radiograph. **3c:** radiograph after 1 year. **3d:** radiograph at last follow-up after 13 years: breakage of a fin of the Spotorno cup may have promoted retro-acetabular osteolysis with separation of the polyethylene from the metal backing.

Figure 4. Survival rates with their 95% confidence intervals. **4a:** survival to revision for any reason. **4b:** survival to revision for aseptic loosening.

Cumulative survival
Time to all-cause revision (years)

Cumulative survival
Time to revision for aseptic loosening (years)

Table 1: Demographic and clinical features before total hip arthroplasty

Total = 115 hips	
<i>Demographic features</i>	
Age, years, mean±SD (range)	57.3 ± 7.9 (29.6 – 75.3)
Females, n (%)	48 (41.7)
BMI, kg/m ² , mean±SD (range)	26.2 ± 2.9 (16.4 – 40.6) (data missing for 5 hips)
<i>Clinical features</i>	
Primary osteoarthritis, n (%)	81 (70.4%)
Secondary osteoarthritis, n (%)	34 (29.6%)
Right hip involved, n (%)	69 (60.0%)
PMA [12], mean±SD (range)	11.4 ± 1.8 (6 – 15) (data missing for 8 hips)

BMI, body mass index; SD, standard deviation, PMA, Postel-Merle d’Aubigné score [12]

Table 2: Details on the 16 revision procedures

Reason for revision	Time to revision	Intra-operative findings	Treatment
Infection	30 days	Staphylococcal infection	Simple irrigation with head and insert exchange
Infection	45 days	Staphylococcal infection	Simple irrigation with head and insert exchange
Infection	60 days	Staphylococcal infection	Simple irrigation with head and insert exchange
Cup loosening	9 months	Cup migration	Cup exchange
Ilio-psoas irritation	1 year	Impingement of cup fin	Cup exchange
Ilio-psoas irritation	1.2 year	Impingement of cup fin	Cup exchange
Cup loosening	6.9 years	Cup loosening	Cup exchange
Ilio-psoas irritation	7.6 years	Impingement of cup fin	Cup exchange
Cup loosening	8.5 years	Cup loosening	Cup exchange
Cup loosening	8.9 years	Cup loosening	Cup exchange
Recurrent dislocation	10.9 years	Cup malposition	Cup exchange + longer neck
Cup and stem loosening	11 years	Cup and stem loosening	Exchange of both components
Cup loosening	11.5 years	Cup loosening	Cup exchange
Recurrent dislocation	13.7 years	Implant malposition	Exchange of both components
Cup loosening	17.3 years	Cup loosening	Cup exchange
Cup loosening	20.2 years	Cup loosening	Cup exchange

Table 3: Charnley class [17], Devane’s activity score [18], and clinical scores at last follow-up

Charnley class, n (%) n=51 patients without revision (missing data, n=1)	A 2 (3.9%)	B 27 (52.9%)	C 22 (43.1%)		
Devane’s activity score [18], n (%) n=51 patients without revision (missing data, n=1)	I 8 (15.7%)	II 19 (37.3%)	III 19 (37,3%)	IV 5 (9.8%)	V 0 (0%)
PMA score [12], mean±SD (range) (missing data, n=1)	15.3 ± 2.8 (6-18)				
Harris Hip Score [19], mean±SD (range) (missing data, n=1)	77.5 ± 18.8 (24-95)				

SD, standard deviation; PMA, Postel-Merle d’Aubigné

Table 4: Cases of osteolysis and loosening

	Stem	Cup	Total
Osteolysis	6	5	11
Loosening	1	8	9
Total	7	13	20

Table 5: Published studies of survival of the Metasul™ implant

First author; Follow-up	Survival to revision for any reason, % [95% CI]	Survival to revision for aseptic loosening, % [95% CI]
Innmann et al. [29], 13 years	90.9% [80.9-95.8]	98.8% [92.5-99.8]
Tardy et al. [26], 13 years	79.3% [68.7-91.5]	87.6% [77.3- 9.3]
Randelli et al. [27], 14 years	94% [89-97]	97% [93-99]
Delaunay et al. [28], 15 years	96% [81-99]	99% [85-99..9]
Ayoub et al. [24], 15 years	95.7% [94.1-98.9]	95.7% [94-98.9]
Lass et al. [25], 18 years	87% [82.6-91.4]	93% [89.5-93.5]
Our study	86.1% [79.8-92.4]	92.6% [87.7-97.6]

95%CI, 95% confidence interval

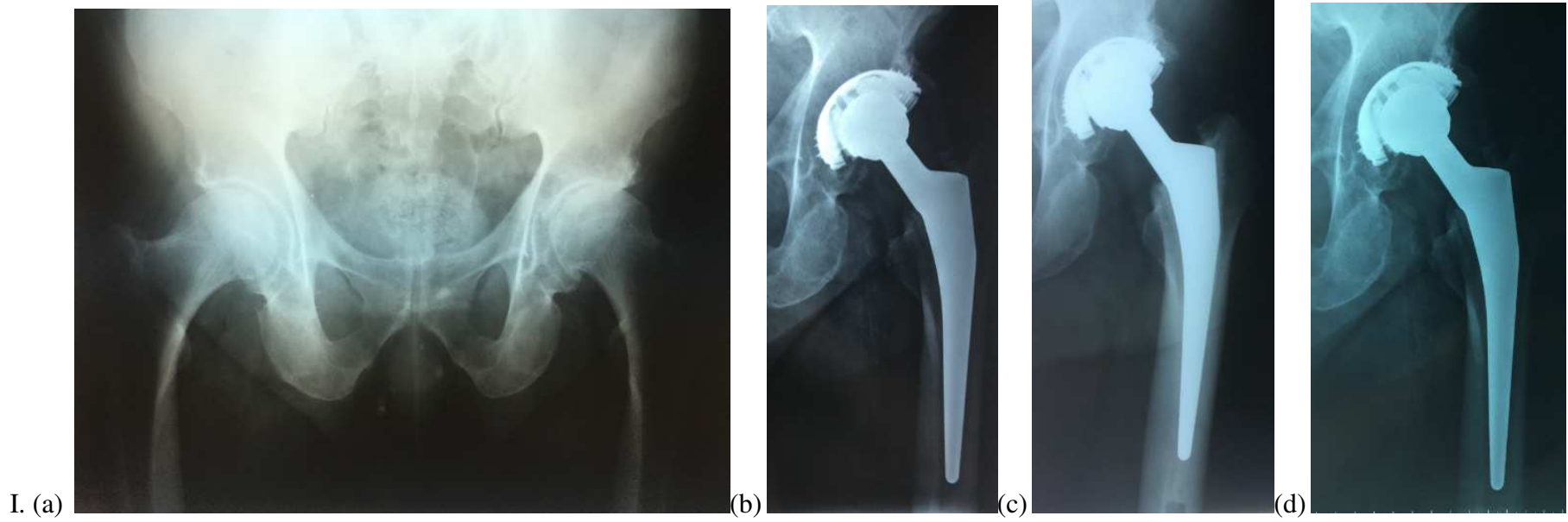


Figure 1:

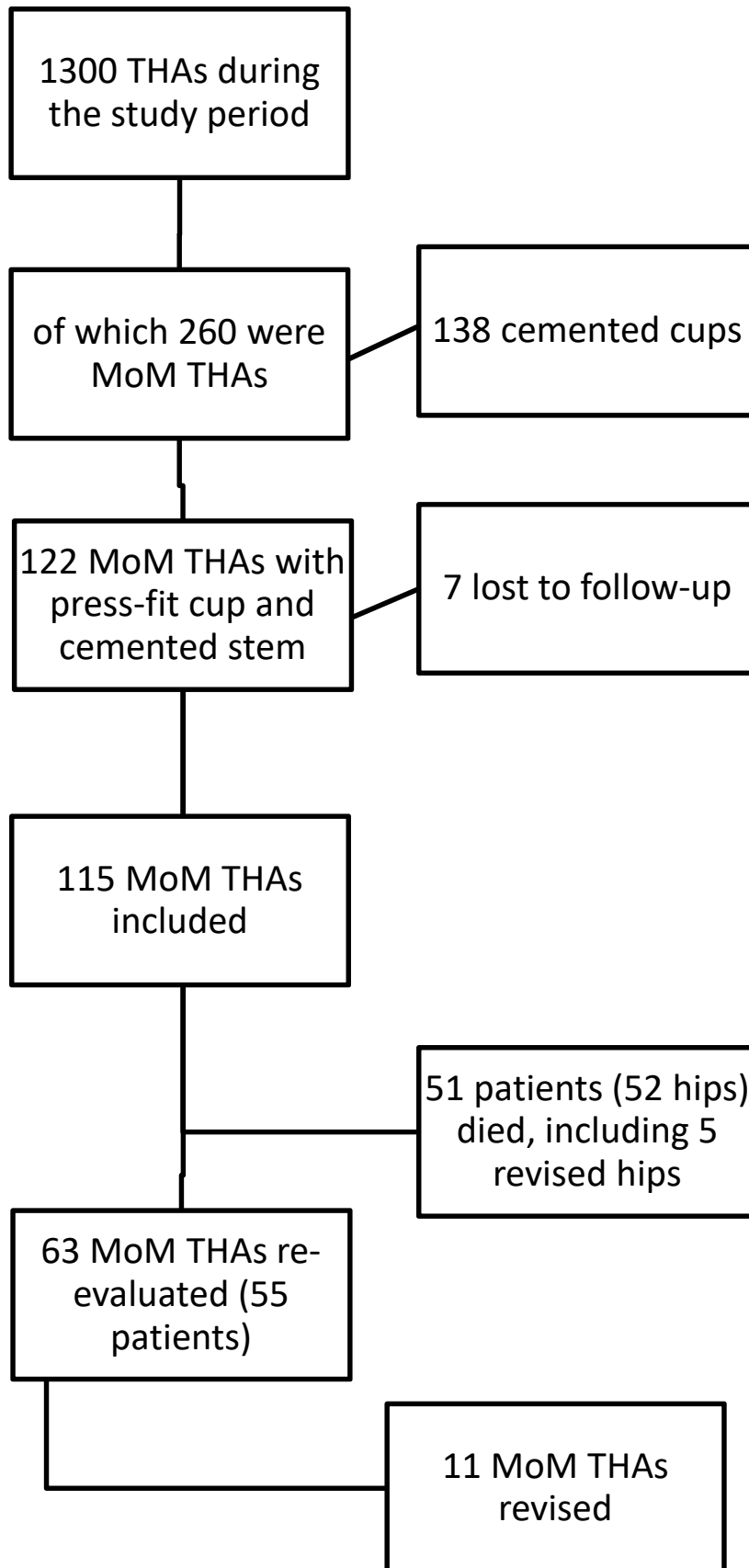


Figure 2 : Patient flow diagram

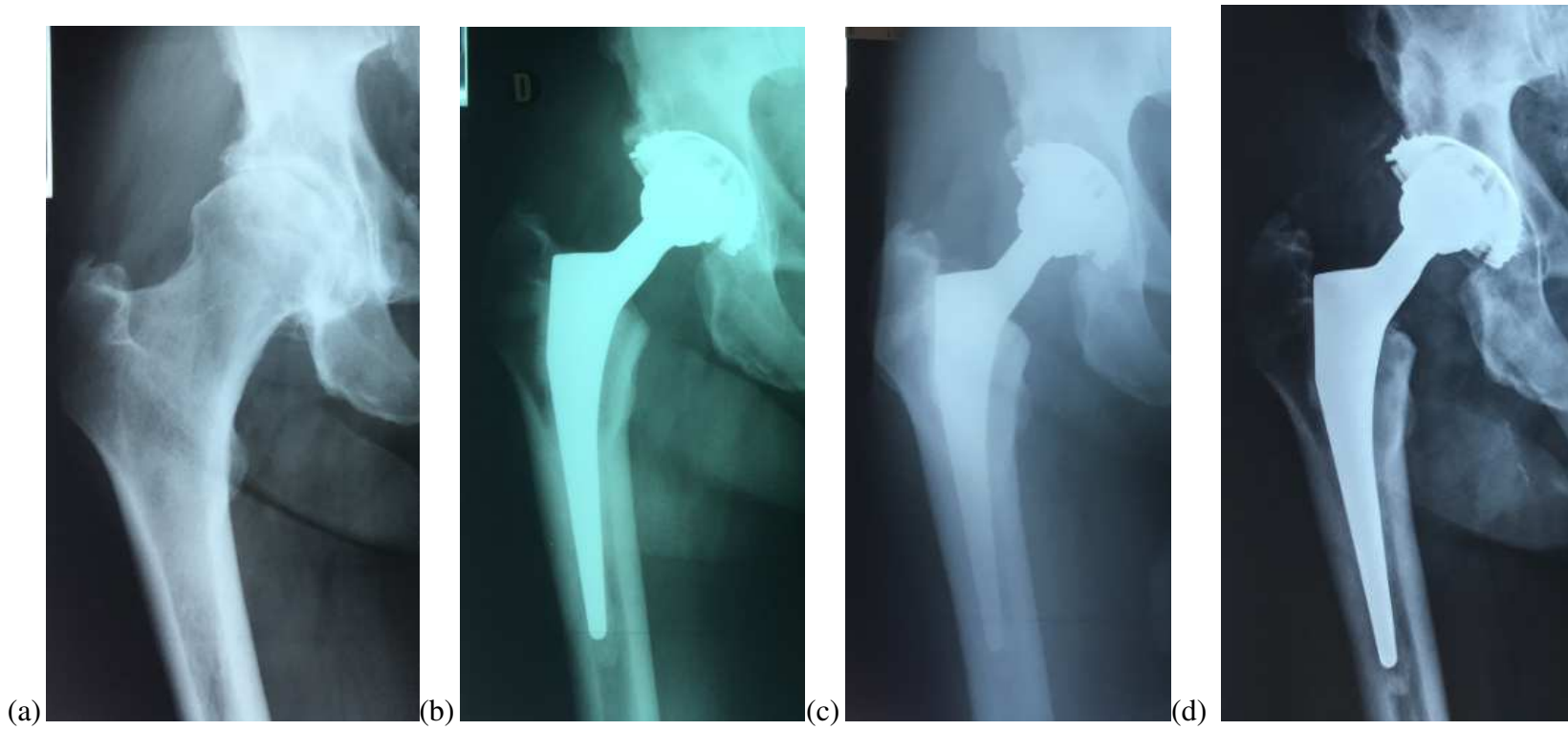
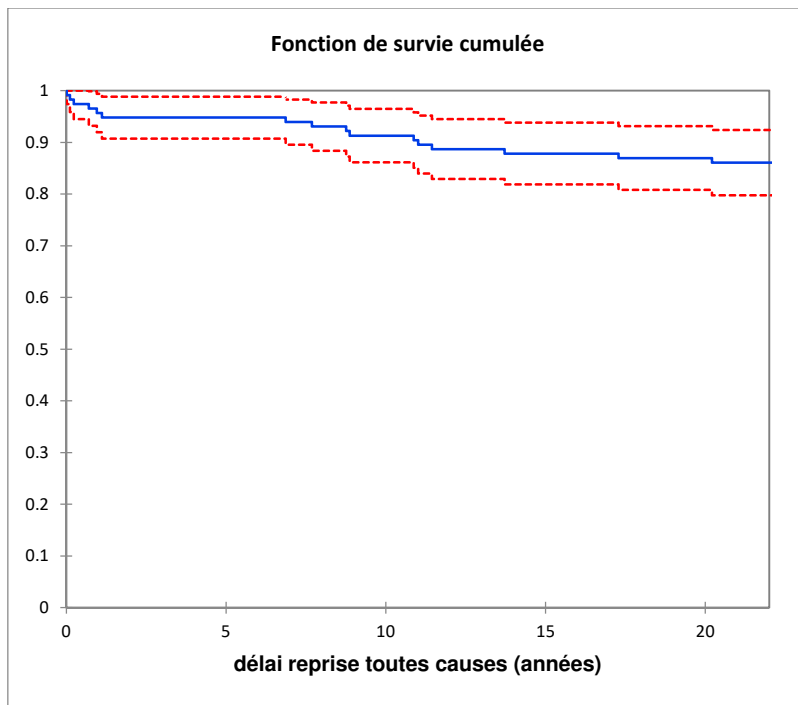
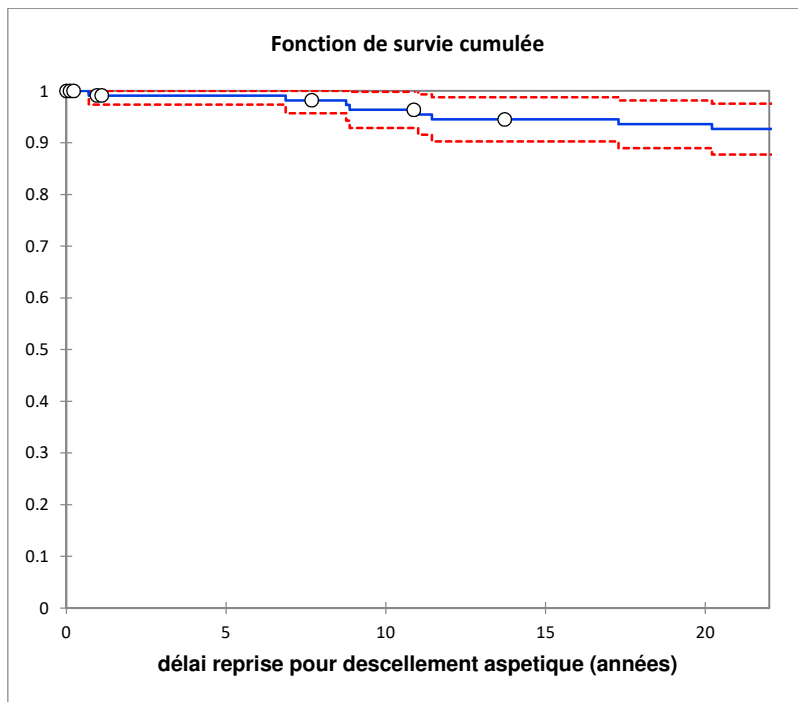


Figure 3:



A.



B

Figure 4: