



HAL
open science

Unusual clinical description of adult with Timothy syndrome, carrier of a new heterozygote mutation of CACNA1C

Cindy Colson, Hervé Mittre, Adeline Busson, Antoine Leenhardt, Isabelle Denjoy, Véronique Fressard, Yann Troadec

► To cite this version:

Cindy Colson, Hervé Mittre, Adeline Busson, Antoine Leenhardt, Isabelle Denjoy, et al.. Unusual clinical description of adult with Timothy syndrome, carrier of a new heterozygote mutation of CACNA1C. European Journal of Medical Genetics, 2019, 62 (7), pp.103648. 10.1016/j.ejmg.2019.04.005 . hal-02393710

HAL Id: hal-02393710

<https://hal.science/hal-02393710>

Submitted on 25 Oct 2021

HAL is a multi-disciplinary open access archive for the deposit and dissemination of scientific research documents, whether they are published or not. The documents may come from teaching and research institutions in France or abroad, or from public or private research centers.

L'archive ouverte pluridisciplinaire **HAL**, est destinée au dépôt et à la diffusion de documents scientifiques de niveau recherche, publiés ou non, émanant des établissements d'enseignement et de recherche français ou étrangers, des laboratoires publics ou privés.



Distributed under a Creative Commons Attribution - NonCommercial 4.0 International License

1 Unusual clinical description of adult with Timothy syndrome, carrier of a new heterozygote mutation
2 of *CACNA1C*
3
4 Cindy Colson^{1,2}, Hervé Mitre³, Adeline Busson³, Antoine Leenhardt⁵, Isabelle Denjoy⁵, Véronique
5 Fressard⁶, Yann Troadec^{1,2}

6 ¹ Service Génétique, Génétique Clinique, CHU Caen, France

7 ² Normandy University, UNICAEN, BIOTARGEN, Caen, France

8 ³ Service Génétique, Génétique Moléculaire, CHU Caen, France

9 ⁴ Service de Génétique Clinique, Hôpital Erasme Bruxelles, Belgique

10 ⁵ Service de cardiologie, Hôpital Xavier Bichat-Claude Bernard Paris, France

11 ⁶ Centre de génétique moléculaire et chromosomique, UF cardiogénétique et myogénétique moléculaire
12 et cellulaire, Hôpital Pitié-Salpêtrière Paris, France

13

14 **Corresponding author:**

15 Cindy Colson

16 Service Génétique, Génétique Clinique, CHR Clémenceau – CHU, 14033 Caen cedex, France

17 Tel: 00231272569

18 Fax: 00231272457

19 Email: colson-c@chu-caen.fr

20

21 **Conflict of interest:** The authors declare no conflict of interest.

22 **Abstract**

23 *CACNA1C* encodes for the main cardiac L-type calcium channel and mutations on it lead to a prolonged
24 QT interval in Timothy Syndrome (TS). We provide a new *de novo* constitutional heterozygote missense
25 variation in *CACNA1C* in a living adult woman, also carrier of the known c.2146-1G>C heterozygous
26 variation of *PKP2* inherited from her father. To our knowledge, this patient is the first to have the two
27 variations in these genes. These clinical and molecular findings expand the clinical and molecular
28 spectrum of TS and show the interest of next generation sequencing or whole exome sequencing in rare
29 disorders, atypical or novel phenotype.

30 **Introduction**

31 Timothy syndrome 1 (TS1) is a rare genetic disorder characterized by associated features such as
32 prolonged QT interval, cardiopathy, hand and foot syndactyly, variable facial dysmorphism, immune

33 deficiency, intermittent hypoglycemia and neurocognitive trouble. This autosomal dominant syndrome
34 is recurrently caused by a heterozygous p.Gly406Arg mutation, in the alternative spliced exon 8A of the
35 *CACNA1C* gene, encoding for the main cardiac L-type calcium channel. Along with p.Gly402Ser,
36 p.Gly406Arg is also responsible for Timothy Syndrome 2 (TS2) with usually absence of syndactyly
37 [1,2,3,4,5]. Other rare mutations have been reported: p.Ala1473Gly and p.Ile1166thr in TS1 [6,7,8].
38 Usually, life expectancy is very short due to the severity of this syndrome for the patients who carry the
39 homogeneous constitutional mutation [9,10]. One of the oldest patients alive published with TS is 24
40 years old and carries the canonic p.Gly406Arg mutation. She presented very mild TS1 with prolonged
41 QTc and mild learning difficulties [11]. Attenuated phenotype has been exposed in mosaic form of TS
42 [9,12,13,14]. We describe a novel *de novo* heterozygous variant p.Glu407Ala in *CACNA1C* identified
43 by the analysis of genes implicated in heart rhythm diseases, on a patient suffering of an first-degree
44 atrioventricular block, ventricular tachycardia and important QT prolongation at 640ms. Phenotypical
45 revision of the proband allowed to classify her in TS1. This case reports the natural history of an adult
46 TS with novel *de novo* heterozygous *CACNA1C* variation and expands the clinical and molecular
47 spectrum of TS. It also shows the significant contribution of targeted NGS in diagnosing rare or atypical
48 diseases and the importance of clinicobiologic discussion leading to classify a variant, in order to
49 conclude on its pathogenicity.

50

51 **Keywords**

52 Timothy; *CACNA1C*; adult; c.1220A>C; *PKP2*

53

54

55 **Clinical report**

56 The proband is 22-year-old girl. She was born as a first of three children to a healthy young Caucasian
57 couple. There was neither report of consanguinity nor premature sudden cardiac death nor arrhythmic
58 disorders nor neurocognitive disorders in the medical family history. She was born eutrophic at term
59 following good pregnancy. The neonatal follow-up was uncomplicated. At 6 months she presented
60 sudden collapse several times a day, more or less associated with convulsive movements. At first, the
61 diagnostic of epilepsy was retained and treatment with Depakine was instituted. However, the sudden
62 collapses persisted and she was addressed to a cardiologist at three years old. Echocardiogram revealed
63 normal cardiac structure and function. ECG identified: a corrected QT interval slightly prolonged to 440

64 ms and reaching 640 ms on Holter monitoring at night, an atrioventricular block and ventricular
65 tachycardia episodes. Long QT syndrome (LQTS) was concluded. Beta-blockers were then prescribed.
66 The treatment was not completely effective with the persistence of syncope. ECGs performed on both
67 her brothers and parents were normal. Sanger sequencing of all introns close to the coding regions of
68 *KCNQ1*, *HERG (KCNH2)* and *SCN5A* was negative. Because of the persistence of syncope, an internal
69 pacemaker was implanted at six and an automated internal cardioverter defibrillator (AICD) at seven
70 years old.

71 **Ethics statement**

72 This study analysis was conducted according to the Declaration of Helsinki with written consent to use
73 clinical data and photographs for research purposes obtained from the patient and her parents.

74 **Genetic analysis**

75 A rhythmologic genes panel (*CASQ2*, *CALM1*, *DSC2*, *DSG2*, *DSP*, *KCNE1*, *KCNE2*, *KCNQ1*, *KCNH2*,
76 *KCNJ2*, *LMNA*, *NKX2-5*, *PKP2*, *RYR2*, *SCN5A*, *TRDN*, *CACNA1C* genes) using next generation
77 sequencing techniques on MiSeq (Illumina, San Diego CA), was performed on genomic DNA extracted
78 from leucocyte of peripheral blood using standard techniques. It studied all exons and flanking intronic
79 region of all genes and identified two heterozygous variations on *CACNA1C* (NM_199460.3) and *PKP2*
80 (NM_004572.3) genes. In the *CACNA1C* gene, a missense variant c.1220A>C in exon 9 was found,
81 predicting an amino acid substitution of an alanine (hydrophilic amino acid) for a glutamine
82 (hydrophobic amino acid with loss of a negative charge) at codon 407 (p.Glu407Ala). This mutation
83 had never been reported before and was missing from the gnomAD exomes database. Assessments of
84 pathogenicity obtained with PolyPhen indicated 100% probability of damaging (1 out of 1). It is the
85 same with other sites (Varsome). Multiple sequence alignments of the mutated region of Cav1.2 protein
86 (OMIM: Q13936- 12) showed a high conservation in many available species. The mutation affects the
87 first codon of the constitutive splicing exon 9 meaning the amino acid downstreams from the one
88 involved in the recurrent mutation p.Gly406Arg. The topological position of the variation in channel
89 architecture is very similar to the position of the original TS mutation. Indeed, the two variation
90 p.Gly406arg and p.Glu407Ala are located in the cytoplasmic DI-DII loop of the channel. p.Glu407Ala

91 leads to structural modifications in channel architecture with an additional alpha helix in the ion
92 transport domain (Figure 1). The patient's mother and father did not carry the variant, indicating a *de*
93 *novo* variant occurrence. In the *PKP2* gene, c.2146-1G>C variation known as responsible for
94 arrhythmogenic right ventricular dysplasia was found, inherited from her father (Figure 2). The two
95 variations were validated by Sanger sequencing (Supplemental data, Figure 1). According to the
96 American College of Medical Genetics 2015 guidelines, *CACNA1C* variation was classified as likely
97 pathogenic (LP) and *PKP2* variation as pathogenic.

98 *A posteriori*, clinical history was marked by mild learning difficulties requiring adapted school
99 orientation with speech therapy and an history of seizures. Cerebral tomodensitometry was normal. To
100 date, there are no signs of a psychiatric disorder. Her physical examination showed cutaneous syndactyly
101 on both hands with hypermobility and partial syndactyly of the 2nd-3rd toes bilaterally. She does not
102 suffer from other musculoskeletal abnormalities and does not have specific craniofacial dysmorphism.
103 Furthermore, laboratory finding did not reveal hypoglycemia and neither hypocalcemia, hypothyroidism
104 nor abnormal immunity. Fragile X testing and Array Comparative Genomic Hybridization were
105 negative. The variant was interpreted as causing the disease and the patient was given the diagnosis of
106 TS.

107 **Discussion**

108 We report an unusual case of homogeneous adult Timothy syndrome with *de novo* novel heterozygous
109 *CACNA1C* variation. She presented severe cardiac phenotype with incomplete TS1 features and the
110 known c.2146-1G>C heterozygous inherited variation of *PKP2*. The fact that the rhythmologic genes
111 panel was not targeted on the known deleterious regions of *CACNA1C* allowed us to diagnose this
112 disease.

113 Next generation sequencing is useful for genetic etiology in patients with rare non-classic phenotypes
114 but results could be difficult to analyze. The assessment of the pathogenicity of the variant on several
115 sites (gnomAD exomes database, PolyPhen, Varsome), the neomutation and the topography of the
116 variation in front of p.Gly406Arg are in favor of very high probability of a damaging effect of the
117 mutation. However, functional expressional studies are required to definitively confirm the disease-

118 causing effect of the p.Glu407Ala mutation. Moreover physical examination and the patient medical
119 history helped to classify the disease as an atypical TS1 rather than a TS2.

120 To our knowledge, it is the first description of a variation in exon 9 of *CACNA1C* in TS. Another
121 variation in exon 9 of *CACNA1C* (c.1368G>A, p.Met456Ile) had been detected in a patient with
122 diagnosed long QT syndrome [15]. Exon 9 is not alternatively spliced and is therefore C (likely
123 constitutively expressed. It has multi-organ expression in multiple adult and fetal tissues including
124 heart and brain. p.Ala1473Gly in exon 38 is also constitutively expressed, that may likely be in favor of
125 the more severe phenotype seen in their patient who manifested prolonged QT interval, polymorphic
126 ventricular tachycardia, dysmorphic facial features, syndactyly of the hands and feet, joint contractures,
127 seizures and developmental delay [6]. p.Ile1166Thr in exon 27 was found by whole exome sequencing
128 in case with severe atypical TS who exhibited QT prolongation, patent ductus arteriosus, seizures, facial
129 dysmorphism, joint hypermobility, hypotonia, hand anomalies (clinodactyly and short thumbs),
130 intellectual impairment and tooth decay [8]. Our case seems less severe, especially in musculoskeletal
131 manifestations and development delay. Interestingly, functional analyses of Boczek et al. identified a
132 novel mechanism of TS-mediated disease through increased window current [8]. They hypothesize it
133 could be linked in signaling cascades in the cytoskeleton and dendrite behavior, which could be
134 important for neuronal and skeletal phenotypes [8]. Despite the canonical mutation, TS1 cardiac and
135 extracardiac features are not identical from one patient to another [16]. Further analyses are necessary
136 to explain the phenotype variability, which is not explained by alternatively splicing or mosaicism
137 [1,12,13,14]. This variability could be due to modifying genetic factors that remain to be identified.

138 The c.2146-1G>C heterozygous variation of *PKP2* is a known splice acceptor site mutation responsible
139 for arrhythmogenic right ventricular cardiomyopathy [17]. Usually, palpitations or ventricular
140 tachyarrhythmias are the common clinical manifestations of the disease [18]. Low-penetrance in family
141 members is also described [19]. Our patient had an echocardiogram, echocardiography and isotopic
142 ventriculography. No data were disponible for her father. These examinations did not show anything in
143 favor of this disease. However, we do not know the effect of this mutation associated with the one in
144 *CACNA1C*. Cerrone et al. reported that *PKP2* knock-out led to decrease the rate of L-type calcium
145 channel inactivation and prolong L-type calcium current decay. This suggests that if the splicing

146 variation PKP2 of the proband affects clinical expression, it may worsen the phenotype of Timothy
147 syndrome. Unfortunately, further tests would be needed to show if the *PKP2* variation could affect the
148 phenotype or not [20].

149 These clinical and molecular findings expand the clinical and molecular spectrum of TS and show the
150 interest of next generation sequencing or whole exome sequencing in rare disorders, atypical or novel
151 phenotype. Further studies are needed to delineate the role of *CACNA1C* and to look for modifying
152 genetic factors that could explain the phenotype variability of TS.

153 **References**

- 154 1. Splawski I et al. Severe arrhythmia disorder caused by cardiac L-type calcium channel
155 mutations. *Proc Natl Acad Sci U S A*. 2005 Jun 7;102(23):8089-96.
- 156 2. Fröhler S et al. Exome sequencing helped the fine diagnosis of two siblings afflicted
157 with atypical Timothy syndrome (TS2). *BMC Med Genet*. 2014 Apr 29;15:48.
- 158 3. Diep V, Seaver LH. Long QT syndrome with craniofacial, digital, and neurologic
159 features: Is it useful to distinguish between Timothy syndrome types 1 and 2? *Am J Med
160 Genet A*. 2015 Nov;167A(11):2780-5
- 161 4. Hiippala A, Tallila J, Myllykangas S, Koskenvuo JW, Alastalo TP. Expanding the
162 phenotype of Timothy syndrome type 2: an adolescent with ventricular fibrillation but
163 normal development. *Am J Med Genet A*. 2015 Mar;167A(3):629-34.
- 164 5. Philipp LR, Rodriguez FH. Cardiac arrest refractory to standard intervention in atypical
165 Timothy syndrome (LQT8 type 2). *Proc (Bayl Univ Med Cent)*. 2016 Apr;29(2):160-2.
- 166 6. Gillis J et al. Long QT, syndactyly, joint contractures, stroke and novel *CACNA1C*
167 mutation: expanding the spectrum of Timothy syndrome. *Am J Med Genet A*. 2012
168 Jan;158A(1):182-7.
- 169 7. Wemhöner K et al. Gain-of-function mutations in the calcium channel *CACNA1C*
170 (*Cav1.2*) cause non-syndromic long-QT but not Timothy syndrome. *J Mol Cell Cardiol*.
171 2015 Mar;80:186-95.

- 172 8. Boczek NJ et al. Novel Timothy syndrome mutation leading to increase in CACNA1C
173 window current. *Heart Rhythm*. 2015 Jan;12(1):211-9.
- 174 9. Splawski I et al. Ca(V)1.2 calcium channel dysfunction causes a multisystem disorder
175 including arrhythmia and autism. *Cell*. 2004 Oct 1;119(1):19-31.
- 176 10. Gao Y et al. Inhibition of late sodium current by mexiletine: a novel
177 pharmacotherapeutic approach in timothy syndrome. *Circ Arrhythm Electrophysiol*.
178 2013 Jun;6(3):614-22.
- 179 11. Walsh MA et al. A multicentre study of patients with Timothy syndrome. *Europace*.
180 2018 Feb 1;20(2):377-385.
- 181 12. Etheridge SP et al. Somatic mosaicism contributes to phenotypic variation in Timothy
182 syndrome. *Am J Med Genet A*. 2011 Oct;155A(10):2578-83.
- 183 13. Dufendach KA, Giudicessi JR, Boczek NJ, Ackerman MJ. Maternal mosaicism
184 confounds the neonatal diagnosis of type 1 Timothy syndrome. *Pediatrics*. 2013
185 Jun;131(6):e1991-5.
- 186 14. Baurand A et al. *Am J Med Genet A*. 2017 Feb;173(2):531-536.
- 187 15. Fukuyama M et al. Long QT syndrome type 8: novel CACNA1C mutations causing QT
188 prolongation and variant phenotypes. *Europace*. 2014 Dec;16(12):1828-37.
- 189 16. Sepp R et al. Timothy syndrome 1 genotype without syndactyly and major extracardiac
190 manifestations. *Am J Med Genet A*. 2017 Mar;173(3):784-789.
- 191 17. Gerull B et al. Mutations in the desmosomal protein plakophilin-2 are common in
192 arrhythmogenic right ventricular cardiomyopathy. *Nat Genet*. 2004 Nov;36(11):1162-
193 4.
- 194 18. Syrris P et al. Clinical expression of plakophilin-2 mutations in familial arrhythmogenic
195 right ventricular cardiomyopathy. *Circulation*. 2006 Jan 24;113(3):356-64.
- 196 19. Dalal D et al. Penetrance of mutations in plakophilin-2 among families with
197 arrhythmogenic right ventricular dysplasia/cardiomyopathy. *J Am Coll Cardiol*. 2006
198 Oct 3;48(7):1416-24.

199 20. Cerrone M et al. Plakophilin-2 is required for transcription of genes that control calcium
200 cycling and cardiac rhythm. Nat Commun. 2017 Jul 24;8(1):106.
201

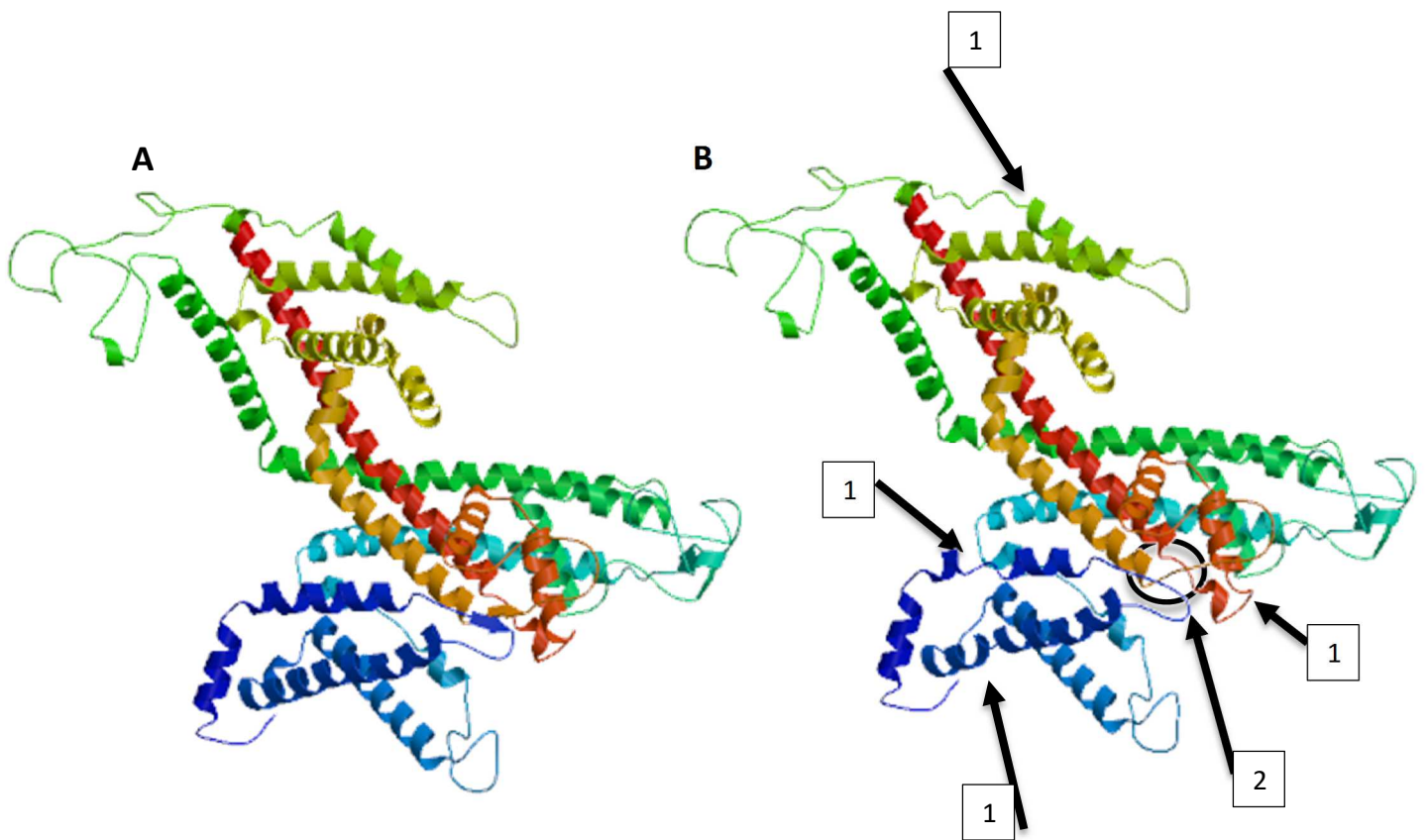


Figure 1 : The tri-dimensional graphical model of the human CACNA1C protein. **A** : wild type protein, **B** : mutated protein, p.Glu407Ala with loss of alpha helix indicated by numbered arrows 1 and loss of beta sheet by numbered arrows 2.

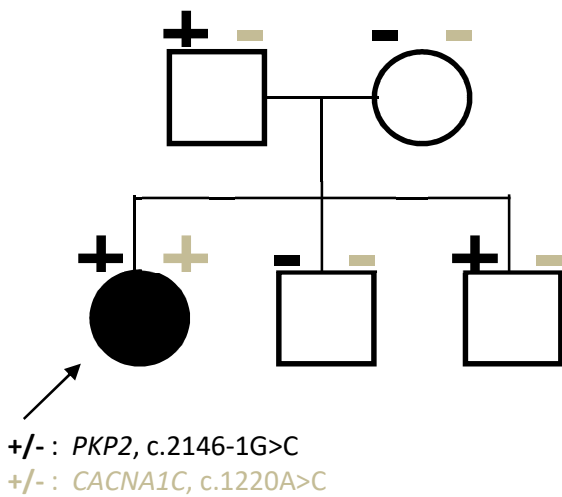


Figure 2 : Pedigree chart of the family : in black : *PKP2* (c.2146-1G>C) and in gray : *CACNA1C*, c.1220A>C ; + : presence of the variation, - : absence of the variation