



**HAL**  
open science

## Impact of Motion Correction Algorithms on Image Quality in Children Undergoing Coronary Computed Tomography Angiography

Julien Le Roy, Hamid Zarqane, Benoit Azais, H el ene Vernhet Kovacsik, Thibault Mura, Darin Okerlund, Alain Lacampagne, Pascal Amedro

### ► To cite this version:

Julien Le Roy, Hamid Zarqane, Benoit Azais, H el ene Vernhet Kovacsik, Thibault Mura, et al.. Impact of Motion Correction Algorithms on Image Quality in Children Undergoing Coronary Computed Tomography Angiography: A Comparison With Regular Monophasic and Multiphasic Acquisitions. *Circulation: Cardiovascular Imaging*, 2019, 12 (12), pp.009650. 10.1161/CIRCIMAGING.119.009650 . hal-02382830

**HAL Id: hal-02382830**

**<https://hal.science/hal-02382830>**

Submitted on 10 Jun 2020

**HAL** is a multi-disciplinary open access archive for the deposit and dissemination of scientific research documents, whether they are published or not. The documents may come from teaching and research institutions in France or abroad, or from public or private research centers.

L'archive ouverte pluridisciplinaire **HAL**, est destin ee au d ep ot et  a la diffusion de documents scientifiques de niveau recherche, publi es ou non,  emanant des  tablissements d'enseignement et de recherche fran ais ou  trangers, des laboratoires publics ou priv es.

# Impact of Motion Correction Algorithms on Image Quality in Children Undergoing Coronary Computed Tomography Angiography

## A Comparison With Regular Monophasic and Multiphasic Acquisitions

Coronary computed tomography angiography (CCTA) utilization in children remains limited by the use of ionizing radiation and motion artifacts, impairing interpretability. Iterative reconstructions associated with prospective ECG-triggered acquisitions have provided significant radiation dose reductions.<sup>1</sup> Similarly, dual-source CT and faster gantry rotation speeds have improved image quality by compressing CT temporal resolution.<sup>2</sup> Yet, given coronary artery speeds, up to 35 mm/s,<sup>3</sup> images acquired with a 75 msec temporal resolution system still involve up to 3.6 mm coronary shifts during acquisitions (0.075 × 35 mm/s). In children, this shift represents almost twice the diameter of a coronary artery, and involves frequent motion artifacts. Motion correction algorithms (MCA) have been introduced to overcome this limitation, but their ability to compensate motion artifacts in pediatrics have not been assessed, yet. In the COROPEDIA trial (Observational Study for Feasibility and Performance of Submillisievert Coronary Computed Tomography Angiography for Coronary Artery Anomalies in Paediatric Patients), we compared 2 MCA generations to monophasic and multiphasic traditional reconstructions.

In this study, 50 children requiring coronary artery assessment were prospectively recruited and had a volumetric ECG-triggered CCTA within a single heartbeat, using a wide-coverage CT (Revolution CT, GE). All children were administered oral beta-blockers and sedation, without general anesthesia, as detailed in our institutional pediatric CCTA protocol.<sup>4</sup> This study was approved by the French southeast ethics committee (2017-A00909-44), and informed consent was obtained from legal guardians. The data, analytic methods, and study materials will not be made available to other researchers for purposes of reproducing the results or replicating the procedure. Only one multiphasic acquisition was performed, to minimize radiation and maximize imaging success. From this acquisition, 4 different reconstructions were performed independently: a regular multiphasic reconstruction including all cardiac phases from 25% to 85% of the R-R interval; a regular monophasic reconstruction either in diastole or systole for patients with heart rate below or above 80 bpm respectively; and the same previous single-phase retrospectively generated with first (SSF1) and second (SSF2) MCA generations (Snapshot Freeze, GE). The first-generation MCA uses adjacent cardiac phases within a single cardiac cycle to characterize motion path and velocity, and adaptively compensates for motion in the prescribed cardiac phase.<sup>5</sup> The second MCA generation extends motion correction to the whole heart, to characterize motion along all 3 axes, and provide greater correction robustness. Two radiologists independently evaluated 16 segments of the coronary tree, left and right ostia, ascending aorta, pulmonary artery, aortic valve, and cardiac chambers, in the 4 reconstructions. A 4-point semi-quantitative scale was used as follows: 4-excellent, no motion artifacts; 3-good, mild motion artifacts; 2-adequate, important artifacts without

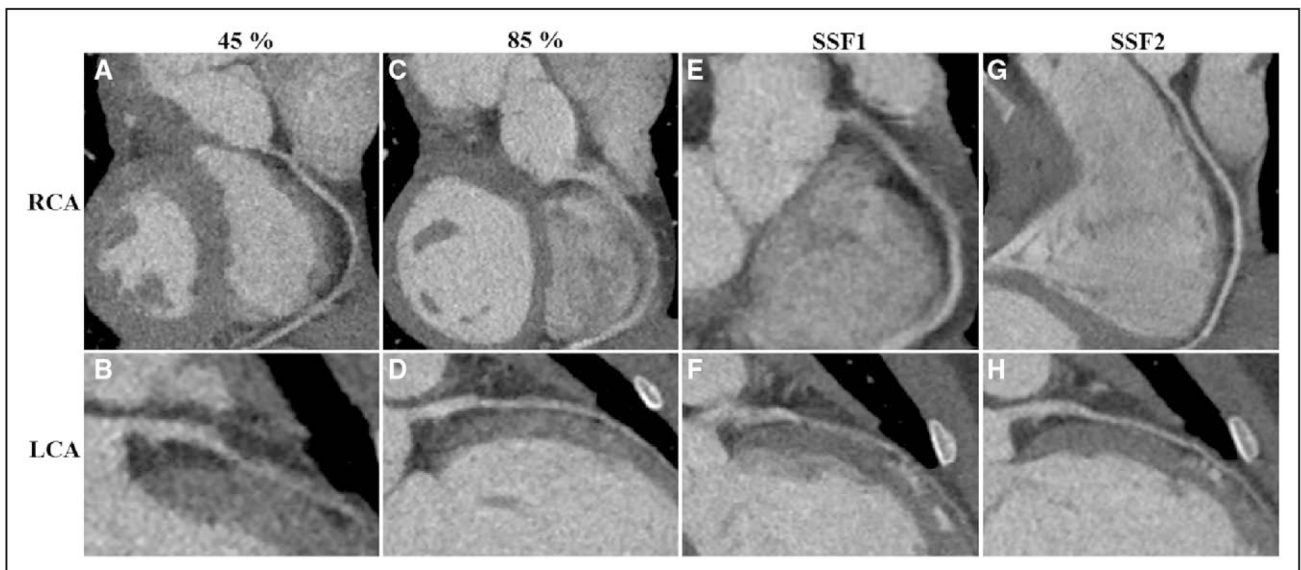
Julien Le Roy, MSc  
Hamid Zarqane, MD  
Benoit Azais, MD  
Helene Vernhet Kovacsik,  
MD, PhD  
Thibault Mura, MD, PhD  
Darin Okerlund, MSc  
Alain Lacampagne, PhD  
Pascal Amedro, MD, PhD

**Key Words:** artifacts ■ computed tomography angiography ■ coronary disease ■ image enhancement ■ motion ■ pediatrics ■ radiation protection

diagnosis interference; 1-nondiagnostic, severe artifacts impairing accurate evaluation. Structures with a score >1 were considered as interpretable for diagnosis. Structures with a score >2 were considered as optimal quality for diagnosis. McNemar's tests were used to compare the proportion of structures with interpretable or optimal quality between the 4 reconstruction techniques. Overall observer agreement was assessed using weighted  $\kappa$ -coefficient and classified according to Landis and Koch, as poor ( $k < 0.0$ ), slight ( $k = 0.00-0.20$ ), fair ( $k = 0.21-0.40$ ), moderate ( $k = 0.41-0.60$ ), substantial ( $k = 0.61-0.80$ ), or almost perfect ( $k = 0.80-1.00$ ).

MCA post-treatment analyses were performed in 47 patients (mean age  $5.5 \pm 4.7$  years, heart rate  $95 \pm 27$  bpm); 3 patients were excluded due to inadequate fields of view, preventing MCA processing. SSF2 reconstructions provided better results than SSF1 or regular monophasic reconstructions in terms of interpretability rates (99.3% versus 94.3% and 92.1%, respectively, all  $P < 0.001$ ) and proportion of structures with optimal quality (90.1% versus 68.2% and 60.3%, respectively, all  $P < 0.001$ ). While SSF2 and multiphasic acquisitions provided similar interpretability rates (99.3% versus 99.6%,  $P = 0.5$ ), SSF2 had higher proportion of structures with optimal quality (90.1% versus 81.1%,  $P < 0.001$ ). Multiphasic acquisitions led to significantly higher interpretability rate (99.6% versus 92.1%,  $P < 0.001$ ) and proportion of optimal structures (81.1% versus 60.3%,  $P < 0.001$ ) than monophasic acquisitions. Inter-observer agreement was substantial ( $k = 0.63 [0.61-0.65]$ ).

In a cohort of 47 children with congenital heart disease undergoing CCTA, the COROPEDIA trial evaluated, for the first time, the improvement of cardiac structures visualization provided by 2 generations of MCA, as compared with traditional monophasic and multiphasic reconstructions (Figure). Multiphasic reconstructions led to significantly better interpretability than monophasic reconstructions. A common interval of least motion for all cardiac structures does not always exist, and in pediatrics, high heart rate, small cardiac structures, uncontrolled breath-holding, agitation or crying, may result in interpretable structures in different cardiac phases.<sup>4</sup> Both MCA generations significantly reduced motion artifacts, as compared with monophasic traditional reconstructions. Yet, SSF1 remains significantly inferior to multiphasic reconstructions, which should be considered, despite higher radiation dose. Existing solutions to perform pediatric multiphasic CCTA with effective dose below 1 mSv were recently reported.<sup>4</sup> However, SSF2 provided similar interpretability rates and higher proportions of structures with optimal quality than multiphasic reconstructions. MCA post-treatment requires 60 msec of data before and after the targeted phase.<sup>5</sup> Considering the minimum irradiation time necessary to complete any acquisition ( $\approx 180^\circ$  gantry rotation; eg, 140 msec),<sup>2</sup> MCA post-treatment never requires additional exposure but could reduce beam-on-time compared to multiphasic acquisitions. In our cohort, replacing a multiple-phase acquisition using 60%, 50%, 40%, 30%, and 20% of the R-R interval, by a 140 msec interval SSF2 acquisition, would provide an average dose reduction of 63%, 56%, 45%, 28%, and 8%, respectively.



**Figure.** Coronary computed tomography angiography performed on a 9-year-old girl with a heart rate of 78 bpm, for a coronary artery fistulae suspicion. Curved multiplanar reformations of right (RCA: top line) and left (LCA: bottom line) coronary arteries are reconstructed at 2 different moments of the cardiac cycle (45%: [A and B]; 85%: [C and D]) and using 2 generations of motion correction algorithm, (SSF1: [E and F]; SSF2: [G and H]). The evaluation of both RCA and LCA couldn't be performed in a single-phase. At 45% of the R-R interval, the RCA is well defined (A), while the LCA is blurry (B). At 85% of the R-R interval, the RCA is blurry (C), while the LCA is well defined (D). SSF1 reduces motion artifacts in both RCA (E) and LCA (F) but without achieving the level of visualization of both RCA and LCA taken on their respective motionless phases: for example, the RCA at 45% (A) and the LCA at 85% (D) of R-R intervals. SSF2 further reduces motion artifacts in both RCA (G) and LCA (H), and could provide, in a single post-treated phase, an image quality at least equivalent to a multiphasic acquisition. LCA indicates left coronary artery; RCA, right coronary artery; SSF1, snapshot freeze first generation; and SSF2, snapshot freeze second generation.

These results suggest that multiple phases provide significantly better interpretability than traditional single-phase acquisitions. However, the second MCA generation offered similar interpretability in a single retrospectively processed cardiac phase and could be adopted to reduce children exposure to radiation.

---

## ARTICLE INFORMATION

### Correspondence

Julien Le Roy, Pediatric and Congenital Cardiology Department, Montpellier University Hospital, 371 Ave du Doyen Giraud, 34295 Montpellier, France. Email [j-le\\_roy@chu-montpellier.fr](mailto:j-le_roy@chu-montpellier.fr)

### Affiliations

Pediatric and Congenital Cardiology Department, M3C Regional Reference CHD Center, CHU Montpellier, France (J.L.R., P.A.). PhyMedExp (J.L.R., A.L., P.A.) and Epidemiology and Clinical Research Department (T.M.), University of Montpellier, CNRS, INSERM, CHU Montpellier, France. Radiology Department, CHU Montpellier, France (H.Z., B.A., H.V.K.). GE Healthcare, Waukesha, Wisconsin (D.O.).

### Acknowledgments

We thank Philippe Richard, clinical computed tomography product specialist at GE Healthcare, for his help setting up this project.

### Sources of Funding

This study was funded by Montpellier University Hospital Clinical Research Program (UF 9785).

## Disclosures

D. Okerlund is employed by GE Healthcare. He performed SSF2 image retrospective processing, and provided technical explanations regarding Snapshot Freeze processing as detailed in the article. Scoring, analyses, results, and conclusions were only performed by Montpellier University Hospital medical staff. GE Healthcare did not provide any financial support to this research, had no access at any point of the study to any results, and did not influence the content of the study. The other authors report no conflicts.

---

## REFERENCES

1. Habib Geryes B, Calmon R, Khraiche D, Boddart N, Bonnet D, Raimondi F. Radiation dose reduction in paediatric coronary computed tomography: assessment of effective dose and image quality. *Eur Radiol*. 2016;26:2030–2038. doi: 10.1007/s00330-015-4032-5
2. Flohr TG, Raupach R, Bruder H. Cardiac CT: how much can temporal resolution, spatial resolution, and volume coverage be improved? *J Cardiovasc Comput Tomogr*. 2009;3:143–152. doi: 10.1016/j.jcct.2009.04.004
3. Husmann L, Leschka S, Desbiolles L, Schepis T, Gaemperli O, Seifert B, Cattin P, Frauenfelder T, Flohr TG, Marincek B, et al Coronary artery motion and cardiac phases: dependency on heart rate – implications for CT image reconstruction. *Radiology*. 2007;245:567–576. doi: 10.1148/radiol.2451061791
4. Le Roy J, Vernhet Kovacsik H, Zargane H, Vincenti M, Abassi H, Lavastre K, Mura T, Lacampagne A, Amedro P. Submillisievert multiphasic coronary computed tomography angiography for pediatric patients with congenital heart diseases. *Circ Cardiovasc Imaging*. 2019;12:e008348. doi: 10.1161/CIRCIMAGING.118.008348
5. Soon J, Sulaiman N, Park JK, Kueh SH, Naoum C, Murphy D, Ellis J, Hague CJ, Blanke P, Leipsic J. The effect of a whole heart motion-correction algorithm on CT image quality and measurement reproducibility in Pre-TAVR aortic annulus evaluation. *J Cardiovasc Comput Tomogr*. 2016;10:386–390. doi: 10.1016/j.jcct.2016.08.001