



**HAL**  
open science

## **Fibromuscular dysplasia and its neurological manifestations: a review**

Emmanuel Touzé, Andrew M Southerland, Marion Boulanger, Paul-Emile Labeyrie, Michel Azizi, Nabila Bouatia-Naji, Stéphanie Debette, Heather L Gornik, Shazam M Hussain, Xavier Jeunemaitre, et al.

### ► **To cite this version:**

Emmanuel Touzé, Andrew M Southerland, Marion Boulanger, Paul-Emile Labeyrie, Michel Azizi, et al.. Fibromuscular dysplasia and its neurological manifestations: a review. *JAMA neurology*, 2019, 10.1001/jamaneurol.2018.2848 . hal-02379350

**HAL Id: hal-02379350**

**<https://hal.science/hal-02379350>**

Submitted on 25 Nov 2019

**HAL** is a multi-disciplinary open access archive for the deposit and dissemination of scientific research documents, whether they are published or not. The documents may come from teaching and research institutions in France or abroad, or from public or private research centers.

L'archive ouverte pluridisciplinaire **HAL**, est destinée au dépôt et à la diffusion de documents scientifiques de niveau recherche, publiés ou non, émanant des établissements d'enseignement et de recherche français ou étrangers, des laboratoires publics ou privés.

## **Fibromuscular dysplasia and its neurological manifestations: a review**

Emmanuel Touzé, MD, PhD, FESO;\*<sup>1</sup> Andrew M Southerland, MD, MSc;\*<sup>2</sup> Marion Boulanger, MD, MSc;\*<sup>1</sup> Paul-Emile Labeyrie, MD, PhD;<sup>1, 3</sup> Michel Azizi, MD, PhD;<sup>4</sup> Nabila Bouatia-Naji, PhD;<sup>4</sup> Stéphanie Debette, MD, PhD;<sup>5</sup> Heather L Gornik, MD;<sup>6</sup> Shazam M Hussain, MD, FRCP;<sup>6</sup> Xavier Jeunemaitre, MD, PhD;<sup>4</sup> Julien Joux, MD;<sup>7</sup> Adam Kirton, MD;<sup>8</sup> Claire Le Hello, MD, PhD;<sup>1,9</sup> Jennifer J Majersik, MD, MS;<sup>10</sup> J Mocco, MD, MS;<sup>11</sup> Alexandre Persu, MD, PhD;<sup>12</sup> Aditya Sharma, MBBS;<sup>2</sup> Bradford B Worrall, MD, MSc;<sup>2</sup> Jeffrey W Olin, DO;<sup>11</sup> Pierre-François Plouin, MD.<sup>4</sup>

\*ET, AMS, and MB contributed equally

<sup>1</sup> Normandie Université, UNICAEN, Inserm U1237, CHU Caen, Caen, France

<sup>2</sup> Departments of Neurology and Public Health Sciences, University of Virginia Health System, Charlottesville, Virginia, USA

<sup>3</sup> University of Lyon, Department of Radiology, Hôpitaux de Lyon, Lyon, France

<sup>4</sup> Paris-Descartes University, and; INSERM UMR970 Paris Cardiovascular Research Center U970; APHP, Hôpital Européen Georges Pompidou, Hypertension Unit Paris, France

<sup>5</sup> Department of Neurology, Memory Clinic, Bordeaux University Hospital  
University of Bordeaux, Inserm U1219, Bordeaux Population Health Research Center,  
Bordeaux, France

<sup>6</sup> Cleveland Clinic Heather and Vascular Institute, Cleveland, Ohio, USA

<sup>7</sup> CHU Fort-de-France, Martinique, French West Indies

<sup>8</sup> University of Calgary, Calgary, AB, Canada

<sup>9</sup> Université de Saint Etienne, Service de Médecine Vasculaire, CHU Saint Etienne, France

<sup>10</sup> University of Utah, Salt Lake City, Utah, USA

<sup>11</sup> Icahn School of Medicine at Mount Sinai, New York, New York, USA

<sup>12</sup> Pole of Cardiovascular Research, Institut de Recherche Expérimentale et Clinique, and Division of Cardiology, Cliniques Universitaires Saint-Luc, Université Catholique de Louvain, Brussels, Belgium

Date of the revision June 10<sup>th</sup>, 2018

Correspondance to: Emmanuel Touzé, Normandie Univ, UNICAEN, Inserm U1237, CHU Caen, Caen,  
France (14000) [emmanuel.touze@unicaen.fr](mailto:emmanuel.touze@unicaen.fr)

Word count abstract: 350 – Word count paper: 3499

References: 67 – Table: 1, Figures: 4

## **Disclosures**

Dr Touzé is assistant editor for Stroke journal (AHA)

Dr Southerland is section editor for the Neurology Podcast, was a consultant for the National Stroke Association, and has received research support from the American Heart Association/American Stroke Association.

Dr Boulanger has no disclosure

Dr Labeyrie has no disclosure

Dr Azizi has received honoraria for advisory board meetings from Actelion, has received speakers' honoraria from CVRx, Servier, Astra Zeneca; has received a research grant from Servier, Novartis, Recor, Quantum genomics.

Dr Bouatia-Naji is supported by INSERM and funding from the French National Research Agency (ANR-13-JSV1-0002) and European Research Council (ERC-Stg-ROSALIND-716628).

Dr Debette has no disclosure

Dr Gornik is member of the Medical Advisory Board of the FMD Society of America, FMD Society of America, a nonprofit organization and has received research grant support from CVR global and has intellectual property and equity from Zin Medical/Flexlife Health.

Dr Hussain has no disclosure

Dr Jeunemaitre has no disclosure

Dr Joux has no disclosure

Dr Kirton has no disclosure

Dr Le Hello has no disclosure

Dr Majersik has significant NIH funding

Dr Mocco is consultant for Rebound Medical, Endostream, Synchron, Cerebrotech and investor/Ownership in Apama, the Stroke Project, Endostream, Synchron, Cerebrotech, NeurVana, NeuroTechnology Investors

Dr Persu has no disclosure

Dr Sharma has disclosed research support from National Institute of Health Sciences, AstraZeneca, Biomet Biologics, Portola Pharmaceuticals.

Dr Worrall is deputy editor of Neurology

Dr Olin served as Chair, Medical Advisory Board, Fibromuscular Dysplasia Society of America Volunteer position

Dr Plouin has no disclosure

### **Acknowledgments**

“Emmanuel Touzé, Andrew Southerland and Marion Boulanger had full access to all the data in the study and take responsibility for the integrity of the data and the accuracy of the data analysis”.

### **Author Contributions**

Dr Touzé, Dr Southerland, Dr Boulanger – Study concept and design, drafting the manuscript

Dr Boulanger, Dr Labeyrie, Dr Azizi, Dr Bouatia-Naji, Dr Debette, Dr Gornik, Dr Hussain, Dr Jeunemaitre,

Dr Joux, Dr Kirton, Dr Le Hello, Dr Majersik, Dr Mocco, Dr Persu, Dr Sharma, Dr Worrall, Dr Olin, and Dr

Plouin – Medical writing for content

Dr Worrall, Dr Majersik, Dr Olin, Dr Plouin – Revising the manuscript

### **Key points**

**Question** What are the neurological manifestations of fibromuscular dysplasia (FMD).

**Findings** This review describes the epidemiology, clinical and radiological manifestations, prognosis and management of FMD involving the cervical or intracranial arteries.

**Meaning** Cerebrovascular FMD is now considered as frequent as renal FMD and longitudinal, international cohort studies with outcomes and genetic sequencing are needed to further understand the clinical course of cerebrovascular FMD and enable development of evidence-based treatments.

## **Abstract**

**IMPORTANCE** Data on neurological manifestations of fibromuscular dysplasia (FMD) are rare and current knowledge remains limited.

**OBJECTIVES** To present a comprehensive review of the epidemiology, management and prognosis of neurological manifestations associated with cerebrovascular FMD (*i.e.* involving cervical or intracranial arteries), and to guide future research priorities.

**EVIDENCE REVIEW** References were identified through searches of PubMed from inception to December 2017 using both the medical subject headings and text words. We also identified additional sources by reviewing reference lists of relevant articles and through searches of the authors' personal files. We selected articles describing at least one clinical or radiological feature and/or outcome of cerebrovascular FMD. Isolated case reports could be included if they described interesting or noteworthy manifestations.

**FINDINGS** We identified 84 relevant references. Diagnosis of cerebrovascular FMD is based on the appearance of alternating arterial dilatation and constriction ("string of beads") or of focal narrowing, with no sign of atherosclerotic or inflammatory lesions. Although the radiographic diagnosis is easily apparent, it can be challenging in children or atypical phenotypes such as purely intracranial FMD and arterial dissection. Multiple artery involvement is common and there is increased incidence of cervical artery dissection and intracranial aneurysms. A variant in the PHACTR1 gene has been associated with FMD, as well as cervical artery dissection and migraine, although <5% of FMD cases are familial. Headaches, mainly of the migraine type, are observed in up to 70% of FMD patients. Cerebrovascular FMD is mostly asymptomatic, but most frequent neurological manifestations include transient ischemic attack (TIA) and ischemic stroke, notably in the presence of associated cervical artery dissection. Other devastating conditions include subarachnoid hemorrhage and rarely intracranial hemorrhage. Management relies on observational data and expert opinion. Antiplatelet therapy is estimated to be reasonable to prevent thromboembolic complications. Endovascular therapy is typically restricted to cases with symptomatic stenosis despite optimal medical therapy or in those with rupture of an intracranial aneurysm.

**CONCLUSION AND RELEVANCE** Longitudinal cohort studies of multiple ethnicities with biosampling are needed to better understand risk factors, pathophysiology, and outcomes. Patient advocacy groups could assist researchers in answering patient centered questions with FMD.

## **Introduction**

Fibromuscular dysplasia (FMD) is an idiopathic, noninflammatory, nonatherosclerotic vascular disease of small- to medium-sized arteries.<sup>1,2</sup> In FMD patients, the frequency of involvement of cervical (carotid and vertebral) and intracranial arteries is higher than previously thought and as common as those of renal artery but data on neurological manifestations of FMD (or cerebrovascular FMD) remain rare.<sup>1,3,4</sup> Although generally considered a benign entity when discovered incidentally, cerebrovascular FMD can lead to potentially devastating cerebrovascular complications, including ischemic and hemorrhagic stroke.<sup>3,5,6</sup> Also, more than half of patients with cerebrovascular FMD have concomitant lesions in the renal artery, which implies that they are exposed to additional potentially severe renal complications, including hypertension, preeclampsia and renal infarction.<sup>1,3,4</sup> This review summarizes data on cerebrovascular FMD, along with a proposal for future research priorities.

## **Methods**

### **Search Strategy**

We searched studies indexed in PubMed using the MeSH term “fibromuscular dysplasia” or the text words “fibromuscular dysplasia” OR “fibromuscular hyperplasia” until December 31, 2017, with no language restrictions. We also identified additional studies through searches of the authors’ personal files. We included articles describing at least one aspect of epidemiology, clinical characteristics, radiological features, or outcomes of cervical or intracranial FMD, and preferentially focused on studies published within the last 5 years and those including  $\geq 15$  patients. However, case reports or small case series describing interesting or noteworthy manifestations could be included. When publications involved overlapping study samples, only the largest and most recent one was included unless in the case of description of new parameter or additional relevant data. The quality of evidence was rated according to the Oxford Centre for Evidence-Based Medicine levels of evidence.<sup>7</sup>



## Results

Of the 2788 articles identified through PubMed and the 16 from hand searching, screening and eligibility assessment led to the inclusion of 84 studies (**eFigure 1 in the Supplement**). Studies were mainly case series or retrospective studies, with therefore a low quality of evidence (**eTable 1**).

## Classification and diagnostic criteria

The historical classification for FMD has focused on arterial wall involvement (medial, intimal and adventitial subtypes).<sup>1</sup> However, in clinical practice, histological specimens are rarely obtained and diagnosis is most commonly based on radiological findings. Therefore, the European consensus statement and the American Heart Association (AHA) scientific statement on FMD have described a new classification based on angiographic appearance to replace the histopathological classification (**Table**).<sup>1,2</sup>

## Imaging

High level evidence data on imaging modalities for the diagnosis of cerebrovascular FMD are lacking, and no imaging modality can be recommended over another. Preferred techniques for computerized tomography-angiography (CTA) and magnetic resonance angiography (MRA) are described in the **Online-Only Materials**.

Digital subtraction arteriography remains the gold standard for diagnosis of FMD, due to its higher sensitivity than CTA or MRA (**Figures 1, 2, eFigures 2,3**).<sup>2,8,9</sup> However, because of the risk of iatrogenic dissection with conventional arteriography (which may be higher in FMD patients than in the general population), its use is typically restricted to severe cases requiring endovascular management while CTA or contrast-enhanced MRA are commonly used as the initial imaging modality in most centres. Duplex ultrasound may be used to diagnose and monitor patients with FMD involving the extracranial carotid arteries but is less accurate than CTA or MRA (**Figure 3**) and inadequate for the assessment of vertebral or intracranial arteries.<sup>10</sup>

FMD primarily occurs in the cervical portion of the carotid and vertebral arteries while intracranial FMD is rare, usually extending from extracranial FMD or as the predominant location of FMD subtypes in

children.<sup>5</sup> Cerebrovascular FMD typically involves the middle and distal portions of the internal carotid artery and the V3/V4 segment of vertebral arteries at the level of the C1 and C2 vertebrae, areas which are usually spared by atherosclerosis.

## **Epidemiology**

As in patients with renal FMD, cerebrovascular FMD is much more common in women and typically becomes symptomatic in the 5<sup>th</sup> decade (**eTable 2**). There is typically no family history with <5% of patients reporting an affected family member.<sup>3-5</sup>

The role of hormonal factors in the development of FMD remains uncertain and case-control studies have found no association between FMD and gravidity or exogenous hormone exposure.<sup>1</sup> Although smoking has been reported to be associated with renal FMD,<sup>1</sup> no similar data exist for cerebrovascular FMD.<sup>11</sup> However, smoking and hormonal factors are associated with aneurysm growth and may therefore influence the risk of stroke in FMD patients.<sup>12,13</sup>

The prevalence of cerebrovascular FMD in the general population is unknown. Only 0.02% of consecutive autopsies performed at the Mayo Clinic over a period of 25 years detected FMD of the internal carotid artery.<sup>14</sup> Several studies suggest that the frequency of involvement of a cervical artery is now as frequent as those of renal artery.<sup>3,15</sup> Cerebrovascular FMD affects the carotid artery (often bilaterally) in 95% of cases and the vertebral artery (usually with co-involvement of the carotid) in 60-85% of cases.<sup>5</sup> Also, multiple locations, especially in the multifocal form but not only, are considered more common than previously thought. In the US Registry, renal artery involvement was reported in 64% of patients with cervical FMD while cervical FMD lesions were found in 65% of patients with renal artery FMD.<sup>3</sup> In the ARCADIA Registry, where assessment for multisite involvement was systematic, the prevalence of multisite locations was 48% in FMD patients and 54% in those with cerebrovascular presentation. Also, among FMD patients with cerebrovascular presentation, the prevalence of renal artery FMD involvement was three times higher with a history of hypertension, suggesting that history of hypertension could help identify patients who may benefit from screening for renal FMD.<sup>4</sup> Data on prevalence of involvement of other arterial beds (e.g. brachial, celiac, iliac, and coronary) in cerebrovascular FMD patients are

scarce.<sup>1,15</sup> While FMD is rarely reported in the coronary arteries,<sup>16</sup> a strong association between FMD and spontaneous coronary artery dissection (SCAD) has been recently identified, with a high prevalence of extra-coronary FMD lesions in SCAD patients.<sup>17</sup> In a large series of SCAD patients (n=168), cervical FMD and intracranial aneurysms were detected in 52% and 14% of cases, respectively.<sup>18</sup> In patients with cerebrovascular FMD, although prevalence of SCAD is very low, silent coronary lesions may exist, however the cost-effectiveness of screening for associated coronary artery disease is unknown and screening is not recommended.

### **Genetic Risk**

Heritability estimates of FMD are challenging due to the frequency of an asymptomatic phenotype and the lack of accurate characterization in family histories. Several candidate gene studies of FMD have been negative or have only been positive in isolated case reports (**eTable 3**),<sup>13</sup> and genome-wide association studies are lacking. While FMD shares some phenotypic features with monogenic connective tissue diseases such as Marfan's, Ehlers-Danlos, and Loeys-Dietz syndromes, systematic screening of genes mutated in these syndromes failed to yield associations with FMD.<sup>19,20</sup> Whole exome sequencing analysis in 16 FMD patients from 7 families found no gene variants shared among all affected sib-pairs.<sup>21</sup> Large-scale studies using low density exome chip arrays have identified an intronic variant (rs9349379) in the *PHACTR1* gene (6p24) as a first susceptibility locus for FMD, with an increased risk of ~40% among risk allele carriers.<sup>22</sup> Interestingly, this same risk allele has previously been associated with migraine and cervical artery dissection, and has recently been found to regulate the expression of endothelin-1 with known physiologic effects on the systemic vasculature.<sup>23</sup>

### **Presenting manifestations**

Although cerebrovascular FMD is frequently asymptomatic and diagnosed incidentally on imaging obtained for other indications, the most common presenting symptoms are headaches and pulsatile tinnitus.<sup>3,4</sup> Compared to the general population, FMD patients have a high prevalence of associated cervical (carotid or vertebral) artery dissection and intracranial saccular aneurysm.<sup>5,24</sup> The main

complications of cerebrovascular FMD are transient ischemic attack (TIA) or ischemic stroke, followed by subarachnoid hemorrhage and intracerebral hemorrhage (**eTable 2**).

**Headaches** are reported by 70% of patients with cerebrovascular FMD with 30% suffering from migraine.<sup>3,4,15</sup> Despite the high co-prevalence of headaches and migraine with cerebrovascular FMD, the underlying pathophysiology remains unclear. Possible mechanisms include alterations in cerebrovascular flow (e.g. labile hypertension, hyper- or hypoperfusion), neurovascular dysregulation or dysautonomia, structural injury (e.g. dissection, microtrauma), or heightened pain sensitivity.<sup>25</sup>

**Carotid bruit** (the most common presenting sign of cervical FMD) or/and **pulsatile tinnitus**, often described by patients as an auditory “whooshing”, are observed in up to 40% of patients with cervical FMD.<sup>3</sup> Less frequently reported symptoms include neck pain/carotidynia, blurry vision, and dizziness, the latter being described mostly as light-headedness or presyncope as opposed to vertigo. These nonspecific symptoms may represent manifestations of fluctuating blood pressure, persistent migraine aura, or dysautonomia secondary to neurovascular disruption in the vessel wall. In rare cases, light-headedness may be due to cerebral hypoperfusion related to severe multi-vessel cerebrovascular FMD.

**Cervical artery dissection:** Recent data from the US registry have shown that the prevalence of carotid and vertebral artery dissections in all patients with FMD is estimated to be 16% and 5%, respectively. Among FMD patients who experience a dissection, the carotid artery is the most frequently involved (64%), followed by the vertebral artery (21%), and prevalence of multiple cervical dissections is high (up to 37%).<sup>3</sup> Among FMD patients with a neurological presentation in the ARCADIA registry, the prevalence of cervical dissection was 27%.<sup>4</sup> Concomitantly, studies of individuals with cervical artery dissection report that the prevalence of cervical FMD may be as high as 15-20%,<sup>13,26</sup> and is increased in the presence of multiple cervical dissections.<sup>27</sup>

Cervical dissection is most often seen in the mid to distal segments of the extracranial internal carotid artery and vertebral arteries, where traction on the arteries is maximal. Extension and lateral rotation of the head and neck enhance stretching of the cervical arteries, and this may play a role in the association

between FMD and cervical dissection but whether these mechanical factors are involved in the etiology of cerebrovascular FMD remains speculative.<sup>5</sup>

**Intracranial saccular aneurysms** are mainly unruptured and diagnosed incidentally on imaging rather than discovered after rupture. A meta-analysis of over 500 cerebrovascular FMD patients reported a prevalence of unruptured intracranial aneurysm of 7%, which was higher than that expected in the general population (<5%).<sup>28</sup> In the US Registry, 13% of women with FMD had at least one intracranial aneurysm and 4% more than one. Interestingly, 29% of these aneurysms were of size  $\geq 5\text{mm}$ , which is the threshold usually considered to classify intracranial aneurysms with a higher risk of rupture.<sup>29</sup> Also, there was no difference in the prevalence of intracranial aneurysms between patients with renal and cervical FMD.<sup>30</sup>

Whether the risk of rupture of intracranial aneurysm is higher in FMD patients than in the general population (<1%/year) remains uncertain.

**TIA or ischemic stroke** in FMD patients can result from different mechanisms: hypoperfusion from cervical or intracranial arterial stenosis or occlusion (hemodynamic mechanism); emboli from a thrombosis in the area of a stenosis or dilation; or via thrombosis of small, perforating arteries due to chronic hypertension secondary to the coexistence of renal FMD (lacunar stroke). However, TIA/ischemic stroke seem to occur mainly in the presence of associated cervical artery dissection, due to artery-to-artery thromboembolism or cerebral hypoperfusion. In the US registry, 10% of FMD patients presented with ischemic stroke and 20% with TIA.<sup>3</sup>

**Intracerebral hemorrhage** is rare in patients with FMD but can occur in the presence of hypertensive microangiopathy or from the rupture of an intracranial aneurysm or dissection.<sup>5</sup>

**Subarachnoid hemorrhage** mainly results from the rupture of an intracranial aneurysm and less commonly from dissecting vertebral artery into the intracranial segment.<sup>5</sup> The prevalence of subarachnoid

hemorrhage is estimated to be 3% in all FMD patients and 20% among those who present with acute neurological manifestations.<sup>4</sup>

### ***Specific subtypes***

#### ***Purely intracranial FMD***

Purely intracranial FMD seems rare and more frequent in children than adults.<sup>5,31</sup> Although intracranial FMD most often corresponds to the extension of extracranial cervical FMD,<sup>5</sup> isolated intracranial FMD with a typical “string of beads” angiographic appearance in the basilar artery, distal internal carotid artery, and middle cerebral artery has also been reported.<sup>5</sup> Additionally, autopsy reports of patients with fatal intracranial artery dissection or aneurysmal subarachnoid hemorrhage have shown histologic evidence of FMD.<sup>5,32</sup> Histologic evidence of FMD has also been reported in fusiform or dolichoectatic intracranial artery,<sup>33,34</sup> moyo-moya syndrome and carotid-cavernous fistula.<sup>5</sup> While FMD of extracranial arteries typically involves the medial layer of the vessel wall, intracranial FMD predominantly involves the intima, suggesting a genotype-phenotype variation by anatomical location in the cerebrovascular vasculature.

#### ***Cerebrovascular FMD in children***

A recent study combining a large series of new cases with the existing literature (totalling 81 cases) showed that cerebrovascular FMD in children (birth to 18 years) differs from adults in clinical and histological characteristics.<sup>31,35</sup> Both genders are equally affected and most cases are diagnosed early in childhood (mean age of 7 years), with a third being diagnosed in the first year of life. Focal FMD with intimal fibroplasia pathology seems to be the predominant form while the more typical adult appearance of multifocal FMD (medial fibroplasia) is estimated to be very rare.<sup>31</sup> Associated moyo-moya syndromes and intracranial aneurysms, have also been reported. Systemic FMD occurred frequently in children, with 63% having renal FMD and 72% having an additional arterial bed involvement.<sup>31</sup> Ischemic stroke appears to be the predominant presentation (63% of cases), mainly due to intracranial stenosis, and affecting multiple territories (40%). The outcome remains poor with a high annual rate of recurrent stroke (10%) and death (13%).<sup>31</sup>

### **Carotid bulb diaphragm**

An entity called “arterial diaphragm” or “web” was reported to share similar histological findings with FMD, with intimal fibroplasia without atheromatous or inflammatory lesions being described in almost all cases treated by surgery.<sup>5,36,37</sup> Several authors estimate that this could be the predominant form of FMD in Black populations and have classified it as “atypical FMD”.<sup>38</sup> Arterial diaphragms are thin translucent endoluminal webs located in the carotid (especially in the posterolateral side of the carotid bulb) or vertebral (V3 segment or ostium) artery and correspond to a linear defect on angiography that do not change or disappear after modification of the patient’s head position (**Figure 4**).<sup>39-41</sup> Since its first description in 1967,<sup>42</sup> >50 cases have been reported. Diaphragms typically affect middle-aged adults, predominantly women, of African or Afro-Caribbean ethnicity, with no atherosclerotic risk factors.<sup>36</sup> The main clinical presentations are TIA or ischemic stroke ipsilateral to the diaphragm and a strong association between carotid bulb diaphragm and ischemic stroke has been reported in a population-based case-control study.<sup>38</sup> Cerebral ischemia is estimated to be mediated by an embolic mechanism, because of stasis upstream to the web or within an associated aneurysmal bulb, or from focal dissection. In the presence of TIA/ischemic stroke, the rate of recurrent ischemic events in the same territory seems particularly high on antiplatelet therapy, up to 30% at 1 year in the largest cohort.<sup>36</sup> In case of recurrent ischemic events despite medical management, diaphragm exclusion with endarterectomy<sup>36</sup> or stenting<sup>43</sup> has been proposed. The largest cohorts of patients undergoing diaphragm exclusion by either method (n=25) reported no recurrences after a follow-up of 1-2 years. In several cases, carotid diaphragm was associated with the presence of an aneurysmal bulb (sometimes called megabulb),<sup>37,44</sup> which may also contribute to the risk of cerebral thromboembolism.

### **Management**

In the absence of randomized trials in cerebrovascular FMD, current medical and interventional strategies rely on observational data and expert opinion. Because of the high prevalence of aneurysms and dissections in other arterial beds (including renal and aortic branch arteries), patients diagnosed with cerebrovascular FMD should undergo a head to pelvic vascular imaging.

### ***Cerebrovascular FMD without stroke complications***

In the presence of FMD without stroke complications, including associated **asymptomatic cervical artery dissection**, daily low dose aspirin (75-100 mg/day) is a reasonable choice to prevent thromboembolic complications, with little evidence to suggest that alternative antiplatelet agents or combination therapy offers additional benefit for primary stroke prevention.<sup>1</sup> Because of the prevalent involvement of other arterial beds, a multidisciplinary approach should be utilized.<sup>2</sup> Hypertension, which is commonly observed in FMD patients, either due to essential or associated renal artery involvement, needs to be controlled. Data comparing antihypertensive therapies in FMD patients with hypertension are lacking and uncertainties remain about which drugs work best in this population. Current guidelines on hypertension should therefore be followed.<sup>45</sup>

In view of the high prevalence of unruptured intracranial aneurysm, FMD patients should also be encouraged to quit smoking, but no data are available in the literature to recommend one method on the others. Observational studies of patients with cervical artery dissection suggest an inverse relationship between dyslipidemia and risk of dissection, in contrast to patients with atherosclerotic disease.<sup>46</sup>

Therefore, statins are not recommended for FMD patients, unless to treat co-prevalent dyslipidemia or atherosclerotic disease. Surgical or endovascular therapy is not recommended for patients with asymptomatic carotid FMD, regardless of the severity of stenosis.<sup>47</sup> Patients should likely avoid chiropractic spinal manipulation and other activities involving rapid hyperextension or lateral rotation of the neck due to the theoretical increased risk of cervical dissection.<sup>48</sup>

### ***Migraine and pulsatile tinnitus***

Although migraine is a common and potentially disabling disorder, no studies have assessed interventions for migraine in FMD patients. Whether typical treatment response differs in FMD patients, or whether certain classes of pharmacotherapy may have specific effects in FMD-related migraine remains unknown. Similar medical management as in the general population is recommended, although abortive triptan therapy or other sympathomimetic agents should be used with caution due to the potential for vasoconstriction.<sup>25</sup> Some studies suggest that patients with incapacitating pulsatile tinnitus might benefit from psychological therapies,<sup>49</sup> although none of these studies focused on patients with FMD.



### ***Unruptured intracranial aneurysm***

In the shortage of data on predictors of rupture of intracranial aneurysm in FMD patients, similar management as in the general population should be proposed. Securing an unruptured intracranial aneurysm (by surgical clipping or endovascular coiling) might be discussed in the presence of risk factors for rupture.<sup>29</sup>

Concern has been raised about the use of antiplatelets in FMD patients because of the high prevalence of intracranial aneurysm. There are insufficient data to establish an association between antiplatelet use and risk of rupture of intracranial aneurysm<sup>29</sup> and its use seems reasonable in FMD patients with a small unruptured intracranial aneurysm. Patients with unruptured intracranial aneurysms who did not undergo an intervention are often monitored with non-invasive imaging, but predictors of aneurysm growth remain unclear and the optimal frequency of follow-up is unknown.<sup>50</sup>

### ***Cerebrovascular FMD with stroke complications***

In FMD patients with **TIA/ischemic stroke** due to arterial stenosis or dissection, management should be similar to that of patients without FMD.<sup>51</sup> In the acute phase, intravenous thrombolysis and/or mechanical thrombectomy are recommended in eligible patients while an antithrombotic agent is to be prescribed in patients non eligible for intravenous thrombolysis.<sup>26,52</sup> Secondary prevention of TIA/ischemic stroke should be tailored to the underlying stroke mechanism. Long-term antithrombotic therapy is recommended but statins are not indicated in the absence of dyslipidemia or vascular atherosclerotic disease.<sup>53</sup> Endovascular therapy (e.g. carotid angioplasty +/- stenting) is typically restricted to cases with persistent cerebrovascular ischemia despite optimal medical therapy,<sup>52,54,55</sup> while dissecting aneurysms (i.e. pseudoaneurysms) are at low risk of ischemic events or rupture and rarely require endovascular treatment.<sup>56,57</sup> If an endovascular intervention is indicated, careful attention should be made to avoid iatrogenic vascular injury during groin access or guide catheter placement. However, whether cerebrovascular FMD increases the risk of iatrogenic dissection or post-stenting pseudoaneurysm development is unknown.

The management of **intracerebral hemorrhage** and **aneurysmal subarachnoid hemorrhage** in patients with FMD does not differ from that in those without.<sup>58,59</sup>

There is limited evidence for endovascular or surgical treatment in cases of intracranial dissection,<sup>60</sup> or moya-moya syndrome in the setting of cerebrovascular FMD.<sup>61</sup>

## **Prognosis**

Given the lack of high quality population-based data, the risk of incident and recurrent stroke in patients with cerebrovascular FMD remains uncertain. Longitudinal studies of cerebrovascular FMD patients (the majority of whom presented with TIA or ischemic stroke) reported a risk of TIA/ischemic stroke during follow-up between 0.6% and 3.7%/year and of intracerebral hemorrhage <1%/year<sup>6,62-67</sup> (**eTable 4**). Risk of FMD progression in cervical/intracranial arteries was estimated to be <1%/year, but no systematic imaging screening was performed in these studies.<sup>6,65,67</sup> Looking at the most recent (>2015) studies of patients with cervical FMD, totalling approximately 100 cases (53% with previous TIA or stroke), the risk of all stroke or TIA during follow-up was <0.5%/year.<sup>6,67</sup> Interestingly, all except one patient with a follow-up event had a previous stroke and none had a progression of FMD in the previously affected artery. Data from the US registry suggest that TIA/ischemic stroke occur mainly in patients with an associated cervical dissection.<sup>3</sup>

In the absence of stroke complications, the prognosis of isolated cerebrovascular FMD appears relatively favourable although cases of cerebrovascular events have been reported in previously unaffected arteries but data on risk factors for FMD progression are lacking.<sup>3,4</sup>

## **Discussion and future directions**

Despite advancements in clinical and radiological characterisation of FMD over time, significant knowledge gaps remain which should foster clinical and pathophysiological research in the neurological manifestations of FMD. International research collaborations as long as inclusion of patients in registries should be promoted to gain knowledge of the mechanisms and evolution of FMD and to raise awareness

among clinicians and patients about this potentially disabling condition. **Box** presents what, we believe, the research priorities specific to cerebrovascular FMD should be.

## References

1. Olin JW, Gornik HL, Bacharach JM, et al. Fibromuscular dysplasia: state of the science and critical unanswered questions: a scientific statement from the American Heart Association. *Circulation*. 2014;129(9):1048-1078.
2. Persu A, Giavarini A, Touze E, et al. European consensus on the diagnosis and management of fibromuscular dysplasia. *J Hypertens*. 2014;32(7):1367-1378.
3. Olin JW, Froehlich J, Gu X, et al. The United States registry for fibromuscular dysplasia: results in the first 447 patients. *Circulation*. 2012;125(25):3182-3190.
4. Plouin PF, Baguet JP, Thony F, et al. High Prevalence of Multiple Arterial Bed Lesions in Patients With Fibromuscular Dysplasia: The ARCADIA Registry (Assessment of Renal and Cervical Artery Dysplasia). *Hypertension*. 2017;70:652-658.
5. Touzé E, Oppenheim C, Trystram D, et al. Fibromuscular dysplasia of cervical and intracranial arteries. *Int J Stroke*. 2010;5(4):296-305.
6. Pasquini M, Trystram D, Nokam G, Gobin-Metteil MP, Oppenheim C, Touze E. Fibromuscular dysplasia of cervicocephalic arteries: Prevalence of multisite involvement and prognosis. *Rev Neurol (Paris)*. 2015;171(8-9):616-623.
7. Oxford Centre for Evidence-Based Medicine—levels of evidence (March 2009). <http://www.cebm.net/oxford-centre-evidence-based-medicine-levels-evidence-march-2009/>. Accessed May, 15 2018.
8. Varennes L, Tahon F, Kastler A, et al. Fibromuscular dysplasia: what the radiologist should know: a pictorial review. *Insights Imaging*. 2015;6(3):295-307.
9. Zhou W, Bush RL, Lin PL, Lumsden AB. Fibromuscular dysplasia of the carotid artery. *J Am Coll Surg*. 2005;200(5):807.
10. Arning C, Grzyska U. Color Doppler imaging of cervicocephalic fibromuscular dysplasia. *Cardiovasc Ultrasound*. 2004;2:7.
11. Sang CN, Whelton PK, Hamper UM, et al. Etiologic factors in renovascular fibromuscular dysplasia. A case-control study. *Hypertension*. 1989;14(5):472-479.
12. O'Connor S, Gornik HL, Froehlich JB, et al. Smoking and Adverse Outcomes in Fibromuscular Dysplasia: U.S. Registry Report. *J Am Coll Cardiol*. 2016;67(14):1750-1751.
13. Southerland AM, Meschia JF, Worrall BB. Shared associations of nonatherosclerotic, large-vessel, cerebrovascular arteriopathies: considering intracranial aneurysms, cervical artery dissection, moyamoya disease and fibromuscular dysplasia. *Curr Opin Neurol*. 2013;26(1):13-28.
14. Schievink WI, Bjornsson J. Fibromuscular dysplasia of the internal carotid artery: a clinicopathological study. *Clin Neuropathol*. 1996;15(1):2-6.
15. De Groote M, Van der Niepen P, Hemelsoet D, et al. Fibromuscular dysplasia - results of a multicentre study in Flanders. *Vasa*. 2017;46(3):211-218.
16. Camuglia A, Manins V, Taylor A, Hengel C. Case Report and Review: Epicardial Coronary Artery Fibromuscular Dysplasia. *Heart Lung Circ*. 2008.
17. Saw J, Ricci D, Starovoytov A, Fox R, Buller CE. Spontaneous coronary artery dissection: prevalence of predisposing conditions including fibromuscular dysplasia in a tertiary center cohort. *JACC Cardiovasc Interv*. 2013;6(1):44-52.
18. Saw J, Aymong E, Sedlak T, et al. Spontaneous coronary artery dissection: association with predisposing arteriopathies and precipitating stressors and cardiovascular outcomes. *Circ Cardiovasc Interv*. 2014;7(5):645-655.
19. Ganesh SK, Morissette R, Xu Z, et al. Clinical and biochemical profiles suggest fibromuscular dysplasia is a systemic disease with altered TGF-beta expression and connective tissue features. *FASEB J*. 2014;28(8):3313-3324.
20. Poloskey SL, Kim E, Sanghani R, et al. Low yield of genetic testing for known vascular connective tissue disorders in patients with fibromuscular dysplasia. *Vasc Med*. 2012;17(6):371-378.

21. Kiando SR, Barlassina C, Cusi D, et al. Exome sequencing in seven families and gene-based association studies indicate genetic heterogeneity and suggest possible candidates for fibromuscular dysplasia. *J Hypertens*. 2015;33(9):1802-1810; discussion 1810.
22. Kiando SR, Tucker NR, Castro-Vega LJ, et al. PHACTR1 Is a Genetic Susceptibility Locus for Fibromuscular Dysplasia Supporting Its Complex Genetic Pattern of Inheritance. *PLoS Genet*. 2016;12(10):e1006367.
23. Gupta RM, Hadaya J, Trehan A, et al. A Genetic Variant Associated with Five Vascular Diseases Is a Distal Regulator of Endothelin-1 Gene Expression. *Cell*. 2017;170(3):522-533 e515.
24. Kadian-Dodov D, Gornik HL, Gu X, et al. Dissection and Aneurysm in Patients With Fibromuscular Dysplasia: Findings From the U.S. Registry for FMD. *J Am Coll Cardiol*. 2016;68(2):176-185.
25. O'Connor SC, Poria N, Gornik HL. Fibromuscular dysplasia: an update for the headache clinician. *Headache*. 2015;55(5):748-755.
26. Debette S. Pathophysiology and risk factors of cervical artery dissection: what have we learnt from large hospital-based cohorts? *Curr Opin Neurol*. 2014;27(1):20-28.
27. Bejot Y, Aboa-Eboule C, Debette S, et al. Characteristics and outcomes of patients with multiple cervical artery dissection. *Stroke*. 2014;45(1):37-41.
28. Cloft HJ, Kallmes DF, Kallmes MH, Goldstein JH, Jensen ME, Dion JE. Prevalence of cerebral aneurysms in patients with fibromuscular dysplasia: a reassessment. *J Neurosurg*. 1998;88(3):436-440.
29. Etminan N, Brown RD, Jr., Beseoglu K, et al. The unruptured intracranial aneurysm treatment score: a multidisciplinary consensus. *Neurology*. 2015;85(10):881-889.
30. Lather HD, Gornik HL, Olin JW, et al. Prevalence of Intracranial Aneurysm in Women With Fibromuscular Dysplasia: A Report From the US Registry for Fibromuscular Dysplasia. *JAMA Neurol*. 2017;74(9):1081-1087.
31. Kirton A, Crone M, Benseler S, et al. Fibromuscular dysplasia and childhood stroke. *Brain*. 2013;136(Pt 6):1846-1856.
32. van de Nes JA, Bajanowski T, Trubner K. Fibromuscular dysplasia of the basilar artery: an unusual case with medico-legal implications. *Forensic Sci Int*. 2007;173(2-3):188-192.
33. Belen D, Bolay H, Firat M, Akpinar G, Bertan V. Unusual appearance of intracranial fibromuscular dysplasia. A case report. *Angiology*. 1996;47(6):627-632.
34. Nakamura M, Rosahl SK, Vorkapic P, Forster C, Samii M. De novo formation of an aneurysm in a case of unusual intracranial fibromuscular dysplasia. *Clin Neurol Neurosurg*. 2000;102(4):259-264.
35. Green R, Gu X, Kline-Rogers E, et al. Differences between the pediatric and adult presentation of fibromuscular dysplasia: results from the US Registry. *Pediatr Nephrol*. 2016;31(4):641-650.
36. Joux J, Chausson N, Jeannin S, et al. Carotid-bulb atypical fibromuscular dysplasia in young Afro-Caribbean patients with stroke. *Stroke*. 2014;45(12):3711-3713.
37. Kubis N, Von LD, Petitjean C, et al. Thrombotic carotid megabulb: fibromuscular dysplasia, septae, and ischemic stroke. *Neurology*. 1999;52(4):883-886.
38. Joux J, Boulanger M, Jeannin S, et al. Association Between Carotid Bulb Diaphragm and Ischemic Stroke in Young Afro-Caribbean Patients: A Population-Based Case-Control Study. *Stroke*. 2016;47:2641-2644.
39. Choi PM, Menon BK, Demchuk AM. Carotid web and stroke. *Eur J Neurol*. 2014;21(6):e53.
40. Choi PM, Singh D, Trivedi A, et al. Carotid Webs and Recurrent Ischemic Strokes in the Era of CT Angiography. *AJNR Am J Neuroradiol*. 2015;36(11):2134-2139.
41. Lenck S, Labeyrie MA, Saint-Maurice JP, Tarlov N, Houdart E. Diaphragms of the carotid and vertebral arteries: an under-diagnosed cause of ischaemic stroke. *Eur J Neurol*. 2014;21(4):586-593.
42. Ehrenfeld WK, Wylie EJ. Fibromuscular dysplasia of the internal carotid artery. *ArchSurg*. 1974;109(5):676-681.
43. Haussen DC, Grossberg JA, Bousslama M, et al. Carotid Web (Intimal Fibromuscular Dysplasia) Has High Stroke Recurrence Risk and Is Amenable to Stenting. *Stroke*. 2017;48(11):3134-3137.

44. Ukkola-Pons E, Sadik JC, Champtiaux N, et al. [Free floating thrombus on carotid megabulb or suspended bulb: what kind of dysplasia?]. *Rev Neurol (Paris)*. 2012;168(1):53-56.
45. Whelton PK, Carey RM, Aronow WS, et al. 2017 ACC/AHA/AAPA/ABC/ACPM/AGS/APhA/ASH/ASPC/NMA/PCNA Guideline for the Prevention, Detection, Evaluation, and Management of High Blood Pressure in Adults: A Report of the American College of Cardiology/American Heart Association Task Force on Clinical Practice Guidelines. *J Am Coll Cardiol*. 2018;71(19):e127-e248.
46. Debette S, Metso T, Pezzini A, et al. Association of vascular risk factors with cervical artery dissection and ischemic stroke in young adults. *Circulation*. 2011;123(14):1537-1544.
47. Brott TG, Halperin JL, Abbara S, et al. 2011 ASA/ACCF/AHA/AANN/AANS/ACR/ASNR/CNS/SAIP/SCAI/SIR/SNIS/SVM/SVS guideline on the management of patients with extracranial carotid and vertebral artery disease: executive summary. A report of the American College of Cardiology Foundation/American Heart Association Task Force on Practice Guidelines, and the American Stroke Association, American Association of Neuroscience Nurses, American Association of Neurological Surgeons, American College of Radiology, American Society of Neuroradiology, Congress of Neurological Surgeons, Society of Atherosclerosis Imaging and Prevention, Society for Cardiovascular Angiography and Interventions, Society of Interventional Radiology, Society of NeuroInterventional Surgery, Society for Vascular Medicine, and Society for Vascular Surgery. *Circulation*. 2011;124(4):489-532.
48. Biller J, Sacco RL, Albuquerque FC, et al. Cervical arterial dissections and association with cervical manipulative therapy: a statement for healthcare professionals from the American Heart Association/American Stroke Association. *Stroke*. 2014;45(10):3155-3174.
49. Searchfield GD, Durai M, Linford T. A State-of-the-Art Review: Personalization of Tinnitus Sound Therapy. *Front Psychol*. 2017;8:1599.
50. Etmnan N, Rinkel GJ. Unruptured intracranial aneurysms: development, rupture and preventive management. *Nat Rev Neurol*. 2016;12(12):699-713.
51. Debette S, Leys D. Cervical-artery dissections: predisposing factors, diagnosis, and outcome. *Lancet neurology*. 2009;8(7):668-678.
52. Powers WJ, Rabinstein AA, Ackerson T, et al. 2018 Guidelines for the Early Management of Patients With Acute Ischemic Stroke: A Guideline for Healthcare Professionals From the American Heart Association/American Stroke Association. *Stroke*. 2018;49(3):e46-e110.
53. Kernan WN, Ovbiagele B, Black HR, et al. Guidelines for the prevention of stroke in patients with stroke and transient ischemic attack: a guideline for healthcare professionals from the American Heart Association/American Stroke Association. *Stroke*. 2014;45(7):2160-2236.
54. Rahme RJ, Aoun SG, McClendon J, Jr., El Ahmadieh TY, Bendok BR. Spontaneous cervical and cerebral arterial dissections: diagnosis and management. *Neuroimaging Clin N Am*. 2013;23(4):661-671.
55. Schirmer CM, Atalay B, Malek AM. Endovascular recanalization of symptomatic flow-limiting cervical carotid dissection in an isolated hemisphere. *Neurosurg Focus*. 2011;30(6):E16.
56. Larsson SC, King A, Madigan J, Levi C, Norris JW, Markus HS. Prognosis of carotid dissecting aneurysms: Results from CADISS and a systematic review. *Neurology*. 2017;88(7):646-652.
57. Touze E, Randoux B, Meary E, Arquizan C, Meder JF, Mas JL. Aneurysmal forms of cervical artery dissection : associated factors and outcome. *Stroke*. 2001;32(2):418-423.
58. Connolly ES, Jr., Rabinstein AA, Carhuapoma JR, et al. Guidelines for the management of aneurysmal subarachnoid hemorrhage: a guideline for healthcare professionals from the American Heart Association/American Stroke Association. *Stroke*. 2012;43(6):1711-1737.
59. Hemphill JC, 3rd, Greenberg SM, Anderson CS, et al. Guidelines for the Management of Spontaneous Intracerebral Hemorrhage: A Guideline for Healthcare Professionals From the American Heart Association/American Stroke Association. *Stroke*. 2015;46(7):2032-2060.
60. Debette S, Compter A, Labeyrie MA, et al. Epidemiology, pathophysiology, diagnosis, and management of intracranial artery dissection. *Lancet Neurol*. 2015;14(6):640-654.

61. Hage ZA, Behbahani M, Amin-Hanjani S, Charbel FT. Carotid bypass for carotid occlusion. *Curr Atheroscler Rep*. 2015;17(7):36.
62. Corrin LS, Sandok BA, Houser OW. Cerebral ischemic events in patients with carotid artery fibromuscular dysplasia. *ArchNeurol*. 1981;38(10):616-618.
63. Liu CH, Wu D, Chin SC, et al. Cervicocranial fibromuscular dysplasia in Taiwanese ischemic stroke patients. *Eur Neurol*. 2012;67(3):129-135.
64. Stewart MT, Moritz MW, Smith RB, III, Fulenwider JT, Perdue GD. The natural history of carotid fibromuscular dysplasia. *J VascSurg*. 1986;3(2):305-310.
65. Wells RP, Smith RR. Fibromuscular dysplasia of the internal carotid artery: a long term follow-up. *Neurosurgery*. 1982;10(1):39-43.
66. Wesen CA, Elliott BM. Fibromuscular dysplasia of the carotid arteries. *Am J Surg*. 1986;151(4):448-451.
67. Harriott AM, Zimmerman E, Singhal AB, Jaff MR, Lindsay ME, Rordorf GA. Cerebrovascular fibromuscular dysplasia: The MGH cohort and literature review. *Neurol Clin Pract*. 2017;7(3):225-236.

**Table – Angiographic Classification of Fibromuscular Dysplasia (FMD) with two categories: focal and multifocal<sup>1,2</sup>**

	<b>Multifocal FMD</b>	<b>Focal FMD</b>
<b>Angiographic appearance</b>	<ul style="list-style-type: none"> <li>• Alternating arterial dilatation and constriction (“string of beads” appearance)</li> <li>• Areas of dilatation are larger than the normal calibre of the artery</li> <li>• Commonly occurs in the middle or distal portion of the artery</li> </ul>	<ul style="list-style-type: none"> <li>• Unifocal concentric (&lt; 1cm in length) or tubular (≥ 1cm) smooth narrowing *</li> <li>• Can occur in any portion of the artery</li> </ul>
<b>Histology</b>	<ul style="list-style-type: none"> <li>• Medial fibroplasia (most common) Involves a functional transformation in smooth muscle cells of the arterial media, ultimately associated with plurifocal medial fibroplasia, attenuation of elastic fibres, and abnormal collagen synthesis.<sup>13</sup></li> <li>• Perimedial fibroplasia (rare)‡</li> </ul>	<ul style="list-style-type: none"> <li>• Intimal fibroplasia (most common)</li> <li>• Adventitial (periarterial) fibroplasia (rare)</li> <li>• Medial hyperplasia (rare)</li> </ul>
<b>Frequency</b>	<ul style="list-style-type: none"> <li>• 90%</li> </ul>	<ul style="list-style-type: none"> <li>• 10% (unifocal FMD: &lt;10% and tubular FMD: &lt;1%)</li> </ul>
<b>Associated features</b>	<p>Aneurysm, dissection, and tortuosity of medium-sized arteries may be present, but their presence alone is insufficient to diagnose FMD. Multifocal and focal lesions may coexist in the same patient (20%).</p>	

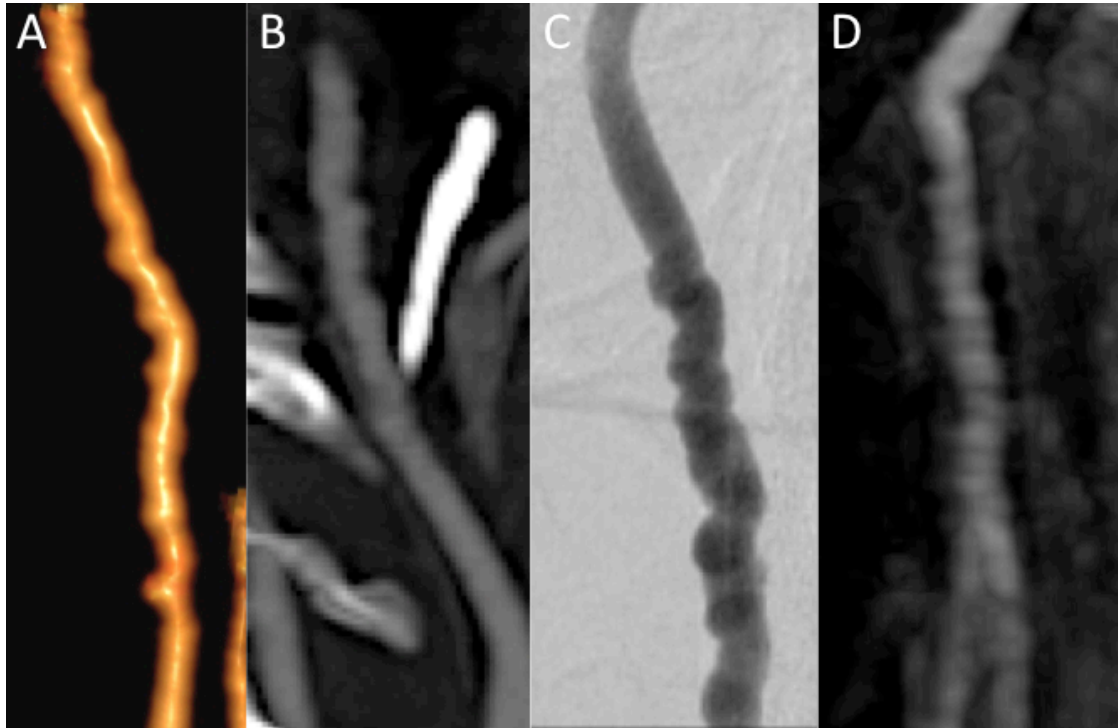
\* There may be multiple areas of focal disease (e.g. carotid and vertebral artery) in the same patient.

‡This rare form of FMD typically occurs in young girls (e.g. 5 to 15 years of age). Although there is a beaded appearance to the renal arteries, the beads are smaller than the normal renal artery and less numerous.



**Figure 1 – Multimodal imaging of the same vessel of a typical multifocal cervical fibromuscular dysplasia**

- A. Computerized tomography-angiography (CTA), volume rendering reconstruction of a left cervical internal carotid artery with string of beads appearance.
- B. CTA, maximum intensity projection reconstruction of the same artery.
- C. Oblique projection of conventional angiography.
- D. 3D T1 contrast enhanced magnetic resonance angiography (MRA) in maximum intensity projection reconstruction.

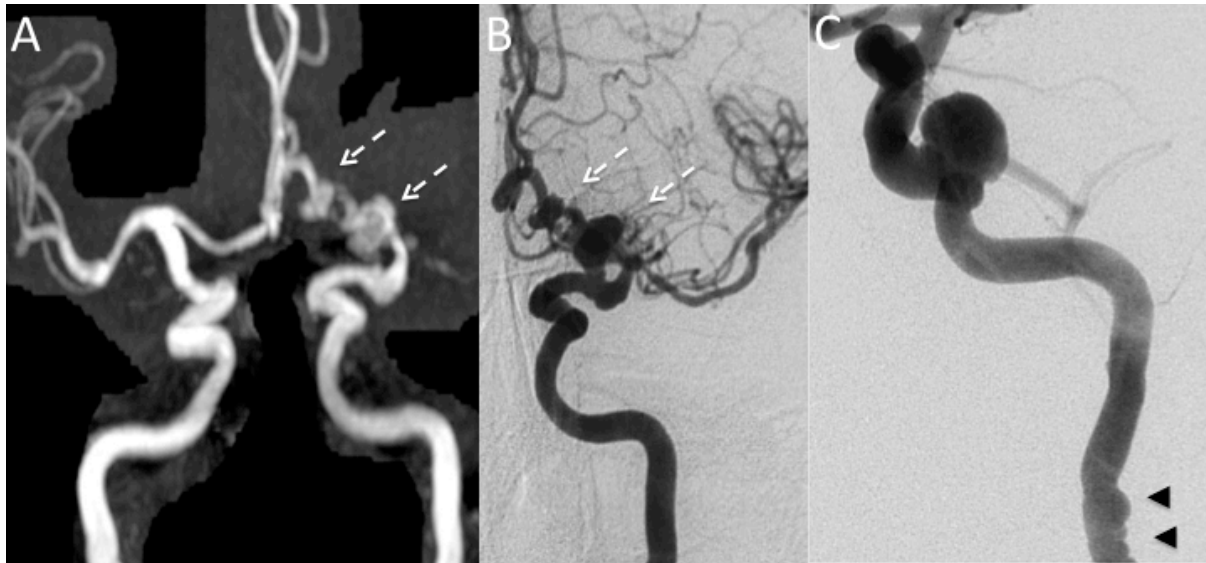


**Figure 2 - Cervical fibromuscular dysplasia (FMD) associated with intracranial aneurysms**

A. Coronal view of a Maximum Intensity Projection (MIP) on a tridimensional Time of Flight sequence MRI of a patient harboring a cervical FMD associated with intracranial aneurysms (dotted white arrows).

B. Antero-posterior angiogram of a left internal carotid artery on the same patient showing more details of this intracranial form.

C. Antero-posterior angiogram of a left internal carotid artery in a different patient, showing on the same image the large intracranial aneurysm and cervical fibromuscular dysplasia (black arrow head).

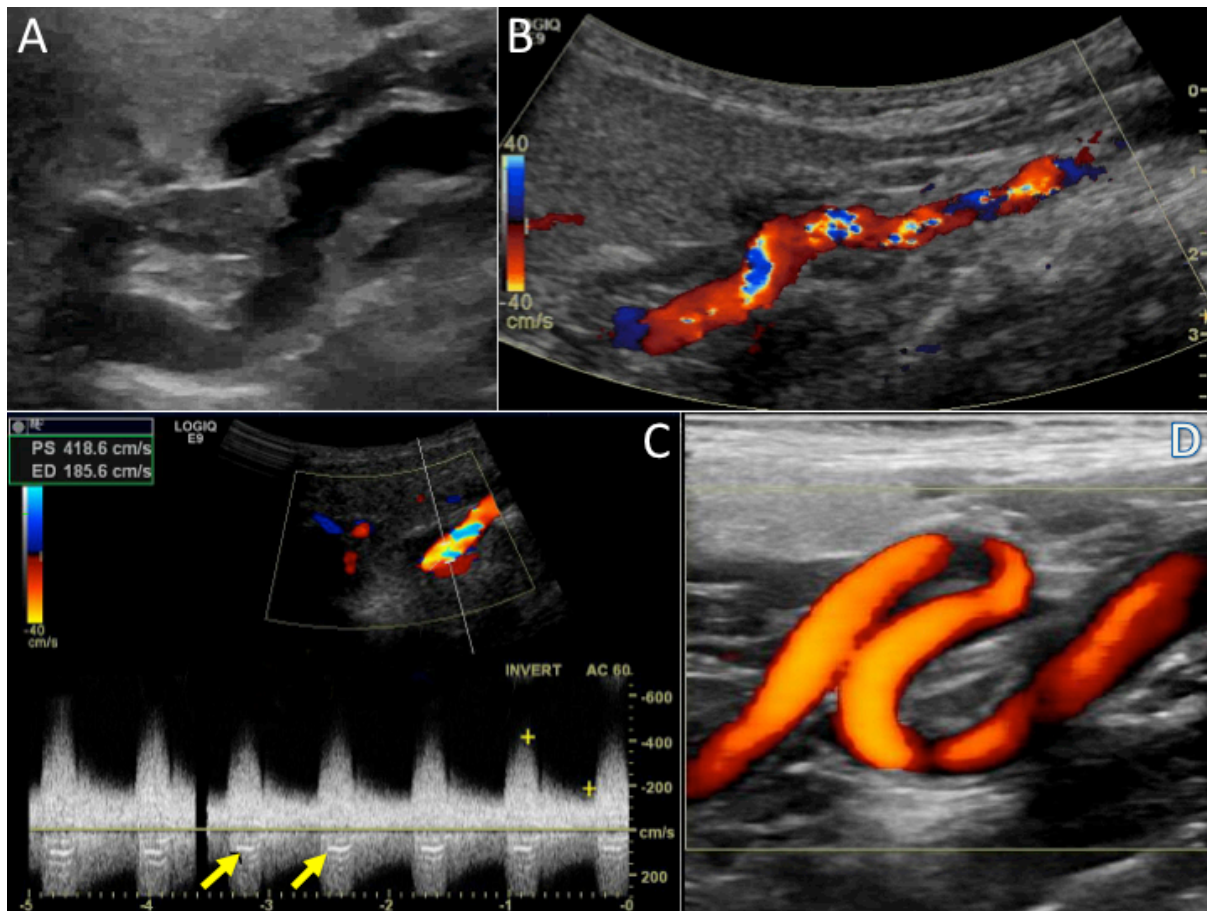


### Figure 3 – Typical duplex ultrasound findings of carotid fibromuscular dysplasia (FMD)

The string of beads appearance, (visualised by multiple areas of focal hyper-echoic thickening of the arterial wall alternating with thin dilated areas), is not commonly seen on ultrasound.<sup>4</sup> Visualization of the beading, when present, can be facilitated by the use of three dimensional color doppler.<sup>5</sup> Common ultrasound findings include a combination of increased velocity of blood flow, tortuosity, and turbulence in the mid to distal internal carotid artery.<sup>6</sup>

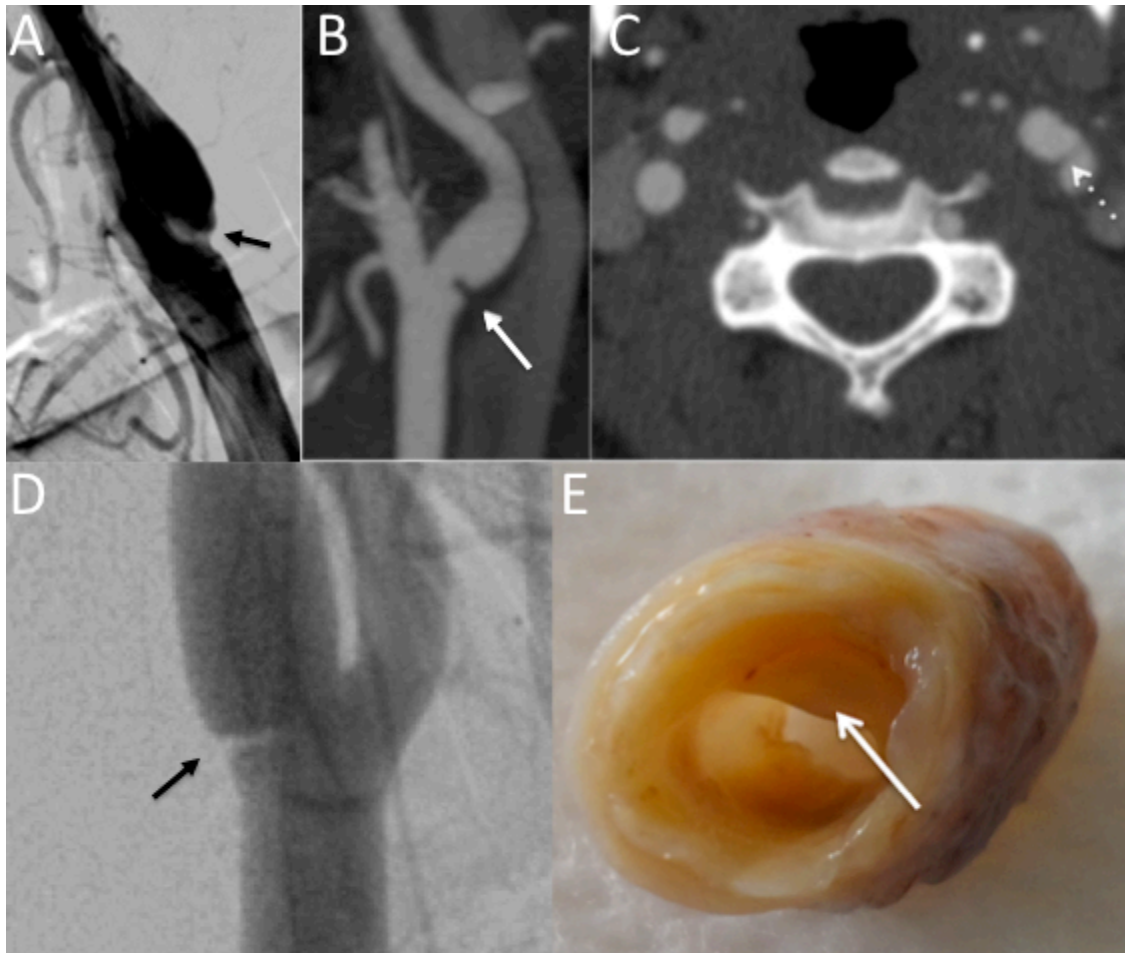
- A. B-mode imaging showing the beading and tortuosity of the mid and distal internal carotid artery.
- B. Color Doppler of the distal internal carotid artery exhibiting the typical pattern of tortuosity and marked turbulence.
- C. Color Doppler showing turbulence and spectral analysis demonstrating high peak velocity (419 cm/s) and end-diastolic velocity (186 cm/s). The "seagull" (yellow arrow) indicates that the stenosis is quite severe.
- D. Color power angiography demonstrating severe tortuosity and redundancy (S curve) of the internal carotid artery.

From Olin JW, Gornik HL, Bacharach JM et al. *Circulation* 2014;129:1048-1078.



**Figure 4 – Carotid Bulb Diaphragm form of fibromuscular dysplasia (FMD)**

- A. Conventional angiography of an internal carotid artery, showing a thin translucent endoluminal diaphragm (black arrow).
- B. Regular and thin intraluminal filling defect on an oblique reconstruction of cervical computerized tomography-angiography (CTA) (white arrow).
- C. Axial appearance on the same exam (white dotted arrow).
- D. Another example of carotid diaphragm on conventional angiography (black arrow).
- E. Macroscopic view of carotid bulb diaphragm: focal and non-circumferential thin membrane (white arrow) located on the posterior wall of the carotid bulb. The relationship of this entity to multifocal or focal fibromuscular dysplasia remains uncertain.



### **Box – Proposal for future research priorities in cerebrovascular fibromuscular dysplasia (FMD)**

- Better determine the natural history of cerebrovascular FMD, identify risk factors for cerebrovascular complications, and to address optimal symptomatic and preventive management in cerebrovascular FMD. Also, more research is needed to risk-stratify asymptomatic/benign FMD phenotypes from more severe types with more disabling symptoms or higher risk for stroke or associated cervical artery dissection or intracranial aneurysm formation. Prospective randomized controlled trials are warranted in cerebrovascular FMD but limited by the relatively small numbers of cases at single centers. Therefore, multicentre trials or expanded prospective registries remain a top research priority. Apart from the US and the European registries, others have been implemented in Argentina, Australia, China, Japan, and Tunisia and strategies to raise awareness of the existence of these registries should be facilitated to help increase our collective knowledge. The French research programs ARCADIA and PROFILE are currently addressing the co-prevalence of cerebrovascular and renal FMD and the risk of clinical or radiological progression in a cohort of about 500 patients.<sup>4</sup>
- To provide further insight, beyond the PHACTR1 locus, into the genetics and pathophysiology of FMD and associated cerebrovascular phenotypes, including migraine, cervical artery dissection, and intracranial aneurysm. We also need better pathophysiological understanding of the mechanism of disease mediated by the PHACTR1 locus on downstream endothelin expression and physiology in the arterial wall. Genetic data collection should be more promoted among clinicians and patients to allow further sequencing studies.
- Characterization of the mechanisms of migraine and/or headaches in cervical FMD as well as to identify which treatment strategies are safe and likely to be the most beneficial.
- To elucidate whether there is an inflammatory or hormonal role in the development, progression and management of cervico-cephalic FMD
- Determination of additional research priorities that are important to patients with cerebrovascular FMD, utilizing patient advocacy groups.

## **Fibromuscular dysplasia and its neurological manifestations: a review**

Emmanuel Touzé, Andrew M Southerland, Marion Boulanger, Paul-Emile Labeyrie, Michel Azizi, Nabila Bouatia-Naji, Stéphanie Debette, Heather L Gornik, Shazam M Hussain, Xavier Jeunemaitre, Julien Joux, Adam Kirton, Claire Le Hello, Jennifer J Majersik, J Mocco, Alexandre Persu, Aditya Sharma, Bradford B Worrall, Jeffrey W Olin, Pierre-François Plouin.

### **Online-only Materials**

**Description of the preferred techniques for computerized tomography-angiography (CTA) and magnetic resonance angiography (MRA) and common findings on ultrasound in cerebrovascular fibromuscular dysplasia (FMD)**

**eTable 1 – Evidence level of studies evaluating epidemiology, genetic risk, presenting manifestations, cerebrovascular clinical manifestations, management and prognosis in neurological manifestations of fibromuscular dysplasia: summary of systematic review according to the Oxford Centre for Evidence-based Medicine**

**eTable 2– Summary of the largest ( $\geq 15$  patients) case studies of patients with cerebrovascular fibromuscular dysplasia**

**eTable 3 – Genetic investigations and syndromic reports of fibromuscular dysplasia**

**eTable 4 – Prognosis of patients with cerebrovascular fibromuscular dysplasia (FMD)**

**eFigure 1 – PRISMA flow diagram describing identification, screening, eligibility, and inclusion of studies in the systematic review**

**eFigure 2 – Mild cervical and focal form of fibromuscular dysplasia (FMD)**

**eFigure 3 – Illustrative clinical case of diffuse fibromuscular dysplasia (FMD) in a young woman.**

## Description of the preferred techniques for computerized tomography-angiography (CTA) and magnetic resonance angiography (MRA) and common findings on ultrasound in cerebrovascular fibromuscular dysplasia (FMD)

### *Computerized tomography-angiography (CTA)*

The preferred technique for CTA includes contrast bolus injection with bolus-tracking acquisition that allows for detection of luminal defects and arterial wall dysplasia.<sup>1</sup> Post-processing is a helpful tool in the diagnosis of **fibromuscular dysplasia** (FMD) involving the cervico-encephalic arteries, including volume rendering, maximum intensity projection, and multi planar reconstruction.

### *Magnetic resonance angiography (MRA)*

Several acquisition techniques and protocols for MRA (such as “time-of-flight”, contrast enhanced time-of-flight, or 3D contrast enhanced fast spin echo) are available but none of these sequences have been compared to one another for the diagnosis of cerebrovascular FMD. However, dynamic contrast enhancement is recommended to reduce artifact due to turbulence and flow modification.<sup>1,2</sup> Like CTA, post-processing tools of MRA may further assist in the diagnosis for mild or focal forms of cervico-cephalic FMD (**efigure 2**).

### *Duplex ultrasound*

Duplex ultrasound may be used to diagnose and monitor patients with FMD involving the extracranial carotid arteries but is less accurate than CTA or MRA (**Figure 3**). Ultrasound is also inadequate for the assessment of vertebral or intracranial arteries.<sup>3</sup> The string of beads appearance, (visualised by multiple areas of focal hyper-echoic thickening of the arterial wall alternating with thin dilated areas), is not commonly seen on ultrasound.<sup>4</sup> Visualization of the beading, when present, can be facilitated by the use of three dimensional color doppler.<sup>5</sup> Common ultrasound findings include a combination of increased velocity of blood flow, tortuosity, and turbulence in the mid to distal internal carotid artery (ICA).<sup>6</sup>

## References

1. Varennes L, Tahon F, Kastler A, et al. Fibromuscular dysplasia: what the radiologist should know: a pictorial review. *Insights into imaging*. 2015;6(3):295-307.
2. Persu A, Giavarini A, Touze E, et al. European consensus on the diagnosis and management of fibromuscular dysplasia. *Journal of hypertension*. 2014;32(7):1367-1378.
3. Arning C, Grzyska U. Color Doppler imaging of cervicocephalic fibromuscular dysplasia. *Cardiovascular ultrasound*. 2004;2:7.
4. Zhou W, Bush RL, Lin PL, Lumsden AB. Fibromuscular dysplasia of the carotid artery. *Journal of the American College of Surgeons*. 2005;200(5):807.
5. Chehab BM, Gupta K. Contemporary diagnosis of carotid fibromuscular dysplasia: role of power Doppler and a review of other diagnostic modalities. *Reviews in cardiovascular medicine*. 2013;14(2-4):e136-143.
6. Olin JW, Gornik HL, Bacharach JM, et al. Fibromuscular dysplasia: state of the science and critical unanswered questions: a scientific statement from the American Heart Association. *Circulation*. 2014;129(9):1048-1078.

**eTable 1 – Evidence level of studies evaluating epidemiology, genetic risk, presenting manifestations, cerebrovascular clinical manifestations, management and prognosis in neurological manifestations of fibromuscular dysplasia according to the Oxford Centre for Evidence-based Medicine.**

**Quality Rating Scheme for Studies and Other Evidence according to the Oxford Centre for Evidence-based Medicine** (<https://www.cebm.net/2009/06/oxford-centre-evidence-based-medicine-levels-evidence-march-2009/>):

1. Properly powered and conducted randomized clinical trial; systematic review with meta-analysis
2. Well-designed controlled trial without randomization; prospective comparative cohort trial
3. Case-control studies; retrospective cohort study
4. Case series with or without intervention; cross-sectional study
5. Opinion of respected authorities; case reports

Manuscript sections	Number of studies included by evidence level
Classification and diagnostic criteria	- 1 Level 4 study (Southerland, 2013) <sup>1</sup> - 2 guidelines/statements (Persu, 2014; Olin, 2014) <sup>2,3</sup>
Imaging	- 3 level 4 studies (Touzé, 2010; Varennes, 2015; Zhou, 2005) <sup>4-6</sup> - 1 level 5 study (Arning, 2004) <sup>7</sup> - 1 guideline/statement (Persu, 2014) <sup>3</sup>
Epidemiology	- 7 Level 3 studies (Schievink, 1996; Olin, 2012; Saw, 2013; Saw, 2014; O'Connor, 2016; Plouin, 2017) <sup>8-13</sup> - 2 level 4 studies (Pasquini, 2015; Southerland, 2013) <sup>1,14</sup> - 2 Level 5 studies (Touzé, 2010; Camuglia, 2008) <sup>6,15</sup> - 1 guideline/statement (Olin, 2014) <sup>2</sup>
Genetic risk	- 5 Level 3 studies (Bofinger, 2000; Bofinger, 2001; Poloskey, 2012; Kiando, 2015; Kiando, 2016) <sup>16-20</sup> - 5 level 4 studies (Schievink, 1996; Grimbert, 1998; Marks, 2011; Southerland, 2013; Gupta, 2017) <sup>1,21-24</sup> - 7 Level 5 study (Fleischer, 1978; Kousseff, 1989; Lancman, 1991; Schievink, 1994; Schievink, 1994; Solder, 1997; Ganesh, 2014) <sup>25-30</sup>
Presenting and cerebrovascular clinical manifestations	- 33 Level 3 studies (Houser, 1971; Ehrenfield, 1974; Manelfe, 1974; Osborn, 1977; Boudin, 1977; Effeney, 1980; Corrin, 1981; So, 1981; Collins, 1981; Wells, 1982; Mettinger, 1982; Kelly, 1982; Stewart, 1986; Wesen, 1986; Moreau, 1993; Cloft, 1998; Liu, 2012; Olin, 2012; Kirton, 2013; Debette, 2014; Béjot 2014; Joux, 2014; O'Connor, 2015; Pasquini, 2015; Choi, 2015; Kadian-Dodov, 2016; Joux, 2016; Green 2016; Hariott, 2017; Plouin, 2017; Haussen, 2017; Lather, 2017; de Groote, 2017) <sup>8,9,14,31-60</sup> - 8 Level 4 studies (Belen, 1996; Faggioli, 1996; Nakamura, 2000; Kubis, 1999; Southerland, 2013; Lenck, 2014; Touzé, 2010; Ukkola-Pons, 2012) <sup>1,6,36,61-66</sup> - 2 Level 5 studies (Choi, 2014; van de Nes, 2017) <sup>67,68</sup>
Management	- 3 level 3 studies (O'Connor, 2015; Debette, 2014; Larsson, 2017) <sup>50,69,70</sup> - 2 level 4 studies (Touzé, 2001; Schirmer, 2011) <sup>71,72</sup> - 3 Level 5 studies (Debette, 2009; Debette, 2015; Hage, 2015) <sup>69,73,74</sup> - 13 guidelines/statements (Brott, 2011; Connolly, 2012; Rahme, 2013; Biller, 2014; Kernan, 2014; Olin, 2014; Persu, 2014; Etminan, 2015; Hemphill, 2015; Etminan, 2016; Searchfield, 2017; Powers, 2018; Whelton, 2018) <sup>2,3,48,75-84</sup>
Prognosis	- 1 Level 3 study (Olin, 2012) <sup>9</sup> - 7 level 4 studies (Corrin, 1981; Wells, 1982; Wesen, 1986; Stewart, 1986; Liu, 2012; Pasquini, 2015; Hariott, 2017) <sup>14,33,36,39,45-47</sup>

**References**



1. Southerland AM, Meschia JF, Worrall BB. Shared associations of nonatherosclerotic, large-vessel, cerebrovascular arteriopathies: considering intracranial aneurysms, cervical artery dissection, moyamoya disease and fibromuscular dysplasia. *Curr Opin Neurol*. 2013;26(1):13-28.
2. Olin JW, Gornik HL, Bacharach JM, et al. Fibromuscular dysplasia: state of the science and critical unanswered questions: a scientific statement from the American Heart Association. *Circulation*. 2014;129(9):1048-1078.
3. Persu A, Giavarini A, Touze E, et al. European consensus on the diagnosis and management of fibromuscular dysplasia. *J Hypertens*. 2014;32(7):1367-1378.
4. Varennes L, Tahon F, Kastler A, et al. Fibromuscular dysplasia: what the radiologist should know: a pictorial review. *Insights Imaging*. 2015;6(3):295-307.
5. Zhou W, Bush RL, Lin PL, Lumsden AB. Fibromuscular dysplasia of the carotid artery. *J Am Coll Surg*. 2005;200(5):807.
6. Touzé E, Oppenheim C, Trystram D, et al. Fibromuscular dysplasia of cervical and intracranial arteries. *Int J Stroke*. 2010;5(4):296-305.
7. Arning C, Grzyska U. Color Doppler imaging of cervicocephalic fibromuscular dysplasia. *Cardiovasc Ultrasound*. 2004;2:7.
8. O'Connor S, Gornik HL, Froehlich JB, et al. Smoking and Adverse Outcomes in Fibromuscular Dysplasia: U.S. Registry Report. *J Am Coll Cardiol*. 2016;67(14):1750-1751.
9. Olin JW, Froehlich J, Gu X, et al. The United States registry for fibromuscular dysplasia: results in the first 447 patients. *Circulation*. 2012;125(25):3182-3190.
10. Saw J, Aymong E, Sedlak T, et al. Spontaneous coronary artery dissection: association with predisposing arteriopathies and precipitating stressors and cardiovascular outcomes. *Circ Cardiovasc Interv*. 2014;7(5):645-655.
11. Saw J, Ricci D, Starovoytov A, Fox R, Buller CE. Spontaneous coronary artery dissection: prevalence of predisposing conditions including fibromuscular dysplasia in a tertiary center cohort. *JACC Cardiovasc Interv*. 2013;6(1):44-52.
12. Schievink WI, Bjornsson J. Fibromuscular dysplasia of the internal carotid artery: a clinicopathological study. *Clin Neuropathol*. 1996;15(1):2-6.
13. Sang CN, Whelton PK, Hamper UM, et al. Etiologic factors in renovascular fibromuscular dysplasia. A case-control study. *Hypertension*. 1989;14(5):472-479.
14. Pasquini M, Trystram D, Nokam G, Gobin-Metteil MP, Oppenheim C, Touze E. Fibromuscular dysplasia of cervicocephalic arteries: Prevalence of multisite involvement and prognosis. *Rev Neurol (Paris)*. 2015;171(8-9):616-623.
15. Camuglia A, Manins V, Taylor A, Hengel C. Case Report and Review: Epicardial Coronary Artery Fibromuscular Dysplasia. *Heart Lung Circ*. 2008.
16. Bofinger A, Hawley C, Fisher P, Daunt N, Stowasser M, Gordon R. Alpha-1-antitrypsin phenotypes in patients with renal arterial fibromuscular dysplasia. *J Hum Hypertens*. 2000;14(2):91-94.
17. Bofinger A, Hawley C, Fisher P, Daunt N, Stowasser M, Gordon R. Polymorphisms of the renin-angiotensin system in patients with multifocal renal arterial fibromuscular dysplasia. *J Hum Hypertens*. 2001;15(3):185-190.
18. Poloskey SL, Kim E, Sanghani R, et al. Low yield of genetic testing for known vascular connective tissue disorders in patients with fibromuscular dysplasia. *Vasc Med*. 2012;17(6):371-378.
19. Kiando SR, Barlassina C, Cusi D, et al. Exome sequencing in seven families and gene-based association studies indicate genetic heterogeneity and suggest possible candidates for fibromuscular dysplasia. *J Hypertens*. 2015;33(9):1802-1810; discussion 1810.
20. Kiando SR, Tucker NR, Castro-Vega LJ, et al. PHACTR1 Is a Genetic Susceptibility Locus for Fibromuscular Dysplasia Supporting Its Complex Genetic Pattern of Inheritance. *PLoS Genet*. 2016;12(10):e1006367.
21. Schievink WI, Puumala MR, Meyer FB, Raffel C, Katzmann JA, Parisi JE. Giant intracranial aneurysm and fibromuscular dysplasia in an adolescent with alpha 1-antitrypsin deficiency. *J Neurosurg*. 1996;85(3):503-506.
22. Grimbert P, Fiquier-Kempf B, Coudol P, et al. [Genetic study of renal artery fibromuscular dysplasia]. *Arch Mal Coeur Vaiss*. 1998;91(8):1069-1071.
23. Marks SD, Gullett AM, Brennan E, et al. Renal FMD may not confer a familial hypertensive risk nor is it caused by ACTA2 mutations. *Pediatr Nephrol*. 2011;26(10):1857-1861.

24. Gupta RM, Hadaya J, Trehan A, et al. A Genetic Variant Associated with Five Vascular Diseases Is a Distal Regulator of Endothelin-1 Gene Expression. *Cell*. 2017;170(3):522-533 e515.
25. Fleisher GR, Buck BE, Cornfeld D. Primary intimal fibroplasia in a child with Down's syndrome. *Am J Dis Child*. 1978;132(7):700-703.
26. Lancman M, Mesropian H, Serra P, Granillo R. Turner's syndrome, fibromuscular dysplasia, and stroke. *Stroke*. 1991;22(2):269-271.
27. Schievink WI, Bjornsson J, Parisi JE, Prakash UB. Arterial fibromuscular dysplasia associated with severe alpha 1-antitrypsin deficiency. *Mayo Clin Proc*. 1994;69(11):1040-1043.
28. Schievink WI, Bjornsson J, Piepgras DG. Coexistence of fibromuscular dysplasia and cystic medial necrosis in a patient with Marfan's syndrome and bilateral carotid artery dissections. *Stroke*. 1994;25(12):2492-2496.
29. Solder B, Streif W, Ellemunter H, Mayr U, Jaschke W. Fibromuscular dysplasia of the internal carotid artery in a child with alpha-1-antitrypsin deficiency. *DevMedChild Neurol*. 1997;39(12):827-829.
30. Ganesh SK, Morissette R, Xu Z, et al. Clinical and biochemical profiles suggest fibromuscular dysplasia is a systemic disease with altered TGF-beta expression and connective tissue features. *FASEB J*. 2014;28(8):3313-3324.
31. Boudin G, Guillard A, Romion A, et al. [Fibro-muscular dysplasia of the carotid and vertebral arteries. Considerations apropos of 37 cases]. *Rev Otoneuroophthalmol*. 1977;49(4):297-300.
32. Collins GJ, Jr., Rich NM, Clagett GP, Spebar MJ, Salander JM. Fibromuscular dysplasia of the internal carotid arteries. Clinical experience and follow-up. *AnnSurg*. 1981;194(1):89-96.
33. Corrin LS, Sandok BA, Houser OW. Cerebral ischemic events in patients with carotid artery fibromuscular dysplasia. *ArchNeurol*. 1981;38(10):616-618.
34. Effeney DJ, Ehrenfeld WK, Stoney RJ, Wylie EJ. Why operate on carotid fibromuscular dysplasia? *ArchSurg*. 1980;115(11):1261-1265.
35. Ehrenfeld WK, Wylie EJ. Fibromuscular dysplasia of the internal carotid artery. *ArchSurg*. 1974;109(5):676-681.
36. Harriott AM, Zimmerman E, Singhal AB, Jaff MR, Lindsay ME, Rordorf GA. Cerebrovascular fibromuscular dysplasia: The MGH cohort and literature review. *Neurol Clin Pract*. 2017;7(3):225-236.
37. Houser OW, Baker HL, Jr., Sandok BA, Holley KE. Cephalic arterial fibromuscular dysplasia. *Radiology*. 1971;101(3):605-611.
38. Kelly TF, Morris GC, Jr. Arterial fibromuscular disease. Observations on pathogenesis and surgical management. *Am J Surg*. 1982;143:232-236.
39. Liu CH, Wu D, Chin SC, et al. Cervicocranial fibromuscular dysplasia in Taiwanese ischemic stroke patients. *Eur Neurol*. 2012;67(3):129-135.
40. Manelfe C, Clarisse J, Fredy D, André JM, Crouzet G. Dysplasies fibromusculaires des artères cervico-céphaliques. *J Neuroradiol*. 1974;1:149-231.
41. Mettinger KL, Ericson K. Fibromuscular dysplasia and the brain. I. Observations on angiographic, clinical and genetic characteristics. *Stroke*. 1982;13(1):46-52.
42. Moreau P, Albat B, Thevenet A. Fibromuscular dysplasia of the internal carotid artery: long-term surgical results. *J CardiovascSurg(Torino)*. 1993;34(6):465-472.
43. Osborn AG, Anderson RE. Angiographic spectrum of cervical and intracranial fibromuscular dysplasia. *Stroke*. 1977;8(5):617-626.
44. So EL, Toole JF, Dalal P, Moody DM. Cephalic fibromuscular dysplasia in 32 patients: clinical findings and radiologic features. *ArchNeurol*. 1981;38(10):619-622.
45. Stewart MT, Moritz MW, Smith RB, III, Fulenwider JT, Perdue GD. The natural history of carotid fibromuscular dysplasia. *J VascSurg*. 1986;3(2):305-310.
46. Wells RP, Smith RR. Fibromuscular dysplasia of the internal carotid artery: a long term follow-up. *Neurosurgery*. 1982;10(1):39-43.
47. Wesen CA, Elliott BM. Fibromuscular dysplasia of the carotid arteries. *Am J Surg*. 1986;151(4):448-451.
48. Biller J, Sacco RL, Albuquerque FC, et al. Cervical arterial dissections and association with cervical manipulative therapy: a statement for healthcare professionals from the american heart association/american stroke association. *Stroke*. 2014;45(10):3155-3174.
49. Debette S. Pathophysiology and risk factors of cervical artery dissection: what have we learnt from large hospital-based cohorts? *Curr Opin Neurol*. 2014;27(1):20-28.
50. O'Connor SC, Poria N, Gornik HL. Fibromuscular dysplasia: an update for the headache clinician. *Headache*. 2015;55(5):748-755.

51. Plouin PF, Baguet JP, Thony F, et al. High Prevalence of Multiple Arterial Bed Lesions in Patients With Fibromuscular Dysplasia: The ARCADIA Registry (Assessment of Renal and Cervical Artery Dysplasia). *Hypertension*. 2017;70:652-658.
52. Choi PM, Singh D, Trivedi A, et al. Carotid Webs and Recurrent Ischemic Strokes in the Era of CT Angiography. *AJNR Am J Neuroradiol*. 2015;36(11):2134-2139.
53. Cloft HJ, Kallmes DF, Kallmes MH, Goldstein JH, Jensen ME, Dion JE. Prevalence of cerebral aneurysms in patients with fibromuscular dysplasia: a reassessment. *J Neurosurg*. 1998;88(3):436-440.
54. Joux J, Boulanger M, Jeannin S, et al. Association Between Carotid Bulb Diaphragm and Ischemic Stroke in Young Afro-Caribbean Patients: A Population-Based Case-Control Study. *Stroke*. 2016;47:2641-2644.
55. Joux J, Chausson N, Jeannin S, et al. Carotid-bulb atypical fibromuscular dysplasia in young Afro-Caribbean patients with stroke. *Stroke*. 2014;45(12):3711-3713.
56. Green R, Gu X, Kline-Rogers E, et al. Differences between the pediatric and adult presentation of fibromuscular dysplasia: results from the US Registry. *Pediatr Nephrol*. 2016;31(4):641-650.
57. Kadian-Dodov D, Gornik HL, Gu X, et al. Dissection and Aneurysm in Patients With Fibromuscular Dysplasia: Findings From the U.S. Registry for FMD. *J Am Coll Cardiol*. 2016;68(2):176-185.
58. Kirton A, Crone M, Benseler S, et al. Fibromuscular dysplasia and childhood stroke. *Brain*. 2013;136(Pt 6):1846-1856.
59. Lather HD, Gornik HL, Olin JW, et al. Prevalence of Intracranial Aneurysm in Women With Fibromuscular Dysplasia: A Report From the US Registry for Fibromuscular Dysplasia. *JAMA Neurol*. 2017;74(9):1081-1087.
60. Haussen DC, Grossberg JA, Bousslama M, et al. Carotid Web (Intimal Fibromuscular Dysplasia) Has High Stroke Recurrence Risk and Is Amenable to Stenting. *Stroke*. 2017;48(11):3134-3137.
61. Belen D, Bolay H, Firat M, Akpınar G, Bertan V. Unusual appearance of intracranial fibromuscular dysplasia. A case report. *Angiology*. 1996;47(6):627-632.
62. Kubis N, Von LD, Petitjean C, et al. Thrombotic carotid megabulb: fibromuscular dysplasia, septae, and ischemic stroke. *Neurology*. 1999;52(4):883-886.
63. Lenck S, Labeyrie MA, Saint-Maurice JP, Tarlov N, Houdart E. Diaphragms of the carotid and vertebral arteries: an under-diagnosed cause of ischaemic stroke. *Eur J Neurol*. 2014;21(4):586-593.
64. Nakamura M, Rosahl SK, Vorkapic P, Forster C, Samii M. De novo formation of an aneurysm in a case of unusual intracranial fibromuscular dysplasia. *Clin NeurolNeurosurg*. 2000;102(4):259-264.
65. Ukkola-Pons E, Sadik JC, Champtiaux N, et al. [Free floating thrombus on carotid megabulb or suspended bulb: what kind of dysplasia?]. *Rev Neurol (Paris)*. 2012;168(1):53-56.
66. De Groote M, Van der Niepen P, Hemelsoet D, et al. Fibromuscular dysplasia - results of a multicentre study in Flanders. *Vasa*. 2017;46(3):211-218.
67. Choi PM, Menon BK, Demchuk AM. Carotid web and stroke. *Eur J Neurol*. 2014;21(6):e53.
68. van de Nes JA, Bajanowski T, Trubner K. Fibromuscular dysplasia of the basilar artery: an unusual case with medico-legal implications. *Forensic Sci Int*. 2007;173(2-3):188-192.
69. Debette S, Compter A, Labeyrie MA, et al. Epidemiology, pathophysiology, diagnosis, and management of intracranial artery dissection. *Lancet Neurol*. 2015;14(6):640-654.
70. Larsson SC, King A, Madigan J, Levi C, Norris JW, Markus HS. Prognosis of carotid dissecting aneurysms: Results from CADISS and a systematic review. *Neurology*. 2017;88(7):646-652.
71. Schirmer CM, Atalay B, Malek AM. Endovascular recanalization of symptomatic flow-limiting cervical carotid dissection in an isolated hemisphere. *Neurosurg Focus*. 2011;30(6):E16.
72. Touze E, Randoux B, Meary E, Arquizan C, Meder JF, Mas JL. Aneurysmal forms of cervical artery dissection : associated factors and outcome. *Stroke*. 2001;32(2):418-423.
73. Debette S, Leys D. Cervical-artery dissections: predisposing factors, diagnosis, and outcome. *Lancet neurology*. 2009;8(7):668-678.
74. Hage ZA, Behbahani M, Amin-Hanjani S, Charbel FT. Carotid bypass for carotid occlusion. *Curr Atheroscler Rep*. 2015;17(7):36.
75. Brott TG, Halperin JL, Abbara S, et al. 2011 ASA/ACCF/AHA/AANN/AANS/ACR/ASNR/CNS/SAIP/SCAI/SIR/SNIS/SVM/SVS guideline on the management of patients with extracranial carotid and vertebral artery disease: executive

- summary. A report of the American College of Cardiology Foundation/American Heart Association Task Force on Practice Guidelines, and the American Stroke Association, American Association of Neuroscience Nurses, American Association of Neurological Surgeons, American College of Radiology, American Society of Neuroradiology, Congress of Neurological Surgeons, Society of Atherosclerosis Imaging and Prevention, Society for Cardiovascular Angiography and Interventions, Society of Interventional Radiology, Society of NeuroInterventional Surgery, Society for Vascular Medicine, and Society for Vascular Surgery. *Circulation*. 2011;124(4):489-532.
76. Connolly ES, Jr., Rabinstein AA, Carhuapoma JR, et al. Guidelines for the management of aneurysmal subarachnoid hemorrhage: a guideline for healthcare professionals from the American Heart Association/American Stroke Association. *Stroke*. 2012;43(6):1711-1737.
  77. Rahme RJ, Aoun SG, McClendon J, Jr., El Ahmadieh TY, Bendok BR. Spontaneous cervical and cerebral arterial dissections: diagnosis and management. *Neuroimaging Clin N Am*. 2013;23(4):661-671.
  78. Kernan WN, Ovbiagele B, Black HR, et al. Guidelines for the prevention of stroke in patients with stroke and transient ischemic attack: a guideline for healthcare professionals from the American Heart Association/American Stroke Association. *Stroke*. 2014;45(7):2160-2236.
  79. Hemphill JC, 3rd, Greenberg SM, Anderson CS, et al. Guidelines for the Management of Spontaneous Intracerebral Hemorrhage: A Guideline for Healthcare Professionals From the American Heart Association/American Stroke Association. *Stroke*. 2015;46(7):2032-2060.
  80. Etminan N, Brown RD, Jr., Beseoglu K, et al. The unruptured intracranial aneurysm treatment score: a multidisciplinary consensus. *Neurology*. 2015;85(10):881-889.
  81. Etminan N, Rinkel GJ. Unruptured intracranial aneurysms: development, rupture and preventive management. *Nat Rev Neurol*. 2016;12(12):699-713.
  82. Searchfield GD, Durai M, Linford T. A State-of-the-Art Review: Personalization of Tinnitus Sound Therapy. *Front Psychol*. 2017;8:1599.
  83. Powers WJ, Rabinstein AA, Ackerson T, et al. 2018 Guidelines for the Early Management of Patients With Acute Ischemic Stroke: A Guideline for Healthcare Professionals From the American Heart Association/American Stroke Association. *Stroke*. 2018;49(3):e46-e110.
  84. Whelton PK, Carey RM, Aronow WS, et al. 2017 ACC/AHA/AAPA/ABC/ACPM/AGS/APhA/ASH/ASPC/NMA/PCNA Guideline for the Prevention, Detection, Evaluation, and Management of High Blood Pressure in Adults: A Report of the American College of Cardiology/American Heart Association Task Force on Clinical Practice Guidelines. *J Am Coll Cardiol*. 2018;71(19):e127-e248.

**eTable 2 – Summary of the largest (≥15 patients) case studies of patients with cerebrovascular fibromuscular dysplasia**

Study, <sup>ref</sup>	N patients	Mean (range) age, yrs	Characteristics, %			Setting	Clinical presentation, % (non exclusive)							IC FMD, %		
			Women	Smoking	HTN		TIA	IS <sup>s</sup>	ICH	SAH	CeAD <sup>s</sup>	Other symptoms	Tinnitus or bruit*	Headaches *	UIA	String of beads
Houser, 1971 <sup>1</sup>	52	NR (12-78)	94	NR	NR	Radiology	8	12	2	17	NR	25	0	NR	6	0
Ehrenfield, 1974 <sup>2</sup>	20	52 (NR)	90	NR	NR	Surgery	35	35	0	9	NR	26	15	NR	NR	NR
Manelfe, 1974 <sup>3</sup>	70	54 (17-75)	74	NR	31	Radiology	13	41	NR	40	4	13	17	14	NR	83
Osborn, 1977 <sup>4</sup>	25	46 (4-71)	80	NR	NR	Radiology	40	24	0	32	NR	8	4	NR	30	20
Boudin, 1977 <sup>5</sup>	37	47 (NR)	85	NR	NR	Neurology Surgery	70		0	0	NR	14	16	NR	NR	NR
Effeney, 1980 <sup>6</sup>	76	58 (27-83)	97	NR	NR	Surgery	42	22	0	0	NR	6	23	NR	13	0
Corrin, 1981 <sup>7</sup>	79	58 (18-76)	94	NR	29	Neurology	8	9	0	13	NR	61	8	NR	NR	0
So, 1981 <sup>8</sup>	32	57 (34-78)	100	NR	NR	Neurology	28	28	0	16	NR	16	13	NR	22	9
Collins, 1981 <sup>9</sup>	18	60 (40-80)	100	NR	NR	Surgery	50		0	0	NR	44	39	NR	5.5	NR
Wells, 1982 <sup>10</sup>	17	58 (36-74)	94	NR	NR	Surgery	53	0	0	0	NR	35	29	38	NR	NR
Mettinger, 1982 <sup>11</sup>	37	48 (24-70)	81	NR	NR	Radiology	11	8	8	49	NR	24	38	78	49	2.7
Kelly, 1982 <sup>12</sup>	40	NR (38-78)	85	NR	NR	Surgery	30	10	0	0	NR	NR	30	43	NR	NR
Stewart, 1986 <sup>13</sup>	49	58 (29-82)	98	NR	NR	Surgery	35	27	6	NR	NR	42	6	4	8	NR
Wesen, 1986 <sup>14</sup>	30	59 (20-77)	77	47	40	Surgery	53	10	0	3	NR	26	NR	NR	NR	NR
Moreau, 1993 <sup>15</sup>	58	55 (20-76)	60	NR	25	Surgery	43		0	0	NR	53	NR	22	NR	NR
Liu, 2012 <sup>16</sup>	19	46 (32-64)	53	NR	NR	Radiology	5	95	0	0	74	0	NR	16	5	16
Pasquini, 2015 <sup>17</sup>	36	57	89	36	39	Neurology	17	47	0	5.6	25	0	5.6	NR	5.6	25
Hariott, 2017 <sup>18</sup>	81	53 (19-83)	96	49	68	Vascular Medicine	24	7	0	4	35	36	30/43	52	NR	NR

HTN : hypertension – TIA : transient ischaemic attack (including amaurosis fugax) – IS : ischaemic stroke – ICH : intracranial haemorrhage – SAH : subarachnoid haemorrhage – UIA : unruptured intracranial aneurysm – CeAD : cervical artery dissection – IC : intracranial fibromuscular dysplasia – NR : not reported – NC : not clear – \* symptoms reported at any time (where available) – <sup>s</sup> patients with IS and CeAD are included in both columns.

## References

1. Houser OW, Baker HL, Jr., Sandok BA, Holley KE. Cephalic arterial fibromuscular dysplasia. *Radiology*. 1971;101(3):605-611.
2. Ehrenfeld WK, Wylie EJ. Fibromuscular dysplasia of the internal carotid artery. *ArchSurg*. 1974;109(5):676-681.
3. Manelfe C, Clarisse J, Fredy D, André JM, Crouzet G. Dysplasies fibromusculaires des artères cervico-céphaliques. *J Neuroradiol*. 1974;1:149-231.
4. Osborn AG, Anderson RE. Angiographic spectrum of cervical and intracranial fibromuscular dysplasia. *Stroke*. 1977;8(5):617-626.
5. Boudin G, Guillard A, Romion A, et al. [Fibro-muscular dysplasia of the carotid and vertebral arteries. Considerations apropos of 37 cases]. *Rev Otoneuroophthalmol*. 1977;49(4):297-300.
6. Effeney DJ, Ehrenfeld WK, Stoney RJ, Wylie EJ. Why operate on carotid fibromuscular dysplasia? *ArchSurg*. 1980;115(11):1261-1265.
7. Corrin LS, Sandok BA, Houser OW. Cerebral ischemic events in patients with carotid artery fibromuscular dysplasia. *ArchNeurol*. 1981;38(10):616-618.
8. So EL, Toole JF, Dalal P, Moody DM. Cephalic fibromuscular dysplasia in 32 patients: clinical findings and radiologic features. *ArchNeurol*. 1981;38(10):619-622.
9. Collins GJ, Jr., Rich NM, Clagett GP, Spebar MJ, Salander JM. Fibromuscular dysplasia of the internal carotid arteries. Clinical experience and follow-up. *AnnSurg*. 1981;194(1):89-96.
10. Wells RP, Smith RR. Fibromuscular dysplasia of the internal carotid artery: a long term follow-up. *Neurosurgery*. 1982;10(1):39-43.
11. Mettinger KL, Ericson K. Fibromuscular dysplasia and the brain. I. Observations on angiographic, clinical and genetic characteristics. *Stroke*. 1982;13(1):46-52.
12. Kelly TF, Morris GC, Jr. Arterial fibromuscular disease. Observations on pathogenesis and surgical management. *Am J Surg*. 1982;143:232-236.
13. Stewart MT, Moritz MW, Smith RB, III, Fulenwider JT, Perdue GD. The natural history of carotid fibromuscular dysplasia. *J VascSurg*. 1986;3(2):305-310.
14. Wesen CA, Elliott BM. Fibromuscular dysplasia of the carotid arteries. *Am J Surg*. 1986;151(4):448-451.
15. Moreau P, Albat B, Thevenet A. Fibromuscular dysplasia of the internal carotid artery: long-term surgical results. *J CardiovascSurg(Torino)*. 1993;34(6):465-472.
16. Liu CH, Wu D, Chin SC, et al. Cervicocranial fibromuscular dysplasia in Taiwanese ischemic stroke patients. *Eur Neurol*. 2012;67(3):129-135.
17. Pasquini M, Trystram D, Nokam G, Gobin-Metteil MP, Oppenheim C, Touze E. Fibromuscular dysplasia of cervicocephalic arteries: Prevalence of multisite involvement and prognosis. *Rev Neurol (Paris)*. 2015;171(8-9):616-623.
18. Harriott AM, Zimmerman E, Singhal AB, Jaff MR, Lindsay ME, Rordorf GA. Cerebrovascular fibromuscular dysplasia: The MGH cohort and literature review. *Neurol Clin Pract*. 2017;7(3):225-236.

**eTable 3 – Genetic investigations and syndromic reports of fibromuscular dysplasia<sup>1</sup>**

Gene/ syndrome	Renal fibromuscular dysplasia	Cerebrovascular fibromuscular dysplasia
ACE	Insertion allele associated <sup>2</sup>	n/a
AT1R	No association <sup>2</sup>	n/a
AGT	No association <sup>2</sup>	n/a
Elastin	No association <sup>3</sup>	n/a
Alpha-1-antitrypsin	No association <sup>4</sup> Case report <sup>5</sup>	Case reports <sup>6-9</sup>
ACTA2	No association <sup>10</sup>	No association <sup>11</sup>
TGFβR1 and	Variants of unknown significance identified	No association <sup>11</sup>
TGFβR2	n/a	No association <sup>11</sup>
collagen 3A1	n/a	No association <sup>11</sup>
SMAD3	n/a	No association <sup>11</sup>
Fibrillin (Marfan syndrome)	n/a	No association <sup>11</sup> Case report <sup>12</sup>
Down Syndrome	Case report <sup>13</sup>	n/a
Turner Syndrome	n/a	Case report <sup>14</sup>
Neurofibromatosis I	Case report <sup>15</sup>	n/a

n/a - not available

ACE: angiotensin I Converting Enzyme

AT1R: angiotensin II type 1 receptor

AGT: Angiotensinogen

ACTA2: smooth muscle alpha (α)-2 actin

TGFβR: transforming growth factor, beta-receptor

SMAD3: mothers against decapentaplegic homolog 3

## References

1. Southerland AM, Meschia JF, Worrall BB. Shared associations of nonatherosclerotic, large-vessel, cerebrovascular arteriopathies: considering intracranial aneurysms, cervical artery dissection, moyamoya disease and fibromuscular dysplasia. *Curr Opin Neurol.* 2013;26(1):13-28.
2. Bofinger A, Hawley C, Fisher P, Daunt N, Stowasser M, Gordon R. Polymorphisms of the renin-angiotensin system in patients with multifocal renal arterial fibromuscular dysplasia. *J HumHypertens.* 2001;15(3):185-190.
3. Grimbirt P, Fiquier-Kempf B, Coudol P, et al. [Genetic study of renal artery fibromuscular dysplasia]. *ArchMal Coeur Vaiss.* 1998;91(8):1069-1071.
4. Perdu J, Gimenez-Roqueplo AP, Boutouyrie P, et al. Alpha1-antitrypsin gene polymorphisms are not associated with renal arterial fibromuscular dysplasia. *J Hypertens.* 2006;24(4):705-710.
5. Bofinger A, Hawley C, Fisher P, Daunt N, Stowasser M, Gordon R. Alpha-1-antitrypsin phenotypes in patients with renal arterial fibromuscular dysplasia. *J HumHypertens.* 2000;14(2):91-94.
6. Solder B, Streif W, Ellemunter H, Mayr U, Jaschke W. Fibromuscular dysplasia of the internal carotid artery in a child with alpha-1-antitrypsin deficiency. *DevMedChild Neurol.* 1997;39(12):827-829.
7. Schievink WI, Bjornsson J. Fibromuscular dysplasia of the internal carotid artery: a clinicopathological study. *Clin Neuropathol.* 1996;15(1):2-6.
8. Schievink WI, Meyer FB, Parisi JE, Wijdicks EF. Fibromuscular dysplasia of the internal carotid artery associated with alpha1-antitrypsin deficiency. *Neurosurgery.* 1998;43(2):229-233.
9. Schievink WI, Bjornsson J, Parisi JE, Prakash UB. Arterial fibromuscular dysplasia associated with severe alpha 1-antitrypsin deficiency. *Mayo Clin Proc.* 1994;69(11):1040-1043.
10. Marks SD, Gullett AM, Brennan E, et al. Renal FMD may not confer a familial hypertensive risk nor is it caused by ACTA2 mutations. *Pediatr Nephrol.* 2011;26(10):1857-1861.
11. Poloskey SL, Kim E, Sanghani R, et al. Low yield of genetic testing for known vascular connective tissue disorders in patients with fibromuscular dysplasia. *Vasc Med.* 2012;17(6):371-378.

12. Schievink WI, Bjornsson J, Piepgras DG. Coexistence of fibromuscular dysplasia and cystic medial necrosis in a patient with Marfan's syndrome and bilateral carotid artery dissections. *Stroke*. 1994;25(12):2492-2496.
13. Fleisher GR, Buck BE, Cornfeld D. Primary intimal fibroplasia in a child with Down's syndrome. *Am J Dis Child*. 1978;132(7):700-703.
14. Lancman M, Mesropian H, Serra P, Granillo R. Turner's syndrome, fibromuscular dysplasia, and stroke. *Stroke*. 1991;22(2):269-271.
15. Kousseff BG, Gilbert-Barness EF. "Vascular neurofibromatosis" and infantile gangrene. *Am J Med Genet*. 1989;34(2):221-226.



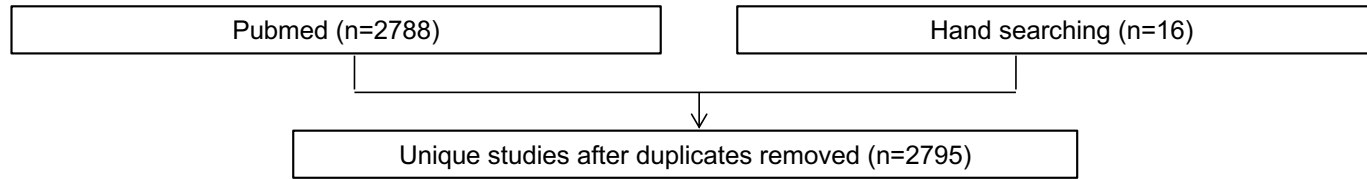
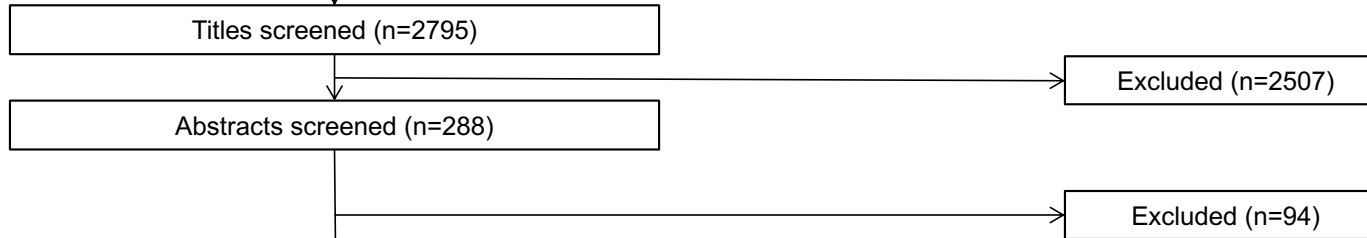

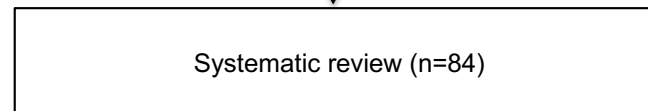
**eTable 4 – Prognosis of patients with cerebrovascular fibromuscular dysplasia (FMD)**

Study, <sup>ref</sup>	N patients	Clinical presentation (%)				Follow-up (years)	Cerebrovascular events during follow-up, n (%/year)				
		TIA/ischemic stroke	ICH	SAH	CeAD		TIA/ischemic stroke	ICH	SAH	CeAD	FMD progression
Corrin, 1981 <sup>1</sup>	79	15	0	13	NR	5	3 (0.76)	NR	NR	NR	NR
Wells, 1982 <sup>2</sup>	16	53	0	0	NR	3.8	2 (3.29)	NR	NR	NR	0
Wesen, 1986 <sup>3</sup>	30	63	NR	3	NR	1.8	2 (3.70)	NR	NR	NR	NR
Stewart, 1986 <sup>4</sup>	35	61	6	6	NR	6.5	0	0	NR	0	NR
Liu, 2012 <sup>5</sup>	19	100	0	0	74	2.2	0	0	NR	NR	NR
Pasquini, 2015 <sup>6</sup>	36	64	0	6	25	3.5	4 (3.18)	1 (0.79)	NR	1 (0.79)	1 (0.79) (stenosis)
Harriott, 2017 <sup>7</sup>	67	23	0	4	35	2.4	1 (0.62)	0	NR	0	1 (0.62) (new intracranial aneurysm)

TIA: transient ischemic attack – ICH: Intracranial hemorrhage – SAH: subarachnoid hemorrhage – CeAD: Cervical Artery dissection – NR: not reported

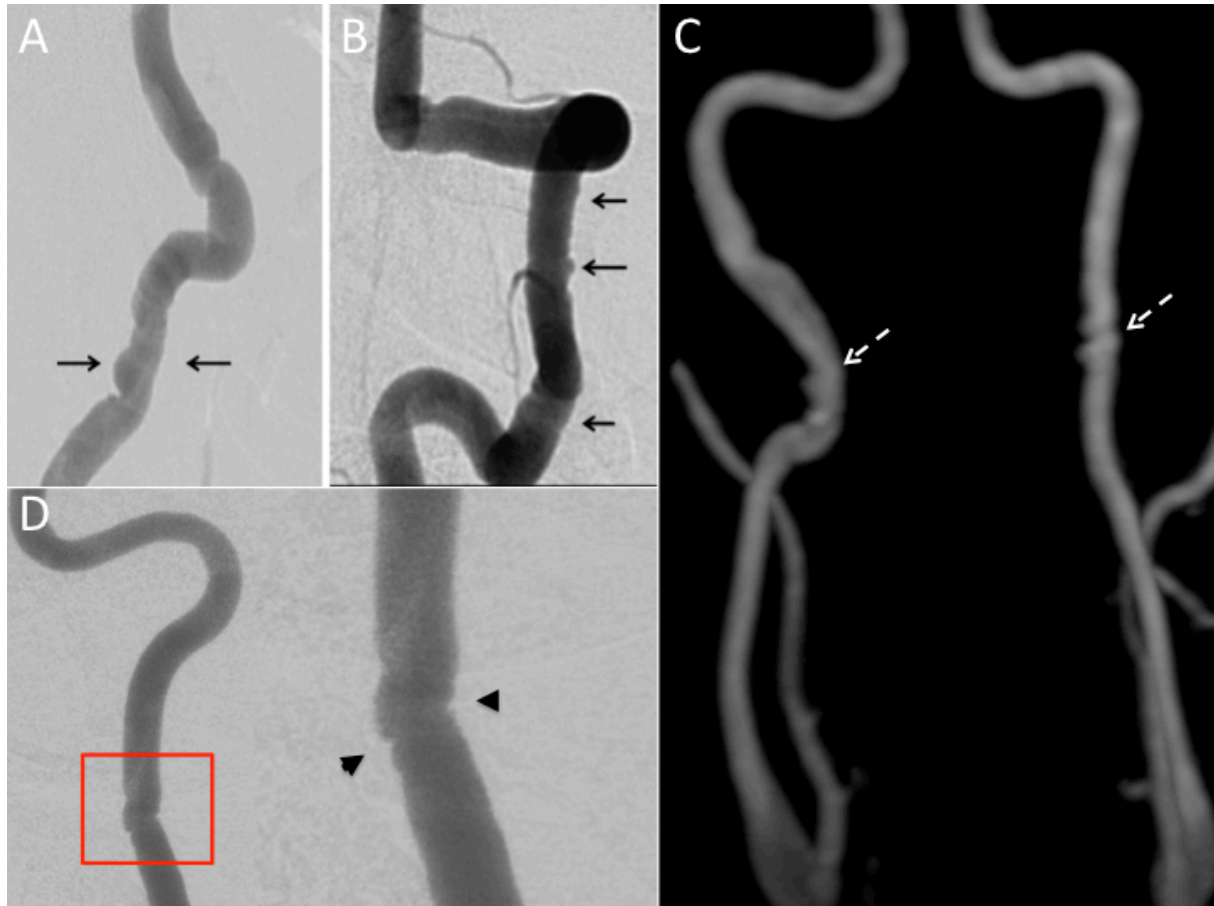### References

1. Corrin LS, Sandok BA, Houser OW. Cerebral ischemic events in patients with carotid artery fibromuscular dysplasia. *ArchNeurol*. 1981;38(10):616-618.
2. Wells RP, Smith RR. Fibromuscular dysplasia of the internal carotid artery: a long term follow-up. *Neurosurgery*. 1982;10(1):39-43.
3. Wesen CA, Elliott BM. Fibromuscular dysplasia of the carotid arteries. *Am J Surg*. 1986;151(4):448-451.
4. Stewart MT, Moritz MW, Smith RB, III, Fulenwider JT, Perdue GD. The natural history of carotid fibromuscular dysplasia. *J VascSurg*. 1986;3(2):305-310.
5. Liu CH, Wu D, Chin SC, et al. Cervicocranial fibromuscular dysplasia in Taiwanese ischemic stroke patients. *Eur Neurol*. 2012;67(3):129-135.
6. Pasquini M, Trystram D, Nokam G, Gobin-Metteil MP, Oppenheim C, Touze E. Fibromuscular dysplasia of cervicocephalic arteries: Prevalence of multisite involvement and prognosis. *Rev Neurol (Paris)*. 2015;171(8-9):616-623.
7. Harriott AM, Zimmerman E, Singhal AB, Jaff MR, Lindsay ME, Rordorf GA. Cerebrovascular fibromuscular dysplasia: The MGH cohort and literature review. *Neurol Clin Pract*. 2017;7(3):225-236

**eFigure 1 – PRISMA flow diagram describing identification, screening, eligibility, and inclusion of studies in the systematic review****IDENTIFICATION****SCREENING****ELIGIBILITY****INCLUSION**

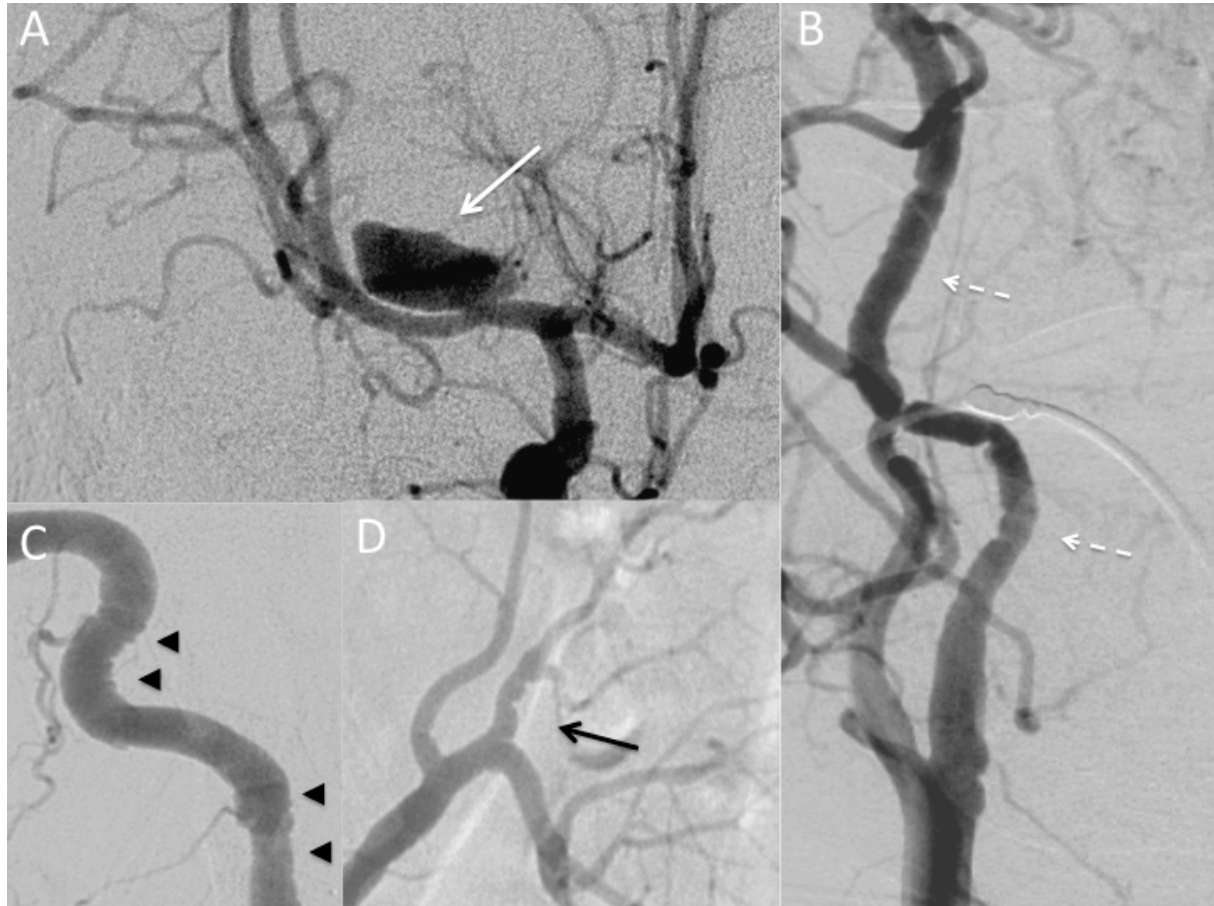**eFigure 2 – Mild cervical and focal form of fibromuscular dysplasia (FMD)**

- A. Lateral conventional angiography of a right internal carotid artery (black arrow).  
B. Conventional angiography of a left vertebral artery (black arrow).  
C. 3D T1 contrast enhanced MRI in maximum intensity projection reconstruction in coronal view of a bilateral focal form of cervical FMD (white dotted arrow).  
D. Conventional angiography of a left cervical internal carotid artery in a patient with a unifocal FMD lesion (black arrow head).



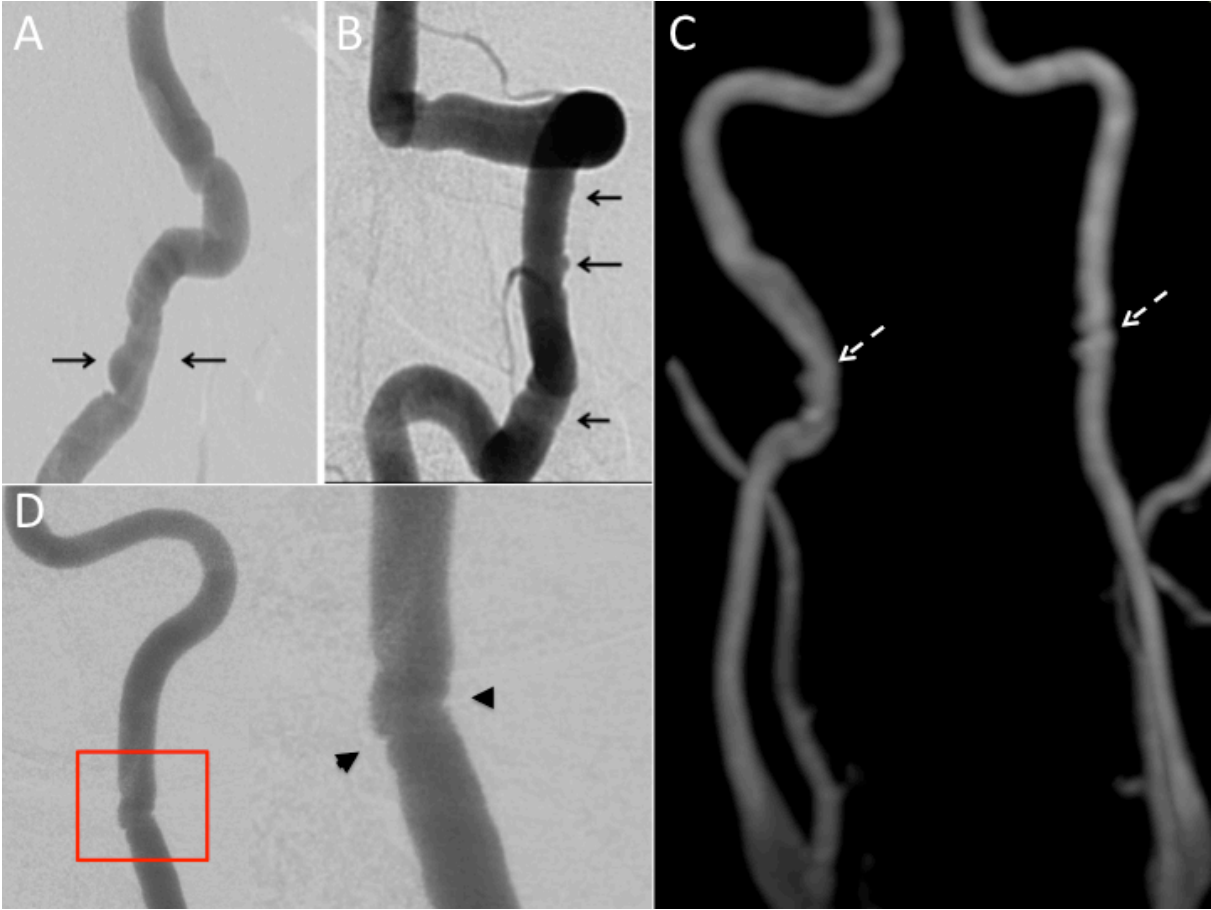
### eFigure 3 – Illustrative clinical case of diffuse fibromuscular dysplasia (FMD) in a young woman

46-year old woman, with acute headache and confusion admitted with a CT scan showing a severe subarachnoid bleeding (Fisher IV) due to the rupture of a large dissecting aneurysm of the proximal segment of the right middle cerebral artery (A, white arrow). The patient presented a diffuse FMD which on internal carotid (B, white dotted arrow) and vertebral (C, black arrow head) arteries. Renal artery angiography also showed FMD on the left (D, black arrow). The patient was successfully treated by a combination of endovascular and neurosurgical intervention.



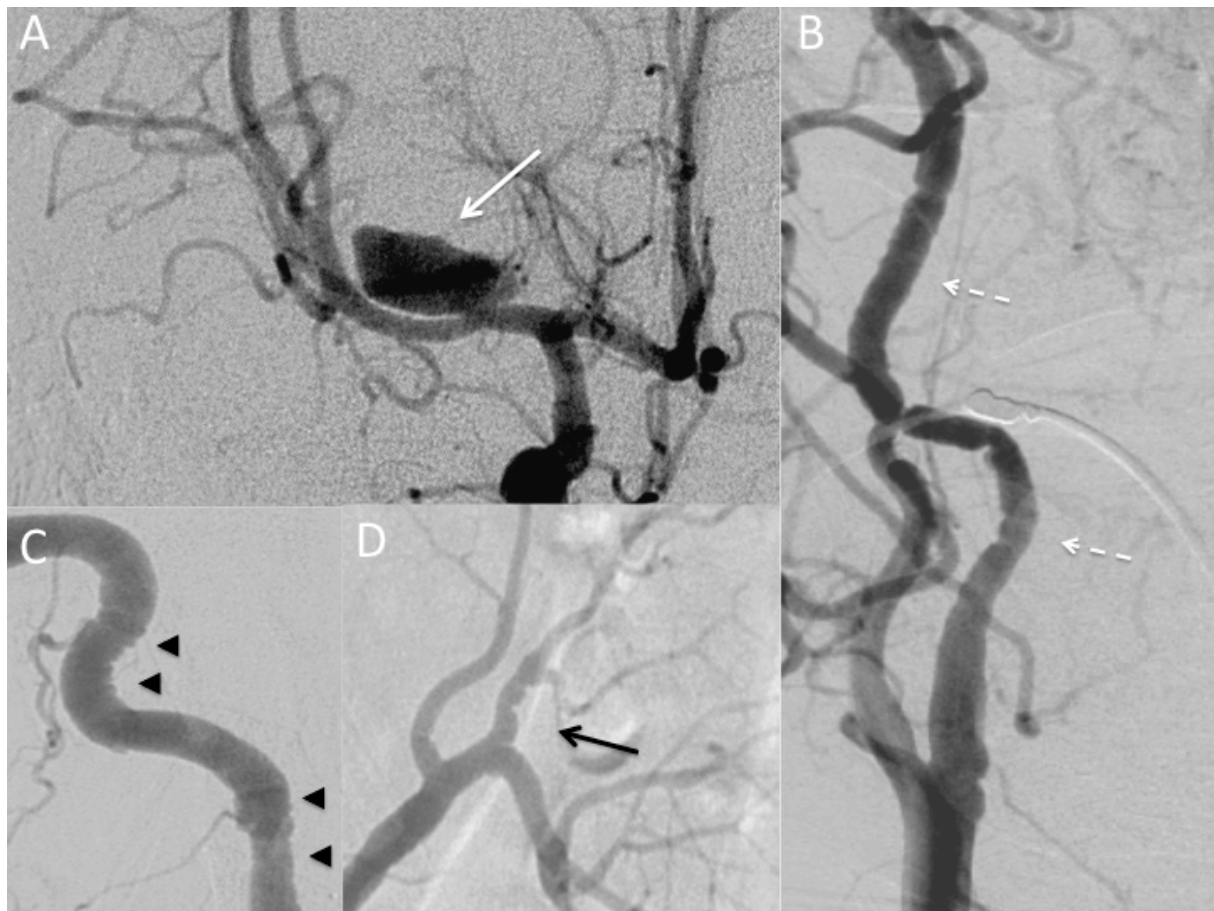
**Supplemental Figure 1 - Mild cervical and focal form of FMD**

A. Lateral conventional angiography of a right internal carotid artery (black arrow). B. Conventional angiography of a left vertebral artery (black arrow). C. 3D T1 contrast enhanced MRI in maximum intensity projection reconstruction in coronal view of a bilateral focal form of cervical FMD (white dotted arrow). D. Conventional angiography of a left cervical internal carotid artery in a patient with a unifocal FMD lesion (black arrow head).



**Supplemental Figure 2 - Illustrative clinical case of diffuse FMD in a young woman.**

46-year old woman, with acute headache and confusion admitted with a CT scan showing a severe subarachnoid bleeding (Fisher IV) due to the rupture of a large dissecting aneurysm of the proximal segment of the right middle cerebral artery (A, white arrow). The patient presented a diffuse FMD which on internal carotid (B, white dotted arrow) and vertebral (C, black arrow head) arteries. Renal artery angiography also showed FMD on the left (D, black arrow). The patient was successfully treated by a combination of endovascular and neurosurgical intervention.



**Supplemental Table 1 – Evidence level of studies evaluating epidemiology, genetic risk, presenting manifestations, cerebrovascular clinical manifestations, management and prognosis in neurological manifestations of fibromuscular dysplasia: summary of systematic review according to the Oxford Centre for Evidence-based Medicine.**

**Quality Rating Scheme for Studies and Other Evidence according to the Oxford Centre for Evidence-based Medicine.**

1. Properly powered and conducted randomized clinical trial; systematic review with meta-analysis
2. Well-designed controlled trial without randomization; prospective comparative cohort trial
3. Case-control studies; retrospective cohort study
4. Case series with or without intervention; cross-sectional study
5. Opinion of respected authorities; case reports

<b>Manuscript sections</b>	<b>Number of studies included by evidence level</b>
Classification and diagnostic criteria	- 1 Level 4 study (Southerland, 2013) <sup>1</sup> - 2 guidelines/statements (Persu, 2014; Olin, 2014) <sup>2,3</sup>
Imaging	- 3 level 4 studies (Touzé, 2010; Varennes, 2015; Zhou, 2005) <sup>4-6</sup> - 1 level 5 study (Arning, 2004) <sup>7</sup> - 1 guideline/statement (Persu, 2014) <sup>3</sup>
Epidemiology	- 7 Level 3 studies (Schievink, 1996; Olin, 2012; Saw, 2013; Saw, 2014; O'Connor, 2016; Plouin, 2017) <sup>8-13</sup> - 2 level 4 studies (Pasquini, 2015; Southerland, 2013) <sup>1,14</sup> - 2 Level 5 studies (Touzé, 2010; Camuglia, 2008) <sup>6,15</sup> - 1 guideline/statement <sup>2</sup>
Genetic risk	- 5 Level 3 studies (Bofinger, 2000; Bofinger, 2001; Poloskey, 2012; Kiando, 2015; Kiando, 2016) <sup>16-20</sup> - 5 level 4 studies (Schievink, 1996; Grimbirt, 1998; Marks, 2011; Southerland, 2013; Gupta, 2017) <sup>1,21-24</sup> - 7 Level 5 study (Fleischer, 1978; Kousseff, 1989; Lancman, 1991; Schievink, 1994; Schievink, 1994; Solder, 1997; Ganesh, 2014) <sup>25-30</sup>
Presenting and cerebrovascular clinical manifestations	- 33 Level 3 studies (Houser, 1971; Ehrenfield, 1974; Manelfe, 1974; Osborn, 1977; Boudin, 1977; Effeney, 1980; Corrin, 1981; So, 1981; Collins, 1981; Wells, 1982; Mettinger, 1982; Kelly, 1982; Stewart, 1986; Wesen, 1986; Moreau, 1993; Cloft, 1998; Liu, 2012; Olin, 2012; Kirton, 2013; Debette, 2014; Béjot 2014; Joux, 2014; O'Connor, 2015; Pasquini, 2015; Choi, 2015; Kadian-Dodov, 2016; Joux, 2016; Green 2016; Hariott, 2017; Plouin, 2017; Haussen, 2017; Lather, 2017; de Groote, 2017) <sup>8,9,14,31-60</sup> - 8 Level 4 studies (Belen, 1996; Faggioli, 1996; Nakamura, 2000; Kubis, 1999; Southerland, 2013; Lenck, 2014; Touzé, 2010; Ukkola-Pons, 2012) <sup>1,6,36,61-66</sup> - 2 Level 5 studies (Choi, 2014; van de Nes, 2017) <sup>67,68</sup>
Management	- 3 level 3 studies (O'Connor, 2015; Debette, 2014; Larsson, 2017) <sup>50,69,70</sup> - 2 level 4 studies (Touzé, 2001; Schirmer, 2011) <sup>71,72</sup> - 3 Level 5 studies (Debette, 2009; Debette, 2015; Hage, 2015) <sup>69,73,74</sup> - 13 guidelines/statements (Brott, 2011; Connolly, 2012; Rahme, 2013; Biller, 2014; Kernan, 2014; Olin, 2014; Persu, 2014; Etmnan, 2015;

	Hemphill, 2015; Etminan, 2016; Searchfield, 2017; Powers, 2018; Whelton, 2018) <sup>2,3,48,75-84</sup>
Prognosis	- 1 Level 3 study (Olin, 2012) <sup>9</sup> - 7 level 4 studies (Corrin, 1981; Wells, 1982; Wesen, 1986; Stewart, 1986; Liu, 2012; Pasquini, 2015; Hariott, 2017) <sup>14,33,36,39,45-47</sup>

## References

1. Southerland AM, Meschia JF, Worrall BB. Shared associations of nonatherosclerotic, large-vessel, cerebrovascular arteriopathies: considering intracranial aneurysms, cervical artery dissection, moyamoya disease and fibromuscular dysplasia. *Curr Opin Neurol*. 2013;26(1):13-28.
2. Olin JW, Gornik HL, Bacharach JM, et al. Fibromuscular dysplasia: state of the science and critical unanswered questions: a scientific statement from the American Heart Association. *Circulation*. 2014;129(9):1048-1078.
3. Persu A, Giavarini A, Touze E, et al. European consensus on the diagnosis and management of fibromuscular dysplasia. *J Hypertens*. 2014;32(7):1367-1378.
4. Varennes L, Tahon F, Kastler A, et al. Fibromuscular dysplasia: what the radiologist should know: a pictorial review. *Insights Imaging*. 2015;6(3):295-307.
5. Zhou W, Bush RL, Lin PL, Lumsden AB. Fibromuscular dysplasia of the carotid artery. *J Am Coll Surg*. 2005;200(5):807.
6. Touzé E, Oppenheim C, Trystram D, et al. Fibromuscular dysplasia of cervical and intracranial arteries. *Int J Stroke*. 2010;5(4):296-305.
7. Arning C, Grzyska U. Color Doppler imaging of cervicocephalic fibromuscular dysplasia. *Cardiovasc Ultrasound*. 2004;2:7.
8. O'Connor S, Gornik HL, Froehlich JB, et al. Smoking and Adverse Outcomes in Fibromuscular Dysplasia: U.S. Registry Report. *J Am Coll Cardiol*. 2016;67(14):1750-1751.
9. Olin JW, Froehlich J, Gu X, et al. The United States registry for fibromuscular dysplasia: results in the first 447 patients. *Circulation*. 2012;125(25):3182-3190.
10. Saw J, Aymong E, Sedlak T, et al. Spontaneous coronary artery dissection: association with predisposing arteriopathies and precipitating stressors and cardiovascular outcomes. *Circ Cardiovasc Interv*. 2014;7(5):645-655.
11. Saw J, Ricci D, Starovoytov A, Fox R, Buller CE. Spontaneous coronary artery dissection: prevalence of predisposing conditions including fibromuscular dysplasia in a tertiary center cohort. *JACC Cardiovasc Interv*. 2013;6(1):44-52.
12. Schievink WI, Bjornsson J. Fibromuscular dysplasia of the internal carotid artery: a clinicopathological study. *Clin Neuropathol*. 1996;15(1):2-6.
13. Sang CN, Whelton PK, Hamper UM, et al. Etiologic factors in renovascular fibromuscular dysplasia. A case-control study. *Hypertension*. 1989;14(5):472-479.
14. Pasquini M, Trystram D, Nokam G, Gobin-Metteil MP, Oppenheim C, Touze E. Fibromuscular dysplasia of cervicocephalic arteries: Prevalence of multisite involvement and prognosis. *Rev Neurol (Paris)*. 2015;171(8-9):616-623.
15. Camuglia A, Manins V, Taylor A, Hengel C. Case Report and Review: Epicardial Coronary Artery Fibromuscular Dysplasia. *Heart Lung Circ*. 2008.



16. Bofinger A, Hawley C, Fisher P, Daunt N, Stowasser M, Gordon R. Alpha-1-antitrypsin phenotypes in patients with renal arterial fibromuscular dysplasia. *J Hum Hypertens*. 2000;14(2):91-94.
17. Bofinger A, Hawley C, Fisher P, Daunt N, Stowasser M, Gordon R. Polymorphisms of the renin-angiotensin system in patients with multifocal renal arterial fibromuscular dysplasia. *J Hum Hypertens*. 2001;15(3):185-190.
18. Poloskey SL, Kim E, Sanghani R, et al. Low yield of genetic testing for known vascular connective tissue disorders in patients with fibromuscular dysplasia. *Vasc Med*. 2012;17(6):371-378.
19. Kiando SR, Barlassina C, Cusi D, et al. Exome sequencing in seven families and gene-based association studies indicate genetic heterogeneity and suggest possible candidates for fibromuscular dysplasia. *J Hypertens*. 2015;33(9):1802-1810; discussion 1810.
20. Kiando SR, Tucker NR, Castro-Vega LJ, et al. PHACTR1 Is a Genetic Susceptibility Locus for Fibromuscular Dysplasia Supporting Its Complex Genetic Pattern of Inheritance. *PLoS Genet*. 2016;12(10):e1006367.
21. Schievink WI, Puumala MR, Meyer FB, Raffel C, Katzmann JA, Parisi JE. Giant intracranial aneurysm and fibromuscular dysplasia in an adolescent with alpha 1-antitrypsin deficiency. *J Neurosurg*. 1996;85(3):503-506.
22. Grimbert P, Fiquer-Kempf B, Coudol P, et al. [Genetic study of renal artery fibromuscular dysplasia]. *Arch Mal Coeur Vaiss*. 1998;91(8):1069-1071.
23. Marks SD, Gullett AM, Brennan E, et al. Renal FMD may not confer a familial hypertensive risk nor is it caused by ACTA2 mutations. *Pediatr Nephrol*. 2011;26(10):1857-1861.
24. Gupta RM, Hadaya J, Trehan A, et al. A Genetic Variant Associated with Five Vascular Diseases Is a Distal Regulator of Endothelin-1 Gene Expression. *Cell*. 2017;170(3):522-533 e515.
25. Fleisher GR, Buck BE, Cornfeld D. Primary intimal fibroplasia in a child with Down's syndrome. *Am J Dis Child*. 1978;132(7):700-703.
26. Lancman M, Mesropian H, Serra P, Granillo R. Turner's syndrome, fibromuscular dysplasia, and stroke. *Stroke*. 1991;22(2):269-271.
27. Schievink WI, Bjornsson J, Parisi JE, Prakash UB. Arterial fibromuscular dysplasia associated with severe alpha 1-antitrypsin deficiency. *Mayo Clin Proc*. 1994;69(11):1040-1043.
28. Schievink WI, Bjornsson J, Piepgras DG. Coexistence of fibromuscular dysplasia and cystic medial necrosis in a patient with Marfan's syndrome and bilateral carotid artery dissections. *Stroke*. 1994;25(12):2492-2496.
29. Solder B, Streif W, Ellemunter H, Mayr U, Jaschke W. Fibromuscular dysplasia of the internal carotid artery in a child with alpha-1-antitrypsin deficiency. *Dev Med Child Neurol*. 1997;39(12):827-829.
30. Ganesh SK, Morissette R, Xu Z, et al. Clinical and biochemical profiles suggest fibromuscular dysplasia is a systemic disease with altered TGF-beta expression and connective tissue features. *FASEB J*. 2014;28(8):3313-3324.
31. Boudin G, Guillard A, Romion A, et al. [Fibro-muscular dysplasia of the carotid and vertebral arteries. Considerations apropos of 37 cases]. *Rev Otoneuroophthalmol*. 1977;49(4):297-300.
32. Collins GJ, Jr., Rich NM, Clagett GP, Spebar MJ, Salander JM. Fibromuscular dysplasia of the internal carotid arteries. Clinical experience and follow-up. *Ann Surg*. 1981;194(1):89-96.
33. Corrin LS, Sandok BA, Houser OW. Cerebral ischemic events in patients with carotid artery fibromuscular dysplasia. *Arch Neurol*. 1981;38(10):616-618.
34. Effeney DJ, Ehrenfeld WK, Stoney RJ, Wylie EJ. Why operate on carotid fibromuscular dysplasia? *Arch Surg*. 1980;115(11):1261-1265.
35. Ehrenfeld WK, Wylie EJ. Fibromuscular dysplasia of the internal carotid artery. *Arch Surg*. 1974;109(5):676-681.

36. Harriott AM, Zimmerman E, Singhal AB, Jaff MR, Lindsay ME, Rordorf GA. Cerebrovascular fibromuscular dysplasia: The MGH cohort and literature review. *Neurol Clin Pract*. 2017;7(3):225-236.
37. Houser OW, Baker HL, Jr., Sandok BA, Holley KE. Cephalic arterial fibromuscular dysplasia. *Radiology*. 1971;101(3):605-611.
38. Kelly TF, Morris GC, Jr. Arterial fibromuscular disease. Observations on pathogenesis and surgical management. *Am J Surg*. 1982;143:232-236.
39. Liu CH, Wu D, Chin SC, et al. Cervicocranial fibromuscular dysplasia in Taiwanese ischemic stroke patients. *Eur Neurol*. 2012;67(3):129-135.
40. Manelfe C, Clarisse J, Fredy D, André JM, Crouzet G. Dysplasies fibromusculaires des artères cervico-céphaliques. *J Neuroradiol*. 1974;1:149-231.
41. Mettinger KL, Ericson K. Fibromuscular dysplasia and the brain. I. Observations on angiographic, clinical and genetic characteristics. *Stroke*. 1982;13(1):46-52.
42. Moreau P, Albat B, Thevenet A. Fibromuscular dysplasia of the internal carotid artery: long-term surgical results. *J CardiovascSurg(Torino)*. 1993;34(6):465-472.
43. Osborn AG, Anderson RE. Angiographic spectrum of cervical and intracranial fibromuscular dysplasia. *Stroke*. 1977;8(5):617-626.
44. So EL, Toole JF, Dalal P, Moody DM. Cephalic fibromuscular dysplasia in 32 patients: clinical findings and radiologic features. *ArchNeurol*. 1981;38(10):619-622.
45. Stewart MT, Moritz MW, Smith RB, III, Fulenwider JT, Perdue GD. The natural history of carotid fibromuscular dysplasia. *J VascSurg*. 1986;3(2):305-310.
46. Wells RP, Smith RR. Fibromuscular dysplasia of the internal carotid artery: a long term follow-up. *Neurosurgery*. 1982;10(1):39-43.
47. Wesen CA, Elliott BM. Fibromuscular dysplasia of the carotid arteries. *Am J Surg*. 1986;151(4):448-451.
48. Biller J, Sacco RL, Albuquerque FC, et al. Cervical arterial dissections and association with cervical manipulative therapy: a statement for healthcare professionals from the american heart association/american stroke association. *Stroke*. 2014;45(10):3155-3174.
49. Debette S. Pathophysiology and risk factors of cervical artery dissection: what have we learnt from large hospital-based cohorts? *Curr Opin Neurol*. 2014;27(1):20-28.
50. O'Connor SC, Poria N, Gornik HL. Fibromuscular dysplasia: an update for the headache clinician. *Headache*. 2015;55(5):748-755.
51. Plouin PF, Baguet JP, Thony F, et al. High Prevalence of Multiple Arterial Bed Lesions in Patients With Fibromuscular Dysplasia: The ARCADIA Registry (Assessment of Renal and Cervical Artery Dysplasia). *Hypertension*. 2017;70:652-658.
52. Choi PM, Singh D, Trivedi A, et al. Carotid Webs and Recurrent Ischemic Strokes in the Era of CT Angiography. *AJNR Am J Neuroradiol*. 2015;36(11):2134-2139.
53. Cloft HJ, Kallmes DF, Kallmes MH, Goldstein JH, Jensen ME, Dion JE. Prevalence of cerebral aneurysms in patients with fibromuscular dysplasia: a reassessment. *J Neurosurg*. 1998;88(3):436-440.
54. Joux J, Boulanger M, Jeannin S, et al. Association Between Carotid Bulb Diaphragm and Ischemic Stroke in Young Afro-Caribbean Patients: A Population-Based Case-Control Study. *Stroke*. 2016;47:2641-2644.
55. Joux J, Chausson N, Jeannin S, et al. Carotid-bulb atypical fibromuscular dysplasia in young Afro-Caribbean patients with stroke. *Stroke*. 2014;45(12):3711-3713.
56. Green R, Gu X, Kline-Rogers E, et al. Differences between the pediatric and adult presentation of fibromuscular dysplasia: results from the US Registry. *Pediatr Nephrol*. 2016;31(4):641-650.
57. Kadian-Dodov D, Gornik HL, Gu X, et al. Dissection and Aneurysm in Patients With Fibromuscular Dysplasia: Findings From the U.S. Registry for FMD. *J Am Coll Cardiol*. 2016;68(2):176-185.

58. Kirton A, Crone M, Benseler S, et al. Fibromuscular dysplasia and childhood stroke. *Brain*. 2013;136(Pt 6):1846-1856.
59. Lather HD, Gornik HL, Olin JW, et al. Prevalence of Intracranial Aneurysm in Women With Fibromuscular Dysplasia: A Report From the US Registry for Fibromuscular Dysplasia. *JAMA Neurol*. 2017;74(9):1081-1087.
60. Haussen DC, Grossberg JA, Bousslama M, et al. Carotid Web (Intimal Fibromuscular Dysplasia) Has High Stroke Recurrence Risk and Is Amenable to Stenting. *Stroke*. 2017;48(11):3134-3137.
61. Belen D, Bolay H, Firat M, Akpınar G, Bertan V. Unusual appearance of intracranial fibromuscular dysplasia. A case report. *Angiology*. 1996;47(6):627-632.
62. Kubis N, Von LD, Petitjean C, et al. Thrombotic carotid megabulb: fibromuscular dysplasia, septae, and ischemic stroke. *Neurology*. 1999;52(4):883-886.
63. Lenck S, Labeyrie MA, Saint-Maurice JP, Tarlov N, Houdart E. Diaphragms of the carotid and vertebral arteries: an under-diagnosed cause of ischaemic stroke. *Eur J Neurol*. 2014;21(4):586-593.
64. Nakamura M, Rosahl SK, Vorkapic P, Forster C, Samii M. De novo formation of an aneurysm in a case of unusual intracranial fibromuscular dysplasia. *Clin NeurolNeurosurg*. 2000;102(4):259-264.
65. Ukkola-Pons E, Sadik JC, Champtiaux N, et al. [Free floating thrombus on carotid megabulb or suspended bulb: what kind of dysplasia?]. *Rev Neurol (Paris)*. 2012;168(1):53-56.
66. De Groot M, Van der Niepen P, Hemelsoet D, et al. Fibromuscular dysplasia - results of a multicentre study in Flanders. *Vasa*. 2017;46(3):211-218.
67. Choi PM, Menon BK, Demchuk AM. Carotid web and stroke. *Eur J Neurol*. 2014;21(6):e53.
68. van de Nes JA, Bajanowski T, Trubner K. Fibromuscular dysplasia of the basilar artery: an unusual case with medico-legal implications. *Forensic Sci Int*. 2007;173(2-3):188-192.
69. Debette S, Compter A, Labeyrie MA, et al. Epidemiology, pathophysiology, diagnosis, and management of intracranial artery dissection. *Lancet Neurol*. 2015;14(6):640-654.
70. Larsson SC, King A, Madigan J, Levi C, Norris JW, Markus HS. Prognosis of carotid dissecting aneurysms: Results from CADISS and a systematic review. *Neurology*. 2017;88(7):646-652.
71. Schirmer CM, Atalay B, Malek AM. Endovascular recanalization of symptomatic flow-limiting cervical carotid dissection in an isolated hemisphere. *Neurosurg Focus*. 2011;30(6):E16.
72. Touze E, Randoux B, Meary E, Arquizan C, Meder JF, Mas JL. Aneurysmal forms of cervical artery dissection : associated factors and outcome. *Stroke*. 2001;32(2):418-423.
73. Debette S, Leys D. Cervical-artery dissections: predisposing factors, diagnosis, and outcome. *Lancet neurology*. 2009;8(7):668-678.
74. Hage ZA, Behbahani M, Amin-Hanjani S, Charbel FT. Carotid bypass for carotid occlusion. *Curr Atheroscler Rep*. 2015;17(7):36.
75. Brott TG, Halperin JL, Abbara S, et al. 2011 ASA/ACCF/AHA/AANN/AANS/ACR/ASNR/CNS/SAIP/SCAI/SIR/SNIS/SVM/SVS guideline on the management of patients with extracranial carotid and vertebral artery disease: executive summary. A report of the American College of Cardiology Foundation/American Heart Association Task Force on Practice Guidelines, and the American Stroke Association, American Association of Neuroscience Nurses, American Association of Neurological Surgeons, American College of Radiology, American Society of Neuroradiology, Congress of Neurological Surgeons, Society of Atherosclerosis Imaging and Prevention, Society for Cardiovascular Angiography and Interventions, Society of Interventional Radiology, Society of NeuroInterventional Surgery, Society for Vascular Medicine, and Society for Vascular Surgery. *Circulation*. 2011;124(4):489-532.
76. Connolly ES, Jr., Rabinstein AA, Carhuapoma JR, et al. Guidelines for the management of aneurysmal subarachnoid hemorrhage: a guideline for healthcare professionals from the American Heart Association/American Stroke Association. *Stroke*. 2012;43(6):1711-1737.

77. Rahme RJ, Aoun SG, McClendon J, Jr., El Ahmadih TY, Bendok BR. Spontaneous cervical and cerebral arterial dissections: diagnosis and management. *Neuroimaging Clin N Am*. 2013;23(4):661-671.
78. Kernan WN, Ovbiagele B, Black HR, et al. Guidelines for the prevention of stroke in patients with stroke and transient ischemic attack: a guideline for healthcare professionals from the American Heart Association/American Stroke Association. *Stroke*. 2014;45(7):2160-2236.
79. Hemphill JC, 3rd, Greenberg SM, Anderson CS, et al. Guidelines for the Management of Spontaneous Intracerebral Hemorrhage: A Guideline for Healthcare Professionals From the American Heart Association/American Stroke Association. *Stroke*. 2015;46(7):2032-2060.
80. Etminan N, Brown RD, Jr., Beseoglu K, et al. The unruptured intracranial aneurysm treatment score: a multidisciplinary consensus. *Neurology*. 2015;85(10):881-889.
81. Etminan N, Rinkel GJ. Unruptured intracranial aneurysms: development, rupture and preventive management. *Nat Rev Neurol*. 2016;12(12):699-713.
82. Searchfield GD, Durai M, Linford T. A State-of-the-Art Review: Personalization of Tinnitus Sound Therapy. *Front Psychol*. 2017;8:1599.
83. Powers WJ, Rabinstein AA, Ackerson T, et al. 2018 Guidelines for the Early Management of Patients With Acute Ischemic Stroke: A Guideline for Healthcare Professionals From the American Heart Association/American Stroke Association. *Stroke*. 2018;49(3):e46-e110.
84. Whelton PK, Carey RM, Aronow WS, et al. 2017 ACC/AHA/AAPA/ABC/ACPM/AGS/APhA/ASH/ASPC/NMA/PCNA Guideline for the Prevention, Detection, Evaluation, and Management of High Blood Pressure in Adults: A Report of the American College of Cardiology/American Heart Association Task Force on Clinical Practice Guidelines. *J Am Coll Cardiol*. 2018;71(19):e127-e248.

**Supplemental table 2- Summary of the largest ( $\geq 15$  patients) case studies of cervico-cephalic fibromuscular dysplasia (FMD)**

Study, <sup>ref</sup>	N patients	Mean (range) age, yrs	Characteristics, %			Setting	Clinical presentation, % (non exclusive)							IC FMD, %		
			Females	Smoking	HTN		TIA	IS <sup>s</sup>	ICH	SAH	CeAD <sub>s</sub>	Miscellaneous symptoms	Tinnitus or bruit*	Headaches*	UIA	String of beads
Houser, 1971 <sup>1</sup>	52	NR (12-78)	94	NR	NR	Radiology	8	12	2	17	NR	25	0	NR	6	0
Ehrenfield, 1974 <sup>2</sup>	20	52 (NR)	90	NR	NR	Surgery	35	35	0	9	NR	26	15	NR	NR	NR
Manelfe, 1974 <sup>3</sup>	70	54 (17-75)	74	NR	31	Radiology	13	41	NR	40	4	13	17	14	NR	83
Osborn, 1977 <sup>4</sup>	25	46 (4-71)	80	NR	NR	Radiology	40	24	0	32	NR	8	4	NR	30	20
Boudin, 1977 <sup>5</sup>	37	47 (NR)	85	NR	NR	Neurology Surgery	70	0	0	0	NR	14	16	NR	NR	NR
Effenev, 1980 <sup>6</sup>	76	58 (27-83)	97	NR	NR	Surgery	42	22	0	0	NR	6	23	NR	13	0
Corrin, 1981 <sup>7</sup>	79	58 (18-76)	94	NR	29	Neurology	8	9	0	13	NR	61	8	NR	NR	0
So, 1981 <sup>8</sup>	32	57 (34-78)	100	NR	NR	Neurology	28	28	0	16	NR	16	13	NR	22	9
Collins, 1981 <sup>9</sup>	18	60 (40-80)	100	NR	NR	Surgery	50	0	0	0	NR	44	39	NR	5.5	NR
Wells, 1982 <sup>10</sup>	17	58 (36-74)	94	NR	NR	Surgery	53	0	0	0	NR	35	29	38	NR	NR
Mettinger, 1982 <sup>11</sup>	37	48 (24-70)	81	NR	NR	Radiology	11	8	8	49	NR	24	38	78	49	2.7
Kelly, 1982 <sup>12</sup>	40	NR (38-78)	85	NR	NR	Surgery	30	10	0	0	NR	NR	30	43	NR	NR
Stewart, 1986 <sup>13</sup>	49	58 (29-82)	98	NR	NR	Surgery	35	27	6	NR	NR	42	6	4	8	NR
Wesen, 1986 <sup>14</sup>	30	59 (20-77)	77	47	40	Surgery	53	10	0	3	NR	26	NR	NR	NR	NR
Moreau, 1993 <sup>15</sup>	58	55 (20-76)	60	NR	25	Surgery	43	0	0	0	NR	53	NR	22	NR	NR
Liu, 2012 <sup>16</sup>	19	46 (32-64)	53	NR	NR	Radiology	5	95	0	0	74	0	NR	16	5	16
Pasquini, 2015 <sup>17</sup>	36	57	89	36	39	Neurology	17	47	0	5.6	25	0	5.6	NR	5.6	25
Hariott, 2017 <sup>18</sup>	81	53 (19-83)	96	49	68	Vascular Medicine	24	7	0	4	35	36	30/43	52	NR	NR

HTN : hypertension – TIA : transient ischaemic attack (including amaurosis fugax) – IS : ischaemic stroke – ICH : intracranial haemorrhage – SAH : subarachnoid haemorrhage – UIA : unruptured intracranial aneurysm – CeAD : cervical artery dissection – IC FMD: intracranial FMD - NR : not reported – NC : not clear – \* symptoms reported at any time (where available) – § patients with IS and CeAD are included in both columns.

## References

1. Houser OW, Baker HL, Jr., Sandok BA, Holley KE. Cephalic arterial fibromuscular dysplasia. *Radiology*. 1971;101(3):605-611.
2. Ehrenfeld WK, Wylie EJ. Fibromuscular dysplasia of the internal carotid artery. *ArchSurg*. 1974;109(5):676-681.
3. Manelfe C, Clarisse J, Fredy D, André JM, Crouzet G. Dysplasies fibromusculaires des artères cervico-céphaliques. *J Neuroradiol*. 1974;1:149-231.
4. Osborn AG, Anderson RE. Angiographic spectrum of cervical and intracranial fibromuscular dysplasia. *Stroke*. 1977;8(5):617-626.
5. Boudin G, Guillard A, Romion A, et al. [Fibro-muscular dysplasia of the carotid and vertebral arteries. Considerations apropos of 37 cases]. *Rev Otoneuroophthalmol*. 1977;49(4):297-300.
6. Effeney DJ, Ehrenfeld WK, Stoney RJ, Wylie EJ. Why operate on carotid fibromuscular dysplasia? *ArchSurg*. 1980;115(11):1261-1265.
7. Corrin LS, Sandok BA, Houser OW. Cerebral ischemic events in patients with carotid artery fibromuscular dysplasia. *ArchNeurol*. 1981;38(10):616-618.
8. So EL, Toole JF, Dalal P, Moody DM. Cephalic fibromuscular dysplasia in 32 patients: clinical findings and radiologic features. *ArchNeurol*. 1981;38(10):619-622.
9. Collins GJ, Jr., Rich NM, Clagett GP, Spebar MJ, Salander JM. Fibromuscular dysplasia of the internal carotid arteries. Clinical experience and follow-up. *AnnSurg*. 1981;194(1):89-96.
10. Wells RP, Smith RR. Fibromuscular dysplasia of the internal carotid artery: a long term follow-up. *Neurosurgery*. 1982;10(1):39-43.
11. Mettinger KL, Ericson K. Fibromuscular dysplasia and the brain. I. Observations on angiographic, clinical and genetic characteristics. *Stroke*. 1982;13(1):46-52.
12. Kelly TF, Morris GC, Jr. Arterial fibromuscular disease. Observations on pathogenesis and surgical management. *Am J Surg*. 1982;143:232-236.
13. Stewart MT, Moritz MW, Smith RB, III, Fulenwider JT, Perdue GD. The natural history of carotid fibromuscular dysplasia. *J VascSurg*. 1986;3(2):305-310.
14. Wesen CA, Elliott BM. Fibromuscular dysplasia of the carotid arteries. *Am J Surg*. 1986;151(4):448-451.
15. Moreau P, Albat B, Thevenet A. Fibromuscular dysplasia of the internal carotid artery: long-term surgical results. *J CardiovascSurg(Torino)*. 1993;34(6):465-472.
16. Liu CH, Wu D, Chin SC, et al. Cervicocranial fibromuscular dysplasia in Taiwanese ischemic stroke patients. *Eur Neurol*. 2012;67(3):129-135.

17. Pasquini M, Trystram D, Nokam G, Gobin-Metteil MP, Oppenheim C, Touze E. Fibromuscular dysplasia of cervicocephalic arteries: Prevalence of multisite involvement and prognosis. *Rev Neurol (Paris)*. 2015;171(8-9):616-623.
18. Harriott AM, Zimmerman E, Singhal AB, Jaff MR, Lindsay ME, Rordorf GA. Cerebrovascular fibromuscular dysplasia: The MGH cohort and literature review. *Neurol Clin Pract*. 2017;7(3):225-236.

**Supplemental table 3: Genetic investigations and syndromic reports of fibromuscular dysplasia (FMD).<sup>1</sup>**

<b>Gene/ syndrome</b>	<b>Renal</b>	<b>Cervico-cephalic FMD</b>
ACE	Insertion allele associated <sup>2</sup>	n/a
AT1R	No association <sup>2</sup>	n/a
AGT	No association <sup>2</sup>	n/a
Elastin	No association <sup>3</sup>	n/a
Alpha-1-antitripsin	No association <sup>4</sup> Case report <sup>5</sup>	Case reports <sup>6-9</sup>
ACTA2	No association <sup>10</sup>	No association <sup>11</sup>
TGFβR1 and	Variants of unknown significance identified	No association <sup>11</sup>
TGFβR2	n/a	No association <sup>11</sup>
collagen 3A1	n/a	No association <sup>11</sup>
SMAD3	n/a	No association <sup>11</sup>
Fibrillin (Marfan syndrome)	n/a	No association <sup>11</sup> Case report <sup>12</sup>
Down Syndrome	Case report <sup>13</sup>	n/a
Turner Syndrome	n/a	Case report <sup>14</sup>
Neurofibromatosis I	Case report <sup>15</sup>	n/a

n/a - not available

ACE: angiotensin I Converting Enzyme

AT1R: angiotensin II type 1 receptor

AGT: Angiotensinogen

ACTA2: smooth muscle alpha ( $\alpha$ )-2 actin

TGFβR: transforming growth factor, beta-receptor

SMAD3: mothers against decapentaplegic homolog 3



## References

1. Southerland AM, Meschia JF, Worrall BB. Shared associations of nonatherosclerotic, large-vessel, cerebrovascular arteriopathies: considering intracranial aneurysms, cervical artery dissection, moyamoya disease and fibromuscular dysplasia. *Curr Opin Neurol.* 2013;26(1):13-28.
2. Bofinger A, Hawley C, Fisher P, Daunt N, Stowasser M, Gordon R. Polymorphisms of the renin-angiotensin system in patients with multifocal renal arterial fibromuscular dysplasia. *J Hum Hypertens.* 2001;15(3):185-190.
3. Grimbert P, Fiquier-Kempf B, Coudol P, et al. [Genetic study of renal artery fibromuscular dysplasia]. *ArchMal Coeur Vaiss.* 1998;91(8):1069-1071.
4. Perdu J, Gimenez-Roqueplo AP, Boutouyrie P, et al. Alpha1-antitrypsin gene polymorphisms are not associated with renal arterial fibromuscular dysplasia. *J Hypertens.* 2006;24(4):705-710.
5. Bofinger A, Hawley C, Fisher P, Daunt N, Stowasser M, Gordon R. Alpha-1-antitrypsin phenotypes in patients with renal arterial fibromuscular dysplasia. *J Hum Hypertens.* 2000;14(2):91-94.
6. Solder B, Streif W, Ellemunter H, Mayr U, Jaschke W. Fibromuscular dysplasia of the internal carotid artery in a child with alpha-1-antitrypsin deficiency. *DevMedChild Neurol.* 1997;39(12):827-829.
7. Schievink WI, Bjornsson J. Fibromuscular dysplasia of the internal carotid artery: a clinicopathological study. *Clin Neuropathol.* 1996;15(1):2-6.
8. Schievink WI, Meyer FB, Parisi JE, Wijidicks EF. Fibromuscular dysplasia of the internal carotid artery associated with alpha1-antitrypsin deficiency. *Neurosurgery.* 1998;43(2):229-233.
9. Schievink WI, Bjornsson J, Parisi JE, Prakash UB. Arterial fibromuscular dysplasia associated with severe alpha 1-antitrypsin deficiency. *Mayo Clin Proc.* 1994;69(11):1040-1043.
10. Marks SD, Gullett AM, Brennan E, et al. Renal FMD may not confer a familial hypertensive risk nor is it caused by ACTA2 mutations. *Pediatr Nephrol.* 2011;26(10):1857-1861.
11. Poloskey SL, Kim E, Sanghani R, et al. Low yield of genetic testing for known vascular connective tissue disorders in patients with fibromuscular dysplasia. *Vasc Med.* 2012;17(6):371-378.
12. Schievink WI, Bjornsson J, Piepgras DG. Coexistence of fibromuscular dysplasia and cystic medial necrosis in a patient with Marfan's syndrome and bilateral carotid artery dissections. *Stroke.* 1994;25(12):2492-2496.
13. Fleisher GR, Buck BE, Cornfeld D. Primary intimal fibroplasia in a child with Down's syndrome. *Am J Dis Child.* 1978;132(7):700-703.
14. Lancman M, Mesropian H, Serra P, Granillo R. Turner's syndrome, fibromuscular dysplasia, and stroke. *Stroke.* 1991;22(2):269-271.
15. Kousseff BG, Gilbert-Barness EF. "Vascular neurofibromatosis" and infantile gangrene. *Am J Med Genet.* 1989;34(2):221-226.

**Supplemental table 4 – Prognosis of patients with cervico-cephalic fibromuscular dysplasia (FMD): risk of cerebrovascular events**

Study, <sup>ref</sup>	N patients	Clinical presentation (%)				Follow-up (years)	Cerebrovascular events during follow-up n (%/year)				
		TIA/ischemic stroke	ICH	SAH	CeAD		TIA/ischemic stroke	ICH	SAH	CeAD	FMD progression
Corrin, 1981 <sup>1</sup>	79	15	0	13	NR	5	3 (0.76)	NR	NR	NR	NR
Wells, 1982 <sup>2</sup>	16	53	0	0	NR	3.8	2 (3.29)	NR	NR	NR	0
Wesen, 1986 <sup>3</sup>	30	63	NR	3	NR	1.8	2 (3.70)	NR	NR	NR	NR
Stewart, 1986 <sup>4</sup>	35	61	6	6	NR	6.5	0	0	NR	0	NR
Liu, 2012 <sup>5</sup>	19	100	0	0	74	2.2	0	0	NR	NR	NR
Pasquini, 2015 <sup>6</sup>	36	64	0	6	25	3.5	4 (3.18)	1 (0.79)	NR	1 (0.79)	1 (0.79) (stenosis)
Harriott, 2017 <sup>7</sup>	67	23	0	4	35	2.4	1 (0.62)	0	NR	0	1 (0.62) (new intracranial aneurysm)

TIA: transient ischemic attack – ICH: Intracranial hemorrhage – SAH: subarachnoid hemorrhage – CeAD: Cervical Artery dissection – NR: not reported

## References

1. Corrin LS, Sandok BA, Houser OW. Cerebral ischemic events in patients with carotid artery fibromuscular dysplasia. *ArchNeurol*. 1981;38(10):616-618.
2. Wells RP, Smith RR. Fibromuscular dysplasia of the internal carotid artery: a long term follow-up. *Neurosurgery*. 1982;10(1):39-43.
3. Wesen CA, Elliott BM. Fibromuscular dysplasia of the carotid arteries. *Am J Surg*. 1986;151(4):448-451.
4. Stewart MT, Moritz MW, Smith RB, III, Fulenwider JT, Perdue GD. The natural history of carotid fibromuscular dysplasia. *J VascSurg*. 1986;3(2):305-310.
5. Liu CH, Wu D, Chin SC, et al. Cervicocranial fibromuscular dysplasia in Taiwanese ischemic stroke patients. *Eur Neurol*. 2012;67(3):129-135.
6. Pasquini M, Trystram D, Nokam G, Gobin-Metteil MP, Oppenheim C, Touze E. Fibromuscular dysplasia of cervicocephalic arteries: Prevalence of multisite involvement and prognosis. *Rev Neurol (Paris)*. 2015;171(8-9):616-623.
7. Harriott AM, Zimmerman E, Singhal AB, Jaff MR, Lindsay ME, Rordorf GA. Cerebrovascular fibromuscular dysplasia: The MGH cohort and literature review. *Neurol Clin Pract*. 2017;7(3):225-236.