



HAL
open science

Hepatic tumor diagnosis by analysing dense transport fields in contrast-enhanced ultrasound

Baudouin Denis de Senneville, Nora Frulio, Hervé Laumonier, Cécile Salut,
Luc Lafitte, Hervé Trillaud

► **To cite this version:**

Baudouin Denis de Senneville, Nora Frulio, Hervé Laumonier, Cécile Salut, Luc Lafitte, et al.. Hepatic tumor diagnosis by analysing dense transport fields in contrast-enhanced ultrasound. ISBI19 - 16th IEEE International Symposium on Biomedical Imaging, Apr 2019, Venice, Italy. hal-02377660

HAL Id: hal-02377660

<https://hal.science/hal-02377660v1>

Submitted on 24 Nov 2019

HAL is a multi-disciplinary open access archive for the deposit and dissemination of scientific research documents, whether they are published or not. The documents may come from teaching and research institutions in France or abroad, or from public or private research centers.

L'archive ouverte pluridisciplinaire **HAL**, est destinée au dépôt et à la diffusion de documents scientifiques de niveau recherche, publiés ou non, émanant des établissements d'enseignement et de recherche français ou étrangers, des laboratoires publics ou privés.

HEPATIC TUMOR DIAGNOSIS BY ANALYSING DENSE TRANSPORT FIELDS IN CONTRAST-ENHANCED ULTRASOUND

B. Denis de Senneville* N. Frulio† H. Laumonier† C. Salut† L. Lafitte* H. Trillaud†,‡

* Mathematical Institute of Bordeaux, UMR 5251 CNRS/University of Bordeaux/INRIA, France

† Department of Diagnostic and Interventional Imaging, Hôpital Saint-André,
Centre Hospitalier Universitaire de Bordeaux, †IMOTION, University of Bordeaux

ABSTRACT

Dynamic contrast agent enhanced ultrasound (DCEUS) is considered as a safe, noninvasive, accurate, and economic tool for analysing blood perfusion of various organs [1]. Gas-filled microbubble contrast agents are used as intravascular flow tracers. In this study, a new methodology is proposed to quantify the divergence (i.e sources, sinks), curl (i.e sheering) and amplitude in the apparent microbubble transports during the bolus arrival. The efficiency of proposed methodology is evaluated *in-vivo*, for the classification of focal nodular hyperplasia (FNH) and inflammatory hepatic adenomas (I-HCA).

1. INTRODUCTION

The diagnosis between FNH and I-HCA is sometime difficult at DCEUS because both demonstrate a hyper-enhancing at the arterial phase with difficulties to differentiate the centrifugal or centripetal filling of the tumor with only qualitative visual analysis.

Recent efforts in DCEUS aim at quantifying parameters related to the ultrasound contrast enhancement in the vascular compartment and at using these latter as indicators for several pathological conditions. In particular, quantitative analysis with the use of a transport equation has been recently introduced to estimate the apparent microbubble velocity of the bolus arrival [2]. In the current study, we propose a new methodology designed to quantify the divergence (i.e sources, sinks), curl (i.e sheering) and amplitude in the estimated apparent dense transport field. The latter provide three very simple indicators of displacement vector directions, orientations and magnitude, which are used as inputs of a binary FNH/I-HCA classifier.

2. RESULTS

46 patients with FNH (n=29) or I-HCA (n=17) were analyzed (histological diagnosis). Fig. 1 reports typical estimated microbubble transport fields obtained for two DCEUS experiment (upper row=FNH/ bottom row=I-HCA) 0.75 s after the microbubble arrival time. The apparent flow field in 1b shows a fast centrifugal filling of the lesion from a central vessel and radial vascular branches. On the contrary, 1d shows a hyper-enhancing in the arterial phase with an enhancement pattern beginning peripherally, with fast centripetal filling. As a consequence, the divergence of the flow field were overall visually higher for the FNH population (insert of 1b) as compared

The authors thank the Laboratory of Excellence TRAIL ANR-10-LABX-57 for funding. This study has been carried out with the financial support of the French National Research Agency (ANR) in the frame of the Investments for the future Programme IdEx Bordeaux-CPU (ANR-10-IDEX-03-02).

to the I-HCA population (insert of 1d). Over the three tested image-based transport indicators, only the divergence indicator led to a significant difference (p-value of Mann-Whitney test= 2.10^{-7}). Diagnostic performances of the divergence indicator: accuracy=93.5%, AUROC=0.93, sensitivity=91.0%, specificity=95.4%, PPV=92.2%, NPV=95.3% (Naïve Bayes classifier).

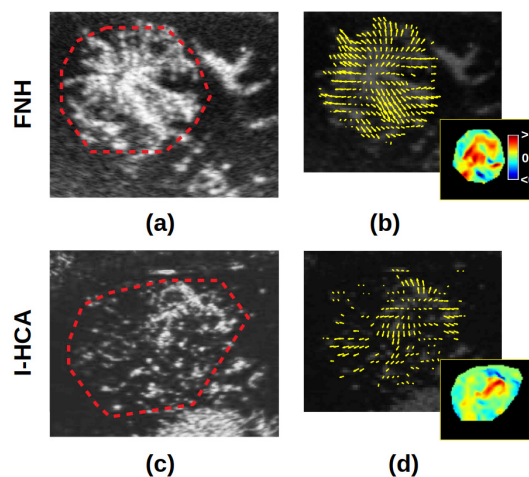


Fig. 1. Typical results obtained for FNH and I-HCA lesions.

3. CONCLUSION

This proof-of-concept study indicates that image-based apparent microbubble transport fields can provide new efficient diagnosis indicators on DCEUS. Machine learning algorithms applied on the latter provides valuable information for the automatic diagnosis of FNH/I-HCA lesions. Future study will concern the optimization of the model, with the study of larger cohorts, the inclusion of other categories of features and the study of other pathologies.

4. REFERENCES

- [1] F. Tranquart et al., “Perfusion quantification in contrast-enhanced ultrasound (CEUS)—ready for research projects and routine clinical use,” *Ultrasound Med*, vol. 33, pp. S31–8, 2012.
- [2] B. Denis de Senneville et al., “Development of a fluid dynamic model for quantitative contrast-enhanced ultrasound imaging,” *IEEE Trans on Med Im*, vol. 37, no. 2, pp. 372–383, 2018.