HAL
open science

Image-based registration for lung nodule localization during VATS

Pablo Alvarez, Simon Rouzé, Matthieu Chabanas, Yohan Payan, Jean-Louis Dillenseger

To cite this version:

Pablo Alvarez, Simon Rouzé, Matthieu Chabanas, Yohan Payan, Jean-Louis Dillenseger. Image-based registration for lung nodule localization during VATS. Surgetica 2019, Jun 2019, Rennes, France. hal-02370279

HAL Id: hal-02370279

https://hal.science/hal-02370279v1

Submitted on 19 Nov 2019

HAL is a multi-disciplinary open access archive for the deposit and dissemination of scientific research documents, whether they are published or not. The documents may come from teaching and research institutions in France or abroad, or from public or private research centers.

L'archive ouverte pluridisciplinaire **HAL**, est destinée au dépôt et à la diffusion de documents scientifiques de niveau recherche, publiés ou non, émanant des établissements d'enseignement et de recherche français ou étrangers, des laboratoires publics ou privés.

Image-based registration for lung nodule localization during VATS

Pablo ALVAREZ [1,2], Simon ROUZÉ [3], Matthieu CHABANAS [2], Yohan PAYAN [2] and Jean-Louis DILLENSEGER [1]

[1] Univ Rennes, Inserm, LTSI - UMR 1099, F-35000 Rennes, France
[2] Univ. Grenoble Alpes, CNRS, Grenoble-INP, TIMC-IMAG, Grenoble, France
[3] CHU Rennes, Service of Thoracic and Cardiac Surgery, Rennes, France
Contact: pablo.alvarez@etudiant.univ-rennes1.fr

Lung nodule localization during Video-Assisted Thoracoscopic Surgery (VATS) is a challenging task for small, low-density nodules. Current preoperative localization techniques are still sub-optimal in some cases. In this work, we studied the use and the limitations of an image-based nonrigid registration approach for nodule localization during VATS. Average target registration errors were of 5.67 mm, meaning an error reduction of 84.36 %.

1 Introduction

In clinical practice, early stage lung cancer nodules can be prescribed for resection through Video-Assisted Thoracoscopic Surgery (VATS). Because of their typically reduced size and density, these nodules might be difficult to find during surgery, especially under large lung deformations. This is caused by a pneumothorax (*i.e.* the abnormal presence of air inside the thoracic cage) resulting from the insertion of the surgical ports. To account for this problem, preoperative nodule localization procedures are typically used. These procedures consist mainly on the placement of hook-wires, dyes or micro-coils in the nodule [1]. However, studies have found these localization techniques to still be sub-optimal [2].

Consequently, there is a growing interest toward the development of intraoperative lung localization procedures. Previous studies have proposed the use of intraoperative imaging for nodule localization [3, 4]. In addition, image processing techniques can be used in combination with intraoperative imaging for nodule localization. For instance, Uneri *et al.* used intraoperative Cone Beam CT (CBCT) and a hybrid shape-intensity nonrigid registration approach for nodule localization on an animal study [5].

In this preliminary work, we propose to use intraoperative CBCT imaging and nonrigid image registration for lung nodule localization during VATS. Our approach was inspired by Wu *et al.* [6], who proposed an algorithm that takes into account sliding effects for registering images of breathing lungs. To the best of our knowledge, this is the first study on human data using intraoperative imaging and nonrigid image registration for nodule localization.

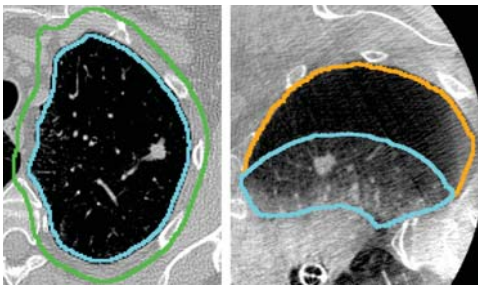

Figure 1: *Left: preoperative CT with the segmentation of the lung (cyan) and its extension (green). Right: intraoperative CBCT with the segmentations of the lung (cyan) and thoracic cage (orange). The pneumothorax is the space between the deflated lung and the thoracic cavity.*

2 Materials and Methods

2.1 Clinical data

This study used two tomographic images issued from a single clinical case of a VATS intervention performed at Rennes University Hospital. The first image, a preoperative CT, was taken following the current clinical protocol (Fig. 1 left). The second image, an intraoperative CBCT, was taken after the patient's lung was deflated as a result of the pneumothorax (Fig. 1 right). Both images were acquired under the patient's informed consent and the local ethics committee approval.

2.2 Segmentation

Three anatomical structures were manually segmented: the lung in the CT and CBCT images and the thoracic cavity in the CBCT image. The binary masks were post-processed using morphological dilatation to extend the boundaries (Fig. 1 left, green contours).

2.3 Nodule localization approach

Our approach consists of two steps: a rigid registration for initial alignment followed by a nonrigid image registration to account for pneumothorax deformation. Both processes were implemented using Elastix [7].

2.3.1 Rigid registration

We used the thoracic cavity as a reference for aligning the preoperative CT and intraoperative CBCT images. We performed rigid image registration using the Mutual Information (MI) similarity metric. The MI computation was filtered to the regions contained in the extended masks of the thoracic cavity. We used discrete probability distributions of a very low resolution for the computation of the MI (*i.e.* the number of bins was only 8). In this way, the strong gradients corresponding to the borders of the thoracic cavity and the main airway branches are more likely to drive the registration process than the weak gradients at the interior of the mismatching thoracic cavities. This is important given that the thoracic cavities contain mismatching lungs.

2.3.2 Nonrigid registration

Before nonrigid registration, we performed an intensity assignment procedure. The intensity values of the voxels outside the segmented lungs were assigned with a constant intensity value, while those at the inside were left unchanged. This constant value (-1500 HU) lies outside the range of values inside the lung. A nonrigid registration process was then performed using these intensity-modified images and the extended masks of the lung parenchyma. We accounted for large deformations using a multi-resolution Free Form Deformation (FFD) strategy, with a total of 4 resolutions. At each iteration, the resolution was doubled and the transformation obtained was carried through consecutive iterations. We used B-Splines as the transformation model with two intensity-based similarity metrics: Mutual Information (MI) and Normalized Cross Correlation (NCC). The B-Spline grid size was allowed to change with image resolution, reaching 16 mm in the last iteration.

3 Results and Discussion

To compute Target Registration Errors (TRE), 27 paired anatomical landmarks were manually placed by an expert thoracic surgeon on the nodule and the bifurcations of airways and vessels. After rigid registration, the mean TRE was 43.72 mm (±9.99 mm).

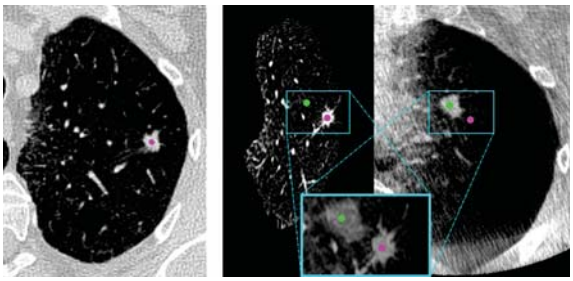

Figure 2: *Result of nonrigid registration with NCC. From left to rigth: preoperative CT, deformed CT and CBCT. Colored circles indicate the paired landmarks on the nodule. The image in the window is a closeup of the superposition of the result.*

Nonrigid registration with MI resulted in TREs of 80 mm (±20.39 mm), which are worse than after rigid registration. This bad performance may be explained by the fact that the MI similarity metric does not necessarily penalize mismatches of intensity, which makes it is less costly to move the CT-lung voxels out of the CBCT-mask than to move them inside.

However, nonrigid registration with NCC reduced the TREs to 5.57 mm (±3.35 mm), which corresponds to an error reduction of 84.35 %. In comparison to MI, NCC aims to closely match image intensities, and hence benefits from the usage of the intensity-modified images and the extended masks. The reason is that the borders of the CT and CBCT lung are forced to match as a result of the strong intensity gradients artificially generated by the intensity assignment procedure.

The result of nonrigid registration with NCC is shown in Fig. 2. Despite the satisfying quantitative measurements, a qualitative comparison of the deformed CT and the CBCT still reveals large misalignment. This can be seen throughout the lung parenchyma, where several internal structures are visible in only one of the images. Particularly, the landmarks placed on the nodule are 11.77 mm apart after nonrigid registration (51.1 mm after rigid registration), which is not within the clinical requirements. The registration problem at hand is a real challenge (*i.e.* very large deformations and low quality images). Although more sophisticated techniques do exist, the use of image intensity only to guide registration is possibly insufficient.

4 Conclusion

This preliminary study evaluated an intensity-based nonrigid registration approach for nodule localization during VATS. The results showed an error correction of 84.36 % when using NCC, although a closer qualitative analysis suggested unsatisfactory matching on some inner structures. We believe that intensity-based nonrigid registration only may be insufficient for nodule localization during VATS. Hence, hybrid approaches combining images and biomechanical models of pneumothorax deformation [8] will be explored.

Acknowledgments

This work was supported in part by the *Région Bretagne* through its *Allocations de Recherche Doctorale* (ARED) framework and by the French National Research Agency (ANR) through the frameworks *Investissements d'Avenir Labex CAMI* (ANR-11-LABX-0004) and *Infrastructure d'Avenir en Biologie et Santé* (ANR-11-INBS-0006).

References

[1] J. Keating and S. Singhal. "Novel methods of intraoperative localization and margin assessment of pulmonary nodules". en. *Seminars in Thoracic and Cardiovascular Surgery* 28.1 (2016), pp. 127–136.

[2] C. H. Park et al. "Comparative effectiveness and safety of preoperative lung localization for pulmonary nodules". en. *Chest* 151.2 (Feb. 2017), pp. 316–328.

[3] S. Rouzé et al. "Small pulmonary nodule localization with cone beam computed tomography during video-assisted thoracic surgery: a feasibility study". en. *Interactive CardioVascular and Thoracic Surgery* 22.6 (June 2016), pp. 705–711.

[4] H. Wada et al. "Thoracoscopic ultrasonography for localization of subcentimetre lung nodules". en. *European Journal of Cardio-Thoracic Surgery* 49.2 (Feb. 2016), pp. 690–697.

[5] A. Uneri et al. "Deformable registration of the inflated and deflated lung in cone-beam CT-guided thoracic surgery: Initial investigation of a combined model-and image-driven approach". *Medical physics* 40.1 (2013).

[6] Z. Wu et al. "Evaluation of deformable registration of patient lung 4DCT with subanatomical region segmentations: Evaluation of deformable registration of 4DCT with segmentations". en. *Medical Physics* 35.2 (Jan. 2008), pp. 775–781.

[7] S. Klein et al. "elastix: A toolbox for intensity-based medical image registration". *IEEE Transactions on Medical Imaging* 29.1 (Jan. 2010), pp. 196–205.

[8] P. Alvarez et al. "Biphasic model of lung deformations for Video-Assisted Thoracoscopic Surgery (VATS)". *IEEE 16th International Symposium on Biomedical Imaging*. 2019.