



HAL
open science

Distinct interferon signatures stratify inflammatory and dysimmune myopathies

Muriel Rigolet, Cyrielle Hou, Yasmine Baba Amer, Jessie Aouizerate, Baptiste Periou, Romain K. Gherardi, Peggy Lafuste, François Authier, Yasmine Baba Amer, François Jérôme Authier

► To cite this version:

Muriel Rigolet, Cyrielle Hou, Yasmine Baba Amer, Jessie Aouizerate, Baptiste Periou, et al.. Distinct interferon signatures stratify inflammatory and dysimmune myopathies. *RMD Open: Rheumatic & Musculoskeletal Diseases*, 2019, 5 (1), pp.e000811. 10.1136/rmdopen-2018-000811 . hal-02354248

HAL Id: hal-02354248

<https://hal.science/hal-02354248>

Submitted on 7 Nov 2019

HAL is a multi-disciplinary open access archive for the deposit and dissemination of scientific research documents, whether they are published or not. The documents may come from teaching and research institutions in France or abroad, or from public or private research centers.

L'archive ouverte pluridisciplinaire **HAL**, est destinée au dépôt et à la diffusion de documents scientifiques de niveau recherche, publiés ou non, émanant des établissements d'enseignement et de recherche français ou étrangers, des laboratoires publics ou privés.

ORIGINAL ARTICLE

Distinct interferon signatures stratify
inflammatory and
dysimmune myopathiesMuriel Rigolet,¹ Cyrielle Hou,¹ Yasmine Baba Amer,¹ Jessie Aouizerate,^{1,2}
Baptiste Periou,¹ Romain K Gherardi,^{1,2} Peggy Lafuste,¹ François Jérôme Authier^{1,2}

To cite: Rigolet M, Hou C, Baba Amer Y, *et al.* Distinct interferon signatures stratify inflammatory and dysimmune myopathies. *RMD Open* 2019;**5**:e000811. doi:10.1136/rmdopen-2018-000811

► Prepublication history and additional material for this paper are available online. To view these files, please visit the journal online (<http://dx.doi.org/10.1136/rmdopen-2018-000811>).

Received 27 August 2018
Revised 20 November 2018
Accepted 8 December 2018

ABSTRACT

Objective The role of interferons (IFN) in the pathophysiology of primary inflammatory and dysimmune myopathies (IDM) is increasingly investigated, notably because specific neutralisation approaches may constitute promising therapeutic tracks. In present work we analysed the muscular expression of specific IFN α/β and IFN γ -stimulated genes in patients with various types of IDM.

Methods 39 patients with IDM with inclusion body myositis (IBM, n=9), dermatomyositis (DM, n=10), necrotising autoimmune myopathies (NAM, n=10) and antisynthetase myositis (ASM, n=10), and 10 controls were included. Quantification of expression levels of IFN γ , ISG15, an IFN α/β -inducible gene and of six IFN γ -inducible genes (GBP2, HLA-DOB, HLA-DPB, CIITA, HLA-DRB and HLA-DMB) was performed on muscle biopsy samples.

Results DM usually associated with strong type I IFN α/β signature, IBM and ASM with prominent type II IFN γ signature and NAM with neither type I nor type II IFN signature. Immunofluorescence study in ASM and IBM showed myofibre expression of major histocompatibility class 2 (MHC-2) and CIITA, confirming the induction of the IFN γ pathway. Furthermore, MHC-2-positive myofibres were observed in close proximity to CD8+ T cells which produce high levels of IFN γ .

Conclusion Distinct IFN signatures allow a more distinct segregation of IDMs and myofibre MHC-2 expression is a reliable biomarker of type II IFN signature.

Key messages

What is already known about this subject?

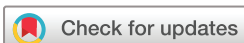- Among inflammatory/dysimmune myopathies (IDMs), dermatomyositis (DM) is the only associated with type I-interferon signature.
- Most IDMs are associated with myofiber expression of major histocompatibility complex (MHC)-class I. MHC-I is induced by interferons suggesting a possible role for type II-interferon in IDMs other than DM.

What does this study add?

- In this study, we showed that myofiber MHC-II expression is observed in inclusion body myositis (IBM) and antisynthetase myositis (ASM), but not in DM and necrotizing autoimmune myopathy (NAM).
- In accordance with this finding, we showed that IBM and ASM are specifically associated with Type-II IFN γ signature, DM only with Type-I IFN signature, and NAM with neither Type-I nor Type-II IFN signature.

How might this impact on clinical practice?

- Distinct IFN signatures allow a more distinct segregation of IDMs and therefore a more accurate diagnosis.
- Deciphering IFN signatures in IDMs will also lead to develop new therapeutic approaches targeting IFNs pathways.



© Author(s) (or their employer(s)) 2019. Re-use permitted under CC BY-NC. No commercial re-use. See rights and permissions. Published by BMJ.

¹IMRB, Inserm U955-Team 10, Paris Est-Creteil University, Paris, France

²Reference Center for Neuromuscular Diseases, Henri Mondor University Hospitals, Paris, France

Correspondence to

Dr François Jérôme Authier;
authier@u-pec.fr

INTRODUCTION

Both muscle biopsy and circulating myositis-specific autoantibodies (MSA) are used in the diagnostic workup for inflammatory and dysimmune myopathies (IDM). Muscle biopsy made possible to visualise and classify the pathological processes leading to myofibre injuries, such as CD8 T cell-mediated cytotoxicity in inclusion body myositis (IBM), endomysial microangiopathy with ischaemic myofibre injuries in dermatomyositis (DM) and complement-mediated myofibre necrosis in necrotising autoimmune myopathies (NAM).¹ MSAs had a major implication in delineation of distinctive patterns of

disease or phenotype and in predicting prognosis of IDMs.² In addition, the role of interferons (IFN) in the pathophysiology of IDMs is increasingly scrutinised in a therapeutic perspective,³ notably because it may lead to specific IFN neutralisation approaches.⁴ For example, DM displays a strong type I IFN α/β signature.^{5,6} In contrast to DM, the role of IFNs has not been well established in other types of IDM.⁷

In a previous study on anti-synthetase syndrome-associated myositis (ASM), a condition in which muscular involvement is associated with peculiar extramuscular features and specific circulating autoantibodies, we observed that, in contrast to DM, there was

conspicuous myofibre expression of major histocompatibility class 2 (MHC-2) antigens.⁷ Since MHC-2 expression by myogenic cells is induced by type II IFN γ and blocked by type I IFN α/β ,⁸ marked MHC-2 expression in ASM suggested imbalance between IFN type I and type II pathways in favour of IFN type II in this specific IDM subtype. In the present study, type I and type II IFN signatures were determined in muscle biopsy samples from patients with the main IDM subtypes, including DM, IBM, NAM and ASM. Expression analysis of specific IFN α/β and IFN γ -stimulated genes characterised DM as specifically associated with type I IFN α/β signature, IBM and ASM with type II IFN γ signature and NAM with neither type I nor type II IFN signature.

MATERIALS AND METHODS

Patients and muscle samples

Muscle biopsies from patients with NAM (n=10), DM (n=10), ASM (n=10), IBM (n=9) and histologically normal muscle (n=10, controls) were obtained from the Department of Pathology, Henri Mondor University Hospital (Créteil, France). A polymyositis (PM) group was not included because of the extreme rarity of idiopathic PM when strict diagnostic criteria are used. This study was conducted in accordance with French rules (Henri Mondor Biological Resource Platform: registration number DC-2009-930, French Ministry of Research). Autoantibodies screening was carried out using commercially available linear dots. All patients had muscle biopsy for diagnostic purposes, with immunoperoxidase staining of MHC-1 and MHC-2 antigens, complement membrane attack complex (C5b-9), CD56/NCAM (myofibre regeneration), CD68 (macrophages), and CD3, CD4, CD8 and CD20 (leucocyte subsets), and immunofluorescence for dual labelling (MHC-2/class II MHC transactivator (CIITA); MHC-2/CD8) (references in online supplementary information). European Neuromuscular Centre (ENMC) criteria were used to diagnose DM, NAM and IBM, and Trojanov classification was used to diagnose overlap myositis,¹ the ASM subset of which being defined by detection of circulating antisynthetase autoantibodies. Myofibre MHC-2 expression was defined by sarcolemmal staining with or without sarcoplasmic staining.⁷

Real-time quantitative PCR

RNAs were extracted from biopsy samples using Trizol reagent and quantified by NanoDrop. cDNAs were synthesised using the Maxima First strand cDNA synthesis kit (Thermo Scientific). We analysed the expression levels of IFN γ , ISG15, an IFN α/β -inducible gene and of six IFN γ -inducible genes: GBP2, HLA-DOB, HLA-DPB, CIITA, HLA-DRB and HLA-DMB. We used quantitative RT-PCR on ABI PRISM 7900HT using TaqMan assays (Applied Biosystems) or the SYBR Green reagent. Assays and primer sequences are indicated in online supplementary information). The median fold change in

expression of six IFN γ -stimulated genes for each patient biopsy sample was used to define an IFN γ score.⁹

Statistical analysis

Statistical analyses were performed using the non-parametric Mann-Whitney test ($p < 0.05$ was considered significant) and GraphPad Prism V.6.0 (GraphPad Software, La Jolla, CA).

RESULTS

Patient characteristics

Patients with ASM included four women and six men (mean age: 55 years; range: 25–83), with anti-Jo1 autoantibodies in 9/10 and anti-PL7 in 1/10. Patients with DM included eight women and two men (mean age: 58 years; range: 34–85), and patients with IBM included four women and five men (mean age: 69 years; range 61–89). Patients with NAM included eight women and two men (mean age: 54 years; range 24–90), with anti-signal recognition particle autoantibodies in 3/10, anti-HMGCR in 3/10 and anti-Ku in 1/10.

IFN α/β -inducible gene expression in muscle tissues

We first tested the involvement of type I IFN α/β in the various IDM subsets by quantifying the level of ISG15 expression, an IFN α/β -inducible gene in muscle. ISG15 expression was markedly and specifically increased in DM: DM versus NAM: $p < 0.0001$; DM versus ASM: $p < 0.0001$; DM versus IBM: $p < 0.0001$ (figure 1H).

Expression IFN γ and its inducible genes in muscle tissue

IFN γ expression in muscle varied according to each IDM subtype. The highest levels of IFN γ were observed in patients with IBM followed by patients with ASM, whereas IFN γ expression was detectable at low level in DM, and absent (comparable to controls) in NAM (figure 1A).

Consistently expression of the IFN γ -inducible CIITA gene tended to be higher in ASM and IBM compared with NAM and DM (figure 1B). Immunohistochemical expression of the IFN γ -inducible MHC-2 differed between ASM and IBM, mainly perifascicular in ASM and multifocal in IBM (figure 2). Expression levels of HLA-DOB and HLA-DPB genes were significantly higher in IBM compared with NAM ($p = 0.0039$ and $p = 0.0002$, respectively) (figure 1E,F), and in ASM compared with NAM ($p = 0.0027$ and $p = 0.0051$, respectively) (figure 1E,F). Expression levels of HLA-DRB genes were significantly higher in IBM compared with NAM ($p = 0.0433$) but not in ASM (figure 1C). Increased HLA-DPB gene expression could segregate both IBM and ASM from DM ($p = 0.002$ and $p = 0.0028$, respectively) (figure 1F). HLA-DQ gene expression level fell beneath the detection threshold. In contrast, increased GBP2 gene expression could discriminate both IBM and ASM from NAM ($p = 0.0524$ and $p = 0.0021$, respectively), and ASM from DM ($p = 0.0062$) (figure 1G).

In line with these results, the IFN γ score defined by the median fold change in expression of six IFN γ -induced

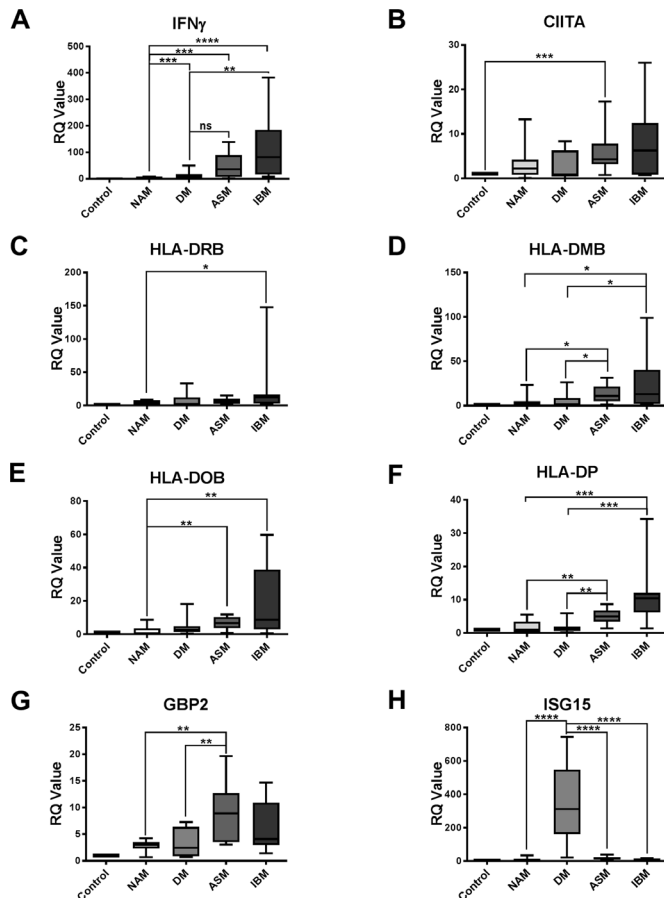


Figure 1 Relative expression of IFN γ (A), CIITA (B), HLA-DRB (C), HLA-DMB (D), HLA-DOB (E), HLA-DPB (F), GBP2 (G) and ISG15 (H) in NAM, DM, ASM and IBM. * $P < 0.05$; ** $P < 0.01$; *** $P < 0.001$. ASM, anti-synthetase syndrome-associated myositis; DM, dermatomyositis; IBM, inclusion body myositis; IFN, interferon; NAM, necrotising autoimmune myopathies; RQ, relative quantification.

genes clearly discriminated ASM and IBM from NAM ($p = 0.0022$ and $p = 0.0022$, respectively) and ASM and IBM from DM ($p = 0.0411$ and $p = 0.0043$). (figure 3) Taken together, these data were consistent with an IFN γ signature in ASM and IBM.

IFN γ pathway activation in myofibres

The respective localisation of MHC-2 and CIITA expressions was assessed by immunofluorescence in IDM subsets with elevated IFN γ score, that is, ASM and IBM. In ASM, MHC-2 and CIITA expressions were primarily observed in perifascicular myofibres (figure 2A). Most myofibres coexpressed MHC-2 and CIITA, with occasional fibre expression MHC-2 or CIITA alone (figure 2A). In contrast, in IBM, MHC-2-positive myofibres were distributed in multifocal clusters that coexpressed CIITA (figure 2A). CD8-positive cells known to produce IFN γ were usually observed in the vicinity of MHC-2-positive myofibres (figure 2B). In DM, only few MHC-2-positive myofibres were observed. In NAM, no myofibre MHC-2 expression was observed, and no or very few CD8-positive cells were detected in the endomysium.

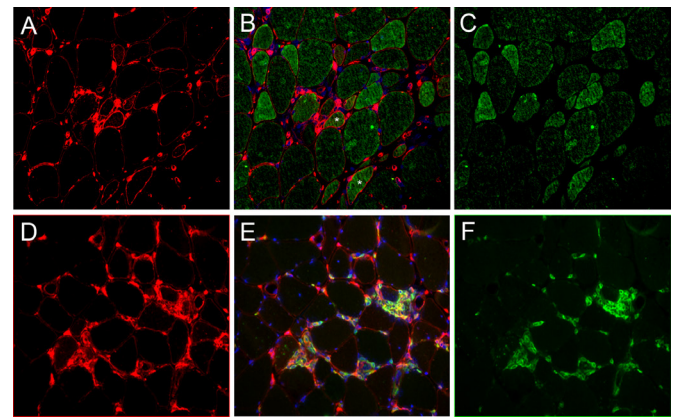


Figure 2 Muscle biopsy from a patient with inclusion body myositis (IBM). (A–C) Immunofluorescence staining of major histocompatibility class 2 (MHC-2) and CIITA: MHC-2, red (A); CIITA, green (C); merged with DAPI for nuclei staining in blue (B). The pattern of MHC-2-positive myofibre distribution appears multifocal. Double staining shows CIITA-positive/MHC-2-negative myofibres corresponding to an early step of interferon- γ (IFN γ) signalling, double-positive CIITA/MHC-2 fibres (stars) indicating early MHC-2 transactivation and CIITA-negative/MHC-2-positive fibres indicating later stages, concomitant with CIITA degradation. (D–F) Immunofluorescence staining of MHC-2 and CD8: MHC-2, red (D); CD8, green (F); merged with DAPI for nuclei staining in blue (E). CD8+ T cells are found proximal to MHC-2-positive myofibres, MHC-2 expression by CD8 T cells (double-stained cells), (E) indicating activated state. Frozen muscle sections (7 μ m). Magnification $\times 10$.

DISCUSSION

Many reports have reported type I IFN α/β signature in muscle and blood of patients with DM.^{10 11} Consistently, the type I IFN-inducible ISG15 gene expression was upregulated in muscle of our patients with DM as previously documented by microarray analyses in whole muscle^{5 12} or microdissected MHC-1-positive myofibres.¹³

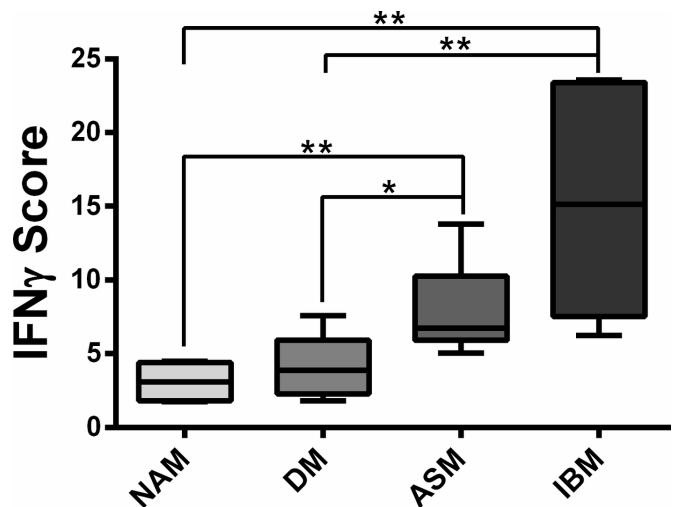


Figure 3 IFN score calculated from the median fold change in expression of six IFN γ -induced genes (CIITA, HLA-DRB, HLA-DMB, HLA-DOB, HLA-DPB, GBP2).¹³ * $P < 0.05$; ** $P < 0.01$; *** $P < 0.001$. IFN, interferon.

In DM, perifascicular atrophic fibres also strongly express MxA protein, an important type I IFN-related factor.⁵ The inducer of type I IFN release is unknown in DM, but IFN α and β are known to be produced by plasmacytoid dendritic cells that are increased in DM muscle.⁵ Type I IFNs have been recognised to play key roles in the initiation and maintenance of the DM process, through exacerbation of inflammatory responses,¹⁴ upregulation of MHC-1 in myofibres, effects on endothelial cells⁵ and induction of mitochondrial dysfunction.¹⁵

To assess type II IFN, we used a panel of genes including IFN γ , CIITA, GBP2 and four MHC-2 genes. This combination was chosen to focus on genes electively induced by IFN γ despite highly weight with MHC-2-related transcripts. Other IFN γ -induced genes could be used such as GBP5, ICAM1, CAMK2D, IRF1, SOCS3, CD44 or CCL2.¹⁶ In accordance with the existence of CD8-positive large granular lymphocytes in sIBM,¹⁰ we showed that type II IFN signature was electively increased in sIBM. IFN γ is a potent inducer of MHC-2 expression,⁷ an effect mediated by the transactivator CIITA.¹¹ Increased muscle expression of IFN γ in ASM and IBM was associated with both CIITA gene upregulation and myofibre expression of MHC-2 antigens. In DM, the type II signature was low but not null, in keeping with the presence of few numbers of MHC-2-positive myofibres.⁷ Previous studies investigating myofibre MHC-2 expression in DM^{17,18} showed a median percentage of MHC-2-positive fibres ranging from 2.2% to 8.6%,¹⁷ a proportion similar to that we reported (7.5%)⁷ and indicating that type I and type II signatures may occasionally overlap in DM. In contrast, NAM expressed virtually no type I or type II IFN signature and no MHC-2 in myofibres, a feature in agreement with current view of NAM pathogenesis highlighting a role for autoantibodies and complement activation in myofibre injuries.^{19,3}

The main sources of IFN γ are natural killer (NK) cells, CD4-Th1 and CD8-cytotoxic T lymphocytes.²⁰ In addition to type II IFN signature, we observed CD8+ T cells in close vicinity of MHC-2 expressing myofibres in both ASM and IBM (figure 3). NK cells are rare in muscular inflammatory infiltrates in ASM²¹ and virtually absent in IBM.²² This finding points out CD8+ T cells as a likely source of local IFN γ production in ASM and IBM. In sIBM, IFN γ signalling cascade was shown upregulated in attacked myofibres but not in non-attacked supporting this view.²³ Expression of CIITA protein was restricted to myofibres in ASM and IBM (figure 2A). In addition to inducing MHC-2, and possibly MHC-1 myofibre expression, IFN γ may also inhibit myogenesis through CIITA by recruiting myogenin together with silencing epigenetic factors to target gene promoters.²⁴ So, IFN γ activity may both sustain inflammation and impair injured myofibre repair, and therefore could aggravate the MHC-1/TCR-mediated myofibre destruction by CD8 T cells.

We hope that the distinctive IFN signatures in the different IDM subtypes reported herein could help in further development of key molecular pathway-based therapeutic approaches, targeting IFN type I in DM,^{3,25}

IFN type II in ASM and IBM, and complement-mediated cell death in NAM.²⁶

Acknowledgements CH and BP benefited from a fellowship from Région Ile-de-France and RHU CARMMA, respectively.

Contributors MR performed RTqPCR, analysed results and wrote the manuscript. CH analysed results, designed the figures, performed immunostaining and participated in the writing of paper. YBA performed immunostaining. JA carried out clinical data and histopathological analyses. BP managed biobanking and performed immunohistochemistry. RKG contributed to the redaction of paper. PL analysed data and participated in the redaction of paper. FJA was in charge of conception, supervision, data analyses and redaction of the paper.

Funding This work was funded by grants from Association Française contre les Myopathies (AFM), Pole Translamuscle (project number 19507), MyoDR (project number 19100).

Competing interests None declared.

Patient consent for publication Obtained.

Ethics approval French Ministry of Research (authorisation number DC-2009-930).

Provenance and peer review Not commissioned; externally peer reviewed.

Data sharing statement There is no data repository for sharing.

Open access This is an open access article distributed in accordance with the Creative Commons Attribution Non Commercial (CC BY-NC 4.0) license, which permits others to distribute, remix, adapt, build upon this work non-commercially, and license their derivative works on different terms, provided the original work is properly cited, appropriate credit is given, any changes made indicated, and the use is non-commercial. See: <http://creativecommons.org/licenses/by-nc/4.0/>.

REFERENCES

- De Bleecker JL, Lundberg IE, de Visser M. 193rd ENMC International workshop Pathology diagnosis of idiopathic inflammatory myopathies 30 November – 2 December 2012, Naarden, The Netherlands. *Neuromuscul Disord* 2013;23:945–51.
- McHugh NJ, Tansley SL. Autoantibodies in myositis. *Nat Rev Rheumatol* 2018;14:290–302.
- Higgs BW, Zhu W, Morehouse C, et al. A phase 1b clinical trial evaluating sifalimumab, an anti-IFN- α monoclonal antibody, shows target neutralisation of a type I IFN signature in blood of dermatomyositis and polymyositis patients. *Ann Rheum Dis* 2014;73:256–62.
- De Paepe B. Interferons as components of the complex web of reactions sustaining inflammation in idiopathic inflammatory myopathies. *Cytokine* 2015;74:81–7.
- Greenberg SA, Pinkus JL, Pinkus GS, et al. Interferon- α/β -mediated innate immune mechanisms in dermatomyositis. *Ann Neurol* 2005;57:664–78.
- Gitiaux C, Latroche C, Weiss-Gayet M, et al. Myogenic Progenitor Cells Exhibit Type I interferon-driven proangiogenic properties and molecular signature during juvenile dermatomyositis. *Arthritis Rheumatol Hoboken NJ* 2018;70:134–45.
- Aouizerate J, De Antonio M, Bassez G, et al. Myofiber HLA-DR expression is a distinctive biomarker for antisynthetase-associated myopathy. *Acta Neuropathol Commun* 2014;2:154.
- Troyanov Y, Targoff IN, Tremblay J-L, et al. Novel classification of idiopathic inflammatory myopathies based on overlap syndrome features and autoantibodies: analysis of 100 French Canadian patients. *Medicine* 2005;84:231–49.
- Allenbach Y, Leroux G, Suárez-Calvet X, et al. Dermatomyositis with or without anti-melanoma differentiation-associated gene 5 antibodies: common interferon signature but distinct NOS2 expression. *Am J Pathol* 2016;186:691–700.
- Greenberg SA. Inclusion body myositis. *Contin Minneap Minn* 2016;22:1871–88.
- Steimle V, Siegrist C, Mottet A, et al. Regulation of MHC class II expression by interferon-gamma mediated by the transactivator gene CIITA. *Science* 1994;265:106–9.
- Salajegheh M, Kong SW, Pinkus JL, et al. Interferon-stimulated gene 15 (ISG15) conjugates proteins in dermatomyositis muscle with perifascicular atrophy. *Ann Neurol* 2010;67:53–63.
- Bilgic H, Ytterberg SR, Amin S, et al. Interleukin-6 and type I interferon-regulated genes and chemokines mark disease activity in dermatomyositis. *Arthritis Rheum* 2009;60:3436–46.

14. Arshanapalli A, Shah M, Veerula V, *et al.* The role of type I interferons and other cytokines in dermatomyositis. *Cytokine* 2015;73:319–25.
15. Meyer A, Laverny G, Allenbach Y, *et al.* IFN- β -induced reactive oxygen species and mitochondrial damage contribute to muscle impairment and inflammation maintenance in dermatomyositis. *Acta Neuropathol* 2017;134:655–66.
16. Qian J, Wang C, Wang B, *et al.* The IFN- γ /PD-L1 axis between T cells and tumor microenvironment: hints for glioma anti-PD-1/PD-L1 therapy. *J Neuroinflammation* 2018;15.
17. Englund P, Lindroos E, Nennesmo I, *et al.* Skeletal muscle fibers express major histocompatibility complex class II antigens independently of inflammatory infiltrates in inflammatory myopathies. *Am J Pathol* 2001;159:1263–73.
18. Das L, Blumbergs PC, Manavis J, *et al.* Major histocompatibility complex class I and II expression in idiopathic inflammatory myopathy. *Appl Immunohistochem Mol Morphol AIMM* 2013;21:539–42.
19. Bergua C, Chiavelli H, Allenbach Y, *et al.* *In vivo* pathogenicity of IgG from patients with anti-SRP or anti-HMGCR autoantibodies in immune-mediated necrotising myopathy. *Ann Rheum Dis* 2018. doi: 10.1136/annrheumdis-2018-213518. [Epub ahead of print 11 Oct 2018].
20. Schoenborn JR, Wilson CB. Regulation of interferon- γ during innate and adaptive immune responses. *Advances in immunology*. Elsevier, 2007: 41–101.
21. Hervier B, Perez M, Allenbach Y, *et al.* Involvement of NK Cells and NKp30 Pathway in Antisynthetase Syndrome. *J Immunol* 2016;197:1621–30.
22. Schleinitz N, Cognet C, Guia S, *et al.* Expression of the CD85j (leukocyte Ig-like receptor 1, Ig-like transcript 2) receptor for class I major histocompatibility complex molecules in idiopathic inflammatory myopathies. *Arthritis Rheum* 2008;58:3216–23.
23. Ivanidze J, Hoffmann R, Lochmüller H, *et al.* Inclusion Body Myositis. *Am J Pathol* 2011;179:1347–59.
24. Londhe P, Davie JK. Interferon- γ resets muscle cell fate by stimulating the sequential recruitment of JARID2 and PRC2 to promoters to repress myogenesis. *Sci Signal* 2013;6:ra107.
25. Ducreux J, Houssiau FA, Vandepapelière P, *et al.* Interferon α kinoid induces neutralizing anti-interferon α antibodies that decrease the expression of interferon-induced and B cell activation associated transcripts: analysis of extended follow-up data from the interferon α kinoid phase I/II study. *Rheumatology* 2016;55:1901–5.
26. Chen P, Vu T, Narayanan A, *et al.* Pharmacokinetic and pharmacodynamic relationship of AMG 811, An Anti-IFN- γ IgG1 monoclonal antibody, in patients with systemic lupus erythematosus. *Pharm Res* 2015;32:640–53.