



**HAL**  
open science

## **Role of near-infrared fluorescence imaging in head and neck cancer surgery: from animal models to humans**

Ihab Atallah, Clément Milet, Jean-Luc Coll, Emile P. Reyt, Christian Adrien Righini, Amandine Hurbin

### ► **To cite this version:**

Ihab Atallah, Clément Milet, Jean-Luc Coll, Emile P. Reyt, Christian Adrien Righini, et al.. Role of near-infrared fluorescence imaging in head and neck cancer surgery: from animal models to humans. *European Archives of Oto-Rhino-Laryngology*, 2015, 272 (10), pp.2593-2600. <10.1007/s00405-014-3224-y>. <hal-02349428>

**HAL Id: hal-02349428**

**<https://hal.science/hal-02349428v1>**

Submitted on 8 Nov 2019

**HAL** is a multi-disciplinary open access archive for the deposit and dissemination of scientific research documents, whether they are published or not. The documents may come from teaching and research institutions in France or abroad, or from public or private research centers.

L'archive ouverte pluridisciplinaire **HAL**, est destinée au dépôt et à la diffusion de documents scientifiques de niveau recherche, publiés ou non, émanant des établissements d'enseignement et de recherche français ou étrangers, des laboratoires publics ou privés.



HAL Authorization

# European Archives of Oto-Rhino-Laryngology and Head & Neck

## ROLE OF NEAR-INFRARED FLUORESCENCE IMAGING IN HEAD AND NECK CANCER SURGERY: FROM ANIMAL MODELS TO HUMANS

--Manuscript Draft--

<b>Manuscript Number:</b>	EAOR-D-14-00616R1
<b>Full Title:</b>	ROLE OF NEAR-INFRARED FLUORESCENCE IMAGING IN HEAD AND NECK CANCER SURGERY: FROM ANIMAL MODELS TO HUMANS
<b>Article Type:</b>	Review Article (Original Article)
<b>Keywords:</b>	head and neck cancer; near-infrared fluorescence imaging; surgical margin; sentinel lymph nodes; fluorescent probes; orthotopic animal models
<b>Corresponding Author:</b>	Ihab Atallah, MD-MSc  FRANCE
<b>Corresponding Author Secondary Information:</b>	
<b>Corresponding Author's Institution:</b>	
<b>Corresponding Author's Secondary Institution:</b>	
<b>First Author:</b>	Ihab Atallah, MD-MSc
<b>First Author Secondary Information:</b>	
<b>Order of Authors:</b>	Ihab Atallah, MD-MSc Clément Milet Jean-Luc Coll, PhD Emile Reyt, MD Christian Adrien Righini, MD-PhD Hurbin Amandine, PhD
<b>Order of Authors Secondary Information:</b>	
<b>Abstract:</b>	<p>Complete resection of head and neck cancers with negative surgical margins improves the prognosis of the disease and decreases the recurrence rate. Near-infrared fluorescence-guided surgery of head and neck cancer is a rapidly evolving field that represents an invaluable tool for tumour detection and resection.</p> <p>Here, we present a literature review of the principles of near-infrared fluorescence imaging and its use in head and neck cancer surgery. We discuss important studies in both animal models and humans that have been carried out up to this point. We also outline the important fluorescent molecules and devices used in head and neck fluorescence imaging-guided surgery.</p> <p>Although near-infrared fluorescence-guided surgery for head and neck cancers showed efficacy in animal models, its use in humans is limited by the small number of fluorescent probes that are approved for clinical use. However, it is considered as a novel surgical aid that helps delineate tumour margins preoperatively and could spare patients from the added morbidity that is associated with additional surgery or chemoradiation. In addition, it is a useful tool to detect sentinel lymph nodes as well as metastatic lymph nodes.</p>

**Professor Christian Adrien Righini**

Otolaryngology- Head and Neck Surgery Department  
Grenoble University Hospital  
BP 217

Albert Bonniot Institute  
CRI INSERM/UJF U823  
BP 170

38042 Grenoble Cedex 9

Tel.: +33 (0) 4 76 76 56 16  
Fax: +33 (0) 4 76 76 51 20  
Mail: IAtallah@chu-grenoble.fr

July 09, 2014

**RE: Resubmission of a manuscript about the role of the near-infrared fluorescence imaging in head and neck cancer surgery**

Dear Editor:

It gives us great pleasure to resubmit to your journal our revised manuscript about the role of the near infrared fluorescence imaging in head and neck cancer surgery: from animal models to humans. We took into consideration all the modifications that we were asked to do.

**We would like to thank the first reviewer for his valuable comments. In reply to him:**

For his comment: « *1)The references are mentioned both as [1], [2], etc and also as an apostrophe which is something confusing and not understandable why two different methods are used to depict the references in one text. This should be corrected. »*

- The citation of references in the text was corrected.

For his comment: « *2) In the legend of Figure 2 it is mentioned NIR, i believe it is mentioned to Near Infrared, please explain the Abbreviation »*

- The abbreviation was explained in the figure legend.

**We would like also to thank the second reviewer for his valuable comments. In reply to him:**

For his comment: « *1. In a review of a new technique one would need to have some speculation how to compare this technique to the existing ones. There are few words considering autofluorescence, but nothing else. How about Lugol-staining, narrow band imaging and others? »*

- We cited the existing imaging techniques for head and neck cancer detection (red font colour) in the section of the principles of in vivo near-infrared fluorescence imaging. These techniques were compared to the role the exogenous near-infrared induced fluorescence in the management of head and neck cancer.

For his comment: «2. In the principles the authors mention that the maximum depth of the detection is usually no more than 1cm. Yet this is claimed to be an alternative method for sentinel node detection. One picture shows sentinel node, but that neck is already opened. This needs to be clarified well. Is it possible to really see before incision all the 2 possible sentinel nodes in the neck like when using technetium-nanocolloid? How does this happen technically? »

- We explained in the last section of the manuscript (red font colour) the advantage and disadvantages of the sentinel lymph node detection using the near infrared fluorescent imaging. We explained that in the concerned study, the sentinel lymph node was only detectable after exposure of the neck structures following subplatysmal flap elevation, which is considered as a limiting factor for the near-infrared fluorescence imaging in comparison to radioactive tracers that can detect sentinel lymph node preoperatively. We mentioned in the manuscript that we think that the relatively low depth sensitivity of the current generation of near infrared imaging systems should be improved in the near future.

For his comment: « 3. In the figure legend there is fluorescent agent Angiostamp mentioned. What does it contain? ICG? Something else? »

- We described in the figure 1 legend (red font colour) the structure of the commercial fluorescent agent Angiostamp and we explained that it targets  $\alpha v\beta 3$  integrin.

For his comment: «4. Histological pictures should be of better quality. 10 x magnification is a bit low to detect all the variations mentioned in the figure legend. And I didn't find an asterisk in figure 1h. »

- We included histological pictures of better quality and made the asterisk in figure 1h clearer.

Our manuscript is a literature review of the near-infrared fluorescent imaging principles and applications in head and neck cancer surgery. We discuss the most important studies in animal models and in humans that were carried out till present. We also outline the most important fluorescent molecules and devices used in head and neck fluorescence imaging guided surgery.

We believe that our manuscript will make an important contribution to the medical and scientific literature. We chose *European Archives of Oto-Rhino-Laryngology* to submit our manuscript because it is a leading journal in both clinical and laboratory-based research on all aspects of head and neck tumours with a broad international readership.

We certify that all authors have seen and approved the manuscript, contributed significantly to the work, and also that the manuscript has not been previously published nor is not being considered for publication elsewhere. We also certify that no writing assistance other than copy editing was provided in the preparation of the manuscript. All authors declare that there is no any conflict of interest.

We hope that our manuscript will be found worthy of publication in *European Archives of Oto-Rhino-Laryngology* and we are confident that this manuscript, when accepted, will be widely and frequently cited for many years.

Sincerely,

**Christian Adrien Righini, MD-PhD**

## **ROLE OF NEAR-INFRARED FLUORESCENCE IMAGING IN HEAD AND NECK CANCER SURGERY: FROM ANIMAL MODELS TO HUMANS**

**Authors:** Ihab Atallah, MD-PhD<sup>1-3</sup>; Clément Milet<sup>1,2</sup>; Jean-Luc Coll, PhD<sup>1,2</sup>; Emile Reyt, MD<sup>2,3</sup>; Christian Adrien Righini, MD-PhD<sup>1-3</sup>\*; Amandine Hurbin PhD<sup>1,2</sup>\*

\*These authors contributed equally to this work

### **Affiliation of authors:**

1. INSERM U823, BP170, 38042 Grenoble Cedex 9, France
2. Joseph Fourier University, 621 Avenue Centrale, 38041 Saint-Martin-d'Hères, France
3. Grenoble University Hospital, Cs 10217, 38043 Grenoble Cedex 9, France

### **E-mail addresses of authors:**

Ihab Atallah: IAtallah@chu-grenoble.fr

Clément Millet: clement.milet@gmail.com

Jean-Luc Coll: jean-luc.coll@ujf-grenoble.fr

Emile Reyt: EReyt@chu-grenoble.fr

Christian Adrien Righini: CRighini@chu-grenoble.fr

Amandine Hurbin: amandine.hurbin@ujf-grenoble.fr

### **Corresponding Author:**

Dr. Ihab Atallah

Albert Bonniot Institute

CRI INSERM/UJF U823 , BP170

38042 Grenoble Cedex 9, FRANCE

Tel.: +33 (0) 6 13 74 30 13 Fax: +33 (0) 4 76 54 94 54

E-Mail: IAtallah@chu-grenoble.fr

**Conflicts of interest:** The authors declare that they have no conflict of interest.

### **Acknowledgment:**

This work was supported by Groupe Pasteur Mutualité and the Société Française d'ORL. Authors declare that they have no financial relationship with these organizations.

## ROLE OF NEAR-INFRARED FLUORESCENCE IMAGING IN HEAD AND NECK CANCER SURGERY: FROM ANIMAL MODELS TO HUMANS

Dear Editor:

It gives us great pleasure to resubmit to your journal our revised manuscript about the role of the near infrared fluorescence imaging in head and neck cancer surgery: from animal models to humans. We took into consideration all the modifications that we were asked to do.

### **We would like to thank the first reviewer for his valuable comments. In reply to him:**

For his comment: « 1) The references are mentioned both as [1], [2], etc and also as an apostrophe which is something confusing and not understandable why two different methods are used to depict the references in one text. This should be corrected. »

- The citation of references in the text was corrected.

For his comment: « 2) In the legend of Figure 2 it is mentioned NIR, I believe it is mentioned to Near Infrared, please explain the Abbreviation »

- The abbreviation was explained in the figure legend.

### **We would like also to thank the second reviewer for his valuable comments. In reply to him:**

For his comment: « 1. In a review of a new technique one would need to have some speculation how to compare this technique to the existing ones. There are few words considering autofluorescence, but nothing else. How about Lugol-staining, narrow band imaging and others? »

- We cited the existing imaging techniques for head and neck cancer detection (red font colour) in the section of the principles of in vivo near-infrared fluorescence imaging. These techniques were compared to the role the exogenous near-infrared induced fluorescence in the management of head and neck cancer.

For his comment: « 2. In the principles the authors mention that the maximum depth of the detection is usually no more than 1cm. Yet this is claimed to be an alternative method for sentinel node detection. One picture shows sentinel node, but that neck is already opened. This needs to be clarified well. Is it possible to really see before incision all the 2 possible sentinel nodes in the neck like when using technetium-nanocolloid? How does this happen technically? »

- We explained in the last section of the manuscript (red font colour) the advantage and disadvantages of the sentinel lymph node detection using the near infrared fluorescent imaging. We explained that in the concerned study, the sentinel lymph node was only detectable after exposure of the neck structures following subplatysmal flap elevation, which is considered as a limiting factor for the near-infrared fluorescence imaging in comparison to radioactive tracers that can detect sentinel lymph node preoperatively. We mentioned in the manuscript that we think that the relatively low depth sensitivity of the current generation of near infrared imaging systems should be improved in the near future.

For his comment: « 3. In the figure legend there is fluorescent agent Angiostamp mentioned. What does it contain? ICG? Something else? »

- We described in the figure 1 legend (red font colour) the structure of the commercial fluorescent agent Angiostamp and we explained that it targets  $\alpha v \beta 3$  integrin.

For his comment: « 4. Histological pictures should be of better quality. 10 x magnification is a bit low to detect all the variations mentioned in the figure legend. And I didn't find an asterisk in figure 1h. »

- We included histological pictures of better quality and made the asterisk in figure 1h clearer.

### **All changes in the manuscript are shown in red**

Sincerely,

The Authors

## **Abstract**

Complete resection of head and neck cancers with negative surgical margins improves the prognosis of the disease and decreases the recurrence rate. Near-infrared fluorescence-guided surgery of head and neck cancer is a rapidly evolving field that represents an invaluable tool for tumour detection and resection.

Here, we present a literature review of the principles of near-infrared fluorescence imaging and its use in head and neck cancer surgery. We discuss important studies in both animal models and humans that have been carried out up to this point. We also outline the important fluorescent molecules and devices used in head and neck fluorescence imaging-guided surgery.

Although near-infrared fluorescence-guided surgery for head and neck cancers showed efficacy in animal models, its use in humans is limited by the small number of fluorescent probes that are approved for clinical use. However, it is considered as a novel surgical aid that helps delineate tumour margins preoperatively and could spare patients from the added morbidity that is associated with additional surgery or chemoradiation. In addition, it is a useful tool to detect sentinel lymph nodes as well as metastatic lymph nodes.

### **Keywords:**

Head and neck cancer; near-infrared fluorescence imaging; surgical margin; sentinel lymph nodes; fluorescent probes; indocyanine green; orthotopic animal models

## Introduction

Worldwide, there are 600,000 new cases of head and neck cancer and 300,000 deaths each year [1]. Surgery is considered one of the main treatments for head and neck cancers and it has the best overall survival rate compared to radiotherapy and chemotherapy. Complete resection of the tumour tissue, detection of lymph nodes metastases and preservation of healthy tissue during head and neck cancer surgery are major issues that strongly influence the patient prognosis. Additionally, these factors affect the functional and physiological integrity of the head and neck region with considerable impacts on multiple facets of patient life [2].

The development of near-infrared optical fluorescent techniques for diagnosis, treatment and follow-up of head and neck cancer is a growing field that provides real-time information regarding the presence, location and dimensions of the cancer tissue and/or metastasis through creation of a specific contrast between normal and cancer tissue. This contrast could be the result of tumour-induced morphologic and biochemical alterations that alter optical properties of tissues and lead to tumor-specific auto-fluorescence [3]. Furthermore, fluorescence can be achieved through targeting head and neck tumours by fluorescent probes that bind to specific receptors on cancer cells.

Orthotopic xenograft animal models were used to test novel applications of near-infrared fluorescence imaging-guided surgery for head and neck cancers. Multiple studies were also performed in humans to evaluate the role of near-infrared fluorescence imaging guided surgery for head and neck tumours detection and resection. Several different fluorescent probes have been proposed to target head and neck cancers cells in animal models using near-infrared fluorescent imaging. For clinical translation of these results, however, very expensive and long lasting safety and reglementary issues should be addressed for each probe. Here, we present an overview of the use of near-infrared fluorescence imaging in head and neck cancer surgery in animal models and its clinical applications in humans. We also outline the most important fluorescent molecules and devices used in head and neck fluorescence imaging-guided surgery.

## Principles of in vivo near-infrared fluorescence imaging

Fluorescence is a process by which molecules absorb the excitation light and re-emit light of a longer wavelength after a brief interval of time. Light is produced from a spectrally resolved light source such as filtered broadband source, light-emitting diode, or laser diode. The light emitted from the excited fluorophore is then captured by a charge-coupled device camera, with special care taken to filter the huge excess of photons coming from the excitation light. Near-infrared fluorescence imaging focuses on the detection of exogenous contrast agents that emit fluorescence between 700 and 900 nm. Because light is poorly absorbed by living tissues in this spectral window, near-infrared imaging can provide real time detection of exogenous fluorescence contrast agents at depths that usually do not exceed 1 cm [4-5]. In parallel, endogenous fluorescence (autofluorescence) imaging can also be of interest. In fact, variations in the levels and depth of endogenous fluorophores can be present in cancer-induced biochemical changes, such as increases in NADH, decreases in FAD concentration, and altered elastin and keratin compositions. It can be also related to the shielding of the autofluorescence of the extracellular matrix that occurs during the thickening of epithelial tissues, which occurs during tumour development. Consequently, autofluorescence profiles are of specific interest because changes in metabolic activity and cellular interactions could be reflected by spectral alteration in the fluorescence signal [6-7]. In addition to autofluorescence, narrow band imaging (NBI) which is based on a modification of the standard white light spectrum by optical filters that narrow the bandwidth of transmitted light through an endoscope giving a blue light that penetrates less deeply into tissue, gives the operator a good resolution of superficial structures like submucosal vessels that could show an abnormal vasculature in early cancerous lesions [8-9]. Finally, other imaging techniques like lugol chromoendoscopy, confocal endoscopy, and endocytology have been reported to be useful for detection of early-stage head and neck squamous cell carcinoma [10]. However, these imaging techniques with autofluorescence and NBI are mainly used to guide biopsies and to detect suspicious precancerous lesions, whereas exogenous near-infrared induced fluorescence is used in tumour resection and metastasis detection [3,11-12].

## Head and neck cancer near-infrared fluorescent contrast agents

Multiple strategies have been proposed for head and neck fluorescence imaging-guided surgery. For clinical translation of these strategies, pharmacokinetic studies must be performed for each fluorophore or fluorophore conjugate that targets specific receptors in cancer tissue. Indocyanine green (ICG) was one of the first fluorescent dyes tested for fluorescence imaging-guided surgery. ICG is an untargeted dye that clears from the

tumour at a different rate than from the surrounding tissue. Because of its passive lymphatic drainage, and of its passive diffusion after extravasation, ICG has already shown promise for sentinel lymph node detection by passive targeting through its enhanced permeability and retention effect. However, its value for delineation of head and neck tumour margins is limited because it is considered as a blood pool agent that is not inherently specific for any tumour receptor [5,13-17]. For these reasons, a targeted probe would provide real-time, intra-operative distinction of the molecular edge between cancer and adjacent normal tissue. The benefit would be to potentially decreasing the incidence of a positive surgical tumour margin.

For clinical translation, an optimal targeted fluorescent probe should have good distribution, high affinity towards its target and a fast clearance from the bloodstream, to allow efficient accumulation at the tumour and rapid acquisition of images with high contrast [5,12-13]. One of the most important targets of fluorescent probes is EGFR (Epidermal Growth Factor Receptor) which is overexpressed in 80–90% of head and neck squamous cell carcinoma cases [18]. The Cetuximab antibody labelled with a near-infrared fluorophore is commonly used in head and neck fluorescence imaging-guided surgery. It is a recombinant, human/mouse chimeric monoclonal antibody that binds specifically to the extracellular domain of the human EGFR and is widely used in the treatment of head and neck squamous cell carcinoma, combined with other chemotherapeutic agents [19,18]. Panitumumab is another probe that targets EGFR. It is a recombinant, fully humanized monoclonal antibody that has the advantage of presenting lower risk of eliciting an immune response in humans than Cetuximab [19-20]. EGFR antibodies have also been conjugated with quantum dots, which are semiconductor nanocrystals (diameter 1–10 nm). When coupled with fluorophores, quantum dots present the advantage of producing near-infrared fluorescence with strong tissue penetrating ability, low absorbance by in vivo tissue, high light stability, high fluorescence quantum yield and minimal interference from normal tissue autofluorescence, but they cannot be used for human applications because of their chemical composition [20-21]. Panitumumab and Cetuximab are conventional antibodies that show slow blood clearance, high accumulation in the liver and limited tumour penetration. Consequently, nanobodies, which are smaller functional antigen-binding fragments (15 kDa) derived from heavy chain antibodies, have been explored. They show highly specific binding to EGFR and ensure efficient distribution and tissue penetration, as well as rapid clearance from the body. When combined with fluorophores, they retain the ability to delineate head and neck tumours and lymph node metastases in head and neck cancer fluorescence imaging-guided surgery [12,22]. Finally, EGFR can be targeted by fluorophore-labeled recombinant human EGF, but this presents the risk of EGFR receptor activation that promotes the malignant phenotype [23].

Another target for fluorescent probes used in head and neck cancer fluorescence imaging-guided surgery, is  $\alpha v\beta 3$  integrin, which plays an important role in cancer-associated angiogenesis, cell proliferation, migration and metastasis. It is widely expressed on neoendothelial cells and in some tumours including head and neck squamous cell carcinoma [24-26]. RAFT-c(-RGDFK-)<sub>4</sub> (regioselectively addressable functionalized template-arginine-glycine-aspartic acid) is a peptide-like scaffold that holds four cyclo(-RGDFK-) (cRGD) motifs. It was shown that this molecule targets  $\alpha v\beta 3$  integrin in vitro and in vivo and could be coupled with multiple fluorophores [27-32]. Like EGFR antibodies, RGD could also be coupled with quantum dots as an alternative way to target  $\alpha v\beta 3$  integrin in head and neck cancer fluorescence imaging-guided surgery [21].

Finally, other probes showed interesting results in head and neck cancer targeting such as fluorescent deoxyglucose probes that detect increased glucose uptake by the glucose transporter 1 (GLUT-1), which shows upregulation in head and neck cancer [23,33]. VEGF was also a target of fluorescent probes comprising bevacizumab, which is an anti-VEGF antibody, that was conjugated to optically active fluorophores and resulted in adequate disease detection in the surgical setting [34]. Lastly, transferrin receptor, which is overexpressed in head and neck squamous cell carcinoma, was targeted using a near-infrared fluorescent transferrin conjugate that was able to identify and delineate head and neck tumours in mice [35].

Although head and neck cancer-specific targeting remains a challenge, numerous commercial near-infrared fluorophores exist. They are largely based on the cyanine chemical structure with specific modifications by each manufacturer. Porphyrins, squaraine, boron dipyrromethane, benzo[c]heterocycles and xanthenes are also known classes of near-infrared fluorophores. Fluorophores can be readily conjugated to a protein or ligand of interest for specific in vivo targeting through conjugation at a lysine residue or N-terminal [5,13,36].

### **Imaging systems used in head and neck cancer fluorescence-guided surgery**

In addition to fluorescent contrast agents, a suitable camera system has to be developed for each application. Several near-infrared fluorescence imaging devices are now available for pre-clinical and clinical studies of head and neck fluorescence imaging-guided surgery. The FLARE™ (Frangioni Lab, Beth Israel Deaconess Medical

Center, MA, USA) imaging system was used in animal studies, and the Mini-FLARE™ system, which is an optimized version for clinical studies, was used to guide sentinel lymph nodes fluorescent detection [12,17]. The Photodynamic Eye camera system (Hamamatsu, Germany) also showed the ability to detect lymph drainage pattern and sentinel lymph nodes in humans [15]. The HyperEye Medical System (Mizuho Medical Co, Ltd, Tokyo, Japan) has been used in fluorescent tumour delineation in humans after systemic administration of ICG, but no histological studies were performed on tumour margins [37]. SPY imaging system (Novadaq, Ontario, Canada) is another device used to image and guide head and neck cancer resection in orthotopic animal models [21-22]. Finally, the FluoSTIC preclinical device and the promising novel commercial fluorescence imaging system version, Fluostick™ (FluoOptics, Grenoble, France), are hand-held near-infrared cameras that have been miniaturized and optimized for oral oncologic procedures in humans [4].

### **Use of near-infrared fluorescence imaging in head and neck cancer surgery in animal models**

Like any novel treatment, head and neck cancer near-infrared fluorescence imaging-guided surgery was first tested in animals before humans. Mice were the animal of choice to test this novel surgical aid because they are small in size, easy to handle and relatively inexpensive. Athymic nude mice were most commonly used because they are considered a suitable host for the development of implanted human head neck cancer cells. In addition, their hairlessness decreases the attenuation of the fluorescence signal emission [38]. Multiple subcutaneous and orthotopic mouse models of head and neck cancer were developed. The advantage of orthotopic models is that they provide specific interactions between cancer cells and their native environment. This can consequently influence molecular, pathologic and clinical features of orthotopic tumours that become representative of human head and neck tumours [39-41].

Near-infrared fluorescence imaging-guided surgery showed promising results for intraoperative fluorescence demarcation of head and neck tumours in both orthotopic and subcutaneous cell line xenografts. Tumor resections were performed under real-time guidance of fluorescence imaging, and there was an adequate correlation between the fluorescence signal and tumour extension on analysis of histological sections [42-43,12,44,34,19,45,23]. Moreover, near-infrared fluorescence imaging in the surgical bed helped to identify fluorescent cancer residues that could remain unidentified if resection was performed exclusively under visual guidance. This had a positive impact on the recurrence-free survival rate of mice in comparison with mice that underwent tumour resection without any aid of fluorescence imaging (figure 1) (Atallah et al., submitted). Furthermore, the use of optical imaging for detection of cervical lymph node metastases showed important value in orthotopic mouse models in which squamous cell carcinoma metastases were found on histological sections in all cervical lymph nodes that showed a fluorescence signal [12,19,23,42-44]. In addition, no tumour was found in the negative lymph nodes on haematoxylin–eosin or immunohistochemical staining analysis [23]. Lastly, fluorescence imaging was used to detect distant pulmonary head and neck squamous cell carcinoma metastases. This could be considered an important tool in the management of head and neck cancers because distant metastasis is a contraindication to surgical therapy [19].

### **Current practice and perspectives of near-infrared fluorescence imaging use in head and neck cancer surgery in humans**

One of the first applications of head and neck cancer near-infrared fluorescence imaging-guided surgery in humans was sentinel lymph node biopsy after peri-tumoural injection of unconjugated ICG. This showed results that are equivalent to radioactive tracers, without the disadvantages of the lack of real-time intraoperative visual information and the need for a nuclear physician [15-16,46]. Moreover, premixing ICG with human serum albumin (HSA) to generate ICG:HSA complexes improved the fluorescent properties and retention in the sentinel lymph node owing to an increased hydrodynamic diameter (figure 2) [17,47]. **However, sentinel lymph node was only detectable after exposure of the neck structures following subplatysmal flap elevation, which is considered as a limiting factor for the near-infrared fluorescence imaging in comparison to radioactive tracers that can detect sentinel lymph node preoperatively. We think that the relatively low depth sensitivity of the current generation of near infrared imaging systems should be improved in the near future.** ICG was also used to delineate head and neck tumours and lymph node metastases in humans 30 to 60 minutes after intravenous administration [37]. All tumours and lymphatic metastases displayed bright fluorescence emissions that clearly contrasted with the normal structures. Fluorescence imaging was very useful to detect metastatic lymph nodes that were not palpable, and not visible macroscopically, in the retropharyngeal space [37]. Precautions have to be taken in tumour margin demarcation using ICG because accumulation of ICG may not be limited to cancerous tissues. In fact, ICG would also be expected to accumulate in inflammatory tissues and areas of surgical trauma that could partly hamper specificity in the initial phase of enhanced permeability and retention effect. However, these effects occur at much lower levels and retention in tumours is greatly increased owing to defective

architecture of lymphatic drainage [48-49]. Autofluorescence has also been used to define tumour margins, but the study was performed on punch biopsies of several sites from ex vivo human specimens. Sensitivity and specificity of the discrimination of normal tissue from cancerous tissue were evaluated by correlating histopathologic diagnosis with visual impression and were 91% and 86%, respectively [6].

The use of head and neck cancer near-infrared fluorescence imaging-guided surgery in humans is limited by the small number of fluorescent probes that are approved for clinical use. Although ICG is considered a blood pool agent that is not inherently specific for any tumour, it is the only near-infrared fluorescent agent that has been used in clinical applications of head and neck cancer surgery because it is EMA (European Medicines Agency) and FDA (US Food and Drug Administration) approved as a near-infrared fluorescent contrast agent. Pharmacokinetics, pharmacodynamics and clinical toxicity studies have to be performed to analyze additional fluorescent probes that have shown efficient targeting of head and neck cancers in animal models. Owing to the complexity of the clinical translation process, we believe that repurposing of fluorescent molecules such as ICG and specific head and neck cancer-targeting probes such as anti-EGFR antibodies, which are already approved for clinical use, is a safe and cost-efficient way to develop new clinically approved fluorescent probes. In addition, more fluorescence imaging devices optimized for both open and endoscopic head and neck cancer surgery have to be developed.

## Conclusion

Technological developments of near-infrared fluorescence imaging-guided cancer surgery have led to promising preclinical and clinical results. In head and neck cancer surgery, it is considered an invaluable tool to delineate tumours and to detect metastasis in animal models because of the real-time feedback and the contrast that it offers. In humans, it also showed encouraging results, but further development depends on the regulatory approval of near-infrared optical devices and fluorescent targeted probes for clinical use. It will certainly lead to significant improvements in the surgical techniques regarding optimization of tumour margins, detection of residual disease and identification of lymph node metastases.

## References

1. Mehanna H, Paleri V, West CM, Nutting C (2011) Head and neck cancer-part 1: epidemiology, presentation, and preservation. *Clin Otolaryngol* 36 (1):65-68. doi:10.1111/j.1749-4486.2010.02231.x
2. Payakachat N, Ounpraseuth S, Suen JY (2013) Late complications and long-term quality of life for survivors (>5 years) with history of head and neck cancer. *Head Neck* 35 (6):819-825. doi:10.1002/hed.23035
3. Swinson B, Jerjes W, El-Maaytah M, Norris P, Hopper C (2006) Optical techniques in diagnosis of head and neck malignancy. *Oral Oncol* 42 (3):221-228. doi:S1368-8375(05)00133-8 [pii] 10.1016/j.oraloncology.2005.05.001
4. Gioux S, Coutard JG, Berger M, Grateau H, Josserand V, Keramidis M, Righini C, Coll JL, Dinten JM (2012) FluoSTIC: miniaturized fluorescence image-guided surgery system. *J Biomed Opt* 17 (10):106014. doi:1378602 [pii] 10.1117/1.JBO.17.10.106014
5. Gioux S, Choi HS, Frangioni JV (2010) Image-guided surgery using invisible near-infrared light: fundamentals of clinical translation. *Mol Imaging* 9 (5):237-255
6. Svistun E, Alizadeh-Naderi R, El-Naggar A, Jacob R, Gillenwater A, Richards-Kortum R (2004) Vision enhancement system for detection of oral cavity neoplasia based on autofluorescence. *Head Neck* 26 (3):205-215. doi:10.1002/hed.10381
7. Poh CF, Ng SP, Williams PM, Zhang L, Laronde DM, Lane P, Macaulay C, Rosin MP (2007) Direct fluorescence visualization of clinically occult high-risk oral premalignant disease using a simple hand-held device. *Head Neck* 29 (1):71-76. doi:10.1002/hed.20468
8. Tan NC, Herd MK, Brennan PA, Puxeddu R (2012) The role of narrow band imaging in early detection of head and neck cancer. *Br J Oral Maxillofac Surg* 50 (2):132-136. doi:S0266-4356(10)00384-0 [pii] 10.1016/j.bjoms.2010.12.001
9. Muto M, Minashi K, Yano T, Saito Y, Oda I, Nonaka S, Omori T, Sugiura H, Goda K, Kaise M, Inoue H, Ishikawa H, Ochiai A, Shimoda T, Watanabe H, Tajiri H, Saito D (2010) Early detection of superficial squamous cell carcinoma in the head and neck region and esophagus by narrow band imaging: a multicenter randomized controlled trial. *J Clin Oncol* 28 (9):1566-1572. doi:JCO.2009.25.4680 [pii] 10.1200/JCO.2009.25.4680
10. Hori K, Okada H, Kawahara Y, Takenaka R, Shimizu S, Ohno Y, Onoda T, Sirakawa Y, Naomoto Y, Yamamoto K (2011) Lugol-voiding lesions are an important risk factor for a second primary squamous cell

- carcinoma in patients with esophageal cancer or head and neck cancer. *Am J Gastroenterol* 106 (5):858-866. doi:ajg2010489 [pii]  
10.1038/ajg.2010.489
11. Jayaprakash V, Sullivan M, Merzianu M, Rigual NR, Loree TR, Popat SR, Moysich KB, Ramananda S, Johnson T, Marshall JR, Hutson AD, Mang TS, Wilson BC, Gill SR, Frustino J, Bogaards A, Reid ME (2009) Autofluorescence-guided surveillance for oral cancer. *Cancer Prev Res (Phila)* 2 (11):966-974. doi:2/11/966 [pii]  
10.1158/1940-6207.CAPR-09-0062
12. van Driel PB, van der Vorst JR, Verbeek FP, Oliveira S, Snoeks TJ, Keereweer S, Frangioni JV, van Bergen En Henegouwen PM, Vahrmeijer AL, Lowik CW (2013) Intraoperative fluorescence delineation of head and neck cancer with a fluorescent anti-epidermal growth factor receptor nanobody. *Int J Cancer*. doi:10.1002/ijc.28601
13. Gibbs SL (2012) Near infrared fluorescence for image-guided surgery. *Quant Imaging Med Surg* 2 (3):177-187. doi:10.3978/j.issn.2223-4292.2012.09.04  
qims-02-03-177 [pii]
14. Hussain T, Nguyen QT (2013) Molecular imaging for cancer diagnosis and surgery. *Adv Drug Deliv Rev*. doi:S0169-409X(13)00203-2 [pii]  
10.1016/j.addr.2013.09.007
15. Bredell MG (2010) Sentinel lymph node mapping by indocyanin green fluorescence imaging in oropharyngeal cancer - preliminary experience. *Head Neck Oncol* 2:31. doi:1758-3284-2-31 [pii]  
10.1186/1758-3284-2-31
16. Nakamura Y, Fujisawa Y, Maruyama H, Furuta J, Kawachi Y, Otsuka F (2013) Improvement of the sentinel lymph node detection rate of cervical sentinel lymph node biopsy using real-time fluorescence navigation with indocyanine green in head and neck skin cancer. *J Dermatol* 40 (6):453-457. doi:10.1111/1346-8138.12158
17. van der Vorst JR, Schaafsma BE, Verbeek FP, Keereweer S, Jansen JC, van der Velden LA, Langeveld AP, Hutteman M, Lowik CW, van de Velde CJ, Frangioni JV, Vahrmeijer AL (2013) Near-infrared fluorescence sentinel lymph node mapping of the oral cavity in head and neck cancer patients. *Oral Oncol* 49 (1):15-19. doi:S1368-8375(12)00245-X [pii]  
10.1016/j.oraloncology.2012.07.017
18. Gleysteen JP, Duncan RD, Magnuson JS, Skipper JB, Zinn K, Rosenthal EL (2007) Fluorescently labeled cetuximab to evaluate head and neck cancer response to treatment. *Cancer Biol Ther* 6 (8):1181-1185. doi:4379 [pii]
19. Gleysteen JP, Newman JR, Chhieng D, Frost A, Zinn KR, Rosenthal EL (2008) Fluorescent labeled anti-EGFR antibody for identification of regional and distant metastasis in a preclinical xenograft model. *Head Neck* 30 (6):782-789. doi:10.1002/hed.20782
20. Yang K, Zhao C, Cao YA, Tang H, Bai YL, Huang H, Zhao CR, Chen R, Zhao D (2012) In vivo and in situ imaging of head and neck squamous cell carcinoma using near-infrared fluorescent quantum dot probes conjugated with epidermal growth factor receptor monoclonal antibodies in mice. *Oncol Rep* 27 (6):1925-1931. doi:10.3892/or.2012.1705
21. Huang H, Bai YL, Yang K, Tang H, Wang YW (2013) Optical imaging of head and neck squamous cell carcinoma in vivo using arginine-glycine-aspartic acid peptide conjugated near-infrared quantum dots. *Oncotargets Ther* 6:1779-1787. doi:10.2147/OTT.S53901  
ott-6-1779 [pii]
22. Oliveira S, van Dongen GA, Stigter-van Walsum M, Roovers RC, Stam JC, Mali W, van Diest PJ, van Bergen en Henegouwen PM (2012) Rapid visualization of human tumor xenografts through optical imaging with a near-infrared fluorescent anti-epidermal growth factor receptor nanobody. *Mol Imaging* 11 (1):33-46
23. Keereweer S, Kerrebijn JD, Mol IM, Mieog JS, Van Driel PB, Baatenburg de Jong RJ, Vahrmeijer AL, Lowik CW (2012) Optical imaging of oral squamous cell carcinoma and cervical lymph node metastasis. *Head Neck* 34 (7):1002-1008. doi:10.1002/hed.21861
24. Fabricius EM, Wildner GP, Kruse-Boitschenko U, Hoffmeister B, Goodman SL, Raguse JD (2011) Immunohistochemical analysis of integrins  $\alpha$ v $\beta$ 3,  $\alpha$ v $\beta$ 5 and  $\alpha$ 5 $\beta$ 1, and their ligands, fibrinogen, fibronectin, osteopontin and vitronectin, in frozen sections of human oral head and neck squamous cell carcinomas. *Exp Ther Med* 2 (1):9-19. doi:10.3892/etm.2010.171  
etm-02-01-0009 [pii]
25. Beer AJ, Grosu AL, Carlsen J, Kolk A, Sarbia M, Stangier I, Watzlowik P, Wester HJ, Haubner R, Schwaiger M (2007) [ $^{18}$ F]galacto-RGD positron emission tomography for imaging of  $\alpha$ v $\beta$ 3 expression on the neovasculature in patients with squamous cell carcinoma of the head and neck. *Clin Cancer Res* 13 (22 Pt 1):6610-6616. doi:13/22/6610 [pii]  
10.1158/1078-0432.CCR-07-0528

26. Li P, Liu F, Sun L, Zhao Z, Ding X, Shang D, Xu Z, Sun C (2011) Chemokine receptor 7 promotes cell migration and adhesion in metastatic squamous cell carcinoma of the head and neck by activating integrin  $\alpha$ v $\beta$ 3. *Int J Mol Med* 27 (5):679-687. doi:10.3892/ijmm.2011.628
27. Jin ZH, Josserand V, Razkin J, Garanger E, Boturn D, Favrot MC, Dumy P, Coll JL (2006) Noninvasive optical imaging of ovarian metastases using Cy5-labeled RAFT-c(-RGDFK)-4. *Mol Imaging* 5 (3):188-197
28. Jin ZH, Josserand V, Foillard S, Boturn D, Dumy P, Favrot MC, Coll JL (2007) In vivo optical imaging of integrin  $\alpha$ v $\beta$ 3 in mice using multivalent or monovalent cRGD targeting vectors. *Mol Cancer* 6:41. doi:1476-4598-6-41 [pii] 10.1186/1476-4598-6-41
29. Sancey L, Ardisson V, Riou LM, Ahmadi M, Marti-Battle D, Boturn D, Dumy P, Fagret D, Ghezzi C, Vuillez JP (2007) In vivo imaging of tumour angiogenesis in mice with the  $\alpha$ (v) $\beta$ 3 integrin-targeted tracer  $^{99m}\text{Tc}$ -RAFT-RGD. *Eur J Nucl Med Mol Imaging* 34 (12):2037-2047. doi:10.1007/s00259-007-0497-z
30. Garanger E, Boturn D, Jin Z, Dumy P, Favrot MC, Coll JL (2005) New multifunctional molecular conjugate vector for targeting, imaging, and therapy of tumors. *Mol Ther* 12 (6):1168-1175. doi:S1525-0016(05)00279-0 [pii] 10.1016/j.ymthe.2005.06.095
31. Wenk CH, Ponce F, Guillermet S, Tenaud C, Boturn D, Dumy P, Watrelot-Virieux D, Carozzo C, Josserand V, Coll JL (2013) Near-infrared optical guided surgery of highly infiltrative fibrosarcomas in cats using an anti- $\alpha$ v $\beta$ 3 integrin molecular probe. *Cancer Lett* 334 (2):188-195. doi:S0304-3835(12)00646-5 [pii] 10.1016/j.canlet.2012.10.041
32. Keramidis M, Josserand V, Righini CA, Wenk C, Faure C, Coll JL (2010) Intraoperative near-infrared image-guided surgery for peritoneal carcinomatosis in a preclinical experimental model. *Br J Surg* 97 (5):737-743. doi:10.1002/bjs.6986
33. Xie BW, Mol IM, Keereweer S, van Beek ER, Que I, Snoeks TJ, Chan A, Kaijzel EL, Lowik CW (2012) Dual-wavelength imaging of tumor progression by activatable and targeting near-infrared fluorescent probes in a bioluminescent breast cancer model. *PLoS One* 7 (2):e31875. doi:10.1371/journal.pone.0031875 PONE-D-11-16502 [pii]
34. Withrow KP, Newman JR, Skipper JB, Gleysteen JP, Magnuson JS, Zinn K, Rosenthal EL (2008) Assessment of bevacizumab conjugated to Cy5.5 for detection of head and neck cancer xenografts. *Technol Cancer Res Treat* 7 (1):61-66. doi:d=3032&c=4249&p=16390&do=detail [pii]
35. Shan L, Hao Y, Wang S, Korotcov A, Zhang R, Wang T, Califano J, Gu X, Sridhar R, Bhujwala ZM, Wang PC (2008) Visualizing head and neck tumors in vivo using near-infrared fluorescent transferrin conjugate. *Mol Imaging* 7 (1):42-49
36. Keereweer S, Sterenborg HJ, Kerrebijn JD, Van Driel PB, Baatenburg de Jong RJ, Lowik CW (2012) Image-guided surgery in head and neck cancer: current practice and future directions of optical imaging. *Head Neck* 34 (1):120-126. doi:10.1002/hed.21625
37. Yokoyama J, Fujimaki M, Ohba S, Anzai T, Yoshii R, Ito S, Kojima M, Ikeda K (2013) A feasibility study of NIR fluorescent image-guided surgery in head and neck cancer based on the assessment of optimum surgical time as revealed through dynamic imaging. *Onco Targets Ther* 6:325-330. doi:10.2147/OTT.S42006 ott-6-325 [pii]
38. Sharkey FE, Fogh J (1984) Considerations in the use of nude mice for cancer research. *Cancer Metastasis Rev* 3 (4):341-360
39. Kim S (2009) Animal models of cancer in the head and neck region. *Clin Exp Otorhinolaryngol* 2 (2):55-60. doi:10.3342/ceo.2009.2.2.55
40. Lu SL, Herrington H, Wang XJ (2006) Mouse models for human head and neck squamous cell carcinomas. *Head Neck* 28 (10):945-954. doi:10.1002/hed.20397
41. Cabanillas R, Secades P, Rodrigo JP, Astudillo A, Suarez C, Chiara MD (2005) [Orthotopic murine model of head and neck squamous cell carcinoma]. *Acta Otorrinolaringol Esp* 56 (3):89-95
42. Heath CH, Deep NL, Sweeny L, Zinn KR, Rosenthal EL (2012) Use of panitumumab-IRDye800 to image microscopic head and neck cancer in an orthotopic surgical model. *Ann Surg Oncol* 19 (12):3879-3887. doi:10.1245/s10434-012-2435-y
43. Day KE, Sweeny L, Kulbersh B, Zinn KR, Rosenthal EL (2013) Preclinical comparison of near-infrared-labeled cetuximab and panitumumab for optical imaging of head and neck squamous cell carcinoma. *Mol Imaging Biol* 15 (6):722-729. doi:10.1007/s11307-013-0652-9
44. Keereweer S, Mol IM, Kerrebijn JD, Van Driel PB, Xie B, Baatenburg de Jong RJ, Vahrmeijer AL, Lowik CW (2012) Targeting integrins and enhanced permeability and retention (EPR) effect for optical imaging of oral cancer. *J Surg Oncol* 105 (7):714-718. doi:10.1002/jso.22102

45. Rosenthal EL, Kulbersh BD, King T, Chaudhuri TR, Zinn KR (2007) Use of fluorescent labeled anti-epidermal growth factor receptor antibody to image head and neck squamous cell carcinoma xenografts. *Mol Cancer Ther* 6 (4):1230-1238. doi:6/4/1230 [pii] 10.1158/1535-7163.MCT-06-0741
46. Brouwer OR, Klop WM, Buckle T, Vermeeren L, van den Brekel MW, Balm AJ, Nieweg OE, Valdes Olmos RA, van Leeuwen FW (2012) Feasibility of sentinel node biopsy in head and neck melanoma using a hybrid radioactive and fluorescent tracer. *Ann Surg Oncol* 19 (6):1988-1994. doi:10.1245/s10434-011-2180-7
47. Ohnishi S, Lomnes SJ, Laurence RG, Gogbashian A, Mariani G, Frangioni JV (2005) Organic alternatives to quantum dots for intraoperative near-infrared fluorescent sentinel lymph node mapping. *Mol Imaging* 4 (3):172-181
48. Sandanaraj BS, Gremlich HU, Kneuer R, Dawson J, Wacha S (2010) Fluorescent nanoprobe as a biomarker for increased vascular permeability: implications in diagnosis and treatment of cancer and inflammation. *Bioconjug Chem* 21 (1):93-101. doi:10.1021/bc900311h
49. Maeda H (2010) Tumor-selective delivery of macromolecular drugs via the EPR effect: background and future prospects. *Bioconjug Chem* 21 (5):797-802. doi:10.1021/bc100070g

### Figure captions

**Fig. 1** Orthotopic tumour resection with the aid of a FluoStick™ Clinical System device after systemic injection of the AngioStamp™ 800 (Fluoptics, Grenoble, France). **This imaging agent is a tetravalent RGD-based peptide (RAFT-c(-RGDfK-)₄) that targets αβ3 integrin. It is labeled with a NIR organic fluorophore with an absorbance and an emission maxima of 781 nm and 794 nm respectively.** a) In vivo fluorescence imaging of the tumour. b) In vivo macroscopic appearance of the tumour. c) Ex vivo fluorescence imaging of the tumour after macroscopic resection without the aid of fluorescence imaging. d) Haematoxylin-eosin (H.E.) staining of the orthotopic tumour showing a moderately differentiated squamous cell carcinoma with disorganized architecture, hyperchromatic nuclei, pleomorphism, increased mitotic activity and a greatly altered nuclear-cytoplasmic ratio. Microscopic images were acquired under **20x** magnification. e) Surgical bed after macroscopic tumour resection showing no residual macroscopic disease. f) Fluorescence imaging of the surgical bed showing a fluorescent focus that was resected under fluorescence imaging guidance. g) Ex vivo fluorescence of the fluorescent residue. h) H.E. staining of the fluorescent residue revealed foci of squamous cell carcinoma (asterisks) that could remain unidentified if resection was performed exclusively under visual guidance. Microscopic images were acquired under **20x** magnification. i) No residual fluorescent signal observed in the surgical bed after removal of the fluorescent tissue. j) The FluoStick™ Clinical System device (**Fluoptics, Grenoble, France**)

**Fig. 2** Sentinel lymph node mapping using NIR (**near infrared**) fluorescence imaging in oropharyngeal cancer patients: Peritumoural injection of 1.6 mL of 500-IM ICG:HSA identifies a SLN (arrow) in an oropharyngeal cancer patient. M = sternocleidomastoid muscle and S = submandibular gland. Figure reproduced, with permission, from Elsevier ©. Van der Vorst et al. Near-infrared fluorescence sentinel lymph node mapping of the oral cavity in head and neck cancer patients. *Oral Oncol* 2013, 9 (1):15-19

Fig1  
[Click here to download high resolution image](#)

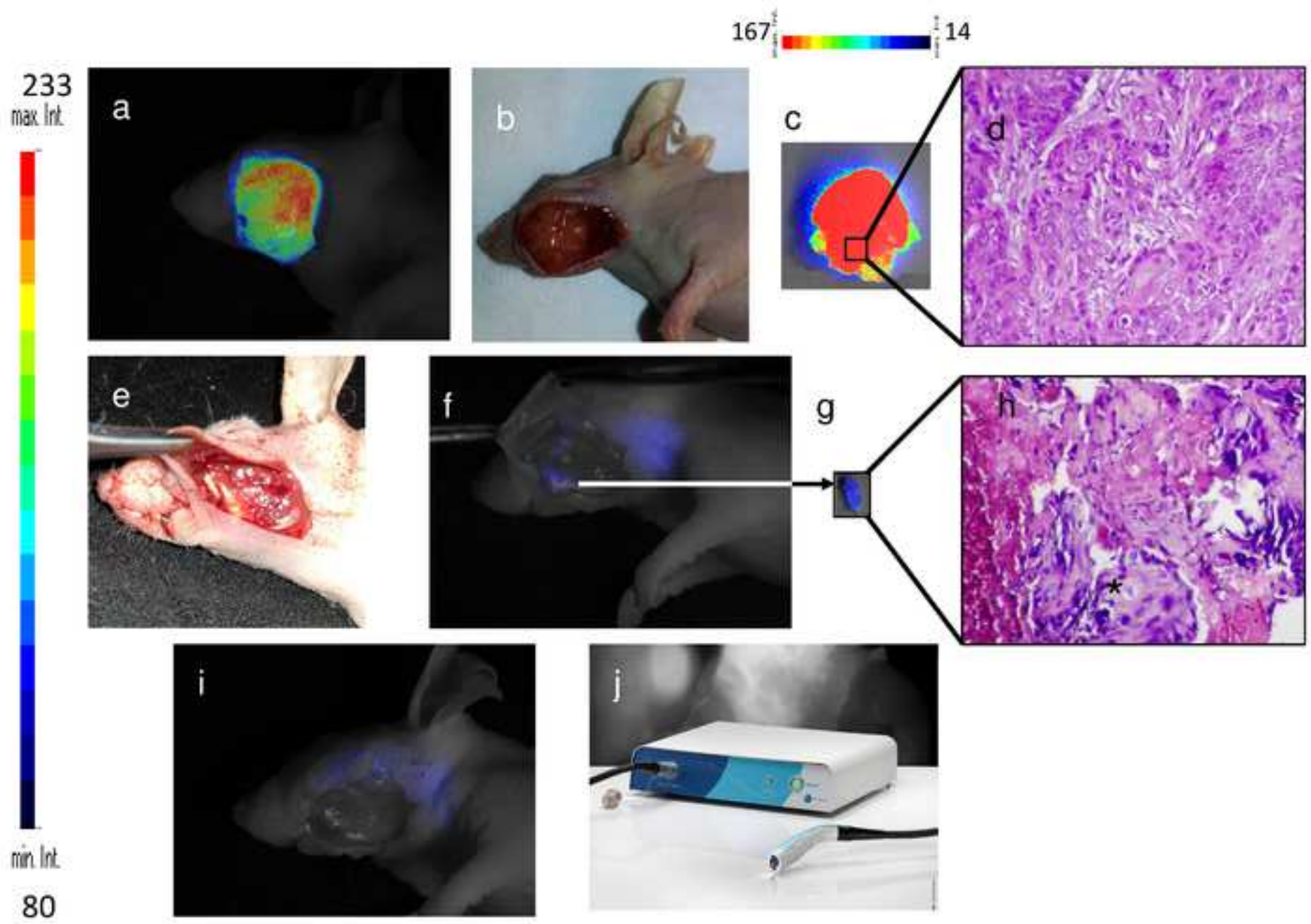


Fig2

[Click here to download high resolution image](#)

