



**HAL**  
open science

## Vitamin D and Calcium Supplementation Accelerates Randall's Plaque Formation in a Murine Model

Elise Boudierlique, Ellie Tang, Joëlle Perez, Amélie E. Coudert, Dominique Bazin, Marie-Christine Verpont, Christophe Duranton, Isabelle Rubera, Jean-Philippe Haymann, Georges Lefthériotis, et al.

► **To cite this version:**

Elise Boudierlique, Ellie Tang, Joëlle Perez, Amélie E. Coudert, Dominique Bazin, et al.. Vitamin D and Calcium Supplementation Accelerates Randall's Plaque Formation in a Murine Model. *American Journal of Pathology*, 2019, 189 (11), pp.2171-2180. 10.1016/j.ajpath.2019.07.013 . hal-02347945

**HAL Id: hal-02347945**

**<https://hal.science/hal-02347945>**

Submitted on 13 Nov 2019

**HAL** is a multi-disciplinary open access archive for the deposit and dissemination of scientific research documents, whether they are published or not. The documents may come from teaching and research institutions in France or abroad, or from public or private research centers.

L'archive ouverte pluridisciplinaire **HAL**, est destinée au dépôt et à la diffusion de documents scientifiques de niveau recherche, publiés ou non, émanant des établissements d'enseignement et de recherche français ou étrangers, des laboratoires publics ou privés.

1 **Vitamin D and calcium supplementation accelerates Randall's plaque formation in a**  
2 **murine model**

3 Elise Boudierlique,<sup>1,2</sup> Ellie Tang,<sup>1,2</sup> Joëlle Perez<sup>1,2</sup>, Amélie Coudert,<sup>3</sup> Dominique Bazin,<sup>4</sup>  
4 Marie-Christine Verpont,<sup>1,2</sup> Christophe Duranton,<sup>5</sup> Isabelle Rubera,<sup>5</sup> Jean-Philippe  
5 Haymann,<sup>1,2,6</sup> Georges Leftheriotis,<sup>5,7</sup> Ludovic Martin,<sup>8,9</sup> Michel Daudon,<sup>1,2,6</sup> Emmanuel  
6 Letavernier,<sup>1,2,6</sup>

7  
8 <sup>1</sup> Sorbonne Universités, UPMC Univ Paris 06, UMR S 1155, F-75020, Paris, France

9  
10 <sup>2</sup> INSERM, UMR S 1155, F-75020, Paris, France

11  
12 <sup>3</sup> UFR d'odontologie (Département des Sciences Biologiques), Université Paris Diderot  
13 BIOSCAR - INSERM U1132, Hôpital Lariboisière 75010 PARIS

14  
15 <sup>4</sup>. Laboratoire de Chimie Physique, CNRS UMR 8000, Université Paris XI, 91405 Orsay,  
16 France.

17 <sup>5</sup> Université Côte d'azur, CNRS-UMR 7370 - Laboratoire de Physiomédecine moléculaire,  
18 06108 Nice, FRANCE

19 <sup>6</sup> Physiology Unit, AP-HP, Hôpital Tenon, F-75020, Paris, France

20 <sup>7</sup> Laboratory of Physiology and Molecular Medicine (LP2M), CNRS-UNS UMR 7370,  
21 University of Nice, 28 rue de Valombrose, 06107 Nice cedex 2, France

22 <sup>8</sup> MITOVASC Institute, - UMR CNRS 6015 INSERM U1083 Angers University, France

23 <sup>9</sup> PXE Reference Center, MAGEC Nord Center for rare skin diseases, Angers University  
24 Hospital, France

25 **AUTHOR INFORMATION**

26 *Correspondence:*

27 Emmanuel LETAVERNIER, Service des Explorations Fonctionnelles Multidisciplinaires,  
28 Hôpital TENON, 4 rue de la Chine, 75020 Paris (France). Phone 33 1 56 01 67 73 ; Fax 33 1  
29 56 01 70 03. E-mail: [emmanuel.letavernier@aphp.fr](mailto:emmanuel.letavernier@aphp.fr)

30 Running Title: Vitamin D and Randall's plaque

31 Word Count: **2808**

32 Number of Figures and Tables: Figures: 7; Tables: 2

33 Keywords: Vitamin D, ABCC6, Kidney stone, Randall's plaque

34 Disclosures: None declared

35 Funding statement: This work has been supported by the Agence Nationale de la Recherche  
36 (ANR-13-JSV1-0010-01, ANR-12-BS08-0022), the Académie Nationale de Médecine  
37 (Nestlé-Waters award), Convergence-UPMC CVG1205 and CORDDIM-2013-COD130042.

38

39

40

41 **Abstract**

42 Most of kidney stones are made of calcium oxalate crystals. Randall's plaque, an apatite  
43 deposit at the tip of the renal papilla is considered to be at the origin of these stones.  
44 Hypercalciuria may promote Randall's plaque formation and growth.

45 We analysed whether long-term exposure of *Abcc6*<sup>-/-</sup> mice (a murine model of Randall's  
46 plaque) to vitamin D supplementation, with or without calcium-rich diet, would accelerate the  
47 formation of Randall's plaque. Eight groups of mice (including *Abcc6*<sup>-/-</sup> and wild-type)  
48 received vitamin D alone (100,000 UI/Kg every 2 weeks), a calcium-enriched diet alone  
49 (calcium gluconate 2g/l in drinking water), both vitamin D supplementation and calcium rich  
50 diet, or a standard diet (controls) for 6 months. Kidney calcifications were assessed by 3D-  
51 micro-computed tomography,  $\mu$ -Fourier transform infrared spectroscopy, field emission-  
52 scanning electron microscopy, transmission electron microscopy and Yasue staining.

53 At 6 months, *Abcc6*<sup>-/-</sup> mice exposed to vitamin D and calcium supplementation developed  
54 massive Randall's plaque when compared to control *Abcc6*<sup>-/-</sup> mice ( $p < 0.01$ ). Wild-type  
55 animals did not develop significant calcifications when exposed to vitamin D.

56 Combined administration of vitamin D and calcium accelerates significantly Randall's plaque  
57 formation in a murine model. This original model raises concerns about the cumulative risk of  
58 vitamin D supplementation and calcium intakes in Randall's plaque formation.

59

60 **Introduction**

61 Renal stone incidence is increasing, affecting almost 10% of the population nowadays.<sup>1,2</sup>  
62 More than two thirds of all kidney stones are made of calcium oxalate.<sup>3,4</sup> Alexander Randall  
63 hypothesized more than eighty years ago that apatite (calcium phosphate) deposits at the tip of  
64 renal papilla would initiate stone formation.<sup>5</sup> Evan et al. reported that these “Randall's plaque”  
65 begin in basement membranes of thin loops of Henle.<sup>6</sup> The same group reported that increased  
66 urine calcium excretion could promote Randall's plaque formation.<sup>7</sup> Stoller et al. and our  
67 group evidenced that Randall's plaque could also originate from vasa recta, capillaries  
68 surrounding renal tubules, in the deepest part of the papilla.<sup>8,9</sup> These observations highlight  
69 that calcium phosphate supersaturation, predicted to be increased around vasa recta in the  
70 papilla, would promote Randall's plaque formation.<sup>10</sup>

71 Several recent studies and meta-analyses highlighted that vitamin D and calcium  
72 supplementation may increase urine calcium excretion and stone formation, especially in  
73 individuals with hypercalciuria.<sup>11,12</sup> A recent randomized controlled trial has shown that the  
74 recommended upper serum level of vitamin D, when associated with calcium supplements,  
75 results frequently in hypercalciuria.<sup>13</sup> Vitamin D, with or without calcium supplements, is  
76 prescribed to prevent bone mass loss, although randomized and controlled studies failed to  
77 evidence a protective role of vitamin D against fractures.<sup>14,15</sup> A few reports suggested that  
78 kidney stone formers with Randall's plaques may have an increased biological response to  
79 vitamin D but there is little evidence that vitamin D promotes or aggravates Randall's plaque  
80 formation to date.<sup>16</sup>

81 The combined administration of high calcium intakes and/or vitamin D has been tested in rats,  
82 leading to kidney stone formation, defining a model of kidney stone disease.<sup>17</sup> However, rats  
83 did not develop tissue calcifications mimicking Randall's plaques.

84 More recently, patients affected by pseudoxanthoma elasticum (PXE) have been described to  
85 be frequently affected by kidney stones. PXE is a genetic (autosomal recessive) disease due to  
86 mutations in *ABCC6* gene. PXE patients are affected by vascular (arterial), retinal and skin  
87 calcifications.<sup>18,19</sup> *ABCC6* is a transporter expressed in the liver which facilitates the release of  
88 extracellular ATP, rapidly converted to inorganic pyrophosphate (PPi) by ectonucleotide  
89 pyrophosphatase phosphodiesterase-1 (ENPP1) in vessels. *ABCC6* and ENPP1 are actually  
90 the main source of systemic pyrophosphate, an inhibitor of calcification limiting ectopic  
91 hydroxyapatite (Ca/Pi) crystalline deposits.<sup>20</sup> Patients with PXE, as well as *Abcc6*<sup>-/-</sup> mice,  
92 have a reduced plasma pyrophosphate level which explains their mineralization disorder.<sup>21,22</sup>  
93 PXE patients develop massive Randall's plaques and are prone to develop kidney stones.<sup>23</sup>  
94 Interestingly, kidneys from *Abcc6*<sup>-/-</sup> mice develop interstitial calcifications with aging  
95 (especially after one year), surrounding the loop of Henle and the vasa recta, made of calcium  
96 phosphate, and developed in the deepest part of the renal papilla, all features of Randall's  
97 plaques.<sup>23</sup> Taken together, these observations suggest pyrophosphate deficiency is a critical  
98 determinant of Randall's plaque formation, by increasing calcium phosphate supersaturation  
99 in renal papilla.<sup>23</sup>

100 As *Abcc6*<sup>-/-</sup> mice represent a unique model of Randall's plaque, we hypothesized that calcium  
101 and/or vitamin D supplementation would accelerate Randall's plaque formation in young  
102 *Abcc6*<sup>-/-</sup> animals, before the spontaneous development of these papillary calcifications.

103 **Material and Methods**

104 **Animal Studies**

105 Mice knock-out for the *Abcc6* gene are usually named *Abcc6*<sup>tm1Aabb</sup>. They were produced on a  
106 129/Ola background and then backcrossed into a C57Bl/6J more than 10 times in Professor A.  
107 Bergen's laboratory. These mice are designated *Abcc6*<sup>-/-</sup> in the manuscript.<sup>23</sup>

108 Forty-eight 10-weeks old female mice were housed and bred at INSERM UMR S 1155  
109 Mouse Facility, with a twelve-hour dark/light cycle. Mice received standard chow, containing  
110 1000 UI vitaminD3/Kg and 1,05 % calcium ad libitum. Six *Abcc6*<sup>+/+</sup> (Wild type-WT) and 6  
111 *Abcc6*<sup>-/-</sup> mice had a free access to water containing 80 mg/l of calcium (control group). Six  
112 WT and 6 *Abcc6*<sup>-/-</sup> mice had a free access to water containing 2g of calcium chloride (calcium  
113 group). Considering that a mouse daily drinking intake is about 5 mL/day (C57Bl/6J, 25g),  
114 calcium daily intake was 10 mg/mouse/day or 0.4 mg/g/day in “calcium” groups. Six WT and  
115 6 *Abcc6*<sup>-/-</sup> mice received vitamin D (ergocalciferol 2500 UI/mouse, Sterogyl 15H, DB  
116 Pharma, La Varenne Saint-Hilaire, France) every 2 weeks, e.g 2.5 UI/g/2 weeks, during 6  
117 months by s.c. injection, and had a free access to water containing 80 mg/l of calcium  
118 (vitamin D group). Six WT and 6 *Abcc6*<sup>-/-</sup> mice received similar vitamin D injections and had  
119 a free access to water containing 2g/l of calcium (calcium + vitamin D group).

120 All studies were performed in accordance with the European Union and National Institutes of  
121 Health guidelines (Comité d'Ethique en Experimentation Charles Darwin C2EA-05). The  
122 project was authorized by the health ministry and local ethics committee (Authorization  
123 number #11420 2017092015335292)

124

125 **Biological samples and biochemistry**

126 Urine was collected in metabolic cages. Mice had a free access to water (calcium-enriched or  
127 not) before the first administration of vitamin D and at 3 and 6 months. Mice were sacrificed  
128 14 days after the last injection of vitamin D and blood was collected at that time.  
129 Several parameters have been measured in urine: diuresis volume, calcium, phosphate,  
130 pyrophosphate, creatinine. The blood samples have been analyzed for calcium (total),  
131 phosphate, urea and vitamin D (at 6 months).  
132 Urinary creatinine and serum urea, and phosphate levels have been analyzed on IDS-iSYS  
133 automat. Calcium serum and urinary levels were measured with the Perkin-Elmer 3300  
134 atomic absorption spectrometer. Vitamin D serum levels have been measured by the IDS-  
135 iSYS 25-Hydroxy Vitamin D immunoassay (IS-2700S), to assess 25-Hydroxy Vitamin D (D2  
136 and D3) levels. Pyrophosphate urine levels were measured by using an ATP sulfurylase  
137 (M0394, NEB) to convert Pyrophosphate into ATP in the presence of excess of adenosine  
138 5'phosphosulfate (A5508; Sigma Aldrich). Generated ATP was then quantified using the ATP  
139 Determination kit (ATPlite 6016941; Perkin Elmer).

140

#### 141 **X-ray microtomography and 3-dimensional modeling**

142 Left kidneys were fixed in formaldehyde and embedded in paraffin. X-ray CT imaging was  
143 performed using a Skyscan 1272 (Bruker, Anvers, Belgium) at Lariboisière Hospital imaging  
144 platform (Paris, France). A 6  $\mu\text{m}$  resolution scale was obtained. Shadow images were  
145 obtained using an X-ray energy of 65 kV and 150 mA without filter exposition. The angular  
146 step between image acquisitions was  $0.5^\circ$  and each image was averaged after 2 frames. Data  
147 were reconstructed using Nrecon software (Bruker, Anvers, Belgium) and then exported into  
148 a 16-bit Tag Image File Format stack of virtual slices. The Mimics Innovation suite 20.0  
149 (Materialise, Leuven, Belgium) was used for the quantification analysis of papilla's  
150 calcification volume, and 3-dimensional modeling of Randall's plaques and kidneys.



151

152 **Histology and Yasue staining**

153 Kidney tissues were fixed in formaldehyde and embedded in paraffin. Four- $\mu\text{m}$  tissue sections  
154 have been performed and stained by Yasue procedure to reveal tissue calcifications.

155

156 **Field emission-scanning electron microscopy**

157 A Zeiss SUPRA55-VP Field Emission scanning Electron Microscope (Zeiss France, Marly-  
158 le-Roi, France) study tissue sections (4  $\mu\text{m}$ ), at low voltage (1.4 KeV).

159

160 **Transmission Electron Microscopy**

161 Half right kidney papilla were fixed in 2.5% glutaraldehyde in 0.1 mmol/L cacodylate buffer  
162 (pH 7.4) at 4°C. Fragments were fixed in 1% osmium tetroxide, dehydrated using alcohol  
163 series and then embedded in epoxy resin. Semi-thin sections (0.5  $\mu\text{m}$ ) were stained using  
164 toluidine blue. Ultrastructure sections (80nm) were contrast-enhanced using Uranyl-Less  
165 staining. A JEOL 1010 electron microscope (JEOL, Ltd., Tokyo, Japan) with a MegaView III  
166 camera (Olympus Soft Imaging Systems GmbH, Munster, Germany) was used to analyze  
167 tissues.

168

169  **$\mu\text{FTIR}$  spectroscopy**

170 Microcalcifications were characterized by using  $\mu\text{Fourier Transform InfraRed}$  spectrometry  
171 (FT-IR) on 4- $\mu\text{m}$  tissue sections deposited on low emission microscope slides (MirrIR,  
172 Keveley Technologies, Tienta Sciences, Indianapolis). FT-IR hyperspectral images were  
173 analyzed with a Spectrum spotlight 400 FT-IR imaging system (Perkin Elmer Life Sciences,  
174 France), at spatial resolution of 6.25  $\mu\text{m}$  and spectral resolution of 8  $\text{cm}^{-1}$ . The spectra were  
175 recorded in the 4000-700  $\text{cm}^{-1}$  mid-InfraRed range.

176

177 **Statistical analyses**

178 Data are expressed as mean (SEM). Data were analyzed with non-parametric tests (Mann-  
179 Whitney), using Statview and GraphPad Prism 5.0 softwares (GraphPad Software Inc., San  
180 Diego, California).The level of significance was set at <0.05.

181

182 **Results**

183 **Serum biochemistry**

184 No significant difference in serum calcium, phosphate and urea levels was observed between  
185 the different groups at 6 months (Table 1). An expected but limited rise in vitamin D serum  
186 levels (about 1.5×control serum levels) was observed in the groups receiving vitamin D  
187 (ergocalciferol) supplementation (Table 1)

188

189 **Urine biochemistry**

190 Urine calcium, phosphate and pyrophosphate excretion was assessed before treatment, and at  
191 3 and 6 months. No significant difference in urine calcium excretion was observed between  
192 WT and *Abcc6*<sup>-/-</sup> mice, although there was a systematic trend toward increased urine calcium  
193 excretion at 3 and 6 months in animals exposed to vitamin D ± calcium (Table 2). When taken  
194 together (considering all *Abcc6*<sup>-/-</sup> and WT mice at each time), *Abcc6*<sup>-/-</sup> mice had a  
195 significantly lower urinary excretion of pyrophosphate in comparison to wild type animals at  
196 each time-point (Figure 1, n=24/group, p<0.01). When considering subgroups of *Abcc6*<sup>-/-</sup> and  
197 WT mice, the difference in urine pyrophosphate was inconsistently significant due to the low  
198 animal number (n=6/group, Table 2).

199

200 **Quantification of renal calcification at 6 months**

201 Micro-CT analyses have been performed to assess global kidney calcifications (Figures 2 and  
202 3). *Abcc6*<sup>-/-</sup> mice had an increased calcification volume (1443548±174767 μm<sup>3</sup>) in  
203 comparison to control mice (198145±42226 μm<sup>3</sup>, n=24/group, p<0.01). In subgroup analysis,  
204 there was a non-significant trend toward an increased renal calcification volume in *Abcc6*<sup>-/-</sup>  
205 mice exposed to calcium and vitamin D (1939003±484442 μm<sup>3</sup>) when compared to *Abcc6*<sup>-/-</sup>  
206 control mice (1051010±166189sem μm<sup>3</sup>, n=6/group, p=NS, Figure 3).

207 Micro-CT analyses focused on the kidney papilla have been performed next (Figures 2 and 4).  
208 WT animals did not develop significant papillary calcifications, even after 6 months exposure  
209 to both calcium and vitamin D (figure 4). *Abcc6*<sup>-/-</sup> mice had an increased papillary  
210 calcification volume (434910±77943 μm<sup>3</sup>) in comparison to control mice (62722±23811  
211 μm<sup>3</sup>, n=24/group, p<0.01). In subgroup analysis, there was a significantly increased  
212 calcification volume in the renal papilla of *Abcc6*<sup>-/-</sup> mice exposed to calcium and vitamin D  
213 (892410±172006 μm<sup>3</sup>) when compared to *Abcc6*<sup>-/-</sup> control mice (248937±101734 μm<sup>3</sup>,  
214 n=6/group, p< 0.01, Figure 4).

215

### 216 **Histopathological analyses and transmission electron microscopy**

217 Yasue staining revealed the presence of rare tubular calcifications (tubular plugs) in WT  
218 animals and massive tubular and interstitial calcifications in the renal papilla in *Abcc6*<sup>-/-</sup> mice,  
219 similar to human Randall's plaque (Figure 5). Of notice, vitamin D and calcium  
220 supplementation increased dramatically the interstitial papillary calcified surface in *Abcc6*<sup>-/-</sup>  
221 mice (Figure 5). Electron microscopy evidenced the massive presence of round-shaped  
222 electron-dense structure in the interstitial tissue, around the vasa recta and the loop of Henle,  
223 especially in *Abcc6*<sup>-/-</sup> mice exposed to calcium and vitamin D (Figure 6).

224

### 225 **Field Emission-Scanning Electron Microscopy (FE-SEM) and μFourier Transform** 226 **InfraRed (μFTIR) spectroscopy**

227 FE-SEM has shown that tubular plugs observed in *Abcc6*<sup>-/-</sup> mice exposed to vitamin D and  
228 calcium were made of aggregated spherulites (Figure 7A; black arrow) and revealed to a  
229 lesser extent the presence of interstitial spherulites embedded in the renal tissue and  
230 corresponding to interstitial calcifications (Figure 7A; white arrows). To go further in the  
231 characterization of the crystalline phases, we performed μFTIR spectroscopy with an imaging

232 system. The analysis of the absorption spectrum and its second derivative revealed some  
233 features specific for the presence of different absorption bands of the apatite  
234  $[\text{Ca}_5(\text{PO}_4)_3(\text{OH})]$ , including the  $\nu_3$  P-O stretching vibration mode measured at 1035-1045  $\text{cm}^{-1}$   
235 <sup>1</sup> (Figures 7B). Carbonate ions were detected together with apatite by their  $\nu_3$  C-O stretching  
236 vibration mode around 1420  $\text{cm}^{-1}$  and the  $\nu_2$  C-O bending mode at 875  $\text{cm}^{-1}$ . The presence of  
237 amorphous calcium phosphate (ACP), revealed by the partial disappearance of the shoulder of  
238 the  $\nu_3$  P-O absorption band of apatite, has been observed in both interstitial deposits and  
239 intratubular calcifications (Figures 7B).

240

241

242

243 **Discussion**

244 The long-term administration of vitamin D, especially in addition to calcium supplementation,  
245 accelerates dramatically Randall's plaque formation in *Abcc6*<sup>-/-</sup> mice. These 8-mo. old  
246 animals were affected by massive papillary calcifications whereas unexposed control *Abcc6*<sup>-/-</sup>  
247 mice developed tiny interstitial calcifications and tubular plugs. In parallel, wild-type mice  
248 exposed to vitamin D, with or without calcium supplementation, developed very sparse  
249 tubular calcifications and no Randall's plaque. *Abcc6*<sup>-/-</sup> had significantly decreased urinary  
250 pyrophosphate levels but calcium and phosphate urine (and serum) levels were similar in  
251 wild-type and *Abcc6*<sup>-/-</sup> mice. In contrast to our seminal observations, we did not confirm any  
252 difference in phosphate metabolism between wild-type and *Abcc6*<sup>-/-</sup> mice.<sup>23</sup> Mice exposed to  
253 both calcium and vitamin D had a non-significant trend toward higher urine calcium  
254 excretion, despite high doses of calcium and vitamin D, in comparison with doses used in  
255 humans in clinical practice. It seems difficult to compare calcium homeostasis in mice and  
256 humans but the modest increase in vitamin D serum levels, the non-significant increase in  
257 urine calcium excretion and the absence of hypercalcemia in animals exposed to calcium and  
258 vitamin D rules out the hypothesis of an "intoxication". Nevertheless, in mice affected by  
259 pyrophosphate deficiency, even a mild increase in urine calcium excretion was sufficient to  
260 accelerate the papillary calcification process.

261 Interestingly, Sprague Dawley rats exposed to high calcium intake did not develop renal  
262 calcifications and rats exposed to vitamin D alone developed hypercalciuria but only tiny  
263 calcium phosphate kidney stones.<sup>17</sup> By contrast, the synergistic administration of calcium and  
264 vitamin D promoted the development of large stones but no Randall's plaque. The genetic  
265 hypercalciuric stone-forming rat (GHS) have an increased expression of the vitamin D  
266 receptor (VDR) in intestine, bone, and kidney.<sup>24</sup> These animals develop calcium phosphate

267 kidney stones but, again, no Randall's plaque. It appears therefore that vitamin D, especially  
268 in combination to calcium is not sufficient to induce papillary calcifications, whose initiation  
269 may be due to calcification inhibitors defect, but accelerates dramatically the development of  
270 the Randall's plaque in *Abcc6*<sup>-/-</sup> mice.

271 Predisposed individuals may be at risk to form kidney stones when exposed to vitamin D,  
272 especially when vitamin D and calcium intakes are combined. In the Women Health Initiative  
273 (WHI) study, a controlled randomized study, 36,282 postmenopausal women received 1 gram  
274 calcium and 400IU vitamin D daily or a placebo during 7 years.<sup>11</sup> The treatment did not  
275 reduce significantly bone fractures but an increased kidney stone risk has been described in  
276 women who received calcium and vitamin D. Recent studies confirmed that vitamin D,  
277 especially when prescribed in addition to calcium supplementation, increases significantly  
278 urine calcium excretion and in some studies the risk to develop kidney stones.<sup>12,13</sup> By contrast,  
279 some studies did not identify an increased risk of kidney stone after exposure to vitamin D  
280 alone (without calcium supplementation) during a median follow-up of 3.3 years.<sup>25</sup>

281 Interventional studies remain sparse but recent observations show that some kidney stone  
282 formers may develop hypercalciuria after vitamin D "repletion".<sup>26,27</sup> An important point to  
283 take into consideration is the time required to develop Randall's plaque, which precede stone  
284 formation. Actually, vitamin D increases urine calcium excretion, which may accelerate  
285 plaque formation and promote calcium oxalate stone formation several years later.<sup>7</sup> The  
286 situation may have worsened during the past decades because of the increase in vitamin D  
287 prescription, although there is no evidence that vitamin D supplementation may protect  
288 against fractures or other conditions, including cancers, cardiac and vascular diseases, obesity,  
289 diabetes, depression, falls, infectious diseases and maternal/perinatal conditions.<sup>28</sup>

290 Interestingly, Ferraro et al. analysed the association of vitamin D intakes and the risk to  
291 develop kidney stones and found no association in the Health Professionals Follow-up Study

292 and Nurses' Health Study I but an increased risk in the more recent Nurses' Health Study II,  
293 including women receiving an increased amount of vitamin D supplements.<sup>29</sup>

294 We observed a synergistic effect of combined vitamin D/calcium supplementation in  
295 experimental models, consistent with clinical studies. Of note, calcium intake in the absence  
296 of vitamin D did not increase the risk Randall's plaque formation in our murine model but  
297 also in humans: on the contrary, higher dietary calcium is associated with a lower risk to  
298 develop kidney stones.<sup>30</sup> This results from calcium-oxalate complex formation in the intestine,  
299 limiting oxalate absorption and eventually calcium oxalate stone formation.

300 Our results raise concerns about the prescription of vitamin D and calcium to patients affected  
301 by PXE. We recently described the presence of massive Randall's plaque and frequent kidney  
302 stones in these patients and it may be hypothesized that vitamin D prescription could  
303 accelerate plaque and stone formation in patients affected by pyrophosphate deficiency.<sup>23</sup> A  
304 deficiency in urine pyrophosphate has been reported in kidney stone formers but  
305 pyrophosphate level in urine is difficult to assess in routine practice. This explains probably  
306 why few studies focused on the importance of pyrophosphate in kidney stone formation, and  
307 no study highlighted its role in Randall's plaque formation until recently.<sup>31-33</sup>

308 Most of kidney stones are made of calcium oxalate and many of them originate from  
309 Randall's plaque. Some observations suggested that patients affected by Randall's plaque  
310 could be more "sensitive" to vitamin D.<sup>16</sup> The dramatic acceleration of papillary calcifications  
311 by the combined administration of vitamin D and calcium in *Abcc6<sup>-/-</sup>* mice suggests that in  
312 some genetically predisposed individuals, combined calcium and vitamin D intake could in  
313 theory accelerate Randall's plaque formation, deserving specific clinical studies to address  
314 this concern.

315

316



317 **Acknowledgements**

318 The authors thank Liliane Louedec and Claude Kitou for their excellent advice on mouse care  
319 and management.

320 **Authors contribution**

321 EL, EB, and MD designed the study

322 EB, ET, JP, AC, DB, MCV, CD, IR, JPH, GL, LM, MD, VP, JZ, OLS, MD, and EL carried  
323 out experiments and clinical research

324 EB, ET, JP, AC, DB, CD, IR, MD and EL analyzed the data

325 EB, ET, and EL made the figures

326 EB, ET, JP, AC, DB, CD, IR, MD, and EL drafted and revised the paper

327

328 EL is the guarantor of this work and, as such, had full access to all of the data in the study and  
329 takes responsibility for the integrity of the data and the accuracy of the data analysis

330

331 All authors approved the final version of the manuscript

332

333 **Financial Conflict of Interest:** none

334

335 **References**

- 336 1. Stamatelou KK, Francis ME, Jones CA, Nyberg LM, Curhan GC: Time trends in reported  
337 prevalence of kidney stones in the United States: 1976-1994. *Kidney Int* 2003; 63: 1817-1823  
338
2. Ziemba JB, Matlaga BR: Epidemiology and economics of nephrolithiasis. *Investig Clin Urol* 2017;  
58: 299-306
3. Daudon M, Doré JC, Jungers P, Lacour B: Changes in stone composition according to age and  
gender of patients: a multivariate epidemiological approach. *Urol Res* 2004; 32: 241-247
4. Singh P, Enders FT, Vaughan LE, Bergstralh EJ, Knoedler JJ, Krambeck AE, Lieske JC, Rule AD:  
Stone Composition Among First-Time Symptomatic Kidney Stone Formers in the Community. *Mayo  
Clin Proc* 2015; 90: 1356-1365
5. Randall A: The origin and growth of renal calculi. *Ann Surg* 1937; 105: 1009-1027
6. Evan AP, Lingeman JE, Coe FL, Parks JH, Bledsoe SB, Shao Y, Sommer AJ, Paterson RF, Kuo  
RL, Grynspas M: Randall's plaque of patients with nephrolithiasis begins in basement membranes of  
thin loops of Henle. *J Clin Invest* 2003; 111: 607-616
7. Kuo RL, Lingeman JE, Evan AP, Paterson RF, Parks JH, Bledsoe SB, Munch LC, Coe FL: Urine  
calcium and volume predict coverage of renal papilla by Randall's plaque. *Kidney Int* 2003; 64: 2150-  
2154
8. Stoller ML, Low RK, Shami GS, McCormick VD, Kerschmann RL: High resolution radiography of  
cadaveric kidneys: unraveling the mystery of Randall's plaque formation. *J Urol* 1996; 156:1263-1266
- 339 9. Verrier C, Bazin D, Hugué L, Stéphan O, Gloter A, Verpont MC, Frochot V, Haymann JP,  
340 Brocheriou I, Traxer O, Daudon M, Letavernier E: Topography, Composition and Structure of  
341 Incipient Randall Plaque at the Nanoscale Level. *J Urol* 2016; 196: 1566-1574  
342
10. Tournus M, Seguin N, Perthame B, Thomas SR, Edwards A: A model of calcium transport along  
the rat nephron. *Am J Physiol Renal Physiol* 2013, 305: F979-994
11. Jackson RD, LaCroix AZ, Gass M, Wallace RB, Robbins J, Lewis CE, Bassford T, Beresford SA,  
Black HR, Blanchette P, Bonds DE, Brunner RL, Brzyski RG, Caan B, Cauley JA, Chlebowski RT,  
Cummings SR, Granek I, Hays J, Heiss G, Hendrix SL, Howard BV, Hsia J, Hubbell FA, Johnson KC,  
Judd H, Kotchen JM, Kuller LH, Langer RD, Lasser NL, Limacher MC, Ludlam S, Manson JE,  
Margolis KL, McGowan J, Ockene JK, O'Sullivan MJ, Phillips L, Prentice RL, Sarto GE, Stefanick  
ML, Van Horn L, Wactawski-Wende J, Whitlock E, Anderson GL, Assaf AR, Barad D; Women's  
Health Initiative Investigators: Calcium plus vitamin D supplementation and the risk of fractures. *N  
Engl J Med* 2006, 354: 669-683
12. Hu H, Zhang J, Lu Y, Zhang Z, Qin B, Gao H, Wang Y, Zhu J, Wang Q, Zhu Y, Xun Y, Wang S:  
Association between Circulating Vitamin D Level and Urolithiasis: A Systematic Review and Meta-  
Analysis. *Nutrients* 2017, 9: E301
13. Aloia JF, Katumuluwa S, Stolberg A, Usera G, Mikhail M, Hoofnagle AN, Islam S. Safety of  
calcium and vitamin D supplements, a randomized controlled trial. *Clin Endocrinol (Oxf)* 2018, 89:  
742-749
14. Bolland MJ, Grey A, Avenell A: Effects of vitamin D supplementation on musculoskeletal health:  
a systematic review, meta-analysis, and trial sequential analysis. *Lancet Diabetes Endocrinol* 2018, 6:  
847-858

15. Reid IR, Bolland MJ, Grey A. Effects of vitamin D supplements on bone mineral density: a systematic review and meta-analysis. *The Lancet* 2014, 383: 146–155
16. Letavernier E, Vandermeersch S, Traxer O, Tligui M, Baud L, Ronco P, Haymann JP, Daudon M: Demographics and characterization of 10,282 Randall plaque-related kidney stones: a new epidemic? *Medicine (Baltimore)* 2015, 94: e566
17. Letavernier E, Verrier C, Goussard F, Perez J, Huguet L, Haymann JP, Baud L, Bazin D, Daudon M: Calcium and vitamin D have a synergistic role in a rat model of kidney stone disease. *Kidney Int* 2016, 90: 809-817
- 343 18. Li Q, Jiang Q, Pfindner E, Váradi A, Uitto J: Pseudoxanthoma elasticum: clinical phenotypes,  
344 molecular genetics and putative pathomechanisms. *Exp Dermatol* 2009, 18: 1-11  
345
19. Le Saux O, Urban Z, Tschuch C, Csiszar K, Bacchelli B, Quaglini D, Pasquali-Ronchetti I, Pope FM, Richards A, Terry S, Bercovitch L, de Paepe A, Boyd CD: Mutations in a gene encoding an ABC transporter cause pseudoxanthoma elasticum. *Nat Genet* 2000, 25: 223-227
20. Jansen RS, Duijst S, Mahakena S, Sommer D, Szeri F, Váradi A, Plomp A, Bergen AA, Oude Elferink RP, Borst P, van de Wetering K: ABCC6-mediated ATP secretion by the liver is the main source of the mineralization inhibitor inorganic pyrophosphate in the systemic circulation-brief report. *Arterioscler Thromb Vasc Biol* 2014, 34: 1985-1989
21. Vanakker OM, Leroy BP, Coucke P, Bercovitch LG, Uitto J, Viljoen D, Terry SF, Van Acker P, Matthys D, Loeys B, De Paepe A: Novel clinico-molecular insights in pseudoxanthoma elasticum provide an efficient molecular screening method and a comprehensive diagnostic flowchart. *Hum Mutat* 2008, 29: 205
22. Ziegler SG, Ferreira CR, MacFarlane EG, Riddle RC, Tomlinson RE, Chew EY, Martin L, Ma CT, Sergienko E, Pinkerton AB, Millán JL, Gahl WA, Dietz HC: Ectopic calcification in pseudoxanthoma elasticum responds to inhibition of tissue-nonspecific alkaline phosphatase. *Sci Transl Med* 2017, 9: 393
23. Letavernier E, Kauffenstein G, Huguet L, Navasiolava N, Boudierlique E, Tang E, Delaitre L, Bazin D, de Frutos M, Gay C, Perez J, Verpont MC, Haymann JP, Pomozi V, Zoll J, Le Saux O, Daudon M, Leftheriotis G, Martin L: ABCC6 Deficiency Promotes Development of Randall Plaque. *J Am Soc Nephrol* 2018, 29: 2337-2347
24. Bushinsky DA, Frick KK, Nehrke K: Genetic hypercalciuric stone-forming rats. *Curr. Opin. Nephrol. Hypertens* 2006, 15: 403–418
25. Malihi Z, Lawes CMM, Wu Z, Huang Y, Waayer D, Toop L, Khaw KT, Camargo CA, Scragg R: Monthly high-dose vitamin D supplementation does not increase kidney stone risk or serum calcium: results from a randomized controlled trial. *Am J Clin Nutr* 2019, in press
26. Johri N, Jaeger P, Ferraro PM, Shavit L, Nair D, Robertson WG, Gambaro G, Unwin RJ. Vitamin D deficiency is prevalent among idiopathic stone formers, but does correction pose any risk? *Urolithiasis* 2017, 45: 535-543
27. Vitale C, Tricerri A, Bermond F, Fabbrini L, Guiotto C, Marangella M: Metabolic effects of Cholecalciferol supplementation in kidney stone formers with vitamin D deficiency. *G Ital Nefrol* 2018, 35

28. Autier P, Mullie P, Macacu A, Dragomir M, Boniol M, Coppens K, Pizot C, Boniol M: Effect of vitamin D supplementation on non-skeletal disorders: a systematic review of meta-analyses and randomised trials. *Lancet Diabetes Endocrinol* 2017, 5: 986-1004

29. Ferraro PM, Taylor EN, Gambaro G, Curhan GC: Vitamin D Intake and the Risk of Incident Kidney Stones. *J Urol* 2017, 197: 405-410

30. Taylor EN, Curhan GC: Dietary calcium from dairy and nondairy sources, and risk of symptomatic kidney stones. *J. Urol* 2013, 190: 1255–1259

346 31. Roberts NB, Dutton J, Helliwell T, Rothwell PJ, Kavanagh JP: Pyrophosphate in synovial  
347 fluid and urine and its relationship to urinary risk factors for stone disease. *Ann Clin Biochem*  
348 1992, 29: 529-534

349  
350 32. Sharma S, Vaidyanathan S, Thind SK, Nath R: Urinary excretion of inorganic  
351 pyrophosphate by normal subjects and patients with renal calculi in north-western India and  
352 the effect of diclofenac sodium upon urinary excretion of pyrophosphate in stone formers.  
353 *Urol Int* 1992, 48: 404-408

354  
355 33. Simonet BM, Grases F, March JG: Enzymatic determination of pyrophosphate in urine by  
356 flow methods. *Anal Sci* 2003, 19: 1029-1032

357  
358  
359  
360

361  
362  
363

## Figure Legends

364

365 **Figure 1.** Urinary pyrophosphate excretion at baseline, 3 and 6 months.

366 Urine pyrophosphate excretion, indexed to urine creatinine ( $\mu\text{mol}/\text{mmol}$ ) was significantly  
367 decreased in *Abcc6*<sup>-/-</sup> mice in comparison to WT animals (\*:  $p < 0.05$ ,  $n=24$  animals/group).

368

369 **Figure 2.** Renal calcifications assessment by X-Ray tomography

370 Micro-CT analyses allowed the identification of kidney calcifications. The global volume of  
371 the calcifications (in red) has been assessed after 3D kidney reconstruction (Figure 2A-H).

372 WT mice (Figure 2 A-D) did not develop significant calcifications, whereas

373 *Abcc6*<sup>-/-</sup> mice (Figure 2E-H) developed calcifications, especially at the tip of the papilla

374 (A) WT Control; (B) WT Calcium; (C) WT Vitamin D ; (D) WT Calcium + Vitamin D; (E)

375 *Abcc6*<sup>-/-</sup> Control; (F) *Abcc6*<sup>-/-</sup> Calcium; (G) *Abcc6*<sup>-/-</sup> Vitamin D; (H) *Abcc6*<sup>-/-</sup> Calcium +

376 Vitamin D

377

378 **Figure 3.** Renal calcification global volume

379 The global volume of the calcifications has been quantified ( $\mu\text{m}^3$ ) after 3D kidney  
380 reconstruction. Global renal calcification volume was significantly increased in *Abcc6*<sup>-/-</sup> mice

381 in comparison to WT animals but there was no significant difference among *Abcc6*<sup>-/-</sup> mice  
382 subgroups ( $n=6$ /group).

383

384 **Figure 4.** Papillary calcifications

385 The volume of the calcifications has been quantified ( $\mu\text{m}^3$ ) in each papilla after 3D kidney  
386 reconstruction. Global papillary calcification volume was significantly increased in *Abcc6*<sup>-/-</sup>  
387 mice exposed to both calcium and vitamin D vs *Abcc6*<sup>-/-</sup> control mice (\*:  $p < 0.05$ ,  $n = 6$   
388 animals/group).

389

390 **Figure 5.** Characterization of papillary calcifications: Yasue staining

391 Yasue staining revealed intratubular and interstitial calcifications predominating in the renal  
392 papilla. WT mice developed very sparse and rare tubular plugs, even after exposure to  
393 calcium and vitamin D (Figure 5A-D magnification x100). By contrast, *Abcc6*<sup>-/-</sup> mice  
394 developed papillary calcifications (tubular plugs and interstitial calcifications, mimicking the  
395 human Randall's plaque, Figure 5E-H). The exposure to vitamin D, especially in addition to  
396 calcium increased interstitial calcifications (Figure 5G-H).

397 (A) WT Control; (B) WT Calcium; (C) WT Vitamin D ; (D) WT Calcium + Vitamin D; (E)  
398 *Abcc6*<sup>-/-</sup> Control; (F) *Abcc6*<sup>-/-</sup> Calcium; (G) *Abcc6*<sup>-/-</sup> Vitamin D; (H) *Abcc6*<sup>-/-</sup> Calcium +  
399 Vitamin D

400

401

402 **Figure 6.** Characterization of papillary calcifications: transmission electron microscopy.

403 Transmission electron microscopy evidenced that the interstitial deposits observed in *Abcc6*<sup>-/-</sup>  
404 *Abcc6*<sup>-/-</sup> mice exposed to vitamin D were round-shaped, concentric and electron-dense structure,  
405 surrounding vasa recta and loop of Henle, features similar to the incipient Randall's plaque  
406 observed in humans.

407

408 **Figure 7.** Characterization of papillary calcifications: Field emission-scanning electron  
409 microscopy images and Fourier Transform InfraRed spectroscopy.

410 Field emission-scanning electron microscopy images showed tubular plug structure (black  
411 arrow), and to a lesser extent interstitial deposits (Figure 7A, white arrows). Calcifications  
412 were made of spherulite aggregates, a typical feature of calcium phosphate (apatite) deposits.  
413 These deposits were made of apatite and to a lower extent amorphous carbonated calcium  
414 phosphate as evidenced by FTIR spectroscopic imaging analyses (Figure 7B: typical spectrum  
415 of a mixture of apatite and amorphous calcium phosphate and Fourier transform infraRed  
416 microspectroscopy hyperspectral image of a papilla from a *Abcc6*<sup>-/-</sup>-exposed to calcium and  
417 vitamin D).  
418

Table 1 : Serum biological parameters

	<b>WT</b>				<b>Abcc6<sup>-/-</sup></b>			
	Control	Calcium	Vitamin D	Calcium + Vitamin D	Control	Calcium	Vitamin D	Calcium + Vitamin D
Urea mmol/l	9.34 ±±0.55	10.78 ± 0.51	9.40 ± 0.21	10.12 ± 0.43	10.67 ± 1.80	9.59 ± 0.37	8.72 ± 0.59	8.32 ± 0.38
Calcium mmol/l	2.51 ± 0.1	2.53 ± 0.07	2.23 ± 0.08	2.49 ± 0.11	2.49 ± 0.06	2.65 ± 0.15	2.5 ± 0.06	2.4 ± 0.1
Phosphate mmol/l	1.83 ± 0.06	2.16 ± 0.39	1.83 ± 0.18	2.38 ± 0.25	2.73 ± 0.41	1.94 ± 0.08	2.29 ± 0.14	2.29 ± 0.08
Vitamin D ng/ml	82.5 ± 6.6	87.6 ± 6.9	123.4 ± 6.9*	144.8 ± 14.5*	88.9 ± 6.9	74.9 ± 3.0	124.4 ± 5.8*	114 ± 5.9*

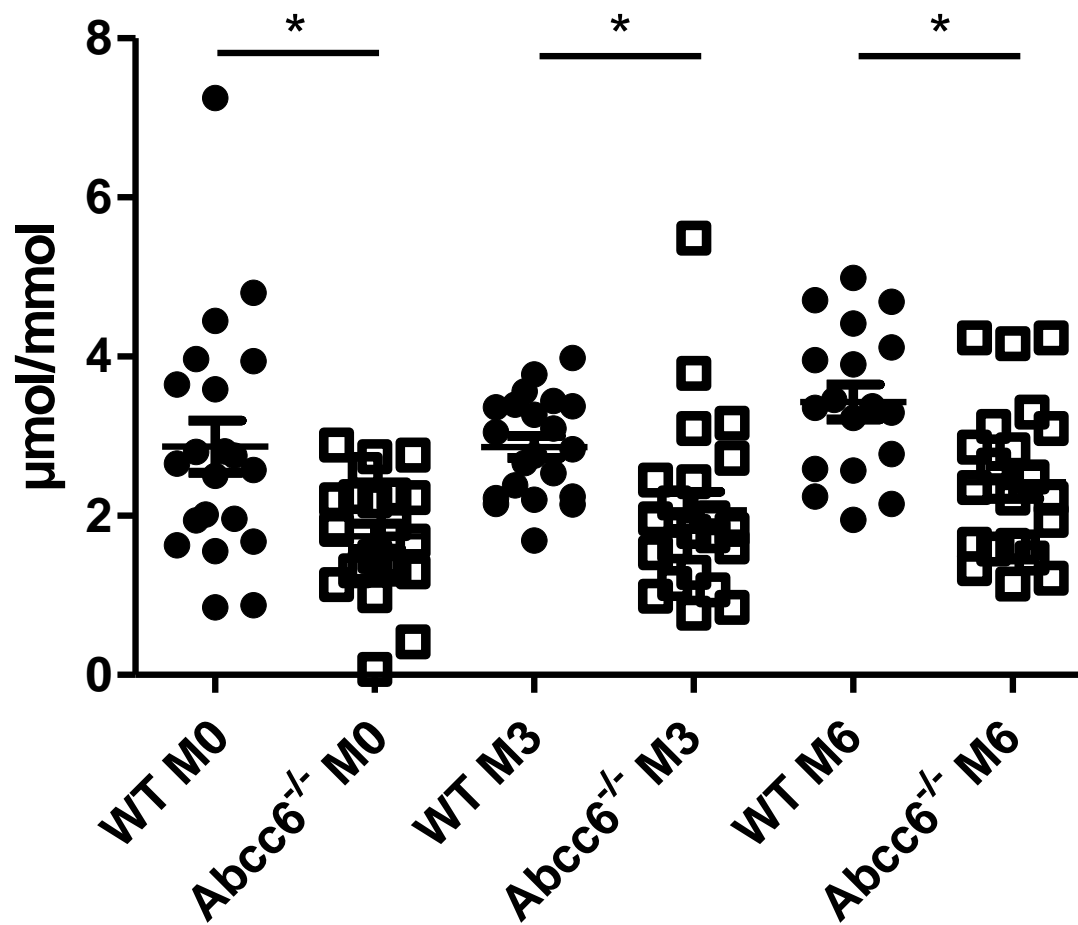
\* p<0.05 versus control and calcium group



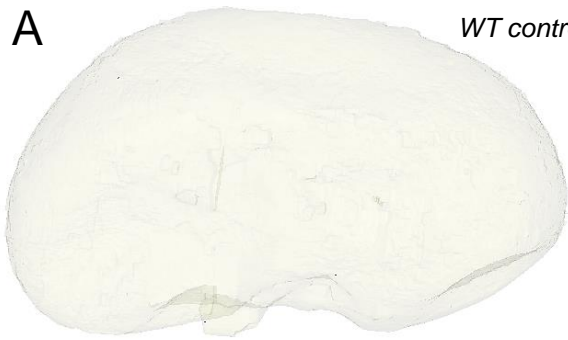Table 2 : Urine biological parameters

	WT				Abcc6 <sup>-/-</sup>			
	Control	Calcium	Vitamin D	Calcium + Vitamin D	Control	Calcium	Vitamin D	Calcium + Vitamin D
<i>At baseline</i>								
Calcium/creatinine mmol/mmol	0.97 ± 0.23	0.66 ± 0.09	0.59 ± 0.06	0.71 ± 0.06	1.06 ± 0.15	1.02 ± 0.11	0.99 ± 0.2	1.23 ± 0.31
Phosphate/creatinine mmol/mmol	15.5 ± 3.3	16.5 ± 1.5	19.6 ± 2.2	24 ± 2.5	23.2 ± 4.6	14.7 ± 1.3	17.4 ± 1.1	20.3 ± 3.2
Pyrophosphate/creatinine μmol/mmol	1.89 ± 0.32	3.84 ± 0.79	2.71 ± 0.46	2.96 ± 0.57	1.82 ± 0.3	1.85 ± 0.4	1.86 ± 0.15	1.42 ± 0.42
<i>At 3 months</i>								
Calcium/creatinine mmol/mmol	0.87 ± 0.08	0.70 ± 0.11	0.94 ± 0.11	0.85 ± 0.09	0.84 ± 0.09	0.89 ± 0.19	1.08 ± 0.13	1.06 ± 0.15
Phosphate/creatinine mmol/mmol	14.6 ± 1.6	15.2 ± 1.5	16.9 ± 1.8	12.6 ± 0.5	16.1 ± 0.8	9.3 ± 1.5	13.7 ± 2.1	17.1 ± 1.8
Pyrophosphate/creatinine μmol/mmol	2.8 ± 0.36	3.25 ± 0.19	2.62 ± 0.3	2.76 ± 0.26	1.83 ± 0.36	1.9 ± 0.41	1.8 ± 0.29	2.68 ± 0.66
<i>At 6 months</i>								
Calcium/creatinine mmol/mmol	0.77 ± 0.17	0.71 ± 0.13	1.03 ± 0.24	0.91 ± 0.12	0.76 ± 0.11	0.63 ± 0.03	1.06 ± 0.1	0.93 ± 0.06
Phosphate/creatinine mmol/mmol	14.3 ± 0.2	13.1 ± 1	17.8 ± 1.9	18.8 ± 2.1	16 ± 0.9	13.3 ± 1.1	13.2 ± 0.9	14.8 ± 0.7
Pyrophosphate/creatinine μmol/mmol	3.92 ± 0.43	3.26 ± 0.47	3.3 ± 0.28	3.17 ± 0.58	2.68 ± 0.43	3.01 ± 0.41	1.83 ± 0.18	2.32 ± 0.5

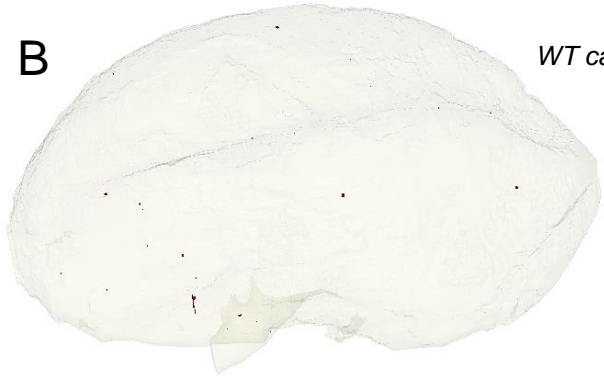# Urine PPI excretion



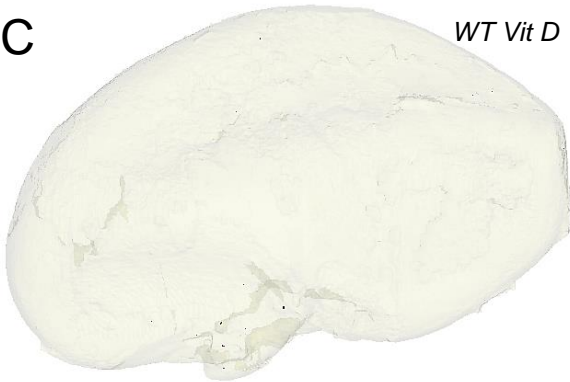
**A** *WT control*



**B** *WT calcium*



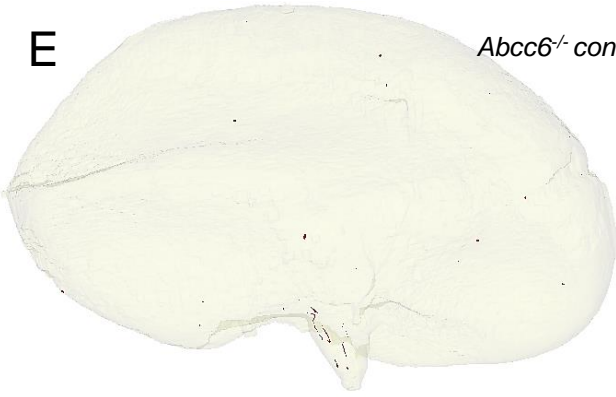
**C** *WT Vit D*



**D** *WT calcium+ VitD*



**E** *Abcc6<sup>-/-</sup> control*



**F** *Abcc6<sup>-/-</sup> calcium*



**G** *Abcc6<sup>-/-</sup> VitD*



**H** *Abcc6<sup>-/-</sup> calcium+ VitD*



