



**HAL**  
open science

## **SHH medulloblastoma in a young adult with a TCF4 germline pathogenic variation**

Maud Blanluet, Julien Masliah-Planchon, Irina Giurgea, Franck Bielle, Élodie Girard, Mamy Andrianteranagna, Stéphane Clémenceau, Christine Bourneix, Lydie Burglen, Diane Doummar, et al.

### ► **To cite this version:**

Maud Blanluet, Julien Masliah-Planchon, Irina Giurgea, Franck Bielle, Élodie Girard, et al.. SHH medulloblastoma in a young adult with a TCF4 germline pathogenic variation. *Acta Neuropathologica*, 2019, 137 (4), pp.675-678. 10.1007/s00401-019-01983-4 . hal-02347134

**HAL Id: hal-02347134**

**<https://hal.science/hal-02347134>**

Submitted on 18 Dec 2020

**HAL** is a multi-disciplinary open access archive for the deposit and dissemination of scientific research documents, whether they are published or not. The documents may come from teaching and research institutions in France or abroad, or from public or private research centers.

L'archive ouverte pluridisciplinaire **HAL**, est destinée au dépôt et à la diffusion de documents scientifiques de niveau recherche, publiés ou non, émanant des établissements d'enseignement et de recherche français ou étrangers, des laboratoires publics ou privés.

## SHH medulloblastoma in a young adult with a *TCF4* germline pathogenic variation

Maud Blanluet<sup>1</sup>, Julien Masliah-Planchon<sup>1,2</sup>, Irina Giurgea<sup>3,4</sup>, Franck Bielle<sup>5</sup>, Elodie Girard<sup>6</sup>, Mamy Andrianteranagna<sup>2</sup>, Stéphane Clemenceau<sup>7</sup>, Christine Bourneix<sup>1</sup>, Lydie Burglen<sup>8</sup>, Diane Doummar<sup>9</sup>, Audrey Rapinat<sup>10</sup>, Badreddine Mohand Oumoussa<sup>11</sup>, Olivier Ayrault<sup>12,13</sup>, Celio Pouponnot<sup>12,13</sup>, David Gentien<sup>10</sup>, Gaëlle Pierron<sup>1,2</sup>, Olivier Delattre<sup>1,2,14</sup>, François Doz<sup>2,15</sup>, Franck Bourdeaut<sup>2,14</sup>

- 1 Unité de Génétique Somatique, Institut Curie, Paris, France
- 2 SIREDO Oncology Centre (Care, innovation, research in pediatric, adolescent and young adults oncology), Institut Curie, Paris, France
- 3 UF de Génétique Moléculaire, Hôpital Armand Trousseau, APHP, Paris, France
- 4 Sorbonne Université, INSERM UMR S933, Paris, France.
- 5 Département de neuropathologie, groupe hospitalier Pitié-Salpêtrière, AP-HP, Paris, France.
- 6 INSERM U900, Institut Curie, Paris, France.
- 7 Neurochirurgie, GH Pitie-Salpêtrière-Charles Foix, APHP, Paris, France.
- 8 Centre de Référence Maladies Rares « Malformations et Maladies Congénitales du Cervelet », et Département de Génétique, Hôpital Armand Trousseau, GHUEP, APHP, Paris, France
- 9 Département de neuropédiatrie, Hôpital Armand Trousseau, APHP, Paris, France
- 10 Institut Curie, PSL Research University, Translational Research Department, Genomics platform, Paris, F-75248 France
- 11 Sorbonne Université, Inserm, UMS Omique, Plateforme Post-génomique de la Pitié-Salpêtrière, P3S, F-75013, Paris, France
- 12 Université Paris Sud, Université Paris-Saclay, CNRS UMR 3347, INSERM U1021, Orsay, France.
- 13 Institut Curie, PSL Research University, CNRS UMR, INSERM, Orsay, France
- 14 Inserm U830, PSL Université, Institut Curie, Paris, France
- 15 Université Paris Descartes, Sorbonne Paris Cité, Paris, France

**Correspondance to:** Dr Franck Bourdeaut.

[franck.bourdeaut@curie.fr](mailto:franck.bourdeaut@curie.fr)

Pediatric Oncology Departement

26, rue d'Ulm 75248 PARIS CEDEX 05 France

fax number: +33153104005

**Key words:**

Medulloblastoma, adult, Pitt-Hopkins, TCF4, predisposition

**No conflict of interest**

Pitt–Hopkins syndrome (PTHS, MIM #610954) is a rare neurodevelopmental disease due to heterozygous loss of function variants in the TCF4 gene (transcription factor 4, MIM #602272) [1]. TCF4 encodes a basic helix-loop-helix (bHLH) transcription factor which is highly expressed in the nervous system during early development and is involved in cellular proliferation and differentiation. To date, approximately 200 PTHS patients have been reported since the first clinical description in 1978 [1, 11, 12]. The limited number of cases described and their early age precludes establishing a comprehensive phenotype, especially regarding cancer pre-disposition. Here we report the case of a 27-year-old woman affected by PTHS who developed a medulloblastoma (MB).

The PTHS patient, previously reported (P12) [11], harbored a typical facial gestalt, hypotonia, hyperventilation, had delayed walking, and never acquired language. The PTHS diagnosis was confirmed by identification of the heterozygous de novo pathogenic frameshift variant c.1241del, p.(Gly414Valfs\*48) in the TCF4 gene (NM\_001083962.1). The patient developed a posterior fossa tumor at the age of 27 years arising from the right cerebellar hemisphere (Fig. 1a). The tumor has been macroscopically completely resected and the anatomopathological examination established a diagnosis of classic MB with SHH immunohistochemical profile (filamin+ , GAB1+ , Supplementary Fig. 1). The patient was then treated using standard dose of craniospinal radiotherapy without post-radiation chemotherapy. Array-CGH performed on the tumor DNA revealed multiple copy number alterations including GLI2 amplification, but no MYC/MYCN amplification and no loss of heterozygosity at the TCF4 locus (Fig. 1d). Nanostring molecular subgrouping [8] and RNAseq analysis unambiguously confirmed the SHH group (Fig. 1b). Nonetheless, based on the DKFZ classifier tool (<https://www.molecularneurology.org>) [2], the

methylation analysis did not confidently match any CNS tumor class. The closest entity was SHH MB followed by IDH mutated gliomas (Supplementary Fig. 2; GSE126545). Sequencing of a custom cancer genes panel on tumor DNA identified the pathogenic variants c.-124C > T in the TERT promoter (NM\_198253.2) and c.514A > G, p.(Arg172Gly) in the IDH2 gene (NM\_002168.3) (Fig. 1c; Supplementary Fig. 2). The TERT promoter variation occurred in a hot spot position which is recurrent in adult SHH MB [9]. No TCF4 second alteration was identified in the tumor sample, neither at the genomic nor at the transcript level (GSE126545).

A recently published large-scale analysis of germline pathogenic variants associated with MB revealed that SHH MB is the most likely to arise in the context of a genetic predisposition [10]. Germline PTCH1 and SUFU pathogenic variants occur in approximately 10% of SHH MB in infants and young children, while recessive diseases affecting DNA damage repair (i.e., Fanconi Anemia with bi-allelic inactivation of PALB2 or BRCA2) are also associated with pediatric SHH MB. SHH MB in older patients is much less frequently associated with germline pathogenic variants, apart from rare TP53 pathogenic variants in Li–Fraumeni syndrome. Thus, no gene is yet known to specifically predispose to adult-onset SHH MB. The case we report here raises the hypothesis that PTHS due to germline *TCF4* pathogenic variants confers increased susceptibility to adult-onset SHH MB. However, a random association of those two rare diseases needs to be carefully ruled out in future studies.

Indeed, to date no MB has been described in PTHS patients. Nevertheless, scarcely more than 200 PTHS cases have been reported worldwide. In one of the biggest cohorts described, including 101 PTHS patients [12], only two were older than 25 years old. Hence,

the susceptibility to adult-onset MB in PTHS is difficult to accurately estimate because of the small number of identified PTHS patients that have reached adulthood, which could mask a slightly elevated age-related risk.

Remarkably, in a large-scale genome wide analysis of 491 MB, eleven SHH MBs and one group 4 MB were reported to show somatic TCF4 variants [7]. TCF4 variants in SHH MB were mainly truncating variants (8/11) in favor of a role of TCF4 loss in SHH MB. Of note, in line with our case, all but one was heterozygous, with no second hit, strongly suggesting a haploinsufficiency mechanism for TCF4 in promoting MB. Thus, TCF4 may act similar to other tumor suppressors and cancer-predisposing genes, for which heterozygous truncating mutations leading to haploinsufficiency are now recurrently reported (updated review in [4]). Of note, all pathogenic TCF4 variants were described in adult-onset tumors [7], strongly suggesting an age-related oncogenic effect of TCF4 pathogenic variations. In line with previous studies investigating the role of CREBBP loss of function in MB according to developmental stages [6], Hell-wig et al. describe in this issue of *Acta Neuropathologica* that TCF4 abrogation increases cell proliferation only on post-natal granule cell progenitors, providing experimental evidence for an age-related oncogenic effect of TCF4 pathogenic variations [3]. Altogether, these results suggest a bivalent effect of TCF4 pathogenic variations, i.e., inducing a developmental disorder in the developing brain and an increased risk of malignant transformation in the adult cerebellum. This could explain the low known incidence of MB in PTHS patients, and fits with the late-onset in this case report.

Of note, all but one of the aforementioned TCF4 mutated MB belonged to the SHH group [7], a finding consistent with previous results identifying TCF4 recurrent pathogenic

variations as one of the most frequent somatic events in adult SHH MB [5]. The strikingly unbalanced distribution of TCF4 alterations among the four MB groups strongly suggests a specific cooperation between constitutive activation of the SHH pathway and TCF4 loss of function. Yet how TCF4 pathogenic variations interact and synergize with the SHH pathway remains to be more deeply investigated.

We postulate that TCF4 germline alterations confer increased susceptibility to late-onset SHH MB. The aging of patients affected by PTHS should bring further insights into this hypothesis and would strengthen the need for further exploration of the potential synergy between TCF4 and the SHH pathway in MB.

## References

1. Amiel J, Rio M, de Pontual L, Redon R, Malan V, Boddaert N et al (2007) Mutations in TCF4, encoding a class I basic helix-loop-helix transcription factor, are responsible for Pitt-Hopkins syndrome, a severe epileptic encephalopathy associated with autonomic dysfunction. *Am J Hum Genet* 80:988–993. <https://doi.org/10.1086/515582>
2. Capper D, Jones DTW, Sill M, Hovestadt V, Schrimpf D, Sturm D et al (2018) DNA methylation-based classification of central nervous system tumours. *Nature* 555:469–474. <https://doi.org/10.1038/nature26000>
3. Hellwig M, Laufer MC, Bockmayr M, Spohn M, Merk DJ, Har-rison L et al (2019) TCF4 (E2-2) harbors tumor suppressive functions in SHH medulloblastoma. *Acta Neuropathol.* <https://doi.org/10.1007/s00401-019-01982-5>
4. Inoue K, Fry EA (2017) Haploinsufficient tumor suppressor genes. *Adv Med Biol* 118:83–122
5. Kool M, Jones DTW, Jäger N, Northcott PA, Pugh TJ, Hovestadt V et al (2014) Genome sequencing of SHH medulloblastoma predicts genotype-related response to smoothed inhibition. *Cancer Cell* 25:393–405. <https://doi.org/10.1016/j.ccr.2014.02.004>
6. Merk DJ, Ohli J, Merk ND, Thatikonda V, Morrissy S, Schoof M et al (2018) Opposing effects of CREBBP mutations govern the phenotype of Rubinstein–Taybi syndrome and adult SHH medulloblastoma. *Dev Cell* 44:709–724.e6. <https://doi.org/10.1016/j.devcel.2018.02.012>
7. Northcott PA, Buchhalter I, Morrissy AS, Hovestadt V, Weischenfeldt J, Ehrenberger T et al (2017) The whole-genome landscape of medulloblastoma subtypes. *Nature* 547:311–317. <https://doi.org/10.1038/nature22973>
8. Northcott PA, Shih DJH, Remke M, Cho Y-J, Kool M, Hawkins C et al (2012) Rapid, reliable, and reproducible molecular sub-grouping of clinical medulloblastoma samples. *Acta Neuropathol (Berl)* 123:615–626. <https://doi.org/10.1007/s00401-011-0899-7>
9. Remke M, Ramaswamy V, Peacock J, Shih DJH, Koelsche C, Northcott PA et al (2013) TERT promoter mutations are highly recurrent in SHH subgroup medulloblastoma. *Acta Neuropathol (Berl)* 126:917–929. <https://doi.org/10.1007/s00401-013-1198-2>
10. Waszak SM, Northcott PA, Buchhalter I, Robinson GW, Sutter C, Groebner S et al (2018) Spectrum and prevalence of genetic predisposition in medulloblastoma: a retrospective genetic study and prospective validation in a clinical trial cohort. *Lancet Oncol* 19:785–798. [https://doi.org/10.1016/S1470-2045\(18\)30242-0](https://doi.org/10.1016/S1470-2045(18)30242-0)
11. Whalen S, Héron D, Gaillon T, Moldovan O, Rossi M, Devilard F et al (2012) Novel comprehensive diagnostic strategy in Pitt-Hopkins syndrome: clinical score and further delineation of the TCF4 mutational spectrum. *Hum Mutat* 33:64–72. <https://doi.org/10.1002/humu.21639>
12. de Winter CF, Baas M, Bijlsma EK, van Heukelingen J, Routledge S, Hennekam RCM (2016) Phenotype and natural history in 101 individuals with Pitt-Hopkins syndrome through an internet questionnaire system. *Orphanet J Rare Dis* 11:37. <https://doi.org/10.1186/s13023-016-0422-2>



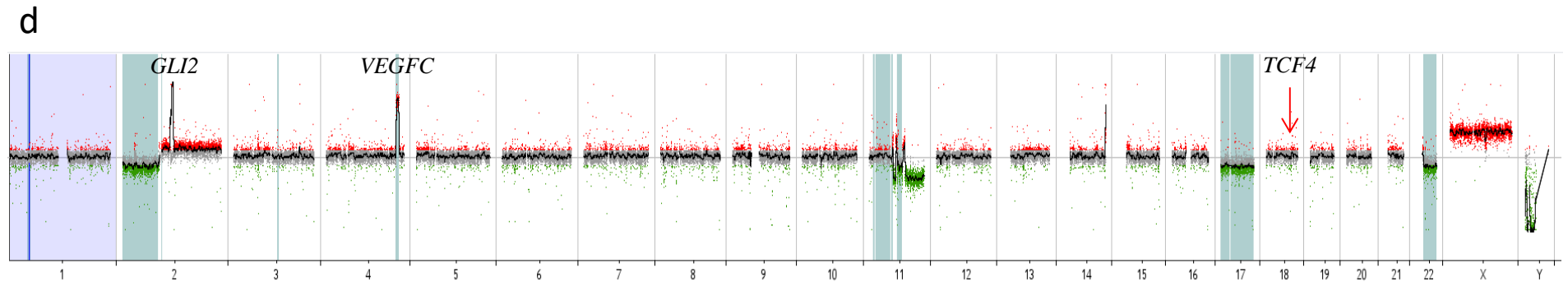
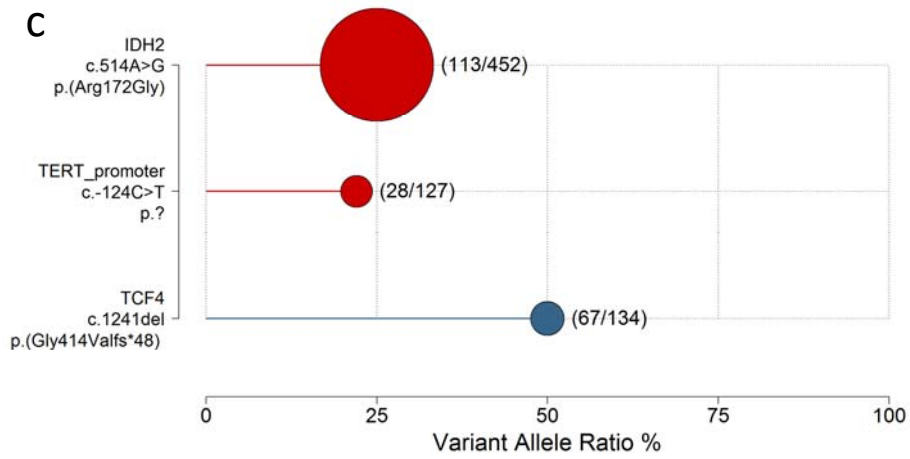
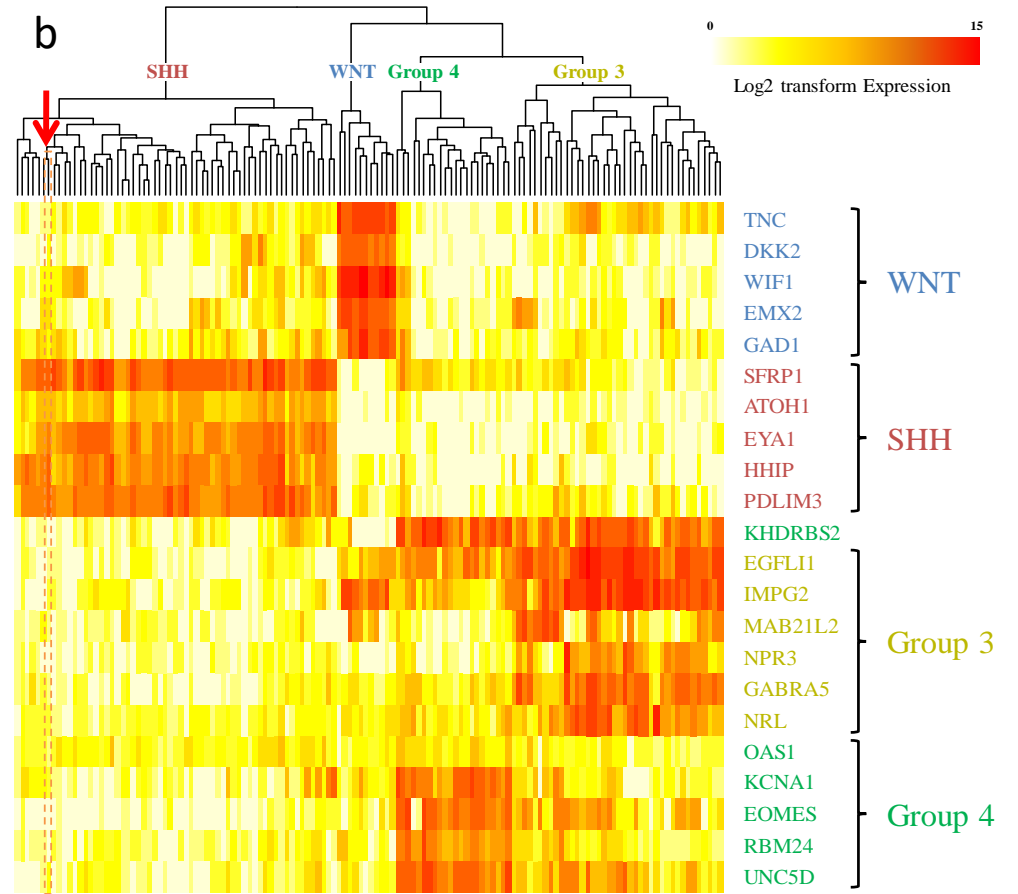
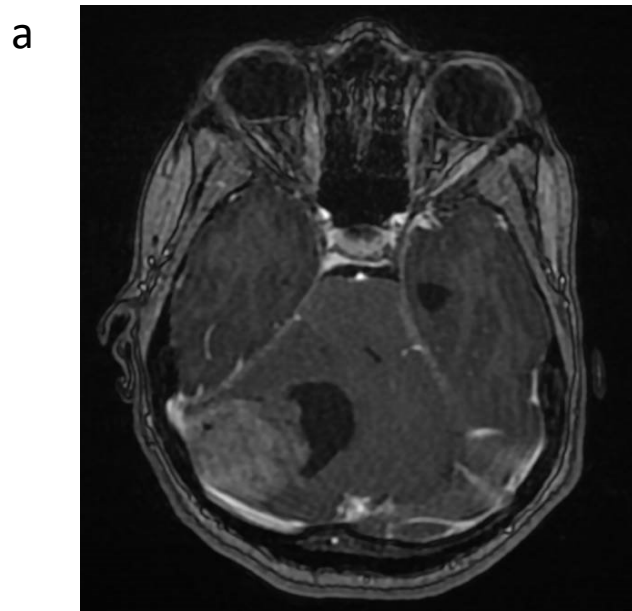
## Legends

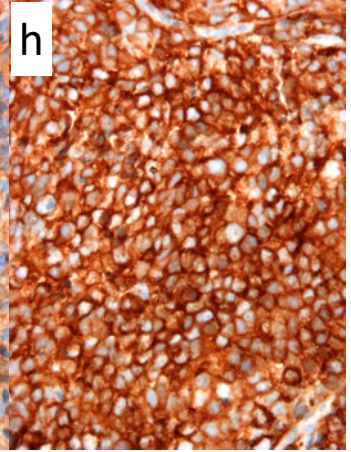
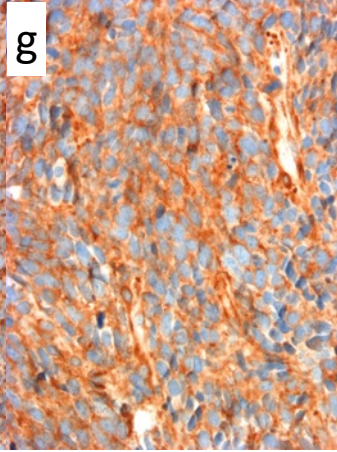
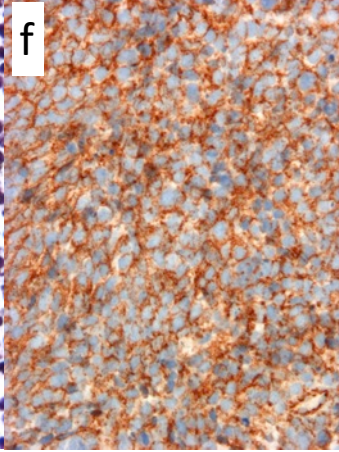
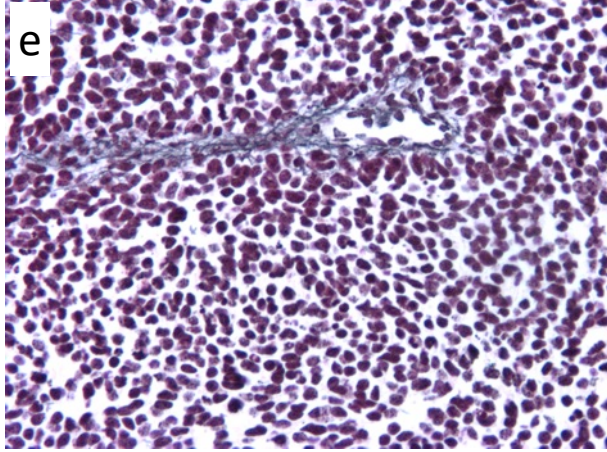
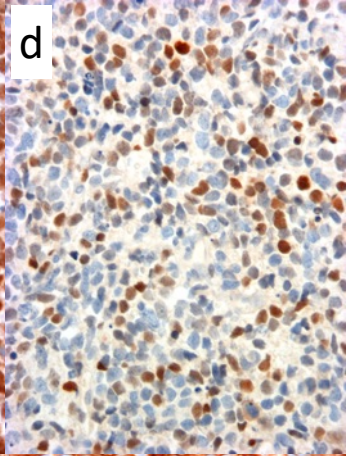
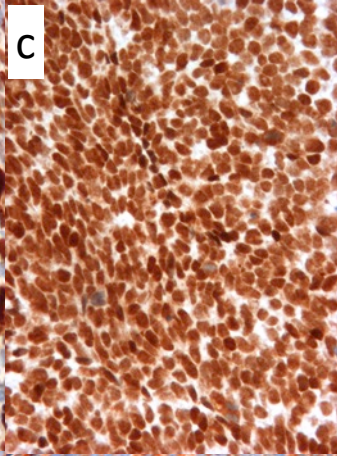
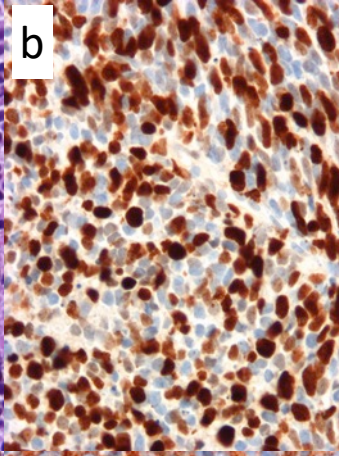
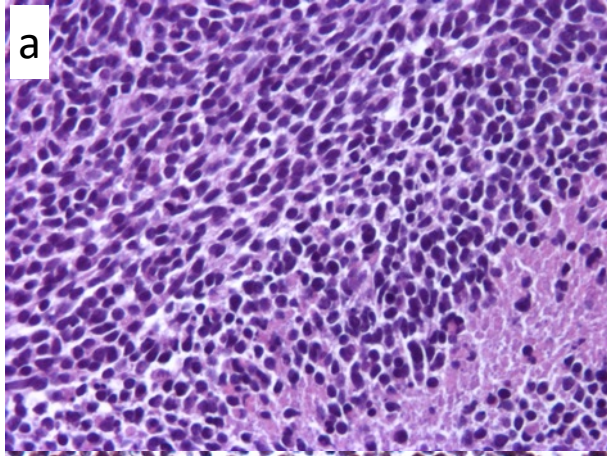
Figure 1. Imaging and molecular features of the tumor. (a) Brain MRI axial T1 with gadolinium injection revealing a tumor in the right cerebellar hemisphere. (b) Hierarchical clustering of 113 MB from Curie dataset, based on the Nanostring signature made of 22 medulloblastoma subgroup-specific genes: the tumor reported in this correspondence is indicated by the arrow and orange dotted line box. Analysis of tumor DNA by the Curie Institute custom cancer panel assessing known cancer-related genes; the two relevant mutated genes in this panel are indicated in bubbles; bubbles sizes are correlated to sequencing depth at variant positions and the read count for alternative variant related to the reference nucleotide is specified in brackets. The allele ratio is specified in the x axis. (c) The *TCF4* pathogenic variation assessed by NGS is added in blue. (d) Array-CGH performed on tumor DNA revealed several copy number alterations including *GLI2* and *VEGFC* amplifications but no loss of heterozygosity at the *TCF4* locus (red arrow; 18q12.2).

Supplementary Figure 1. Histopathological features of the tumor. (a) Hematoxylin and eosin staining showed a histological aspect of classic medulloblastoma with necrosis. (b) Immunostainings showed a diffusely high Ki67 proliferation index, (c) a maintained expression of SMARCB1/INI1, and (d) a mild positivity of P53. (e) Reticulin staining showed no reticulenic network between tumor cells. (f) Immunostainings showed a membrane staining for Beta-catenin, and (g) a strong positivity for Filamin-1 and (h) GAB1 favoring the genetic group of SHH-activated medulloblastomas.

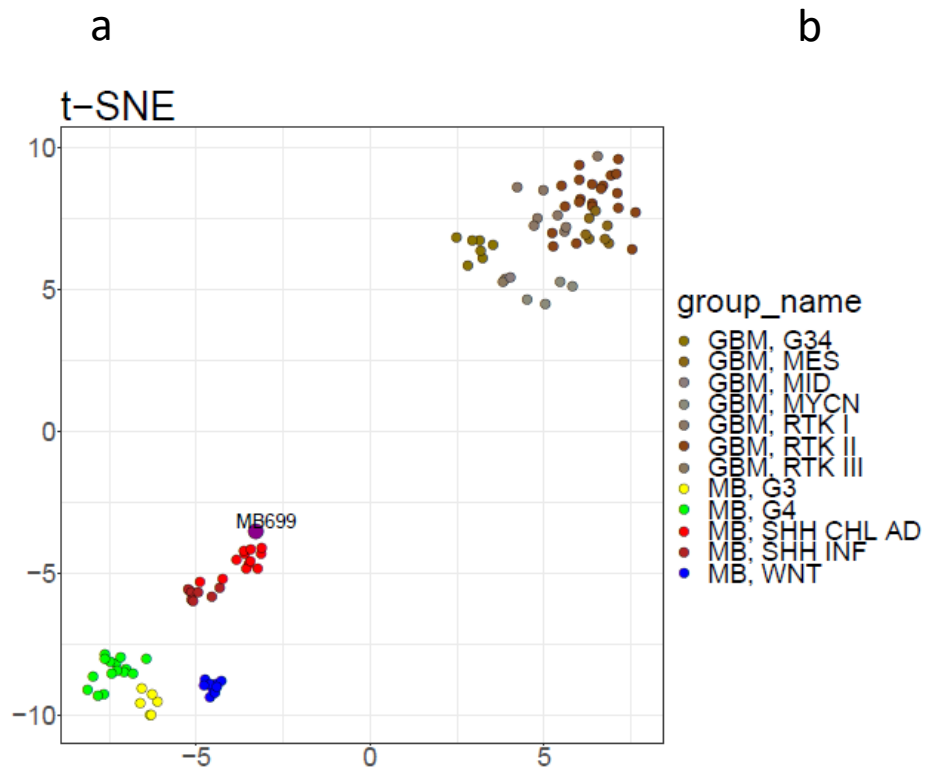
Supplementary Figure 2. Methylation and genomic tumor data. (a) t-distributed Stochastic Neighbor Embedding (t-SNE) analysis using DNA methylation data (generated using

HumanMethylation450K array type) of glioblastoma (GBM) and medulloblastoma (MB) samples published in Capper *et al.* (2018) [2] and DNA methylation data of our case (generated using HumanMethylationEPIC array type) named MB699. (b) MNP2.0-based DNA methylation class prediction calibrated scores for our case (DKFZ classifier version: 11b4). The other scores (data not shown) are inferior to 0.01. (c) Analysis of tumor DNA of our case by the Curie Institute custom cancer panel assessing known cancer-related genes (8 alterations), compared with the proportion of relevant tumor DNA alterations of these genes for all SHH MB (SHH MB column) and *TCF4* mutated SHH MB (*TCF4* mutated SHH MB column) samples published by Northcott *et al.* (2017) [6].









Methylation class	Name	Calibrated Scores ▼
MB, SHH CHL AD	methylation class medulloblastoma, subclass SHH A (children and adult)	0.424
O IDH	methylation class IDH glioma, subclass 1p/19q codeleted oligodendroglioma	0.051
A IDH, HG	methylation class IDH glioma, subclass high grade astrocytoma	0.038
A IDH	methylation class IDH glioma, subclass astrocytoma	0.035
GBM, RTK I	methylation class glioblastoma, IDH wildtype, subclass RTK I	0.025
DMG, K27	methylation class diffuse midline glioma H3 K27M mutant	0.02
MB, G3	methylation class medulloblastoma, subclass group 3	0.019
PLEX, PED B	methylation class plexus tumor, subclass pediatric B	0.018
EPN, RELA	methylation class ependymoma, RELA fusion	0.017
MNG	methylation class meningioma	0.014
MB, G4	methylation class medulloblastoma, subclass group 4	0.013
LGG, PA PF	methylation class low grade glioma, subclass posterior fossa pilocytic astrocytoma	0.013
GBM, RTK II	methylation class glioblastoma, IDH wildtype, subclass RTK II	0.013
GBM, G34	methylation class glioblastoma, IDH wildtype, H3.3 G34 mutant	0.013
PLEX, PED A	methylation class plexus tumor, subclass pediatric A	0.012
EPN, PF A	methylation class ependymoma, posterior fossa group A	0.012
ETMR	methylation class embryonal tumor with multilayered rosettes	0.01

**C**

Gene	Alteration	NM	DNA	Protein	Allelic Ratio ▲	Depth	SHH MB	TCF4 mutated SHH MB
<i>SUZ12</i>	Stopgain	NM_015355.3	c.856C>T	p.(Arg286*)	16,9%	142X	0/123	0/11
<i>WT1</i>	Nonsynonymous_SNV	NM_024426.4	c.835G>T	p.(Gly279Cys)	18,8%	490X	0/123	0/11
<i>IDH2</i>	Nonsynonymous_SNV	NM_002168.3	c.514A>G	p.(Arg172Gly)	22,3%	1234X	0/123	0/11
<i>TERT</i>	Upstream	NM_198253.2	c.-124C>T	p.?	46,0%	126X	44/123	8/11
<i>BCOR</i>	Nonsynonymous_SNV	NM_017745.5	c.5071G>C	p.(Asp1691His)	49,8%	1069X	7/123	0/11
<b><i>TCF4</i></b>	<b>Frameshift</b>	<b>NM_001083962.1</b>	<b>c.1241del</b>	<b>p.(Gly414Valfs*48)</b>	<b>50,0%</b>	<b>201X</b>	<b>11/123</b>	<b>11/11</b>
<i>RASA1</i>	Splicing_SNV	NM_022650.2	c.1822A>G	p.(Thr608Ala)	54,0%	272X	0/123	0/11
<i>GLI2</i>	Full gene amplification	-	-	-	-	-	8/123	0/11
<i>PTCH1</i>	WT	-	-	-	-	-	50/123	8/11
<i>IDH1</i>	WT	-	-	-	-	-	5/123	1/11