



HAL
open science

An unusual community-acquired invasive and multi systemic infection due to ExoU-harboring *Pseudomonas aeruginosa* strain: Clinical disease and microbiological characteristics

Alexandre Elabbadi, Stéphane Pont, Charlotte Verdet, Patrick Plésiat, François Cretin, Guillaume Voiriot, Muriel Fartoukh, Michel Djibré

► To cite this version:

Alexandre Elabbadi, Stéphane Pont, Charlotte Verdet, Patrick Plésiat, François Cretin, et al.. An unusual community-acquired invasive and multi systemic infection due to ExoU-harboring *Pseudomonas aeruginosa* strain: Clinical disease and microbiological characteristics. *Journal of Microbiology, Immunology and Infection*, 2020, 53 (4), pp.647-651. 10.1016/j.jmii.2019.06.008 . hal-02345592

HAL Id: hal-02345592

<https://hal.science/hal-02345592>


Submitted on 4 Nov 2019

HAL is a multi-disciplinary open access archive for the deposit and dissemination of scientific research documents, whether they are published or not. The documents may come from teaching and research institutions in France or abroad, or from public or private research centers.

L'archive ouverte pluridisciplinaire **HAL**, est destinée au dépôt et à la diffusion de documents scientifiques de niveau recherche, publiés ou non, émanant des établissements d'enseignement et de recherche français ou étrangers, des laboratoires publics ou privés.

Available online at www.sciencedirect.com

ScienceDirect

journal homepage: www.e-jmii.com

Short Communication

An unusual community-acquired invasive and multi systemic infection due to ExoU-harboring *Pseudomonas aeruginosa* strain: Clinical disease and microbiological characteristics

Alexandre Elabbadi ^a, Stéphane Pont ^b, Charlotte Verdet ^c,
 Patrick Plésiat ^d, François Cretin ^b, Guillaume Voiriot ^{a,e,f},
 Muriel Fartoukh ^{a,e,f}, Michel Djibré ^{a,*}

^a AP-HP, Hôpital Tenon, Service de Réanimation médico-chirurgicale, 4 rue de la Chine, 75020, Paris Cedex 20, France

^b Biology of Cancer and Infection, University of Grenoble Alpes, U1036 INSERM, CEA, ERL5261 CNRS, Grenoble, France

^c AP-HP, Hôpital Tenon, Service de Bactériologie-Hygiène, Groupe hospitalier des Hôpitaux Universitaires de l'Est Parisien, Paris, France

^d Centre National de Référence de la résistance aux antibiotiques, CHRU Jean Minjoz, Besançon, France

^e Faculté de médecine Sorbonne Université, France

^f Groupe de Recherche Clinique CARMAS, Collégium Gallilée, UPEC, France

Received 13 March 2019; received in revised form 12 June 2019; accepted 26 June 2019

Available online ■ ■ ■

KEYWORDS

Pseudomonas aeruginosa;
 Virulence;
 Invasive infection

Abstract Community-acquired *Pseudomonas aeruginosa* infections are rare. Most cases involve patients either with underlying immunosuppression or structural chronic lung diseases. We report here an atypical case of a severe community-acquired invasive infection due to a hypervirulent ExoU-producing strain, in an immunocompetent patient.

Copyright © 2019, Taiwan Society of Microbiology. Published by Elsevier Taiwan LLC. This is an open access article under the CC BY-NC-ND license (<http://creativecommons.org/licenses/by-nc-nd/4.0/>).

* Corresponding author.

E-mail address: michel.djibre@aphp.fr (M. Djibré).

<https://doi.org/10.1016/j.jmii.2019.06.008>

1684-1182/Copyright © 2019, Taiwan Society of Microbiology. Published by Elsevier Taiwan LLC. This is an open access article under the CC BY-NC-ND license (<http://creativecommons.org/licenses/by-nc-nd/4.0/>).

Please cite this article as: Elabbadi A et al., An unusual community-acquired invasive and multi systemic infection due to ExoU-harboring *Pseudomonas aeruginosa* strain: Clinical disease and microbiological characteristics, Journal of Microbiology, Immunology and Infection, <https://doi.org/10.1016/j.jmii.2019.06.008>

Introduction

Community-acquired *Pseudomonas aeruginosa* (*P. aeruginosa*) infections are rare. Most cases involve patients either with underlying immunosuppression or structural chronic lung diseases, such bronchiectasis. The virulence factors play an important role that may lead to acute lung injury, bacteremia, sepsis and invasion of tissues. *P. aeruginosa* possesses a virulence mechanism known as the type III secretion system. The type III secretory toxin, ExoU is a major virulence factor associated with poor clinical outcome. We report here an atypical case of a community-acquired invasive infection due to a hypervirulent ExoU-producing strain, in an immunocompetent patient.

Case report

A 49 year-old man was admitted to the intensive care unit (ICU) of our hospital for septic shock. He had no previous underlying disease, except being a past smoker; he was not taking any medication and had no relation with any type of healthcare resources. Three days before ICU admission, he returned to France by car from Turkey where he had stayed by the sea for 1 month. During the trip, he reported diffuse abdominal and back pain with nausea, vomiting and diarrhoea associated with chills. He was referred to the Emergency department of our hospital. Glasgow Coma Scale was 15/15, blood pressure 75/50 mmHg, heart rate 100 beats/min, respiratory rate 22/min, room air pulse oximetry 98% and core temperature 37.1 °C. Physical examination revealed diffuse abdominal pain, mainly in the right upper quadrant of the abdomen, and subcutaneous erythematous nodules on the torso, pelvis and legs (Fig. 1A). Laboratory tests on ICU admission were as follows: leukocytosis 14×10^9 cell/L (N 4–10 $\times 10^9$ /L), polymorphonuclear neutrophils (PMNs) 11.8×10^9 (N 1.5–7 $\times 10^9$ /L), haemoglobin 11.6 g/dL (N 12–18 g/dL), platelet count 113×10^9 cells/L (N 150–400 $\times 10^9$ /L), serum creatinine 307 μ mol/l (N 60–120 μ mol/l), serum urea 19.5 mmol/L (N 3–7), lactate 3.2 mmol/l (<2 mmol/l), prothrombin time 60% (N 70–120%), serum bilirubin 19 μ mol/l (N < 17), serum aspartate aminotransferase 544 IU/L (N < 35), serum alanine aminotransferase 299 IU/L (N < 43), and CRP 476.3 mg/L (N < 5). Chest X-ray and computed tomography (CT) scan showed a left-upper

alveolar infiltrate with excavation, suggestive of a necrotizing pneumonia (Fig. 1B), while abdominal and pelvic CT scans were unremarkable.

Fluid expansion and catecholamines were administered promptly. Empirical antimicrobial therapy including cefotaxime, spiramycin and linezolid was initiated. The patient rapidly developed acute respiratory failure requiring high-flow nasal cannula oxygen therapy.

A bronchoalveolar lavage (BAL) was performed on day 1, revealing neutrophilic alveolitis (200×10^3 /ml, 59% PMNs) without any microorganism on Gram stain. Skin biopsies were also performed on day 1 on subcutaneous erythematous nodules. Pathological examination revealed lesions of neutrophilic panniculitis associated with lesions of vasculitis with thrombosis suggestive of ecthyma gangrenosum. Finally, a wild-type *P. aeruginosa* yielded on BAL, blood, and urine cultures on day 2, and all the strains had the same profile of antimicrobial resistance. Viral and fungal cultures of BAL were negative. Empirical antibiotics were stopped, and ceftazidime and ciprofloxacin were initiated on day 3.

A binocular blurring followed by a scotoma of the right eye occurred on day 1. A brain MRI was performed and found no abnormalities. The fundus examination revealed subretinal nodules (Fig. 1C) suggestive of endogenous endophthalmitis. Two intravitreal injections of ceftazidime were administered on day 8, resulting in a retinal atrophy scarring on day 15. A functional disability of the left leg associated with pain occurred on day 4, suggestive of cruralgia. There were no signs of spondylodiscitis or discoradicular conflict on spinal MRI. A repeat abdominal and pelvic CT scan revealed a nodular hypodensity of 12 mm at the femoral insertion of the left ilio-psoas muscle. Finally, a (18F)-fluorodeoxyglucose positron emission tomography was performed and identified several areas of increased metabolic activity within the lungs, the trochanteric insertion of the left psoas, the prostate and the subcutaneous nodules. A trans-oesophageal echocardiography ruled out an infectious endocarditis.

The patient gradually improved with a rapid decrease of oxygen therapy and a complete recovery of renal and liver functions. It should be noted that cutaneous lesions co-existed at different stages of development, some of which had evolved towards gangrenous ulcers like ecthyma gangrenosum. However, the right eye scotoma still persisted. Finally, the patient was discharged from hospital on day 24.

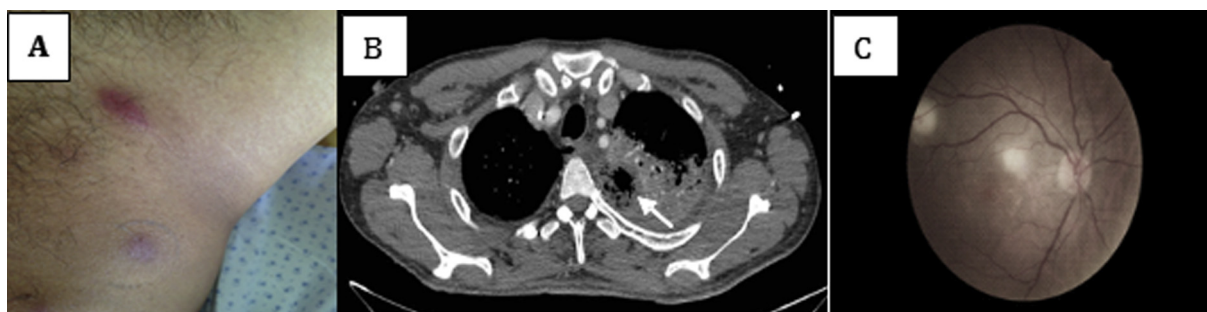


Figure 1. Multiple necrotizing organ damages due to *P. aeruginosa*. 1A. Erythematous nodules of the left side of the pelvis. 1B. Section of lung CT scan showing air-space consolidation with necrosis (arrows) and air-bronchogram of the left upper lobe. 1C. Colour fundus photograph of the left eye with two areas of retinitis.

Additional investigations were performed to search for an immunosuppressive status, including HIV testing, neutrophils count and functional activity, serum protein electrophoresis, and biological dysimmunity. The results of these tests were all negative, and there was no underlying diabetes.

Microbiological findings

The strain of *P. aeruginosa* (YIK) was investigated further. This isolate turned out to belong to a quite rare sequence type, ST137 (<https://pubmlst.org/paeruginosa/>), and like the hypervirulent strain PA14,¹ to code for an exotoxin named ExoU. Considering the impressive ability of this strain to invade multiple organs in an immunocompetent individual, we examined the capacity of the strain to induce epithelial cell death *in vitro*. The A549 cells were incubated with YIK and laboratory strains PAO1 (that

produces the less potent exotoxin ExoS⁺) and PA14 (ExoU⁺), in presence of propidium iodide (PI) to monitor the kinetics of membrane permeability over 300 min post-infection. The cytotoxicity is presented as an increase in fluorescence intensity (AU) and the calculated area under curve (AUC) as described in the material and methods section. In accordance with the fact that ExoS⁺ strains do not trigger necrosis,² PAO1 did not induce any significant incorporation of PI within epithelial cells within time lapse of 300 min, whereas YIK was the most cytotoxic strain (Fig. 2A and B), causing even more cell death than the ExoU-positive strain PA14. To assess whether the cytotoxicity induced by YIK was dependent on an active type III secretion system (T3SS), we used an immune serum directed against T3SS protective antigen PcrV, which is an essential component of this secretion machinery. This serum was previously shown to inhibit *P. aeruginosa* induced haemolysis.³ Indeed, as shown in Fig. 2C and D, the cytotoxicity of the YIK strain towards A549 cells was significantly inhibited in the

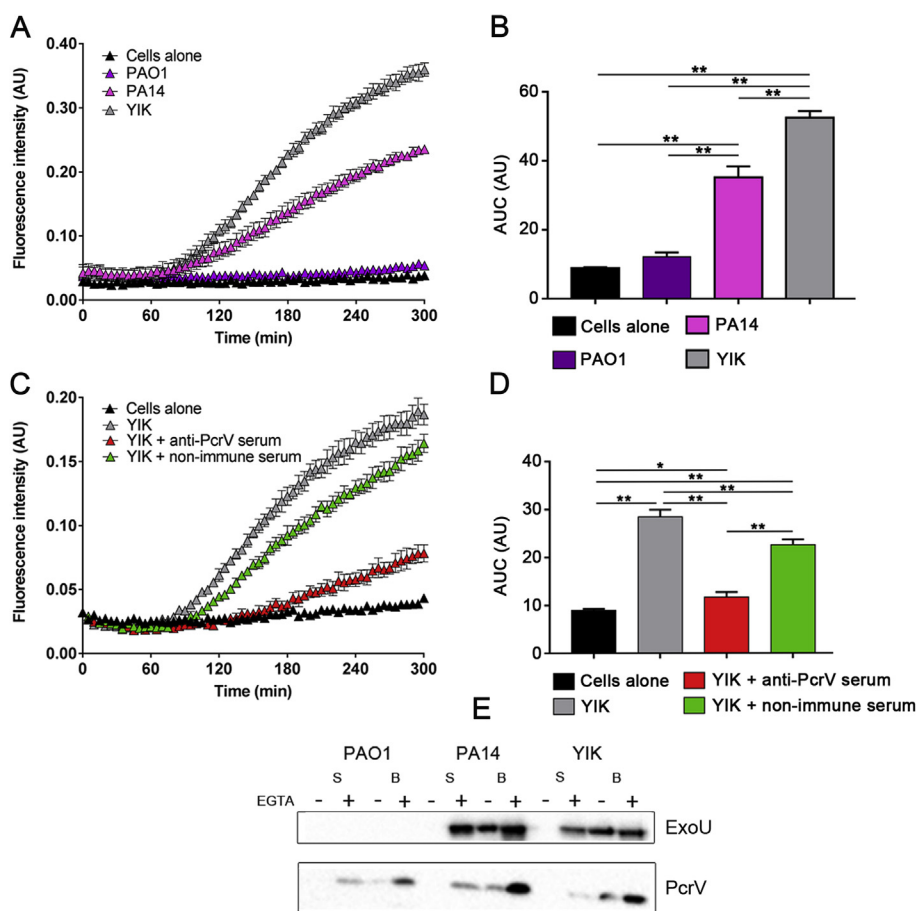


Figure 2. *P. aeruginosa* YIK is cytotoxic on epithelial cells by using the T3SS effector ExoU. **2A.** Kinetic of propidium iodide (PI) incorporation in A549 cells in presence of PAO1 (ExoS⁺), PA14 (ExoU⁺) or YIK, at a MOI of 10. At each time point, data represent mean \pm SD of triplicates. Results are representatives of three independent experiments. **2B.** Cytotoxicity curves in A. represented as area under curves (AUC). ANOVA, $p < 0.001$; Holm-Sidak's post-hoc test: $**p < 0.001$. **2C.** Kinetic of PI incorporation in A549 cells infected with YIK, in presence of either immune serum directed against the protective antigen PcrV (anti-PcrV) or non-immune serum. At each time point, data represent mean \pm SD of quadruplicates. Results are representatives of three independent experiments. **2D.** Cytotoxicity curves in C. represented as area under curves (AUC). ANOVA, $p < 0.001$; Holm-Sidak's post-hoc test: $*p = 0.007$, $**p < 0.001$. **2E.** Detection of PcrV and ExoU. PAO1, PA14 and YIK culture supernatants (S) or bacterial cells (B) were analysed by immunoblotting using specific antibodies raised against PcrV and ExoU. T3SS was induced where indicated by adding EGTA and MgCl₂, as described in Materials and Methods.

presence of anti-PcrV serum. The kinetics and the inhibition of cytotoxicity on A549 cell by the anti-PcrV serum confirmed that the YIK induced cell death was caused by the well-described T3SS effector ExoU.⁴ To confirm the synthesis and secretion of ExoU by YIK, we performed immunodetection of secreted proteins by different strains under conditions where T3SS is induced by chelation of calcium (+EGTA). ExoU was readily detected in whole bacteria (B) and supernatants (S) of PA14 (positive control strain) and YIK, and was absent from PA01, that lacks gene *exoU*. PcrV was detected in all three strains. In conclusion, these experiments show that the YIK strain is highly cytotoxic on epithelial cells in an ExoU-dependent manner.

Materials and methods (online supplement)

Discussion

This observation is remarkable for several reasons. First, the illness was community-acquired and occurred in a subject with no known immunodeficiency. Second, the illness was severe with septic shock and direct multiple necrotizing organ damages (necrotizing pneumonia, muscular abscesses, ecthyma gangrenosum, retinal involvement and prostatic localisation). Third, an unusual virulent strain of *P. aeruginosa* with ExoU positive phenotype was identified.

In a retrospective series of 39 cases of community-acquired *P. aeruginosa* bacteraemia, Kang et al.⁵ reported that the primary site of infection was the lung (23% of cases), followed by the biliary (20%) and urinary (12%) tracts. The initial presentation was associated with septic shock in 38% of cases, overall mortality rate was 38.5% and only 2 patients were immunocompetent. The overall incidence of community-acquired *P. aeruginosa* bacteraemia is estimated at 1 to 1.3/100,000,⁶ with a greater incidence in men. The associated ocular damage due to *P. aeruginosa* is also very atypical and few cases have been reported in immunocompetent patients.⁷ In children, several severe community-acquired cases of *P. aeruginosa* infection have been reported in the context of Shanghai fever. Fever and diarrhoea are the most common clinical presentation and ecthyma gangrenosum occurs in more than 50% of cases.⁸ In our case, there was no sign of enteritis, despite the fact that the patient suffered initial digestive symptoms.

Virulence of *P. aeruginosa* is multifactorial.^{9,10} Among the factors that *P. aeruginosa* may produce during infection, ExoU is of major clinical importance because of its high cytotoxic and procoagulant activities, as well as its role in vascular hyperpermeability, platelet activation and thrombus formation.¹¹ ExoU is a phospholipase directly injected into the eukaryotic cells by the needle-like T3SS of *P. aeruginosa*, with subsequent cell death and tissue necrosis. Infections related to ExoU-producing strains are associated with more severe clinical symptoms and poorer outcomes, as compared with ExoS-positive (ExoU-negative) isolates.^{11,12} They are also responsible for acute lung epithelial injury, sepsis, and corneal lesions.¹³ In 328 *P. aeruginosa* clinical and environmental isolates collected worldwide, Pirnay J-P et al. reported that 73% of isolates harboured the *exoS* gene, which was indicative of an

invasive phenotype, and that 23% of isolates harboured the *exoU* gene, which was associated with virulence and disease severity.¹⁴ There was no difference in the distribution of genotypes between clinical and environmental isolates, except for the cystic fibrosis (CF) isolates that exhibited almost exclusively the *exoS*+/*exoU*- genotype, which might be required for the process of a bronchial colonization in CF lungs. The examination of the Shanghai fever strains showed that 59% of them were carrying an ExoU strain, and 41% an ExoS strain. Shanghai fever isolates with *exoU* were significantly more cytotoxic than isolates with *exoS*.⁸

Innovative therapeutic strategies, based on T3SS-targeting antibodies or inhibitors, have been proposed over the last decade to combat nosocomial strains of *P. aeruginosa*.^{11,15} As illustrated here, such novel approaches could also be valuable in the treatment of life-threatening community-acquired infections.

Conclusion

We report a rare case of a particularly severe lower respiratory tract infection with septic shock and multiple direct necrotizing organ damages due to a highly cytotoxic strain of *P. aeruginosa* exhibiting an ExoU-phenotype. Physicians should be aware of the possible occurrence of such an infection in immunocompetent hosts, to early target anti-pseudomonal antimicrobial treatments.

Ethical approval and consent to participate

Not applicable.

Consent to publish

The patient gave a written consent for publication of his potentially-identifying information (including individual details and images).

Availability of data and materials

Not applicable.

Competing interests

The authors declare that they have no competing interests.

Funding

The work in "Biology of Cancer and Infection" laboratory in Grenoble is funded by grants from Agence Nationale de la Recherche (ANR-15-CE11-0018-01), the Laboratory of Excellence GRAL (ANR-10-LABX-49-01) and the Fondation pour la Recherche Médicale (Team FRM 2017, DEQ20170336705). S.P. received the PhD fellowship from French Ministry of Education and Research.

Authors' contributions

MD and MF drafted the manuscript. AE and GV were responsible for the clinical management and therapy. PP, CV, FC and SP performed the investigation of the strain of *P. aeruginosa*. All authors read and approved the final manuscript.

Acknowledgements

Not applicable.

References

1. Rahme LG, Stevens EJ, Wolfort SF, Shao J, Tompkins RG, Ausubel FM. Common virulence factors for bacterial pathogenicity in plants and animals. *Science* 1995;268:1899–902.
2. Hauser AR. The type III secretion system of *Pseudomonas aeruginosa*: infection by injection. *Nat Rev Microbiol* 2009;7:654–65.
3. Goure J, Broz P, Attree O, Cornelis GR, Attree I. Protective anti-V antibodies inhibit *Pseudomonas* and *Yersinia* translocon assembly within host membranes. *J Infect Dis* 2005;192:218–25.
4. Sato H, Frank DW. ExoU is a potent intracellular phospholipase. *Mol Microbiol* 2004;53:1279–90.
5. Kang C-I, Kim S-H, Park WB, et al. Clinical features and outcome of patients with community-acquired *Pseudomonas aeruginosa* bacteraemia. *Clin Microbiol Infect Off Publ Eur Soc Clin Microbiol Infect Dis* 2005;11:415–8.
6. Schechner V, Nobre V, Kaye KS, et al. Gram-negative bacteremia upon hospital admission: when should *Pseudomonas aeruginosa* be suspected? *Clin Infect Dis Off Publ Infect Dis Soc Am* 2009;48:580–6.
7. Diaz-Valle D, Benitez del Castillo JM, Fernandez Acenero MJ, Santos-Bueso E, Martinez de la Casa JM, Garcia-Sanchez J. Endogenous *Pseudomonas* endophthalmitis in an immunocompetent patient. *Eur J Ophthalmol* 2007;17:461–3.
8. Chuang C-H, Wang Y-H, Chang H-J, et al. Shanghai fever: a distinct *Pseudomonas aeruginosa* enteric disease. *Gut* 2014;63:736–43.
9. Lee DG, Urbach JM, Wu G, et al. Genomic analysis reveals that *Pseudomonas aeruginosa* virulence is combinatorial. *Genome Biol* 2006;7:R90.
10. Gellatly SL, Hancock REW. *Pseudomonas aeruginosa*: new insights into pathogenesis and host defenses. *Pathog Dis* 2013;67:159–73.
11. Sawa T, Shimizu M, Moriyama K, Wiener-Kronish JP. Association between *Pseudomonas aeruginosa* type III secretion, antibiotic resistance, and clinical outcome: a review. *Crit Care Lond Engl* 2014;18:668.
12. Peña C, Cabot G, Gómez-Zorrilla S, et al. Influence of virulence genotype and resistance profile in the mortality of *Pseudomonas aeruginosa* bloodstream infections. *Clin Infect Dis Off Publ Infect Dis Soc Am* 2015;60:539–48.
13. Ramirez JC, Fleiszig SMJ, Sullivan AB, Tam C, Borazjani R, Evans DJ. Traversal of multilayered corneal epithelia by cytotoxic *Pseudomonas aeruginosa* requires the phospholipase domain of exoU. *Investig Ophthalmol Vis Sci* 2012;53:448–53.
14. Pirnay J-P, Bilocq F, Pot B, et al. *Pseudomonas aeruginosa* population structure revisited. *PLoS One* 2009;4:e7740.
15. Katoh H, Yasumoto H, Shimizu M, et al. IV immunoglobulin for acute lung injury and bacteremia in *Pseudomonas aeruginosa* pneumonia. *Crit Care Med* 2016;44:e12–24.

Appendix A. Supplementary data

Supplementary data to this article can be found online at <https://doi.org/10.1016/j.jmii.2019.06.008>.