



HAL
open science

Pathobiology and innate immune responses of gallinaceous poultry to clade 2.3.4.4A H5Nx highly pathogenic avian influenza virus infection

Kateri Bertran, Mary J. Pantin-Jackwood, Miria F. Criado, Dong-Hun Lee,
Charles L. Balzli, Erica Spackman, David L. Suarez, David E. Swayne

► To cite this version:

Kateri Bertran, Mary J. Pantin-Jackwood, Miria F. Criado, Dong-Hun Lee, Charles L. Balzli, et al.. Pathobiology and innate immune responses of gallinaceous poultry to clade 2.3.4.4A H5Nx highly pathogenic avian influenza virus infection. *Veterinary Research*, 2019, 50 (1), pp.89. 10.1186/s13567-019-0704-5 . hal-02344201

HAL Id: hal-02344201

<https://hal.science/hal-02344201>

Submitted on 4 Nov 2019

HAL is a multi-disciplinary open access archive for the deposit and dissemination of scientific research documents, whether they are published or not. The documents may come from teaching and research institutions in France or abroad, or from public or private research centers.

L'archive ouverte pluridisciplinaire **HAL**, est destinée au dépôt et à la diffusion de documents scientifiques de niveau recherche, publiés ou non, émanant des établissements d'enseignement et de recherche français ou étrangers, des laboratoires publics ou privés.

RESEARCH ARTICLE

Open Access



Pathobiology and innate immune responses of gallinaceous poultry to clade 2.3.4.4A H5Nx highly pathogenic avian influenza virus infection

Kateri Bertran^{1,2}, Mary J. Pantin-Jackwood¹, Miria F. Criado¹, Dong-Hun Lee^{1,3}, Charles L. Balzli^{1,4}, Erica Spackman¹, David L. Suarez¹ and David E. Swayne^{1*} 

Abstract

In the 2014–2015 Eurasian lineage clade 2.3.4.4A H5 highly pathogenic avian influenza (HPAI) outbreak in the U.S., backyard flocks with minor gallinaceous poultry and large commercial poultry (chickens and turkeys) operations were affected. The pathogenesis of the first H5N8 and reassortant H5N2 clade 2.3.4.4A HPAI U.S. isolates was investigated in six gallinaceous species: chickens, Japanese quail, Bobwhite quail, Pearl guinea fowl, Chukar partridges, and Ring-necked pheasants. Both viruses caused 80–100% mortality in all species, except for H5N2 virus that caused 60% mortality in chickens. The surviving challenged birds remained uninfected based on lack of clinical disease and lack of seroconversion. Among the infected birds, chickens and Japanese quail in early clinical stages (asymptomatic and listless) lacked histopathologic findings. In contrast, birds of all species in later clinical stages (moribund and dead) had histopathologic lesions and systemic virus replication consistent with HPAI virus infection in gallinaceous poultry. These birds had widespread multifocal areas of necrosis, sometimes with heterophilic or lymphoplasmacytic inflammatory infiltrate, and viral antigen in parenchymal cells of most tissues. In general, lesions and antigen distribution were similar regardless of virus and species. However, endotheliotropism was the most striking difference among species, with only Pearl guinea fowl showing widespread replication of both viruses in endothelial cells of most tissues. The expression of IFN- γ and IL-10 in Japanese quail, and IL-6 in chickens, were up-regulated in later clinical stages compared to asymptomatic birds.

Introduction

The H5 A/goose/Guangdong/1/1996 (Gs/GD) lineage of highly pathogenic avian influenza (HPAI) virus has spread across multiple continents, affecting wild birds, poultry, and humans [1]. In 2014, Gs/GD lineage clade 2.3.4.4 Group A, also described as Buan2-like or icA, spread across Asia, Europe, and North

America was a reassortant H5N2 with five Eurasian avian influenza (AI) virus gene segments (including the H5 clade 2.3.4.4 hemagglutinin) and three North American wild bird lineage low pathogenic AI (LPAI) virus gene segments [3, 4] detected in November 2014 in British Columbia, Canada. Concurrently, an H5N8 HPAI virus with all 8 gene segments of Eurasian origin and the reassortant H5N2 HPAI virus were detected in a captive-reared gyrfalcon (*Falco rusticolus*) and a wild Northern pintail duck (*Anas acuta*), respectively, in Washington state, U.S. Over the next 7 months, the U.S. poultry industry experienced an unprecedented outbreak caused by these H5 HPAI viruses, with more than 7.5 million turkeys and 42.1 million chickens having died

*Correspondence: david.swayne@usda.gov

¹ Exotic and Emerging Avian Viral Diseases Research Unit, Southeast Poultry Research Laboratory, U.S. National Poultry Research Center, Agricultural Research Service, U.S. Department of Agriculture, Athens, GA 30605, USA

Full list of author information is available at the end of the article



or culled during the control program [5] and widespread bans on exports of U.S. poultry and poultry products [6].

During the outbreak, virus was detected in 21 backyard flocks that included: (i) minor gallinaceous poultry species (quail, guinea fowl, pheasants, partridges, and grouse) on the same premise; (ii) different breeds of chickens and turkeys; and (iii) domestic ducks and geese [5, 7]. Minor gallinaceous poultry are commonly raised in small commercial outdoor operations and backyards, or are sometimes marketed in temporary or permanent live poultry markets (LPMs) [8], which highlights their importance as intermediary hosts in virus transmission under poor biosecurity conditions. Globally, two facts support their importance in AI epidemiology: (i) outdoor-raised systems often have higher potential of AI virus exposure from wild waterfowl, contributing to the increase of AI outbreaks and their impact [9]; and (ii) LPMs, with tendency for prevalent AI virus [10], contain a wide variety of live poultry and non-poultry species, providing the ideal environment for introduction, maintenance, and adaptation of viruses, as well as potential conditions for zoonotic transmission [11–13]. Although there is no direct epidemiological link between minor gallinaceous poultry from backyard flocks and chickens and turkeys from commercial farms in these U.S. clade 2.3.4.4A virus outbreaks [14], minor poultry have been identified or suggested as key link species in other outbreaks [15–18]. Moreover, the game bird poultry industry and backyard flocks in both developed and developing countries are known to suffer from HPAI epidemics [19].

Gallinaceous species infected with clade 2.3.4.4 viruses generally exhibit clinical disease, mortality, and pathological features that are indicative of HPAI virus infection [2], although several studies have pointed out that clade 2.3.4.4 H5 reassortants have reduced virulence compared to the parental Gs/GD H5N1 virus [2, 4, 20]. Lee et al. examined the pathogenicity of clade 2.3.4.4 viruses in Japanese quail and showed severe clinical disease, virus shedding, and contact transmission following challenge with $6 \log_{10}$ EID₅₀ of Korean Group A H5N8 virus [21]. Prior to the emergence of clade 2.3.4.4 viruses, numerous outbreaks of both LPAI and HPAI viruses had been reported in species such as Japanese quail, Pearl guinea fowl, and Ring-necked pheasants [19, 22]. Some studies suggest that certain gallinaceous species like Ring-necked pheasants and Japanese quail are more susceptible to LPAI viruses from free-living aquatic birds than chickens and turkeys [19, 23–28]. Others show that Japanese quail and European quail (*Coturnix c. coturnix*) may support the replication of almost all LPAI virus subtypes [26, 29]. Japanese quail are recognized as mixing vessels for avian and mammalian viruses [30–33] and facilitate the adaptation of duck viruses to chicken [34–36]. In addition,

several studies have proven that HPAI viruses are able to infect and cause lesions and death in many gallinaceous species under experimental conditions [19, 37, 38]. Collectively, these findings highlight the relevance of avian species other than chickens, turkeys, and domestic ducks in the epidemiology of AI in small farming operations, village poultry, and LPMs.

Recently, we experimentally confirmed that the first U.S. Eurasian H5N8 and reassortant H5N2 clade 2.3.4.4A HPAI viruses lacked adaptation to chickens, i.e. 4.4 and 5.7 \log_{10} mean bird infectious doses (BID₅₀), respectively [39], but were more adapted to minor gallinaceous poultry, i.e. $<3.7 \log_{10}$ BID₅₀ for direct infection [40]. In addition, these higher BID₅₀ required to produce chicken infections also resulted in greatly reduced contact transmission. Here we present the pathology results from our previously published infectivity studies [39, 40]. Specifically, we examined the severity and distribution of gross and microscopic lesions in experimentally infected birds and identified the organs and cell types with AI virus replication. In addition, we analyzed the innate immune response in chickens and Japanese quail at different clinical stages.

Materials and methods

Viruses

The influenza A isolates A/Gyrfalcon/Washington/40188-6/2014 (H5N8) and A/Northern pintail/Washington/40964/2014 (H5N2) were used as challenge viruses. These were the first two HPAI isolates from the U.S. outbreak and they are considered representative of the initial AI viruses from wild waterfowl introduction of both the Eurasian lineage H5N8 viruses and the reassortant Eurasian/North American lineage H5N2 viruses, respectively [40]. The viruses were propagated and titrated by allantoic sac inoculation of 9–10 day-old embryonated chicken eggs by standard methods [41].

Birds and housing

Six species of the order Galliformes were utilized: specific pathogen free White Leghorn chickens (*Gallus domesticus*; Southeast Poultry Research Laboratory [SEPR], Athens, GA, USA), Japanese quail (*Coturnix c. japonica*; McMurray Hatchery, Webster City, IA, USA), Bobwhite quail (*Colinus virginianus*; M&M Quail Farm Inc., Gillsville, GA, USA), Pearl guinea fowl (*Numida meleagris*; McMurray Hatchery), Chukar partridges (*Alectoris chukar*; McMurray Hatchery), and Ring-necked pheasants (*Phasianus colchicus*; McMurray Hatchery). All birds were inoculated at 4 weeks of age. Prior to inoculation, 30–50% of birds were randomly sampled and confirmed negative for current infection with or previous exposure to AI virus [42, 43]. Each experimental group was housed

separately in negative-pressure isolators with HEPA-filtered inlet air. Birds had ad libitum access to feed and water. All procedures were performed according to the requirements of the protocol approved by the Institutional Laboratory Animal Care and Use Committee.

Experimental design and sampling

Bird inoculation and sampling were performed as previously described [39, 40]. Briefly, each species was divided into three groups: H5N2 virus inoculated group, H5N8 virus inoculated group, and sham-inoculated group (10 to 17 birds/virus group and 5 birds/sham group). Birds were inoculated intratracheally with approximately $6 \log_{10}$ mean egg infectious doses (EID₅₀) of H5N2 or H5N8 virus, or sterile allantoic fluid. This challenge dose was necessitated for comparison with previous HPAI pathogenesis studies [21, 25, 44–48]. Clinical signs were monitored twice a day during the first 4 days post-challenge (dpc) and daily thereafter. Two birds from each species exposed to each virus and showing severe clinical signs or found dead were necropsied at 2 and 3 dpc, except for chickens and Japanese quail that were necropsied at four time points based on clinical progression, as previously described [39, 40]: asymptomatic (twice, at 18 and 24 h post-challenge [hpc]), listless (showing mild to moderate clinical signs), and moribund or dead. One sham-inoculated bird of each species was euthanized and necropsied at the first and the last necropsy time points. At time of necropsy, portions of nasal cavity, brain, thymus, trachea, lung, proventriculus, duodenum, pancreas, jejunum-ileum, spleen, kidney, adrenal gland, gonad, liver, skeletal muscle, comb, and heart were collected in 10% buffered formalin (Thermo Fisher Scientific, Waltham, MA, USA) for histopathologic evaluation. Severely sick birds were euthanized. At 10 dpc, surviving birds were bled to evaluate antibody titers and euthanized.

Histopathology and immunohistochemistry

Tissues in 10% formalin were processed for routine hematoxylin and eosin (HE) staining and immunohistochemical (IHC) staining using a mouse-derived monoclonal antibody (P13C11, developed at SEPRL) specific for type A influenza virus nucleoprotein [39, 44].

Quantification of innate immune response genes

The mRNA expression of genes representative of different innate pathways, including type 1 interferon (IFN) (IFN- α), type 2 IFN (IFN- γ), Th1-type cytokine (interleukin (IL)-12, IL-18), Th2-type cytokine (IL-10), pro-inflammatory cytokine (IL-6), and toll-like receptor (TLR-7), was quantified from formalin-fixed paraffin-embedded (FFPE) lung and spleen tissues

from chickens and Japanese quail necropsied at different clinical stages of infection. The FFPE tissue sections and RNA extraction were performed as previously described [49] with modifications. Briefly, ten 10- μ m-thick sections were collected and deparaffinized, total RNA was extracted using the RNeasy FFPE Kit (Qiagen, Germantown, MD, USA), and RNA concentration and purity were measured on a NanoDrop 1000 Spectrophotometer (Thermo Fisher Scientific). The cDNA was synthesized with the High Capacity cDNA Reverse Transcription Kit (Thermo Fisher Scientific) using approximately 500 ng of RNA and following the manufacturer's protocol and thermal cycling conditions. The mRNA expressions of the aforementioned genes were quantified by quantitative real time PCR (qRRT-PCR) using gene specific primers and conditions previously described [50, 51] with modifications. Briefly, qRRT-PCR was performed on a 7500 FAST Real-time PCR System (Applied Biosystems, Foster City, CA, USA). The qRRT-PCR reaction mixture contained 1.0 μ L of sample cDNA, 0.1 to 0.5 μ L of forward and reverse primers (1 to 5 μ M each, standardized for efficient detection of target gene and absence of dimers) (Additional file 1), 5 μ L of KAPA SYBR FAST MasterMix (KAPA Biosystems, Wilmington, MA, USA), and nuclease free water for a final reaction volume of 10.0 μ L. The thermal profile consisted of one cycle for 3 min of polymerase activation at 95 °C, followed by 45 cycles of PCR at 95 °C for 10 s and specific annealing temperature of 60 °C for 30 s. After the completion of amplification step, the dissociation (melting) curve was performed at 95 °C for 10 s and 60 °C for 30 s. The relative expression of each target gene was normalized using the housekeeping gene β -actin (Additional file 1). The expression of β -actin was constant within each species regardless of clinical stage and tissue. The relative quantification of gene expression was done by the $2^{-\Delta\Delta Ct}$ formula and expressed as fold change in infected birds compared to sham (negative control) birds. Results from H5N2 and H5N8 virus infected birds were pooled due to similar mRNA expression levels for all the genes. Similarly, results from moribund and dead birds were pooled due to similar mRNA expression levels for all the genes. After normalization with β -actin, gene expression results in infected birds were analyzed based on species, tissue, and clinical stage and compared to sham birds. Our data had a non-parametric distribution and was analyzed with Kruskal–Wallis test and Dunn's Multiple Comparison Test using Prism 7 (GraphPad software, San Diego, CA, USA). A p value of < 0.05 was considered to be significant.

Results

Clinical signs, mortality, and gross lesions

Previously, we determined that intratracheal inoculation of $6 \log_{10}$ EID₅₀ of either H5N2 or H5N8 virus caused 80–100% mortality in the six gallinaceous species [39, 40], with the exception of H5N2 virus that caused 60% mortality in chickens [39] (Table 1). Mean death times (MDTs) ranged from 2.5 to 5.2 days and were not significantly different among them [39, 40] (Table 1). The surviving birds were considered uninfected based on lack of clinical disease and lack of HA antibodies at the end of the experiment [39, 40]. Among the infected birds, clinical signs and gross lesions are described in detail for chickens [39] and the other gallinaceous species [40] elsewhere.

Microscopic findings

Multifocal areas of necrosis, sometimes accompanied by heterophilic or lymphoplasmacytic inflammatory infiltrate, with viral antigen were widespread in the parenchymal cells of most tissues (Tables 2, 3, 4 and Figure 1). In general, asymptomatic or listless chickens and Japanese quail did not show significant histopathological lesions or antigen staining, with some exceptions like severe vacuolation and necrosis of the pancreatic acinar epithelium of a listless H5N2 virus infected Japanese quail (Figure 1A) and nucleoprotein-positive pancreatic acinar cells (Figure 1D). More severe lesions and widespread viral staining were observed in moribund and dead birds, especially in lung, heart, brain, pancreas, spleen, and adrenal gland.

Collectively, similar type and severity of histological lesions and antigen staining were observed with all species and both viruses, although some differences between the two viruses were observed (Tables 2 and 3). In the pancreas, lesions and staining were mild and infrequent in H5N2 virus infected birds, but were severe and widespread in H5N8 virus infected birds; in the thymus and

cloacal bursa, the opposite was observed. A remarkable difference among species was observed in the kidney: Chukar partridges and Ring-necked pheasants (Figure 1H) displayed mild to moderate nephrosis and widespread staining, while chickens, Japanese quail, and Bobwhite quail had generally no lesions or staining, and lesions and staining in Pearl guinea fowl tissues were in between in extent. Another difference among species was found in nasal cavity, which was especially affected in Bobwhite quail (Figures 1B–E) and Pearl guinea fowl. Virus staining in vascular endothelial cells was infrequent in all the species examined except for Pearl guinea fowl, which showed extensive endothelial cell staining with both viruses. In particular, vascular endothelial cells expressed virus antigen in the following tissues: sheath arterioles of spleen of H5N2 virus inoculated Japanese quail; comb of H5N8 and nasal cavity of H5N2 virus inoculated Bobwhite quail; systemically in Pearl guinea fowl (Figure 1F); ovary of H5N8 virus inoculated Ring-necked pheasants; spleen and proventriculus of H5N2 and brain of H5N8 virus inoculated Chukar partridges.

Immune gene expression profiles

The mRNA expression of innate immune response genes is summarized in Figure 2. The mRNA levels of IFN- γ were significantly up-regulated in lung of moribund/dead Japanese quail compared to asymptomatic birds. Similarly, the mRNA levels of IL-10 were significantly up-regulated in both lung and spleen of Japanese quail in later clinical stages compared to earlier clinical stages. In chickens, IL-6 was the only gene with significant variation among clinical stages, as its mRNA levels were significantly up-regulated in spleen of moribund/dead chickens compared to asymptomatic ones. Several genes were down-regulated in some clinical stages when compared to shams, like IFN- α , IL-12, and IL-18 for both

Table 1 Summary results of gallinaceous poultry challenged with $6 \log_{10}$ EID₅₀ of A/northern pintail/Washington/40964/2014 (H5N2) and A/gyrfalcon/Washington/40188-6/2014 (H5N8). Data from [39, 40]

Species	H5N2			H5N8		
	Mortality ^a	MDT ^b	Log ₁₀ BID ₅₀ ^c	Mortality ^a	MDT ^b	Log ₁₀ BID ₅₀ ^c
Chicken	3/5 (60%)	3.0	5.7	5/5 (100%)	4.1	4.4
Japanese quail	4/5 (80%)	2.8	3.7	4/5 (80%)	2.5	3.2
Bobwhite quail	7/7 (100%)	4.7	<2	8/8 (100%)	4.9	<2
Pearl guinea fowl	5/5 (100%)	2.8	3.0	5/5 (100%)	3.8	3.0
Chukar partridge	8/8 (100%)	4.1	3.6	7/8 (87.5%)	5.2	3.6
Ring-necked pheasant	8/8 (100%)	4.7	3.4	8/8 (100%)	4.8	3.0

^a #dead birds/total (%)

^b MDT, mean death time: #dead birds \times dpc/total dead birds (expressed as dpc). MDTs were not statistically different among species or between viruses

^c BID₅₀, mean bird infectious dose

Table 2 Microscopic lesions and viral antigen distribution in gallinaceous inoculated with A/Northern pintail/Washington/40964/2014 (H5N2) HPAI virus

	Chicken		Japanese quail		Bobwhite quail		Pearl guinea fowl		Chukar partridge		Ring-necked pheasant	
Clinical stage or day post-challenge ^a	Asymptomatic Listless Moribund/dead		Asymptomatic Listless Moribund/dead		2d 2d 3d 3d	2d 2d	2d 2d	2d 2d 3d 3d	2d 2d 3d 3d	2d 2d 3d 3d	2d 2d 3d 3d	
Tissue	Histo score ^b	IHC score ^c	Histo score ^b	IHC score ^c	Histo score ^b	IHC score ^c	Histo score ^b	IHC score ^c	Histo score ^b	IHC score ^c	Histo score ^b	IHC score ^c
Nasal cavity	- + ++	- + +	- - -	- - -	++ - ++ +++	+++ +++ +++ +++	- - -	+++ +++ -	- - -	- - ++	- - -	- - +
Trachea	- - -	- - -	- - -	- - -	- nt - -	- nt - -	- nt - -	- nt - -	- - -	- + -	- - nt ++	- - nt +
Lung	- - ++	- - ++	- ++ -	- +++ +	- - -	+++ + +++ +	+++ +++ -	+++ +++ -	- ++ +++ +++	- +++ +++ +++	- ++ ++ ++	- +++ +++ +++
Comb	- + +++	- + +++	nt nt nt	nt nt nt	- - -	+++ +++ -	- +++ -	+++ +++ -	- - -	- - ++	- - -	- - + +
Heart	- - +++	- + +++	- - ++	- - +++	+ + ++ +	+++ ++ +++ ++	- - -	++ ++ -	- + +	- +++ +++ +++	- + ++ +++	- +++ +++ +++
Brain	- - ++	- - +++	- - +	- - +++	- - -	+++ ++ +++ ++	- - -	+++ +++ -	- - +	- ++ +++	- + -	- + +++ +++
Proventriculus	- - +	- - +	nt nt nt	nt nt nt	- - -	- - -	- nt -	- nt -	- + -	- - +	- - +	- - ++
Intestine	- - +	- - +	- - -	- - -	- - +	- - +	- - -	++ +	- - -	- - -	- - -	- - ++
Pancreas	- - +	- - -	- + +++	- ++ +++	- - ++	- - +++	- - -	++ +	- + -	- + ++	- - +++	- - +++
Liver	- - -	- + +	- - -	- - -	- + -	- +++ -	- - -	+++ ++	- - -	- ++ -	- - +	- +++ ++
Spleen	- + ++	- + ++	- + -	- + +	+++ ++ + nt	++ +++ ++ nt	- - -	+++ +++ -	- + +	- +++ ++	- ++ ++	- +++ +++ +++
Thymus	- + ++	- - ++	- - nt	- - nt	- + + +	- + ++ ++	- - -	+++ ++	- + +	- + +++	- + +	- ++ ++ +++
Cloacal bursa	- - ++	- - ++	+ - +	- - -	+++ +++ ++ ++	++ + +++ ++	nt + +	nt + +	- - -	- + +	- ++ ++	- - ++ +++

Table 2 (continued)

Tissue	Histo score ^b	IHC score ^c	Histo score ^b	IHC score ^c	Histo score ^b	IHC score ^c	Histo score ^b	IHC score ^c	Histo score ^b	IHC score ^c	Histo score ^b	IHC score ^c
Kidney	-	-	-	-	-	-	-	++	-	-	-	-
	-	-	-	-	-	-	-	+	-	++	-	-
	+	++	-	-	-	-	-	-	-	++	+	+++
Gonad	-	-	-	-	-	+	nt	nt	-	-	nt	nt
	-	-	-	-	nt	nt	nt	nt	+	+++	nt	nt
	-	+	+	+++	nt	nt	nt	nt	+	++	nt	nt
Adrenal gland	-	-	-	-	-	-	nt	nt	-	-	-	-
	-	-	-	-	nt	nt	nt	nt	nt	nt	nt	nt
	+	++	+	+++	nt	nt	nt	nt	nt	nt	+++	+++
Skeletal muscle	-	-	-	-	-	-	-	++	-	-	-	-
	-	-	-	-	-	-	-	+	-	-	-	++
	-	-	-	-	-	+	-	-	-	-	nt	nt
											nt	nt

nt: no tissue.

^a For chicken and Japanese quail, scores represent the mean of the birds sampled at each clinical stage: asymptomatic (18 and 24 hpc), listless, and moribund/dead.

^b Histopathology score of lesions in HE staining: -, no lesions; +, mild; ++, moderate; +++, severe.

^c Immunohistochemical (IHC) staining: -, no antigen staining; +, infrequent; ++, common; +++, widespread.

species; IFN-γ and IL-10 for chickens; and TLR-7 for Japanese quail.

Discussion

Since 2014, Gs/GD H5 HPAI clade 2.3.4.4 viruses have spread rapidly and globally by migratory aquatic birds and have evolved through reassortment with prevailing local LPAI viruses [2]. Under both experimental and natural conditions, a wide range of avian species including wild and domestic waterfowl, domestic poultry, and even zoo birds appear to be permissive for infection by and/or transmission with these viruses [2]. In the present study, the pathobiology of the first U.S. clade 2.3.4.4A HPAI viruses in the 2014–2015 outbreak was investigated in six gallinaceous species. In addition, innate immune responses to infection with these viruses were analyzed in chickens and Japanese quail.

We previously confirmed that these two viruses were poorly adapted to chickens, based on high mean chicken infectious dose (i.e. 4.4 and 5.7 log₁₀ BID₅₀) and poor transmissibility [39], but were more adapted to minor gallinaceous poultry (<3.7 BID₅₀) [40]. As expected with 6 log₁₀ EID₅₀ challenge dose, some chickens did not become infected, as evident by only 60% mortality with H5N2, and the survivors were confirmed as not being infected because they lacked clinical disease, virus shedding, and HA antibodies [39]. By contrast, high morbidity and mortality rates and severe pathobiology upon challenge with 6 log₁₀ EID₅₀ confirmed that these viruses were highly pathogenic for minor gallinaceous poultry [40].

In the present study, chickens and Japanese quail were necropsied at four time-points based on clinical progression. Similar type and severity of histological lesions and antigen staining were observed in both species and for both viruses at each clinical stage, but differences were observed between clinical stages. Asymptomatic and listless chickens and Japanese quail (necropsied from 18 hpc to 2–3 dpc) lacked histopathological lesions or antigen staining in the tissue samples tested, while moribund or dead birds (necropsied from 2 to 5 dpc) displayed more severe lesions and widespread viral staining in known HPAI virus-target tissues and cells [47]. Although rapidity of clinical progression is highly dependent on the HPAI virus strain [47], our findings are in line with previous studies showing lack of antigen staining when clinical signs are absent, but severe histopathological lesions and widespread antigen staining in moribund or dead gallinaceous birds [44, 52]. Our observations suggest that there is a short time window between the initial virus replication in epithelial cells of the respiratory tract and the subsequent viremia and dissemination to multiple organs, where the virus replicates in parenchymal cells [53]. The other four species were necropsied when showing severe clinical signs or found dead (at 2 and 3 dpc), with both viruses showing similar type and severity of histological lesions and antigen detection in tissues across species.

Among the few discrepancies observed in virus replication in tissues of different species, the vascular endothelium showed the most remarkable variations. We observed that chickens, Japanese quail, Bobwhite quail,

Table 3 Microscopic lesions and viral antigen distribution in gallinaceous inoculated with A/Gyrfalcon/Washington/40188-6/2014 (H5N8) HPAI virus

	Chicken		Japanese quail		Bobwhite quail		Pearl guinea fowl		Chukar partridge		Ring-necked pheasant	
Clinical stage or day post-challenge ^a	Asymptomatic	Asymptomatic	Asymptomatic	Asymptomatic	2d	2d	2d	2d	2d	2d	2d	2d
	Listless	Listless	Listless	Listless	2d	2d	2d	2d	2d	2d	2d	2d
	Moribund/dead	Moribund/dead	Moribund/dead	Moribund/dead	3d	3d	3d	3d	3d	3d	3d	3d
					3d							
Tissue	Histo score ^b	IHC score ^c	Histo score ^b	IHC score ^c	Histo score ^b	IHC score ^c	Histo score ^b	IHC score ^c	Histo score ^b	IHC score ^c	Histo score ^b	IHC score ^c
Nasal cavity	-	-	-	-	++	+++	-	+++	-	-	-	-
	-	-	-	++	++	+++	-	+++	+	+	-	-
	+	+	+	++	++	+++	-	++	-	+	-	++
					+	+++			-	-	-	++
Trachea	-	-	-	-	-	-	-	-	-	-	-	-
	-	-	-	-	-	++	-	-	+	-	-	-
	+	+	-	-	-	-	-	-	-	+	+	++
					-	-			-	-	-	+
Lung	-	-	-	-	-	+	+++	+++	+++	+++	-	++
	-	-	++	+++	++	+++	+++	+++	+	++	-	-
	++	+	+	++	+	++	+++	+++	++	++	++	+++
					-	+			+	++	+	++
Comb	-	-	nt	nt	-	++	-	++	-	+	nt	nt
	-	-	nt	nt	-	++	-	++	-	-	-	-
	+++	+++	nt	nt	+	+++	+	++	-	++	nt	nt
					+	++			-	-	nt	nt
Heart	-	-	-	-	+	-	-	+++	+	++	+	++
	-	-	+	+++	+	+++	-	+++	+	++	-	++
	+++	+++	+++	+++	+	+++	+	+++	++	+++	++	+++
					++	+++			++	+++	++	+++
Brain	-	-	-	-	-	-	-	+++	-	++	-	+
	-	-	+	+++	-	+	-	+++	-	+	-	++
	+	+++	+++	+++	+	+++	-	+++	-	+++	++	+++
					-	+++			-	++	++	+++
Proventriculus	-	-	nt	nt	-	-	-	++	-	-	-	-
	-	-	nt	nt	-	+	-	+++	-	-	-	-
	-	+	nt	nt	-	-	-	-	-	-	-	++
					-	-			-	-	-	-
Intestine	-	-	-	-	-	-	nt	nt	-	+	-	-
	-	-	-	-	-	-	-	-	-	-	-	-
	-	-	-	-	-	-	-	-	-	-	-	++
					-	-			-	-	-	-
Pancreas	-	-	-	-	-	-	-	-	+	++	-	-
	-	-	++	+++	-	-	-	+	-	-	-	-
	+	+	+++	+++	++	++	++	+	+++	+++	+++	+++
					+	+			+++	+++	+	++
Liver	-	-	-	-	-	-	-	+	+	++	-	-
	-	-	-	-	-	+	-	++	-	-	-	-
	-	+	-	-	-	+	-	-	-	-	-	++
					-	-			-	-	++	-
Spleen	-	-	-	-	+	-	++	+++	+	-	+	-
	-	-	++	++	+	++	+	+++	-	-	+	-
	+	+	+	-	++	+++	+	++	-	+	-	+++
					+	++			-	-	-	-
Thymus	-	-	-	-	+	-	-	-	-	+	-	+
	-	-	nt	nt	-	-	-	-	-	-	-	-
	+	+	-	-	+	-	+	+	+	+	-	+++
					nt	nt			-	-	-	+++
Cloacal bursa	-	-	-	-	+	-	+	++	++	+	+	-
	-	-	nt	nt	-	-	-	-	-	-	-	-
	++	+	++	-	++	+	+	-	+	-	++	++
					++	++			-	+	++	-

Table 3 (continued)

Tissue	Histo score ^b	IHC score ^c	Histo score ^b	IHC score ^c	Histo score ^b	IHC score ^c	Histo score ^b	IHC score ^c	Histo score ^b	IHC score ^c	Histo score ^b	IHC score ^c
Kidney	–	–	–	–	–	–	–	++	+	++	–	–
	–	–	–	–	nt	nt	–	++	–	++	+	++
	+	+	–	–	–	–	+	++	+	++	++	+++
Gonad	–	–	–	–	nt	nt	nt	nt	–	–	–	–
	–	–	–	–	nt	nt	nt	nt	–	–	nt	nt
	+	+	++	++	nt	nt	nt	nt	–	–	–	++
Adrenal gland	–	–	–	–	nt	nt	nt	nt	++	+++	++	+++
	–	–	+	+++	nt	nt	nt	nt	nt	nt	++	+++
	++	+	++	+++	nt	nt	nt	nt	+++	+++	+++	+++
Skeletal muscle	–	–	–	–	–	–	–	+	–	–	–	–
	–	–	–	–	–	–	–	+	–	–	–	+
	–	+	+	–	–	+	–	+	–	–	+	+++
				–	–			–	–	+	++	

nt: no tissue.

^a For chicken and Japanese quail, scores represent the mean of the birds sampled at each clinical stage: asymptomatic (18 and 24 hpc), listless, and moribund/dead.

^b Histopathology score of lesions in HE staining: –, no lesions; +, mild; ++, moderate; +++, severe.

^c Immunohistochemical (IHC) staining: –, no antigen staining; +, infrequent; ++, common; +++, widespread.

Table 4 Microscopic lesions and viral antigen distribution in gallinaceous inoculated with clade 2.3.4.4 H5Nx HPAI virus

Tissue	Lesions	Cell types expressing virus antigen
Nasal cavity	Epithelial cell necrosis and desquamation, rhinitis, sinusitis, mononuclear cell infiltrate, heterophilic rhinitis	Vascular endothelial cells, nasal epithelial cells, nasal gland epithelium, mononuclear cells, bone marrow, autonomic nerves, buccal stratified epithelium, skeletal jaw muscle, feather pulp
Trachea	Focal necrosis with mild lymphoplasmacytic inflammatory infiltrate	Pseudostratified epithelial cells, vascular endothelial cells, sternotrachealis muscle
Lung	Severe interstitial pneumonia, edema, congestion, necrosis, monocytic infiltrate	Epithelium of air capillaries, mononuclear cells, necrotic debris
Comb	Edema, hemorrhages, necrosis	Vascular endothelial cells, mononuclear cells, necrotic debris, feather follicle epithelium, nerves in dermis, gland basilar cells, pili muscles
Heart	Focal necrosis of myocardiocytes	Myocardiocytes
Brain	Neuronal necrosis, gliosis, chromatolysis of Purkinje cell layer	Neurons, Purkinje cells, ependymal cells, glial cells, vascular endothelial cells
Proventriculus	Focal necrosis	Glandular and surface epithelium, nerves
Intestine	Lymphohistiocytic infiltration in submucosa	Mononuclear cells in lymphoid associated tissue, capillary endothelium and serosa
Pancreas	Degeneration of individual pancreatic acinar cells	Pancreatic acinar cells, duct cells, capillary endothelium
Liver	Focal necrosis with lymphoplasmacytic inflammatory infiltrate	Kupffer cells, hepatocytes, vascular endothelial cells, macrophages
Spleen	Multifocal areas of necrosis, hemorrhages, lymphoid depletion, hyperplasia of macrophage-phagocytic cells	Mononuclear cells, periarteriolar lymphoid sheaths, mononuclear phagocytic system
Thymus	Focal necrosis, lymphocyte depletion, apoptotic lymphocytes	Mononuclear cells, thymic epithelium in medullary area
Cloacal bursa	Lymphocyte necrosis and apoptosis, lymphocyte depletion, phagocytic hyperplasia	Mononuclear cells, medullary support cells, nerve ganglia
Kidney	Focal necrosis of tubular epithelium with lymphoplasmacytic inflammation	Tubular epithelial cells, glomerular cells
Gonad	Necrosis, focal interstitial necrosis with heterophilic infiltration	Tegument/interstitial tissue
Adrenal gland	Necrosis with mononuclear inflammatory infiltrate, heterophilic infiltrate	Corticotrophic and corticotrophic cells
Skeletal muscle	Scattered necrotic fibers	Myocytes

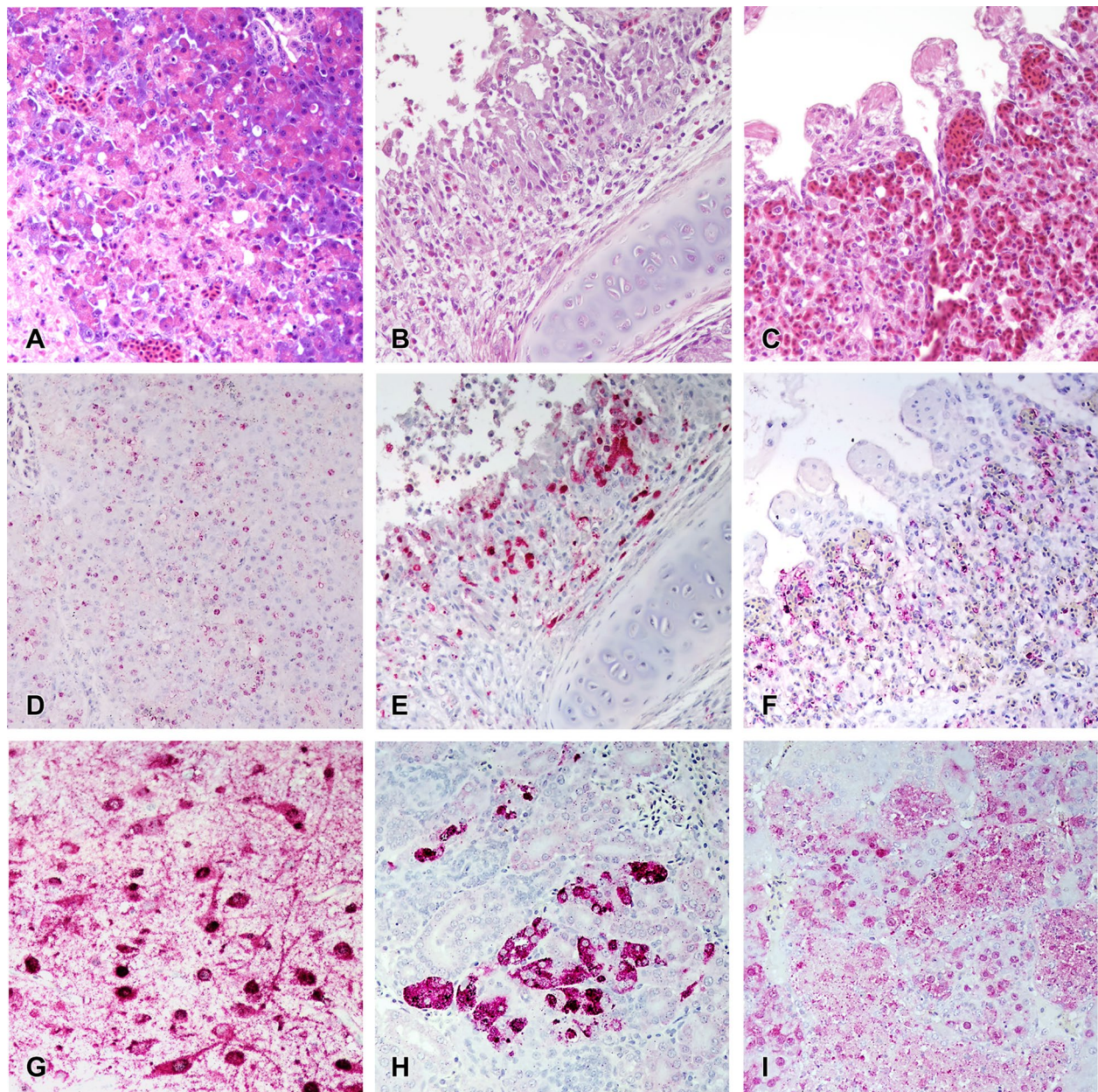


Figure 1 Histological lesions in gallinaceous following experimental infection with clade 2.3.4.4A HPAI viruses. A/Northern pintail/Washington/40964/2014 (H5N2); A/Gyrfalcon/Washington/40188-6/2014 (H5N8). Magnification $\times 40$. Japanese quail, listless (3 dpc), H5N2 virus, pancreas, HE staining (A) and IHC staining (D). Bobwhite quail, 3 dpc, H5N2 virus, respiratory epithelium, HE staining (B) and IHC staining (E). Pearl guinea fowl, 2 dpc, H5N8 virus, lung (endothelium), HE staining (C) and IHC staining (F). Ring-necked pheasant, 3 dpc, H5N2 virus, cerebrum, IHC staining (G). Ring-necked pheasant, 3 dpc, H5N2 virus, kidney, IHC staining (H). Chukar partridge, 3 dpc, H5N8 virus, adrenal gland, IHC staining (I).

Chukar partridges, and Ring-necked pheasants lacked widespread virus replication in capillary endothelial cells at any clinical stage, with consequent lack of severe edematous and hemorrhagic lesions. In contrast, Pearl guinea fowl presenting severe clinical signs or found dead had endothelial cell staining for both viruses in capillary endothelium of almost all tissues. Previous studies

have shown that endotheliotropism is common in gallinaceous poultry infections with HPAI viruses [46, 54]. Such tropism has been extensively studied in chickens infected with early H5N1 HPAI Gs/GD viruses, which typically show widespread virus replication in vascular endothelium alongside edematous, hemorrhagic, and necrotic cutaneous lesions [44, 45, 48]. Noteworthy,

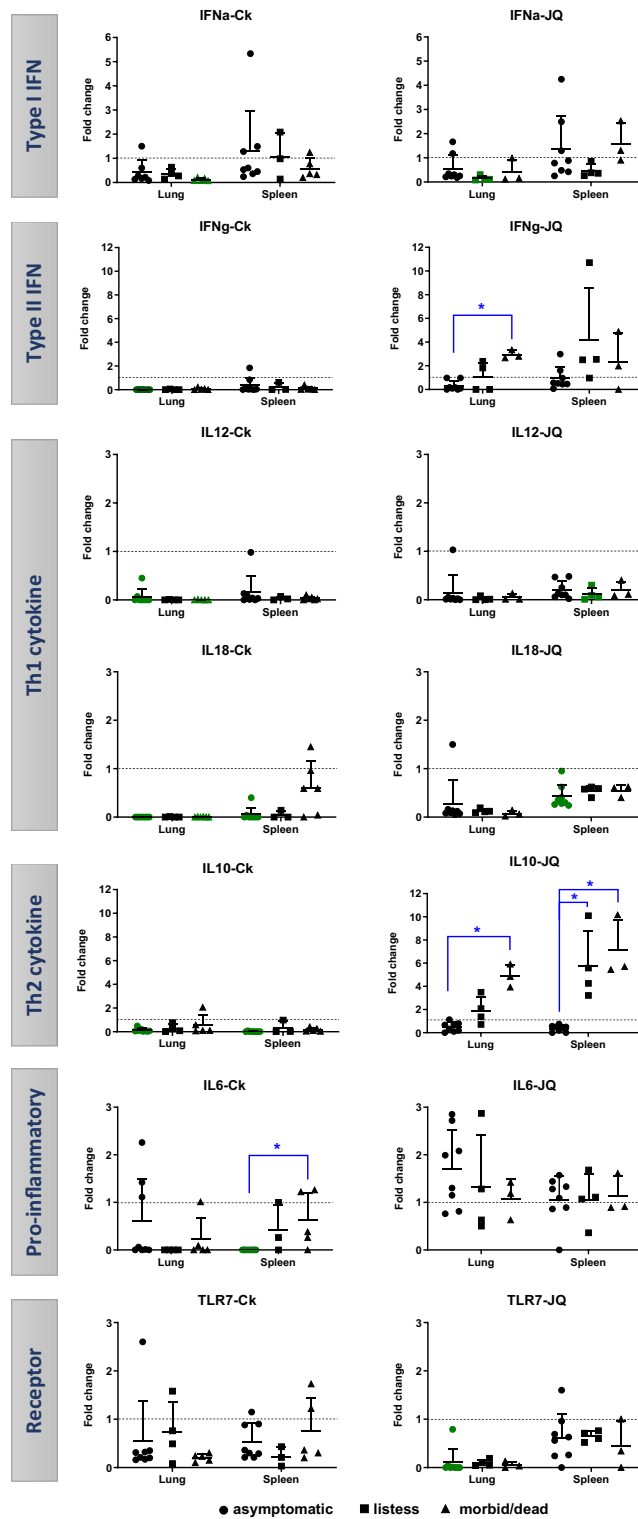


Figure 2 Relative RNA expression of innate immune genes in chicken (Ck) and Japanese quail (JQ). The fold change was calculated relative to levels of mRNA expression in infected birds compared to sham birds. Data plotted in green represents down-regulation (significantly lower than shams). Blue (*) shows significant differences between clinical stages ● asymptomatic, ■ listless, and ▲ moribund/dead. Significance $p < 0.05$.

these early H5N1 HPAI Gs/GD viruses are well adapted to and remarkably virulent for chickens [38, 55]. Peracute HPAI virus infections tend to be more endotheliotropic than subacute infections, with subacute infections having more extensive virus replication in parenchymal cells of visceral organs [38, 53]. Therefore, it is unclear why the clade 2.3.4.4A HPAI viruses tested in the present study replicated systemically and extensively in endothelial cells of Pearl guinea fowl but had infrequent endothelial replication and in a limited number of tissues in the other gallinaceous species, even in peracute infections. Interestingly, Pearl guinea fowl not only showed some of the lowest BID_{50} among the gallinaceous species tested, but also some of the shortest MDTs [40], indicating that the virus was well adapted to this host. Further studies are needed to elucidate the mechanisms that determine either restrictive or permissive replication of clade 2.3.4.4A viruses in endothelial cells of different gallinaceous species.

Several studies have shown that different avian species display differential innate immune responses to AI infection [51, 56–60], and that these responses tend to correlate with different pathobiology outcomes [57, 60, 61]. Here, the innate immune responses of chickens and Japanese quail infected with two H5Nx HPAI viruses were compared in order to elucidate any potential link between cytokine responses and clinical or pathological progression of infection. Type II IFN- γ and Th2-type cytokine IL-10 in Japanese quail, and pro-inflammatory IL-6 in chickens, were up-regulated in later clinical stages compared to asymptomatic birds, probably in response to widespread virus replication in parenchymal cells. Previously, Uno et al. found up-regulation of IFN- γ , IL-10, and IL-6 genes in peripheral blood mononuclear cells of Japanese quail collected 24 h after Gs/GD H5N1 HPAI virus challenge and before showing severe neurologic signs around 3 dpc [51]. This supports the idea that the pro-inflammatory cytokine IL-6 is produced early after infection as part of the induced innate immune response and has been associated with the recruitment of inflammatory cells and severe pathology [58, 62, 63]. Similarly, IL-6 was up-regulated in lung and spleen collected from H5 or H7 HPAI virus inoculated chickens [57, 58]. Besides IL-6, innate responses of infected chickens were similar or down-regulated compared to shams, which differs from other studies that find up-regulation in the expression of IFN- α , IFN- γ , and IL-12 in lung and spleen of chickens infected with H5N1 HPAI viruses, H7 HPAI and LPAI viruses, or H9N2 LPAI [56–58, 60, 64, 65]. However, in line with our findings, TLR-7 remained stable in lung of chickens infected with H7 HPAI virus [57], and IL-10 remained stable in lung and spleen of

chickens infected with Gs/GD H5 HPAI virus clade 1 [66]. In the present study, chickens appeared to elicit weaker innate immune responses than Japanese quail, suggesting that the lower infectivity and replication of these viruses in chickens may trigger weaker antiviral immune responses. It is worth mentioning that, initially, the innate immune gene expression analysis was performed separately for moribund and dead birds. All genes analyzed had similar mRNA expression levels in moribund and dead birds within each species, confirming that tissue necrosis did not alter cytokine expression. Also, it is worth emphasizing that quantification of innate immune genes was performed on FFPE tissues. Despite the improved isolation methods, RNA obtained from FFPE tissues can be of lower quality and smaller size (less than 200 bp) than fresh tissues due to formalin-induced cross-linking and deterioration of RNA during fixation and storage [67, 68]. Consequently, smaller amplicon sizes are needed for optimal sensitivity [67], with targets in the 70–150-bp being the ideal range [69]. Yet, FFPE tissues have been commonly used for the analysis of RNA expression because of the high availability of FFPE-preserved clinical samples and the direct correlation of these analyses with clinical data [67, 70]. Therefore, although many of our results corresponded with previous data, they should be interpreted with caution.

In conclusion, although the first U.S. clade 2.3.4.4A HPAI viruses in the 2014–2015 outbreak were differently adapted to the six gallinaceous species studied here [39, 40], we observed similar type and severity of histopathological lesions and antigen distribution in those birds that became infected, regardless of virus and species. Asymptomatic or listless infected chickens and Japanese quail lacked microscopic findings, emphasizing the risk of unrecognized virus spread if only passive surveillance is practiced. These viruses appear to have high mortality in minor gallinaceous poultry without prior adaptation, supporting the relevance of minor poultry species in the epidemiology of HPAI as intermediate hosts between wild waterfowl and major commercial gallinaceous poultry. The striking endotheliotropism in Pearl guinea fowl but not the other species calls for further investigation.

Supplementary information

Supplementary information accompanies this paper at <https://doi.org/10.1186/s13567-019-0704-5>.

Additional file 1. Primers used for the qRRT-PCR of innate immune response genes.

Abbreviations

AI: avian influenza; BID_{50} : mean bird infectious dose; dpc: day post-challenge; EID_{50} : mean egg infectious dose; FFPE: formalin-fixed paraffin-embedded; Gs/

GD: A/goose/Guangdong/1/1996; HE: hematoxylin and eosin; HPAI: highly pathogenic avian influenza; IFN: interferon; IL: interleukin; IHC: immunohistochemistry; LPM: live poultry market; LPAI: low pathogenic avian influenza; MDT: mean death time; nt: no tissue; qRRT-PCR: quantitative real-time RT-PCR; SEPR: Southeast Poultry Research Laboratory; TLR: toll-like receptor.

Acknowledgements

The authors gratefully acknowledge Kira Moresco, Roger Brock, Jerry Damron, Keith Crawford, Suzanne DeBlois, Marisela Rodriguez, Diane Smith, Mar Costa-Hurtado, and Eric DeJesus for their excellent technical assistance. The authors also thank Dr Alba for statistical assistance.

Authors' contributions

MPJ, ES, DLS, and DES conceived this project. KB, MFC, DHL, CLB, and MPJ conducted the animal experiments and sample processing. KB, MFC, and DHL analyzed the data. KB, MFC, MPJ, and DES drafted the manuscript. All authors read and approved the final manuscript.

Funding

This research was supported by USDA/ARS Research Project 6612-32000-066-00D, by the NIAID-funded Center of Excellence in Influenza Research and Surveillance (CEIRS; Contract HHSN272201400008C), by the ARS/Animal and Plant Health Inspection Service (APHIS) interagency agreement Project 60-6040-6-005, and by the DELTA-FLU Project 58-6040-7-012FN. The funders had no role in study design, data collection and interpretation, or the decision to submit the work for publication. Its contents are solely the responsibility of the authors and do not necessarily represent the official views of the USDA or NIH. Mention of trade names or commercial products in this publication is solely for the purpose of providing specific information and does not imply recommendation or endorsement by the USDA.

Availability of data and materials

The datasets generated and/or analyzed during the current study are included in this published article and its supplementary information files, or are available from the corresponding author on reasonable request.

Competing interests

The authors declare that they have no competing interests.

Author details

¹ Exotic and Emerging Avian Viral Diseases Research Unit, Southeast Poultry Research Laboratory, U.S. National Poultry Research Center, Agricultural Research Service, U.S. Department of Agriculture, Athens, GA 30605, USA. ² Present Address: IRTA, Centre de Recerca en Sanitat Animal (CRESA, IRTA-UAB), Campus de la Universitat Autònoma de Barcelona, 08193 Bellaterra, Barcelona, Spain. ³ Present Address: Department of Pathobiology & Veterinary Science, University of Connecticut, Storrs, CT 06269, USA. ⁴ Present Address: Battelle National Biodefense Institute, National Biodefense Analysis and Countermeasures Center, 8300 Research Pl, Fort Detrick, MD 21702, USA.

Received: 9 July 2019 Accepted: 27 September 2019

Published online: 01 November 2019

References

- Sims LD, Brown IH (2016) Multi-continental panzootic of H5 highly pathogenic avian influenza (1996–2015). In: Swayne DE (ed) *Animal influenza*. Wiley Blackwell, Ames
- Lee DH, Bertran K, Kwon JH, Swayne DE (2017) Evolution, global spread, and pathogenicity of highly pathogenic avian influenza H5Nx clade 2.3.4.4. *J Vet Sci* 18:269–280
- Ip HS, Torchetti MK, Crespo R, Kohrs P, DeBruyn P, Mansfield KG, Baszler T, Badcoe L, Bodenstern B, Shearn-Bochsler V, Killian ML, Pedersen JC, Hines N, Gidlewski T, DeLiberto T, Sleeman JM (2015) Novel Eurasian highly pathogenic avian influenza A H5 viruses in wild birds, Washington, USA, 2014. *Emerg Infect Dis* 21:886–890
- Lee DH, Bahl J, Torchetti MK, Killian ML, Ip HS, DeLiberto TJ, Swayne DE (2016) Highly pathogenic avian influenza viruses and generation of novel reassortants, United States, 2014–2015. *Emerg Infect Dis* 22:1283–1285
- United States Department of Agriculture, Animal and Plant Health Inspection Service (2015) Highly Pathogenic Avian Influenza Infected Premises 2014–2015. https://www.aphis.usda.gov/animal_health/animal_dis_spec/poultry/downloads/hpai-positive-premises-2014-2015.pdf
- United States Department of Agriculture, Food Safety and Inspection Service (2015) Export library—requirements by country. <http://www.fsis.usda.gov/wps/portal/fsis/topics/international-affairs/exporting-products/export-library-requirements-by-country>
- World Organisation for Animal Health (OIE) (2017) Update on avian influenza in animals (types H5 and H7). <http://www.oie.int/en/animal-health-in-the-world/update-on-avian-influenza/2017/>
- Sims LD, Weaver J, Swayne DE (2016) Epidemiology of avian influenza in agricultural and other man-made systems. In: Swayne DE (ed) *Animal Influenza*. Blackwell Publishing, Ames
- Alexander DJ (2007) An overview of the epidemiology of avian influenza. *Vaccine* 25:5637–5644
- Ni X, He F, Hu M, Zhou X, Wang B, Feng C, Wu Y, Li Y, Tu J, Li H, Liu M, Chen H, Chen S (2015) Investigation of avian influenza virus in poultry and wild birds due to novel avian-origin influenza A(H10N8) in Nanchang City, China. *Microbes Infect* 17:48–53
- Lee SS, Wong NS, Leung CC (2013) Exposure to avian influenza H7N9 in farms and wet markets. *Lancet* 381:1815
- Lai S, Qin Y, Cowling BJ, Ren X, Wardrop NA, Gilbert M, Tsang TK, Wu P, Feng L, Jiang H, Peng Z, Zheng J, Liao Q, Li S, Horby PW, Farrar JJ, Gao GF, Tatem AJ, Yu H (2016) Global epidemiology of avian influenza A H5N1 virus infection in humans, 1997–2015: a systematic review of individual case data. *Lancet Infect Dis* 16:e108–e118
- World Organisation for Animal Health (OIE) (2018) Cumulative number of confirmed human cases of avian influenza A(H5N1) reported to WHO. http://www.who.int/influenza/human_animal_interface/H5N1_cumulative_table_archives/en/
- United States Department of Agriculture, Animal and Plant Health Inspection Service (2015) Epidemiologic and other analyses of HPAI-affected poultry flocks, September 2015. https://www.aphis.usda.gov/animal_health/animal_dis_spec/poultry/downloads/Epidemiologic-Analysis-Sept-2015.pdf
- Peiris M, Yuen KY, Leung CW, Chan KH, Ip PL, Lai RW, Orr WK, Shortridge KF (1999) Human infection with influenza H9N2. *Lancet* 354:916–917
- Guan Y, Shortridge KF, Krauss S, Chin PS, Dyrting KC, Ellis TM, Webster RG, Peiris M (2000) H9N2 influenza viruses possessing H5N1-like internal genomes continue to circulate in poultry in southeastern China. *J Virol* 74:9372–9380
- Bosco-Lauth AM, Bowen RA, Root JJ (2016) Limited transmission of emergent H7N9 influenza A virus in a simulated live animal market: do chickens pose the principal transmission threat? *Virology* 495:161–166
- Turner JC, Feeroz MM, Hasan MK, Akhtar S, Walker D, Seiler P, Barman S, Franks J, Jones-Engel L, McKenzie P, Krauss S, Webby RJ, Kayali G, Webster RG (2017) Insight into live bird markets of Bangladesh: an overview of the dynamics of transmission of H5N1 and H9N2 avian influenza viruses. *Emerg Microbes Infect* 6:e12
- Bertran K, Dolz R, Majo N (2014) Pathobiology of avian influenza virus infection in minor gallinaceous species: a review. *Avian Pathol* 43:9–25
- Sun H, Pu J, Hu J, Liu L, Xu G, Gao GF, Liu X, Liu J (2016) Characterization of clade 2.3.4.4 highly pathogenic H5 avian influenza viruses in ducks and chickens. *Vet Microbiol* 182:116–122
- Lee DH, Kwon JH, Noh JY, Park JK, Yuk SS, Erdene-Ochir TO, Lee JB, Park SY, Choi IS, Lee SW, Song CS (2016) Pathogenicity of the Korean H5N8 highly pathogenic avian influenza virus in commercial domestic poultry species. *Avian Pathol* 45:208–211
- Carnaccini S, Crossley B, Breitmeyer R, Charlton BR, Bland M, Fowler K, De La Torre F, Torchetti MK, Wong SS, Wilson D, Jones A, Senties-Cue CG (2015) Diagnosis and control of a LPAI H5N8 outbreak in a Japanese quail (*Coturnix coturnix japonica*) commercial flock in the Central Valley of California. *Avian Dis* 59:344–348
- Senne DA, Pederson JC, Panigraphy B (2005) Live-bird markets in the Northeastern United States: a source of avian influenza in commercial poultry. In: Koch G, Schrijver RS (eds) *Avian Influenza*. Prevention and Control. Springer, Dordrecht
- Humberd J, Boyd K, Webster RG (2007) Emergence of influenza A virus variants after prolonged shedding from pheasants. *J Virol* 81:4044–4051

25. Bertran K, Perez-Ramirez E, Busquets N, Dolz R, Ramis A, Darji A, Abad FX, Valle R, Chaves A, Vergara-Alert J, Barral M, Hofle U, Majo N (2011) Pathogenesis and transmissibility of highly (H7N1) and low (H7N9) pathogenic avian influenza virus infection in red-legged partridge (*Alectoris rufa*). *Vet Res* 42:24
26. Bertran K, Dolz R, Busquets N, Gamino V, Vergara-Alert J, Chaves AJ, Ramis A, Abad FX, Hofle U, Majo N (2013) Pathobiology and transmission of highly and low pathogenic avian influenza viruses in European quail (*Coturnix c. coturnix*). *Vet Res* 44:23
27. Bonfante F, Patrono LV, Aiello R, Beato MS, Terregino C, Capua I (2013) Susceptibility and intra-species transmission of the H9N2 G1 prototype lineage virus in Japanese quail and turkeys. *Vet Microbiol* 165:177–183
28. Pantin-Jackwood MJ, Miller PJ, Spackman E, Swayne DE, Susta L, Costa-Hurtado M, Suarez DL (2014) Role of poultry in the spread of novel H7N9 influenza virus in China. *J Virol* 88:5381–5390
29. Makarova NV, Ozaki H, Kida H, Webster RG, Perez DR (2003) Replication and transmission of influenza viruses in Japanese quail. *Virology* 310:8–15
30. Castrucci MR, Donatelli I, Sidoli L, Barigazzi G, Kawaoka Y, Webster RG (1993) Genetic reassortment between avian and human influenza A viruses in Italian pigs. *Virology* 193:503–506
31. Perez DR, Lim W, Seiler JP, Yi G, Peiris M, Shortridge KF, Webster RG (2003) Role of quail in the interspecies transmission of H9 influenza A viruses: molecular changes on HA that correspond to adaptation from ducks to chickens. *J Virol* 77:3148–3156
32. Perez DR, Webby RJ, Hoffmann E, Webster RG (2003) Land-based birds as potential disseminators of avian mammalian reassortant influenza A viruses. *Avian Dis* 47:1114–1117
33. Obadan AO, Kimble BJ, Rajao D, Lager K, Santos JJ, Vincent A, Perez DR (2015) Replication and transmission of mammalian-adapted H9 subtype influenza virus in pigs and quail. *J Gen Virol* 96:2511–2521
34. Tashiro M, Reinacher M, Rott R (1987) Aggravation of pathogenicity of an avian influenza virus by adaptation to quails. *Arch Virol* 93:81–95
35. Cilloni F, Toffan A, Giannecchini S, Clausi V, Azzi A, Capua I, Terregino C (2010) Increased pathogenicity and shedding in chickens of a wild bird-origin low pathogenicity avian influenza virus of the H7N3 subtype following multiple in vivo passages in quail and turkey. *Avian Dis* 54:555–557
36. Giannecchini S, Clausi V, Di Trani L, Falcone E, Terregino C, Toffan A, Cilloni F, Matrosovich M, Gambaryan AS, Bovin NV, Delogu M, Capua I, Donatelli I, Azzi A (2010) Molecular adaptation of an H7N3 wild duck influenza virus following experimental multiple passages in quail and turkey. *Virology* 408:167–173
37. Spickler AR, Trampel DW, Roth JA (2008) The onset of virus shedding and clinical signs in chickens infected with high-pathogenicity and low-pathogenicity avian influenza viruses. *Avian Pathol* 37:555–577
38. Pantin-Jackwood MJ, Swayne DE (2009) Pathogenesis and pathobiology of avian influenza virus infection in birds. *Rev Sci Tech* 28:113–136
39. Bertran K, Swayne DE, Pantin-Jackwood MJ, Kapczynski DR, Spackman E, Suarez DL (2016) Lack of chicken adaptation of newly emergent Eurasian H5N8 and reassortant H5N2 high pathogenicity avian influenza viruses in the U.S. is consistent with restricted poultry outbreaks in the Pacific flyway during 2014–2015. *Virology* 494:190–197
40. Bertran K, Lee DH, Pantin-Jackwood MJ, Spackman E, Balzli C, Suarez DL, Swayne DE (2017) Pathobiology of clade 2.3.4.4 H5Nx high-pathogenicity avian influenza virus infections in minor gallinaceous poultry supports early backyard flock introductions in the Western United States in 2014–2015. *J Virol* 91:e00960
41. Swayne DE, Senne DA, Beard CW (1998) Influenza. In: Swayne DE, Glisson JR, Jackwood MW, Pearson JE, Reed WM (eds) *Isolation and Identification of Avian Pathogens*. American Association of Avian Pathologists, Kennett Square
42. Spackman E, Senne DA, Myers TJ, Bulaga LL, Garber LP, Perdue ML, Lohman K, Daum LT, Suarez DL (2002) Development of a real-time reverse transcriptase PCR assay for type A influenza virus and the avian H5 and H7 hemagglutinin subtypes. *J Clin Microbiol* 40:3256–3260
43. Pedersen JC (2008) Hemagglutination-inhibition test for avian influenza virus subtype identification and the detection and quantitation of serum antibodies to the avian influenza virus. *Methods Mol Biol* 436:53–66
44. Perkins LE, Swayne DE (2001) Pathobiology of A/chicken/Hong Kong/220/97 (H5N1) avian influenza virus in seven gallinaceous species. *Vet Pathol* 38:149–164
45. Antarasena C, Sirimujalin R, Prommuang P, Blacksell SD, Promkuntod N, Prommuang P (2006) Tissue tropism of a Thailand strain of high-pathogenicity avian influenza virus (H5N1) in tissues of naturally infected native chickens (*Gallus gallus*), Japanese quail (*Coturnix coturnix japonica*) and ducks (*Anas* spp.). *Avian Pathol* 35:250–253
46. Swayne DE (2007) Understanding the complex pathobiology of high pathogenicity avian influenza viruses in birds. *Avian Dis* 51:242–249
47. Swayne DE, Pantin-Jackwood MJ (2008) Pathobiology of avian influenza virus infections in birds and mammals. In: Swayne DE (ed) *Avian Influenza*. Blackwell Publishing, Ames
48. Jeong OM, Kim MC, Kim MJ, Kang HM, Kim HR, Kim YJ, Joh SJ, Kwon JH, Lee YJ (2009) Experimental infection of chickens, ducks and quails with the highly pathogenic H5N1 avian influenza virus. *J Vet Sci* 10:53–60
49. Butt SL, Dimitrov KM, Zhang J, Wajid A, Bibi T, Basharat A, Brown CC, Rehmani SF, Stanton JB, Afonso CL (2019) Enhanced phylogenetic resolution of Newcastle disease outbreaks using complete viral genome sequences from formalin-fixed paraffin-embedded tissue samples. *Virus Genes* 55:502–512
50. Uno Y, Usui T, Fujimoto Y, Ito T, Yamaguchi T (2012) Quantification of interferon, interleukin, and Toll-like receptor 7 mRNA in quail splenocytes using real-time PCR. *Poult Sci* 91:2496–2501
51. Uno Y, Usui T, Soda K, Fujimoto Y, Takeuchi T, Ito H, Ito T, Yamaguchi T (2013) The pathogenicity and host immune response associated with H5N1 highly pathogenic avian influenza virus in quail. *J Vet Med Sci* 75:451–457
52. Chaves AJ, Busquets N, Valle R, Rivas R, Vergara-Alert J, Dolz R, Ramis A, Darji A, Majo N (2011) Neuropathogenesis of a highly pathogenic avian influenza virus (H7N1) in experimentally infected chickens. *Vet Res* 42:106
53. Kuiken T, van den Brand J, van Riel D, Pantin-Jackwood M, Swayne DE (2010) Comparative pathology of select agent influenza A virus infections. *Vet Pathol* 47:893–914
54. Short KR, Veldhuis Kroeze EJ, Reperant LA, Richard M, Kuiken T (2014) Influenza virus and endothelial cells: a species specific relationship. *Front Microbiol* 5:653
55. Swayne DE, Slemons RD (2008) Using mean infectious dose of high- and low-pathogenicity avian influenza viruses originating from wild duck and poultry as one measure of infectivity and adaptation to poultry. *Avian Dis* 52:455–460
56. Cornelissen JB, Post J, Peeters B, Vervelde L, Rebel JM (2012) Differential innate responses of chickens and ducks to low-pathogenic avian influenza. *Avian Pathol* 41:519–529
57. Cornelissen JB, Vervelde L, Post J, Rebel JM (2013) Differences in highly pathogenic avian influenza viral pathogenesis and associated early inflammatory response in chickens and ducks. *Avian Pathol* 42:347–364
58. Kuchipudi SV, Tellabati M, Sebastian S, Londt BZ, Jansen C, Vervelde L, Brookes SM, Brown IH, Dunham SP, Chang KC (2014) Highly pathogenic avian influenza virus infection in chickens but not ducks is associated with elevated host immune and pro-inflammatory responses. *Vet Res* 45:118
59. Cao Y, Huang Y, Xu K, Liu Y, Li X, Xu Y, Zhong W, Hao P (2017) Differential responses of innate immunity triggered by different subtypes of influenza A viruses in human and avian hosts. *BMC Med Genomics* 10(Suppl 4):70
60. Vidana B, Dolz R, Busquets N, Ramis A, Sanchez R, Rivas R, Valle R, Cordon I, Solanes D, Martinez J, Majo N (2018) Transmission and immunopathology of the avian influenza virus A/Anhui/1/2013 (H7N9) human isolate in three commonly commercialized avian species. *Zoonoses Public Health* 65:312–321
61. Vidana B, Martinez J, Martinez-Orellana P, Garcia Migura L, Montoya M, Martorell J, Majo N (2014) Heterogeneous pathological outcomes after experimental pH1N1 influenza infection in ferrets correlate with viral replication and host immune responses in the lung. *Vet Res* 45:85
62. Fukuyama S, Kawaoka Y (2011) The pathogenesis of influenza virus infections: the contributions of virus and host factors. *Curr Opin Immunol* 23:481–486
63. Kuribayashi S, Sakoda Y, Kawasaki T, Tanaka T, Yamamoto N, Okamatsu M, Isoda N, Tsuda Y, Sunden Y, Umemura T, Nakajima N, Hasegawa H, Kida H (2013) Excessive cytokine response to rapid proliferation of highly pathogenic avian influenza viruses leads to fatal systemic capillary leakage in chickens. *PLoS One* 8:e68375

64. Ranaware PB, Mishra A, Vijayakumar P, Gandhale PN, Kumar H, Kulkarni DD, Raut AA (2016) Genome wide host gene expression analysis in chicken lungs infected with avian influenza viruses. *PLoS One* 11:e0153671
65. Wang J, Cao Z, Guo X, Zhang Y, Wang D, Xu S, Yin Y (2016) Cytokine expression in three chicken host systems infected with H9N2 influenza viruses with different pathogenicities. *Avian Pathol* 45:630–639
66. Karpala AJ, Bingham J, Schat KA, Chen LM, Donis RO, Lowenthal JW, Bean AG (2011) Highly pathogenic (H5N1) avian influenza induces an inflammatory T helper type 1 cytokine response in the chicken. *J Interferon Cytokine Res* 31:393–400
67. Ecco R, Brown C, Susta L, Cagle C, Cornax I, Pantin-Jackwood M, Miller PJ, Afonso CL (2011) In vivo transcriptional cytokine responses and association with clinical and pathological outcomes in chickens infected with different Newcastle disease virus isolates using formalin-fixed paraffin-embedded samples. *Vet Immunol Immunopathol* 141:221–229
68. Nam SK, Im J, Kwak Y, Han N, Nam KH, Seo AN, Lee HS (2014) Effects of fixation and storage of human tissue samples on nucleic Acid preservation. *Korean J Pathol* 48:36–42
69. McKinney MD, Moon SJ, Kulesh DA, Larsen T, Schoepp RJ (2009) Detection of viral RNA from paraffin-embedded tissues after prolonged formalin fixation. *J Clin Virol* 44:39–42
70. Penland SK, Keku TO, Torrice C, He X, Krishnamurthy J, Hoadley KA, Woosley JT, Thomas NE, Perou CM, Sandler RS, Sharpless NE (2007) RNA expression analysis of formalin-fixed paraffin-embedded tumors. *Lab Invest* 87:383–391

Publisher's Note

Springer Nature remains neutral with regard to jurisdictional claims in published maps and institutional affiliations.

Ready to submit your research? Choose BMC and benefit from:

- fast, convenient online submission
- thorough peer review by experienced researchers in your field
- rapid publication on acceptance
- support for research data, including large and complex data types
- gold Open Access which fosters wider collaboration and increased citations
- maximum visibility for your research: over 100M website views per year

At BMC, research is always in progress.

Learn more biomedcentral.com/submissions

