



HAL
open science

Diagnostic challenges in a child with early onset desmoplastic medulloblastoma and homozygous variants in MSH2 and MSH6

Julia Taeubner, Katharina Wimmer, Martine Muleris, Olivier Lascols, Chrystelle Colas, Christine Fauth, Triantafyllia Brozou, Joerg Felsberg, Jasmin Riemer, Michael Gombert, et al.

► To cite this version:

Julia Taeubner, Katharina Wimmer, Martine Muleris, Olivier Lascols, Chrystelle Colas, et al.. Diagnostic challenges in a child with early onset desmoplastic medulloblastoma and homozygous variants in MSH2 and MSH6. *European Journal of Human Genetics*, 2018, 26 (3), pp.440-444. 10.1038/s41431-017-0071-5 . hal-02340250

HAL Id: hal-02340250

<https://hal.science/hal-02340250>

Submitted on 30 Oct 2019

HAL is a multi-disciplinary open access archive for the deposit and dissemination of scientific research documents, whether they are published or not. The documents may come from teaching and research institutions in France or abroad, or from public or private research centers.

L'archive ouverte pluridisciplinaire **HAL**, est destinée au dépôt et à la diffusion de documents scientifiques de niveau recherche, publiés ou non, émanant des établissements d'enseignement et de recherche français ou étrangers, des laboratoires publics ou privés.

Short Report

Diagnostic challenges in a child with early onset desmoplastic medulloblastoma and homozygous variants in *MSH2* and *MSH6*

Running title: challenges diagnosing CMMRD

Julia Taeubner ^{1*}, Katharina Wimmer ^{2*}, Martine Muleris ³, Olivier Lascols ^{3,4}, Chrystelle Colas ^{3,5}, Christine Fauth ², Triantafyllia Brozou ¹, Joerg Felsberg ⁶, Jasmin Riemer ⁷, Michael Gombert ¹, Sebastian Ginzel ¹, Jessica I. Hoell ¹, Arndt Borkhardt ¹ and Michaela Kuhlen ¹⁺

¹Department of Paediatric Oncology, Haematology and Clinical Immunology, University Children's Hospital, Medical Faculty, Heinrich Heine University, Duesseldorf, Germany

²Division of Human Genetics, Medical University Innsbruck, Innsbruck, Austria

³Sorbonne Université, UPMC Univ Paris 06, INSERM, CNRS, Centre de Recherche Saint-Antoine (CRSA), F75012 Paris, France

⁴AP-HP, Saint-Antoine Hospital, Department of molecular biology and genetics, Paris, France

⁵AP-HP, Pitié Salpêtrière Hospital, Department of genetics, Paris, France

⁶ Department of Neuropathology, Medical Faculty, Heinrich Heine University, Duesseldorf, Germany

⁷ Institute of Pathology, Medical Faculty, Heinrich Heine University, Duesseldorf, Germany

*These authors contributed equally to this work.

⁺Correspondence: Michaela Kuhlen, Department of Paediatric Oncology, Haematology and Clinical Immunology, University Children's Hospital, Moorenstr. 5, 40225 Duesseldorf, Germany; Tel.: +49-211-81-16491, Fax: +49-211-81-04982; Email: Michaela.Kuhlen@med.uni-duesseldorf.de;

Abstract

Constitutional mismatch repair deficiency (CMMRD) is an autosomal recessively inherited childhood cancer susceptibility syndrome caused by biallelic germline mutations in one of the mismatch repair (MMR)

genes. The spectrum of CMMRD-associated tumours is very broad and many CMMRD patients additionally display signposting non-neoplastic features, most frequently café-au-lait macules and other pigmentation alterations.

We report on a 13 months old girl suspected of having CMMRD due to a desmoplastic medulloblastoma and a striking skin pigmentation that included multiple café-au-lait macules, hypopigmented areas and Mongolian spots. Whole-exome sequencing revealed homozygosity for *MSH2* variant p.(Leu92Val) and *MSH6* variant p.(Val809del), both variants of uncertain significance. Immunohistochemical analysis of the tumour tissue showed expression of all four MMR proteins and gMSI testing was negative. However, functional assays demonstrated that the cells of the patient displayed methylation tolerance and *ex vivo* microsatellite instability, which unequivocally confirmed the diagnosis of CMMRD. Taken together, the results render the *MSH2* variant unlikely to be responsible for the phenotype, while they are compatible with *MSH6*-associated CMMRD.

This case illustrates the diagnostic strategy of confirming CMMRD syndrome in patients with VUS.

Keywords: CMMRD; desmoplastic medulloblastoma; *MSH2*; *MSH6*; whole-exome sequencing, germline

Introduction

Constitutional mismatch repair deficiency (CMMRD) caused by biallelic germline mutations in one of the four mismatch repair (MMR) genes confers a high risk for a broad spectrum of malignancies primarily including haematological malignancies, brain tumours and tumours of the Lynch syndrome (LS) spectrum. Typically, patients develop tumours in the first two decades of life and survivors of the primary malignancy are at high risk to develop a second cancer.¹ Therefore, timely diagnosis of CMMRD is important for appropriate anticancer treatment^{2,3,4,5}, surveillance and genetic counselling of parents regarding the recurrence risk in siblings as well as their own risk for LS-associated tumours. About two-thirds of CMMRD patients present with pigmentary alterations, most frequently café-au-lait macules (CALM) reminiscent of neurofibromatosis type 1 (NF1)², but also a variety of other unspecific pigmentation anomalies. Here, we report on a child with desmoplastic medulloblastoma (DMB) and peculiar skin pigmentation who meets the criteria for CMMRD testing.¹ Whole exome sequencing (WES) revealed homozygous variants of uncertain significance (VUS) in *MSH2* and *MSH6*. The diagnostic strategy allowing us to assign the clinical significance of these variants and finally to confirm CMMRD in the patient is presented.

Results

Case report

The 13 months old girl suffering from vomiting for several weeks presented with ataxia, convergent strabism and developmental regression at hospitalization. Magnet resonance imaging of the brain showed massive hydrocephalus caused by a large infratentorial tumour (49x41x85 mm) with both solid and cystic parts (Figure 1D). Pathologic analysis of the resected tumour revealed desmoplastic medulloblastoma with a balanced c-Myc and n-Myc status and β -Catenin negativity. Metastases to the cerebral fluid or spinal cord were excluded. According to the HIT (**H**irn-**T**umor) guidance protocol, treatment with vincristine, cyclophosphamide, high-dose methotrexate, carboplatin and etoposide and intraventricular methotrexate was initiated and fairly well tolerated under supportive care. Radiotherapy was omitted due to the patient's age. One year after diagnosis, the child is well and in complete remission.

The patient had a very peculiar skin phenotype with a heterogeneous spectrum of pigmentary alterations including CALM and inguinal freckling reminiscent of NF1 as well as other hyper- and hypo-pigmented skin patches, atypical dermal melanocytosis/Mongolian spots and naevus-like spots (Figure 1A-B). Neither the

healthy three-year-old sister nor the parents showed these alterations of skin pigmentation. The parents having both Roma background reported non-consanguinity, a pregnancy with a third child who died in utero for unknown reasons and a family history without cancer diagnosis in the three preceding generations (Figure 1C).

Identification of homozygous variants in MSH2 and MSH6

The family was included in our prospective study 'Germline predisposition in children with cancer'. According to the study protocol, a trio-based WES analysis, including patient and both parents, was performed. Analysis of the WES data for causative variants in the MMR genes revealed a *MSH2* missense variant (c.274C>G, p.(Leu92Val)) and a *MSH6* 3-bp deletion (del) (c.2426_2428delTAG, p.(Val809del)) both present in a homozygous state in the patient and heterozygous in both parents (Figure 2A).

The ExAC-database lists the *MSH2* variant with an overall minor allele frequency of G=0.00007. This variant located in the functionally relevant N-terminal MutS-like protein domain (Figure 2B) affects a highly conserved amino-acid and is predicted to be deleterious by several programs (Polyphen, SIFT, MutationTaster). The InSiGHT group database lists this *MSH2* variant once with unknown pathogenicity (InSiGHT class 3).

No data on the frequency in unselected individuals is available for the 3-bp del in *MSH6*. It is predicted to lead to loss of a valine (Val) in a moderately conserved region of the core domain of *MSH6*. In the InSiGHT database, this variant (2 entries) was classified as variant with unknown pathogenicity (InSiGHT class 3).

Since, both variants were classified as VUS, neither of them could unequivocally confirm the diagnosis of CMMRD. Therefore, we performed additional tests in order to unravel whether the clinical phenotype of the child is caused by CMMRD and to render indications whether homozygosity of one or both of the VUS is disease causing.

Diagnostic workup

Many inactivating *MSH2* missense variants lead at least to expression loss of the heterodimerisation partner *MSH6*. Therefore, we performed immunohistochemical (IHC) staining on the tumour tissue, which showed nuclear expression of all MMR proteins in neoplastic and non-neoplastic cells (Supplement Figure 1). gMSI testing performed according to the protocol developed by Ingham *et al.*³ did not reveal increased gMSI ratios in the patient's lymphocytes and, hence, could not confirm CMMRD in the child. Therefore, we next

performed methylation tolerance and *ex vivo* microsatellite instability (evMSI) assays using a lymphoblastoid cell line (LCL) of the patient (Supplementary Material and Methods). These cells displayed a methylation-tolerance phenotype characteristic of MMR-deficient cells (Figure 3A). Furthermore, the cell line from the patient achieved the evMSI phenotype as demonstrated by a 1bp-del in the NR27 microsatellite in the LCL in comparison to peripheral blood lymphocytes (Figure 3B). Taken together, both assays clearly confirm CMMRD in the patient.

Discussion

Diagnosing CMMRD has important implications for the management of paediatric cancer patients and their families. Therefore, coming to a definite diagnosis in a suspected patient is of utmost importance. ~~In the era of large scale sequencing the major challenge is correct classification of variants that affect functions or are being neutral.~~ This case illustrates an effective diagnostic strategy to definitely confirm (or refute) CMMRD in patients in whom only MMR gene VUS are identified.

IHC staining of the MMR proteins and analysis of MSI are the preferred diagnostic methods to substantiate suspected CMMRD. However, due to the non-truncating nature of the VUS identified in *MSH2* and *MSH6*, which is compatible with expression of a non-functional protein, IHC was not informative in our patient. This limitation of IHC has already been shown in other CMMRD patients.⁴⁻⁶ It is known that standard MSI testing developed for LS-associated tumours often fails to show MSI in brain tumours of CMMRD patients.⁷ Therefore, we performed gMSI testing. This simple and fast assay detects altered dinucleotide-microsatellite alleles present at low level in non-neoplastic cells of individuals with CMMRD due to biallelic *PMS2* or *MLH1* mutations. CMMRD due to bi-allelic *MSH2* mutations is rare and data are therefore limited, but all cases of *MSH2*-associated CMMRD analysed so far also showed increased gMSI ratios.^{3,4} However, since the assay relies on the analysis of dinucleotide microsatellite markers, it is insensitive towards *MSH6*-associated CMMRD.³ Hence, a negative gMSI result, as observed in our patient, is compatible with a constitutive *MSH6* defect, but speaks against a defect in *PMS2*, *MLH1* or *MSH2*. Another approach is based on the evaluation of MSI using mononucleotide markers and methylation tolerance – another functional characteristic of MMR-deficient cells –, in immortalized lymphoblastoid cells (i.e. *ex vivo*) of suspected patients.⁴ This method demonstrated unequivocal results in a case-control study, i.e. abnormal results for both assays were found in all CMMRD

patients, whereas normal results for both assays were found in the control cohort.⁴ This assay could finally confirm CMMRD also in our patient.

The preserved expression of *MSH2* and *MSH6* and, in particular, the negative gMSI result speaks against an inactivation of *MSH2* in the patient rendering the *MSH2* variant p.(Leu92Val) unlikely the disease causing variant. However, these results are compatible with *MSH6*-associated CMMRD and, consequently, a deleterious effect of the *MSH6* variant p.(Val809del). Hence, it is possible that the *MSH2* variant is a rare benign variant that happens to be genetically linked to the disease causing mutation in *MSH6* (distance between the two variants is ~39kb). This notion is corroborated by data from the UMD database, which also reports this *MSH2* variant as “likely neutral” and together with a different clearly disease-causing *MSH6* mutation in a patient with LS. Ultimately however, functional studies would be needed to come to a final conclusion which of the two variants contributed to which extend to the clinical phenotype of the patient.

Upon confirming CMMRD, our patient was integrated into a cancer surveillance program as proposed by the European consortium ‘C4CMMRD’, the international biallelic MMR deficiency consortium and the consensus statement of the American Association for Cancer Research.^{8,9} According to the InSiGHT-database the *MSH6* variant was also found in patients tested for LS. We therefore assume that this variant increases the risk for LS-associated tumours in adult heterozygous carriers and strongly recommended that the parents are enrolled in a LS surveillance protocol even in absence of LS-associated tumours in their family history. The sister who did not show pigmentation alterations or any other signs of CMMRD was not tested for the *MSH6* variant.

A very particular skin pigmentation phenotype was crucial for suspecting CMMRD in our patient. The girl not only has a large number of hyper- and hypopigmented skin areas, which are frequently reported in CMMRD patients, but also several Mongolian spots. With this very heterogeneous skin pigmentation phenotype she resembles a recently published CMMRD patient with atypical dermal melanocytosis¹⁰ and a patient published by Scott et al.¹¹ These patients indicate that also multiple Mongolian spots may belong to the CMMRD-associated skin features.

In conclusion, our case illustrates that WES may be a valid and rapid method to confirm the diagnosis. However, paediatric oncologists and molecular geneticists should be prepared that the interpretation of sequencing data may be challenging and require thorough functional analysis to come to a valid conclusion.

Informed consent

The study was approved by the local ethics committee and written informed consent was obtained from the parents.

Author Contributions

J. T. and M.K. performed WES data analysis and first drafted the manuscript. K.W. helped writing the manuscript. K.W., M.M. and C.F. critically revised the manuscript for important intellectual content. J.T. performed Sanger sequencing. K.W. and C.F. performed gMSI testing. M.M., O.L., C.C. performed methylation tolerance assay and evMSI. T.B. obtained informed consent and asked for the family history. T.B., J.I.H., A.B. and M.K. cared for the child. J.F. and J.R. performed the pathological analysis. M.G. was responsible for library preparation, S.G. for the internal SQL database. A.B. and M.K. designed and supervised the project. All authors approved the final manuscript as submitted.

Conflict of interest: The authors declare no conflict of interest.

Acknowledgments: This work was supported by the Elterninitiative Kinderkrebsklinik e.V. Duesseldorf. The authors wish to thank Dr. Claudia Potthoff and Dr. Stefan Balzer for their contribution in sample acquisition, Mrs. Silke Furlan and Mrs. Katayoun Alemazkour for technical assistance, Mrs. Fanny Bouchlis and Mrs. Brigitte Litra for functional assays and Dr. Joerg Schaper for providing the radiological image. We thank the Biological Resource Center, Hôpital Cochin, APHP-Paris France, for the lymphoid cell line establishment.

Supplementary information is available at xxx's website

References

1. Wimmer K, Kratz CP, Vasen HF *et al*: Diagnostic criteria for constitutional mismatch repair deficiency syndrome: suggestions of the European consortium 'care for CMMRD' (C4CMMRD). *Journal of medical genetics* 2014; **51**: 355-365.

2. Wimmer K, Rosenbaum T, Messiaen L: Connections between constitutional mismatch repair deficiency syndrome and neurofibromatosis type 1. *Clinical genetics* 2017; **91**: 507-519.
3. Ingham D, Diggle CP, Berry I *et al*: Simple detection of germline microsatellite instability for diagnosis of constitutional mismatch repair cancer syndrome. *Human mutation* 2013; **34**: 847-852.
4. Bodo S, Colas C, Buhard O *et al*: Diagnosis of Constitutional Mismatch Repair-Deficiency Syndrome Based on Microsatellite Instability and Lymphocyte Tolerance to Methylating Agents. *Gastroenterology* 2015; **149**: 1017-1029 e1013.
5. Mork ME, Borrás E, Taggart MW *et al*: Identification of a novel PMS2 alteration c.505C>G (R169G) in trans with a PMS2 pathogenic mutation in a patient with constitutional mismatch repair deficiency. *Familial cancer* 2016.
6. Sjurset W, Bjornevoll I, Engebretsen LF, Fjelland K, Halvorsen T, Myrvold HE: A homozygote splice site PMS2 mutation as cause of Turcot syndrome gives rise to two different abnormal transcripts. *Familial cancer* 2009; **8**: 179-186.
7. Bougeard G, Charbonnier F, Moerman A *et al*: Early onset brain tumor and lymphoma in MSH2-deficient children. *American journal of human genetics* 2003; **72**: 213-216.
8. Durno CA, Aronson M, Tabori U, Malkin D, Gallinger S, Chan HS: Oncologic surveillance for subjects with biallelic mismatch repair gene mutations: 10 year follow-up of a kindred. *Pediatric blood & cancer* 2012; **59**: 652-656.
9. Tabori U, Hansford JR, Achatz MI *et al*: Clinical Management and Tumor Surveillance Recommendations of Inherited Mismatch Repair Deficiency in Childhood. *Clinical cancer research : an official journal of the American Association for Cancer Research* 2017; **23**: e32-e37.
10. Polubothu S, Scott RH, Vabres P, Kinsler VA: Atypical dermal melanocytosis: diagnostic clue in constitutional mismatch repair deficiency syndrome. *The British journal of dermatology* 2017.
11. Scott RH, Mansour S, Pritchard-Jones K, Kumar D, MacSweeney F, Rahman N: Medulloblastoma, acute myelocytic leukemia and colonic carcinomas in a child with biallelic MSH6 mutations. *Nat Clin Pract Oncol* 2007; **4**: 130-134.

Titles and legends to figures

Figure 1. A-B Variegated skin pattern with CAL spots, hypo-pigmented areas, and Mongolian and naevus-like spots. **C** Pedigree of the family; circles, females; squares, males; quarter symbol, heterozygous variants; half symbol, homozygous variant; black symbol, MSH2 variant; red symbol, MSH6 variant. **D** Cerebellar medulloblastoma with solid and cystic parts, T2 weighed axial.

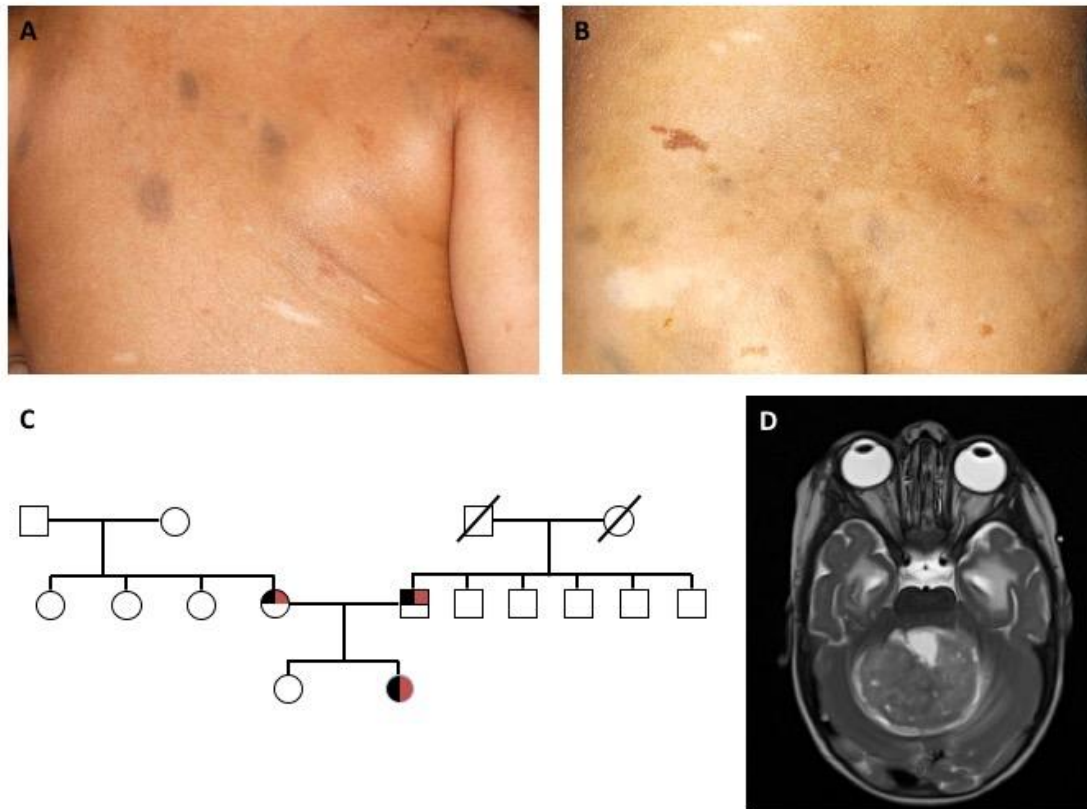


Figure 2. **A** WES reveals a homozygous missense variant in *MSH2* (c.274C>G, p.Leu92Val) and a 3-bp deletion in *MSH6* (c.2426_2428delTAG, p.Val809del) in DNA extracted from peripheral blood of the patient. Both variants are heterozygous in the parents. **B** The *MSH2* variant is located in the MutS_I protein domain and the *MSH6* variant is located in the MutS_III protein domain. **C** Sanger sequencing confirmed homozygosity of the two variants in the patient. Both variants are present in a heterozygous state in the parents.

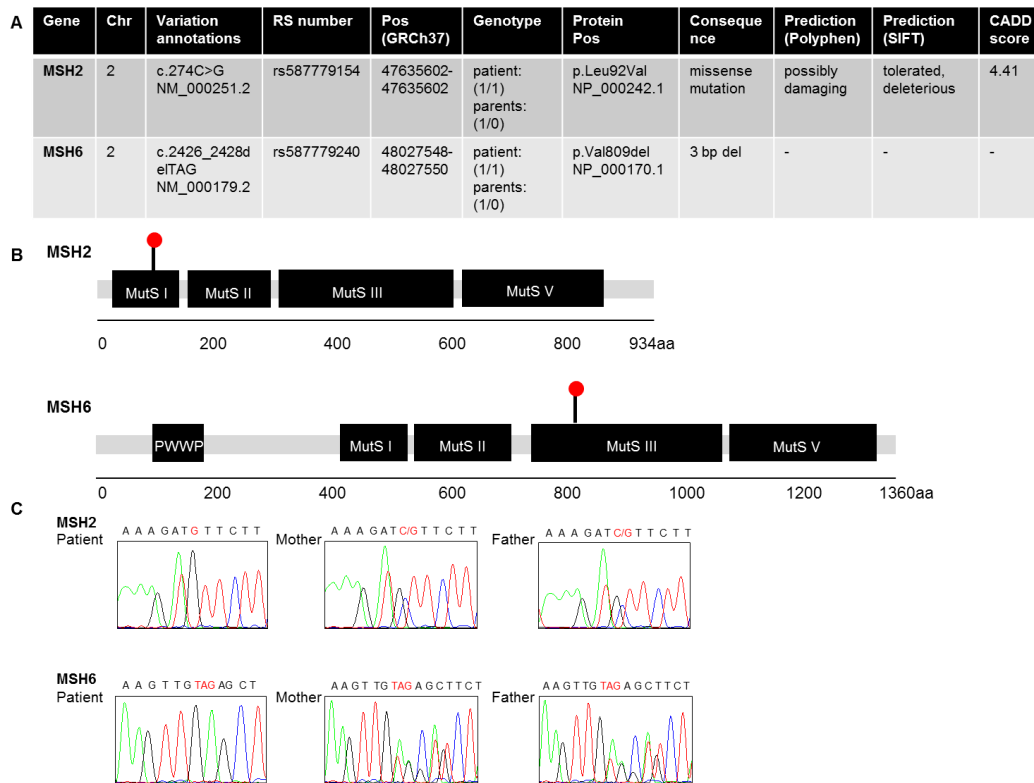
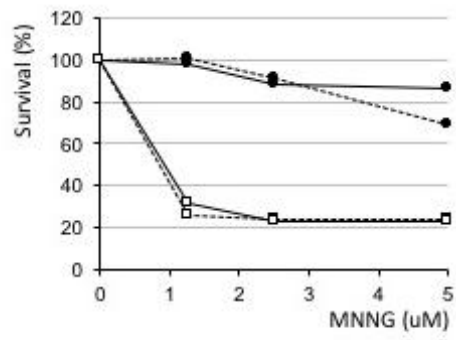


Figure 3. A The lymphoblastoid cell line from the patient displayed methylation tolerance. Survival (%) of immortalized lymphoid cells derived from the patient (dark circles) and from an MMR wild-type control (open squares) after two (full lines) or three (dotted lines) rounds of MNNG treatment. **B** Immortalized lymphoid cells from the patient displayed ex vivo microsatellite instability. Electrophoretograms of fluorescent amplification products for NR21, NR27, and BAT26 microsatellites, respectively. The length of the predominant allele (in base pairs) and the fluorescence intensity are indicated in the box below each profile. A 1bp deletion (red arrow) occurred at the NR27 locus in the lymphoblastoid cell line (LCL) derived from the patient compared with the respective peripheral blood lymphocytes (PBLs).

A**B**