



HAL
open science

Contribution of 3D printing to mandibular reconstruction after cancer

Agnes Dupret-Bories, Sebastien Vergez, Thomas Meresse, Fabien Brouillet,
Ghislaine Bertrand

► **To cite this version:**

Agnes Dupret-Bories, Sebastien Vergez, Thomas Meresse, Fabien Brouillet, Ghislaine Bertrand. Contribution of 3D printing to mandibular reconstruction after cancer. *European Annals of Otorhinolaryngology, Head and Neck Diseases*, 2018, 135 (2), pp.133-136. 10.1016/j.anorl.2017.09.007 . hal-02338495

HAL Id: hal-02338495

<https://hal.science/hal-02338495>

Submitted on 30 Oct 2019

HAL is a multi-disciplinary open access archive for the deposit and dissemination of scientific research documents, whether they are published or not. The documents may come from teaching and research institutions in France or abroad, or from public or private research centers.

L'archive ouverte pluridisciplinaire **HAL**, est destinée au dépôt et à la diffusion de documents scientifiques de niveau recherche, publiés ou non, émanant des établissements d'enseignement et de recherche français ou étrangers, des laboratoires publics ou privés.





Open Archive Toulouse Archive Ouverte (OATAO)

OATAO is an open access repository that collects the work of Toulouse researchers and makes it freely available over the web where possible

This is an author's version published in: <http://oatao.univ-toulouse.fr/24513>

Official URL: <https://doi.org/10.1016/j.anorl.2017.09.007>

To cite this version:

Dupret-Bories, Agnes and Vergez, Sebastien and Meresse, Thomas and Brouillet, Fabien  and Bertrand, Ghislaine  *Contribution of 3D printing to mandibular reconstruction after cancer.* (2018) *European Annals of Otorhinolaryngology, Head and Neck Diseases*, 135 (2). 133-136. ISSN 1879-7296

Any correspondence concerning this service should be sent to the repository administrator: tech-oatao@listes-diff.inp-toulouse.fr

Contribution of 3D printing to mandibular reconstruction after cancer

A. Dupret-Bories^{a,*}, S. Vergez^b, T. Meresse^c, F. Brouillet^{d,e}, G. Bertrand^{d,e}

^a Chirurgie ORL et cervico-faciale, Institut Universitaire du Cancer Toulouse Oncopole, institut Claudius-Regaud, 1, avenue Irène-Joliot-Curie, 31059 Toulouse cedex 9, France

^b Chirurgie ORL et cervico-faciale, Institut Universitaire du Cancer Toulouse Oncopole, CHU Larrey, 24, chemin de Pouvoirville, 31059 Toulouse cedex 9, France

^c Chirurgie plastique et reconstruction, Institut Universitaire du Cancer Toulouse Oncopole, institut Claudius-Regaud, 1, avenue Irène-Joliot-Curie, 31059 Toulouse cedex 9, France

^d Laboratoire CIRIMAT, UMR 5085 UPS-INPT-CNRS, institut Carnot, équipe « Phosphates, Pharmacotechnie, Biomateriaux », 4, allée Émile-Monso, CS 44362, 31030 Toulouse cedex 4, France

^e École nationale supérieure des ingénieurs en arts chimiques et technologiques, 4, allée Émile-Monso, CS 44362 31030 Toulouse cedex 4, France

ARTICLE INFO

Keywords:

Cancer
Mandibular reconstruction
3D printing
Surgical guides
Mandible template

ABSTRACT

Three-dimensional (3D) printing is booming in the medical field. This technology increases the possibilities of personalized treatment for patients, while lowering manufacturing costs. To facilitate mandibular reconstruction with fibula free flap, some companies propose cutting guides obtained by CT-guided moulding. However, these guides are prohibitively expensive (€ 2,000 to € 6,000). Based on a partnership with the CNRS, engineering students and a biomedical company, the authors have developed cutting guides and 3D-printed mandible templates, deliverable in 7 days and at a lower cost. The novelty of this project is the speed of product development at a significantly lower price. In this technical note, the authors describe the logistic chain of production of mandible templates and cutting guides, as well as the results obtained. The goal is to allow access to this technology to all patients in the near future.

1. Introduction

Segmental mandibulectomy is a common head and neck surgical procedure. When mandibular reconstruction is performed by titanium plate, conformation of these plates is usually performed intraoperatively. The limitations of this technique are the considerable duration of plate modelling depending on the defect to be repaired and modelling that remains only approximate. Various companies, such as KLS Martin Group or Synthes, propose preformed plates adapted to the morphology of the defect, at prices ranging from € 700 to 1300. When mandibular reconstruction is performed with fibula free flap, which constitutes the reference technique, the long bone must be reconfigured into a three-dimensional (3D) angular structure, making this a complex technique. In order to facilitate free flap modelling, several companies propose various solutions, ranging from virtual planning to cutting guides with or without screw plates. The cost of these solutions varies between € 2500 and 6000, depending on the option selected, i.e. cutting guides with or without 3D-printed template, with or without preformed plates. Manufacturing times are at least 21 days. At the present time, French national health insurance does

not reimburse preoperative planning, and these additional costs remain at the charge of healthcare institutions.

3D printing is a rapidly growing technology in the medical field, which can provide adapted solutions, but can the production chain be simplified in order to reduce delivery times and simultaneously limit costs? Based on a partnership between a head and neck surgery department, a CNRS biomaterial laboratory and an engineering school, the authors have demonstrated that personalized 3D-printed mandible templates can be produced by using only free software and an open source BCN3D[®] printer costing € 1500 (BCN3D Technologies). These templates allowed planning of operations and conformation of titanium plates. In the light of these preliminary results, the authors contacted AnatomikModeling, which designs custom-made 3D implants and masters the digital chain. 3D-printed cutting guides for fibula free flap conformation were jointly developed. In this technical note, the authors describe the logistic chain and perspectives of this study in order to allow, in the near future, access to 3D modelling prior to mandibular reconstruction for all patients.

2. Technique

Neck and chest CT scan was performed in all patients and CT angiography of the lower limbs was performed before fibula free flap reconstruction.

* Corresponding author.

E-mail address: Dupret-Bories.Agnes@iuct-oncopole.fr (A. Dupret-Bories).

2.1. Manufacture of mandible templates and preformed screw plates.

3D printing of objects requires generation of an STL (STereolI-hography) format file that can be used directly by the printer. In the field of medical imaging, the set of 2D images (Digital Imaging and Communications in Medicine format, i.e. DICOM) obtained from the patient's CT scan in various planes (coronal, axial and sagittal) are compiled to reconstitute a virtual 3D view of the patient's tissues and isolate a view of the mandible, which is then exported in STL format to be optimized (correction of imperfections and creation of a support) before 3D printing.

In order to demonstrate the feasibility and potential cost reduction, we preferred to use a free access software suite (3D Slicer, Blender, 3D Builder) (Fig. 1A).

2.1.1. Generation of the STL file

After importing the DICOM file into 3D Slicer software, volume rendering functions are initially used to display a 3D image of all tissues and then isolate the bony part of the patient's skull before exclusively extracting the mandible. Residual artifacts are partly corrected by the software (removal of parts of the maxilla remaining on the image, filling of certain internal defects of the mandible). The file obtained is in STL format.

2.1.2. Preparation of the print file

The new file contains certain residual imperfections derived from CT image acquisition (diffuse white zones related to the patient's dental fillings) and 2D-to-3D image transformation (non-smooth surface of the mandible). These various artifacts are

eliminated with Blender software (Fig. 1B). The first types of defects are therefore selected and eliminated one by one, while the smoothing function smoothes the bone surface, resulting in acceptable, slight, 5 mm maximum undersizing of the mandible.

For 3D printing by layer-by-layer extrusion of polymer filament, the first layer must be flat, which is not the case for an object like the mandible. 3D Builder software easily optimizes spatial positioning of the mandible and adds a flat support allowing printing under suitable conditions. The total duration to obtain a printable mandible file is 1.5 hours.

2.1.3. 3D printing of the mandible template

3D printing was performed on a BCN 3D+ open source modular printer (BCN3D Technologies, Spain) using PLA polymer filament melted at 205 °C (printing speed: 160 mm/s). The mandible printing time is 3 hours (Fig. 1C).

Mandible templates were scanned and superimposed onto the patient's preoperative CT images, revealing a difference in dimensions of less than 2 mm.

The initial data processing learning time was 3 hours, and the initial 3D printer learning time was 1.5 hours.

2.1.4. Conformation of the titanium plate

For each patient, 72 hours before the surgical operation, the titanium screw plate was conformed onto the mandible template (Fig. 1D) adapted to the future mandibular resection. The plate was then sterilized according to the usual procedures. The mandible template was then also sterilized according to the Sterrad process (UV irradiation + H₂O₂ plasma) in order to be available for the surgical procedure.




Fig. 1. A. Free digital chain allowing 3D printing of mandible templates from DICOM files. Use of 3D Slicer for image processing. C. PLA printed mandible template with osteosarcoma impression. D. Titanium plate preoperatively conformed onto the mandible template with printed fibular segment replacing the body of the mandible.

2.2. 3D printing of the mandible template, mandibular and fibula cutting guides

Using the patient's CT data (DICOM CT scans), the mandible and the fibula with its septo-cutaneous perforators were segmented and their respective 3D templates were generated (VGStudio MAX 3.0 software, Volume Graphics GmbH). Mandibular planes of section were indicated by the head and neck surgeon (Fig. 2A). 3D templates of mandibular cutting guides were created by CAO on the patient's 3D virtual mandible (Geomagic Freeform software, Geomagic)(Fig. 2B). After defining the zone of mandibular resection, the 3D fibula template was aligned and sectioned to follow the curve of the zone of mandibular resection (Fig. 2C). The various cuts were then virtually realigned on the 3D template of the fibula and the fibula cutting guide was generated by CAO (Fig. 2D).

3D printing comprises the mandible template (Fig. 2F), the fibula cutting guide and 2 mandible cutting guides (Fig. 2E). 3D printing was performed with a Builder Premium Medium FDM 3D printer using PLA filament (filament diameter: 1.75 mm, melting temperature: 195 °C). All 3D-printed objects were then submitted

to dimension controls by high precision 3D digitization. 3D templates derived from 3D digitization (Artec Spider scanner and Artec Studio 11 software suite) were compared to CAO 3D templates.

Cutting guides were sterilized according to the Sterrad process (UV irradiation + H₂O₂ plasma).

3. Discussion

From February 2016 to September 2016, 7 patients underwent preoperative planning of 3D printer mandibular reconstruction in the context of cancer of the oral cavity, i.e. squamous cell carcinoma ($n=6$) and osteosarcoma ($n=1$). Three titanium plates and 4 screw plates were pre-conformed on 3D-printed mandible templates then sterilized. Three cutting guides for fibula free flap reconstruction were printed and used (Figs. 2G, 2H and 2I).

In collaboration with AnatomikModeling, creation of cutting guides with joint review by the surgeon took an average of 1.5 hours. Printing of the 3 cutting guides (fibula and mandible) and the mandible template took an average of 3 hours.

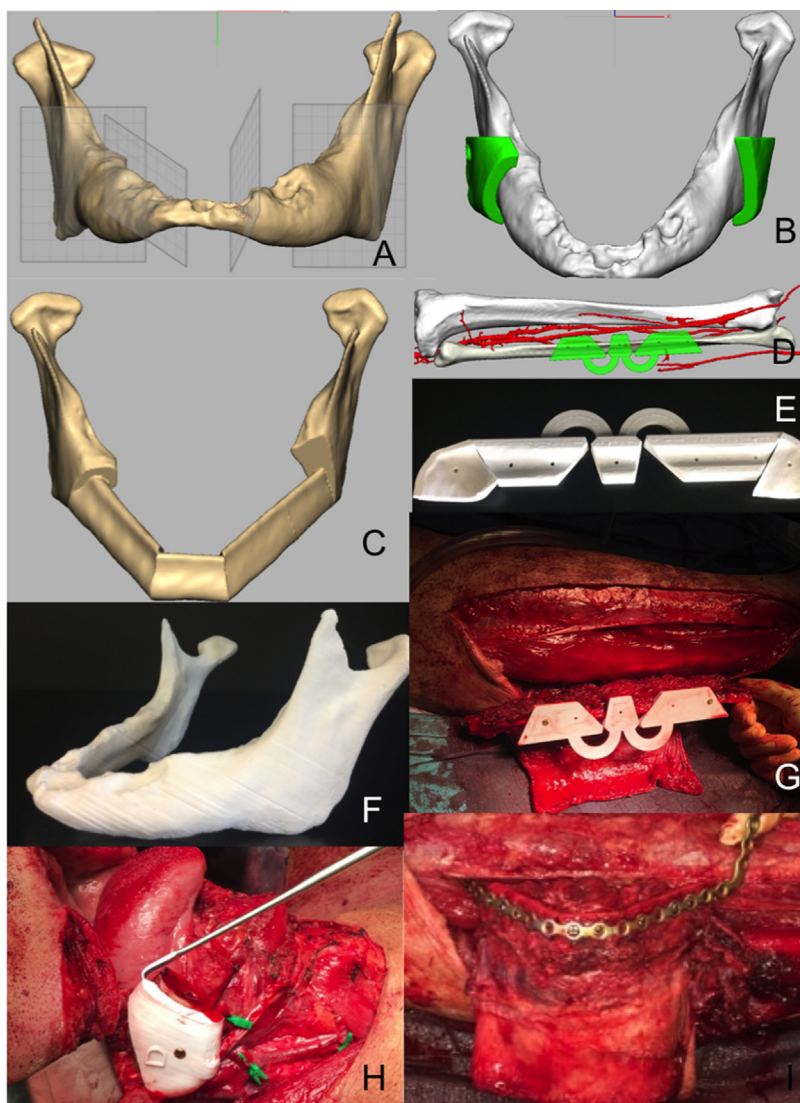


Fig. 2. Patient with squamous cell carcinoma of the oral floor invading the symphysis, the 2 parasymphyses and the left body of the mandible. A. 3D view of the mandible with planes of section. B. 3D view of mandibular cutting guides. C. 2D view of virtual reconstruction of the mandible with fibular segments: 3D view of cutting guides on the fibula. E. Printed fibular and mandibular cutting guides. F. Mandible template. G. Cutting guides on the right fibula. H. Cutting guide on the patient's mandible after mandibulectomy. I. Fibula conformed with the titanium plate, the flap is still attached by its pedicle.

The time gain estimated by surgeons was 30 mins for titanium plate reconstructions and 1.5 to 2 hours for fibula free flap reconstructions with pre-conformation of the plates. These data are consistent with those reported in the literature. The estimated average operating time gain with the use of cutting guides for mandibular reconstructions was 1.7 hours for Hanasono et al. [1] and 45 mins for Culié et al. [2]. The flap ischaemia time was reduced by 42 mins according to Zhang et al. [3] and 73 mins according to Culié et al. Reduction of the flap ischaemia time is a factor of good prognosis in terms of flap viability [4]. Reduction of the operating time reduces morbidity, especially the infectious risk [5].

Zhang et al. compared intercondylar distances between virtual planning and fibula free flap mandibular reconstruction with and without cutting guides with a significant difference between the 2 groups, confirming the value of cutting guides and preoperative planning to ensure greater precision and efficacy [6].

Many recent publications have demonstrated the value cutting guides for mandibular reconstruction both for patients and surgical teams, especially in the case of complex reconstructions, i.e. symphyses [7]. However, these solutions currently remain very expensive and few centres have the necessary funds. Reduction of the operating time alone cannot constitute a sufficient economic argument for healthcare institutions, as, for long surgical procedures such as fibula free flap reconstructions, the time gain is not sufficient to allow a second operation in the same operating room. Reduction of morbidity and/or length of hospital stay would be the only acceptable financial argument. However, no prospective study of these data has been conducted to validate the health economics value of using cutting guides, preformed plates, and preoperative planning on mandible templates. A French multicentre study on this subject is about to be initiated.

The present study demonstrates:

- feasibility of using a free access software chain and FDM 3D printing of mandible templates and cutting guides with an open source printer by an engineer with complete self-learning in 4.5 hours;
- proven time gain as a result of preoperative planning and the use of mandibular and fibular cutting guides (30 mins to 2 hours) and estimated gains in terms of the efficacy and precision of the procedure;
- reduction of template and cutting guide delivery times from 21 days to 5 days;
- the value of collaborating with a company of engineers able to adapt to unexpected and complex situations, which, as a result of the manufacture of greater numbers, can reduce the associated production costs (the current cost price of the solution is estimated to be less than € 1000).

4. Conclusion

The authors' purpose was to show head and neck surgeons who perform mandibular reconstructions that 3D printing provides a decisive contribution to this complex operation by allowing optimal planning on a template, with a gain in time and improved quality of pre-conformed screw plates, improved precision of the procedure and better flap survival by using cutting guides. The free software 3D printing technique described here requires a considerable image processing time, justifying collaboration with the AnatomikModeling biomedical company specialized in 3D technologies. These solutions (templates and cutting guides) should be commercially available in the near future, allowing access to this technology for a greater number of patients.

Disclosure of interest

The authors declare that they have no competing interest.

Acknowledgements

Surgeons who are involved in the 3D project at IUCT Toulouse Oncopole: Jérôme Sarini, Benjamin Vairel, Gaël Espinasse, Dimitri Gangloff.

AnatomikModeling: Benjamin Moreno, Prof. Chavoïn, Pierre Leyx.

Students at *Institut national polytechnique de Toulouse*: Louis Barre, Quentin Bunoux, Federico Cantoni, Gabriel Delaunay, Wendy Grondin, Pierre Leyx, Ludovic Manificier.

References

- [1] Hanasono MM, Skoracki RJ. Computer-assisted design and rapid prototype modeling in microvascular mandible reconstruction. *Laryngoscope* 2013;123(3):597–604.
- [2] Culié D, Dassonville O, Poissonnet G, Riss JC, Fernandez J, Bozec A. Virtual planning and guided surgery in fibular free-flap mandibular reconstruction: a 29-case series. *Eur Ann Otorhinolaryngol Head Neck Dis* 2016;133(3):175–8.
- [3] Zhang W, Yu H, Guo Z, Li B, Si T, Yang X, et al. Percutaneous cryoablation of liver metastases from breast cancer: initial experience in 17 patients. *Clin Radiol* 2014;69(3):231–8.
- [4] Chang SY, Huang JJ, Tsao CK, Nguyen A, Mittakanti K, Lin CY, et al. Does ischemia time affect the outcome of free fibula flaps for head and neck reconstruction? A review of 116 cases. *Plast Reconstruct Surg* 2010;126(6):1988–95.
- [5] Leong G, Wilson J, Charlett A. Duration of operation as a risk factor for surgical site infection: comparison of English and US data. *J Hosp Infect* 2006;63(3):255–62.
- [6] Zhang L, Liu Z, Li B, Yu H, Shen SG, Wang X. Evaluation of computer-assisted mandibular reconstruction with vascularized fibular flap compared to conventional surgery. *Oral Surg Oral Med Oral Pathol Oral Radiol* 2016;121(2):139–48.
- [7] Tarsitano A, Del Corso G, Ciocca L, Scotti R, Marchetti C. Mandibular reconstructions using computer-aided design/computer-aided manufacturing: a systematic review of a defect-based reconstructive algorithm. *J Craniomaxillofac Surg* 2015;43(9):1785–91.