



HAL
open science

The comparative anatomy of frontal eye fields in primates

Laurent Petit, Pierre Pouget

► **To cite this version:**

Laurent Petit, Pierre Pouget. The comparative anatomy of frontal eye fields in primates. *Cortex*, 2019, 118, pp.51-64. 10.1016/j.cortex.2019.02.023 . hal-02331725

HAL Id: hal-02331725

<https://hal.science/hal-02331725>

Submitted on 13 Nov 2020

HAL is a multi-disciplinary open access archive for the deposit and dissemination of scientific research documents, whether they are published or not. The documents may come from teaching and research institutions in France or abroad, or from public or private research centers.

L'archive ouverte pluridisciplinaire **HAL**, est destinée au dépôt et à la diffusion de documents scientifiques de niveau recherche, publiés ou non, émanant des établissements d'enseignement et de recherche français ou étrangers, des laboratoires publics ou privés.

The comparative anatomy of frontal eye fields in primates

Laurent PETIT^{1‡} and Pierre POUGET^{2‡}

^{1‡} *Groupe d'Imagerie Neurofonctionnelle, Institut des Maladies Neurodégénératives - UMR 5293, CNRS, CEA University of Bordeaux, Bordeaux, France*

^{2‡} *Institute du Cerveau et de la Moelle épinière (ICM), UMRS 975 INSERM, CNRS 7225, UMPC, Paris, France*

‡ These authors share co-authorship

Corresponding authors: Pierre POUGET

Institute du Cerveau et de la Moelle épinière (ICM), UMRS 975 INSERM, CNRS 7225, UMPC, Paris, France (pougetp@gmail.com)

ABSTRACT

The frontal eye field (FEF) is a relatively small frontal region that has been intensely studied. It received multiple definitions that help to locate it with some discrepancies between non-human primates and humans. The goal of this review is to provide an inter-species comparison of the location, extent, and boundaries of the FEF through the multiple anatomical and functional methodologies that has been used for its description as an oculomotor-associated area. We therefore propose a new orientation for using white matter fibers co-localizations between frontal structures to study their evolution and clarify the FEF homologies in primates.

INTRODUCTION

The Frontal Eye Field (FEF) is an oculomotor region that has been intensely studied since its first description by David Ferrier nearly 150 years ago. Ferrier performed electrical stimulation studies on various animal species including cats, dogs, rabbits and macaque monkey, and stated: *“In the superior frontal convolution, in advance of the centre for certain forward movements of the arm, as well as in the corresponding part of the middle frontal convolution, are areas, stimulation of which causes lateral (crossed) movements of the head and eyes and dilation of pupils”* (Ferrier, 1874). In a study published in 2013 about the hemispheric specialization of voluntary control of spatial attention in humans, Duecker et al. wrote: *“Although this study focused on the role of the FEF in spatial attention, we have chosen for localization based on eye movements. Conceptually, this is closer to the original definition of the FEF. Moreover, eye movement-related BOLD signal changes in FEF are more robust compared with attention-related activation changes allowing easier and more time-efficient localization. Several studies have confirmed the involvement of the FEF in both spatial attention and eye movements, and neuroimaging studies generally report overlapping clusters of activation...”* (Duecker et al., 2013). These few sentences summarize alone more than 20 years of neuroimaging studies dealing with the neural bases of the oculomotor systems, including the localization of the FEF in humans and their common involvement for saccadic eye movement and spatial attention tasks. At first, this review is going to describe the various tracks, which have characterized the anatomical localization of the FEF in primate species from the seminal work of Ferrier to the latest functional imaging methods. We will illustrate that the location of the FEF can be assessed with a variety of methods studying saccadic eye movements both in human and non-human primates. We will then focus on the phylogenetic placement of the FEF

in different primate brains according to different anatomical and functional criteria. Finally, this review (but see also (Paus, 1996; Tehovnik et al., 2000; Amiez and Petrides, 2009; Vernet et al., 2014; Percheron et al., 2015; Schall et al., 2017) is proposing a new discussion for using fibers co-localizations between structures to study their evolution and function.

Similitudes in eye movements patterns among primates

A search for homologies among primates in the cortical and subcortical organization of eye movements is encouraged by the many similarities in gaze behavior observed between monkeys, apes, and humans. Members of each species produce each of the different types of eye movements: fixation maintained by gaze-holding vestibular and visual reflexes, which is interrupted by rapid gaze shifts and slow pursuit eye movements to direct vision in three dimensions. In numerous quantitative respects, the eye movements of macaque monkeys and humans are more similar than different in execution but they can differ in planning and context (Baizer and Bender, 1989; Einhäuser et al., 2006; Martinez-Conde and Macknik, 2008; Berg et al., 2009; Shepherd et al., 2010). In a wide range of testing conditions, the advanced cognitive control of eye movements is indistinguishable between humans and macaque monkeys (Hanes and Schall, 1995; Hanes and Carpenter, 1999; Munoz and Everling, 2004; Camalier et al., 2007; Nelson et al., 2010). Consequently, the macaque has been a faithful source of insights for human clinics of neurology (Leigh and Zee, 2015) and psychiatry (Driscoll and Barr, 2016). Comparisons of the eye movements of chimpanzees, gorillas, and orangutans with those of humans also have noted numerous similarities with particular differences (Kano and Tomonaga, 2009; Kano et

al., 2011; Kano and Tomonaga, 2011; Kano et al., 2018). Primates in general are visual creatures with particular ocular, muscular (Blumer et al., 2016), and neural adaptations including devotion of a large proportion of the brain to visual processing rationalized by the amount of cortex dedicated to such processing.

The location of FEF as regards with sulcal patterns

The sulcus pattern in apes and human brains is notably more complex than that in monkeys, especially in the frontal lobe, but particular associations have been described (Hervé, 1888; Owen, 1900; Connolly, 1950; Falk, 2014). First, there is general agreement that the arcuate sulcus, or at least the ventral (vertical) branch, of monkeys corresponds to the inferior precentral sulcus in apes and humans. Second, the superior frontal sulcus and superior precentral sulcus of apes and humans may be derived from the precentral dimple of monkeys. Alternatively, they may correspond to the superior (horizontal) limb of the macaque arcuate sulcus. Third, early authors identified the macaque principal sulcus (also referred to as rectus sulcus) with the hominid inferior frontal sulcus, but later analyses conclude that the inferior frontal sulcus of apes and humans has no counterpart in monkeys and instead the principal sulcus of monkeys corresponds to the middle frontal sulcus of humans. Thus, the ventral frontal lobe of humans has expanded relative to apes and monkeys. Such an expansion could lead to a relatively more dorsal location of the FEF in humans relative to apes and monkeys. These topological identifications of sulci can guide a perspective on the location of FEF in nonhuman primates and humans. Hence, if the FEF of monkeys is in the arcuate sulcus, and the arcuate sulcus is homologous with the inferior precentral sulcus, then does it follow that the FEF of humans is located in the

inferior precentral sulcus? Such reasoning can account for the lateral BOLD activation observed in imaging studies. If this reasoning is sound and valid, then what is the status of the FEF region at the intersection of the superior frontal sulcus and the dorsal precentral sulcus? One possibility is that this dorsal region is homologous to the premotor eye field of macaques. On the other hand, if the dorsal region is correctly understood as the homologue of the macaque FEF, based on evidence reviewed previously, then what is the proper relation of the ventral FEF region (Gabernet et al., 1999)? Perhaps it is a premotor eye field as suggested earlier. Confusing all of this, though, is the evidence that the eye movement region in orangutans, gorillas, and chimpanzees is located clearly rostral to the precentral sulci. We note, though, that in spite of the similar appearance of the frontal sulci of humans and chimpanzees the precentral sulcus of chimpanzees does not mark the border between premotor and prefrontal cortex as it may in humans; instead it marks the border between motor and premotor cortex (Preuss, personnel communication). This can explain why the FEF is located on the middle frontal gyrus of the apes, but it cannot help us understand the apparent caudal migration of the FEF in humans. Clearly, many questions remain. Naturally, the location of FEF and surrounding areas will vary as a function of systematic and random variability of sulcal patterns. In fact, as detailed in the following, Amiez et al. (2006) conducted a subject-by-subject analysis of the locus of eye movement-related functional activity revealed in relation to the detailed morphology of the precentral and superior frontal sulci (Amiez et al., 2006). A focus of activation associated with saccadic eye movements was located in the ventral branch of the superior precentral sulcus in both hemispheres. A second focus has been found in the dorsal part of the inferior precentral sulcus. Imaging during a hand response selection task revealed activation focused in the dorsal branch of the superior precentral sulcus

close to the caudal end of the superior frontal sulcus. Activation in primary motor cortex was focused in the precentral knob (or Broca's pli de passage moyen). The relationship of FEF to the bordering premotor cortex is elaborated in the following paragraphs. Compared to humans, the cerebral sulcal pattern is much less variable across Old World monkeys (Cercopithecidae) (Falk, 1978). The frontal lobe consists of an arcuate sulcus rostral to the central sulcus and a longitudinal principal sulcus (known also as sulcus rectus) rostral to the arcuate sulcus (Walker, 1940; Connolly, 1950). The arcuate sulcus consists of a superior (horizontal) limb or branch and an inferior (vertical); at the genu or curve, typically located caudal to the end of the principal sulcus. However, some individuals exhibit a posterior extension of the sulcus referred to as a "spur." Thus, the shape and extent of the arcuate sulcus in monkeys also varies.

Despite these important variabilities observed in humans and monkeys, many if not all brain atlases of primates, implicitly assume a relative homogeneity across individuals. Atlases based on averages of macaque brains (Frey et al., 2011; Calabrese et al., 2015) imply that sulcal patterns are more regular and uniform across individuals than they actually are. As a consequence, such averaged atlases underestimate the length of the spur observed in many individuals by representing only a small spur (Frey et al., 2011) or none at all (Calabrese et al., 2015; Rohlfing et al., 2012). Likewise, atlases based on a single individual will misrepresent the incidental presence or lack of a spur as standard anatomy (e.g. (Saleem and Logothetis, 2012)). A variety of mechanisms for variabilities in cortical folding have been proposed: differential cell proliferation, differential tangential expansion, radial intercalation, axon tension, radial glia, and so on (see for review (Striedter et al., 2015); see also (Mota and Herculano-Houzel, 2015; Tallinen et al., 2016)). These data cannot distinguish among these alternatives, but they offer an opportunity for further exploration to determine how the variation of sulcal

morphology relates to the location and boundaries of FEF and neighboring areas. Functionally, some of these anatomical heterogeneities might be obscured by the time-averaged signal obtained with functional imaging techniques. In fact, and despite the inter-individual variations, within the cortical oculomotor network, resting state imaging have permitted to reveal significant global correlations of activities between the intraparietal sulcus, posterior central sulcus, parieto-occipital sulcus, upper superior temporal sulcus, and cingulate sulcus marginal ramus. Across laboratories, these results have permitted to support that the projection of the human oculomotor map on the macaque map and *vice versa* exist and that the putative human homolog of macaque Lateral Intra Parietal (LIP) cortex lies medial to the intraparietal sulcus, within the superior parietal lobule (Koyama et al. 2004).

A cytoarchitectonic definition

In humans and non-human primates, the cytoarchitecture of the FEF is rather included as Brodmann's area 6 or 8. A reason to explain this double assignment, is that Brodmann's map area 6 occupies a very large amount of the frontal lobe and in fact contemporaneous as well subsequent maps by other investigators subdivide Brodmann's area 6 into many more areas. For example, myeloarchitectonic studies have distinguished the caudal end of the middle frontal gyrus as distinct from surrounding areas (Nieuwenhuys et al., 2015). While other authors locate the caudal end of the middle frontal gyrus in area 6 (Sarkissov et al., 1955), it has also been labeled area FB (von Economo, 1929), area 4s (Von Bonin and Bailey, 1947), the boundary of FA and FB (Bailey and Von Bonin, 1951), and $8\alpha\beta\gamma$ (Vogt and Vogt, 1926). Penfield, with Förster, described the majority of stimulation sites eliciting eye

movements as being in $8\alpha\beta\gamma$ (Penfield and Rasmussen, 1950), and the exceedingly elaborate map of von Kleist (1934) identifies ocular aversive movements with Brodmann's area 8 (von Kleist, 1934).

Of note, the structure of the cortex occupied by FEF has been reevaluated more recently. Human FEF can be distinguished from surrounding areas by MRI myelin mapping (Glasser et al., 2016). In addition, a recent anatomical study reexamined the architecture of this region using modern chemoarchitectonic methods in postmortem tissue from six subjects ((Rosano et al., 2003); see also (Schmitt et al., 2005)). The histological structure of the superior precentral sulcus was distinct from adjacent rostral and caudal regions. A thin granular layer 4 was observed in sections labeled with neuronal nuclear protein (NeuN), and the non-phosphorylated neurofilament triplet protein (NNFP). Also, clusters of large, intensely immunoreactive pyramidal cells were located in deep layers 3 and 5 (Figure 5). In sections labeled for calcium-binding proteins, the two walls of the sulcus were characterized by higher density of calretinin-labeled interneurons, lower density of calbindin-labeled pyramidal neurons, higher density of calbindin-labeled interneurons in layers 2–3, and higher density of large parvalbumin-labeled interneurons in deep layer 3. It is noteworthy that these histological features resemble the macaque FEF more than agranular area 6. These immunohistochemistry methods highlighted distinctions across this cortical region that are obscured in Nissl-stained section. Based on this analysis of cytoarchitectural, myeloarchitectural, and histochemical studies, one can conclude that Brodmann's description is unlikely to be correct because it misplaced the caudal boundary of area 8 of humans rostrally. This characterization seems to resolve the discrepancy. However, some questions remain. As described earlier, BOLD activation is also observed in the convexity of the precentral gyrus, close to the inferior precentral sulcus,

near areas 44 and 45. In non-human primates, the FEF in the arcuate sulcus which is bordered ventrally by areas 44 and 45. Also, the macaque has a region caudal to the FEF in agranular premotor cortex with visual responsiveness and from which saccadic eye movements can be elicited by intracortical microstimulation (Preuss et al., 1996; Fujii et al., 1998).

A lesion definition

Ablations and inactivation of the FEF in the macaque monkey have extensively shown that the execution of visually guided, memory-guided and predictive saccades is moderately but impaired (Schiller and Sandell, 1983). It corresponds generally to a decrease in saccadic velocities and an increase in saccadic latencies reported both with lesions and with reversible inactivation using lidocaine or muscimol (Deng et al., 1986; Sommer and Tehovnik, 1997; Schiller and Chou, 1998; Sommer and Tehovnik, 1999; Wardak et al., 2006; Wardak et al., 2012). Tehovnik summarized the size and location of FEF inactivation and lesions for various studies and showed that they were mainly in the anterior bank and part of the arcuate sulcus (see Figures 9 and 10 in (Tehovnik et al., 2000)). Recently, a new approach based on focused ultrasounds stimulation applied in the anterior bank of the arcuate sulcus has been used to transiently modulate the execution of antisaccades (Deffieux et al., 2013). In humans, some aspects of visually guided saccades have been shown impaired with large frontal lesions not restricted to the FEF (Guitton et al., 1985), followed by studies with lesions more restricted to the FEF which have shown that visually-guided and memory-guided saccades were impaired (Pierrot-Deseilligny et al., 1991; Pierrot-Deseilligny et al., 1993; Rivaud et al., 1994). These later studies clearly demonstrated that the common

area of damage between patients affected the precentral sulcus, between the superior and inferior frontal sulci, and the adjacent parts of the precentral and middle frontal gyri (Figure 2). Note that, as in the monkey, unilateral FEF lesions present mainly contralateral saccade impairment (but see Reuter-Lorenz et al., 2011). In a more general point of view, human studies for the most part are consistent with the findings reported in monkeys, namely lesions of the peri-precentral cortex in humans and adjacent to the arcuate sulcus in monkeys lead to voluntary saccadic eye movements impairments.

An electrophysiological definition

As mentioned above, we attribute the first description of the FEF to David Ferrier who discovered an area in the dorsal portion of the arcuate sulcus of anesthetized monkeys where electric stimulation elicited movements of the eyes and head in the direction opposite the stimulated hemisphere (Figure 1). These are referred to as contraversive movements. This finding has been replicated in multiple species including prosimians, new-world monkeys, old-world monkeys, apes, and humans. Förster (1926) described the area from which he could evoke eye movement as the “*frontales Augenfelds*,” which was translated into “frontal eye fields” (Förster, 1926; Davidoff, 1928; Foerster and Penfield, 1930). Later in the twentieth century, more precise microstimulation studies evoking eye movements (Crosby et al., 1952; Wagman et al., 1961; Robinson and Fuchs, 1969), followed by electrophysiological recordings during visual stimulation and/or eye movements (Bizzi, 1968; Mohler et al., 1973; Bruce and Goldberg, 1985b, a; Segraves and Goldberg, 1987; Segraves, 1992) confirmed the existence of the FEF

as the cortical area located in the posterior part of the arcuate sulcus that evokes a rapid contralateral and conjugate movement of both eyes when electrically stimulated.

In humans, Penfield and Boldrey (1937), using electrical stimulation, located the FEF in the posterior extremity of the middle frontal gyrus and the adjacent part of the precentral gyrus, around the precentral sulcus. In a more systematic study, eye movements were elicited by electrical stimulation of the frontal lobe in 19 awake patients evaluated with subdural electrodes for epilepsy surgery (Godoy et al., 1990). In 90% of the patients the FEF were located in front or at the level of the motor representation in the peri-precentral cortex (see also (Blanke et al., 1999; Blanke et al., 2000)). Finally, according to this functional criteria, Lobel and colleagues reported that the region where saccadic eye movements could be the most easily elicited by electrical stimulation was consistently located at the intersection of the precentral sulcus with the superior frontal sulcus (Lobel et al., 2001). Note that they also described a second precentral region more laterally, close to the convexity of the precentral gyrus that also elicited saccades when stimulated but to a lesser extent.

A neuroimaging definition

The description of FEF and its location has historically been based on early data from monkey studies and has been extended to studies in humans. The history of the location of the FEF through neuroimaging techniques ($H_2^{15}O$ -PET, fMRI) is reversed. Humans neuroimaging studies first attributed and located some frontal activation during the execution of saccades to the FEF involvement before being able to train monkeys to stay still in a scanner and check their known location. The first study of the

measurement of cerebral blood flow performed in humans during a task of visually-guided horizontal saccades used the ^{133}Xe technique, which only allows the analysis of the cortex of one hemisphere (Melamed and Larsen, 1979). This pioneering work described a frontal activation centered within the precentral gyrus, between the regions involved in the control of hand and mouth movements, and was attributed to the activation of the FEF. The same cortical region was described but bilaterally in the first H_2^{15}O -PET study while participants performed visually- and auditory-guided saccades (Fox et al., 1985). Fox et al. observed consistent activation in front of the motor region of the hand, covering both a portion of the middle frontal gyrus and the precentral gyrus that they identified as the FEF. Taking into account the individual anatomy in the analysis of the PET data, Petit et al. found later that the activations elicited by performing self-paced horizontal saccades were located bilaterally in the peri-precentral cortex, including the precentral sulcus and parts of the precentral gyrus (Figure 3) (Petit et al., 1993). Dozens of studies have since come to corroborate this description both in PET and with the advent of fMRI (Figure 4). Thanks to its higher spatial resolution, fMRI allowed to progressively restrict the site hosting the FEF along the precentral sulcus (Darby et al., 1996; Müri et al., 1996), at the junction with the superior frontal sulcus (Petit et al., 1997; Berman et al., 1999; Gitelman et al., 2000). Interestingly, Luna et al. observed that performing visually-guided saccades co-activates the peri-precentral cortex at the junction with the superior frontal sulcus and to a lesser extent, more laterally, in the convexity of the precentral gyrus (Luna et al., 1998). The older has therefore been considered as the med-FEF and the later the lat-FEF (Corbetta et al., 1998; Beauchamp et al., 2001; Heide et al., 2001; Petit and Beauchamp, 2003; Petit et al., 2009; Petit et al., 2015).

Note that, at the beginning of the 2000's, a series of neuroimaging studies demonstrated that the same dorsal fronto-parietal network including the FEF is involved in the orienting of spatial attention with or without any saccadic eye movements (Corbetta et al., 1998; Kim et al., 1999; Gitelman et al., 2000; Beauchamp et al., 2001). Different reviews already addressed this topic that extend the functional role of the human FEF beyond its strict oculomotor role to a more general epicenter of the Dorsal Attentional Network that won't be more developed in the present review (Corbetta and Shulman, 2002; Corbetta et al., 2008; Power et al., 2011).

Functional MRI using macaque monkey was developed in awake animals with the turn of the new millennium (Vanduffel et al., 2001; Nakahara et al., 2002; Vanduffel et al., 2002). It allowed to better understand inter-species correspondences but also differences between non-human and human primate cortical organization (Tootell et al., 2003). As a matter of fact, Koyama et al. compared fMRI activation patterns in humans and macaques performing the same task of visually guided saccades. BOLD activation in macaques was found as expected in the rostral bank of the arcuate sulcus, but also in premotor cortex caudal to the arcuate sulcus (Koyama et al., 2004). In humans a large domain of activation occupied the banks of the precentral sulcus including both med- and lat-FEF. As previous studies mentioned above, the authors proposed the peak of activation near the junction of the precentral and the superior frontal sulci (med-FEF) corresponds to the FEF in monkeys. Two fMRI studies successively confirmed that when monkeys performed visually-guided saccades, a main activation was observed in the anterior bank of the arcuate sulcus but also into part of the premotor cortex (Baker et al., 2006; Ford et al., 2009; Kagan et al., 2010).

More recently, resting-state fMRI (rs-fMRI) connectivity of FEF has been compared in macaques and humans (Hutchison et al., 2012; Babapoor-Farrokhran et al., 2013). Since a valid comparison of functional connectivity between macaques and humans should rely on a correct anatomical identification of the homologous functional area for the seed-based resting-state fMRI analysis, it is interesting to note that the authors based their seed location to the correspondence between the med-FEF location at the junction of the precentral and superior frontal sulci in humans and the rostral bank of the arcuate sulcus in macaques. These studies have found consistent and similar functional connections of the seeded FEF with frontal and parietal cortical areas in humans and macaques. Interestingly, Hutchison et al (2012) also described an stronger asymmetry in correlation strength between left and right FEF seeds with the contralateral hemispheres in humans than in monkeys. These findings are consistent with the general evolution to increased functional specialization in humans, including the saccadic fronto-parietal network (Petit et al., 2009; Petit et al., 2015).

From a phylogenetical perspective, recent event-related fMRI studies have also shown strong contralateral activations in monkeys, which were significantly weaker in putative human homologs, while the asymmetry between the hemispheres was stronger (Kagan et al., 2010). Among the sparse fMRI studies in non-human primates, a noteworthy fMRI experiment on two cynomolgus monkeys (*Macaca fascicularis*) has reported an intriguing lateralized activation in the pulvinar during the execution of visually guided saccades while the rest of the oculomotor network (including the FEF) was symmetrical (Baker et al., 2006). Outside the field of imagery, using cortical surface macro-potentials to directly compare the electrophysiological responses of the two hemispheres during the performance of a cognitive task, Sandrew et al. (1977) recorded preparatory responses above the prefrontal, precentral

and occipital cortex of stump-tail monkeys (*Macaca speciosa*) and showed that a shift during the preparation period over the prefrontal area was consistently present and dominant in one of the hemispheres (Sandrew et al., 1977). More precisely, the side on which the potential shift was greater depended on the hand that the animal was trained to use to give a response. Of note, Petit et al. (2015) recently demonstrated in humans that the dorsal fronto-parietal network including the FEF showed a robust rightward asymmetry in left-handers, even more pronounced when considering the sighting-dominant eye (Petit et al., 2015). Altogether, these findings point to the importance of ontogenetic experience (training of unilateral actions) and spatial orientation biases that can greatly influence future studies on functional hemispheric lateralization in animals, which in most cases are over-trained in particular tasks and manual actions. This commonality in human and nonhuman primate lateralized processing may provide cues for the evolutionary origin of some hemispheric specialization.

What is the human homologue location of the non-human primate FEF location?

Strictly speaking, the location of FEF differs between non-human primates and humans. How could it be otherwise considering the phylogenetic evolution of the frontal lobe between these species? We show in this review that a multi-factorial description of anatomical and functional FEF definitions suggests that the homologue of the FEF lying anterior to arcuate sulcus in monkeys corresponds more likely to the peri-precentral FEF identified in humans (Figure 6). But this is still not unanimous (e.g. (Vernet et al., 2014; Percheron et al., 2015; Schall et al., 2017)).

It seems certain nowadays that the FEF is sulcal, still located on one wall of the frontal lobe, either the arcuate sulcus in monkey or the precentral sulcus in human. Thus, one may just consider that as far as we will understand how the sulcal neuroanatomy evolved between non-human primates and humans, we will be able to understand the discrepancies of inter-species FEF locations. But we have described above that it is not yet fully conclusive. The cytoarchitectonic homologies pointed out interesting correspondence between the anterior bank of the monkey arcuate sulcus and the anterior bank of the human superior precentral sulcus (Rosano et al., 2003). But the proximity of the Brodmann's areas 44 and 45 bordering the arcuate sulcus in monkey and the inferior precentral sulcus in human leaves a doubt floating when considering the lat-FEF activation close to this later. As a matter of fact, the macaque has also a region caudal to the FEF in the premotor cortex with visual responsiveness and from which saccadic eye movements can be elicited by intracortical microstimulation, namely PEF (Preuss et al., 1996; Fujii et al., 1998). A provocative hypothesis has been proposed recently, namely the "lat-FEF" close to the inferior precentral sulcus would be homologous with the "FEF" in the arcuate sulcus, while the "med-FEF" in the superior precentral sulcus would be homologous with the premotor eye movement region caudal to the arcuate sulcus of macaques (Schall et al., 2017). Such an assignment is opposite to the most often considered homologies that have been featured in a recent comprehensive mapping of human cerebral cortical areas where FEF is considered as the superior precentral area and PEF the inferior one ((Glasser et al., 2016), see also (Amiez and Petrides, 2009; Thiebaut de Schotten et al., 2017)). An older fMRI study also goes in line with such a scheme by studying if the dorsal vs. ventral model of domain specificity for object vs. spatial working memory demonstrated in monkeys (Wilson et al., 1993; Scaldidhe et al., 1997) could be apply to the human

prefrontal cortex as well (Courtney et al., 1998). In the monkey, the area specialized for spatial working memory is located just anterior to the FEF (Wilson et al., 1993; Rao et al., 1997), thus Courtney et al. predicted that in humans, if a spatial working memory area did exist, it would also lie just anterior to the FEF. By comparing fMRI activation evoked during tasks involving spatial working memory, face working memory and eye movements, they found that the activity in the superior frontal sulcus was selectively related to spatial working memory and located distinctly anterior to the activity of the FEF centered in the junction between the superior frontal and precentral sulci. Thus, in humans, compared with monkeys, both areas occupy a more dorsal and posterior location, although the topological relationship between them has been conserved. The difference between monkeys and humans in the exact location of both FEF and the spatial working memory area have implications for human brain evolution. The more dorsal and posterior location of these areas in humans suggests that they were displaced by the expansion of the dorsolateral portion of the prefrontal cortex and the emergence of phylogenetically newer regions accompanied by sulcus displacements.

Is it conceivable that premotor cortex in humans takes over functions that are performed by prefrontal cortex in monkeys? The emergence of language, for example, may entail such a phylogenetic displacement. Indeed, functional characterization of the left dorsal premotor (PMd) module shows a behavioral pattern dominated by visual and language-related functions. Accordingly, functional connectivity also shows that the left ventral part of PMd is functionally coupled with Broca's area and temporal areas assigned to the ventral processing stream supporting object recognition (Gross, 1994). In line with these considerations, Genon et al. (2017) have shown with a quantitative approach of activation paradigms that the region at the junction of the superior precentral sulcus and the superior frontal sulcus, namely the med-FEF, could be

considered as the core dorsal premotor cortex and is engaged in a range of visuo-moto tasks including saccades (Genon et al., 2017). In line with previous studies, the authors therefore suggested that this region could be an important integration spot (including visuo-motor integration) beyond the relatively specific FEF label. They also showed that the region lying ventrally in the PMd, namely lat-FEF, is relatively more specifically engaged in saccades hence suggesting that the two anatomical eye-fields might actually correspond to two different functional concepts despite being both engaged in saccades. When examining the functional profile of the left ventral PMd module and its spatial correspondence with the right PMd premotor eye-field, it appeared that the left ventral PMd module conceptually overlapped with the left premotor eye-field (Genon et al., 2018). In support of this view, a recent meta-analysis has identified a premotor eye-field located in left PMd ventral module (Cieslik et al., 2016). Nevertheless, the left premotor ventral module appeared to be additionally related to language functions and overlaps with Area 55b, a language-related area recently suggested by Glasser et al. (2016). Behavioral functional characterization of the volume definition of Area 55b also revealed that this subregion is associated with simple eye movements. Altogether, the current evidence converges to suggest that the ventral subregion of the left PMd consists jointly of premotor eye-field and Area 55b.

This pattern of functional interaction with higher associative regions and engagement in abstract behavioral functions suggests that this region, at the transition between left prefrontal cortex and left ventral PMd, may be involved in deriving mental abstractions from one's current ongoing situation/environment (Genon et al., 2018). Such abstraction involves reference to a different time frame (required for long-term memory retrieval), a different spatial frame (required for scenes imagination), and a different mental frame (required for deception). There is no such clear evidence for rostro-

ventral subregion in right PMd suggesting that in humans, the right and left PMd are differently functionally characterized. Abstract functions could be more predominantly represented in the posterior part of prefrontal cortex/anterior part of premotor cortex in the left hemisphere than in the right hemisphere. Such a mixed behavioral profile could reflect the integration/coordination of visual identification (visual screening) processes with word production (speech execution) processes in the ventral PMd, although future studies are needed to empirically confirm this hypothesis.

Finally, we find it instructive to consider the finding that cortical control of the larynx in monkeys is located in area 6, while in humans it is located in area 4, presumably to provide for articulated speech (Simonyan, 2014). Considering the FEF region in the superior precentral sulcus as a premotor area could provide rationale for the findings of a recent study that compared diffusion tractography of corticostriatal pathways in humans and macaques (Neggens et al., 2015). In macaques a seed region in the rostral bank of the arcuate sulcus had connectivity primarily with the head of the caudate and also the anteromedial putamen, while a seed in primary motor cortex in the rostral bank of the central sulcus was connected with more posterior sections of caudate and mainly putamen. These observations replicate neuroanatomical tract tracing findings in macaques. In humans, though, the medial region of activation associated with saccadic eye movements was connected primarily to putamen and only a small portion of the caudate. Moreover, the region of striatum connected with the dorsal FEF in humans overlapped substantially the region of striatal connectivity with a point in primary motor cortex in the rostral bank of the central sulcus. We look forward to a future study examining the subcortical connectivity of the FEF region in the inferior precentral sulcus.

What would be the further proof of FEF homologies in primates?

There is every reason to believe that perfect homology cannot be definitively considered between the monkey FEF on the anterior bank of the arcuate sulcus and its counterpart centered on the upper part of the precentral sulcus in human. Some questions remain in non-human primates regarding the role of the premotor eye field (PEF) along the posterior bank of the arcuate sulcus which has been much less studied than the FEF. The existence of the PEF nevertheless makes it possible to consider that two regions related to saccadic eye movements finally exist along the arcuate sulcus while the execution of saccadic eye movements lead to two foci of activation along the precentral sulcus in humans. Thus, rather to try to understand how the FEF in monkeys (restricted to the anterior arcuate sulcus) may be homologous to either the superior or the inferior precentral FEF in humans, one may consider that the whole arcuate region encompassing eye movements activity in monkey has been split in two precentral regions in humans. This is in line with Figure 6 in Amiez and Petrides review (2009).

As presented in Table 1, there is a missing approach among the multi-factorial definition of the FEF, namely its structural connectivity (but see Neggers et al. 2015). Monkey FEF neurons interconnect extensively with other known cortical structures of the primate saccadic system, such as supplementary eye field, premotor cortex and intraparietal cortex (Huerta et al., 1987). In addition to the connections with cortical oculomotor structures FEF neurons connect extensively with many oculomotor-associated nuclei in the thalamus, midbrain and pons including the “brainstem saccade generator” nuclei (Huerta et al., 1986; Segraves and Goldberg, 1987; Segraves, 1992).

Does such connectivity exist for the posterior bank of the arcuate sulcus? Cortico-cortical connections have been observed with the inferior parietal lobule (Rozzi et al., 2006) but lot of less attention has been paid on that oculomotor-associated premotor area. Some changes in connections of FEF and visuomotor functions have emerged since the time prosimian and anthropoid primate lines of evolution diverged (Stepniewska et al., 2018) and needs for additional marker especially fibers co-localizations between structures to study their evolution and function. Some of these debates are resurfacing about homologous neuroanatomy not only for FEF location, but also for the identification of homologous white matter bundles at the level of the external/extreme capsule in both monkeys and humans (Mars et al., 2016; Petit et al., 2018).

The emergence of diffusion weighted-imaging tractography allows a promising solution to better understand the phylogenetical evolution of the oculomotor-associated areas between monkeys (FEF/PEF) and humans (med-FEF/lat-FEF). We may expect that anterior and posterior banks of the arcuate sulcus in the monkey could not present exactly the same types of cortico-cortical association and cortico-subcortical projection pathways. In line with these suggestions, Neggers' et al. have recently observed that the oculomotor cortico-striatal pathway starting in the med-FEF terminates in both putamen and caudate nucleus, with a prevalence for the putamen in humans as compared to macaques (Neggers et al., 2015). If dissociation would be also observed in human structural connectivity along the precentral sulcus, both in terms of association and projection pathways, it may offer a solution to the conclusion of Tehovnik et al. wrote in 2000 “the anatomy of FEFs in an enigma”.

References

- Amiez C, Petrides M (2009) Anatomical organization of the eye fields in the human and non-human primate frontal cortex. *Progress in Neurobiology* 89:220-230.
- Amiez C, Kostopoulos P, Champod A-S, Petrides M (2006) Local Morphology Predicts Functional Organization of the Dorsal Premotor Region in the Human Brain. *J Neurosci* 26:2724-2731.
- Babapoor-Farrokhran S, Hutchison RM, Gati JS, Menon RS, Everling S (2013) Functional connectivity patterns of medial and lateral macaque frontal eye fields reveal distinct visuomotor networks. *J Neurophysiol* 109:2560-2570.
- Bailey P, Von Bonin G (1951) *The isocortex of man*. Urbana: Univ. Illinois Press.
- Baizer JS, Bender DB (1989) Comparison of saccadic eye movements in humans and macaques to single-step and double-step target movements. *Vision Research* 29:485-495.
- Baker JT, Patel GH, Corbetta M, Snyder LH (2006) Distribution of Activity Across the Monkey Cerebral Cortical Surface, Thalamus and Midbrain during Rapid, Visually Guided Saccades. *Cereb Cortex* 16:447-459.
- Beauchamp MS, Petit L, Ellmore TM, Ingelholm J, Haxby JV (2001) A Parametric fMRI Study of Overt and Covert Shifts of Visuospatial Attention. *Neuroimage* 14:310-321.
- Berg DJ, Boehnke SE, Marino RA, Munoz DP, Itti L (2009) Free viewing of dynamic stimuli by humans and monkeys. *J Vis* 9:19 11-15.
- Berman RA, Colby CL, Genovese CR, Voyvodic JT, Luna B, Thulborn KR, Sweeney JA (1999) Cortical networks subserving pursuit and saccadic eye movements in humans: An fMRI study. *Human Brain Mapping* 8:209-225.
- Bizzi E (1968) Discharge of frontal eye field neurons during saccadic and following eye movements in unanesthetized monkeys. *Exp Brain Res* 6:69-80.
- Blanke O, Morand S, Thut G, Michel CM, Spinelli L, Landis T, Seeck M (1999) Visual activity on the human frontal eye field. *NeuroReport* 10:925-930.
- Blanke O, Spinelli L, Thut G, Michel CM, Perrig S, Landis T, Seeck M (2000) Location of the human frontal eye field as defined by electrical cortical stimulation: anatomical, functional and electrophysiological characteristics [In Process Citation]. *Neuroreport* 11:1907-1913.
- Blumer R, Maurer-Gesek B, Gesslbauer B, Blumer M, Pechriggl E, Davis-López de Carrizosa MA, Horn AK, May PJ, Streicher J, de la Cruz RR, Pastor ÁM (2016) Palisade Endings Are a Constant Feature in the Extraocular Muscles of Frontal-Eyed, But Not Lateral-Eyed, Animals. *Investigative Ophthalmology & Visual Science* 57:320-331.
- Bruce CJ, Goldberg ME (1985a) Primate frontal eye fields. 1: Single neurons discharging before saccades. *Journal of Neurophysiology* 53:603-635.
- Bruce CJ, Goldberg ME (1985b) Primate frontal eye fields. 2: Physiological and anatomical correlates of electrically evoked eye movements. *Journal of Neurophysiology* 54:714-734.
- Calabrese E, Badea A, Coe CL, Lubach GR, Shi Y, Styner MA, Johnson GA (2015) A diffusion tensor MRI atlas of the postmortem rhesus macaque brain. *NeuroImage* 117:408-416.
- Camalier CR, Gotler A, Murthy A, Thompson KG, Logan GD, Palmeri TJ, Schall JD (2007) Dynamics of saccade target selection: Race model analysis of double step and search step saccade production in human and macaque. *Vision Research* 47:2187-2211.

- Cieslik EC, Seidler I, Laird AR, Fox PT, Eickhoff SB (2016) Different involvement of subregions within dorsal premotor and medial frontal cortex for pro- and antisaccades. *Neuroscience & Biobehavioral Reviews* 68:256-269.
- Connolly CJ (1950) External morphology of the primate brain. Springfield: Charles C. Thomas.
- Corbetta M, Shulman GL (2002) Control of goal-directed and stimulus-driven attention in the brain. *Nat Rev Neurosci* 3:201-215.
- Corbetta M, Patel G, Shulman GL (2008) The Reorienting System of the Human Brain: From Environment to Theory of Mind. *Neuron* 58:306.
- Corbetta M, Akbudak E, Conturo TE, Drury HA, Linenweber MR, Ollinger JM, Petersen SE, Raichle ME, Snyder AZ, Van Essen DC, Shulman GL (1998) A common cortical network for attention and eye movements. *Neuron* 21:761-768.
- Courtney SM, Petit L, Maisog JM, Ungerleider LG, Haxby JV (1998) An area specialized for spatial working memory in human frontal cortex. *Science* 279:1347-1351.
- Crosby EC, Yoss RE, Henderson JW (1952) The mammalian midbrain and isthmus regions. 2. The fiber connections. The pattern for eye movements on the frontal eye field and the discharge of specific portion of this field to and through midbrain levels. *JCompNeurol* 97:357-381.
- Darby DG, Nobre AC, Thangaraj V, Edelman R, Mesulam MM, Warach S (1996) Cortical activation in the human brain during lateral saccades using EPISTAR functional magnetic resonance imaging. *Neuroimage* 3:53-62.
- Davidoff LM (1928) A visit to professor Förster's clinic in Breslau with special observation of his treatment of epilepsy. *Psychiatric Quart* 2:307-313.
- Deffieux T, Younan Y, Wattiez N, Tanter M, Pouget P, Aubry J-F (2013) Low-Intensity Focused Ultrasound Modulates Monkey Visuomotor Behavior. *Current Biology* 23:2430-2433.
- Deng SY, Goldberg ME, Segraves MA, Ungerleider LG, Mishkin M (1986) The effect of unilateral ablation of the frontal eye fields on the saccadic performance in the monkey. In: *Adaptive processes in visual oculomotor systems* (Keller EL, Zee DS, eds), pp 201-208. Oxford: Pergamon.
- Driscoll CA, Barr CS (2016) Studying longitudinal trajectories in animal models of psychiatric illness and their translation to the human condition. *Neuroscience research* 102:67-77.
- Duecker F, Formisano E, Sack AT (2013) Hemispheric Differences in the Voluntary Control of Spatial Attention: Direct Evidence for a Right-Hemispheric Dominance within Frontal Cortex. *Journal of Cognitive Neuroscience* 25:1332-1342.
- Einhäuser W, Kruse W, Hoffmann K-P, König P (2006) Differences of monkey and human overt attention under natural conditions. *Vision Research* 46:1194-1209.
- Falk D (1978) Cerebral asymmetry in Old World monkeys. *Acta Anat* 101:334-339.
- Falk D (2014) Interpreting sulci on hominin endocasts: old hypotheses and new findings. *Front Hum Neurosci* 8:134.
- Ferrier D (1874) The localization of function in the brain. *ProcRSocLondonSer B* 22:229-232.
- Foerster O, Penfield W (1930) THE STRUCTURAL BASIS OF TRAUMATIC EPILEPSY AND RESULTS OF RADICAL OPERATION1. *Brain* 53:99-119.
- Ford KA, Gati JS, Menon RS, Everling S (2009) BOLD fMRI activation for anti-saccades in nonhuman primates. *NeuroImage* 45:470-476.
- Förster O (1926) Zur operativen nehandlung der epilepsie. *J Neurol* 89:137-147.

- Fox PT, Fox JM, Raichle ME, Burde RM (1985) The role of cerebral cortex in the generation of voluntary saccades: a positron emission tomographic study. *J Neurophysiol* 54:348-369.
- Frey S, Pandya DN, Chakravarty MM, Bailey L, Petrides M, Collins DL (2011) An MRI based average macaque monkey stereotaxic atlas and space (MNI monkey space). *NeuroImage* 55:1435-1442.
- Fujii N, Mushiake H, Tanji J (1998) An oculomotor representation area within the ventral premotor cortex. *Proc Natl Acad Sci U S A* 95:12034-12037.
- Gabernet L, Meskenaite V, Hepp-Reymond M-C (1999) Parcellation of the lateral premotor cortex of the macaque monkey based on staining with the neurofilament antibody SMI-32. *Experimental Brain Research* 128:188-193.
- Genon S, Reid A, Li H, Fan L, Müller VI, Cieslik EC, Hoffstaedter F, Langner R, Grefkes C, Laird AR, Fox PT, Jiang T, Amunts K, Eickhoff SB (2018) The heterogeneity of the left dorsal premotor cortex evidenced by multimodal connectivity-based parcellation and functional characterization. *NeuroImage* 170:400-411.
- Genon S, Li H, Fan L, Muller VI, Cieslik EC, Hoffstaedter F, Reid AT, Langner R, Grefkes C, Fox PT, Moebus S, Caspers S, Amunts K, Jiang T, Eickhoff SB (2017) The Right Dorsal Premotor Mosaic: Organization, Functions, and Connectivity. *Cereb Cortex* 27:2095-2110.
- Gitelman DR, Parrish TB, Labar KS, Mesulam MM (2000) Real-time monitoring of eye movements using infrared video-oculography during functional magnetic resonance imaging of the frontal eye fields. *Neuroimage* 11:58-65.
- Glasser MF, Coalson TS, Robinson EC, Hacker CD, Harwell J, Yacoub E, Ugurbil K, Andersson J, Beckmann CF, Jenkinson M, Smith SM, Van Essen DC (2016) A multi-modal parcellation of human cerebral cortex. *Nature* 536:171-178.
- Godoy J, Lüders H, Dinner DS, Morris HH, Wyllie E (1990) Versive eye movements elicited by cortical stimulation of the human brain. *Neurology* 40:296-299.
- Gross CG (1994) How inferior temporal cortex became a visual area. *Cerebral Cortex* 5:455-469.
- Guitton D, Buchtel HA, Douglas RM (1985) Frontal lobe lesions in man cause difficulties in suppressing reflexive glances and in generating goal-directed saccades. *ExpBrain Res* 58:455-472.
- Hanes DP, Schall JD (1995) Countermanding saccades in macaque. *Visual Neurosci* 12:929-937.
- Hanes DP, Carpenter RHS (1999) Countermanding saccades in humans. *Vision Research* 39:2777-2791.
- Heide W, Binkofski F, Seitz RJ, Posse S, Nitschke MF, Freund HJ, Kompf D (2001) Activation of frontoparietal cortices during memorized triple-step sequences of saccadic eye movements: an fMRI study. *Eur J Neurosci* 13:1177-1189.
- Hervé G (1888) *La circonvolution de Broca - Etude de morphologie cérébrale*. Paris.
- Huerta MF, Krubitzer LA, Kaas JH (1986) Frontal eye field as defined by intracortical microstimulation in squirrel monkeys, owl monkeys, and macaque monkeys: I. Subcortical connections. *J Comp Neurol* 253:415-439.
- Huerta MF, Krubitzer LA, Kaas JH (1987) Frontal eye field as defined by intracortical microstimulation in squirrel monkeys, owl monkeys, and macaque monkeys. 2. cortical connections. *JCompNeurol* 265:332-361.

- Hutchison RM, Gallivan JP, Culham JC, Gati JS, Menon RS, Everling S (2012) Functional connectivity of the frontal eye fields in humans and macaque monkeys investigated with resting-state fMRI. *Journal of Neurophysiology* 107:2463-2474.
- Kagan I, Iyer A, Lindner A, Andersen RA (2010) Space representation for eye movements is more contralateral in monkeys than in humans. *Proceedings of the National Academy of Sciences* 107:7933-7938.
- Kano F, Tomonaga M (2009) How chimpanzees look at pictures: a comparative eye-tracking study. *Proceedings of the Royal Society B: Biological Sciences* 276:1949-1955.
- Kano F, Tomonaga M (2011) Species difference in the timing of gaze movement between chimpanzees and humans. *Anim Cogn* 14:879-892.
- Kano F, Hirata S, Call J, Tomonaga M (2011) The visual strategy specific to humans among hominids: A study using the gap–overlap paradigm. *Vision Research* 51:2348-2355.
- Kano F, Shepherd SV, Hirata S, Call J (2018) Primate social attention: Species differences and effects of individual experience in humans, great apes, and macaques. *PLOS ONE* 13:e0193283.
- Kim YH, Gitelman DR, Nobre AC, Parrish TB, Labar KS, Mesulam MM (1999) The large-scale neural network for spatial attention displays multifunctional overlap but differential asymmetry. *Neuroimage* 9:269-277.
- Koyama M, Hasegawa I, Osada T, Adachi Y, Nakahara K, Miyashita Y (2004) Functional magnetic resonance imaging of macaque monkeys performing visually guided saccade tasks: comparison of cortical eye fields with humans. *Neuron* 41:795-807.
- Leigh RJ, Zee DS (2015) *The neurology of eye movements*. New York: Oxford University Press.
- Lobel E, Kahane P, Leonards U, Grosbras M, Lehericy S, Le Bihan D, Berthoz A (2001) Localization of human frontal eye fields: anatomical and functional findings of functional magnetic resonance imaging and intracerebral electrical stimulation. *J Neurosurg* 95:804-815.
- Luna B, Thulborn KR, Strojwas MH, McCurtain BJ, Berman RA, Genovese CR, Sweeney JA (1998) Dorsal cortical regions subserving visually-guided saccades in humans: An fMRI study. *Cerebral Cortex* 8:40-47.
- Mars RB, Foxley S, Verhagen L, Jbabdi S, Sallet J, Noonan MP, Neubert FX, Andersson JL, Croxson PL, Dunbar RI, Khrapitchev AA, Sibson NR, Miller KL, Rushworth MF (2016) The extreme capsule fiber complex in humans and macaque monkeys: a comparative diffusion MRI tractography study. *Brain Struct Funct* 221:4059-4071.
- Martinez-Conde S, Macknik SL (2008) Fixational eye movements across vertebrates: comparative dynamics, physiology, and perception. *J Vis* 8:28 21-16.
- Melamed E, Larsen B (1979) Cortical activation pattern during saccadic eye movements in humans: Localization by focal cerebral blood flow increases. *AnnNeurol* 5:79-88.
- Mohler CW, Goldberg ME, Wurtz RH (1973) Visual receptive fields of frontal eye field neurons. *Brain Res* 61:385-389.
- Mota B, Herculano-Houzel S (2015) Cortical folding scales universally with surface area and thickness, not number of neurons. *Science* 349:74-77.
- Munoz DP, Everling S (2004) Look away: the anti-saccade task and the voluntary control of eye movement. *Nat Rev Neurosci* 5:218-228.
- Müri RM, Nirkko AC, Ozdoba C, Felblinger J, Heid O, Schroth G, Hess CW (1996) Functional organization of cortical control of prosaccades and antisaccades in the frontal lobes. A functional magnetic resonance imaging (fMRI) study. *Neuroimage* 3:S352.

- Nakahara K, Hayashi T, Konishi S, Miyashita Y (2002) Functional MRI of macaque monkeys performing a cognitive set-shifting task. *Science* 295:1532-1536.
- Neggers SF, Zandbelt BB, Schall MS, Schall JD (2015) Comparative diffusion tractography of corticostriatal motor pathways reveals differences between humans and macaques. *J Neurophysiol* 113:2164-2172.
- Nelson MJ, Boucher L, Logan GD, Palmeri TJ, Schall JD (2010) NONINDEPENDENT AND NONSTATIONARY RESPONSE TIMES IN STOPPING AND STEPPING SACCADE TASKS. *Attention, perception & psychophysics* 72:1913-1929.
- Nieuwenhuys R, Broere CA, Cerliani L (2015) A new myeloarchitectonic map of the human neocortex based on data from the Vogt-Vogt school. *Brain Struct Funct* 220:2551-2573.
- Owen R (1900) Descriptive and illustrated catalogue of the physiological series of comparative anatomy contained in the Museum of the Royal College of Surgeons of England. . London: Taylor & Francis.
- Paus T (1996) Location and function of the human frontal eye field: A selective review. *Neuropsychologia* 34:475-483.
- Penfield W, Rasmussen T (1950) The cerebral cortex of man. A clinical study of localization of function. New York: The Macmillan Company.
- Percheron G, Francois C, Pouget P (2015) What makes a frontal area of primate brain the frontal eye field? *Front Integr Neurosci* 9:33.
- Petit L, Beauchamp MS (2003) Neural basis of visually guided head movements studied with fMRI. *J Neurophysiol* 89:2516-2527.
- Petit L, Clark VP, Ingeholm JE, Haxby JV (1997) Dissociation of saccade-related and pursuit-related activation in human frontal eye fields as revealed by fMRI. *Journal of Neurophysiology* 77:3386-3390.
- Petit L, Orssaud C, Tzourio N, Salamon G, Mazoyer B, Berthoz A (1993) PET study of voluntary saccadic eye movements in humans: Basal ganglia-thalamocortical system and cingulate cortex involvement. *Journal of Neurophysiology* 69:1009-1017.
- Petit L, Sarubbo S, De Benedictis A, Chioffi F, Ptito M, Dyrby TB (2018) The existence of the inferior fronto-occipital fasciculus (IFOF) revealed in the non-human primate by ex-vivo diffusion-weighted tractography and blunt dissection. In: 26th ISMRM Annual Meeting. Paris, France.
- Petit L, Zago L, Vigneau M, Andersson F, Crivello F, Mazoyer B, Mellet E, Tzourio-Mazoyer N (2009) Functional asymmetries revealed in visually guided saccades: an FMRI study. *J Neurophysiol* 102:2994-3003.
- Petit L, Zago L, Mellet E, Jobard G, Crivello F, Joliot M, Mazoyer B, Tzourio-Mazoyer N (2015) Strong rightward lateralization of the dorsal attentional network in left-handers with right sighting-eye: an evolutionary advantage. *Hum Brain Mapp* 36:1151-1164.
- Pierrot-Deseilligny C, Rivaud S, Gaymard B, Agid Y (1991) Cortical control of memory-guided saccades in man. *ExpBrain Res* 83:607-617.
- Pierrot-Deseilligny C, Israël I, Berthoz A, Rivaud S, Gaymard B (1993) Role of the different frontal lobe areas in the control of the horizontal component of memory-guided saccades in man. *ExpBrain Res* 95:166-171.
- Power JD, Cohen AL, Nelson SM, Wig GS, Barnes KA, Church JA, Vogel AC, Laumann TO, Miezin FM, Schlaggar BL, Petersen SE (2011) Functional Network Organization of the Human Brain. *Neuron* 72:665-678.

- Preuss TM, Stepniewska I, Kaas JH (1996) Movement representation in the dorsal and ventral premotor areas of owl monkeys: a microstimulation study. *JCompNeuro* 371:649-676.
- Rao SC, Rainer G, Miller EK (1997) Integration of what and where in the primate prefrontal cortex. *Science* 276:821-824.
- Reuter-Lorenz PA, Herter TM, Guitton D (2011) Control of Reflexive Saccades following Hemispherectomy. *Journal of Cognitive Neuroscience* 23:1368-1378.
- Rivaud S, Müri RM, Gaymard B, Vermersch AI, Pierrot-Deseilligny C (1994) Eye movement disorders after frontal eye field lesions in humans. *ExpBrain Res* 102:110-120.
- Robinson DA, Fuchs AF (1969) Eye movements evoked by stimulation of frontal eye fields. *Journal of Neurophysiology* 32:637-648.
- Rosano C, Sweeney JA, Melchitzky DS, Lewis DA (2003) The human precentral sulcus: chemoarchitecture of a region corresponding to the frontal eye fields. *Brain Res* 972:16-30.
- Rozzi S, Calzavara R, Belmalih A, Borra E, Gregoriou GG, Matelli M, Luppino G (2006) Cortical Connections of the Inferior Parietal Cortical Convexity of the Macaque Monkey. *Cerebral Cortex* 16:1389-1417.
- Saleem KS, Logothetis NK (2012) A combined MRI and histology atlas of the rehsus monkey brain in stereotaxic coordinates, 2nd Edition. London: Academic Press.
- Sandrew BB, Stamm JS, Rosen SC (1977) Steady potential shifts and facilitated learning of delayed response in monkeys. *Experimental Neurology* 55:43-55.
- Sarkissov S, Filimnoff I, Kononowa E, Preobraschenskaja I, Kukuew L (1955) Atlas of cytoarchitectonics of the human cerebral cortex. Moscow: Medgiz.
- Scalaidhe SPO, Wilson FAW, Goldman-Rakic PS (1997) Areal segregation of face-processing neurons in prefrontal cortex. *Science* 278:1135-1138.
- Schall JD, Zinke W, Cosman JD, Schall MS, Paré M, Pouget P (2017) On the evolution of the frontal eye field: Comparisons of monkeys, Apes and humans. In: *Evolution of Nervous Systems*, 2nd Edition (Kaas J, H., ed), pp 249-275. Oxford: Academic Press.
- Schiller PH, Sandell JH (1983) Interactions between visually and electrically elicited saccades before and after superior colliculus and frontal eye field ablations in the rhesus monkey. *Experimental Brain Research* 49:381-392.
- Schiller PH, Chou I (1998) The effects of frontal eye field and dorsomedial frontal cortex lesions on visually guided eye movements. *Nature Neuroscience* 1:248-253.
- Schmitt O, Modersitzki J, Heldmann S, Wirtz S, Homke L, Heide W, Kompf D, Wree A (2005) Three-dimensional cytoarchitectonic analysis of the posterior bank of the human precentral sulcus. *Anat Embryol (Berl)* 210:387-400.
- Segraves MA (1992) Activity of monkey frontal eye field neurons projecting to oculomotor regions of the pons. *Journal of Neurophysiology* 68:1967-1985.
- Segraves MA, Goldberg ME (1987) Functional properties of corticotectal neurons in the monkey's frontal eye field. *Journal of Neurophysiology* 58:1387-1419.
- Shepherd SV, Steckenfinger SA, Hasson U, Ghazanfar AA (2010) Human-Monkey Gaze Correlations Reveal Convergent and Divergent Patterns of Movie Viewing. *Current Biology* 20:649-656.
- Simonyan K (2014) The laryngeal motor cortex: its organization and connectivity. *Current Opinion in Neurobiology* 28:15-21.
- Sommer MA, Tehovnik EJ (1997) Reversible inactivation of macaque frontal eye field. *ExpBrain Res* 116:229-249.

- Sommer MA, Tehovnik EJ (1999) Reversible inactivation of macaque dorsomedial frontal cortex: Effects on saccades and fixations. *Exp Brain Res* 124:429-446.
- Stanton GB, Deng SY, Goldberg ME, McMullen NT (1989) Cytoarchitectural characteristics of the frontal eye fields in macaque monkeys. *J Comp Neurol* 282:415-427.
- Stepniewska I, Pouget P, Kaas JH (2018) Frontal eye field in prosimian galagos: Intracortical microstimulation and tracing studies. *J Comp Neurol* 526:626-652.
- Striedter GF, Srinivasan S, Monuki ES (2015) Cortical Folding: When, Where, How, and Why? *Annual Review of Neuroscience* 38:291-307.
- Tallinen T, Chung JY, Rousseau F, Girard N, Lefevre J, Mahadevan L (2016) On the growth and form of cortical convolutions. *Nat Phys* advance online publication.
- Tehovnik EJ, Sommer MA, Chou IH, Slocum WM, Schiller PH (2000) Eye fields in the frontal lobes of primates. *Brain Res Brain Res Rev* 32:413-448.
- Thiebaut de Schotten M, Urbanski M, Batrancourt B, Levy R, Dubois B, Cerliani L, Volle E (2017) Rostro-caudal Architecture of the Frontal Lobes in Humans. *Cereb Cortex* 27:4033-4047.
- Tootell RB, Tsao D, Vanduffel W (2003) Neuroimaging weighs in: humans meet macaques in "primate" visual cortex. *J Neurosci* 23:3981-3989.
- Vanduffel W, Fize D, Peuskens H, Denys K, Sunaert S, Todd JT, Orban GA (2002) Extracting 3D from motion: differences in human and monkey intraparietal cortex. *Science* 298:413-415.
- Vanduffel W, Fize D, Mandeville JB, Nelissen K, Van Hecke P, Rosen BR, Tootell RB, Orban GA (2001) Visual motion processing investigated using contrast agent-enhanced fMRI in awake behaving monkeys. *Neuron* 32:565-577.
- Vernet M, Quentin R, Chanes L, Mitsumasu A, Valero-Cabre A (2014) Frontal eye field, where art thou? Anatomy, function, and non-invasive manipulation of frontal regions involved in eye movements and associated cognitive operations. *Front Integr Neurosci* 8:66.
- Vogt C, Vogt O (1926) Die vergleichend-architektonische und die vergleichend-reizphysiologische Felderung der Großhirnrinde unter besonderer Berücksichtigung der menschlichen. *Die Naturwissenschaften* 14:1190-1194.
- Von Bonin G, Bailey P (1947) *The neocortex of Macaca mulatta*. Urbana: Univ. of Illinois Press.
- von Economo C (1929) *The cytoarchitectonics of the human cerebral cortex*. London: Oxford University Press.
- von Kleist K (1934) *Gehirnpathologie*. Leipzig: J.A. Barth.
- Wagman IH, Krieger HP, Papatheodorou CA, Bender MB (1961) Eye movements elicited by surface and depth stimulation of the frontal lobe of *macaque mulatta*. *J Comp Neurol* 117:179-188.
- Walker AE (1940) A cytoarchitectural study of the prefrontal area of the macaque monkey. *J Comp Neurol* 73:59-115.
- Wardak C, Ibos G, Duhamel J-R, Olivier E (2006) Contribution of the Monkey Frontal Eye Field to Covert Visual Attention. *J Neurosci* 26:4228-4235.
- Wardak C, Ben Hamed S, Olivier E, Duhamel J-R (2012) Differential effects of parietal and frontal inactivations on reaction times distributions in a visual search task. *Frontiers in Integrative Neuroscience* 6:39.
- Wilson FAW, Scaldie SPO, Goldman-Rakic PS (1993) Dissociation of object and spatial processing domains in primate prefrontal cortex. *Science* 260:1955-1958.

Figure legends

Figure 1: Ferrier's Monkey Brain Map (1874). The highlighted area labeled '12' is the area in which Ferrier observed to cause eye and head movements when electrically stimulated. This area was located in the peri-arcuate frontal cortex.

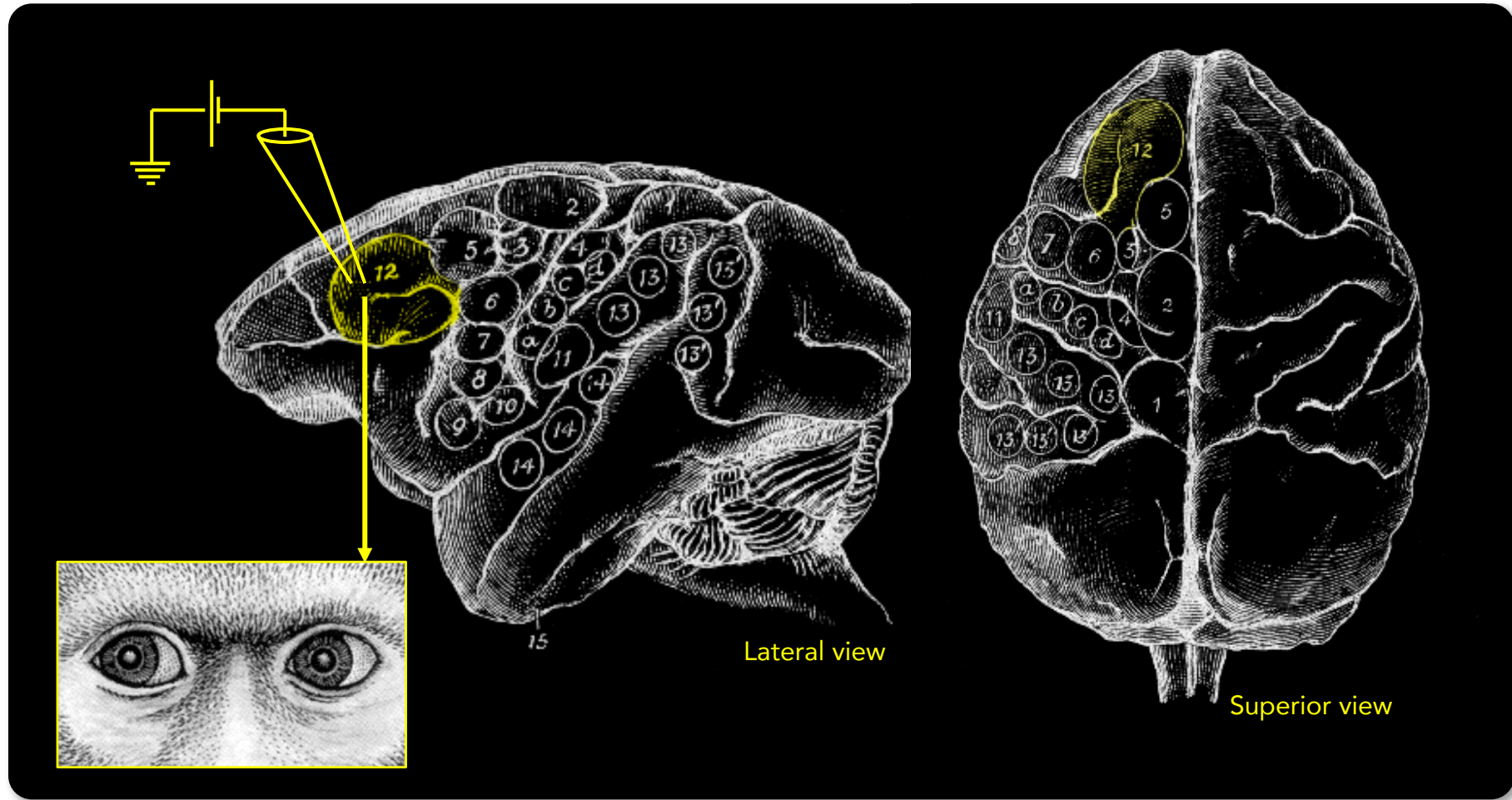
Figure 2: Lesions of patients. The lesions affected the precentral sulcus, between the superior and inferior frontal sulci, and the adjacent parts of the precentral gyrus and of the middle frontal gyrus, i.e. the area corresponding to the frontal eye field. These lesions did not extend to the internal capsule. Note that the frontal lesion restricted to the precentral sulcus, between the superior and inferior frontal sulci, induces some deficits in the performance of visually-guided saccades (Adapted from Rivaud et al. 1993).

Figure 3: Normalized regional cerebral blood flow (NrCBF) was measured using positron emission tomography (PET) and H₂-¹⁵O bolus intravenous injections in four right-handed healthy volunteers at rest and while performing self-paced voluntary horizontal saccadic eye movements in total darkness. FEF are localized along the precentral sulcus, at the level of the junction with the superior frontal sulcus (adapted from Petit et al. (1993)).

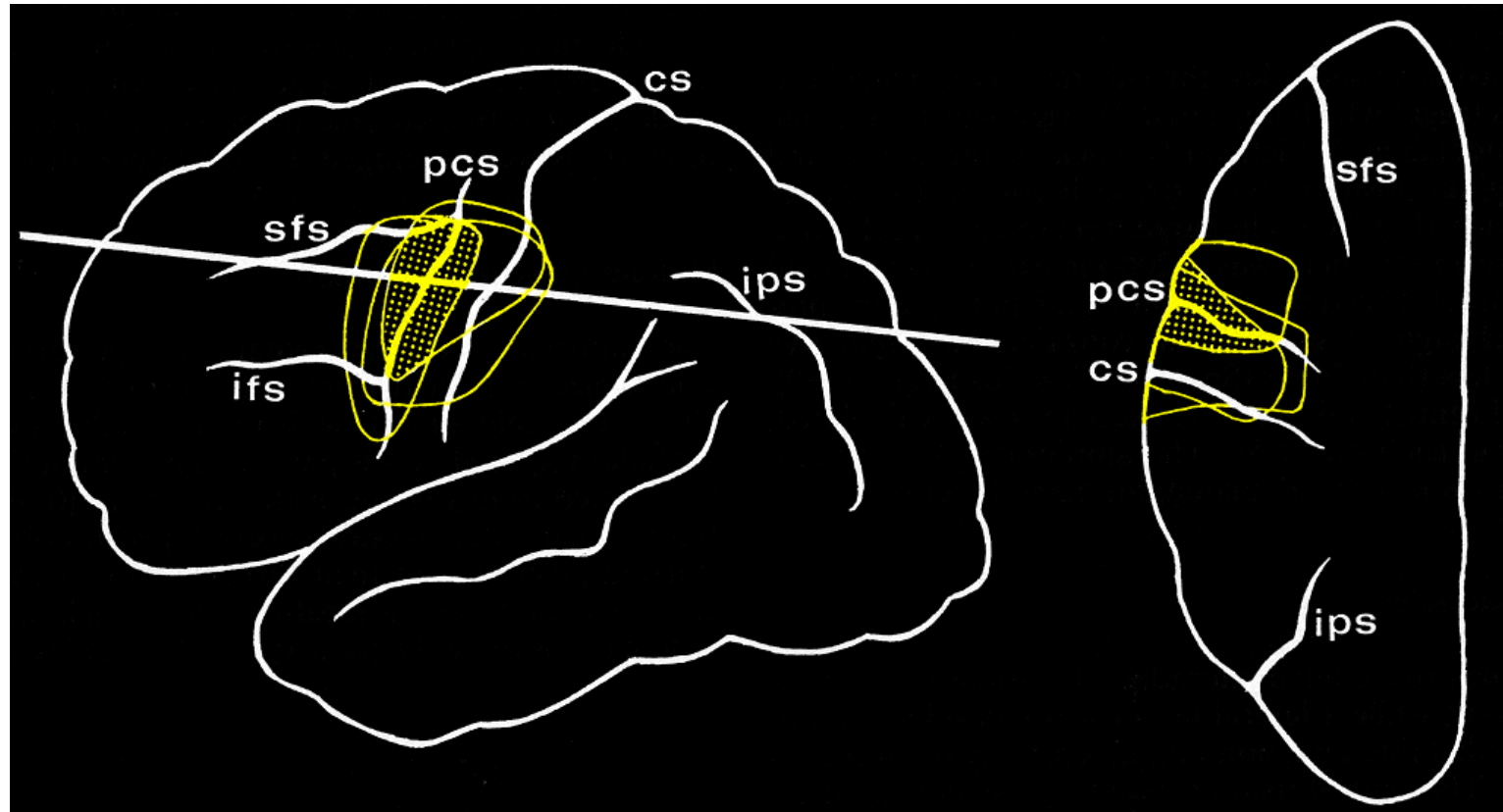
Figure 4: Fronto-parietal activation observed in fMRI during the execution of visually-guided saccades. The same pattern of activation was observed in multiple contexts and laboratories, especially the FEF activation with its characteristic pattern of activation centered on the junction between the precentral and the superior frontal sulci (white arrow). (Petit et al., 1997; Luna et al., 1998; Berman et al., 1999; Gitelman et al., 2000; Heide et al., 2001; Petit and Beauchamp, 2003)

Figure 5: Specific cytoarchitectonic distribution with group of large pyramidal cells in the layer V, along the anterior bank of the precentral sulcus, facing the posterior termination of the superior frontal sulcus (adapted from Rosano et al. 2003).

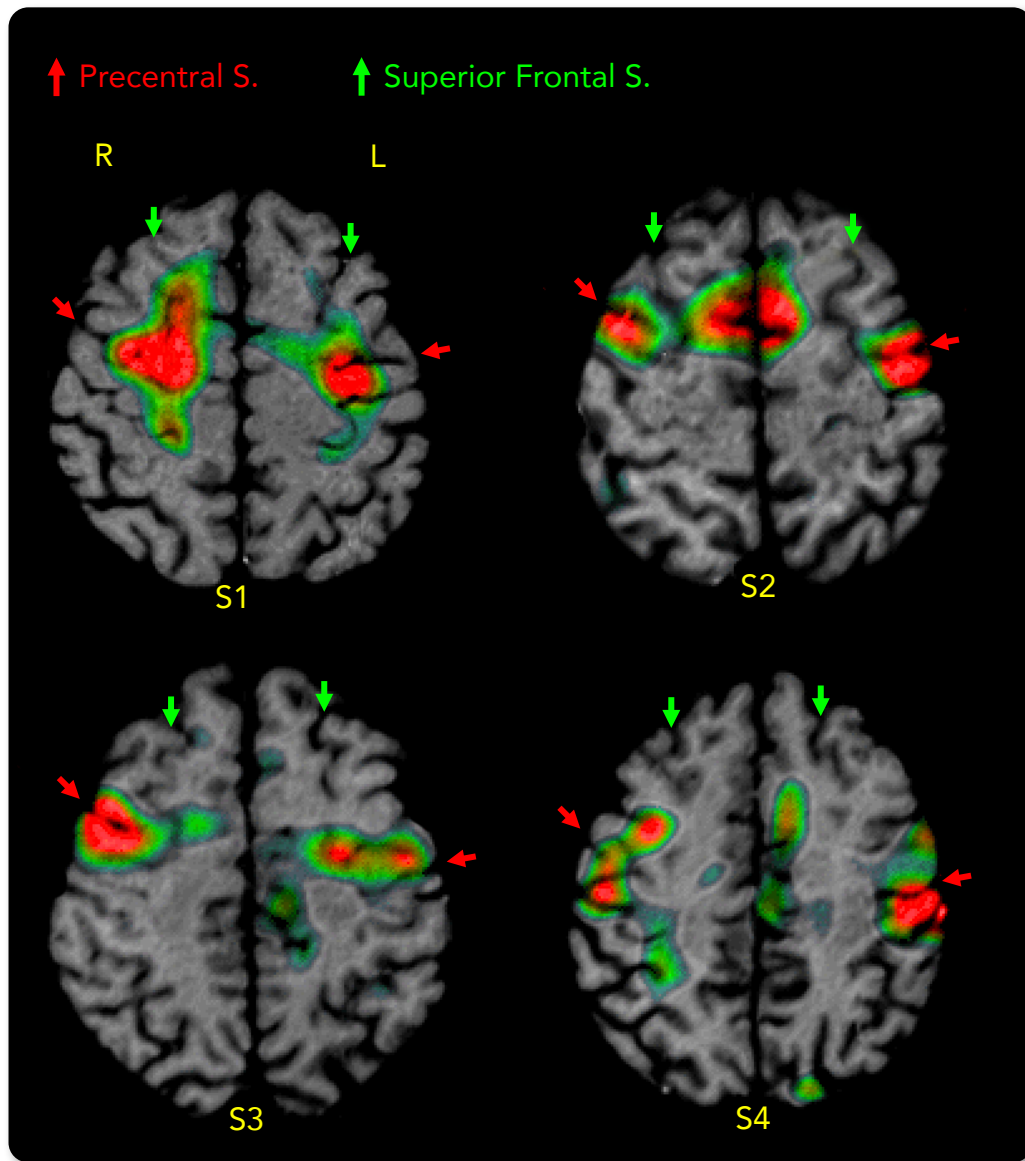
Figure 6: Summary of electrophysiological responses, lesion distributions, cytoarchitectonic characteristics as well as functional neuroimaging criteria allowing a multi-factorial definition of the FEF. From left to right, the figures were adapted from (Bruce and Goldberg, 1985b; Stanton et al., 1989; Sommer and Tehovnik, 1997; Koyama et al., 2004) on top row and (Rivaud et al., 1994; Berman et al., 1999; Blanke et al., 2000; Rosano et al., 2003)



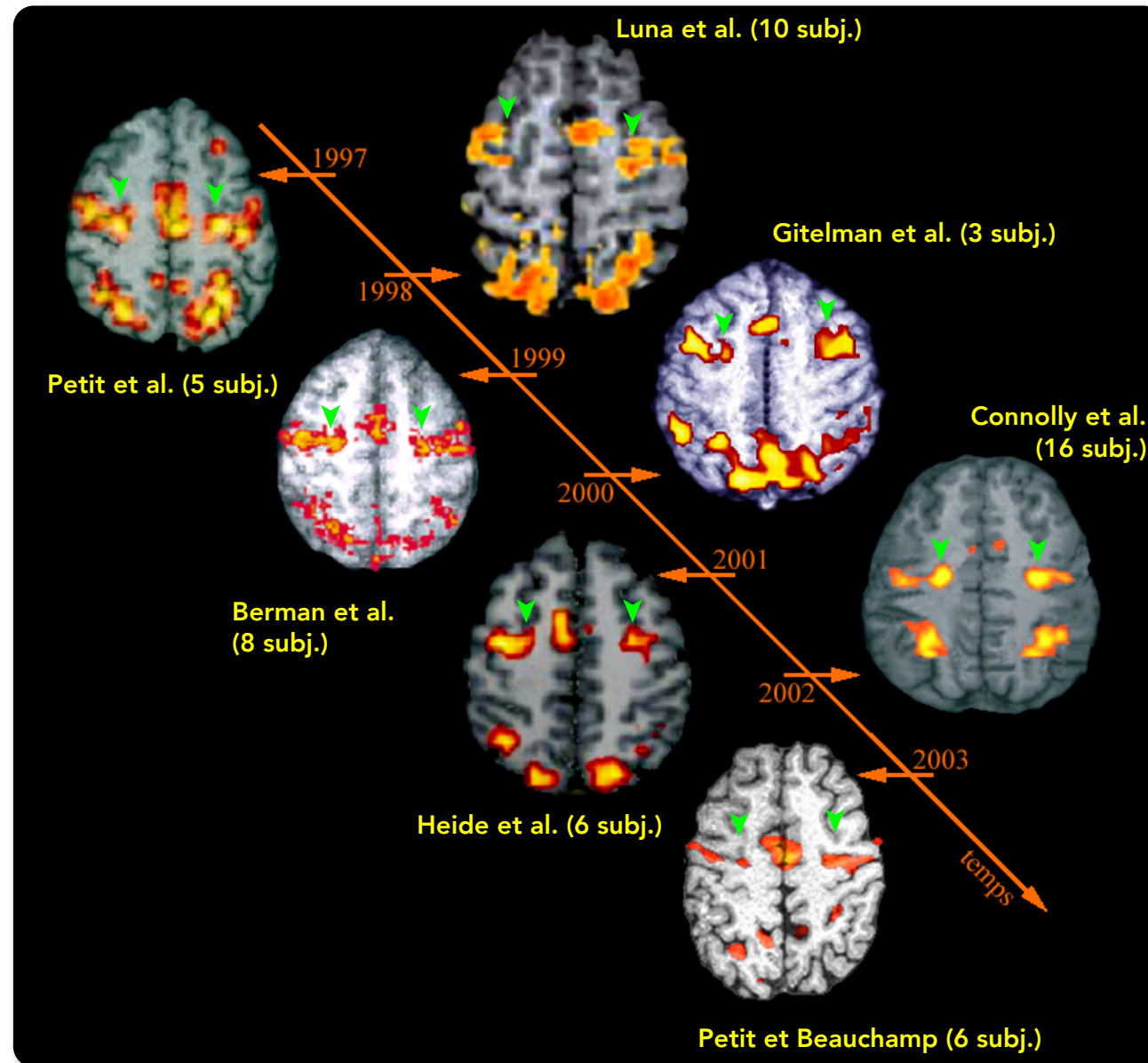
Figure



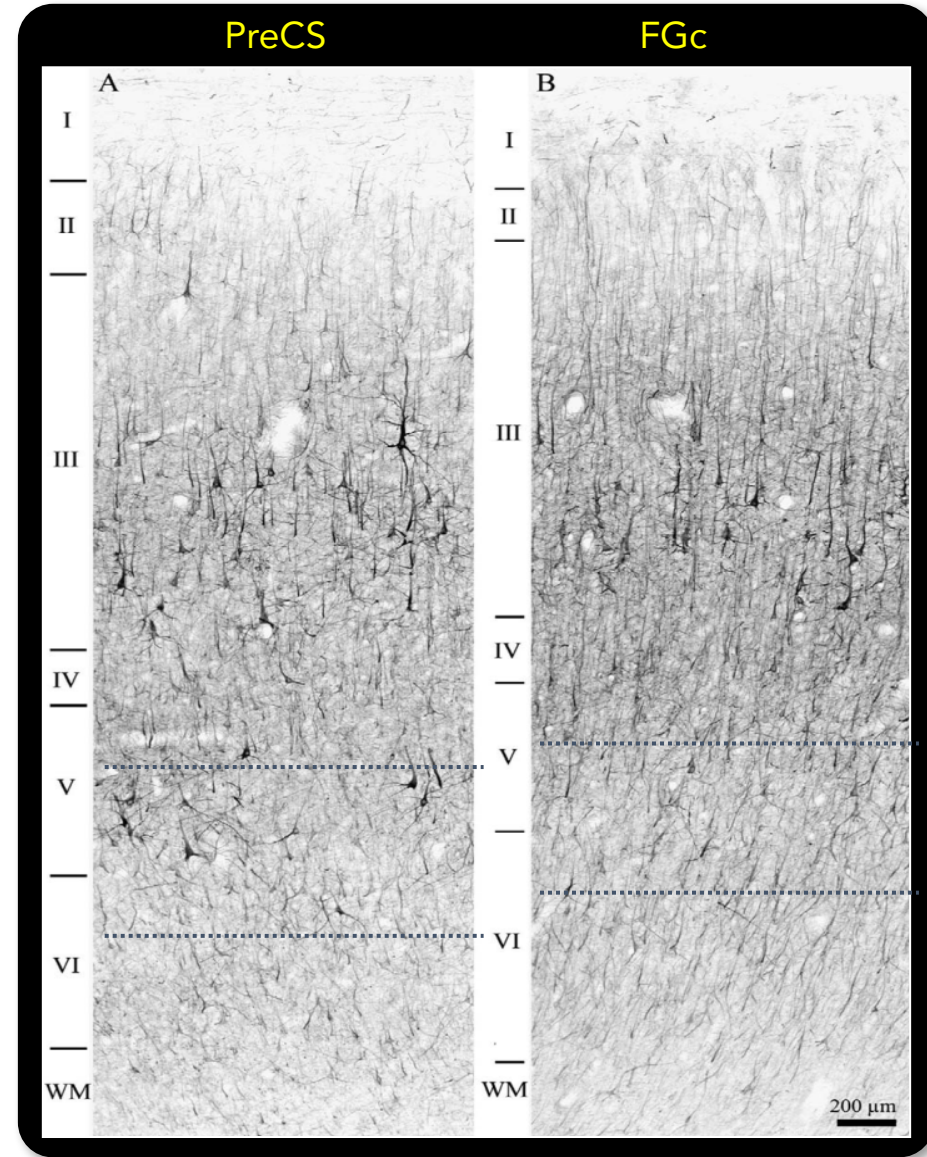
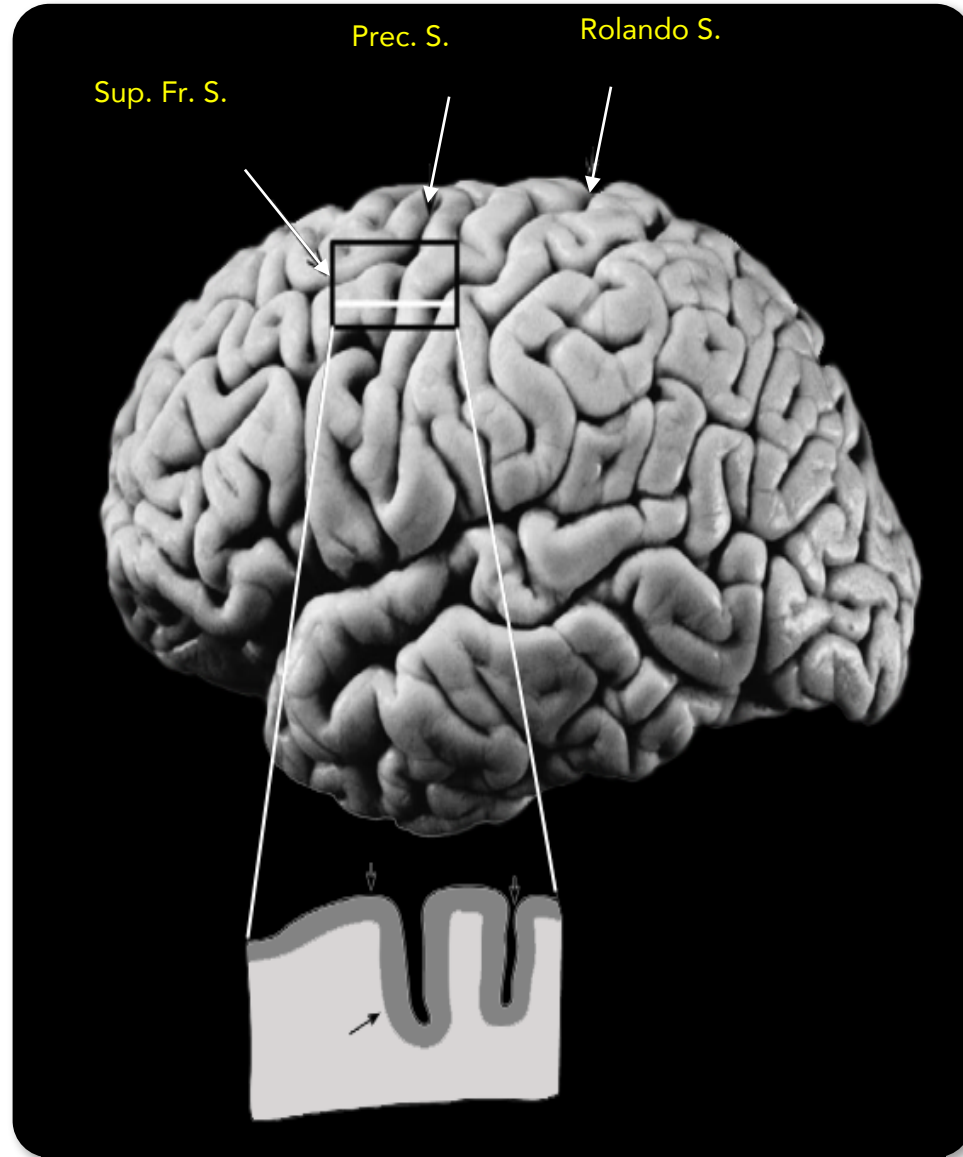
Figure



Figure



Figure



Figure

electrophysiological

lesion

cytoarchitectonic

functional

