



Pulsed cavitation therapy using high-frequency ultrasound for the treatment of deep vein thrombosis in an in vitro model of human blood clot

G Goudot, T Mirault, Benoît Arnal, C Boisson-Vidal, B Le Bonniec, P. Gaussem, A Galloula, M. Tanter, E. Messas, M Pernot

► To cite this version:

G Goudot, T Mirault, Benoît Arnal, C Boisson-Vidal, B Le Bonniec, et al.. Pulsed cavitation therapy using high-frequency ultrasound for the treatment of deep vein thrombosis in an in vitro model of human blood clot. *Physics in Medicine and Biology*, 2017, 62 (24), pp.9282-9294. 10.1088/1361-6560/aa9506 . hal-02327100

HAL Id: hal-02327100

<https://hal.science/hal-02327100>

Submitted on 22 Oct 2019

HAL is a multi-disciplinary open access archive for the deposit and dissemination of scientific research documents, whether they are published or not. The documents may come from teaching and research institutions in France or abroad, or from public or private research centers.

L'archive ouverte pluridisciplinaire **HAL**, est destinée au dépôt et à la diffusion de documents scientifiques de niveau recherche, publiés ou non, émanant des établissements d'enseignement et de recherche français ou étrangers, des laboratoires publics ou privés.

ACCEPTED MANUSCRIPT

Pulsed cavitation therapy using high-frequency ultrasound for the treatment of deep vein thrombosis in an in vitro model of human blood clot

To cite this article before publication: Guillaume Goudot *et al* 2017 *Phys. Med. Biol.* in press <https://doi.org/10.1088/1361-6560/aa9506>

Manuscript version: Accepted Manuscript

Accepted Manuscript is “the version of the article accepted for publication including all changes made as a result of the peer review process, and which may also include the addition to the article by IOP Publishing of a header, an article ID, a cover sheet and/or an ‘Accepted Manuscript’ watermark, but excluding any other editing, typesetting or other changes made by IOP Publishing and/or its licensors”

This Accepted Manuscript is © 2017 Institute of Physics and Engineering in Medicine.

During the embargo period (the 12 month period from the publication of the Version of Record of this article), the Accepted Manuscript is fully protected by copyright and cannot be reused or reposted elsewhere.

As the Version of Record of this article is going to be / has been published on a subscription basis, this Accepted Manuscript is available for reuse under a CC BY-NC-ND 3.0 licence after the 12 month embargo period.

After the embargo period, everyone is permitted to use copy and redistribute this article for non-commercial purposes only, provided that they adhere to all the terms of the licence <https://creativecommons.org/licenses/by-nc-nd/3.0>

Although reasonable endeavours have been taken to obtain all necessary permissions from third parties to include their copyrighted content within this article, their full citation and copyright line may not be present in this Accepted Manuscript version. Before using any content from this article, please refer to the Version of Record on IOPscience once published for full citation and copyright details, as permissions will likely be required. All third party content is fully copyright protected, unless specifically stated otherwise in the figure caption in the Version of Record.

View the [article online](#) for updates and enhancements.

Pulsed cavitational therapy using high-frequency ultrasound for the treatment of deep vein thrombosis in an in vitro model of human blood clot

G. Goudot¹, T. Mirault^{2, 3}, B. Arnal¹, C. Boisson-Vidal⁴, B. Le Bonniec⁴, P. Gaussem^{2, 4}, A. Galloula^{2, 3}, M. Tanter¹, E. Messas^{2, 3}, M. Pernot^{1*}

(1) Institut Langevin, INSERM U979, ESPCI Paris, CNRS UMR 7587, PSL Research University, Paris, France

(2) Georges-Pompidou European Hospital, APHP, Paris Descartes University – USPC Sorbonne Paris Cité, Paris, France

(3) INSERM U970 PARCC, Paris Descartes University – USPC Sorbonne Paris Cité University, Paris, France

(4) INSERM UMRS 1140, Paris Descartes University – USPC Sorbonne Paris Cité University, Paris, France

*: Corresponding author
MP and EM share the senior co-authorship

Abstract

Post-thrombotic syndrome, a frequent complication of deep venous thrombosis, can be reduced with early vein recanalization. Pulsed cavitational therapy (PCT) using ultrasound is a recent non-invasive approach. We propose to test the efficacy and safety of high-frequency focused PCT for drug-free thrombolysis (thrombotripsy) in a realistic in vitro model of venous thrombosis.

To reproduce venous thrombosis conditions, human whole blood was allowed to clot by stasis in silicone tubes (6 mm internal diameter) at a 30 cmH₂O pressure, maintained during the whole experiment. We engineered an ultrasound device composed of dual 2.25 MHz

transducers centered around a 6 MHz imaging probe. A therapeutic focus was generated at a 3.2 cm depth from the probe. Thrombotripsy was performed by longitudinally scanning the thrombus at 3 different speeds: 1 mm.s⁻¹ (n=6); 2 mm.s⁻¹ (n= 6); 3 mm.s⁻¹ (n= 12). Restored outflow was measured every 3 passages. Filters were placed to evaluate the debris size.

24 occlusive thrombi, of 2.5 cm mean length and 4.4 kPa mean stiffness, were studied. Flow restoration was systematically obtained by 9 subsequent passages (4.5 min maximum). By varying the device's speed, we found an optimal speed of 1 mm.s⁻¹ to be efficient for effective recanalization with 90 s (3 passages). Within 90 s, flow restoration was of 80, 62 and 74 % at respectively 1, 2 and 3 mm.s⁻¹. For all groups, cavitation cloud drilled a 1.7 mm mean diameter channel throughout the clot. Debris analysis showed 92 % of debris <10 µm, with no fragment > 200 µm.

CONCLUSION: High-frequency thrombotripsy allowed fast and effective recanalization of whole-blood thrombus in vitro, without any parietal alteration or bulky debris formation.

Keywords: thrombolysis – histotripsy – venous thrombosis – therapeutic ultrasound

Word count: abstract: 252 words, manuscript 2860 words.

I. Purpose

Deep venous thrombosis of the lower limbs is a frequent disease, affecting approximately 0.1% to 0.2% of people per year [1, 2, 3]. The main initial risk is the migration of fibrinocruoric emboli responsible for pulmonary embolism in about 30 % of cases (Heit *et al* 2016). In the long term, the main risk for proximal thrombosis is the appearance of post-thrombotic syndrome in about 20 to 50 % of cases (Kahn *et al* 2015), with an increased incidence in cases of iliofemoral persistent occlusion (Delis *et al* 2004). It is characterized by functional impotence, pain, pruritus and distal trophic disorders, with a major alteration of the quality of life (Kahn *et al* 2008). Current treatment of venous thrombosis is based on effective anticoagulation, expected to avoid embolic migration and to reduce morbidity and mortality. On the other hand, anticoagulation is frequently inefficient for recanalizing the occluded vessel [6, 7], with a consequently low influence on the incidence of post-thrombotic syndrome. Several studies suggest that the flow restoration in the occluded vein allows for long-term venous recanalization and thus limits the risk of post-thrombotic syndrome (Watson and Armon 2004, Enden *et al* 2012). The use of plasminogen activators or other thrombolytic agents has been shown to significantly improve the repermeabilization of the occluded vein. It was however associated with a 10% rate of severe haemorrhagic events (Watson and Armon 2004). Similarly, effective endovascular invasive recanalization procedures were associated with a decrease in post-thrombotic syndrome at 6 weeks (Enden *et al* 2012) whereas the persistence of a residual thrombus was associated with an increased risk of post-thrombotic syndrome (Comerota *et al* 2012). However this intervention is associated with a substantial risk of hematoma, false aneurysm, reocclusion or stent rupture.

Therapeutic ultrasound has been investigated by several groups as a promising drug-free approach for non-invasive recanalization in deep venous thrombosis settings. Various techniques such as histotripsy based on short high intensity ultrasound pulses or High Intensity Focused Ultrasound (HIFU) based on longer excitation pulses have been proposed as a way to fragment thrombi by acoustic cavitation without the need of injecting microbubbles. Vascular wall damage can however be observed when cavitation occurs near the vessel walls (Maxwell *et al* 2009). To overcome this issue, microtripsy has been recently introduced to generate a cavitation cloud contained in a small volume, therefore avoiding

any damage to the vessel walls (Zhang *et al* 2015b). Microtripsy requires a very high negative pressure to reach the intrinsic cavitation threshold (-30 MPa), which remains challenging to achieve in vivo. We propose hereby an alternative approach by increasing the ultrasound frequency (a frequency lower than 1.5 MHz is used in most histotripsy applications) in order to decrease the focus size and achieve very accurate fragmentation of the thrombus without damaging the vessel walls. The goal of this study was to 1) evaluate the feasibility of this approach on an in vitro model of human blood clot, 2) assess the recanalization efficacy of pulsed cavitation ultrasound and 3) quantify the size of the debris.

II. Materials and methods

1) Obtaining an occlusive thrombus

Human citrated (3.2%) whole blood was obtained from healthy volunteers from the French Blood Bank Institute (Etablissement Français du Sang, Paris, France, agreement ref. C CPSL UNT n°13/EFS/064). The subjects had normal complete blood count, denied having taken drugs interfering with haemostasis in the past 10 days and gave written informed consent. Coagulation was induced by adding 20 mM calcium chloride (CaCl_2 , number C 5080; Sigma Chemical®, St. Louis, MO, USA). Aprotinin (100 kIU/mL final concentration; Trasylol $500\,000$ kIU/ 50 mL, Bayer®) was added to block the endogenous fibrinolysis during the recanalization procedure. Clots of 2.5 cm in length were obtained by coagulation under stasis at 37°C in sealed roughened silicone tubes (6 mm wide, 1 mm thick, close to the characteristics of the human femoral vein) and held in vertical position for 1 hour after the deposition of 0.8 ml of citrated whole blood. After coagulation and thrombus retraction, the cap was removed and the tube placed horizontally and charged with a saline solution (0.9% NaCl) via a pressure column at 30 cm H_2O . Non-obstructive thrombi were not retained for the experiments. The silicon tube was positioned in order to approach a realistic depth based on an example of human femoral vein (Figure 1).

2) Thrombi stiffness evaluation

Shear wave elastography was performed using a clinical ultrafast scanner (Aixplorer®, Supersonics Imagine®, Aix-en-Provence, France) and a linear ultrasound probe (SL10-2, central frequency 6 MHz, 192 elements). Thrombus stiffness was obtained by measuring the

1
2
3
4
5
6
7
8
9
10
11
12
13
14
15
16
17
18
19
20
21
22
23
24
25
26
27
28
29
30
31
32
33
34
35
36
37
38
39
40
41
42
43
44
45
46
47
48
49
50
51
52
53
54
55
56
57
58
59
60

mean elasticity of three circular regions of interest at a distance from the walls to avoid interference with the silicone tube's wall stiffness.

3) Thrombotripsy device

Using an in-house heterodyne interferometer (Royer *et al* 1992), two 2.25 MHz focused transducers (central frequency 2.25 MHz, focal distance 38 mm, F/D=1, Imasonic®, Voray-sur-l'Ognon, France) were positioned confocally on either side of a SL10-2 probe. The whole system was assembled thanks to 3D printed parts, immersed in a degassed water-bath, and moved by a motor along the silicone tube. The focal point was located 3.2 cm away from the imaging probe (Figure 2). The size of the focal spot (-6 dB) in the plane of the 2 transducers was 0.45 x 1.25 mm at low pressure. The transducers alone had a theoretical focal spot of 0.67 mm x 4.667 mm. Using these two aperture confocal transducers allowed reaching high enough peak negative pressure for cavitation inception even though their aperture was small (38 mm diameter). The use of two confocal transducers allowed reducing the non-linear propagation effects as shown in simulation by Fowler *et al.* and Lafond *et al.* (Fowler *et al* 2013, Lafond *et al* 2017). As a consequence, such a setup allowed a better spatial localization of the focal point and a higher negative pressure compared to what would be generated by a single large aperture. The two transducers were driven by a signal generator (Tektronix®) amplified by a gain of 60dB by a 2.5 kW power amplifier (GA-2500, RITEC®, USA). The signals were composed of bursts of 8-cycles at 2.25 MHz transmitted with a Pulse Repetition Frequency (PRF) of 100Hz. The negative pressure's peak generated at the focus of the two confocal transducers was measured with an optical interferometer at -15 MPa.

4) Recanalization:

The SL10-2 probe was used to appropriately align the device with the tube in order to place the focal spot in the center of the tube. Each group received 3 sequences of cavitation (1 sequence = 3 passages) along the thrombus, with assessment of the restored flow after each sequence. One passage is the displacement of the device along the thrombus length. We fixed three different passage speeds along the thrombus: 1 mm.s⁻¹ (n=6; 1 passage=30 s), 2 mm.s⁻¹ (n=6; 1 passage=15 s) and 3 mm.s⁻¹ (n=12; 1 passage=10 s). Thus, the total cavitation time (3 sequences) ranged between 1.5 min (at 3 mm.s⁻¹) to 4.5 min (at 1 mm.s⁻¹). The drilled channel was longitudinally scanned by plane-by-plane volumetric acquisition with

1 a dedicated probe (SuperLinear™ Volumetric SLV16-5, Supersonics, Aix en Provence, France)
2 to assess the continuity of the thrombus recanalization.

3 5) Outflow evaluation

4 After each sequence, outflow was investigated by measuring the volume of the outflow
5 solution for a defined period of 1 minute. Initial flow measurement was carried out after
6 mounting the tube with the pressure column (30 cmH₂O i.e. 22 mmHg). Results are
7 expressed as a percentage of the maximum flow rate (flow rate measured with the silicone
8 tube without thrombus under the same conditions).

9 6) Debris analysis

10 The outflow was filtered through 2 consecutive filters with 100 µm and 40 µm nylon
11 mesh filters (Cell Stainer, BD Biosciences®). Each filter was rinsed with a saline solution,
12 dried, and analysed under an optical microscope. Debris were counted by scanning the
13 whole filter under a microscope, using x100 and x200 optical magnifications. Small debris
14 (<40 µm) were collected and then analysed by sampling using a computerised counter (Cell
15 Counter BioRad Laboratory®). The diameter distribution of the small debris is represented by
16 the number of debris normalized to the removed thrombus volume.

17 7) Statistical analysis

18 Continuous variables, presented as their mean ± standard deviation, were compared with
19 the Mann–Whitney U-test, or Kruskal–Wallis test when comparing more than 2 groups (3
20 different speed groups). Variances between groups were compared using Levene's test with
21 a Bonferroni correction for multiple comparisons. Two-sided p values <0.05 were considered
22 significant. All statistical computations used the R software.

23 III. Results

24 Twenty-four consecutive adherent thrombi were evaluated. After 1 hour of clot
25 formation and retraction, the thrombus occupied the tube volume (6 mm internal diameter)
26 and 2.51 cm in length on average. Only occlusive thrombi were retained, with a microflow
27 through the thrombus lower than 0.5 mL.min⁻¹. Shear wave elastography of the thrombus
28 showed an average stiffness of 4.4 ± 1.8 kPa, corresponding to a recent deep venous
29 thrombosis (Mfoumou *et al* 2014).

1
2
3
4
5
6
7
8
9
10
11
12
13
14
15
16
17
18
19
20
21
22
23
24
25
26
27
28
29
30
31
32
33
34
35
36
37
38
39
40
41
42
43
44
45
46
47
48
49
50
51
52
53
54
55
56
57
58
59
60

1) Recanalization efficiency:

Histotripsy formed a circular channel of 1.7 ± 0.4 mm mean cross sectional diameter throughout the clot (the average volume of thrombus removed was 5.70 mm^3) (a movie of the recanalization procedure is presented in the supplementary materials). Transverse alignment of the device made it possible to center the cavitation cloud so it did not reach the tube's walls. End experiment examination revealed a residual thrombus coating the tube's inner walls of 2.1 mm mean thickness. This ensured that the cavitation cloud was well centered and far from the tube's walls, while respecting the material's integrity (Figure 3).

2) Speed and time for thrombus recanalization

A speed of 1 mm.s^{-1} allowed efficient recanalization ($80 \pm 7\%$) after only one sequence (3 passages), corresponding to a treatment duration of 90 s (Figure 4). For the same duration time, we obtained only $61 \pm 32\%$ at 2 mm.s^{-1} and $74 \pm 22\%$ at 3 mm.s^{-1} ($p = \text{NS}$ for all groups). When comparing the time required for effective recanalization, regardless of the transducer's speed, an average time of 76 ± 17 s was required to obtain a flow recovery at 70% and 101 ± 45 s for a flow at 80% of the initial flow (Figure 5). However, flow restoration variance between thrombi recanalizations was significantly lower at a speed of 1 mm.s^{-1} , 7.4%, compared to other speeds (32.5% for 2 mm.s^{-1} : $p = 0.003$; 22.4% for 3 mm.s^{-1} : $p = 0.027$).

3) Debris analysis

Gross examination of the $100 \text{ }\mu\text{m}$ filter at the end of each experiment revealed no macroscopic debris, whatever the speed group. Microscopic analysis of the nylon mesh filters (Figure 6) found rare debris (1.6 ± 1.7 per thrombus) but none bigger than $200 \text{ }\mu\text{m}$, which is consistent with the gross examination findings (Figure 7). The small debris diameter distribution (less than $40 \text{ }\mu\text{m}$) is represented in Figure 8, according to the device's speed and reported by the number of debris, normalized to the removed thrombus volume. No significant difference was noticed between the three groups of speed: $p = 0.30$ with the Kruskal-Wallis test. For the absolute number of small debris, a non-significant trend to an increase of small debris was observed at a speed of 1 mm.s^{-1} , which corresponds to a slightly larger volume of recanalized channel ($89 \pm 29 \text{ mm}^3$ for 1 mm.s^{-1} vs. $50 \pm 14 \text{ mm}^3$ for other speeds, $p = 0.008$) with a lower residual thrombus (1.93 ± 0.20 vs. $2.20 \pm 0.11 \text{ mm}$, $p = 0.01$).

IV. Discussion

We aimed at demonstrating the effectiveness of thrombotripsy to recanalize a silicon tube containing an occlusive thrombus obtained with human whole blood stasis, reproducing as closely as possible the conditions of a recent femoral vein thrombosis. For this reason, we performed thrombus in stasis at 37°C, in whole blood obtained from fresh human blood. Obtaining a thrombus adhering well to the walls was an important step, in order to prevent the migration of the entire thrombus when loaded with the pressurized saline solution. Moreover, it avoided the use of stenosis to block the clot as used in other studies (Zhang *et al* 2015a, 2015b, 2016). We abandoned this procedure, first because it deviates from physiological conditions, second because when recanalization is performed, it turns out that the thrombus migrates inside the stenosis, therefore reducing the debris to be drained by the restored outflow. Our initial use of a 600 kHz transducer failed to form a cavitation cloud within the channel without creating cavitation on the outer walls of the tube. This shielding reduced the acoustic power at the focus depth and thus the cavitation activity in the channel. Moreover, the formation of a large cavitation cloud could damage the vessel walls. Depending on the emitted acoustic power, the cavitation cloud position varied unpredictably.

In our study, the use of higher frequency confocal transducers solved these issues. It allowed forming a cloud of limited size with isotropic dimensions (2x2x2 mm). Compared to large phased array systems powered with multi-channel electronics, this system was designed and built at a much lower cost. It induced a complete repeatability of the cavitation cloud position, which will enable a higher innocuousness of the treatment for future in vivo trials.

Sonothrombolysis usually corresponds to multiple techniques whose only common feature is the use of ultrasound during the thrombolysis procedure. The main techniques developed are High Intensity Focused Ultrasound (HIFU), for which the main advantage is the use of the thermal properties of ultrasound waves to facilitate the action of a chemical thrombolysis (Bader *et al* 2016, Wright *et al* 2012). Thrombus fragmentation techniques using microbubbles underlined the mechanical thrombolytic effects of gas microbubbles, which can be injected or directly formed by cavitation alone. In order to develop a strictly non-invasive technique, our work stands on a model of cavitation alone, according to

1
2
3
4
5
6
7
8
9
10
11
12
13
14
15
16
17
18
19
20
21
22
23
24
25
26
27
28
29
30
31
32
33
34
35
36
37
38
39
40
41
42
43
44
45
46
47
48
49
50
51
52
53
54
55
56
57
58
59
60

1 previous work from the University of Michigan [11, 18, 19, 20]. In order to improve this
2 method, we used a higher frequency 2-channel device, developed a model close to the
3 human venous thrombosis and defined the optimal therapeutic time for a recent thrombus
4 length of 2.5 cm as studied herein. The advantage of our technique, even though it has not
5 been tested yet in vivo, is the use of a smaller device, easier to handle. Cavitation with our
6 device can be achieved with commercially available generators and amplifiers.

7 Flow restoration was initiated as soon as a little channel was formed along the thrombus,
8 with a rapid increase during the procedure related to the channel enlargement. Longitudinal
9 alignment of the thrombus, with control of the channel drilling throughout the procedure,
10 allowed rapid recanalization by performing continuous cavitation with a fixed transducer
11 speed.

12 We defined the 1 mm.s^{-1} speed as the optimal speed of therapy from our 3 experimental
13 conditions. Indeed, it allowed a minimal number of passages (3) to achieve the optimal flow
14 rate ($> 80\%$) with a short time of therapy (90 s). The time required to recanalize a thrombus
15 did not depend significantly on the speed. At higher velocities (2 and 3 mm.s^{-1}), complete
16 recanalization required more passages, which ended to the same recanalization than at 1 mm.s^{-1} . We can note, however, that a higher variability of the recanalization time was
17 observed at higher speed. We can anticipate that a lower speed would also provide a
18 complete recanalization, but it would require longer treatment time, which would increase
19 the exposure risk of the vessel wall. Our objective being to allow a fast and safe
20 recanalization, we did not choose to explore lower speeds than 1 mm.s^{-1} . This method of
21 longitudinal thrombolysis greatly shortened the procedure's duration. However, this
22 requires adapting the displacement of the transducer in order to follow the venous
23 thrombus. Such a device can be developed using image guidance combined to a robotic arm.

24 The purpose of the thrombus recanalization procedure was not to remove the entire
25 thrombus clotted inside the tube but to create a small flowing channel in the clot.
26 Recanalization was conducted at a distance from the tube's walls, in order to limit as much
27 as possible the risk of parietal injury. Moreover, even with a small diameter channel, good
28 outflow (more than 80% of the maximal flow) was obtained. Although the presence of
29 residual thrombus may expose to the risk of post-procedure venous occlusion, we plan in
30 further pre-clinical studies to perform the procedure under effective anticoagulation. We

1 expect the recanalization to allow the heparin treatment to act locally and maintain the
2 vessel's permeability.

3 Thrombus elastography was achieved to verify our thrombosis model. An average
4 thrombus elasticity of 4.5 kPa was consistent with the maturation time of 1 hour after in
5 vitro coagulation induction. According to the study carried out by Mfoumou et al [16], with
6 the same Aixplorer® apparatus on in vivo thrombosis in the rabbit, 5 kPa thrombus actually
7 corresponded to a thrombus triggered in 1 to 2 hours. We did not test our device on
8 thrombus with a higher stiffness, due to the conditions needed for thrombus maturation,
9 with a progressive enrichment in fibrin as well as the loss of the platelets, which could not be
10 achieved in our in vitro conditions.

11 Debris formation is inherent to any recanalization procedure. The release of small debris
12 is necessary to allow secure venous recanalization. In our experiment, we did not notice any
13 macroscopic debris or any debris with a diameter over 200 µm. Occlusion of the pulmonary
14 artery or its proximal branches, responsible for proximal pulmonary embolism is only
15 triggered by bulky macroscopic thrombi. However, overall innocuousness of the debris
16 obtained is difficult to assess in vitro. During a perfusion lung scintigraphy, between 200 000
17 and 700 000 particles of albumin aggregates are injected, with a diameter between 10 and
18 90 µm and with a maximum diameter of 150 µm. Even though albumin aggregates will block
19 some lung capillaries (between 1/200 and 1/1000 (Dworkin *et al* 1966)), this examination is
20 considered as safe, without significant hypoxemia due to arteriolar blockade (Renowden *et*
21 *al* 1991) and is performed in daily practice to diagnose pulmonary embolism. We mainly
22 obtained debris corresponding to fragments of red blood cells, size <10 µm not threatening
23 to the pulmonary vascular tree. Debris likely to obstruct a pulmonary arteriole, i.e. over 100
24 µm diameter in theory, were very scarce (more than 99% of the debris were under 40 µm).
25 The risk of poor tolerance due to the embolization of these debris is therefore very low with
26 a small number of affected arterioles.

27 The limitation of this in vitro model of deep venous thrombosis is the relatively short size
28 of the thrombus. This limits the procedure to suspended proximal thrombosis. Finally, the
29 potential danger of the debris requires a specific evaluation in animals. In order to obtain a
30 sufficient venous diameter close to the human femoral vein, the pig model is the smallest
31 animal model appropriate for this purpose, as already tested (Maxwell et al 2009, Zhang et

1
2
3
4
5
6
7
8
9
10
11
12
13
14
15
16
17
18
19
20
21
22
23
24
25
26
27
28
29
30
31
32
33
34
35
36
37
38
39
40
41
42
43
44
45
46
47
48
49
50
51
52
53
54
55
56
57
58
59
60

al 2017). In an in vivo application, we need to consider tissue attenuation. With an average depth of 3 cm of the femoral vein in pig, and an average tissue attenuation of 0.6 dB.MHz⁻¹.cm⁻¹, we expect a total attenuation of 4.05 dB with a 2.25 MHz transducer. This attenuation factor can be easily compensated by increasing the amplification gain by 1.6 fold. On the other hand with histotripsy, tissue heating remains limited due to the low energy transmitted. With our setup at PRF of 100Hz, the total temporal average acoustic power transmitted in tissue is evaluated to be less than 1W with therefore no risk of heating the tissue on the beam path.

Our thrombotripsy device has demonstrated its efficacy and safety in a recanalization model close to the conditions of human deep venous thrombosis. We carried out recanalization through recent thrombi, at a distance from the vessel's walls, without generating large debris. This first experiment is encouraging in the development of a non-invasive tool for venous recanalization.

Acknowledgements:

We would like to thank Cardiawave[®] for the funding support. We also thank Mrs. Beatrice Walker for her careful proofreading of the manuscript.

V. References

Bader K B, Bouchoux G and Holland C K 2016 Sonothrombolysis. *Adv. Exp. Med. Biol.* **880** 339–62 Online: <http://www.ncbi.nlm.nih.gov/pubmed/26486347>

Comerota A J, Grewal N, Martinez J T, Chen J T, Disalle R, Andrews L, Sepanski D and Assi Z 2012 Postthrombotic morbidity correlates with residual thrombus following catheter-directed thrombolysis for iliofemoral deep vein thrombosis *J. Vasc. Surg.* **55** 768–73 Online: <http://dx.doi.org/10.1016/j.jvs.2011.10.032>

Delis K T, Bountouroglou D and Mansfield A O 2004 Venous claudication in iliofemoral thrombosis: long-term effects on venous hemodynamics, clinical status, and quality of life. *Ann. Surg.* **239** 118–26 Online: <http://content.wkhealth.com/linkback/openurl?sid=WKPTLP:landingpage&an=00000658-200401000-00017>

- 1 Dworkin H J, Smith J R and Bull F E 1966 A reaction following administration of
2 macroaggregated albumin (maa) for a lung scan. *Am. J. Roentgenol. Radium Ther. Nucl.*
3 *Med.* **98** 427–33 Online: <http://www.ncbi.nlm.nih.gov/pubmed/5925113>
- 4 Enden T, Haig Y, Kløw N-E, Slagsvold C-E, Sandvik L, Ghanima W, Hafsahl G, Holme P A,
5 Holmen L O, Njaastad A M, Sandbæk G and Sandset P M 2012 Long-term outcome after
6 additional catheter-directed thrombolysis versus standard treatment for acute
7 iliofemoral deep vein thrombosis (the CaVenT study): a randomised controlled trial.
8 *Lancet* (London, England) **379** 31–8 Online:
9 <http://www.ncbi.nlm.nih.gov/pubmed/22172244>
- 10 Fowler R-A, Lafond M, Poizat A, Mestas J-L, Chavrier F, Béra J-C and Lafon C 2013 Inertial
11 cavitation enhancement using confocal ultrasound *J. Acoust. Soc. Am.* **134** 4234
- 12 Heit J A, Spencer F A and White R H 2016 The epidemiology of venous thromboembolism *J.*
13 *Thromb. Thrombolysis* **41** 3–14 Online:
14 <http://www.ncbi.nlm.nih.gov/pubmed/26780736>
- 15 Kahn S R, Comerota A J, Cushman M, Evans N S, Ginsberg J S, Goldenberg N A, Gupta D K and
16 Prandoni P 2015 The Postthrombotic Syndrome: Evidence-Based Prevention , Diagnosis
17 , and Treatment Strategies *Circulation* **130** 1636–61
- 18 Kahn S R, Shbaklo H, Lamping D L, Holcroft C A, Shrier I, Miron M J, Roussin A, Desmarais S,
19 Joyal F, Kassis J, Solymoss S, Desjardins L, Johri M and Ginsberg J S 2008 Determinants
20 of health-related quality of life during the 2 years following deep vein thrombosis. *J.*
21 *Thromb. Haemost.* **6** 1105–12 Online: [http://doi.wiley.com/10.1111/j.1538-](http://doi.wiley.com/10.1111/j.1538-7836.2008.03002.x)
22 [7836.2008.03002.x](http://doi.wiley.com/10.1111/j.1538-7836.2008.03002.x)
- 23 Lafond M, Prieur F, Chavrier F, Mestas J-L and Lafon C 2017 Numerical study of a confocal
24 ultrasonic setup for cavitation creation. *J. Acoust. Soc. Am.* **141** 1953 Online:
25 <http://aip.scitation.org/doi/10.1121/1.4978061>
- 26 Maxwell A D, Cain C A, Duryea A P, Yuan L, Gurm H S and Xu Z 2009 Noninvasive
27 thrombolysis using pulsed ultrasound cavitation therapy - histotripsy. *Ultrasound Med.*
28 *Biol.* **35** 1982–94 Online:
29 [http://www.pubmedcentral.nih.gov/articlerender.fcgi?artid=2796469&tool=pmcentrez](http://www.pubmedcentral.nih.gov/articlerender.fcgi?artid=2796469&tool=pmcentrez&rendertype=abstract)
30 [&rendertype=abstract](http://www.pubmedcentral.nih.gov/articlerender.fcgi?artid=2796469&tool=pmcentrez&rendertype=abstract)
- 31 Maxwell A D, Owens G, Gurm H S, Ives K, Myers D D and Xu Z 2011 Noninvasive treatment of

1
2
3
4
5
6
7
8
9
10
11
12
13
14
15
16
17
18
19
20
21
22
23
24
25
26
27
28
29
30
31
32
33
34
35
36
37
38
39
40
41
42
43
44
45
46
47
48
49
50
51
52
53
54
55
56
57
58
59
60

1 deep venous thrombosis using pulsed ultrasound cavitation therapy (histotripsy) in a
2 porcine model. *J. Vasc. Interv. Radiol.* **22** 369–77 Online:
3 [http://www.pubmedcentral.nih.gov/articlerender.fcgi?artid=3053086&tool=pmcentrez](http://www.pubmedcentral.nih.gov/articlerender.fcgi?artid=3053086&tool=pmcentrez&rendertype=abstract)
4 &rendertype=abstract
5 Messas E, Wahl D and Pernod G 2016 [Management of deep-vein thrombosis: A 2015
6 update]. *J. Mal. Vasc.* **41** 42–50 Online:
7 <http://www.ncbi.nlm.nih.gov/pubmed/26357937>
8 Mfoumou E, Tripette J, Blostein M and Cloutier G 2014 Time-dependent hardening of blood
9 clots quantitatively measured in vivo with shear-wave ultrasound imaging in a rabbit
10 model of venous thrombosis *Thromb. Res.* **133** 265–71 Online:
11 <http://dx.doi.org/10.1016/j.thromres.2013.11.001>
12 Patel K, Fasanya A, Yadam S, Joshi A A, Singh A C and DuMont T 2017 Pathogenesis and
13 Epidemiology of Venous Thromboembolic Disease *Crit. Care Nurs. Q.* **40** 191–200
14 Online: <http://www.ncbi.nlm.nih.gov/pubmed/28557890>
15 Popuri R K and Vedantham S 2011 The role of thrombolysis in the clinical management of
16 deep vein thrombosis. *Arterioscler. Thromb. Vasc. Biol.* **31** 479–84 Online:
17 <http://atvb.ahajournals.org/cgi/doi/10.1161/ATVBAHA.110.213413>
18 Puurunen M K, Gona P N, Larson M G, Murabito J M, Magnani J W and O'Donnell C J 2016
19 Epidemiology of venous thromboembolism in the Framingham Heart Study *Thromb.*
20 *Res.* **145** 27–33 Online: <http://dx.doi.org/10.1016/j.thromres.2016.06.033>
21 Renowden S A, Dunne J A and Hayward M W 1991 Changes in arterial oxygen saturation
22 during isotope perfusion scans using human macroaggregates of albumin. *Nucl. Med.*
23 *Commun.* **12** 959–63 Online: <http://www.ncbi.nlm.nih.gov/pubmed/1754156>
24 Royer D, Dubois N and Fink M 1992 Optical probing of pulsed, focused ultrasonic fields using
25 a heterodyne interferometer *Appl. Phys. Lett.* **61** 153–155
26 Watson L I and Armon M P 2004 Thrombolysis for acute deep vein thrombosis. *Cochrane*
27 *database Syst. Rev.* CD002783 Online: <http://www.ncbi.nlm.nih.gov/pubmed/15495034>
28 Wright C, Hynynen K and Goertz D 2012 In vitro and in vivo high intensity focused ultrasound
29 thrombolysis *Invest. Radiol.* **47** 217
30 Zhang X, Macoskey J J, Ives K, Owens G E, Gurm H S, Shi J, Pizzuto M, Cain C A and Xu Z 2017

1 Non-invasive Thrombolysis Using Microtripsy in a Porcine Deep Vein Thrombosis Model

2 *Ultrasound Med. Biol.* Online:

3 <http://www.sciencedirect.com/science/article/pii/S0301562917300595>

4 Zhang X, Miller R M, Lin K-W, Levin A M, Owens G E, Gurm H S, Cain C A and Xu Z 2015a Real-
5 time feedback of histotripsy thrombolysis using bubble-induced color Doppler.

6 *Ultrasound Med. Biol.* **41** 1386–401 Online:

7 <http://www.umbjournal.org/article/S030156291400800X/fulltext>

8 Zhang X, Owens G E, Cain C A, Gurm H S, Macoskey J and Xu Z 2016 Histotripsy Thrombolysis
9 on Retracted Clots. *Ultrasound Med. Biol.* **42** 1903–18 Online:

10 <http://linkinghub.elsevier.com/retrieve/pii/S0301562916300035>

11 Zhang X, Owens G E, Gurm H S, Ding Y, Cain C A, Arbor A, Diseases C, Arbor A and Arbor A
12 2015b Non-invasive Thrombolysis using Histotripsy beyond the ‘Intrinsic’ Threshold
13 (Microtripsy) *IEEE Trans Ultrason Ferroelectr Freq Control* **62**

1
2
3
4 VI. Figures Legends

5
6 Fig. 1. Comparison of the depth and diameter of the femoral vein in a patient with an
7
8
9 occlusive thrombus (A) versus the parameters used in our setup (B).

10
11 Fig. 2. Illustration of the thrombotripsy experimentation setup (A). The two transducers
12
13 are coupled and centered by a linear probe of 7 MHz (B). It is then immersed and centered
14
15
16 on the occlusive thrombus in the silicon tube (C).

17
18 Fig. 3. Imaging of a recanalized thrombus. Ultrasonic acquisition before thrombolysis (A).
19
20 Complete recanalization after 3 series of 3 passages of thrombotripsy (B). Volumetric
21
22 acquisition with a dedicated probe confirms the recanalization's continuity, remotely from
23
24
25
26 the walls (C).

27
28 Fig. 4. Rate of recanalization according to thrombotripsy passages and device's speed: 1
29
30 mm.s⁻¹ (red), 2 mm.s⁻¹ (purple), 3 mm.s⁻¹ (blue). The restored outflow is presented as a
31
32
33 percentage of the maximum flow (initial flow without thrombus).

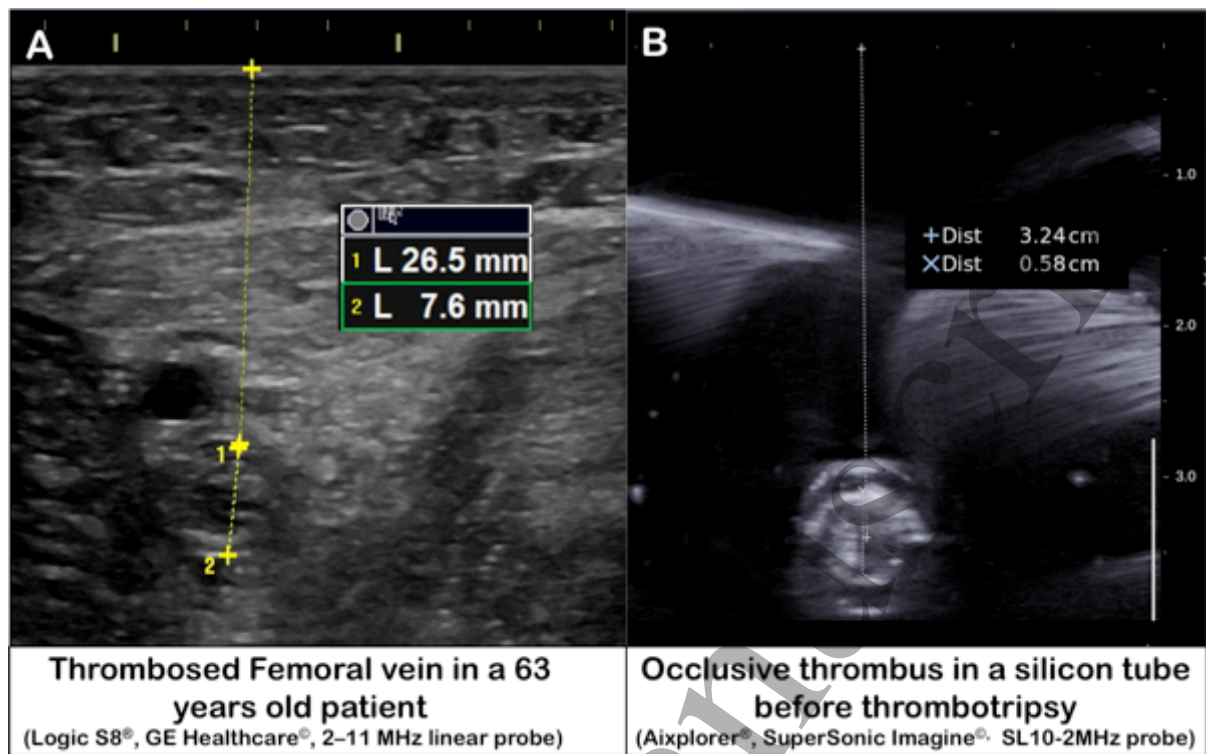
34
35 Fig. 5. Recanalization rate according to the cavitation time. The restored outflow is
36
37
38 presented as a percentage of the maximum flow (initial flow without thrombus).

39
40 Fig. 6. Setup for debris collection (A). The 100 μm and 40 μm filters allowed to collect
41
42
43 debris >40 μm. Pictures B and C show debris >100μm and pictures D and E show debris >40
44
45
46 μm.

47
48 Fig. 7. Debris count >40μm according to the device's speed. Debris on filters of 40 μm and
49
50
51 100 μm were counted under light microscopy.

52
53 Fig. 8. Small debris (<40 μm) diameter distribution represented by the number of debris
54
55
56 standardized to the removed thrombus volume. Debris count was obtained by the automatic
57
58
59 Counter and presented according to device's speed.

Figure 1



1
2
3
4
5
6
7
8
9
10
11
12
13
14
15
16
17
18
19
20
21
22
23
24
25
26
27
28
29
30
31
32
33
34
35
36
37
38
39
40
41
42
43
44
45
46
47
48
49
50
51
52
53
54
55
56
57
58
59
60

Figure 2

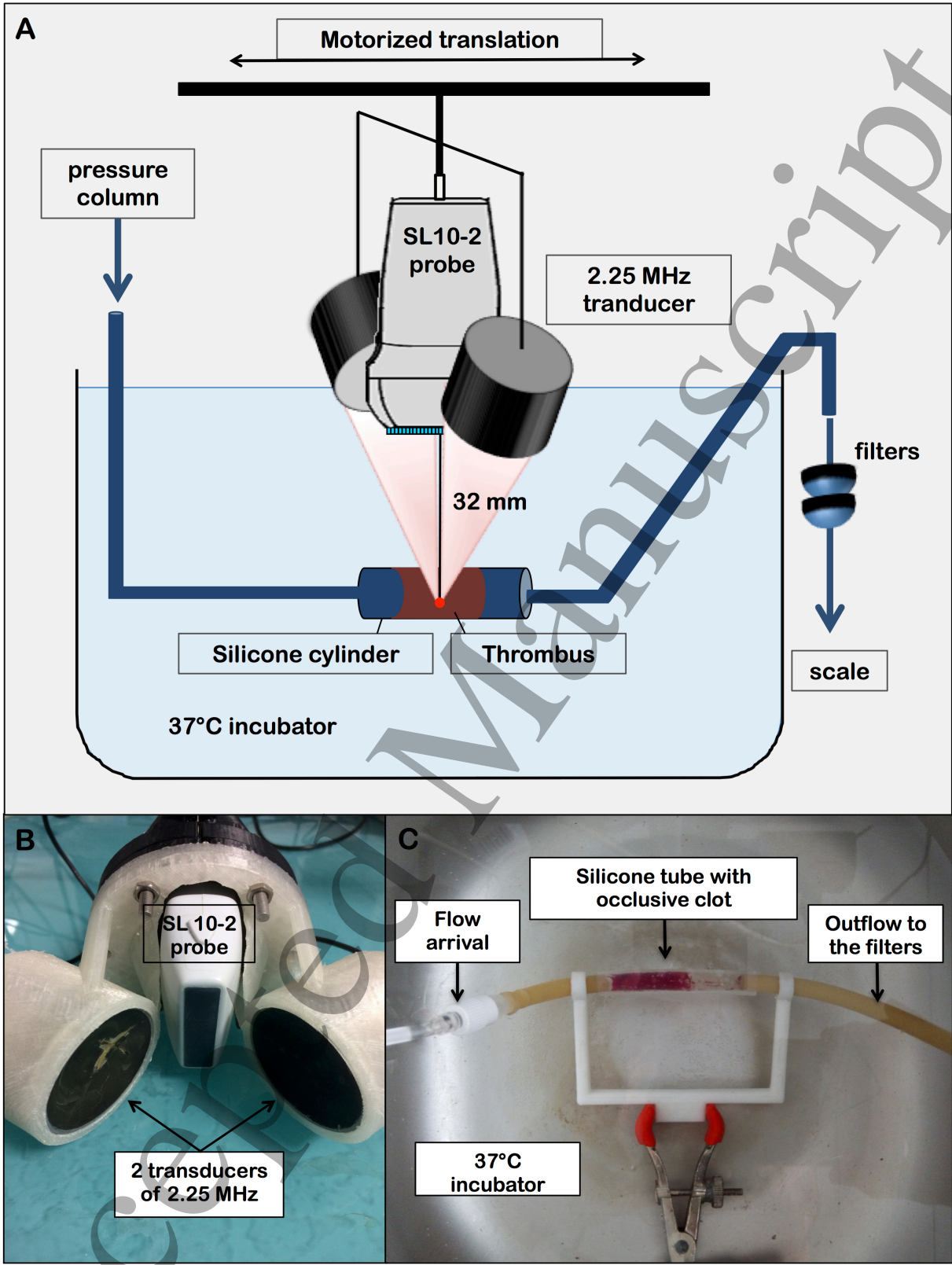


Figure 3

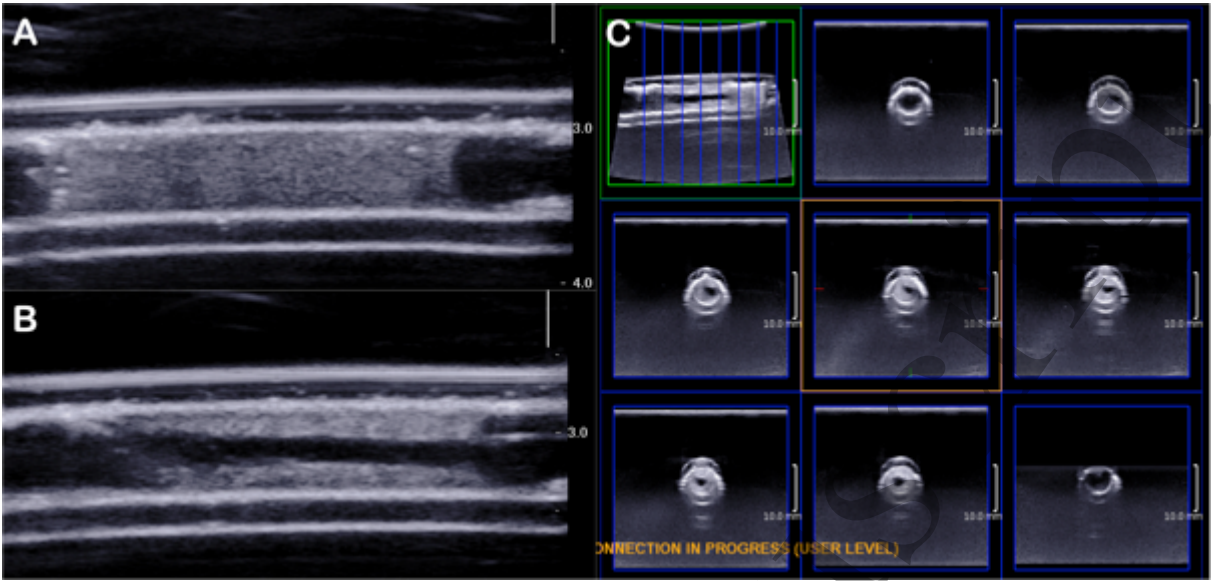


Figure 4

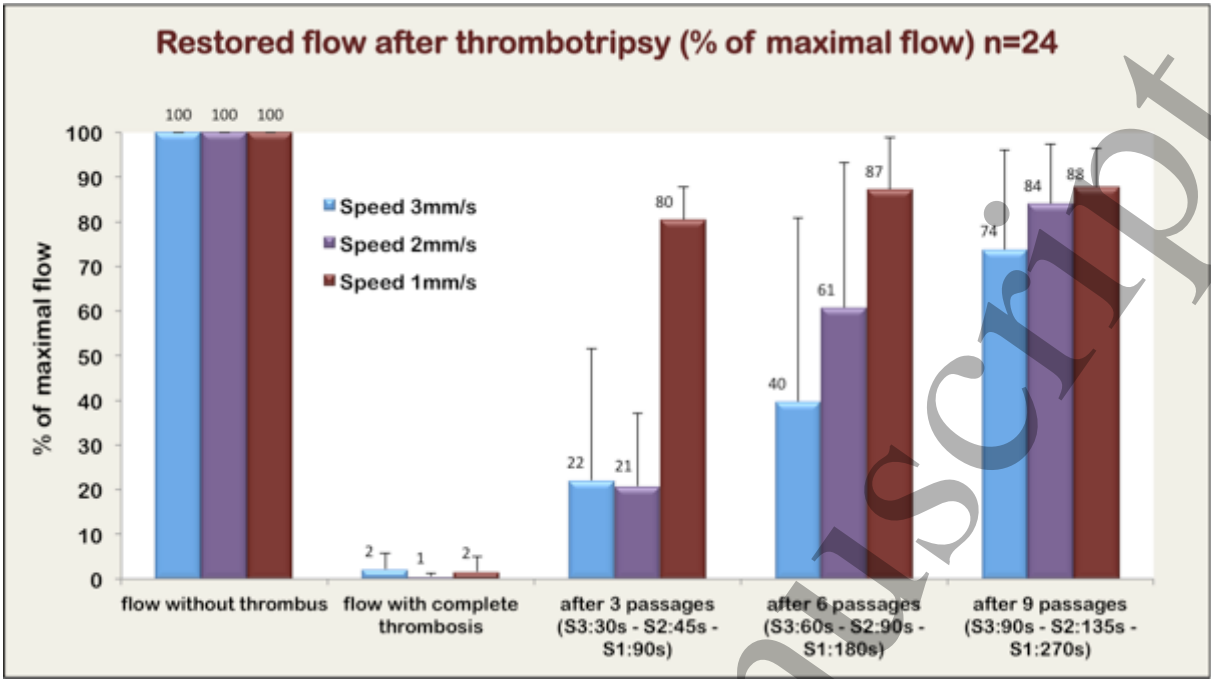


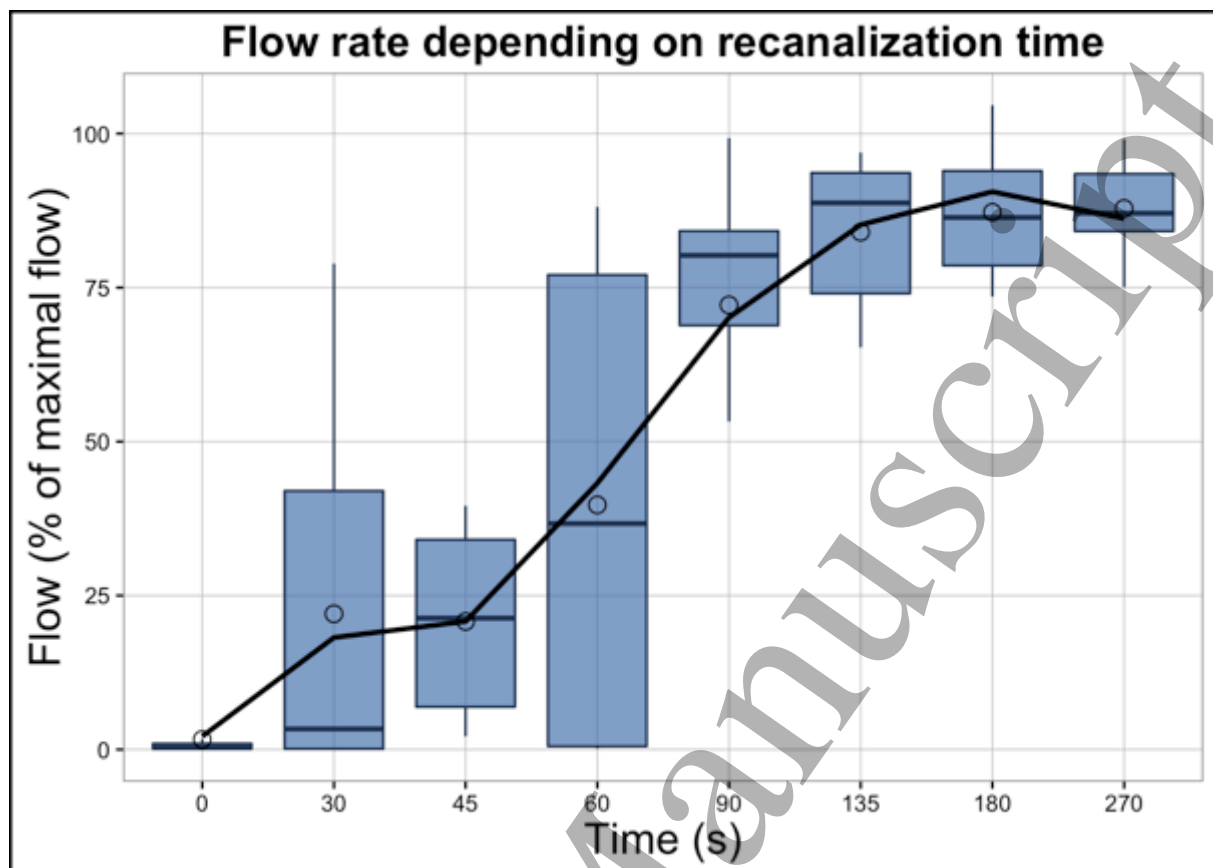
Figure 5

Figure 6




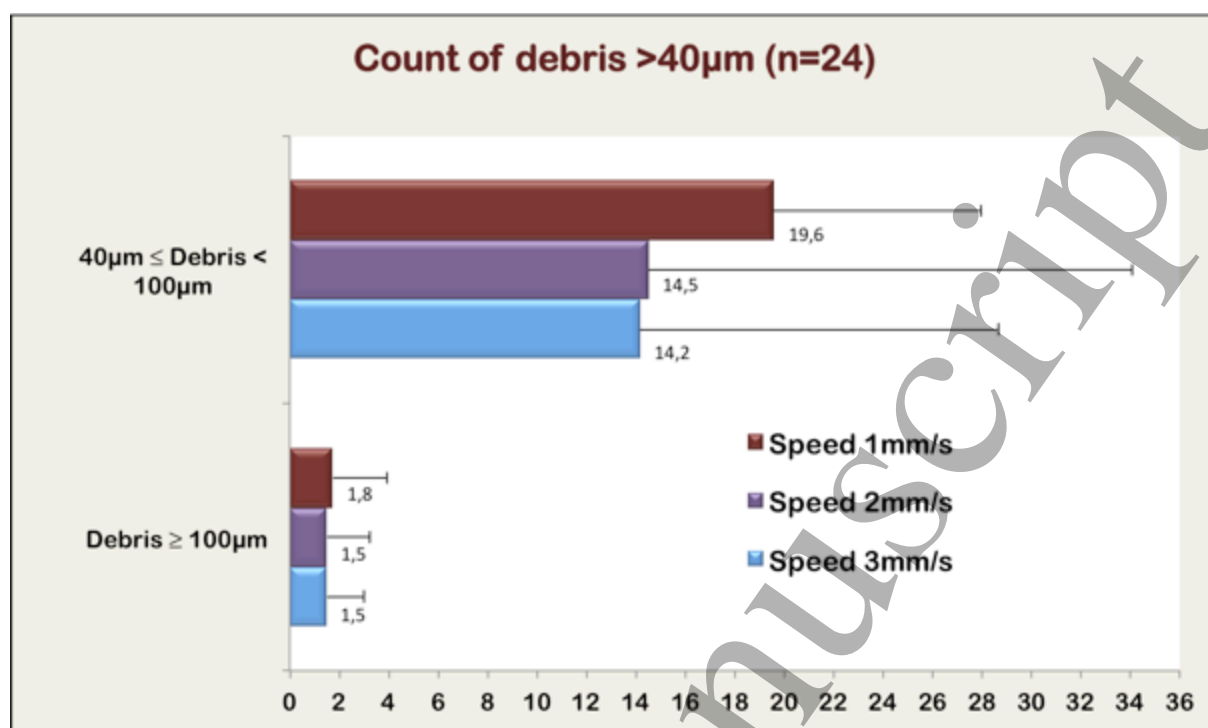
Figure 7

Figure 8

