



Mutation Screening of Candidate Genes in Patients with Nonsyndromic Sagittal Craniosynostosis

Xiaoqian Ye, Audrey Guilmatre, Boris Reva, Inga Peter, Yann Heuzé, Joan Richtsmeier, Deborah Fox, Rhinda Goedken, Ethylin Wang Jabs, Paul Romitti

► To cite this version:

Xiaoqian Ye, Audrey Guilmatre, Boris Reva, Inga Peter, Yann Heuzé, et al.. Mutation Screening of Candidate Genes in Patients with Nonsyndromic Sagittal Craniosynostosis. *Plastic and Reconstructive Surgery*, 2016, 137 (3), pp.952-961. 10.1097/01.prs.0000479978.75545.ee . hal-02322637

HAL Id: hal-02322637

<https://hal.science/hal-02322637>

Submitted on 11 Jan 2021

HAL is a multi-disciplinary open access archive for the deposit and dissemination of scientific research documents, whether they are published or not. The documents may come from teaching and research institutions in France or abroad, or from public or private research centers.

L'archive ouverte pluridisciplinaire **HAL**, est destinée au dépôt et à la diffusion de documents scientifiques de niveau recherche, publiés ou non, émanant des établissements d'enseignement et de recherche français ou étrangers, des laboratoires publics ou privés.



Published in final edited form as:

Plast Reconstr Surg. 2016 March ; 137(3): 952–961. doi:10.1097/01.prs.0000479978.75545.ee.

Mutation Screening of Candidate Genes in Patients with Nonsyndromic Sagittal Craniosynostosis

Xiaoqian Ye, D.M.D., Ph.D.^{1,2}, Audrey Guilmatre, Ph.D.³, Boris Reva, Ph.D.¹, Inga Peter, Ph.D.¹, Yann Heuzé, Ph.D.⁴, Joan T. Richtsmeier, Ph.D.⁵, Deborah J. Fox, M.P.H.⁶, Rhinda J. Goedken, B.A.⁷, Ethylin W Jabs, M.D.¹, and Paul A. Romitti, Ph.D.⁷

Paul A. Romitti: paul-romitti@uiowa.edu

¹Department of Genetics and Genomic Sciences, Icahn School of Medicine at Mount Sinai, New York, NY, USA

²The State Key Laboratory Breeding Base of Basic Science of Stomatology (Hubei-MOST) and Key Laboratory of Oral Biomedicine Ministry of Education, School and Hospital of Stomatology, Wuhan University, Wuhan, P. R. China

³Robert Debré Hospital, Department of Pediatric Hematology, Paris, France

⁴Université de Bordeaux, UMR5199 PACEA, Bordeaux Archaeological Sciences Cluster of Excellence, Pessac, France

⁵Department of Anthropology, Pennsylvania State University, University Park, Pennsylvania, PA, USA

⁶Congenital Malformations Registry, New York State Department of Health, Albany, New York, NY, USA

⁷Department of Epidemiology, The University of Iowa, Iowa City, Iowa, IA, USA

Abstract

Background—Craniosynostosis is a condition that includes the premature fusion of one or multiple cranial sutures. Among various craniosynostosis forms, midline sagittal nonsyndromic craniosynostosis (sNSC) is the most prevalent. Although different gene mutations have been identified in some craniosynostosis syndromes, the etiology of sNSC remains largely unknown.

Corresponding author: Dr. Ethylin Wang Jabs, Correspondence address: Department of Genetics and Genomic Science, Icahn School of Medicine at Mount Sinai, New York, NY, 10029, USA, Phone: (212)241-3504, Fax: (212)849-2508, ethylin.jabs@mssm.edu.

The abstract has been presented at the Society for Craniofacial Genetics and Developmental Biology Annual Meeting and the American Society of Human Genetics 61st Annual Meeting in October 2011, at Montreal, Canada

Full Financial Disclosure

None of the authors has a financial interest in any of the products, devices, or drugs mentioned in this manuscript.

Authors' contribution

XY and AG performed mutation screening. XY, BR, IP, YH and JR analyzed data. DJF, RJ and PAR collected clinical cases. XY, EWJ and PAR drafted the manuscript. EWJ and PAR conceived and designed the study, coordinated and oversaw the project.

Statement of Ethical approval

Written informed consents were obtained from the parents or guardians of the patient. The study protocol was approved by the Icahn School of Medicine at Mount Sinai and the University of Iowa and New York State Department of Health institutional review boards, and conformed to the guidelines set forth by the Declaration of Helsinki.

Methods—To screen for candidate genes for sNSC, we performed Sanger sequencing on DNA from 93 sNSC patients from a population-based, case-control study conducted in Iowa and New York states. FGFR1-3 mutational hotspots known to be associated with sNSC, and the entire TWIST1, RAB23, BMP2 coding regions were screened because of their known roles in human nonsyndromic or syndromic sagittal craniosynostosis, expression patterns, and/or animal model studies.

Results—We identified two rare variants in our cohort. An insertion c.730_731insG in FGFR1, which led to a premature stop codon, was predicted to abolish the entire IgIII domain, including the ligand binding region. A c.439C>G variant was observed in TWIST1 at its highly conserved loop domain in another patient. The patient's mother harbored the same variant and was reported to have jaw abnormalities. These two variants were not detected in 116 alleles from unaffected controls or seen in the several databases; however, TWIST1 variant was found in a low frequency of .000831 percent in ExAC database.

Conclusions—The low mutation detection rate indicates that these genes only account for a very small proportion of sNSC patients. Our results add to the perception that sNSC is a complex developmental defect with considerable genetic heterogeneity.

INTRODUCTION

Craniosynostosis is defined by the premature fusion of one or more cranial sutures and the malformation of cranial bones that result in abnormal skull shape. It is one of the most common birth defects, occurring in 1 per 2,000 to 2,500 live births. Craniosynostosis patients are often classified according to the suture(s) involved and whether the cranial vault features occur as an isolated defect (nonsyndromic form), or are associated with other facial, specific limb, or dermatological features as part of a syndrome (syndromic form). Nonsyndromic craniosynostosis (NSC) typically involves premature closure of a single suture, the most frequent type being sagittal, and it is controversial whether it is followed by the coronal (unicoronal being more frequent than bicoronal synostosis) or the metopic suture.¹

The premature fusion of the sagittal suture results in an increase of the anteroposterior direction of the skull, particularly the calvarium, with growth restriction in the transverse direction, causing a narrow, elongated, boat-shaped skull deformity (dolichocephaly or scaphocephaly) and varying degrees of frontal bossing and occipital bossing. Abnormal growth of the skull can subsequently lead to increased intracranial pressure that can be associated with changes in brain morphology, which in turn can contribute to visual impairment and neurocognitive deficiency.^{2,3} The treatment of sagittal craniosynostosis is currently evolving. Total vault remodeling (CVR) has been effective for correcting cranial shape and expanding intracranial volume. Minimally invasive techniques, such as endoscopic suture release, spring assisted surgery, and distraction osteogenesis have been used in an effort to potentially reduce surgical morbidity.⁴

Sagittal nonsyndromic craniosynostosis (sNSC) accounts for approximately one-half of all affected patients and shows a strong male predominance (male:female ratio of 3.5:1).⁵ Segregation analysis indicates that sNSC follows an autosomal dominant inheritance with a

reduced penetrance in only 6% of cases.⁵ The majority of sNSC is thought to be sporadic. The current genetic understanding suggests that the underlying etiology of sNSC is complex, most likely involving both genetic and environmental exposures (broadly defined).⁶ In the past two decades, intensive investigations among the more than 180 craniosynostosis syndromes have provided valuable insights into identifying genes involved in calvarial suture development.⁷ Among the identified syndromic-causing genes, some are responsible for rare syndromes with midline sagittal or multiple suture craniosynostosis (Table 1). Heterozygous gain-of-function mutation hotspots in fibroblast growth factor receptors 1, 2 and 3 (*FGFR1*, *FGFR2*, *FGFR3*) account for most of the common craniosynostosis syndromes, including Apert, Crouzon, Pfeiffer, Jackson-Weiss, Beare-Stevenson and Muenke syndrome.⁸ In addition to those FGFR-related craniosynostosis syndromes, mutations in several transcription factors such as *TWIST1* and *MSX2* have been implicated in Saethre-Chotzen syndrome and Boston-type craniosynostosis respectively. The clinical phenotypes of these syndromes vary greatly, but all have coronal suture involvement. In contrast to the increasing number of human genes associated with syndromic craniosynostosis,⁸ only variants in a small number of genes, *FGFR1-3*, *TWIST1*, *ALX4*, *ERF*, *IGF1R*, and *LRIT3* (Table 2) have been reported in sNSC patients. The mutation hotspots that are important for syndromic craniosynostosis, *FGFR1* exon IIIa, *FGFR2* exons IIIa and IIIc, *FGFR3* exon IIIa, and *TWIST1* exon 1 and their somatic changes, have been less likely to be associated with sNSC,^{2,3,9,10} perhaps because the sagittal suture is infrequently closed prematurely in syndromic patients. As such, patients with nonsyndromic unilateral or bilateral coronal synostosis merit the genetic testing of mutation hotspots in *FGFR1-3* and *TWIST1*, but mutation testing is not proposed for patients with sNSC unless a syndromic association is suspected due to familial recurrence.^{3,10} With regard to sNSC, a genome-wide association study (GWAS) showed significant association in a 120kb region downstream of *BMP2* and within a 167kb region of *BBS9* in 130 non-Hispanic white case-parent trios (N=130) and replicated in 172 case-controls of the same ethnicity, but without identifying plausible causative mutations.¹¹

To further investigate the pathogenesis of sNSC, we sequenced known *FGFR1-3* and *TWIST1* mutations that were found to be related to sNSC (Table 2) and two new candidate genes *RAB23* and *BMP2* using case-parent trio specimens from families identified from two population-based birth defect surveillance programs in the U.S.

MATERIALS AND METHODS

Study Population and Data Collection

Cases were live born children with a diagnosis of single suture, sagittal craniosynostosis born from January 1, 1998 through December 31, 2008 to resident mothers in Iowa or New York State. Cases were enumerated from the Iowa Registry for Congenital and Inherited Disorders and the New York State Congenital Malformations Registry, two population-based birth defect surveillance programs. Controls were live children born without a major birth defect diagnosis to resident mothers in Iowa or New York State during the same time frame as cases and frequency matched by birth year to cases. To be eligible for recruitment,

a case or control mother needed to be able to complete an English language questionnaire and to have custody of the case or control child.

Data collection was conducted in three phases: family history questionnaire, saliva specimen collection, and medical record abstraction. A case or control mother was sent a pre-contact letter informing them about the study, and two weeks later, an introductory packet comprised of an introductory letter, the family history questionnaire, a fact sheet/rights as a research subject, a frequently asked questions sheet, and \$10 reimbursement was mailed. A systematic follow-up protocol was used to encourage return of a completed family history questionnaire. Following receipt of a completed questionnaire, a case or control mother was sent a saliva specimen collection kit comprised of: a specimen collection letter and instructions; written consent forms for mother and father; specimen collection supplies for mother, father and child; \$20 reimbursement; and a medical release form (case mothers only). Again, a systematic follow-up protocol was used to encourage return of saliva specimens and for case mothers, a medical release form. Once a family returned the saliva specimens, a thank you letter and \$20 were sent to the mother. For case mothers who returned a signed medical record release form, medical record abstraction for postnatal events, including request for computed tomographic cranial images, was completed. The study protocol was approved by the Icahn School of Medicine at Mount Sinai, The University of Iowa and New York State Department of Health institutional review boards, and conformed to the guidelines set forth by the Declaration of Helsinki.

Mutation Screening

Candidate genes or mutations were selected based on their known involvement in human sagittal craniosynostosis, in animal models, and/or expression studies related to sagittal suture development. In addition to selected variants in *FGFR1* (c.1508C>T), *FGFR2* (c.833 G>A; c.943 G>A), *FGFR3* (c.749C>G; c.1000 G>A) (Table 2), and the *TWIST1* gene, we also included in our screen two new candidate genes: *RAB23*, which is responsible for Carpenter syndrome, which presents with midline sagittal, as well as metopic, synostosis, and *BMP2*, which was identified from the previously mentioned GWAS study.¹¹ DNA sequence analysis was performed on 93 affected sNSC cases. Primers for the coding regions of all candidate genes or variants (*FGFR1* NM_023105; *FGFR2* NM_000141; *FGFR3* NM_000142.2; *TWIST1* NM_000474; *RAB23* NM_183227; *BMP2* NM_001200) were designed using Primer 3 (<http://bioinfo.ut.ee/primer3-0.4.0/>) (see Supplemental Digital Content 1, Table shows sequencing primers for candidate genes, INSERT LINK). The sequencing was conducted by Genewiz Inc (<http://www.genewiz.com/>) and sequences analyzed using Sequencher software (v4.8; Gene Codes Corporation, Ann Arbor, MI). We initially screened only the case child. When a variant was identified, we sequenced maternal DNA specimens, and if available, paternal DNA specimens to determine if the variant was *de novo* or segregated within the family. To confirm the variation, we carried out molecular analysis of 58 healthy children, or 116 control alleles, and compared our results to the 1000 Genomes Project (1KG) database (<http://browser.1000genomes.org>), the NHLBI Grand Opportunity Exome Sequencing Project (ESP) database (<http://evs.gs.washington.edu/EVS/>), the Exome Aggregation Consortium (ExAC) database (<http://>

exac.broadinstitute.org/) and Locus Specific Mutation Database (LSDB) (http://grenada.lumc.nl/LSDB_list/lsdbs).

RESULTS

Among the 93 affected sNSC cases screened, we identified two rare novel coding variants in our case child sample. These variants included a heterozygous c.439C>G transversion in *TWIST1* exon 1 (Fig. 1), which predicted a glutamine-to-glutamic acid transition that occurred within the highly conserved loop domain. This variant was also present in the case child's mother, who had an undefined jaw anomaly with corrective surgery when she was a teenager. The other heterozygous variant, c.730_731insG (NM_023105), was observed in exon 6 in *FGFR1* in a different case child (Fig. 1), but not in the case child's mother; a specimen was not available for the case child's father to be able to determine if this variant was a *de novo* variant. This insertion was predicted to abolish the entire immunoglobulin III domain, including the ligand binding region. These two variants were not seen in the 1KG, ESP or LSDB databases, however the *TWIST1* variant c.439C>G was found in an extremely low frequency in ExAC database (1 in 120318 alleles, phenotypic information unavailable). In addition, we identified a heterozygous variant, c.546A>C, in *RAB23* in a third case child; this variant predicted the amino acid substitution of glutamic acid to aspartic acid. There is not sufficient extant data in the literature to predict a functional effect of this variant from evolutionary conservation using Mutation Assessor tool.¹² The case child's unaffected mother carried the same variant with no obvious phenotype, and this rare variant was also found in one individual from the NHLBI ESP database. It is unknown if the carrier from ESP had any relevant phenotype. Also we did not find any of the previously reported variants in *FGFR1-3*, *TWIST1*, *RAB23* and *BMP2* in our study samples (Table 2).

DISCUSSION

Using a population-based sample, we identified a very rare variant glutamine-to-glutamic acid transition in exon 1 in *TWIST1* (c.439C>G; Fig. 1). The assessment of the functionality of this variant made by the Mutation Assessor tool is presented in Figure 2 and Figure 3.¹² From multiple sequence alignment, we concluded that the variant residue occupies one of the top specificity positions (Fig. 2) and contributes to the complex formation between transcriptional regulator TWIST1 and the transcriptional factor E2 alpha (Fig. 3). Interestingly, both types of the variant residues, the original glutamine and variant glutamic acid are present in specific subfamilies. This suggests that the glutamic acid variant may be responsible for the specific regulation of the DNA transcription, biologically different from the one performed by the common glutamine variant of the TWIST1. We believe this variant to be pathogenic based on the following evidence. First, this variant was located within the highly conserved loop domain, which is important for the TWIST1 protein's tertiary structure and dimerization. A number of mutations, including c.435G>C and c.443C>A, have been detected in different Saethre-Chotzen patients within the coding sequence for the loop domain at the surrounding nucleotide positions and were confirmed to be deleterious.^{13,14} Second, the variant was extremely rare in the general population. It was absent in a panel of 116 normal control alleles and two of the largest human genome databases; and it was found only once in more than 6000 individuals in ExAC database and

the individual information is unknown. The low frequency of the variant could not exclude its pathogenicity. In previous studies, some mutations which were found in other large cohorts of sNSC patients or confirmed with functional analysis also showed a very low population frequency in the public databases (Table 2). Lastly, the variant was found in both the case child and mother. Although the mother had no features of obvious craniosynostosis, she was reported to have anomalous jaw formation, another developmental bone abnormality. *TWIST1*, a helix-loop-helix transcription factor, has been implicated both in Saethre-Chotzen syndrome and in nonsyndromic coronal craniosynostosis.^{10,15} However, detected point mutations in *TWIST1* have been implicated in very few cases of sNSC (Table 2) and are likely to contribute to very few patients. Variable phenotypic expressivity in patients with *TWIST1* mutations is common. A S188L mutation in the *TWIST* Box domain was previously identified to be pathogenic both in a patient with sNSC and the patient's father, who had only small, square-shaped ears and is considered to represent a very mild manifestation of the *TWIST1* mutation.¹⁶ Similarly in our study, the mother might have variable expressivity of the phenotype with only jaw defects. In the *Twist1*^{+/-} mice, sagittal suture closure was found to be related to the canonical Wnt signaling downregulation and the causative effects for sNSC are most likely of an epigenetic nature.¹⁷

Few *FGFR1* mutations have been associated with craniosynostosis. A specific mutation P252R in Pfeiffer syndrome and a heterozygous *FGFR1* I300L were found in a trigonocephaly patient with isolated metopic synostosis.¹⁸ With our population-based sample, we also screened the previously reported *FGFR1* c.1508C>T variant,¹⁶ but failed to detect the same variant in our study sample. Instead, we identified another novel variant, c.730_731insG, near the c.1508C>T variant, which led to a premature stop codon (p.A244fs*26) and was predicted to abolish the entire IgIII domain, including the ligand binding region. The function of c.730_731insG needs to be further studied. Gain-of-function mutations in *FGFR2* have been identified in a majority of autosomal dominant craniosynostosis syndromes that usually include the coronal suture, but multiple affected sutures (coronal and sagittal) can also be involved in some complex cases. In addition to the mutation hotspots found in syndromic craniosynostosis, a few *FGFR2* mutations have been reported in different patients with nonsyndromic sagittal craniosynostosis (Table 2). In contrast to *FGFR2*, only four mutations in *FGFR3* have been identified in patients with craniosynostosis, P250R mutation in Muenke syndrome, A391E in Crouzon syndrome with acanthosis nigricans, P250L in one family with nonsyndromic craniosynostosis (sutures involved were unknown), and A334T in a family with mild sagittal craniosynostosis.^{3,19,20} A complete screening of *FGFR3* was undertaken in 97 craniosynostosis patients with no known molecular defect and no causative mutation was identified.¹⁵ Our screening for *FGFR2* C278Y and A315T variants and the *FGFR3* mutation hotspots P250R and A334T failed to identify any novel sequence variants in either gene.

Carpenter syndrome is a rare craniosynostosis syndrome with midline sagittal suture involvement. Presumed loss-of-function mutations were found in *RAB23*, which encodes a member of the RAB guanosine triphosphatase family of vesicle transport proteins and acts as a negative regulator of hedgehog signaling. We screened the entire *RAB23* and *BMP2* coding and flanking regions in our study sample, but failed to identify any novel sequence

variants in either gene. Our study is also the first population-based cohort that demonstrates that mutations in several genes associated with currently known or identified craniosynostosis usually associated with coronal craniosynostosis, were not common in our sNSC cases. Our sequencing results were consistent with the data from previous reports in non-population, Caucasian cohorts.^{2,3,11} Thus, sNSC remains a heterogeneous and challenging disorder. Furthering knowledge of gene variants that produce craniosynostosis will require identifying functional variants, investigating pathway and other interactions by using whole exome/genome sequencing, and conducting genome-wide association studies to identify genetic interactions that may reveal critical genetic relationships that modify craniosynostosis phenotypes.

CONCLUSIONS

The etiology of sNSC is complex and is yet unknown. Our sequencing results of a population-based cohort of sNSC patients indicate that the *FGFR1-3* mutational hotspots, *TWIST1*, *RAB23* and *BMP2* gene coding regions which are involved in syndromic sagittal craniosynostosis and/or sagittal nonsyndromic craniosynostosis contribute to only a few cases of sNSC (variant detection frequency about 1%). Additional studies are needed to elucidate the pathological mechanisms underlying sNSC since these candidate genes may not be the major causes of sNSC and genetic testing of these genes was negative in most cases.

Supplementary Material

Refer to Web version on PubMed Central for supplementary material.

Acknowledgments

We thank the patients and their families for participation in this study. We are indebted to Charlotte M. Druschel, M.D., M.P.H., who is retired from the Congenital Malformation Registry, New York State Department of Health, Albany, New York and the Department of Epidemiology and Biostatistics, School of Public Health, University at Albany State University of New York, Albany, New York. She was a major contributor to this project in design and recruitment of New York State participants. This research was supported by grants including CDC 5 R01 DD000350 and NIH/NICHD 1 P01 HD078233.

References

1. Heuzé Y, Holmes G, Peter I, Richtsmeier J, Jabs EW. Closing the gap: Genetic and genomic continuum from syndromic to nonsyndromic craniosynostoses. *Curr Genet Med Rep*. 2014; 2:135–145. [PubMed: 26146596]
2. Zeiger JS, Beaty TH, Hetmanski JB, et al. Genetic and environmental risk factors for sagittal craniosynostosis. *J Craniofac Surg*. 2002; 13:602–606. [PubMed: 12218784]
3. Boyadjiev SA. International Craniosynostosis Consortium. Genetic analysis of non-syndromic craniosynostosis. *Orthod Craniofac Res*. 2007; 10:129–137. [PubMed: 17651129]
4. Gerety P, Basta MN, Fischer JP, Taylor JA, Bartlett SP. Operative management of non-syndromic sagittal craniosynostosis: A head-to-head meta-analysis of outcomes comparing three techniques. *Plast Reconstr Surg*. 2014; 134:23–24.
5. Lajeunie E, Le Merrer M, Bonaiti-Pellie C, Marchac D, Renier D. Genetic study of scaphocephaly. *Am J Med Genet*. 1996; 62:282–285. [PubMed: 8882788]
6. Kallen K. Maternal smoking and craniosynostosis. *Teratology*. 1999; 60:146–150. [PubMed: 10471899]

7. Passos-Bueno MR, Serti Eacute AE, Jehee FS, Fanganiello R, Yeh E. Genetics of craniosynostosis: Genes, syndromes, mutations and genotype-phenotype correlations. *Front Oral Biol.* 2008; 12:107–143. [PubMed: 18391498]
8. Melville H, Wang Y, Taub PJ, Jabs EW. Genetic basis of potential therapeutic strategies for craniosynostosis. *Am J Med Genet A.* 2010; 152A:3007–3015. [PubMed: 21082653]
9. Anderson PJ, Cox TC, Roscioli T, et al. Somatic FGFR and TWIST mutations are not a common cause of isolated nonsyndromic single suture craniosynostosis. *J Craniofac Surg.* 2007; 18:312–314. [PubMed: 17414280]
10. Roscioli T, Elakis G, Cox TC, et al. Genotype and clinical care correlations in craniosynostosis: findings from a cohort of 630 Australian and New Zealand patients. *Am J Med Genet C Semin Med Genet.* 2013; 163C:259–270. [PubMed: 24127277]
11. Justice CM, Yagnik G, Kim Y, et al. A genome-wide association study identifies susceptibility loci for nonsyndromic sagittal craniosynostosis near BMP2 and within BBS9. *Nat Genet.* 2012; 44:1360–1364. [PubMed: 23160099]
12. Reva B, Antipin Y, Sander C. Predicting the functional impact of protein mutations: Application to cancer genomics. *Nucleic Acids Res.* 2011; 39:e118. [PubMed: 21727090]
13. Rose CS, Patel P, Reardon W, Malcolm S, Winter RM. The TWIST gene, although not disrupted in Saethre-Chotzen patients with apparently balanced translocations of 7p21, is mutated in familial and sporadic cases. *Hum Mol Genet.* 1997; 6:1369–1373. [PubMed: 9259286]
14. Kress W, Schropp C, Lieb G, et al. Saethre-Chotzen syndrome caused by TWIST 1 gene mutations: Functional differentiation from Muenke coronal synostosis syndrome. *Eur J Hum Genet.* 2006; 14:39–48. [PubMed: 16251895]
15. Wilkie AO, Byren JC, Hurst JA, et al. Prevalence and complications of single-gene and chromosomal disorders in craniosynostosis. *Pediatrics.* 2010; 126:e391–400. [PubMed: 20643727]
16. Seto ML, Hing AV, Chang J, et al. Isolated sagittal and coronal craniosynostosis associated with TWIST box mutations. *Am J Med Genet A.* 2007; 143A:678–686. [PubMed: 17343269]
17. Behr B, Longaker MT, Quarto N. Differential activation of canonical Wnt signaling determines cranial sutures fate: A novel mechanism for sagittal suture craniosynostosis. *Dev Biol.* 2010; 344:922–940. [PubMed: 20547147]
18. Kress W, Petersen B, Collmann H, Grimm T. An unusual FGFR1 mutation (fibroblast growth factor receptor 1 mutation) in a girl with non-syndromic trigonocephaly. *Cytogenet Cell Genet.* 2000; 91:138–140. [PubMed: 11173846]
19. Schindler S, Friedrich M, Wagener H, Lorenz B, Preising MN. Heterozygous P250L mutation of fibroblast growth factor receptor 3 in a case of isolated craniosynostosis. *J Med Genet.* 2002; 39:764–766. [PubMed: 12362036]
20. Barroso E, Perez-Carrizosa V, Garcia-Recuero I, et al. Mild isolated craniosynostosis due to a novel FGFR3 mutation, p.Ala334Thr. *Am J Med Genet A.* 2011; 155A:3050–3053. [PubMed: 22038757]
21. Hiraki Y, Miyatake S, Hayashidani M, et al. Aortic aneurysm and craniosynostosis in a family with Cantu syndrome. *Am J Med Genet A.* 2014; 164A:231–236. [PubMed: 24352916]
22. Mornet E. Hypophosphatasia. *Orphanet J Rare Dis.* 2007; 2:40. [PubMed: 17916236]
23. Searle C, Jewell R, Kraft J, et al. Craniosynostosis: A previously unreported association with CHST3-related skeletal dysplasia (autosomal recessive Larsen syndrome). *Clin Dysmorphol.* 2014; 23:12–15. [PubMed: 24300290]
24. Simpson MA, Scheuerle A, Hurst J, et al. Mutations in FAM20C also identified in non-lethal osteosclerotic bone dysplasia. *Clin Genet.* 2009; 75:271–276. [PubMed: 19250384]
25. Kosaki K, Takahashi D, Udaka T, et al. Molecular pathology of Shprintzen-Goldberg syndrome. *Am J Med Genet A.* 2006; 140:104–108. author reply 109–110. [PubMed: 16333834]
26. Jehee FS, Bertola DR, Yelavarthi KK, et al. An 11q11-q13.3 duplication, including FGF3 and FGF4 genes, in a patient with syndromic multiple craniosynostoses. *Am J Med Genet A.* 2007; 143A:1912–1918. [PubMed: 17632770]
27. White KE, Cabral JM, Davis SI, et al. Mutations that cause osteoglophonic dysplasia define novel roles for FGFR1 in bone elongation. *Am J Hum Genet.* 2005; 76:361–367. [PubMed: 15625620]

28. Sharma VP, Wall SA, Lord H, Lester T, Wilkie AO. Atypical Crouzon syndrome with a novel Cys62Arg mutation in FGFR2 presenting with sagittal synostosis. *Cleft Palate Craniofac J*. 2012; 49:373–377. [PubMed: 22117175]
29. McGillivray G, Savarirayan R, Cox TC, et al. Familial scaphocephaly syndrome caused by a novel mutation in the FGFR2 tyrosine kinase domain. *J Med Genet*. 2005; 42:656–662. [PubMed: 16061565]
30. Tavormina PL, Shiang R, Thompson LM, et al. Thanatophoric dysplasia (types I and II) caused by distinct mutations in fibroblast growth factor receptor 3. *Nat Genet*. 1995; 9:321–328. [PubMed: 7773297]
31. Hurst JA, Jenkins D, Vasudevan PC, et al. Metopic and sagittal synostosis in Greig cephalopolysyndactyly syndrome: Five cases with intragenic mutations or complete deletions of GLI3. *Eur J Hum Genet*. 2011; 19:757–762. [PubMed: 21326280]
32. Walczak-Sztulpa J, Eggenschwiler J, Osborn D, et al. Cranioectodermal dysplasia, Sensenbrenner syndrome, is a ciliopathy caused by mutations in the IFT122 gene. *Am J Hum Genet*. 2010; 86:949–956. [PubMed: 20493458]
33. Arts HH, Bongers EM, Mans DA, et al. C14ORF179 encoding IFT43 is mutated in Sensenbrenner syndrome. *J Med Genet*. 2011; 48:390–395. [PubMed: 21378380]
34. Klopocki E, Lohan S, Brancati F, et al. Copy-number variations involving the IHH locus are associated with syndactyly and craniosynostosis. *Am J Hum Genet*. 2011; 88:70–75. [PubMed: 21167467]
35. Nieminen P, Morgan NV, Fenwick AL, et al. Inactivation of IL11 signaling causes craniosynostosis, delayed tooth eruption, and supernumerary teeth. *Am J Hum Genet*. 2011; 89:67–81. [PubMed: 21741611]
36. Kamath BM, Stolle C, Bason L, et al. Craniosynostosis in Alagille syndrome. *Am J Med Genet*. 2002; 112:176–180. [PubMed: 12244552]
37. Twigg SR, Lloyd D, Jenkins D, et al. Mutations in multidomain protein MEGF8 identify a Carpenter syndrome subtype associated with defective lateralization. *Am J Hum Genet*. 2012; 91:897–905. [PubMed: 23063620]
38. Jabs EW, Muller U, Li X, et al. A mutation in the homeodomain of the human MSX2 gene in a family affected with autosomal dominant craniosynostosis. *Cell*. 1993; 75:443–450. [PubMed: 8106171]
39. del Mahmoud AAH, Abdullah AA, Eissa F. Infantile osteopetrosis, craniosynostosis, and Chiari malformation type I with novel OSTEM1 mutation. *J Pediatr Neurosci*. 2013; 8:34–37. [PubMed: 23772242]
40. Freudlsperger C, Hoffmann J, Castrillon-Oberndorfer G, Engel M. Bilateral coronal and sagittal synostosis in X-linked hypophosphatemic rickets: A case report. *J Craniomaxillofac Surg*. 2013; 41:842–844. [PubMed: 23466123]
41. Jenkins D, Seelow D, Jehee FS, et al. RAB23 mutations in Carpenter syndrome imply an unexpected role for hedgehog signaling in cranial-suture development and obesity. *Am J Hum Genet*. 2007; 80:1162–1170. [PubMed: 17503333]
42. Bendon CL, Fenwick AL, Hurst JA, et al. Frank-ter Haar syndrome associated with sagittal craniosynostosis and raised intracranial pressure. *BMC Med Genet*. 2012; 13:104. [PubMed: 23140272]
43. Takenouchi T, Sakamoto Y, Miwa T, et al. Severe craniosynostosis with Noonan syndrome phenotype associated with SHOC2 mutation: Clinical evidence of crosslink between FGFR and RAS signaling pathways. *Am J Med Genet A*. 2014; 164A:2869–2872. [PubMed: 25123707]
44. Carmignac V, Thevenon J, Ades L, et al. In-frame mutations in exon 1 of SKI cause dominant Shprintzen-Goldberg syndrome. *Am J Hum Genet*. 2012; 91:950–957. [PubMed: 23103230]
45. Loeys BL, Chen J, Neptune ER, et al. A syndrome of altered cardiovascular, craniofacial, neurocognitive and skeletal development caused by mutations in TGFBR1 or TGFBR2. *Nat Genet*. 2005; 37:275–281. [PubMed: 15731757]
46. Bredrup C, Saunier S, Oud MM, et al. Ciliopathies with skeletal anomalies and renal insufficiency due to mutations in the IFT-A gene WDR19. *Am J Hum Genet*. 2011; 89:634–643. [PubMed: 22019273]

47. Gilissen C, Arts HH, Hoischen A, et al. Exome sequencing identifies WDR35 variants involved in Sensenbrenner syndrome. *Am J Hum Genet.* 2010; 87:418–423. [PubMed: 20817137]
48. Yagnik G, Ghuman A, Kim S, et al. ALX4 gain-of-function mutations in nonsyndromic craniosynostosis. *Hum Mutat.* 2012; 33:1626–1629. [PubMed: 22829454]
49. Twigg SR, Vorgia E, McGowan SJ, et al. Reduced dosage of ERF causes complex craniosynostosis in humans and mice and links ERK1/2 signaling to regulation of osteogenesis. *Nat Genet.* 2013; 45:308–313. [PubMed: 23354439]
50. Wilkie AO, Bochukova EG, Hansen RM, et al. Clinical dividends from the molecular genetic diagnosis of craniosynostosis. *Am J Med Genet A.* 2007; 143A:1941–1949. [PubMed: 17621648]
51. Cunningham ML, Horst JA, Rieder MJ, et al. IGF1R variants associated with isolated single suture craniosynostosis. *Am J Med Genet A.* 2011; 155A:91–97. [PubMed: 21204214]
52. Kim SD, Liu JL, Roscioli T, et al. Leucine-rich repeat, immunoglobulin-like and transmembrane domain 3 (LRIT3) is a modulator of FGFR1. *FEBS Lett.* 2012; 586:1516–1521. [PubMed: 22673519]
53. Tagariello A, Heller R, Greven A, et al. Balanced translocation in a patient with craniosynostosis disrupts the SOX6 gene and an evolutionarily conserved non-transcribed region. *J Med Genet.* 2006; 43:534–540. [PubMed: 16258006]

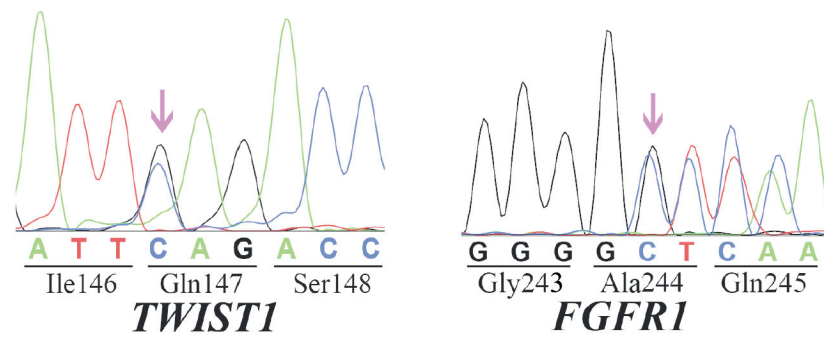


Fig. 1.

Sequencing chromatogram of novel variants identified in this study. The arrows indicate the positions of the variants. (*Left*) *TWIST1* c.439C>G; (*Right*) *FGFR1* c.730_731insG.




Fig. 2.

Assessment of the functional impact of the variant p.Q147E (c.439 C>G) in TWIST1. A reduced presentation of the multiple sequence alignment of the protein region with mutated residue produced by Mutation Assessor.¹² The whole alignment is composed of 393 sequence homologs of TWIST1 (both human and non-human) and divided into 29 subfamilies; only 50 sequences and 4 subfamilies are shown. The positions in the alignment are assessed by evolutionary conservation within entire protein family and by specificity, i.e. evolutionary conservation within subfamilies; the lengths of the bars above the alignment represent the relative strength of conservation and specificity in positions of the multiple alignment. The residues, which are conserved within subfamilies, i.e. specific to the subfamilies, are typically responsible for the actual binding specificity of proteins. The mutated residue is located in one of the top specificity positions, both the original glutamine and the mutated glutamic acid residues are represented by subfamilies; however the dominant residue in this position is a glutamic acid.

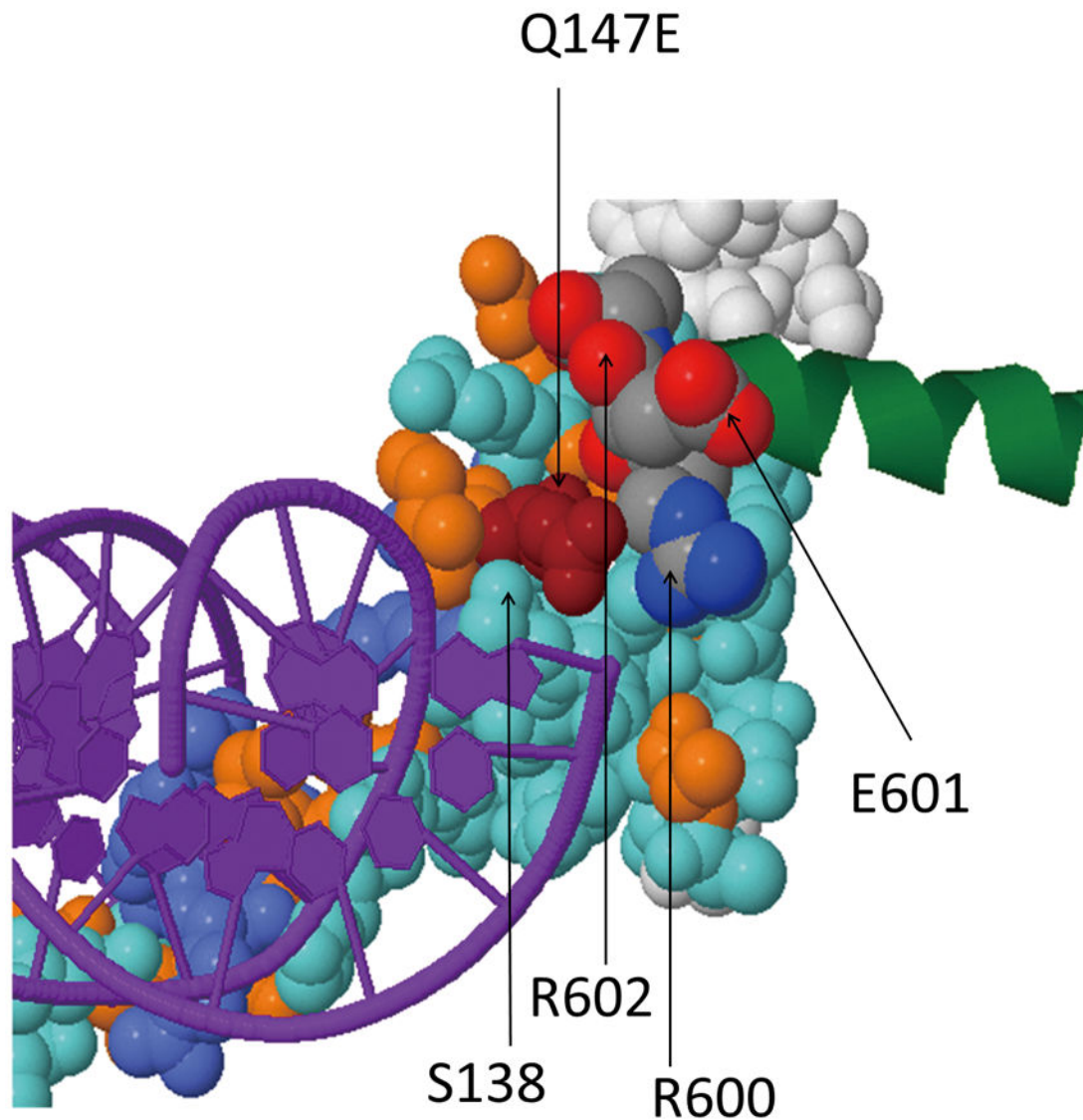


Fig. 3.

The 3D view of the complex of the neurogenic differentiation factor 1 (mouse homolog of TWIST1) and the transcription factor E2-alpha bound to DNA (PDB code 2QL2). The conserved and the specificity residues derived from multiple sequence alignment of TWIST1 homologs are mapped on the 3D structure of the neurogenic differentiation factor 1 and shown in blue and orange, respectively; DNA fragment is shown in violet; an alpha-helix fragment of E2-alpha is shown in green. The glutamic acid E147 in the position of the mutated residue (shown in dark red) contributes to the complex formation by interacting with the charged residues of the arginine 600 and the main chain of the glutamic acid 601 of E2-alpha protein; it also interacts with the hydroxyl group of serine 138 of TWIST1. The mutation of the glutamine Q147 to glutamic acid in TWIST1 is predicted to affect the stability, the complex and the regulation of transcription performed by TWIST1 molecule.

Table 1
Syndromic Craniosynostosis with Sagittal Suture Involvement and Related Genes

| Gene | OMIM | Syndrome/Phenotype | Sutures affected | Mutation effect | Mechanisms/Pathway | Reference |
|-------------------|----------------|---|--|-----------------------------------|--|-----------|
| <i>ABCC9</i> | 601439 | Cantu syndrome | Coronal, sagittal | LOF | Reduced ATP-dependent K ⁺ channel inhibition | 21 |
| <i>ALPL</i> | 171760 | Hypophosphatasia infantile type | Coronal, sagittal, lambdoid | LOF | Abnormal ALP enzyme expression and mineralization | 22 |
| <i>CHST3</i> | 603799 | Autosomal recessive Larsen syndrome | Sagittal | LOF | Affect GAG sulfation | 23 |
| <i>FAM20C</i> | 611061 | Raine syndrome (non-lethal osteosclerotic bone dysplasia) | Multiple | LOF | Abnormal kinase activity and secretion in mineralization | 24 |
| <i>FBN1</i> | 134797 | Shprintzen-Goldberg syndrome (Marfanoid craniosynostosis) | Coronal, sagittal, metopic | LOF | TGFβ | 25 |
| <i>FGF3, FGF4</i> | 164950, 164980 | Syndromic multiple craniosynostosis | Sagittal, metopic, lambdoid, temporal, squamosal | 11q11-q13.3 duplication | FGF | 26 |
| <i>FGFR1</i> | 136350 | Osteoglophonic dysplasia | Multiple | GOF | FGF | 27 |
| <i>FGFR2</i> | 176943 | Crouzonoid syndrome; Familial scaphocephaly syndrome | Sagittal | GOF | FGF | 28 |
| <i>FGFR3</i> | 134934 | Thanatophoric dysplasia type II | Coronal, sagittal, lambdoid | GOF | FGF | 10,29 |
| <i>GLI3</i> | 165240 | Greig cephalopolysyndactyly syndrome | Coronal, sagittal, metopic | LOF | Disrupt GLI-PTCH1-SHH signaling | 30 |
| <i>IFT122</i> | 606045 | Cranioectodermal dysplasia 1 (Sensenbrenner syndrome) | Sagittal | LOF | Reduced cilia frequency and length | 31 |
| <i>IFT43</i> | 614068 | Cranioectodermal dysplasia 3 (Sensenbrenner syndrome) | Sagittal | LOF | Cilia | 32 |
| <i>IHH</i> | 600726 | Craniosynostosis and syndactyly | Coronal, sagittal, metopic, lambdoid | Microduplication at the IHH locus | Misexpression and/or overexpression of IHH signaling | 33 |
| <i>IL11RA</i> | 600939 | Craniosynostosis and dental anomalies syndrome | Coronal, sagittal, metopic, lambdoid | LOF | Abnormal IL11/gp130 affect JAK/STAT1/3 or SHP2/MAPK/ERK phosphorylation cascades | 34 |
| <i>JAGGED1</i> | 601920 | Alagille syndrome | Coronal, sagittal, metopic, lambdoid | LOF | Loss of Notch signaling activity | 35 |
| <i>MEGF8</i> | 604267 | Carpenter syndrome 2 | Coronal, sagittal, metopic | LOF | Perturb HH and Nodal signaling | 36 |
| <i>MSX2</i> | 123101 | Boston-type craniosynostosis | Sagittal, metopic | GOF | FGF/BMP | 37 |
| <i>OSTM1</i> | 607649 | Infant osteopetrosis craniosynostosis, Chiari malformation type I | Coronal, sagittal | LOF | Abnormal osteoclast function | 38 |
| <i>PHEX</i> | 300550 | X-linked dominant hypophosphatemic rickets | Coronal, sagittal | LOF | Aberrant function in osteoblast-mediated bone mineralization | 39 |

| Gene | OMIM | Syndrome/Phenotype | Sutures affected | Mutation effect | Mechanisms/Pathway | Reference |
|-----------------|--------|---|--------------------------------------|-----------------|---|-----------|
| <i>RAB23</i> | 606144 | Carpenter syndrome 1 | Coronal, sagittal, metopic, lambdoid | LOF | Abnormal SHH signaling | 41 |
| <i>SH3PXD2B</i> | 613293 | Frank-ter Haar syndrome | Sagittal, lambdoid | LOF | Disrupt extracellular matrix remodeling | 42 |
| <i>SHOC2</i> | 602775 | Noonan syndrome | Coronal, sagittal, lambdoid | LOF | Enhance MAPK activation | 43 |
| <i>SKI</i> | 164780 | Shprintzen-Goldberg Craniosynostosis syndrome | Coronal, sagittal | LOF | Aberrant SMAD3-TGFB signaling | 44 |
| <i>TGFBR1</i> | 190181 | Loeys-Dietz type 1 | Sagittal, metopic | LOF | Activate and phosphorylation in SMAD-TGFβ signaling | 45 |
| <i>TGFBR2</i> | 190182 | Loeys-Dietz type 2 | Sagittal, metopic | LOF | TGFβ | 45 |
| <i>WDR19</i> | 608151 | Cranioectodermal dysplasia 4 (Sensenbrenner syndrome) | Sagittal | LOF | Encode intraflagellar transport (IFT) 144 gene that drive ciliary transport | 46 |
| <i>WDR35</i> | 613602 | Cranioectodermal dysplasia 2 (Sensenbrenner syndrome) | Sagittal | LOF | Cilia | 47 |

Table 2

Mutations/Variants Found in Human Sagittal Nonsyndromic Craniosynostosis

| Gene | Nucleotide Change | Amino Acid Change | Case Population Studied | Mutation Detection Rate | Population Frequency (IKG/ESP/ExAC) | Reference |
|---------------|-------------------|-------------------|---|---|---|------------|
| <i>AIX4</i> | c.19G>T | V7F | 203 NSC patients (197 sNSC and 6 multiple suture CS with sagittal suture involvement) | 1% (2/203) | 1/12956 (ESP); 1/49772 (ExAC) | 48 |
| | c.631A>G | K211E | | | 0 | |
| <i>ERF</i> | c.194G>A | R65C | 70 sNSC | 1% (1/70) | 0 | 49 |
| <i>FGFR1</i> | c.1508C>T | T261M | 164 infants with isolated, single-suture craniosynostosis (83 sagittal, 37 metopic, 12 lambdoid, 32 unilateral coronal) | 1% (1/83) | 21/5008 (IKG); 1/6788 (ESP); 85/35096 (ExAC) | 16 |
| | c.730_731insG | A244fs*26 | 93 sNSC patients | 1% (1/93) | 0 | This study |
| <i>FGFR2</i> | c.1032G>A | A344A | 2 familial sNSC | 2 patients | 0 | 15 |
| | c.833G>A | C278Y | 1 familial (1 individual has isolated sagittal/unilambdoid synostosis, 3 others unaffected) | 1 patient | 0 | 50 |
| | c.943G>A | A315T | 29 sNSC patients | 3% (1/29) | 1/121146 (ExAC) | 11 |
| | c.1139_1196dup | M400fs*53 | 630 craniosynostosis (94 sNSC) | 1% (1/94) | 0 | 10 |
| <i>FGFR3</i> | c.1000G>A | A334T | 1 familial, sagittal and metopic ridging | 3 patients | 1/13006 (ESP) | 20 |
| <i>IGF1R</i> | c.1217G>A | R406H | 186 NSC (94 sagittal, 46 coronal, 46 metopic) | 2% (2/94) | 2/12988 (ESP); 4/121408 (ExAC) | 51 |
| | c.2570A>G | N857S | | | 24/5008 (IKG); 1/12988 (ESP); 247/121406 (ExAC) | |
| <i>LRIT3</i> | c.1346G>C | S494T | 431 NSC patients (no information if only sagittal or multiple sutures affected) | 0.5% (2/431) | 0 | 52 |
| | c.1640G>A | C592Y | | | 2/121380 (ExAC) | |
| <i>SOX6</i> | c.263G>A | D68N | 104 sagittal/coronal (no information if nonsyndromic or multiple sutures) | 1% (1/104) | 1/5008 (IKG); 8/12988 (ESP); 129/121130 (ExAC) | 53 |
| <i>TWIST1</i> | c.563C>T | S188L | 164 infants with isolated, single-suture craniosynostosis (83 sagittal, 37 metopic, 12 lambdoid, 32 unilateral coronal) | 1% (1/83) | 0 | 16 |
| | c.602C>A | S201Y | 178 patients (84 Saethre-Chotzen syndrome, 7 Muenke syndrome, 12 other syndromes, 75 nonsyndromic coronal synostosis) | 2 patients from 1 family, 1 has scaphocephaly, 1 has no synostosis (reduced penetrance) | 0 | 14 |
| | c.439C>G | Q147E | 93 sNSC patients | 1% (1/93) | 1/120318 (ExAC) | This study |