



HAL
open science

Choanal Atresia and Craniosynostosis

Kate Lesciotto, Yann Heuzé, Ethylin Wang Jabs, Joseph Bernstein, Joan Richtsmeier

► **To cite this version:**

Kate Lesciotto, Yann Heuzé, Ethylin Wang Jabs, Joseph Bernstein, Joan Richtsmeier. Choanal Atresia and Craniosynostosis. *Plastic and Reconstructive Surgery*, 2018, 141 (1), pp.156-168. 10.1097/PRS.0000000000003928 . hal-02322414

HAL Id: hal-02322414

<https://hal.science/hal-02322414>

Submitted on 11 Jan 2021

HAL is a multi-disciplinary open access archive for the deposit and dissemination of scientific research documents, whether they are published or not. The documents may come from teaching and research institutions in France or abroad, or from public or private research centers.

L'archive ouverte pluridisciplinaire **HAL**, est destinée au dépôt et à la diffusion de documents scientifiques de niveau recherche, publiés ou non, émanant des établissements d'enseignement et de recherche français ou étrangers, des laboratoires publics ou privés.



Published in final edited form as:

Plast Reconstr Surg. 2018 January ; 141(1): 156–168. doi:10.1097/PRS.0000000000003928.

Choanal Atresia and Craniosynostosis: Development and Disease

Ms. Kate M. Lesciotto, MS¹, Dr. Yann Heuzé, PhD², Dr. Ethylin Wang Jabs, MD³, Dr. Joseph M. Bernstein, MD⁴, and Dr. Joan T. Richtsmeier, PhD¹

¹Department of Anthropology, Pennsylvania State University, University Park, Pennsylvania

²Univ. Bordeaux, CNRS, MCC, PACEA, UMR5199, Bordeaux Archaeological Sciences Cluster of Excellence, Pessac, France

³Department of Genetics and Genomic Sciences, Icahn School of Medicine at Mount Sinai, New York, New York

⁴Department of Otolaryngology, Icahn School of Medicine at Mount Sinai, New York, New York

Summary

A number of textbooks, review papers, and case reports highlight the potential comorbidity of choanal atresia in craniosynostosis patients. However, the lack of a precise definition of choanal atresia within the current craniosynostosis literature and widely varying methods of detection and diagnosis has produced uncertainty regarding the true coincidence of these conditions. We review the anatomy and embryological basis of the human choanae, provide an overview of choanal atresia, and analyze the available literature that links choanal atresia and craniosynostosis. Review of over 50 case reports that describe patients diagnosed with both conditions reveals inconsistent descriptions of choanal atresia and limited use of definitive diagnostic methodologies. We further present preliminary analysis of 3D medical head computed tomography scans of children diagnosed with craniosynostosis syndromes of Apert, Pfeiffer, Muenke, or Crouzon and typically developing children and, while finding no evidence of choanal atresia, we report the potentially reduced nasal airway volumes in children diagnosed with Apert and Pfeiffer syndromes. A recent study of the *Fgfr2c^{+C342Y}* Crouzon/Pfeiffer syndrome mouse model similarly found a significant reduction in nasal airway volumes in littermates carrying this FGFR2 mutation relative to unaffected littermates, without detection of choanal atresia. The significant correlation between specific craniosynostosis syndromes and reduced nasal airway volume in mouse models for

Corresponding author: Joan T. Richtsmeier, Department of Anthropology, Pennsylvania State University, 409 Carpenter Building, University Park, PA 16802, jta10@psu.edu.

Author's Role/Participation:

Kate M. Lesciotto: Ms. Lesciotto conceptualized the article, conducted the literature review, drafted the initial manuscript, reviewed and revised the manuscript, and approved the final manuscript as submitted.

Yann Heuzé, PhD: Dr. Heuzé carried out the analyses on human pediatric craniosynostosis patients, reviewed and revised the manuscript, and approved the final manuscript as submitted.

Ethylin Wang Jabs, MD: Dr. Jabs conceptualized the article, reviewed and revised the manuscript, and approved the final manuscript as submitted.

Joseph M. Bernstein, MD: Dr. Bernstein conceptualized the article, reviewed and revised the manuscript, and approved the final manuscript as submitted.

Joan T. Richtsmeier, PhD: Dr. Richtsmeier conceptualized the article, drafted the initial manuscript, reviewed data analysis, reviewed and revised the manuscript, and approved the final manuscript as submitted.

craniosynostosis and human pediatric patients indicates comorbidity of choanal and nasopharyngeal dysmorphologies and craniosynostosis conditions. Genetic, developmental and epidemiologic sources of these interactions are areas particularly worthy of further research.

Introduction

We present a review of case reports that link craniosynostosis and choanal atresia to highlight the uncertainty of a choanal atresia diagnosis in pediatric craniosynostosis patients and provide anatomical data from human and mouse to more fully define choanal and associated dysmorphologies. The lack of a precise definition of choanal atresia in the current craniosynostosis literature results in an unclear set of standards for the diagnosis of choanal dysmorphologies. The developmental genetic significance of the association of choanal atresia and craniosynostosis and the implications for developing appropriate therapeutics requires a clear understanding of these anomalies.

The Human Choanae

In humans, the choanae are defined in several ways. Osteologically, the choanae are the posterior openings of the right and left nasal passages that are bordered medially by the posterior border of the vomer, superiorly by the sphenoid body, laterally by the medial pterygoid plates, and inferiorly by the horizontal plate of the palatine bones¹ (Fig. 1). An anatomical definition includes these osteological borders of the choanae, or posterior nares, while incorporating the surrounding soft tissues: the choanae are the pair of posterior apertures of the nasal cavity that open into the nasopharynx. Each choana can be defined functionally, as an internal nostril, connecting the nasal air space and the posterior roof of the pharyngeal cavity (Fig. 2). Study of extant jawed fishes and fossil vertebrates show that choanae evolved from a condition in which anterior and posterior external nostrils functioned without a connection between the nasal sac and the oral cavity². The tetrapod choanae (“internal nostrils”) are homologous to the posterior external nostrils of jawed fishes² and are a key feature of the evolution of tetrapods, a group that includes, reptiles, mammals, and humans. The tetrapod respiratory system appeared with the evolution of the palate separating the nasal and oral respiratory systems. Only tetrapods possess choanae².

Embryogenesis of the choanae is complex, characterized by several distinct developmental periods, each requiring the precise spatiotemporal coordination of the development of diverse tissues and functioning spaces before the final structure and function are reached (Fig. 3). At the end of the seventh week of prenatal ontogeny, the medial nasal prominences fuse³, providing the foundation for the primary palate^{3,4}. The posterior portion of the intermaxillary process becomes the oro-olfactory, oronasal, or nasobuccal membrane, which separates the developing olfactory sac from the oral cavity^{3,5}. When this membrane ruptures, the *primary choanae* are formed, permitting communication between the nasal and oral cavities^{3,6}. At this stage, the lateral palatal shelves are still oriented vertically^{3,6}. As these shelves transition downward to their final horizontal position, the remnants of the primary choanae become the incisive foramen, the primary palate fuses to the secondary palate posteriorly, the right and left lateral shelves of the secondary palate fuse along the midline,

and the posterior or *secondary choanae* are formed and shifted posteriorly following this progressive fusion^{3,5-8}. During this time, the nasal septum has formed from the roof of the nasal cavity to meet the superior surfaces of the primary and secondary palates along the midline, dividing the left and right nasal cavities³. The completion of this process results in separation of the right and left nostrils and separation of the nasal and oral cavities, with the secondary choanae defining the posterior aspect of the left and right nasal cavities immediately rostral to the nasopharynx. For the purposes of this article, the secondary choanae are referred to generally as the choanae.

Choanal Atresia – Definition, development and diagnosis

Errors in timing, organization, or development of the palate can give rise to numerous dysmorphic conditions, including various degrees of clefting of the hard and/or soft palate⁴. Choanal atresia is a less common, though medically significant, anomaly associated with errors of development of the nasal cavity and palate. Choanal atresia is defined as the complete obstruction of the posterior nasal apertures (choanae) by osseous tissue, either alone or in combination with non-osseous tissue^{1,9-11}. This blockage may occur unilaterally or bilaterally and results in a lack of communication of the nasal cavity with the pharyngeal cavity via the nasopharynx¹, thereby preventing inhalation and exhalation of air through the affected nasal passage(s). Two major osteological deformities have been described in choanal atresia: 1) a medialization of the medial pterygoid plates; and 2) a thickening of the posterior vomer^{9,10,12,13}. Either of these deformations can lead to a narrowing of the choanae, potentially resulting in complete obstruction of the choanae. Several developmental theories are commonly cited in the formation of choanal atresia: (1) persistence of the buccopharyngeal membrane from the foregut; (2) persistence or abnormal location of mesoderm forming adhesions in the nasochoanal region; (3) persistence of the nasobuccal membrane of Hochstetter; and (4) misdirection of neural crest cell migration and subsequent flow of mesoderm^{1,5,9-11,14}. However, none of these provides a precise explanation for obstruction or minimization of the size of the choanal openings by developmental processes, and to date, there has been no definitive evidence supporting one theory over the others.

Significantly, choanal atresia must be differentiated from choanal stenosis, a diagnosis defined as the narrowing of the posterior choanae without complete obstruction¹⁵, and from nasal pyriform aperture stenosis, which involves narrowing of the skeletal borders of the anterior nasal cavity^{1,16,17}. Precise definitions are required to correct common errors that incorporate narrowing or incomplete obstruction of the choanae within the definition of choanal atresia or that conflate choanal atresia with choanal stenosis (see, e.g.,^{10,18-20}). The potential for the misdiagnosis of choanal atresia has been recognized in pediatric patients with major craniofacial anomalies since these conditions routinely include some form of midfacial retrusion. Airway obstruction is common in craniofacial syndromes due to potential maldevelopment of the palate (floor of the pyriform aperture), the nasal airway, the nasopharynx, or the entire midfacial skeleton in the production of midfacial dysmorphogenesis^{1,21-23}.

Choanal atresia is typically suspected in infants exhibiting respiratory distress, particularly when feeding^{12,13}. Bilateral choanal atresia in neonates presents an emergent situation, as

infants are obligate nasal breathers. Bilateral choanal atresia leads to cyclic cyanosis relieved by crying which facilitates mouth breathing^{1,10,11}. While truly complete obstruction of the posterior choanae can only be confirmed through diagnostic imaging or endoscopy, choanal atresia is often diagnosed by the inability to cannulate the nasal passage with a small catheter, a procedure that cannot definitively distinguish partial stenosis or complete obstruction of the choanae^{9,12,17,22,24}. The incidence of choanal atresia ranges from 1 in 5000–8000 live births, with a 2:1 higher occurrence in females^{9,10,13,24,25}. Unilateral choanal atresia is slightly more common than bilateral atresia, while bilateral atresia is more common when other craniofacial malformations are present^{9,10,13,24}.

In an early review, Durward and colleagues (1945) defined choanal atresia as a very rare condition and concluded that the association between choanal atresia and other syndromic craniofacial dysmorphologies was no more than spurious²⁶. Improvements in diagnostic imaging and neonatal care have permitted researchers to make the explicit link between choanal atresia and a number of craniofacial disorders, most notably CHARGE syndrome, with an estimated 7–29% of choanal atresia patients also being diagnosed with CHARGE¹⁰. Syndromic craniosynostosis patients make up another core subset of patients diagnosed with choanal atresia, with specific associations made between choanal atresia and Antley-Bixler, Apert, Beare-Stevenson, Crouzon, Crouzonodermoskeletal (Crouzon with acanthosis nigricans), Jackson-Weiss, and Pfeiffer syndromes^{1,10,15,17,18,27–29}.

Choanal Atresia and Syndromic Craniosynostosis in Pediatric Patients

Craniosynostosis is a condition of complex etiology that always involves the premature fusion of one or multiple cranial sutures and includes various anomalies of the soft and hard tissues of the head³⁰. In cases of syndromic craniosynostosis, the closed suture occurs as part of a suite of symptoms or features, and mutations in a number of genes have been identified as being associated with these syndromes (see, e.g.,^{30–32}). The nearly 200 identified craniosynostosis syndromes account for approximately 15% of all craniosynostosis cases³⁰. Recent work stresses the complexity of craniosynostosis phenotypes even in cases of nonsyndromic (isolated) craniosynostosis, emphasizing that craniosynostosis conditions need to be defined not simply by premature suture closure, but more broadly as growth disorders that affect many different cell and tissue lineages^{30,31,33–35}. Consequent to the broad developmental impact of the genes on which craniosynostosis-causing mutations are located (e.g., fibroblast growth factor receptors, TWIST), many craniofacial tissues are affected in craniosynostosis syndromes, including skeletal (bone and cartilage), muscular, neural, and circulatory structures. Facial dysmorphologies potentially associated with craniosynostosis syndromes include maxillary dysmorphogenesis resulting in a reduced midface, hypertelorism, exophthalmos, depressed or low nasal bridge, mandibular prognathism, cleft palate, and highly arched and/or constricted palate^{27,36–40}. Any one of these structural anomalies has the potential to contribute to altering the position, size, shape, or patency of the choanae.

Craniosynostosis has been explicitly linked with choanal atresia in one of the seminal texts on the diagnosis and evaluation of craniosynostosis, noting that atresia or stenosis is an “expected” clinical finding in craniosynostosis syndromes, particularly where there have

been structural rearrangements in the cranial base²⁷, a region of the skull that forms endochondrally from a complex series of cartilages that underlie the brain. Additional links between syndromic craniosynostosis and choanal atresia can be found in review and research articles throughout the clinical literature (see, e.g.,^{1,10,15,17,18,29,37}). Table 1 lists published case reports that have explicitly reported choanal atresia in patients diagnosed with syndromic craniosynostosis. Craniosynostosis cases reporting only choanal stenosis are not included.

Of the 54 case reports reviewed, none included a definition of choanal atresia, and several provide descriptions suggesting that the condition may have more likely been choanal stenosis^{19,20,41}. For example, various authors reported (emphases added):

- "all four of our patients exhibited choanal atresia (*narrowed* nasal passage)"¹⁹
- "*incomplete* choanal atresia led to respiratory difficulties"²⁰
- condition was first labeled "choanal atresia" and later as "choanal *hypoplasia*"⁴¹, the former being a diagnostic category and the latter being a description that suggests the developmental basis of this anomaly.

Additionally, the methods of evaluation and diagnosis were often not indicated, and the fundamental differences among diagnostic tools were not discussed by these authors. Only eight cases reported the use of CT imaging to confirm the choanal atresia diagnosis^{42–49}, while others cited Doppler evidence⁵⁰, choanagraphy⁵¹, inability to pass a naso-gastric tube through the posterior choanae⁵², simple reference to "imaging"⁴⁷, and pharyngiogram⁵³. Although CT imaging was mentioned in seven additional case reports, those reports did not include an indication of whether the scan was utilized in the choanal atresia diagnosis^{53–59}. Another nine reports mentioned various types of surgical intervention in which direct visualization may have been possible, but no explicit description of the surgical evaluation was given^{54,57,60–66}. These reports also varied widely in the detail of the description of co-occurring facial anomalies that might contribute to respiratory difficulties. It is important to note that, unless the above-referenced case reports included images of the diagnostic scans, it is impossible to say for certain whether the suggested choanal atresia was correctly diagnosed.

Looking Forward

The clear implication of the case reports (Table 1) is the need for a consistent application of an invariant clinical definition of choanal atresia that is distinct from choanal stenosis. The term "choanal atresia" was used in a number of these case reports, yet the condition described may actually be choanal stenosis. Without review of each described patient's medical records and associated diagnostic images and results, we are only able to note that the diagnosis is not well supported based on the published information and cannot definitively state whether any of these choanal atresia diagnoses are truly erroneous. Other reports simply group the conditions together and report a finding of "choanal stenosis/atresia." Although options may be similar from a treatment perspective, understanding choanal stenosis and atresia as potentially different pathologies with distinct etiologies requires more precise descriptions and further research. While several craniofacial textbooks

and journal articles provide clear definitions of choanal atresia^{1,9–11,16}, many authors either omit a definition from published case reports or fail to explicitly match a given definition to their clinical observations and reports. Additionally, while medical CT is acknowledged to be the gold standard for the diagnosis of choanal atresia^{1,11,15,17,18,67}, the vast majority of published case reports either fail to report the use of this preferred diagnostic methodology, or utilize less reliable techniques that may erroneously lead to a choanal atresia diagnosis when choanal stenosis or other choanal or nasal dysmorphology is present. Sculerati and colleagues' previous study of over 250 pediatric patients with major craniofacial anomalies produced results that support our observations, finding that choanal atresia was often misdiagnosed when respiratory difficulties were actually being caused by nasal obstructions secondary to midfacial retrusion²¹. In addition to the need for a better understanding of the facial dysmorphologies associated with midfacial retrusion (hypoplasia, flattening, dysgenesis), further research should be directed towards the investigation of the relationship between choanal stenosis and choanal atresia and whether they are distinct abnormalities or represent unique conditions along a continuum of choanal dysmorphogenesis. Given the state of the existing literature, it is recommended that case reports and research articles focusing on choanal atresia provide both an explicit definition of the condition, as well as details regarding the methodology used to detect and diagnose the condition. Recent caution regarding radiation exposure when using CT as a primary diagnostic tool⁶⁸ provides a timely opportunity to refine both the clinical definition of choanal atresia, as well as to develop a new standard for detection and diagnosis.

Research focused on choanal development, structure, and morphology in humans (especially within the pediatric craniosynostosis syndrome population) and animal models is needed to better understand the true incidence of choanal atresia within this patient population. Several studies have reported nasal airway volume or morphology in pediatric choanal atresia patients^{12,13}, but little work has been done to quantify or describe choanal or nasal airway morphology in syndromic craniosynostosis patients. Perhaps more importantly, there have been few serious attempts to tie craniosynostosis conditions to choanal atresia developmentally or by molecular causation.

A recent analysis of 3D medical CT scans comprising children diagnosed with Apert, Pfeiffer, Muenke, or Crouzon syndrome and typically developing children (aged 0–23 months) without craniosynostosis who underwent CT imaging for unrelated conditions (e.g., seizures) provides information about differences in facial skeletal shape among craniosynostosis syndromes⁴⁰. The 3D isosurfaces were reconstructed from the set of DICOM images⁴⁰, and these 3DCTs were evaluated visually for the presence of choanal atresia. Of 33 individuals diagnosed with syndromic craniosynostosis, none had choanal atresia. Nasopharyngeal volume, including the ethmoidal air cells, was estimated for each patient using the segmentation editor of the software package Avizo 6.3 (Visualization Sciences Group, VSG). The nasal vestibule defined the anterior end of the nasal cavity, with the borders defined by soft tissue when present in individual 3DCT slices or by manually closing the nostrils when soft tissue was not present (Figure 4A–C). Posteriorly, only the nasopharyngeal lumen that was present anterior to or coincident with a line connecting the most posterior points on the right and left medial plates of the pterygoid was included in the segmented volume (Figure 4D). Comparisons between unaffected children and those

diagnosed with syndromic craniosynostosis reveal potentially reduced nasal airway volumes in children diagnosed with Apert and Pfeiffer syndromes (Figs. 5 and 6). Analysis of cross sectional data representing nasal airway volumes of varying groups from birth to ~30 months of age shows that children diagnosed with Apert and Pfeiffer syndromes appear to share similar nasal airway volumes with children diagnosed with Muenke syndromes and their typically developing peers at birth. Although the sample size is small, the results also indicate that children diagnosed with Crouzon syndrome may have reduced nasal airway volumes at birth. Based on this analysis using limited samples, children diagnosed with Apert and Pfeiffer syndromes may experience an early postnatal developmental divergence that results in smaller overall nasal airways within the first year of life (Fig. 5).

The distinction between true choanal atresia and more diffuse nasal airway stenosis that is often present in syndromic craniosynostosis is important for both clinical and basic research reasons. While it is paramount that researchers in the field have a clear understanding of the correct terminology in order to ensure appropriate communication and reporting, there are also potential clinical ramifications to consider. Choanal atresia in the newborn is a condition that is very amenable to early surgical intervention, which can often obviate the need for tracheostomy, prolonged NICU hospitalization, and continued respiratory monitoring. Nasal airway obstruction in the newborn with syndromic craniosynostosis may not be as readily surgically correctable in early life. Incorrect terminology may lead a surgeon down an errant pathway and may lead the child's family to have unrealistic expectations. Knowledge of associations between craniosynostosis and choanal atresia will require development of standards of diagnosis and application of those standards.

Mouse models have been developed for a number of craniosynostosis syndromes that replicate the genetic cause as well as the skeletal and soft tissue phenotypes seen in human patients, including midfacial hypoplasia⁶⁹⁻⁷⁵. Several of these models have also been utilized to investigate nasal airway volumes. A recent study of the soft tissue phenotype of the *Fgfr2c^{+/-}C342Y* Crouzon/Pfeiffer syndrome mouse model found a significant reduction in nasal airway volumes in littermates carrying this mutation relative to unaffected littermates³⁵. The C342Y mutation is equivalent to the most common mutation associated with human patients diagnosed with Crouzon syndrome. The human Crouzon syndrome phenotype has been associated with a number of craniofacial dysmorphologies related to both hard and soft tissues, such as premature closure of the coronal suture, midfacial hypoplasia/retrusion, and alterations to nasopharyngeal morphology^{27,38}. Skeletal phenotypic correspondences between human patients with Crouzon syndrome and the *Fgfr2c^{+/-}C342Y* mouse model of Crouzon syndrome have been demonstrated, and this mouse model also mimics the altered human nasopharyngeal phenotype³⁵. At P0 (day of birth), heterozygous *Fgfr2c^{+/-}C342Y* littermates exhibited a statistically significant restriction in nasal airway volume ($2.81 \pm 0.17 \text{ mm}^3$), as compared to their unaffected littermates ($3.28 \pm 0.13 \text{ mm}^3$, $p = 0.012$)³⁵. However, choanal atresia was not reported in any of the mice studied. As of this date, there have been no published reports of definitive choanal atresia in any mouse models of syndromic craniosynostosis.

While murine data provide valuable information about the molecular and developmental mechanisms that produce the choanae, significant differences in human and murine

craniofacial anatomy and development must be taken into consideration when evaluating the comorbidity of choanal atresia and craniosynostosis using cross-species comparisons. Due to the rostral-caudal elongation of the murine premaxillae, maxillae, palatine bones, and the soft palate, different osteological and soft tissue boundaries define the murine choanae relative to humans. In humans, choanal atresia has been attributed to a combination of a thickening of the posterior vomer with medialization of the pterygoid plates of the sphenoid. Although useful murine models of choanal atresia have recently been produced and will be critical to determining the molecular and developmental basis of choanal atresia⁷⁶, species-specific differences including the anatomical separation of the vomer and pterygoid plates along the rostro-caudal axis in mice suggests an alternate structural foundation for murine choanal atresia (Fig. 7). While mouse models are an excellent tool for understanding the etiology of human craniofacial disorders like craniosynostosis, given the tremendous number of genetic mutations implicated in craniosynostosis conditions, each model can represent only a single development pathway to the craniosynostosis phenotype. We propose that there are potentially as many ways to produce choanal atresia.

The significant correlation between specific craniosynostosis syndromes and reduced nasal airway volume in mouse models for craniosynostosis and human pediatric patients indicates comorbidity of choanal and nasopharyngeal dysmorphologies and craniosynostosis conditions. Genetic, developmental and epidemiologic sources of these interactions are areas particularly worthy of further research.

Acknowledgments

The authors thank members of the Bernstein, Jabs, and Richtsmeier labs for ongoing discussions about the development, anatomy and dysmorphology of the choanae that informed this study, including Susan Motch Perrine, Kevin Flaherty, Kazuhiko Kawasaki, Mizuho Kawasaki, Greg Holmes, James Azzi, and Sameep Kadakia. Use of the CT images was approved by the Institutional Review Boards of the Pennsylvania State University and the participating institutions and the images were acquired in accordance with institutional guidelines. All collected images were anonymized and no information other than sex, age at the time of the CT exam, and causative mutation were available. Research presented here was funded in part by the National Institutes of Health (NIDCR, NICHD and ARRA) [R01-DE018500, R01-DE018500-S1, R01-DE022988, P01HD078233] and the National Science Foundation [BCS-0725227].

References

1. Adil E, Huntley C, Choudhary A, Carr M. Congenital nasal obstruction: clinical and radiologic review. *Eur J Pediatr*. 2012; 171(4):641–650. [PubMed: 21964985]
2. Zhu M, Ahlberg PE. The origin of the internal nostril in tetrapods. *Nature*. 2004; 432(7013):94–97. [PubMed: 15525987]
3. Jankowski, R. *The Evo-Devo Origin of the Nose, Anterior Skull Base and Midface*. Paris: Springer Paris; 2013.
4. Sperber, GH., Sperber, SM., Guttmann, GD. *Craniofacial Embryogenetics and Development*. PMPH; 2010.
5. Hengerer AS, Brickman TM, Jeyakumar A. Choanal atresia: Embryologic analysis and evolution of treatment, a 30-year experience. *The Laryngoscope*. 2008; 118(5):862–866. [PubMed: 18197129]
6. Kim C-H, Park HW, Kim K, Yoon J-H. Early development of the nose in human embryos: a stereomicroscopic and histologic analysis. *The Laryngoscope*. 2004; 114(10):1791–1800. [PubMed: 15454774]
7. Tamarin A. The formation of the primitive choanae and the junction of the primary and secondary palates in the mouse. *Am J Anat*. 1982; 165(3):319–337. [PubMed: 7180818]

8. Mankarious LA, Goudy SL. Craniofacial and upper airway development. *Paediatr Respir Rev.* 2010; 11(4):193–198. [PubMed: 21109176]
9. Kwong KM. Current Updates on Choanal Atresia. *Front Pediatr.* 2015; 3(52)doi: 10.3389/fped.2015.00052
10. Corrales CE, Koltai PJ. Choanal atresia: current concepts and controversies. *Curr Opin Otolaryngol Head Neck Surg.* 2009; 17(6):466–470. [PubMed: 19779346]
11. Harney, MS., Russell, J. Choanal Atresia. In: Puri, P., Höllwarth, M., editors. *Pediatric Surgery.* Berlin, Heidelberg: Springer Berlin Heidelberg; 2009. p. 223–227.
12. Aslan S, Yilmazer C, Yildirim T, Akkuzu B, Yilmaz I. Comparison of nasal region dimensions in bilateral choanal atresia patients and normal controls: A computed tomographic analysis with clinical implications. *Int J Pediatr Otorhinolaryngol.* 2009; 73(2):329–335. [PubMed: 19101042]
13. Cheung R, Prince M. Comparison of craniofacial skeletal characteristics of infants with bilateral choanal atresia and an age-matched normative population: computed tomography analysis. *J Otolaryngol.* 2001; 30(3):173–178. [PubMed: 11771048]
14. Bergstrom L, Owens O. Posterior choanal atresia - a syndromal disorder. *Laryngoscope.* 1984; 94(10):1273–1276. [PubMed: 6482622]
15. Lowe LH, Booth TN, Joglar JM, Rollins NK. Midface anomalies in children. *Radiographics.* 2000; 20(4):907–922. [PubMed: 10903683]
16. Brown OE, Myer CM III, Manning SC. Congenital nasal pyriform aperture stenosis. *Laryngoscope.* 1989; 99:86–91. [PubMed: 2909825]
17. Keller JL, Kacker A. Choanal atresia, CHARGE association, and congenital nasal stenosis. *Otolaryngol Clin North Am.* 2000; 33(6):1343–1351. [PubMed: 11449791]
18. Ramsden JD, Campisi P, Forte V. Choanal Atresia and Choanal Stenosis. *Otolaryngol Clin North Am.* 2009; 42(2):339–352. [PubMed: 19328897]
19. Meyers GA, Orlow SJ, Munro IR, Przylepa KA, Jabs EW. Fibroblast growth factor receptor 3 (FGFR3) transmembrane mutation in Crouzon syndrome with acanthosis nigricans. *Nat Genet.* 1995; 11(4):462–464. [PubMed: 7493034]
20. Wilkes D, Rutland P, Pulleyn LJ, et al. A recurrent mutation, ala391glu, in the transmembrane region of FGFR3 causes Crouzon syndrome and acanthosis nigricans. *J Med Genet.* 1996; 33(9):744–748. [PubMed: 8880573]
21. Sculerati N, Gottlieb MD, Zimble MS, Chibbaro PD, McCarthy JG. Airway management in children with major craniofacial anomalies. *Laryngoscope.* 1998; 108(12):1806–1812. [PubMed: 9851495]
22. Buchman, SR., Muraszko, K. Syndromic craniosynostosis. In: Thaller, S, Bradley, JP., Garri, JI., editors. *Craniofacial Surgery.* New York: CRC Press; 2007. p. 103–126.
23. Allanson JE, Cunniff C, Hoyme HE, McGaughran J, Muenke M, Neri G. Elements of morphology: Standard terminology for the head and face. *Am J Med Genet A.* 2009; 149A(1):6–28. DOI: 10.1002/ajmg.a.32612 [PubMed: 19125436]
24. Neskey D, Eloy JA, Casiano RR. Nasal, Septal, and Turbinate Anatomy and Embryology. *Otolaryngol Clin North Am.* 2009; 42(2):193–205. DOI: 10.1016/j.otc.2009.01.008 [PubMed: 19328886]
25. Burrow TA, Saal HM, de Alarcon A, Martin LJ, Cotton RT, Hopkin RJ. Characterization of congenital anomalies in individuals with choanal atresia. *Arch Otolaryngol Neck Surg.* 2009; 135(6):543–547.
26. Durward A, Lord OC, Polson CJ. Congenital choanal atresia. *J Laryngol Otol.* 1945; 60(12):461–500. [PubMed: 20994680]
27. Cohen, MM., MacLean, RE., editors. *Craniosynostosis: Diagnosis, Evaluation, and Management.* USA: Oxford University Press; 2000.
28. Arnaud-López L, Frago R, Mantilla-Capacho J, Barros-Núñez P. Crouzon with acanthosis nigricans. Further delineation of the syndrome. *Clin Genet.* 2007; 72(5):405–410. [PubMed: 17935505]
29. Hehr U, Muenke M. Craniosynostosis syndromes: from genes to premature fusion of skull bones. *Mol Genet Metab.* 1999; 68:139–151. [PubMed: 10527665]

30. Flaherty K, Singh N, Richtsmeier JT. Understanding craniosynostosis as a growth disorder. *Wiley Interdiscip Rev Dev Biol.* 2016; 5:429–459. [PubMed: 27002187]
31. Heuzé Y, Holmes G, Peter I, Richtsmeier JT, Jabs EW. Closing the gap: genetic and genomic continuum from syndromic to nonsyndromic craniosynostoses. *Curr Genet Med Rep.* 2014; 2(3): 135–145. [PubMed: 26146596]
32. Lattanzi W, Barba M, Pietro LD, Boyadjiev SA. Genetic advances in craniosynostosis. *Am J Med Genet A.* Feb.2017 doi: 10.1002/ajmg.a.38159
33. Heuzé Y, Boyadjiev SA, Marsh JL, et al. New insights into the relationship between suture closure and craniofacial dysmorphology in sagittal nonsyndromic craniosynostosis: Skull shape in isolated sagittal craniosynostosis. *J Anat.* 2010; 217:85–96. [PubMed: 20572900]
34. Heuzé Y, Martínez-Abadías N, Stella JM, et al. Unilateral and bilateral expression of a quantitative trait: asymmetry and symmetry in coronal craniosynostosis. *J Exp Zool B Mol Dev Evol.* 2012; 318(2):109–122.
35. Martínez-Abadías N, Motch SM, Pankratz TL, et al. Tissue-specific responses to aberrant FGF signaling in complex head phenotypes. *Dev Dyn.* 2013; 242(1):80–94. [PubMed: 23172727]
36. Cohen MM Jr, Kreiborg S. A clinical study of the craniofacial features in Apert syndrome. *Int J Oral Maxillofac Surg.* 1996; 25:45–53. [PubMed: 8833300]
37. Cunningham ML, Seto ML, Ratisoontorn C, Heike CL, Hing AV. Syndromic craniosynostosis: from history to hydrogen bonds. *Orthod Craniofac Res.* 2007; 10(2):67–81. [PubMed: 17552943]
38. Johnson D, Wilkie AO. Craniosynostosis. *Eur J Hum Genet.* 2011; 19(4):369–376. [PubMed: 21248745]
39. Nah HD, Koyama E, Agochukwu NB, Bartlett SP, Muenke M. Phenotype profile of a genetic mouse model for Muenke syndrome. *Childs Nerv Syst.* 2012; 28(9):1483–1493. [PubMed: 22872265]
40. Heuzé Y, Martínez-Abadías N, Stella JM, et al. Quantification of facial skeletal shape variation in fibroblast growth factor receptor-related craniosynostosis syndromes: Facial shape in Fgfr-Related craniosynostoses. *Birt Defects Res A Clin Mol Teratol.* 2014; 100(4):250–259.
41. Erten E, Çekmen N. Respiratory and cranial complications during anaesthesia in Pfeiffer syndrome. *Brain Disord Ther.* 2015; 04(04)doi: 10.4172/2168-975X.1000175
42. Barge-Schaapveld DQCM, Brooks AS, Lequin MH, van Spaendonk R, Vermeulen RJ, Cobben JM. Beare-Stevenson syndrome: Two Dutch patients with cerebral abnormalities. *Pediatr Neurol.* 2011; 44(4):303–307. [PubMed: 21397175]
43. Scheid SC, Spector AR, Luft JD. Tracheal cartilaginous sleeve in Crouzon syndrome. *Int J Pediatr Otorhinolaryngol.* 2002; 65(2):147–152. [PubMed: 12176186]
44. Wenger TL, Bhoj EJ, Wetmore RF, et al. Beare-Stevenson syndrome: Two new patients, including a novel finding of tracheal cartilaginous sleeve. *Am J Med Genet A.* 2015; 167(4):852–857.
45. Sharda S, Panigrahi I, Gupta K, Singhi S, Kumar R. A newborn with acanthosis nigricans: Can it be Crouzon syndrome with acanthosis nigricans? *Pediatr Dermatol.* 2010; 27(1):43–47. [PubMed: 20199409]
46. Hassell S, Butler MG. Antley-Bixler syndrome: report of a patient and review of literature. *Clin Genet.* 1994; 46(5):372–376. [PubMed: 7889649]
47. Hosalkar HS, Shah HS, Gujar PS, Shaw BA, et al. The Antley-Bixler syndrome: two new cases. *J Postgrad Med.* 2001; 47(4):252. [PubMed: 11832641]
48. Ron N, Leung S, Carney E, Gerber A, David KL. A case of Beare-Stevenson syndrome with unusual manifestations. *Am J Case Rep.* 2016; 17:254–258. [PubMed: 27079505]
49. Dunmade AD, Ajayi I, Alabi BS, Mokuolu OA, Bolaji BO, Oyinloye OI. Intranasal endoscopic repair of bilateral choanal atresia in a male newborn with Crouzon's syndrome. *East Cent Afr J Surg.* 2015; 20(2):96–101.
50. Machado LE, Osborne NG, Bonilla-Musoles F. Antley-Bixler Syndrome. *J Ultrasound Med.* 2001; 20:73–77. [PubMed: 11149533]
51. Pius S, Ibrahim HA, Bello M, Mbaya K, Ambe JP. Apert syndrome: A case report and review of literature. *Open J Pediatr.* 2016; 06(02):175–184.

52. Shrestha M, Adhikari N, Shah G. Apert syndrome (acrocephalosyndactyly): A rare syndromic craniosynostosis. *J Nepal Paediatr Soc.* 2009; 29(2):92–93.
53. Alpers CE, Edwards MSB. Hemangiomas of bone in Crouzon's syndrome - case report. *Neurosurgery.* 1985; 16(3):391–394. [PubMed: 3982620]
54. Hall BD, Cadle RG, Golabi M, Morris CA, Cohen MM. Beare-Stevenson cutis gyrata syndrome. *Am J Med Genet.* 1992; 44(1):82–89. [PubMed: 1519658]
55. Hsu T-Y, Chang S-Y, Wang T-J, Ou C-Y, Chen Z-H, Hsu P-H. Prenatal sonographic appearance of Beare-Stevenson cutis gyrata syndrome: two- and three-dimensional ultrasonographic findings. *Prenat Diagn.* 2001; 21(8):665–667. [PubMed: 11536267]
56. Ito S, Matsui K, Ohsaki E, et al. A cloverleaf skull syndrome probably of Beare-Stevenson type associated with Chiari malformation. *Brain Dev.* 1996; 18:307–311. [PubMed: 8879651]
57. Kroczeck RA, Mühlbauer W, Zimmermann I. Cloverleaf skull associated with Pfeiffer syndrome: pathology and management. *Eur J Pediatr.* 1986; 145(5):442–445. [PubMed: 3792393]
58. Mathijssen IMJ, Vaandrager JM, Hoogeboom AJM, Hesselink-Janssen ALW, van den Ouweland AMW. Pfeiffer's syndrome resulting from an S351C mutation in the fibroblast growth factor receptor-2 gene. *J Craniofac Surg.* 1998; 9(3):207–209. [PubMed: 9693549]
59. Oyamada MK, Ferreira HSA, Hoff M. Pfeiffer syndrome type 2: case report. *Sao Paulo Med J.* 2003; 121(4):176–179. [PubMed: 14595512]
60. Lo LJ, Chen YR. Airway obstruction in severe syndromic craniosynostosis. *Ann Plast Surg.* 1999; 43(3):258–264. [PubMed: 10490176]
61. Adolphs N, Klein M, Haberl EJ, Graul-Neumann L, Menneking H, Hoffmeister B. Antley-Bixler-Syndrome – Staged management of craniofacial malformations from birth to adolescence – A case report. *J Cranio-Maxillofac Surg.* 2011; 39(7):487–495.
62. Vargas RAP, Maegawa GHB, Taucher SC, et al. Beare-Stevenson syndrome: Two South American patients with *FGFR2* analysis. *Am J Med Genet A.* 2003; 121A(1):41–46. [PubMed: 12900900]
63. Oldridge M, Zackai EH, McDonald-McGinn DM, et al. De novo alu-element insertions in *FGFR2* identify a distinct pathological basis for Apert syndrome. *Am J Hum Genet.* 1999; 64(2):446–461. [PubMed: 9973282]
64. Boynukalın K, Baykal C, Dolar O, Özcan N. Prenatal diagnosis of Apert syndrome: a case report. *Basic Clin Sci.* 2013; 2(4):165–169.
65. Schweitzer DN, Graham JM, Lachman RS, et al. Subtle radiographic findings of achondroplasia in patients with Crouzon syndrome with acanthosis nigricans due to an Ala391Glu substitution in *FGFR3*. *Am J Med Genet.* 2001; 98(1):75–91. [PubMed: 11426459]
66. Suslak L, Glista B, Gertzman GB, Lieberman L, Schwartz RA, Desposito F. Crouzon syndrome with periapical cemental dysplasia and acanthosis nigricans: the pleiotropic effect of a single gene? *Birth Defects Orig Artic Ser.* 1984; 21(2):127–134.
67. Brown OE, Smith T, Armstrong E, Grundfast K. The evaluation of choanal atresia by computed tomography. *Int J Pediatr Otorhinolaryngol.* 1986; 12:85–98. [PubMed: 3818194]
68. Chen JX, Kachniarz B, Gilani S, Shin JJ. Risk of malignancy associated with head and neck CT in children: a systematic review. *Otolaryngol Neck Surg.* 2014; 151(4):554–566.
69. Chen L, Li D, Li C, Engel A, Deng CX. A Ser250Trp substitution in mouse fibroblast growth factor receptor 2 (*Fgfr2*) results in craniosynostosis. *Bone.* 2003; 33(2):169–178. [PubMed: 14499350]
70. Holmes G. Mouse models of Apert syndrome. *Childs Nerv Syst.* 2012; 28(9):1505–1510. [PubMed: 22872267]
71. Mai S, Wei K, Flenniken A, et al. The missense mutation W290R in *Fgfr2* causes developmental defects from aberrant IIIb and IIIc signaling. *Dev Dyn.* 2010; 239(6):1888–1900. [PubMed: 20503384]
72. Twigg SRF, Healy C, Babbs C, et al. Skeletal analysis of the *Fgfr3P244R* mouse, a genetic model for the Muenke craniosynostosis syndrome. *Dev Dyn.* 2009; 238(2):331–342. [PubMed: 19086028]
73. Wang Y. Abnormalities in cartilage and bone development in the Apert syndrome *FGFR2+/S252W* mouse. *Development.* 2005; 132(15):3537–3548. [PubMed: 15975938]

74. Zhou YX, Xu X, Chen L, Li C, Brodle SG, Deng CX. A Pro250Arg substitution in mouse Fgfr1 causes increased expression of Cbfa1 and premature fusion of calvarial sutures. *Hum Mol Genet.* 2000; 9(13):2001–2008. [PubMed: 10942429]
75. Eswarakumar VP, Horowitz MC, Locklin R, Morriss-Kay GM, Lonai P. A gain-of-function mutation of Fgfr2c demonstrates the roles of this receptor variant in osteogenesis. *Proc Natl Acad Sci U S A.* 2004; 101(34):12555–12560. [PubMed: 15316116]
76. Kurosaka H, Wang Q, Sandell L, Yamashiro T, Trainor PA. Rdh10 loss-of-function and perturbed retinoid signaling underlies the etiology of choanal atresia. *Hum Mol Genet.* 2017; 26(7):1268–1279. [PubMed: 28169399]
77. Kelley RI, Kratz LE, Glaser RL, Netzloff ML, Miller Wolf L, Jabs EW. Abnormal sterol metabolism in a patient with Antley-Bixler syndrome and ambiguous genitalia. *Am J Med Genet.* 2002; 110(2):95–102. [PubMed: 12116245]
78. Kumar MR, Bhat BV, Bhatia BD. Apert syndrome with partial post-axial polydactyly and unilateral choanal atresia. *Indian Pediatr.* 1994; 31:869–869.
79. Al-Qattan MM, Al-Husain MA. Classification of hand anomalies in Apert's syndrome. *J Hand Surg Br Eur Vol.* 1996; 21(2):266–268.
80. Park WJ, Theda C, Maestri NE, et al. Analysis of phenotypic features and FGFR2 mutations in Apert syndrome. *Am J Hum Genet.* 1995; 57(2):321. [PubMed: 7668257]
81. Lajeunie E, Cameron R, El Ghouzzi V, et al. Clinical variability in patients with Apert's syndrome. *J Neurosurg.* 1999; 90(3):443–447. [PubMed: 10067911]
82. Upmeyer S, Bothwell M, Tobias JD. Perioperative care of a patient with Beare-Stevenson syndrome. *Pediatr Anesth.* 2005; 15:1131–1136.
83. Too CW, Tang PH. Imaging findings of chronic subluxation of the os odontoideum and cervical myelopathy in a child with Beare-Stevenson cutis gyrata syndrome after surgery to the head and neck. *Ann Acad Med Singap.* 2009; 38(9):832–834. [PubMed: 19816645]
84. Fonseca RF, Costa-Lima MA, Pereira ET, Castilla EE, Orioli IM. Beare-Stevenson cutis gyrata syndrome: A new case of a c.1124C→G (Y375C) mutation in the FGFR2 gene. *Mol Med Rep.* 2008; 1:753–755. [PubMed: 21479481]
85. Yu J, Jeong SY, Yang JA, Park M, Kim H, Yoon S. Genotypic and phenotypic analyses of Korean patients with syndromic craniosynostosis. *Clin Genet.* 2009; 76(3):287–291. [PubMed: 19624690]
86. Beck R, Sertie AL, Brik R, Shinawi M. Crouzon syndrome: Association with absent pulmonary valve syndrome and severe tracheobronchomalacia. *Pediatr Pulmonol.* 2002; 34(6):478–481. [PubMed: 12422346]
87. Okajima K, Robinson LK, Hart MA, et al. Ocular anterior chamber dysgenesis in craniosynostosis syndromes with a fibroblast growth factor receptor 2 mutation. *Am J Med Genet.* 1999; 85(2):160–170. [PubMed: 10406670]
88. Breitbart AS, Eaton C, McCarthy JG. Crouzon's syndrome with acanthosis nigricans: Ramifications for the craniofacial surgeon. *Ann Plast Surg.* 1989; 22(4):310–315. [PubMed: 2650599]
89. Di Rocco F, Collet C, Legeai-Mallet L, et al. Crouzon syndrome with acanthosis nigricans: A case-based update. *Childs Nerv Syst.* 2011; 27(3):349–354. [PubMed: 21136065]
90. Stoler JM, Rosen H, Desai U, Mulliken JB, Meara JG, Rogers GF. Cleft palate in Pfeiffer syndrome. *J Craniofac Surg.* 2009; 20(5):1375–1377. [PubMed: 19816260]

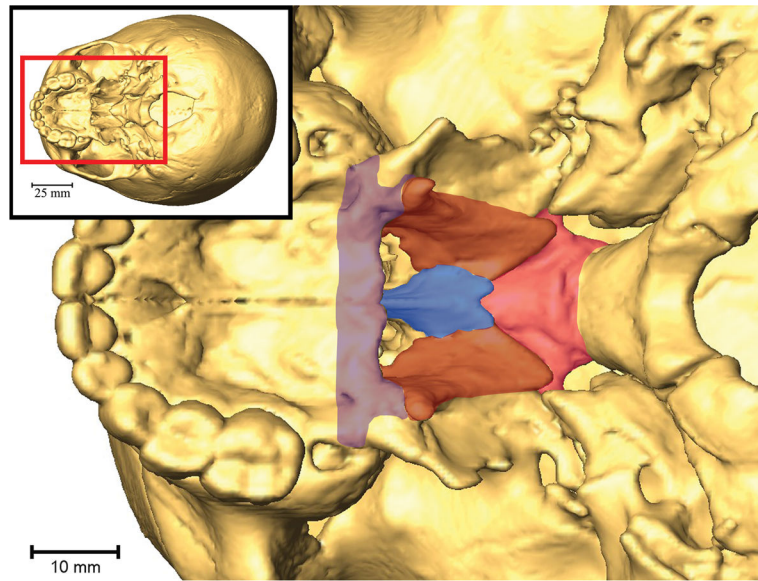


Figure 1. 3DCT reconstruction of the cranium of a typically developing child viewed from below showing the osteological borders of the choanae: vomer (blue), sphenoid body (pink), medial pterygoid plates (red), and horizontal plates of the palatine bones (purple).

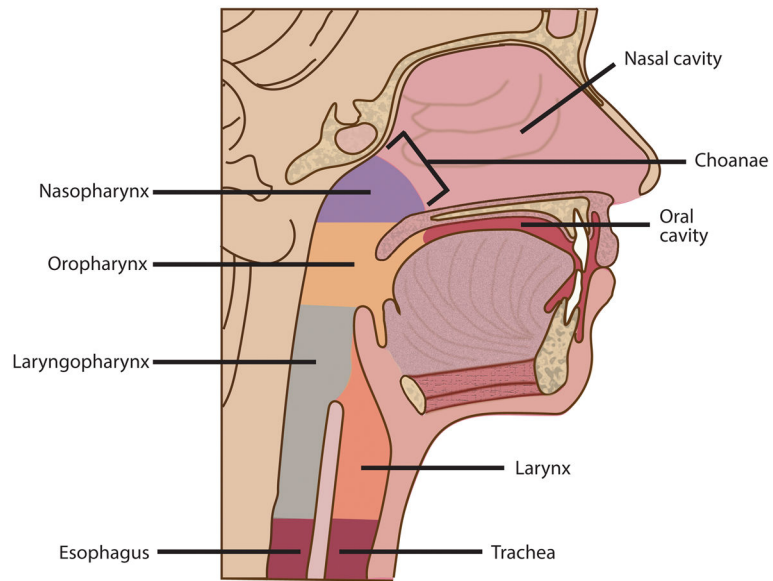


Figure 2. Mid-sagittal section of adult human showing the position of the choanae relative to the human nasal, oral, and pharyngeal airways.

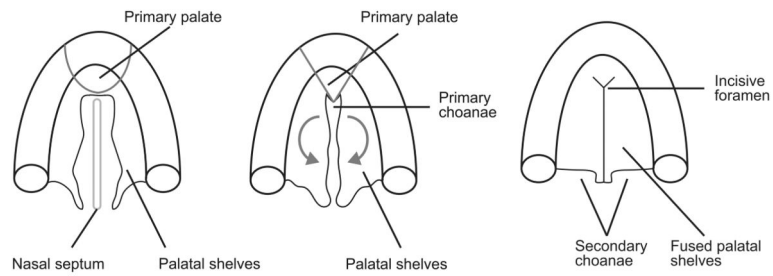


Figure 3.

Formation of the secondary palate and choanae. Inferior view of the forming palate showing (left) vertically oriented palatal shelves, (center) the palatal shelves as they rotate downward into a horizontal position and begin to approximate one another to form the primary choanae, and (right) fused palatal shelves in their final orientation, with the incisive foramen at the intersection of the primary and secondary palate and the secondary, or definitive, choanal openings at the posterior end of the palate. (Adapted from 3)

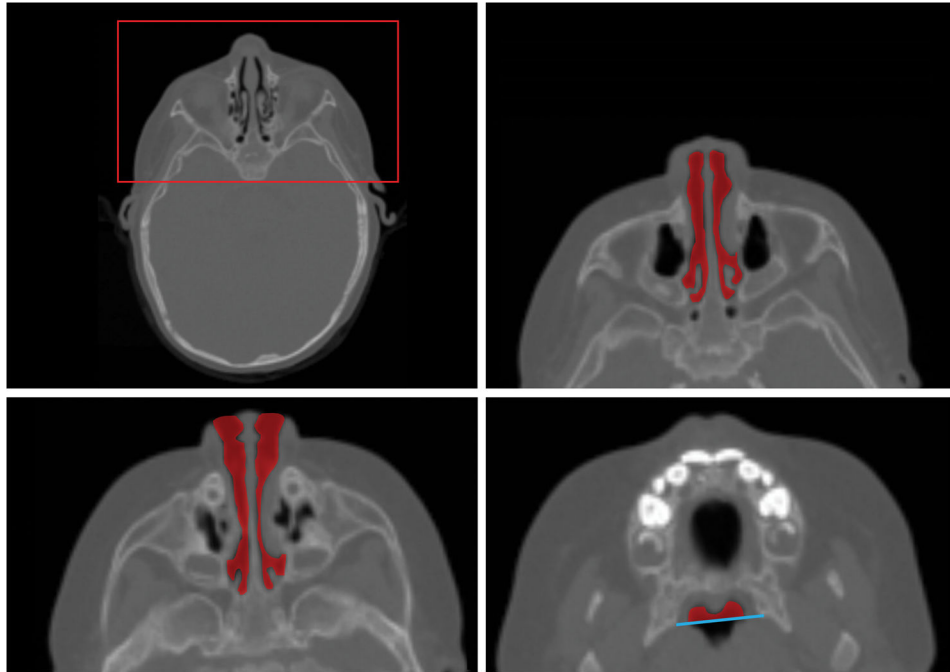


Figure 4. Nasal airway segmented from CT image of a typically developing child at 10 months, as an example of how the nasal airway volume data presented in Figure 5 were collected. Top Left) Axial CT image at the level of the orbits indicating area of close-up (red box) for three additional anatomical levels including: Top Right) the nasal cavity (red) with soft tissue of the nose bordering the anterior nares at the level of the maxillary sinuses; Bottom Left) mid-nares level with partial soft tissue border of the anterior nares; and Bottom Right) at the level of the alveolar processes of the maxillae showing the nasopharyngeal lumen (red) anterior to a line (blue) connecting the most posterior points on the medial plates of the pterygoid bone.

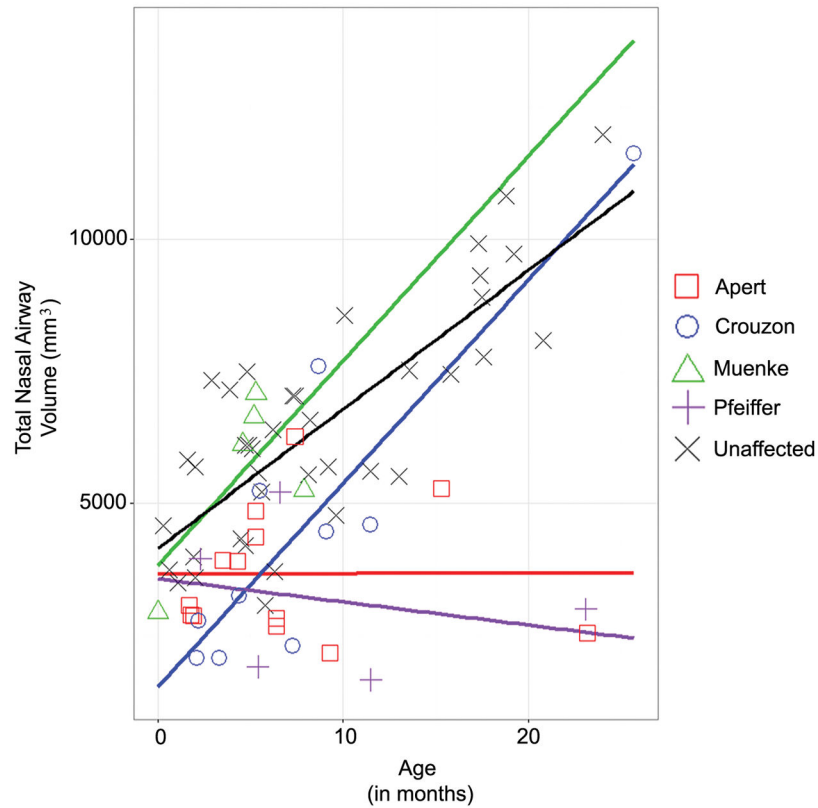


Figure 5.

Scatterplot of total nasal airway volume and age (in months) of individuals diagnosed with various craniosynostosis syndromes and typically developing individuals. Sample sizes are as follows: Apert ($n = 13$), Crouzon ($n = 10$), Muenke ($n = 5$), Pfeiffer ($n = 5$), unaffected ($n = 39$). Lines representing the results of regression analysis showing the relationship between age and total nasal airway volume (including the ethmoidal air cells) for each group. It is important to note that this plot and the regression lines estimated from the cross-sectional data are used to demonstrate the variation in nasal airway volumes among craniosynostosis syndromes. As the nasal airway volume data are based on cross-sectional datasets for each diagnostic category, these regression lines do not necessarily indicate growth patterns or growth trajectories.

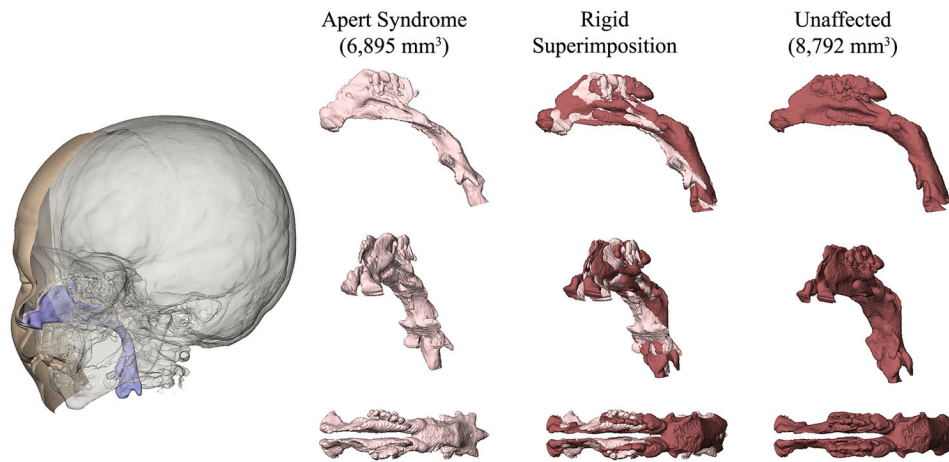


Figure 6.

3DCT reconstruction of a typically developing child (left) showing superimposed segmentations of skin surface (beige), brain surface (grey) and upper airway lumen (blue). At right are “virtual endocasts” of the nasopharynx of a child with Apert syndrome (pink, at left) and a typically developing child (maroon, at right) as segmented from high resolution 3DCT. Superimposition of the two virtual endocasts (center) shows local areas of greatest shape difference. This comparison is not a statistical comparison of the nasopharyngeal anatomy of patients with Apert syndrome and typically developing individuals; rather, this superimposition provides an example of how nasopharyngeal morphology of craniosynostosis patients may differ from typically developing individuals.

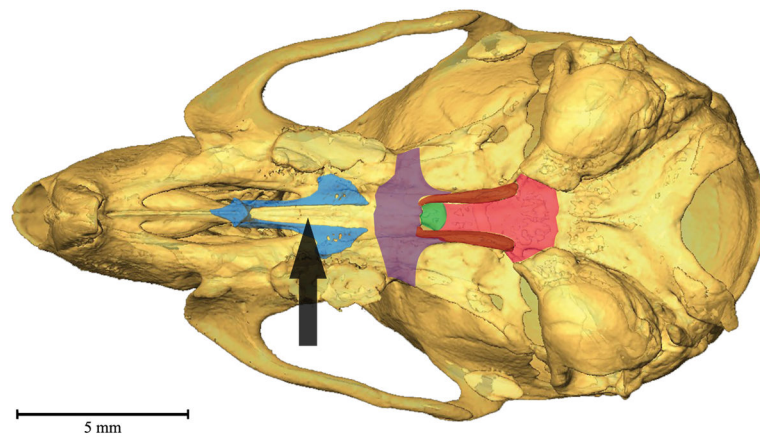


Figure 7.

3DCT reconstruction of the cranium of 6 week old C57BL/6J mouse showing the bones that form the osteological borders of the choanae in the human skull: vomer (blue), basisphenoid (pink), medial pterygoid plates (red), and horizontal plates of the palatine bones (purple). The vomer (which is ghosted in this illustration) lies deep to the maxillae and so is hidden in an inferior view. The presphenoid is shown in green. Note the anatomical separation of these bones compared to the human skull in Figure 1. The black arrow indicates the position of the choanae in mice at the soft tissue intersection of the posterior nasal cavity and nasopharynx.

Table 1

Case reports that explicitly diagnose syndromic craniosynostosis and choanal atresia. NR=not reported.

Gene	Mutation	Diagnosis	Calvarial Sutures	Choanal atresia/stenosis	Method of Evaluation	Citation
NR	NR	Antley-Bixler	Lambdoid	Unilateral atresia	NR	77
NR	NR	Antley-Bixler	Metopic	Choanal atresia	Doppler; autopsy	50
NR	NR	Antley-Bixler	NR	Unilateral right atresia and left stenosis	CT	46
NR	NR	Antley-Bixler	Coronal	Bilateral atresia	CT	47
NR	NR	Antley-Bixler	Coronal	Unilateral atresia	Imaging	47
NR	NR	Antley-Bixler	Coronal, metopic	Bilateral atresia	Surgical intervention	61
NR	NR	Apert	Coronal	Unilateral atresia and stenosis	NR	78
NR	NR	Apert	Coronal	Bilateral atresia	NR	79
NR	NR	Apert	Coronal	Unilateral atresia	Choanography; surgical intervention	51
NR	NR	Apert	Multiple	Bilateral atresia	Inability to cannulate	52
FGFR2	NR	Apert	Coronal	Bilateral atresia	Surgical intervention	64
FGFR2	S252W	Apert	NR	“Choanal stenosis/atresia”	NR	80
FGFR2	S252W	Apert	Coronal, lambdoid	Choanal atresia	NR	81
FGFR2	S252W	Apert	NR	Choanal atresia	NR	81
FGFR2	S252W	Apert	NR	Choanal atresia	NR	81
FGFR2	P253R	Apert	NR	Choanal atresia	NR	81
FGFR3	P253R	Apert	NR	“Choanal stenosis/atresia”	NR	79
FGFR2	Alu insertion	Apert	NR	Choanal atresia	Surgical intervention	63
NR	NR	Beare-Stevenson	Coronal, lambdoid, squamous	Choanal atresia	NR	54
NR	NR	Beare-Stevenson	Coronal, lambdoid, sagittal	Bilateral atresia	Surgical intervention	54
NR	NR	Beare-Stevenson	Coronal, lambdoid, sagittal	Choanal atresia	NR	54
NR	NR	Beare-Stevenson	Coronal, lambdoid, sagittal	Choanal atresia	NR	54
NR	NR	Beare-Stevenson	Cloverleaf	Choanal atresia	NR	55
NR	NR	Beare-Stevenson	Cloverleaf	Choanal atresia	NR	56
NR	NR	Beare-Stevenson	NR	Choanal atresia	NR	82
NR	NR	Beare-Stevenson	NR	Choanal atresia	NR	83
FGFR2	Tyr375Cys	Beare-Stevenson	Cloverleaf	Bilateral atresia	CT	42
FGFR2	Tyr375Cys	Beare-Stevenson	Cloverleaf	Unilateral atresia	NR	42

Gene	Mutation	Diagnosis	Calvarial Sutures	Choanal atresia/stenosis	Method of Evaluation	Citation
FGFR2	Tyr375Cys	Beare-Stevenson	Cloverleaf	Choanal atresia	NR	84
FGFR2	Tyr375Cys	Beare-Stevenson	Coronal, sagittal, lambdoid	Bilateral atresia	Surgical intervention	62
FGFR2	Tyr375Cys	Beare-Stevenson	Cloverleaf	Choanal stenosis with possible atresia	CT	44
FGFR2	Tyr375Cys	Beare-Stevenson	Multiple	Choanal atresia	NR	85
FGFR2	Tyr375Cys	Beare-Stevenson	None	Bilateral atresia	CT	48
NR	NR	Crouzon	NR	Unilateral right atresia and left stenosis	CT	43
NR	NR	Crouzon	Cloverleaf	Bilateral atresia	Pharyngiogram	53
NR	NR	Crouzon	NR	Bilateral atresia	CT	49
NR	NR	Crouzon	NR	Unilateral right atresia and left stenosis	Surgical intervention	60
FGFR2	Cys342Tyr	Crouzon	Coronal, lambdoid, sagittal	Unilateral atresia	NR	86
FGFR2	Cys342Tyr	Crouzon	Coronal	Choanal atresia	NR	85
FGFR2	Ser351Cys	Crouzon	Cloverleaf	Bilateral atresia	NR	87
NR	NR	Crouzon with acanthosis nigricans	Coronal, sagittal	Bilateral atresia	Surgical intervention	66
NR	NR	Crouzon with acanthosis nigricans	Coronal	Choanal atresia	NR	88
NR	NR	Crouzon with acanthosis nigricans	Coronal, sagittal	Choanal atresia	NR	88
FGFR3	Ala391Glu	Crouzon with acanthosis nigricans	Coronal	"Incomplete" choanal atresia	NR	20
FGFR3	Ala391Glu	Crouzon with acanthosis nigricans	NR	Choanal atresia (narrowed nasal passage)	NR	19
FGFR3	Ala391Glu	Crouzon with acanthosis nigricans	Cloverleaf/multiple sutures	Unilateral atresia and stenosis	Surgical intervention	65
FGFR3	Ala391Glu	Crouzon with acanthosis nigricans	Multiple	Unilateral atresia and stenosis	Surgical intervention	65
FGFR3	Ala391Glu	Crouzon with acanthosis nigricans	Coronal	Choanal atresia	NR	89
FGFR3	Ala391Glu	Crouzon with acanthosis nigricans	Cloverleaf	Bilateral atresia	CT	45
NR	NR	Pfeiffer	Coronal, lambdoid, sagittal	Bilateral atresia	NR	57
NR	NR	Pfeiffer	Cloverleaf	Choanal atresia	NR	59
NR	NR	Pfeiffer	NR	Choanal atresia/stenosis	NR	90
NR	NR	Pfeiffer	Cloverleaf	Choanal atresia/hypoplasia	NR	41
FGFR2	Ser351Cys	Pfeiffer	Coronal	Choanal atresia	NR	58