



HAL
open science

TAVI: Simplification Is the Ultimate Sophistication

Mariama Akodad, Thierry Lefèvre

► **To cite this version:**

Mariama Akodad, Thierry Lefèvre. TAVI: Simplification Is the Ultimate Sophistication. *Frontiers in Cardiovascular Medicine*, 2018, 5, pp.96. 10.3389/fcvm.2018.00096 . hal-02317671

HAL Id: hal-02317671

<https://hal.science/hal-02317671>

Submitted on 8 Jun 2021

HAL is a multi-disciplinary open access archive for the deposit and dissemination of scientific research documents, whether they are published or not. The documents may come from teaching and research institutions in France or abroad, or from public or private research centers.

L'archive ouverte pluridisciplinaire **HAL**, est destinée au dépôt et à la diffusion de documents scientifiques de niveau recherche, publiés ou non, émanant des établissements d'enseignement et de recherche français ou étrangers, des laboratoires publics ou privés.



Distributed under a Creative Commons Attribution 4.0 International License



TAVI: Simplification Is the Ultimate Sophistication

Mariama Akodad^{1,2} and Thierry Lefèvre^{1*}

¹ Ramsay Générale de Santé, Institut Cardiovasculaire Paris Sud, Massy, France, ² Centre Hospitalier Universitaire Arnaud de Villeneuve, Montpellier, France

OPEN ACCESS

Edited by:

Darren Mylotte,
National University of Ireland Galway,
Ireland

Reviewed by:

Marco Barbanti,
Università degli Studi di Catania, Italy
Andrew Roy,
Mater Private Hospital, Ireland, Ireland
Alexander Lauten,
Charité Universitätsmedizin Berlin,
Germany
Gidon Yehuda Perlman,
Hadassah Medical Center, Israel

*Correspondence:

Thierry Lefèvre
t.lefevre@icps.com.fr

Specialty section:

This article was submitted to
Structural Interventional Cardiology,
a section of the journal
Frontiers in Cardiovascular Medicine

Received: 10 March 2018

Accepted: 29 June 2018

Published: 18 July 2018

Citation:

Akodad M and Lefèvre T (2018) TAVI:
Simplification Is the Ultimate
Sophistication.
Front. Cardiovasc. Med. 5:96.
doi: 10.3389/fcvm.2018.00096

Since its introduction in 2002, TAVI has evolved dramatically and is now standard of care for intermediate risk patients when the femoral approach can be implemented safely. The development of innovative transcatheter heart valves (THVs) and refinement of technical skills have contributed to the decrease in complication rates associated with TAVI⁴. Increased experience, smaller sheaths, rigorous pre-procedural planning and improved vascular closing techniques have resulted in markedly lower rates of vascular complications. The next step is the simplification of the procedure, which should contribute to a further decrease in complications, and also reduce procedural time, hospital stay as well as staff workload and costs. Moving to conscious sedation, no predilatation, no temporary pace maker and use of the radial approach as the contralateral approach are all instrumental in achieving this ultimate refinement.

Keywords: TAVI, simplification, minimalist, vascular complications, temporary pace maker, hospital stay duration

INTRODUCTION

Since the first successful procedure was carried out in 2002 (1), transcatheter aortic valve implantation (TAVI) has gradually been established as an alternative to conventional surgery in patients with severe aortic stenosis contra-indicated to surgery or at high surgical risk (2). In 2017, during the last ESC meeting, TAVI indications were extended to intermediate risk patients when the transfemoral approach (TFA) is feasible (3).

Improvements in technique, devices, operator's experience, and patient selection have contributed to a dramatic decrease in procedural complications, thus allowing further technical simplification at every step of the procedure (4–9). In this paper, our aim is to describe how to simplify the technique at each stage of the procedure in order to turn it into a “PCI-like” procedure and to discuss how this may improve TAVI outcomes.

PRE-PROCEDURAL EVALUATION AND PROCEDURAL SETTING

Patient clinical and anatomical criteria may influence per- and post- procedural outcomes. Therefore, a truly minimalist approach should be considered only when femoral access is possible. Recently, Barbalios et al. compared minimalist TAVI performed in the catheterization laboratory to standard TAVI performed in the hybrid room demonstrating shorter procedure and intensive care unit time, as well as reduced hospitalization duration and costs in the minimalist approach group without differences in terms of short- and long-term survival (10).

Multislice CT (MSCT) is instrumental in procedural simplification. Image quality and optimal analysis are therefore crucial for anticipating the potential difficulty of the procedure as well as for optimal valve selection and working view. The role of MSCT has also been central in allowing a shift from general anesthesia to conscious sedation by obviating the need for transesophageal echocardiography (TOE) during the procedure. MSCT became the gold standard for evaluation of the aortic root in our center in 2009.

The use of the TRA for preprocedural evaluation of the coronary arteries is also part of the simplification process. It helps not only to reduce the risk of vascular complications related to the screening phase, but also to assess femoral access by performing a selective bilateral iliac injection using a long multipurpose catheter. Recently, screening of coronary artery disease and ad hoc percutaneous coronary intervention (PCI) during TAVI has been described by Barbanti et al. showing to be feasible without increased periprocedural complications (11).

A minimalist approach can be performed in routine practice with two operators, two nurses and an anesthesiologist (Figure 1). A cardiac surgeon and an echocardiographer are not mandatory in the room but should be available.

FROM GENERAL ANESTHESIA TO CONSCIOUS SEDATION

Although the first in-man TAVI cases in Rouen were initially performed on conscious sedation (1), the procedure was commonly carried out under general anesthesia between 2002 and 2008 in Europe. It remains standard practice in the majority of cases in North America (12). However, it was Alain Cribier's idea that TAVI should be a "PCI-like" procedure. Potential advantages of general anesthesia are patient's procedural comfort, possibility of using TOE and rapid conversion to surgery when complications occur (13–15). Conversely, many issues are related to general anesthesia such as hemodynamic instability, higher need for inotropic drugs, higher risk of bleeding, increased risk of pulmonary infection, extubation difficulty or delay in patients with chronic pulmonary disease, late complication identification such as stroke or aortic complications and finally, longer procedural duration, hospital stay, higher staff workload, and global costs (16–18). In the France 2 and the France TAVI registries, the adoption of local anesthesia with conscious sedation has progressively increased from 30% in 2010 to 70% in 2017 (15, 19). In a recent meta-analysis, outcomes of both approaches were similar with respect to in-hospital mortality, conversion to open-heart surgery, major vascular complications, acute kidney failure and stroke (17). Cross-over to general anesthesia was observed in only 6%. Conversely, catecholamine requirement and transfusion were less frequent in patients on conscious sedation, and duration of intensive care unit and

global hospital stay was also shorter (17, 20, 21). No difference concerning neurocognitive outcomes was highlighted between both approaches (21).

Data from registries demonstrated the feasibility, safety, and cost-effectiveness of local anesthesia with conscious sedation in comparison to general anesthesia, with potential advantages in terms of bleeding and hospitalization length. It has been adopted as the default approach in our center since April 2009.

FROM SURGICAL CUT DOWN TO PERCUTANEOUS ACCESS

Initially, TAVI procedures were performed exclusively via surgical cut down (1). Over the past decade, sheath diameter has been gradually reduced to 14–16 French with the last generation percutaneous heart valves (Figure 2). TFA is currently the default access route, with superior outcomes than transapical route and other transvascular approaches as carotid, aortic, axillary, and caval-aortic. Alternative transvascular routes may be considered only in case of unsuitable femoral access (22).

Percutaneous closure has been progressively adopted in routine practice in most centers for TF TAVI procedures (23). Indeed, even though the surgical approach has been reported to be associated with a low rate of vascular complications and to provide a more direct control of haemostasis (24), percutaneous closure is a less invasive technique and may result in shorter hospital stay (25). With the refinement of the TAVI procedure, better patient preprocedural screening, increased operator experience, and device improvement, the percutaneous approach has become more simple, less time consuming, thus allowing a reduction in staff workload. The Prostar technique was introduced in our center in 2009 and we moved progressively to Proglide (Abbott Vascular Devices, Redwood City, CA, United States) preclosing in 2015–2016 (26) because this technique was simpler and less costly. In 2016, a lower risk of vascular complications was reported with the use of 2 Proglide devices in comparison with Prostar (27). New collagen-based closure devices were recently described in TAVI procedure as the MANTA closure device with similar results than suture based closure devices (28).

In addition to the selection of the most appropriate percutaneous device, the percutaneous technique should be rigorous in order to limit access site complications. Indeed, the common femoral artery puncture site should be carefully selected on the CT-scan or angiography before the procedure. During the procedure, puncture should be performed under angiographic or ultra-sound guidance at the center of the anterior arterial wall (29). Percutaneous closure devices should be subsequently deployed as previously described (30).

Thus, percutaneous transfemoral access is as safe as the surgical approach and feasible in the majority of cases with a very high rate of success after the learning phase. Most vascular complications can be managed percutaneously. It is an essential component of TAVI's simplification process allowing early discharge.

Abbreviations: BAV, balloon aortic valvuloplasty; CCU, conventional cardiology unit; ICU, intensive care unit; LV, left ventricle; MP, multipurpose; MSCT, multislice CT; PCI, percutaneous coronary intervention; TAVI, transcatheter aortic valve implantation; TFA, transfemoral approach; TOE, transesophageal echocardiography; TRA, transradial approach.

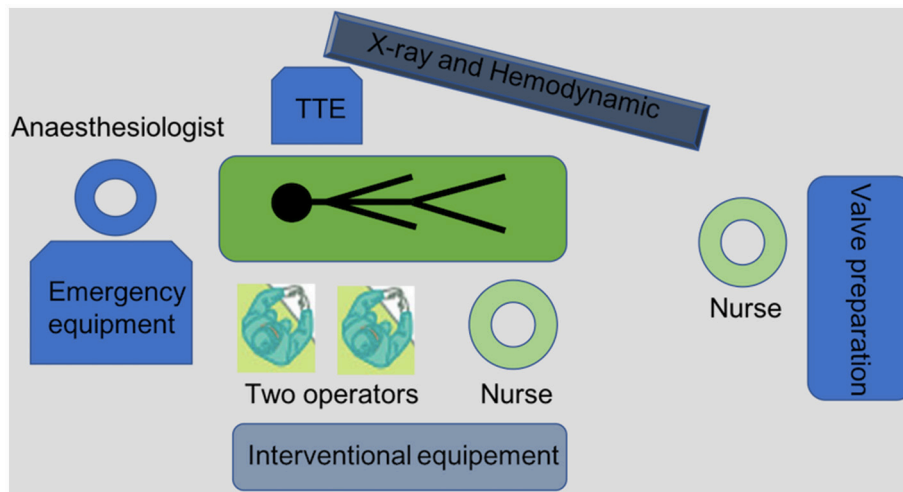


FIGURE 1 | Equipment and procedural set-up for a "minimalist" TAVI procedure.

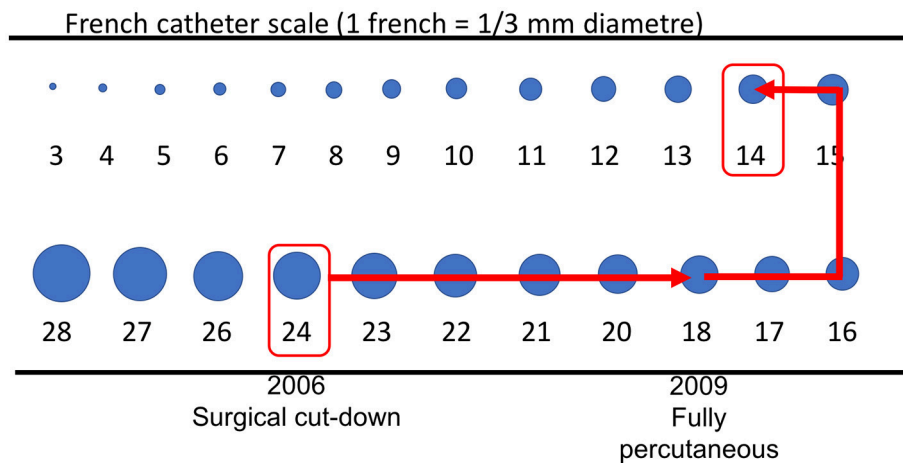


FIGURE 2 | Sheath size from first to last generation devices.

FROM CONTRALATERAL FEMORAL ACCESS TO RADIAL ACCESS

Although vascular complications dramatically decreased in parallel with enhanced operator experience, availability of low profile sheaths and better patient selection, 25–30% of these complications occurred at the contralateral femoral access site, (9). Therefore, using the TRA as a secondary access appears to be very promising (29–31). We have been using this approach since 2016 and have observed a 50% reduction in vascular complications. The radial artery (right or left) is punctured and a 40 cm 6 Fr hydrophilic sheath with a side port for blood pressure measurement is subsequently inserted through the radial artery. A 125 4 or 5 Fr multipurpose (MP) catheter is advanced over a standard 0.35 guide wire to the common iliac artery in order to obtain a reference image and guide the puncture. After the puncture, the MP catheter is retrieved and a pig-tail is advanced

in the ascending aorta via the 0.35 guide wire to perform aortography before and after TAVI. At the end of the procedure, prior to access closure, the MP catheter is re-advanced to the common femoral artery in order to check the final result of the closure (29). In cases of vascular complication, a long 120 cm 5 Fr catheter (Optimed, Germany) can be positioned in the common femoral artery to perform femoral artery balloon inflation or stent implantation. In rare cases where a covered stent is needed, a larger balloon can be used through the Optimed catheter in order to close temporarily the iliac or femoral artery, while a cross-over femoral approach is implemented (29). Indeed, in our practice, even if the radial secondary access is our default approach, the contralateral femoral access should be available immediately in case of failure or emergent need of cross-over.

Therefore, by reducing contralateral vascular complications and simplifying the procedure, TRA will probably follow the predominant tendency observed in other interventional

cardiology settings and become the gold standard contralateral approach for TAVI.

FROM VENOUS STIMULATION TO LV GUIDE WIRE PACING

During balloon valvuloplasty (BAV) or balloon expandable TAVI procedures, rapid ventricular pacing is mandatory. Traditionally, rapid pacing is performed through a venous access with temporary pacemaker implantation (1). However, this technique may be challenging in anatomic variations and may lead to increased X-ray exposure and complications (32) such as hematoma, arterio-venous fistula, thrombosis or right ventricle perforation. Recently, rapid ventricular pacing through the left ventricle guide wire has been described as a way of simplifying the procedure by eliminating the need for additional vascular access during TAVI (33). This approach was adopted in 2016 in our center. Briefly, a 22G needle is inserted subcutaneously near the femoral sheath. Alligator clips are then connected to the left ventricle guide wire (negative clip) and to the needle (positive clip) following insertion of the delivery system close to the aortic valve. The rapid pacing is then tested using maximal output and minimal sensitivity (Figure 3). Valve implantation is then carried out under rapid pacing. In the presence of high-degree conduction disturbance, stimulation can be performed with this technique while a temporary pacemaker is inserted through a venous access, more frequently through brachial vein access to limit femoral vascular complications.

This new technique has been shown to be feasible and safe, allowing stable stimulation with a low rate of complications and a potential reduction in procedural time. A randomized trial comparing left ventricle guide wire rapid pacing to conventional pacing (Easy TAVI) is ongoing in France (NCT02781896).

VALVE IMPLANTATION WITHOUT PREDILATION

In the early days of TAVI, BAV was considered a mandatory step. However BAV have been shown to be associated with a higher risk of cerebral embolization, and severe acute aortic regurgitation may occur after predilatation in up to 3% of cases. TAVI without BAV was evaluated for the first time in 2011 by Gröbe et al. (34) and was shown to be feasible in non-randomized studies (35, 36).

Currently, improvements in new generation devices including paravalvular skirts, the ability of repositioning of the valve, lower profile of delivery system, and of the prosthesis provide more favorable outcomes (22). Therefore, BAV seems no longer essential during TAVI procedures, and consequently, TAVI without predilatation is routinely implemented in many centers.

We moved progressively to this approach between 2012 and 2015 in our center. Today, more than 90% of cases are performed without predilatation. Only very complex anatomies or highly calcified valves are predilated before valve deployment (5–10%). Post dilatation is performed mainly after self-expandable valve deployment in the presence of significant paravalvular leak or transvalvular gradient (10–15%).

Thus, avoiding balloon predilatation may reduce complication rates, decrease the need for permanent pacemaker and reduce procedural time. A large randomized trial (37) with the Sapien 3 valve is on-going in France (NCT02729519).

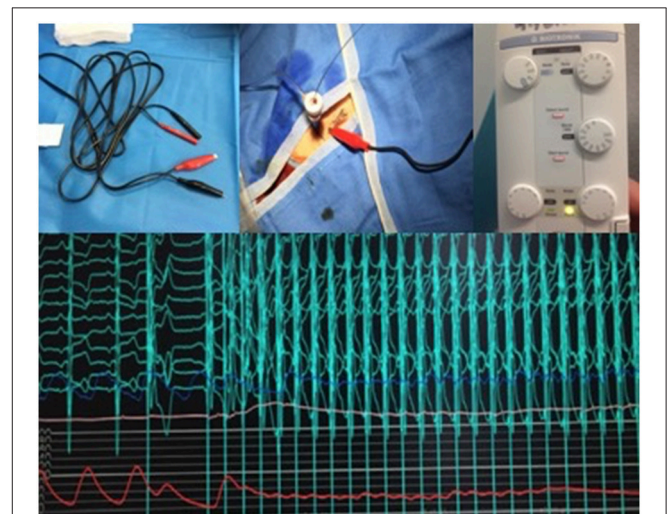


FIGURE 3 | From left to right and up to down: Alligator clips with negative clip (black) and positive clip (red). After insertion of Sheath, a 22G needle is inserted subcutaneously through the skin, close to the femoral sheath and the positive clip is connected to the needle while the negative clip is connected to the guidewire. Setting of the temporary pacemaker with maximal output and minimal sensitivity. Pacing efficacy at 180 beats per minute with the LV wire and drop in blood pressure.

TABLE 1 | Current outcomes of early discharge after TAVI.

Study	Patients	Early discharge, n (%)	Timing of early discharge	30-days mortality, n (%)	Rehospitalization within 30-days, n (%)
Durand et al. (40)	337	121 (36)	Within 3 days	0 (0)	4 (3.3)
Noad et al. (41)	120	26 (21.7)	Same/next day	0 (0)	1 (3.84)
Serletis-Bizios et al. (42)	130	76 (59)	Within 3 days	1 (1.3)	3 (3.94)
Lauck et al. (43)	393	150 (38.2)	Within 2 days	1 (0.7)	12 (8)

POST-PROCEDURE MANAGEMENT: From Intensive Care Unit (ICU) to Conventional Cardiology Unit (CCU)

After TAVI, systematic close monitoring with special attention to hemodynamic and cardiac rhythm is mandatory to allow early detection of periprocedural complications. In many centers, monitoring is performed for at least 12 to 24 h in the ICU before transferring the patient to a CCU after clinical and paraclinical status re-assessment. Recently, TAVI without subsequent ICU admission has been evaluated and has been shown to be feasible and safe in selected patients after rigorous preprocedural and postprocedural evaluation (38). Indeed, this new strategy adopted in our center in 2017 may obviate ICU admission in up to one third of cases and should be considered a part of the “minimalist” approach.

Short Hospitalization

Early discharge was evaluated in the literature demonstrating safety in patients with hospitalization duration shorter than 48 h (39). Indeed, the median length of hospitalization was 1 day in the early discharge group with no differences between early discharge and discharge after 48 h in terms of 1-month mortality, stroke and readmission. A “minimalistic” TAVI procedure with local anesthesia, no predilatation, urinary catheter avoidance

and early removal of temporary pacemaker was predictive of early discharge in this study. Current outcomes of early discharge after TAVI are summarized in **Table 1**. Shortening hospital stay is also an essential component of the TAVI simplification process with a potential reduction in procedural costs and need for rehabilitation but may be studied in large studies to ensure safety without increased risk of outcomes or readmission.

CONCLUSION

TAVI simplification has already been adopted in routine practice in experienced centers, resulting in a low rate of complications, shorter procedural time, improved patient comfort, as well as decreased costs and staff workload. However, rigorous patient selection, and risk stratification are key factors in ensuring successful “PCI-like” procedures. On-going randomized trials may confirm preliminary results, thus leading to a “simple” but not “simpler” procedure in the near future with lower profile devices.

AUTHOR CONTRIBUTIONS

All authors listed have made a substantial, direct and intellectual contribution to the work, and approved it for publication.

REFERENCES

- Cribier A, Eltchaninoff H, Bash A, Borenstein N, Tron C, Bauer F, et al. Percutaneous transcatheter implantation of an aortic valve prosthesis for calcific aortic stenosis: first human case description. *Circulation* (2002) 106:3006–8. doi: 10.1161/01.CIR.0000047200.36165.B8
- Vahanian A, Alferi O, Andreotti F, Antunes MJ, Barón-Esquivias G, Baumgartner H, et al. Guidelines on the management of valvular heart disease (version 2012): the Joint Task Force on the Management of Valvular Heart Disease of the European Society of Cardiology (ESC) and the European Association for Cardio-Thoracic Surgery (EACTS). *Eur J Cardiothorac Surg* (2012) 42:S1–44. doi: 10.1093/ejcts/ezs455
- Baumgartner H, Falk V, Bax JJ, De Bonis M, Hamm C, Holm PJ, et al. ESC Scientific Document Group. ESC/EACTS Guidelines for the management of valvular heart disease. *Eur Heart J*. (2017) 38:2739–91. doi: 10.1093/eurheartj/ehx391
- Auffret V, Lefèvre T, Van Belle E, Eltchaninoff H, Iung B, Koning R, et al. Temporal trends in transcatheter aortic valve replacement in France: FRANCE 2 to FRANCE TAVI. *JACC* 70:42–55. doi: 10.1016/j.jacc.2017.04.053
- Durand E, Borz B, Godin M, Tron C, Litzler PY, Bessou JP, et al. Transfemoral aortic valve replacement with the Edwards SAPIEN and Edwards SAPIEN XT prosthesis using exclusively local anesthesia and fluoroscopic guidance: feasibility and 30-day outcomes. *JACC Cardiovasc Interv*. (2012) 5:461–7. doi: 10.1016/j.jcin.2012.01.018
- Landes U, Barsheshet A, Finkelstein A, Guetta V, Assali A, Halkin A, et al. Temporal trends in transcatheter aortic valve implantation, 2008–2014: patient characteristics, procedural issues, and clinical outcome. *Clin Cardiol*. (2017) 40:82–8. doi: 10.1002/clc.22632
- Vahl TP, Kodali SK, Leon MB. Transcatheter aortic valve replacement 2016: a modern-day “Through the Looking-Glass” Adventure. *JACC* (2016) 67:1472–87. doi: 10.1016/j.jacc.2015.12.059
- Kodali S, Thourani VH, White J, Malaisrie SC, Lim S, Greason KL, et al. Early clinical and echocardiographic outcomes after SAPIEN 3 transcatheter aortic valve replacement in inoperable, high-risk and intermediate-risk patients with aortic stenosis. *Eur Heart J*. (2016) 37:2252–62. doi: 10.1093/eurheartj/ehw112
- Allende R, Urena M, Cordoba JG, Ribeiro HB, Amat-Santos I, DeLarochelière R, et al. Impact of the use of transradial versus transfemoral approach as secondary access in transcatheter aortic valve implantation procedures. *Am J Cardiol*. (2014) 114:1729–34. doi: 10.1016/j.amjcard.2014.09.009
- Babalarios V, Devireddy C, Lerakis S, Leonardi R, Iturra SA, Mavromatis K, et al. Comparison of transfemoral transcatheter aortic valve replacement performed in the catheterization laboratory (minimalist approach) versus hybrid operating room (standard approach): outcomes and cost analysis. *JACC Cardiovasc Interv*. (2014) 7:898–904. doi: 10.1016/j.jcin.2014.04.005
- Barbanti M, Todaro D, Costa G, Pilato G, Picci A, Gulino S, et al. Optimized screening of coronary artery disease with invasive coronary angiography and Ad Hoc percutaneous coronary intervention during transcatheter aortic valve replacement. *Circ Cardiovasc Interv*. (2017) 10:e005234. doi: 10.1161/CIRCINTERVENTIONS.117.005234
- Rodés-Cabau J, Webb JG, Cheung A, Ye J, Dumont E, Feindel CM, et al. Transcatheter aortic valve implantation for the treatment of severe symptomatic aortic stenosis in patients at very high or prohibitive surgical risk: acute and late outcomes of the multicenter Canadian experience. *JACC* (2010) 55:1080–90. doi: 10.1016/j.jacc.2009.12.014
- Villablanca PA, Mohanany D, Nikolic K, Bangalore S, Slovut DP, Mathew V, et al. Comparison of local versus general anesthesia in patients undergoing transcatheter aortic valve replacement: a meta-analysis. *Catheter Cardiovasc Interv*. (2018) 91:330–42 doi: 10.1002/ccd.27207
- Maas EHA, Pieters BMA, Van de Velde M, Rex S. General or local anesthesia for TAVI? a systematic review of the literature and meta-analysis. *Curr Pharm Des*. (2016) 22:1868–78. doi: 10.2174/1381612822666151208121825
- Oguri A, Yamamoto M, Mouillet G, Gilard M, Laskar M, Eltchaninoff H, et al. FRANCE 2 Registry Investigators. Clinical outcomes and safety of transfemoral aortic valve implantation under general versus local anesthesia: subanalysis of the French Aortic National CoreValve and Edwards 2 registry. *Circ Cardiovasc Interv*. (2014) 7:602–10. doi: 10.1161/CIRCINTERVENTIONS.113.000403

16. Fröhlich GM, Lansky AJ, Webb J, Roffi M, Toggweiler S, Reinthaler M, et al. Local versus general anesthesia for transcatheter aortic valve implantation (TAVR) – systematic review and meta-analysis. *BMC Med.* (2014) 12: 41. doi: 10.1186/1741-7015-12-41
17. Ehret C, Rossaint R, Foldenauer AC, Stoppe C, Stevanovic A, Dohms K, et al. Is local anaesthesia a favourable approach for transcatheter aortic valve implantation? A systematic review and meta-analysis comparing local and general anaesthesia. *BMJ Open* (2017) 7:e016321. doi: 10.1136/bmjopen-2017-016321
18. Hosoba S, Yamamoto M, Shioda K, Sago M, Koyama Y, Shimura T, et al. Safety and efficacy of minimalist approach in transfemoral transcatheter aortic valve replacement: insights from the Optimized transCathEter vAlvular interventioN-Transcatheter Aortic Valve Implantation (OCEAN-TAVI) registry. *Interact Cardiovasc Thorac Surg.* (2017) 26:420–4. doi: 10.1093/icvts/ivx355
19. Auffret V, Bedossa M, Boulmier D, Verhoye JP, Ruggieri VG, Koning R, et al. [From FRANCE 2 to FRANCE TAVI: are indications, technique and results of transcatheter aortic valve replacement the same?]. *Presse Med.* (2015) 44:752–60. doi: 10.1016/j.lpm.2015.05.004
20. Yamamoto M, Meguro K, Mouillet G, Bergoend E, Monin JL, Lim P, et al. Effect of local anesthetic management with conscious sedation in patients undergoing transcatheter aortic valve implantation. *Am J Cardiol.* (2013) 111:94–9. doi: 10.1016/j.amjcard.2012.08.053
21. Mayr NP, Hapfelmeier A, Martin K, Kurz A, van der Starre P, Babik B, et al. Comparison of sedation and general anaesthesia for transcatheter aortic valve implantation on cerebral oxygen saturation and neurocognitive outcome^T. *Br J Anaesth.* (2016) 116:90–9. doi: 10.1093/bja/aev294
22. Figulla HR, Webb JG, Lauten A, Feldman T. The transcatheter valve technology pipeline for treatment of adult valvular heart disease. *Eur Heart J.* (2016) 37:2226–39. doi: 10.1093/eurheartj/ehw153
23. Webb J, Gerosa G, Lefèvre T, Leipsic J, Spence M, Thomas M, et al. Multicenter evaluation of a next-generation balloon-expandable transcatheter aortic valve. *JACC* (2014) 64:2235–43. doi: 10.1016/j.jacc.2014.09.026
24. Leclercq F, Akodad M, Macia JC, Gandet T, Lattuca B, Schmutz L, et al. Vascular complications and bleeding after transfemoral transcatheter aortic valve implantation performed through open surgical access. *Am J Cardiol.* (2015) 116:1399–404. doi: 10.1016/j.amjcard.2015.08.003
25. Kadakia MB, Herrmann HC, Desai ND, Fox Z, Ogbara J, Anwaruddin S, et al. Factors associated with vascular complications in patients undergoing balloon-expandable transfemoral transcatheter aortic valve replacement via open versus percutaneous approaches. *Circ Cardiovasc Interv.* (2014) 7:570–6. doi: 10.1161/CIRCINTERVENTIONS.113.001030
26. Barbash IM, Barbanti M, Webb J, Molina-Martin De Nicolas J, Abramowitz Y, et al. Comparison of vascular closure devices for access site closure after transfemoral aortic valve implantation. *Eur Heart J.* (2015) 36:3370–9. doi: 10.1093/eurheartj/ehv417
27. Julinda M, David J, Mohamed AW, D RK, Hans T, Nina S, et al. One-year outcomes with two suture-mediated closure devices to achieve access-site haemostasis following transfemoral transcatheter aortic valve implantation. *EuroIntervention* (2016) 12:1298–304. doi: 10.4244/EIJV12I10A213
28. De Palma R, Settergren M, Rück A, Linder R, Saleh N. Impact of percutaneous femoral arteriotomy closure using the MANTATM device on vascular and bleeding complications after transcatheter aortic valve replacement. *Catheter Cardiovasc Interv.* (2018). doi: 10.1002/ccd.27595. [Epub ahead of print].
29. Sawaya FJ, Lefèvre T, Spaziano M, Roy A, Fernandez L, Garot P, et al. Transfemoral transcatheter aortic valve implantation: how minimalist can we become? *J Interv Cardiol.* (2016) 29:628–31. doi: 10.1111/joic.12348
30. Dato I, Burzotta F, Trani C, Crea F, Ussia GP. Percutaneous management of vascular access in transfemoral transcatheter aortic valve implantation. *World J Cardiol.* (2014) 6:836–46. doi: 10.4330/wjcv.v6.i8.836
31. Curran H, Chieffo A, Buchanan GL, Bernelli C, Montorfano M, Maisano F, et al. A comparison of the femoral and radial crossover techniques for vascular access management in transcatheter aortic valve implantation: the Milan experience. *Catheter Cardiovasc Interv.* (2014) 83:156–61. doi: 10.1002/ccd.24913
32. Jolly SS, Amlani S, Hamon M, Yusuf S, Mehta SR. Radial versus femoral access for coronary angiography or intervention and the impact on major bleeding and ischemic events: a systematic review and meta-analysis of randomized trials. *Am Heart J.* (2009) 157:132–40. doi: 10.1016/j.ahj.2008.08.023
33. Faurie B, Abdellaoui M, Wautot F, Staap P, Champagnac D, Wintzer-Wehekind J, et al. Rapid pacing using the left ventricular guidewire: reviving an old technique to simplify BAV and TAVI procedures. *Cathet Cardiovasc Intervent.* (2016) 88:988–93. doi: 10.1002/ccd.26666
34. Grube E, Naber C, Abizaid A, Sousa E, Mendiz O, Lemos P, et al. Feasibility of transcatheter aortic valve implantation without balloon pre-dilation: a pilot study. *JACC Cardiovasc Interv.* (2011) 4:751–7. doi: 10.1016/j.jcin.2011.03.015
35. Fiorina C, Maffeo D, Curello S, Lipartiti F, Chizzola G, D'Aloia A, et al. Direct transcatheter aortic valve implantation with self-expandable bioprosthesis: feasibility and safety. *Cardiovasc Revasc Med* (2014) 15:200–3. doi: 10.1016/j.carrev.2014.03.005
36. Spaziano M, Sawaya F, Chevalier B, Roy A, Neylon A, Garot P, et al. Comparison of systematic predilation, selective predilation, and direct transcatheter aortic valve implantation with the SAPIEN S3 Valve. *Can J Cardiol.* (2017) 33:260–8. doi: 10.1016/j.cjca.2016.09.007
37. Leclercq F, Robert P, Labour J, Lattuca B, Akodad M, Macia JC, et al. Prior balloon valvuloplasty versus DIRECT transcatheter Aortic Valve Implantation (DIRECTAVI): study protocol for a randomized controlled trial. *Trials* (2017) 18:303. doi: 10.1186/s13063-017-2036-y
38. Leclercq F, Lemmi A, Lattuca B, Macia JC, Gervasoni R, Roubille F, et al. Feasibility and safety of transcatheter aortic valve implantation performed without intensive care unit admission. *Am J Cardiol.* (2016) 118:99–106. doi: 10.1016/j.amjcard.2016.04.019
39. Mallikethi-Reddy S, Akintoye E, Telila T, Sudhakar R, Jagadeesh K, Briasoulis A, et al. Transcatheter aortic valve implantation in the United States: Predictors of early hospital discharge. *J Interv Cardiol.* (2017) 30:149–55. doi: 10.1111/joic.12373
40. Durand E, Eltchaninoff H, Canville A, Bouhazam N, Godin M, Tron C, et al. Feasibility and safety of early discharge after transfemoral transcatheter aortic valve implantation with the Edwards SAPIEN-XT prosthesis. *Am J Cardiol.* (2015) 115:1116–22. doi: 10.1016/j.amjcard.2015.01.546
41. Noad RL, Johnston N, McKinley A, Dougherty M, Nzewi OC, Jeganathan R, et al. A pathway to earlier discharge following TAVI: assessment of safety and resource utilization. *Catheter Cardiovasc Interv.* (2016) 87:134–42. doi: 10.1002/ccd.26005
42. Serletis-Bizios A, Durand E, Cellier G, Tron C, Bauer F, Glinel B, et al. A prospective analysis of early discharge after transfemoral transcatheter aortic valve implantation. *Am J Cardiol.* (2016) 118:866–72. doi: 10.1016/j.amjcard.2016.06.035
43. Lauck SB, Wood DA, Baumbusch J, Kwon JY, Stub D, Achtem L, et al. Vancouver transcatheter aortic valve replacement clinical pathway: minimalist approach, standardized care, and discharge criteria to reduce length of stay. *Circ Cardiovasc Qual Outcomes* (2016) 9:312–21. doi: 10.1161/CIRCOUTCOMES.115.002541

Conflict of Interest Statement: TL is proctor for edwards and Abbott vascular MA received research grants from Edwards Lifescience and Medtronic.

Copyright © 2018 Akodad and Lefèvre. This is an open-access article distributed under the terms of the Creative Commons Attribution License (CC BY). The use, distribution or reproduction in other forums is permitted, provided the original author(s) and the copyright owner(s) are credited and that the original publication in this journal is cited, in accordance with accepted academic practice. No use, distribution or reproduction is permitted which does not comply with these terms.